

6-2019

Anesthesiology Posters - 2019

Stanlies D'Souza

Nishal D'Souza MD

Brian Mason MD

Long-Chau Van DO

Ruth E. Ebert MD

See next page for additional authors

Follow this and additional works at: https://scholarlycommons.libraryinfo.bhs.org/research_education

 Part of the [Medicine and Health Sciences Commons](#)

Authors

Stanlies D'Souza, Nishal D'Souza MD, Brian Mason MD, Long-Chau Van DO, Ruth E. Ebert MD, Richard Nguyen MD, Lakshmi Madabhushi MD, Erica Tramontana DO, and Sarafina Kankam MD

Introduction

We describe a case of failed spinal anesthesia in a neonate after satisfactory successful spinal local anesthetic administration. We describe the risk factors for failed spinal anesthesia. Concerns about repeat spinal are also addressed.

Case description

A 4 month old, 4.4 kg female child, with cystic fibrosis and failure to thrive secondary to pancreatic insufficiency presented for laparoscopic assisted gastric tube placement. Her past medical history was significant for recurrent bronchiolitis with acute respiratory failure.

After induction of general anesthesia (GA), an intravenous line was obtained and spinal anesthetic was performed at L5-S1 level with 1mg/kg of hyperbaric bupivacaine. Patient was awakened and there was no block even after 20 min period.

A second spinal injection was administered at L4-L5 level. Second spinal was unsuccessful.

Surgery was successfully completed under GA and perioperative course was uneventful.

Case discussion

Neonatal spinal compared to adult spinal:

- Need larger dose due to large volume of cerebrospinal fluid (CSF) compared to adult
- Short duration of action due to rapid turnover of the CSF
- Spinal cord ends at a lower level compared to an adult. Spinal cord ends at the lower border of L1 in adults; in a newborn it ends at L3 level.

Dose of Neonatal spinal: 1 mg/kg of bupivacaine. Inguinal hernia repair is the most common operation performed under spinal anesthesia in a neonate.

Causes for failure of spinal anesthesia ^{1,2}

Unsuccessful lumbar puncture due to poor patient positioning or anatomical variability

Inadequate dosage

Loss of injectate

Misplaced injectate due movement of needle during injection

Inadequate intrathecal spread of successfully injected local anesthetic solution due to anatomical variability

Physiochemical incompatibility of adjunct solution due to alteration of pH (addition of vasoconstrictor solution)

Local anesthetic resistance due to mutation of the sodium channel

Management of failed spinal ^{1,2}

No block	General anesthesia Repeat spinal: Wait for 20 min and confirm that there is no block before attempting a repeat spinal
Patchy block	GA or intravenous sedation
Unilateral block	Postural adjustments, sedation or GA
Inadequate height	Postural adjustments, IV sedation, GA

Repeating the spinal block ^{1,2}

Confirm the complete failure of the spinal block and wait for 20 min before attempting a repeat spinal. In the event of patchy block or block with inadequate height, repeat spinal anesthetic block can result in high block and total spinal anesthesia. Total spinal anesthesia can result in respiratory and cardiovascular compromise.

Risk factors for Neurotoxicity following neuraxial blockade

1. Preexisting neuropathy
2. Spinal stenosis
3. Spinal cord compression due to disc herniation
4. Multiple attempts at spinal leading to spinal hematoma
5. Indwelling spinal micro catheters constantly delivering local anesthetic solution at a particular nerve root
6. Higher concentration of spinal local anesthetic (0.75% bupivacaine compared to 0.5% Bupivacaine) ³
7. Addition of vasoconstrictors ³

Conclusion

In our case we did a repeat spinal due to patient's respiratory condition which also did not work due to unknown reason.

In the absence of above known risk factors, spinal neurotoxicity is an unlikely event.

The concern of such repeat spinal is a high block, not neurotoxicity.

References:

1. Mechanism and management of failed spinal anesthesia: NYSORA continuing medical education
2. Fettes PDW, Jansson JR, Wildsmith JAW: Failed spinal anaesthesia: mechanisms, management, and prevention. British J Anaesth 2009; 102:739-48
3. Verlinde M, Hollmann MW, Stevens MF, Hermanns H, Werdehausen R, Lirk P: Local Anesthetic-Induced Neurotoxicity. International Journal of Molecular Sciences Int J Mol. Sci. 2016; 17 : 339

Introduction

Lennox-Gastaut syndrome is childhood epileptic encephalopathy characterized by intractable seizures resistant to antiepileptic medications. Here we describe a child with this syndrome who presented for gastroduodenoscopy.

Case Description

A 9-year-old male with Lennox-Gastaut syndrome with refractory seizures to antiepileptic therapy presented for gastroduodenoscopy for evaluation of gastroesophageal reflux disease. His history was significant for cerebral palsy, agenesis of corpus callosum, neurodevelopmental delay, sleep apnea, panhypopituitarism and cortical blindness due to septo-optic dysplasia. Panhypopituitarism was secondary to congenital absence of pituitary gland. Inhalation general anesthesia was induced with nitrous oxide, oxygen and sevoflurane and after securing an intravenous line, anesthesia was maintained with intermittent doses of propofol. Stress dose of hydrocortisone was intravenously administered prior to the procedure. Perioperative course was uneventful.

Clinical Features¹

- ✓ Epilepsy with frequent seizures
- ✓ Childhood epileptic encephalopathy
- ✓ Learning disability
- ✓ Delayed development of motor milestones
- ✓ Developmental delay

Case Discussion

- Lennox–Gastaut syndrome is a severe form of childhood epilepsy that typically begins at 3-5 years of age.¹
- Mode of inheritance: Most of the cases are sporadic with no family history.
- From 3 to 30% may have a family history of epilepsy.¹
- More common in males than females.¹
- Frequency: Accounts for 4% of all childhood epilepsy.¹
- Incidence: 1; 50,000-1:100,000.¹

Seizures in Lennox-Gastaut Syndrome¹

- Intractable seizures resistant to medications
- Usually brief, sometimes prolonged
- Seizures occur most often during sleep
- About 75% of the seizures are tonic-clonic
- Other types of seizures include atypical absence seizures
- Seizures are associated with complete or partial loss of consciousness
- Seizure leads to confusion and lack of alertness which may be prolonged
- Seizures may be associated with drop attacks with sudden loss of muscle tone

Pathophysiology¹

- No specific genes are identified
- Associated with pre-existing neurological condition.
- May result from brain injuries occurring before or during birth
- May be associated with cortical dysplasia
- May be a part of the genetic disorder tuberous sclerosis

Anesthetic Considerations²

1. Preoperative anxiety, child may not be cooperative for induction of anesthesia
2. Administer regular pre-operative anti-epileptic medication
3. No specific anesthetic considerations
4. Inhalational induction sevoflurane well tolerated
5. Propofol total intravenous anesthesia (TIVA) is well tolerated (Propofol has anti-epileptic activity)
6. Hepatic microsomal induction may need higher dose of drugs

Evidence of anesthetic management is limited to case reports.

CONCLUSION

No specific modification in anesthetic technique is needed and inhalational induction and maintenance of anesthesia with volatile anesthetic agents and nitrous oxide/air or TIVA is well tolerated as per case reports.² We managed this case successfully with such technique uneventfully.

References

1. Lennox-Gastaut syndrome: Genetic Home Reference.
2. Kapoor I, Rath GP: Anesthetic management of a child with Lennox–Gastaut syndrome with intractable epilepsy posted for intracranial surgery! J Pediatr Neurosci. 2016; 11: 290–91.

Introduction

This case involves the anesthetic management of a 15-year-old patient with thoracic aortic root dilatation presenting for multi-level spinal fusion for idiopathic scoliosis. The importance of perioperative hemodynamic monitoring and smooth arterial pressure management is emphasized in order to prevent aortic dissection.

Case Description

A patient with thoracic aortic root dilatation in Marfan Syndrome has an increased risk of perioperative aortic dissection, making strict control of blood pressure (BP) essential in the perioperative period. A 15-year-old, 92 kg male with Marfan Syndrome with thoracic aortic root dilatation presented for T3-L4 posterior spine instrumentation and fusion (PSIF). Preoperatively, he was started on losartan 50 mg, which was continued in the postoperative period. An arterial line was placed for close monitoring of BP in the intraoperative and postoperative period. We tightly controlled patient's BP during induction, intubation, intraoperative period, extubation and postoperatively.

Case Discussion

Cardiovascular manifestations of Marfan Syndrome¹

- ✓ **Thoracic aortic root dilatation: Usually asymptomatic, frequency 60-80%, aortic dissection is the most common complication. Dissection is rare in children under the age of 10.**
- ✓ **Pulmonary artery dilatation: Usually asymptomatic, frequency 75%, dissection is rare**
- ✓ **Mitral valve prolapse, mitral regurgitation: Palpitations are usual symptoms, frequency 50-70%, arrhythmias may be present**
- ✓ **Descending aorta dilatation: Usually asymptomatic, frequency 80-100%, increased risk of dissection in adults**
- ✓ **Tricuspid valve prolapse: Patients most commonly asymptomatic, incidence is around 4%**
- ✓ **Left ventricular dysfunction: Common presenting symptom is dyspnea. Frequency is 100%, initially diastolic and may progress to systolic dysfunction.**

Medical therapy to prevent Progression of Aortic Root dilatation and Aortic Dissection¹

1. Beta blockers are the main mode of therapy²
2. Calcium channel blockers
3. Angiotensin converting enzyme inhibitors
4. Angiotensin receptor blockers

Indication for Aortic Root Replacement Surgery in Thoracic Aortic Root Dilatation³

1. Thoracic root diameter > 5 cm
2. Progressive dilatation > 1 cm/year
3. Progressive aortic regurgitation

Management Strategy for Patients with Marfan Syndrome with Thoracic Root Dilatation presenting for Major Surgery

1. Close hemodynamic monitoring with invasive arterial line
2. Avoid acute hemodynamic changes
3. Continue the elective antihypertensive therapy in the perioperative period

CONCLUSION

In our case of multi-level posterior spinal fusion for idiopathic scoliosis, we continued losartan in the perioperative period and avoided swings in blood pressure during critical times in the perioperative period.

INTRODUCTION

Adequate preparation with alpha blockade is important in a patient presenting for pheochromocytoma resection. Use of vasopressin is indicated to treat intraoperative hypotension refractory to alpha agonistic agents. Clevidipine is a new, novel agent effective in the management of hypertensive episodes.

CASE DESCRIPTION

A 75- year- old with left adrenal mass, hypertension and atrial fibrillation with elevated metanephrine and normetanephrine was diagnosed with pheochromocytoma. Adequate preoperative alpha blockade was established with oral doxazocin. General anesthesia with endotracheal tube was performed for laparoscopic left adrenalectomy. Perioperative blood pressure was closely monitored with an arterial line. Hypotension in the post-induction period was effectively managed with vasopressin. Hypertension during resection and hypotension following resection were not encountered as this patient was adequately alpha- blocked preoperatively.

P R E - O P

CLINICAL FEATURES:	Headaches, Palpitations, Diaphoresis , Severe Hypertension , Postural Hypotension, Tachyarrhythmias, Diabetes mellitus, Pallor, Weight Loss, Cardiomyopathy
PREFERRED DIAGNOSTIC TESTS for Pheochromocytoma (per Task Force of the Endocrine Society):¹	1. Plasma metanephrine: Sensitivity 96%, specificity 85% 2. 24-hr collection of urinary catecholamines: Sensitivity 87.5%, specificity 99.7%
PREOPERATIVE PREPARATION:	1. Initiate alpha blockage 10-14 days before surgery 2. Initiate beta blockade only after complete alpha blockade
ALPHA BLOCKERS for preoperative preparation:^{2,3}	1. <u>Phenoxybenzamine</u> : Non-selective; prolonged half-life; causes reflex tachycardia; should be stopped within 24-48 hours 2. <u>Doxazocin</u> : Selective Alpha 2 antagonist; doesn't cause reflex tachycardia; reduced incidence of intraop hypertension and postop hypotension
PREOPERATIVE OBJECTIVES for adequate alpha blockade:²	1. Control hypertension. 2. Reverse circulating blood volume. 3. Control heart rate and arrhythmia. 4. EEG free of ST segment and T wave changes. 5. Reverse hyperglycemia and electrolyte abnormalities.
PREOPERATIVE TARGETS of adequate alpha blockade:²	1. In-hospital blood pressure below 160/90 mmHg for 24 hours prior to surgery. 2. No orthostatic hypotension with blood pressure <80/45 mmHg. 3. EKG free of ST and T wave changes for one week prior to surgery. 4. Fewer than five (5) premature ventricular contractions per minute.

DRUGS TO AVOID INTRAOPERATIVELY^{2,3}

(Laparoscopic adrenalectomy is currently the surgical method of choice)

✓ Histamine releasing drugs (morphine, atracurium)

✓ Vagolytic agent (pancuronium)

✓ Ketamine

CRITICAL PERIODS OF HEMODYNAMIC CHANGES DURING RESECTION^{2,3}

✓ *Catecholamine surge leading to hypertensive episode:* Laryngoscopy; peritoneal insufflation; tumor manipulation

✓ *Hypotension due to catecholamine decline:* Tumor ligation

ANESTHETIC GOALS^{2,3}

1. Avoid or reduce catecholamine release due to surgical and anesthetic techniques

2. Avoid drugs that release catecholamines or histamines

3. Minimize the hypertensive response during tumor handling.

4. Minimize the hypotensive response following tumor resection.

PHARMACOLOGICAL AGENTS TO CONTROL HEMODYNAMIC CHANGES DURING SURGERY⁵

CLEVIDIPINE is effective in controlling hypertension during tumor handling. VASOPRESSIN is the agent of choice to treat hypotension resistant to alpha adrenergic agonistic agents.

CONCLUSION

Preoperatively, adequate selective alpha2 blockade with doxazocin minimizes hypertensive and hypotensive episodes during pheochromocytoma resection.³

Introduction

We describe a case of management of emergence agitation in a nonverbal developmentally delayed anxious child without an intravenous line in the postoperative care unit (PACU).

Case description

A 6 year old, morbidly obese, 77 kg male, non-verbal with developmental delay and autism presented for resection of in-growing toe nail. He had oral midazolam preoperatively and was cooperative for inhalational induction with nitrous oxide, oxygen and sevoflurane.

After securing an intravenous (IV) line after induction, laryngeal mask airway (LMA) was placed and anesthesia was maintained with sevoflurane, fentanyl and local digital block. Propofol was administered pre-emptively for emergence agitation at the time of removal of the LMA under deep anesthesia. Patient became combative in PACU and IV was lost.

Emergence agitation was successfully managed with intramuscular lorazepam and haloperidol.

Case discussion

Risk factors for pre-op anxiety¹

- Preschool children
- No siblings
- Shy or inhibited children
- High IQ with poor social adaptive abilities
- Divorced or separated parents
- Prior bad experience with surgical experience
- Poor child-parent relationship

Risk factors for emergent agitation²

1. Preoperative anxiety
2. Preschool children
3. Sevoflurane anesthesia
4. Pain

Options to manage pre-op anxiety in our child²

1. Parental presence at induction
2. Oral midazolam
3. Oral Lorazepam
4. Oral ketamine
5. Oral Clonidine
6. Oral Dexmedetomidine

Factors not associated with increased incidence of emergence agitation²

- Rapid emergence from anesthesia
- Depth of anesthesia
- Duration of anesthesia
- Emergence agitation from a prior anesthetic
- Type of surgery provided pain is well controlled

Prevention of emergence agitation^{2,3}

1. Propofol 1mg/kg at the time of emergence
2. Fentanyl IV
3. Dexmedetomidine IV²
4. Clonidine 1V²
5. Ketamine IV

REFERENCES:

1. Kar SK, Ganguly T, Dasgupta CS, Goswami A: Translational Biomedicine 2015; 6:30
2. Costi D, Cyna AM, Ahmed S, Stephens K, Strickland P, Ellwood J, Larsson JN, Chooi C, Burgoyne LL, Middleton P. Effects of sevoflurane versus other general anaesthesia on emergence agitation in children. Cochrane Database of Systematic Reviews 2014: CD007084
3. A. Pickard P. Davies K. Birnie R. Beringer: Systematic review and meta-analysis of the effect of intraoperative α 2-adrenergic agonists on postoperative behaviour in children. British J Anaesth 2014; 112:982-90
4. Lee YC, Kim JM, Ko HB, Lee SR: Use of laryngeal mask airway and its removal in a deeply anaesthetized state reduces emergence agitation after sevoflurane anaesthesia in children. J Int Med Res. 2011; 39:2385-92

Assess the patient for potentially dangerous causes of agitation in PACU

Hypoxia, Hypoglycemia, Pain, Hypercarbia

Factors of unproven benefit in the management of emergence agitation²

1. Parental presence
2. Midazolam
3. Dexmedetomidine PO

Management of emergence delirium in a patient with lost IV in PACU

1. IM Benzodiazepines, Lorazepam/Midazolam
2. IM Haloperidol
3. IM Dexmedetomidine
4. Induction of general anesthesia and insertion of IV

Deep removal of LMA vs awake extubation of endotracheal tube⁴

The incidence of emergence agitation is lower when LMA is removed deep compared to awake extubation of an endotracheal tube anesthesia.

Conclusion: In the absence of an IV In our case, we successfully managed emergence agitation with intramuscular lorazepam and haloperidol.

Introduction^{3,5}

Hemophilia refers to an inherited bleeding disorder caused by deficiency of coagulation factor VIII (hemophilia A), factor IX (hemophilia B), or factor XI (hemophilia C). Hemophilia A and B are X-linked recessive diseases that present in male children of carrier females.^{3,4}

Hemophilia A – Inherited deficiency of factor VIII; an X-linked recessive disorder⁴.

Case description

Patient is a 5-year-old male with severe factor VIII deficiency initially diagnosed, at age 3, as severe oral bleeding following a lip laceration. His factor VIII was less than 1%. Consequently, patient had been on "on demand" replacement but, due to an increase in bleeds, is being switched to prophylaxis. The main joints affected are the elbows, knees and ankles. Because of the increasing need for home factor infusion, a Port-A-Cath is being placed. His disease is considered severe. The known duration is approximately two years and is associated with spontaneous hemarthroses and bleeding. It is ameliorated with factor replacement. Patient is to receive Recombinant factor VIII 500 units IV twice a week (approximately 18 U/kg).

Before the procedure, patient received approximately 50 U/kg of recombinant factor VIII immediately before the port placement. He was intubated with an LMA and had no excessive bleeding during the procedure.

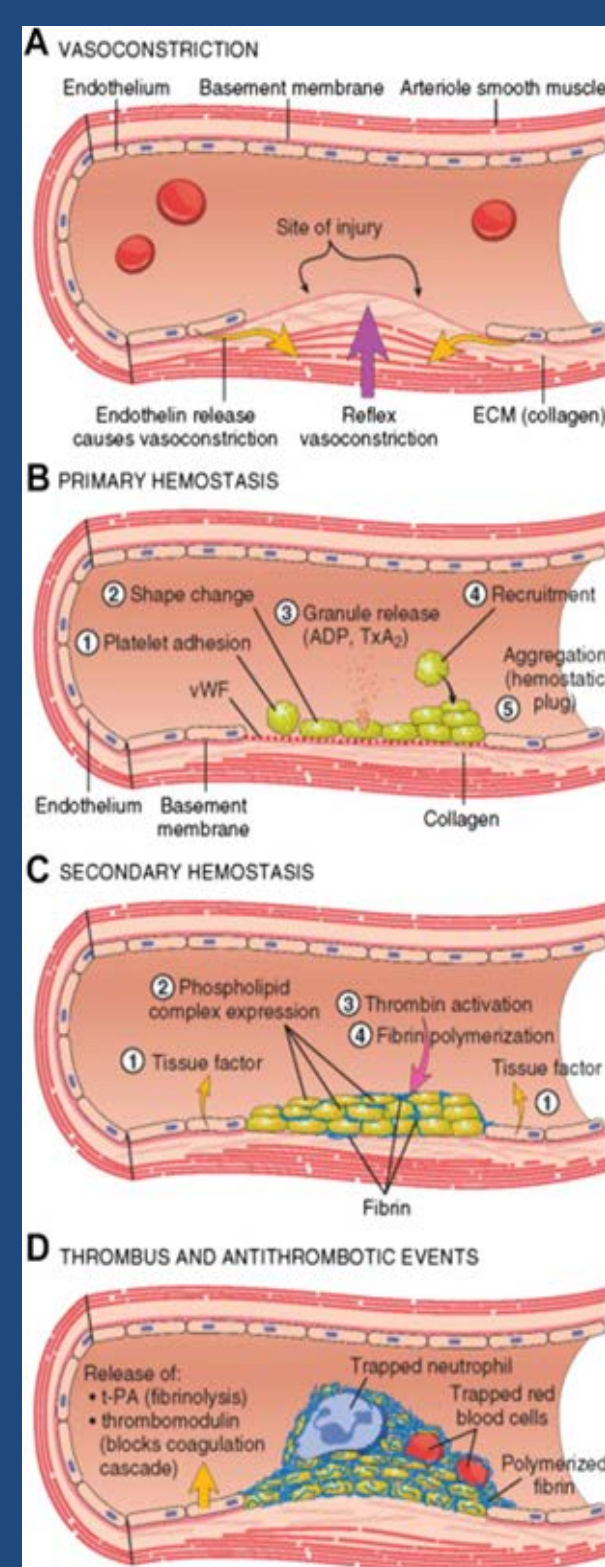


Fig. 1. Source: Bhat R, Cabey W. Evaluation and Management of Congenital Bleeding Disorders.⁶ Downloaded from Clinical Key. Accessed Sept 22, 2018.

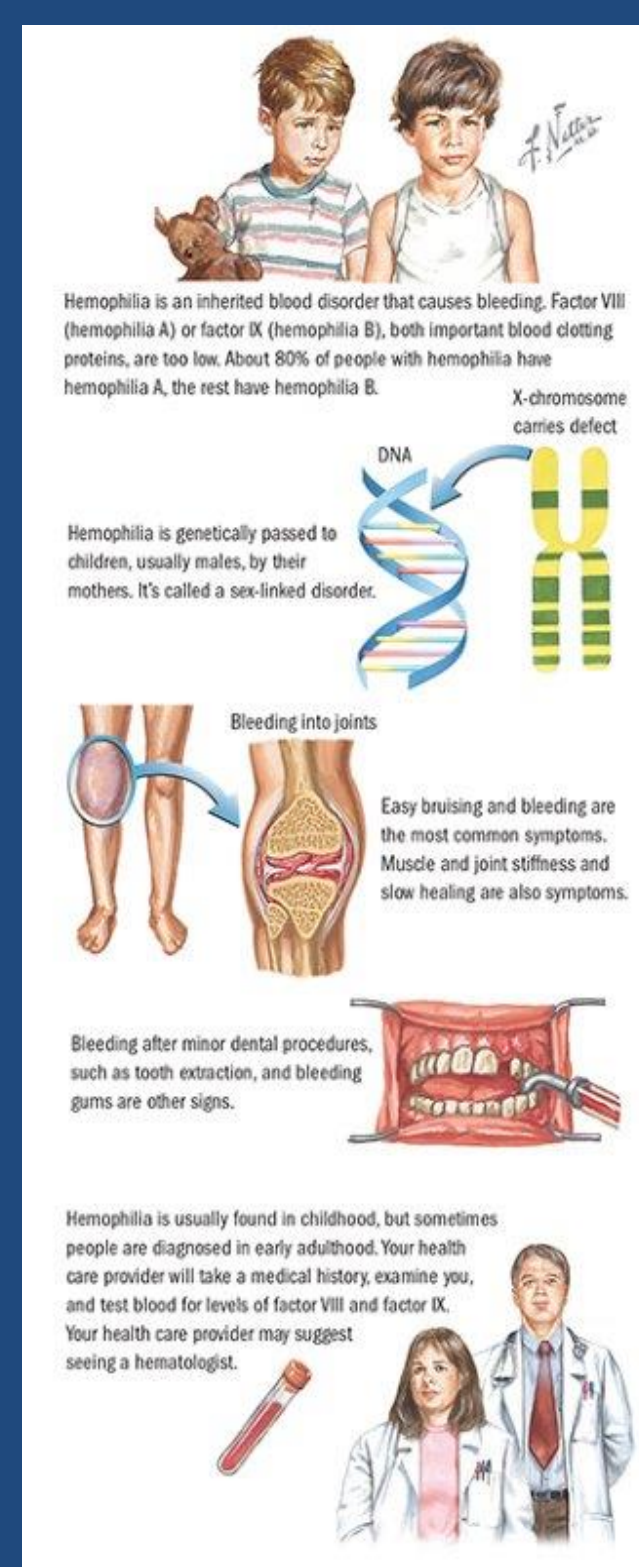


Fig. 2. Source: Managing Your Hemophilia.. Copy right © 2016 by Saunders, an imprint of Elsevier, Inc. Downloaded from ClinicalKey. Accessed Sept. 22, 2018.

Factor Replacement

→Purified factor products are the 1st choice and should be used whenever possible to avoid potential transfusion-transmitted infection and transfusion reactions.^{2,4}

→However, other blood products like Cryoprecipitate can also be used. One bag of Cryoprecipitate is made from approximately 250 mL of fresh frozen plasma (FFP) and contains approximately 70 to 80 units of factor VIII in a volume of 30 to 40 mL (approximately 3 to 5 units/mL).²

→FFP is deemed an inadequate choice for factor replacement because 1mL of FFP contains 1unit of factor activity. A dose of 15 to 20 mL/kg will raise the factor VIII level by approximately 30 to 40 percent. This amounts to lots of bags of FFP to get the desired factor amount, which consequently exposes patient to possible fluid overload, transfusion infections and reactions.^{1,2}

Therapies other than factor replacement^{1,2,4}

Therapies	Use	DOSAGES
Tranexamic Acid (TXA)	Inhibit fibrinolysis by inhibiting plasminogen activation in the fibrin clot, thereby enhancing clot stability.	25 mg/kg every 6-8 hours
Epsilon Aminocaproic Acid (EACA)	Same as above	75-100 mg/kg every 6 hours, max 3-4g
Desmopressin (DDAVP)	Increases factor VIII level two-four fold. Not effective for patients with severe hemophilia A (Factor VIII activity <1%).	0.3 mcg/kg (max, 20 mcg/kg), IV or nasal

REFERENCES

1. Srivastava A, Brewer AK, Mauser-Bunschoten EP et al; Treatment Guidelines Working Group on Behalf of The World Federation Of Hemophilia . *Haemophilia*. 2013;19(1):e1-47.
2. Hoots KW. Emergency management of hemophilia. In: Textbook of Hemophilia, 3rd ed, Lee CA, Berntorp EE, Hoots WK (Eds), John Wiley & Sons, Ltd, 2014. p.463.
3. Blanchette VS, Key NS, Ljung LR, et al; Subcommittee on Factor VIII, Factor IX and Rare Coagulation Disorders of the Scientific and Standardization Committee of the International Society on Thrombosis and Hemostasis. Definitions in hemophilia: communication from the SSC of the ISTH. *J Thromb Haemost*. 2014;12(11):1935-9.
4. Shetty S. Hemophilia - diagnosis and management challenges. *Molecular Cytogenetics*. 2014;7(Suppl 1):144. doi:10.1186/1755-8166-7-S1-144.
5. Tuddenham E. (2014). In search of the source of factor VIII. *Blood*. 2014;123(24), 3691. https://doi.org/10.1182/blood-2014-05-568857. Accessed August 22, 2018.
6. Bhat R, Cabey W. Evaluation and Management of Congenital Bleeding Disorders. In: Hematology/Oncology Clinics of North America. 2017; 31(6):1105-1122.

Discussion

Hemophilia A (factor VIII deficiency) is an X-linked coagulation factor disorder associated with bleeding of variable severity, from life-threatening to clinically silent.¹

Factor VIII deficiency/Hemophilia A affects 1 in 5000 to 10,000 males; roughly 60 percent have severe disease, with factor VIII activity less than 1 percent of normal.^{1,2}

The factor VIII gene is located on the X chromosome. It is one of the largest known genes. It circulates in plasma with von Willebrand factor. Cleavage of factor VIII by thrombin or factor Xa is necessary to activate factor VIII and allow it to participate in the intrinsic pathway. Activated factor VIII is inactivated by activated protein C in conjunction with proteins.^{3,4,5}

In patients with hemophilia with acute bleeding, the immediate goal is to raise the factor activity to a level sufficient to achieve hemostasis.²

For severe bleeding, the factor activity level should be maintained above 50 percent at all times.

An initial dose of 50 units/kg to raise the factor VIII level to 100 percent should be given. The second and subsequent doses are given at intervals of approximately one half-life of the infused product for that patient. A typical half-life for standard half-life factor VIII products is approximately 8 to 12 hours.^{2,3}

For patients who require perioperative factor administration, the initial dose should be timed to provide maximal coverage at the time of greatest bleeding risk (or, typically, 30 to 60 minutes before the procedure). The dose is calculated from the patient's weight, baseline factor level, desired factor level, volume of distribution, and presence of an inhibitor.^{2,5}

Conclusion

- Perioperative management of Factor VIII deficiency, is dependent on the severity of the factor deficiency as well as the type of procedure being performed.^{1,3}
- Factor VIII replacement with recombinant Factor VIII, 30 minutes before surgery, is the preferred method of treatment; however, alternative forms of replacement, factor related and otherwise, can be implemented.^{2,4}
- Depending on the surgery, factor replacement should be given before and after surgery, as surgeries with a lot of blood loss deplete Factor VIII faster.^{2,3,5}

INTRODUCTION

Spinal anesthesia in neonate is used primarily to reduce immediate pain perioperatively as well as post-operative apneic complications due to opioid use.

CASE DESCRIPTION

A 4.7 kg 6-week old male born full-term with no prior medical history, presented for an incarcerated left inguinal hernia needing repair. In the quest to reduce the exposure of general anesthesia as well as apneic episodes from opioid in this neonate, surgical procedure under spinal anesthesia was implemented.

Method: Patient was brought into the operating room (OR) and placed in the left lateral decubitus position on the OR table. Patient's back was clean with chlorohexidine and draped afterwards. Skin infiltration with local anesthetic was used before the single spinal injection of 0.6ml of 0.75% bupivacaine was placed at the L5-S1 level. Patient was then laid on his back and surgery ensued. The spinal anesthesia was adequate for the duration of the surgery and perioperative course was uneventful.

Benefits of Using Spinal Anesthesia in Neonates

- ✓ Neuraxial analgesia may improve postoperative outcomes for high-risk neonates who are susceptible to respiratory complications (e.g. preterm born neonates with lung disease and postoperative apnea). Less post-operative apnea from opioid use.²
- ✓ Analysis of four trials comparing spinal and general anesthesia in neonates born preterm undergoing inguinal herniorrhaphy found a reduction in the incidence of postoperative apnea only if systemic sedatives were avoided.²
- ✓ Minimize the exposure of the developing brain to general anesthesia
- ✓ Exposure to general anesthesia reduces excitation (NMDA antagonists) or enhances inhibition (GABA agonists), may trigger excessive apoptosis in many brain areas.
- ✓ It has been suggested that spinal anesthesia can reduce costs related to postoperative monitoring and hospitalization.
- ✓ Attenuation of stress response.
- ✓ Cardiac stability
- ✓ Reduction in hospital stay
- ✓ Improved surgical outcome

Adverse effects of spinal anesthesia of the types commonly seen in adults—hypotension, bradycardia, postdural puncture and transient radicular symptoms—are less common in children.²

Fig. 1. Sitting or lateral position for spinal anesthesia procedure.

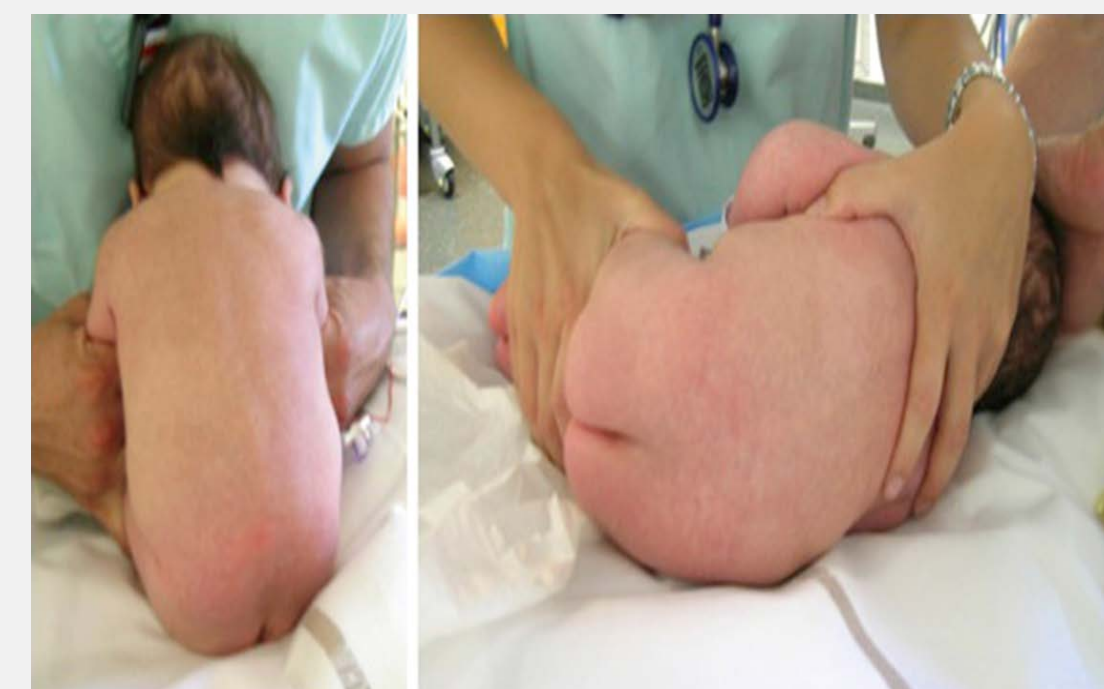

Image Source: Dadure C, Sola C, Dalens B, Capdevila X. Regional Anesthesia in Children. In: Miller's Anesthesia, 8th edition, Chap. 92, Fig. 92-9, p.2706-2756.e7. Downloaded from ClinicalKey.

Fig. 2. Spinal anesthesia procedure in sitting position in 1-month-old girl.

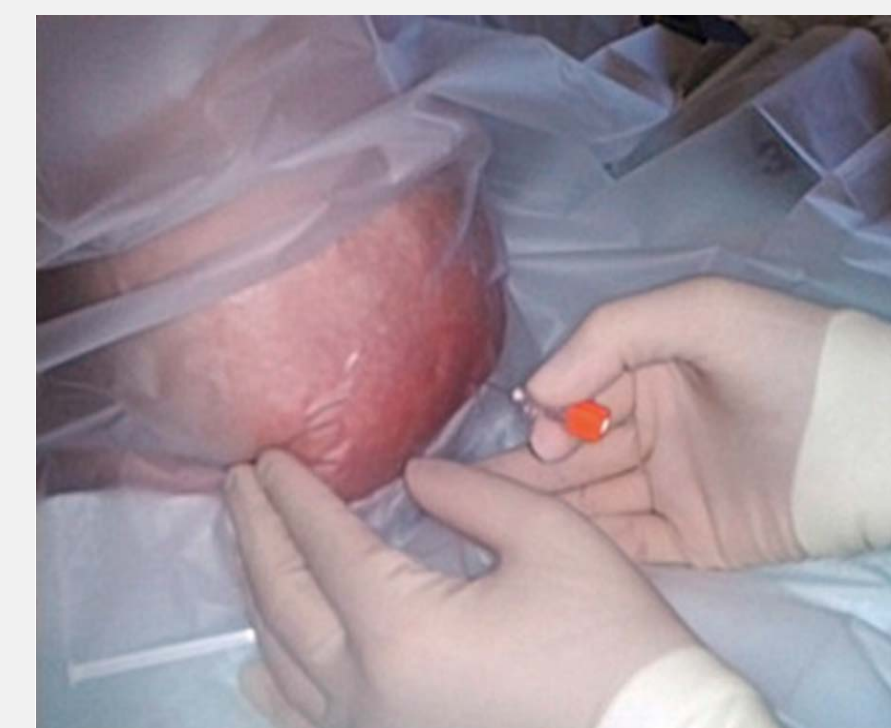

Image Source: Dadure C, Sola C, Dalens B, Capdevila X. Regional Anesthesia in Children. In: Miller's Anesthesia, 8th edition, Chap. 92, Fig. 92-8, p.2706-2756.e7. Downloaded from ClinicalKey.

DISCUSSION

- Neuraxial agents provide full-bodied pain control, have the potential to improve outcomes, and are an important component of the perioperative care of children.²
- The control of afferent traffic through neuraxial interventions (epidural or intrathecal delivery) can be utilized in neonates and infants as a sole neuraxial anesthetic technique for abdominal and lower limb surgery or as a supplement to reduce intraoperative general anesthetic requirements and manage peri-operative pain.¹
- "Single shot" spinal anesthesia provides an alternative to general anesthesia for lower abdominal or inguinal surgery.³
- The clinical utility of this technique is limited by the duration of action of intrathecal local anesthetics in neonates however, and conversion to general anesthesia is often required if surgical duration exceeds one hour.¹

CONCLUSION

- ❖ **Neuraxial agents provide robust pain control, have the potential to improve outcomes, and are an important component of the perioperative care of children.¹**
- ❖ **Neonates need a larger dose of neuraxial anesthetic due to high cerebrospinal fluid (CSF) volume and the duration of action is shorter due to rapid turnover of the CSF compared to an adult.**

REFERENCES

1. Stratmann G. Review article: neurotoxicity of anesthetic drugs in the developing brain. *Anesth Analg.* 2011;113:1170–9. [PubMed]
2. Walker SM, Yaksh TL. Neuraxial Analgesia In Neonates And Infants: Review of Clinical and Preclinical Strategies for the Development of Safety and Efficacy Data. *Anesthesia and analgesia.* 2012;115(3):638–662. doi:10.1213/ANE.0b013e31826253f2.
3. Dadure C, Sola C, Dalens B, Capdevila X. Regional Anesthesia in Children. In: Miller's Anesthesia, 8th edition, Chap. 92, p.2706-2756.e7.

Introduction

Acute surgical pain management in the perioperative period for scheduled surgical procedure is challenging as there are no consensus guidelines for buprenorphine/naloxone (Suboxone®) use in the perioperative period. Here we present management of such a patient who presented to surgery with Suboxone® use on the day of the surgery.

Case Description

A 44-year-old woman on 12 mg Suboxone® per day with past history of narcotic addiction, with radiculopathy secondary to C3-4 disc herniation, presented for anterior cervical discectomy and fusion. She received oral acetaminophen preoperatively. During general anesthetic with endotracheal intubation, her multimodal pain management plan included intraoperative intravenous administration of fentanyl, ketorolac, dexmedetomidine bolus followed by infusion, lidocaine bolus followed by infusion, magnesium infusion, ketamine and postoperative administration of Suboxone®. She was comfortable in the postoperative period.

Case Discussion

Characteristics of Suboxone® (buprenorphine/naloxone)¹

Suboxone® is an alternate mode of pain management in the opiate dependent. As per Cochrane database review, It is equally as effective as methadone.²

BUPRENORPHINE:

- ✓ Partial Mu receptor agonist
- ✓ High affinity to Mu receptor
- ✓ 1000 times more potent compared to morphine in its affinity to Mu receptor
- ✓ Slowly dissociates from Mu receptors
- ✓ Partial Kappa receptor antagonistic activity
- ✓ 1000 times more potent at Kappa receptor activity
- ✓ 1000 times more potent than morphine at Kappa receptor antagonistic activity
- ✓ It displaces other opiate agonists such as fentanyl, hydromorphone, methadone or morphine
- ✓ Has ceiling effect due to partial agonistic activity at Mu receptor
- ✓ Greater safety profile in the event unintentional overdose compared to other opiates
- ✓ Less respiratory depression compared to other opiates
- ✓ Low potential for abuse or physical dependence

NALOXONE:

- ✓ Naloxone is added to reverse the effect of intravenous opiate abuse.

Pain management options in a patient on Suboxone®¹

- Stop Suboxone® and add full opiate agonist preoperatively
- Continue Suboxone® and add high dose opiates to the pain management regimen
- Continue Suboxone® and give it additionally in the perioperative period

Multimodal Pain Management Approach in Patient on Suboxone®

There is no consensus about how to manage acute pain in a patient on Suboxone®. However, a multimodal approach should be considered for acute pain management in surgical patients.

- ✓ Regional anesthesia: Peripheral nerve blocks or neuraxial blockade
- ✓ High dose opiates
- ✓ Intravenous lidocaine
- ✓ Gabapentin or pregabalin
- ✓ Non-steroidal anti-inflammatory drugs
- ✓ Acetaminophen
- ✓ Ketamine
- ✓ Magnesium

CONCLUSION

We successfully managed the pain in the perioperative period with a multimodal approach using high dose fentanyl, intravenous acetaminophen, ketorolac, magnesium, ketamine and lidocaine.

References

1. Jonan AB, Kaye AD, Urman RD: Buprenorphine Formulations: Clinical best practice strategies recommendations for perioperative management of patients undergoing surgical or interventional pain procedures. *Pain Physician* 2018; 21:E1-E12
2. Nielsen S, Larance B, Degenhardt L, Gowing L, Kehler C, Lintzeris N: Opioid agonist treatment for pharmaceutical opioid dependent people. *Cochrane Database Syst Rev.* 2016; 9:CD011117

Introduction

An anterior mediastinal mass may compress the major airway and may result in total compression during induction of anesthesia. Identification of airway compression warning signs preoperatively and adequate preoperative preparation for airway management in the event of total airway compression is a vital part of anesthetic technique in the anesthetic management of a patient with large anterior mediastinal mass.

Case description

A 74 year old woman with an anterior mediastinal mass with total obstruction of the left main stem bronchus presented for flexible bronchoscopy. Her imaging studies showed a large lobulated mediastinal mass measuring 15 cm X 13 cm X 12cm with complete obstruction of left main stem bronchus with opacification of left hemithorax secondary to atelectasis of the left lung. An underlying pleural effusion is also a contributory factor for this opacification.

A gentle induction of general anesthesia (GA) was performed with a combination of propofol and sevoflurane, with patient breathing spontaneously. After confirming easy mask ventilation, rocuronium was administered and the airway was easily secured with an endotracheal tube with direct laryngoscopy.

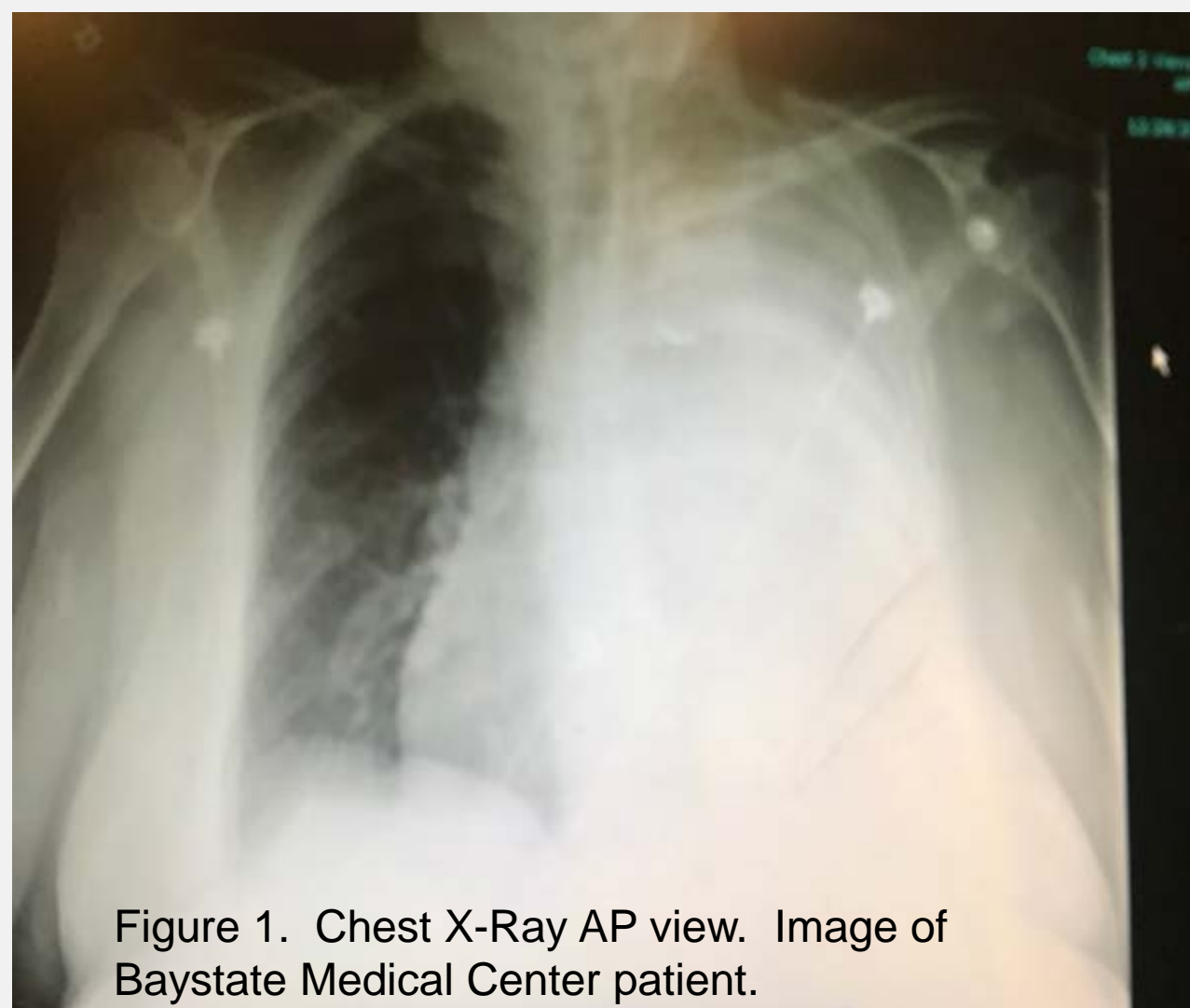


Figure 1. Chest X-Ray AP view. Image of Baystate Medical Center patient.

Case discussion

Mediastinal components¹

- **Anterior** Thymus, Lymph nodes and fat
- **Middle** Heart, Pericardium, Aorta, vena cava, pulmonary vessels, lymph nodes, fat
- **Posterior** Aorta, thoracic duct nerves, azygos vein, hemiazygos vein, lymph nodes, fat

Anterior mediastinal masses^{1, 2}

- **Boundaries:** Anteriorly by sternum, posteriorly by brachiocephalic vessels, pericardium and aorta
- **Contents :** Thymus, lymph nodes and fat

Anterior Mediastinum¹

Benign:

- Thymoma
- Thymic cyst
- Thymic hyperplasia
- Thyroid
- Cystic hygroma

Malignant:

- Lymphoma
- Thymic carcinoma
- Seminoma
- Thyroid carcinoma
- Metastatic lung carcinoma

Preoperative warning signs:²

- Dyspnea
- Inability to assume supine position
- Signs airway compromise on chest X-ray and CT scan
- Hypoxia with supplemental oxygen

Warning signs on CT:

- Narrowing of trachea or major bronchi
- Atelectasis of whole lung / one or more lobes

Unique preparation for a patient with a large mediastinal mass with airway compromise:²

- Rigid bronchoscope for high frequency ventilation
- Thoracic surgeon standby
- Cardiopulmonary (CPB) bypass standby
- ECMO standby

Possible Reasons for opacification of left hemithorax in our case:

1. Atelectasis due to left main stem bronchial obstruction
2. Atelectasis due to endobronchial extension
3. Underlying pleural effusion

Other considerations:²

1. Flow volume loops show variable intrathoracic obstruction. CT is diagnostic and preferable over flow volume loops
2. Start intravenous line in lower extremity in the presence of superior vena cava obstruction
3. Initiate ECMO or CPB cannulation under sedation prior to induction

Airway management techniques:

1. Awake fiberoptic intubation
2. Inhalational induction with patient breathing spontaneously

Specialized endotracheal tubes for airway management:


1. Reinforced endotracheal tube
2. Long microlaryngoscopy tubes
3. Double lumen tubes

Airway Management techniques for possible airway compression post induction:²

1. Pass the reinforced endotracheal tube distal to the obstruction,
2. Rigid bronchoscopy and high frequency ventilation
3. Endobronchial stent placement
4. Cardiopulmonary bypass
5. ECMO

CONCLUSIONS

Maintenance of spontaneous ventilation during induction of general anesthesia is paramount in a patient with airway compromise with an anterior mediastinal mass. In our patient we were able to intubate while maintaining spontaneous ventilation and after confirming of adequate ventilation we administered non depolarizing muscle relaxant.



INTRODUCTION

Arthrogryposis is a spectrum of disorders characterized by persistent multiple limb contractures. It is often associated with myopathies, spinal muscular atrophy, and hypotonia.

Due to the abnormal craniofacial features along with severe limb and neck contractures, patients with Arthrogryposis syndromes often present with difficult airway management, intravenous (IV) line placement, neuraxial technique and patient positioning.

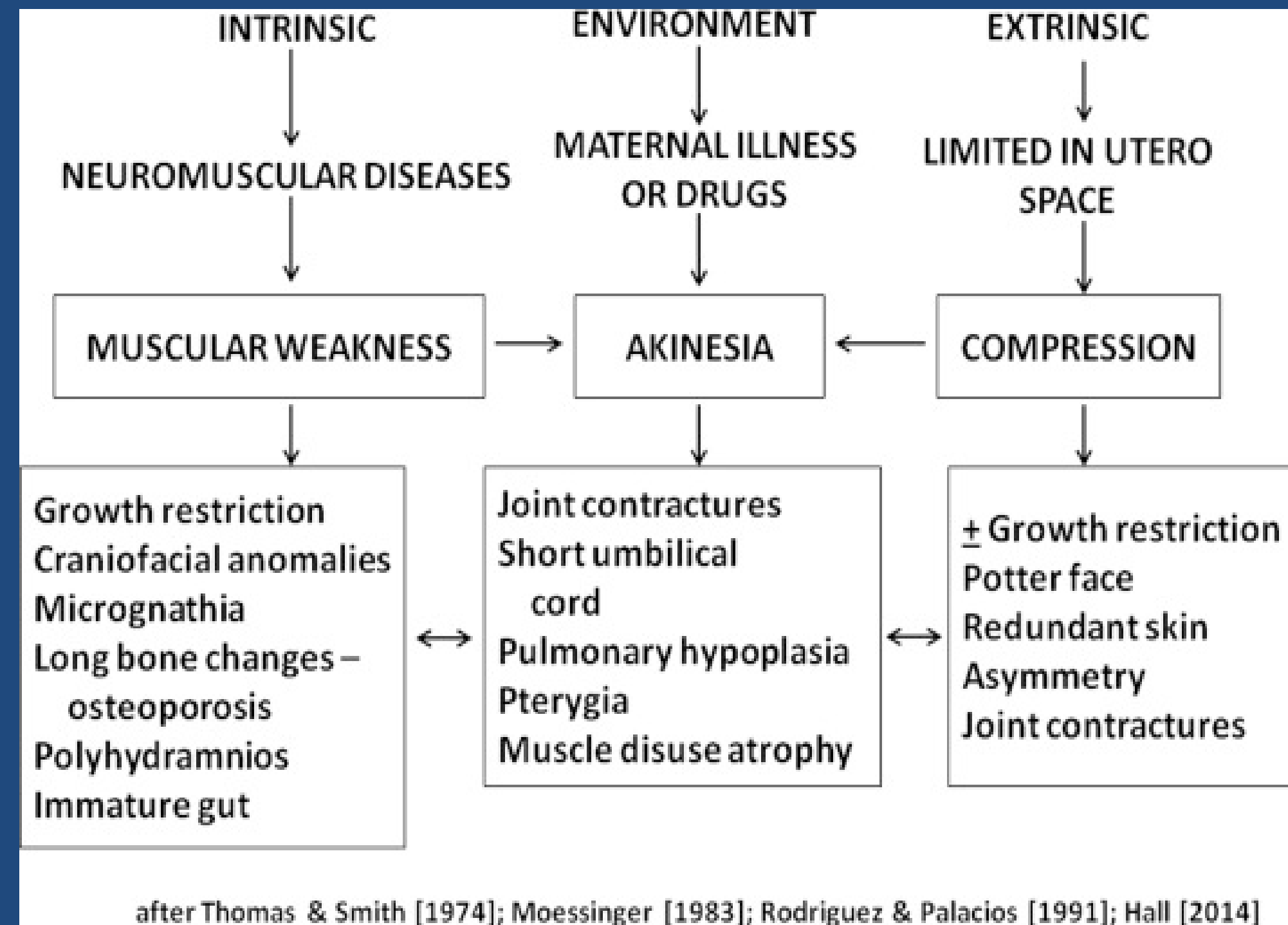
CASE DESCRIPTION

A 9-year-old female with history of congenital bilateral talipes equinovarus with underlying Arthrogryposis syndrome status post triple arthrodesis presented for bilateral cast removal and short leg cast application.

The patient received inhalation masked induction with sevoflurane and nitrous oxide. A Laryngeal Mask Airway (LMA) was placed after successful placement of left hand peripheral IV. General anesthesia was maintained with sevoflurane inhalation. Patient's temperature was monitored closely during the intraoperative period.

Her perioperative course was uneventful and patient was discharged home same day of surgery.

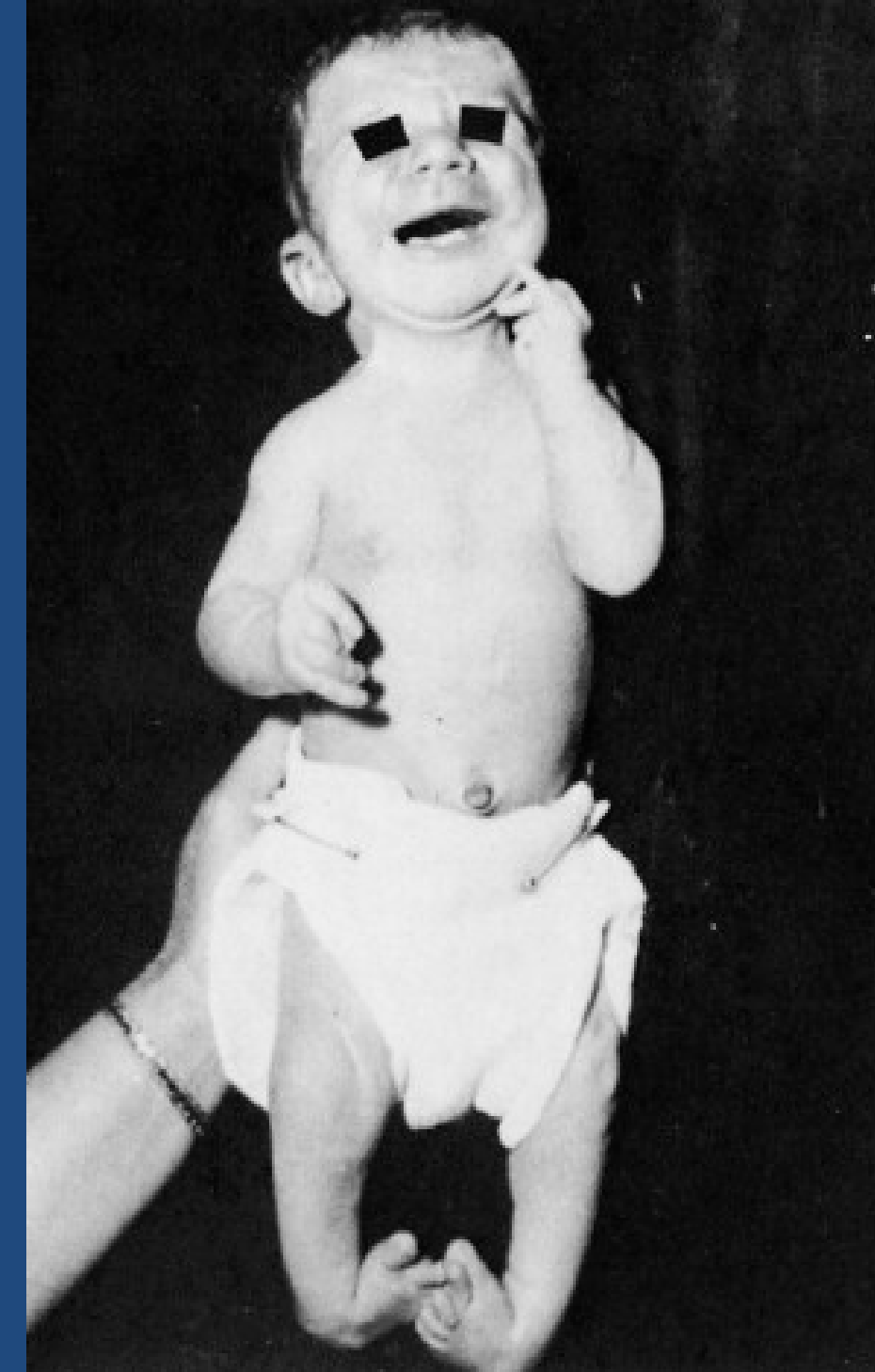Figure 1: Mechanism of Secondary Effects of Fetal Akinesia⁵



Hall, J. Arthrogryposis (multiple congenital contractures): Diagnostic approach to etiology, classification, genetics, and general principles. *European Journal of Medical Genetics*. July 2014. Image obtained from Clinical key.

Figure 2. Distal Arthrogryposis Type I⁶

Note predominant distal contractures, with overlapping finger contractures, ulnar deviation, and clubfeet.



Hall, J. et al. Emery and Rimoin's Principles and Practice of Medical Genetics. Arthrogryposes (Multiple Congenital Contractures). Figure 161-2. Jan 2013. Image obtained from Clinical Key.

DISCUSSION

Most Arthrogryposis Syndrome cases are of sporadic inheritance. Incidence varies from 0.3-3 cases per 1000 live births.¹

- Arthrogryposis Multiplex Congenita (AMC), most severe arthrogryposis syndrome, are characterized by multiple joint contractures with coexisting comorbid multisystem disease such as pharyngeal, cardiac, urologic, and gastric abnormalities.²
- The less severe, Distal Arthrogryposis Syndromes (DAS) only involve distal joints such as hands and feet. Neurologic development is normal and response to physical therapy is usually good in patients with DAS.

Clinical diagnosis is usually made at birth. Severe equinovarus deformity of the feet usually presents. The face is usually round, flat nasal bridge, and micrognathia. Contractures and rigidity of the joints are common and result in joint pterygia and dislocation of large joints (hip, knee, shoulder and elbow). There is significant decrease mobility of temporomandibular joint, atlantoaxial instability, scoliosis, and/or fusions of cervical vertebrae have been reported.¹

Abnormal craniofacial features along with severe limb and neck contractures result in difficult airway management, therefore spontaneous ventilation is recommended until the airway is secured. The use of LMAs, fiberoptic intubation, or fiberoptic-guided intubation via LMAs have been proposed and used successfully. Careful intraoperative positioning is mandatory to prevent injuries and fractures. Risk of hypermetabolism and hyperpyrexia during and after anesthesia has been described in prior case reports. However, no relation between malignant hyperthermia and arthrogryposis has been demonstrated.¹⁻³ An exaggerated hyperkalemic response to succinylcholine may occur secondary to muscle structure changes.

CONCLUSION

Patients with Arthrogryposis syndromes are at increased risk of difficult airway management, challenging vascular access, and hypermetabolic state with hyperthermia in the setting of myopathies. Along with joint contracture problems and associated congenital anomalies (cardiac, respiratory, genitourinary, neurogenic, and facial anomalies) present further challenges for anesthesiologists. Therefore, careful airway evaluation, close perioperative monitoring of vitals for hyperthermia, tachycardia, and hypercarbia, and preparation for anticipated emergencies are needed to avoid critical events.

Table 1. Precautions before Anesthesia and Anesthetic Considerations¹⁻⁶

Risk of Difficult Airway	-Micrognathia -Limited temporomandibular joints mobility -Atlanto-occipital instability -Fusion of cervical vertebrae -Short neck -Craniofacial anomalies
Difficult Venous Access and regional block	-Severe flexion/contracture abnormalities of the extremities -Joints pterygia
Abnormal cardiopulmonary function	-Severe scoliosis -Congenital cardiomyopathy -Congenital hypoplastic lungs, tracheal stenosis
Neuromuscular Disease	-Muscle atrophy
Risk of hyperkalemic response to succinylcholine	-Absence of muscles
Risk of aspiration	-Muscle structural abnormalities
Risk of hyperthermia	-Hypermetabolism

REFERENCES

1. Bissonnette, Luginbuehl, I, Marciniak B, Dalen BJ. eds. Arthrogryposis (Arthrogryposis Multiplex Congenita). In: Syndromes: Rapid Recognition and Perioperative Implications. New York, NY: McGraw-Hill; 2006.
2. Gleich S J , T M Schroeder, AC. Hanson. Anesthetic Outcomes of Children with Arthrogryposis Syndromes: No evidence of Hyperthermia. *Anesth Analg*. 2017; 124(3):908-914.
3. Jung J W, Heo BY, Oh EJ, et.al. Anesthesia in Patients with Arthrogryposis Multiplex Congenita: A Report of 10 Patients. *Letter to the Editor. Korean J Anesthesiol* 2014;67(Suppl):S89-90. doi: 10.4097/kjae.2014.67.S.S89
4. Bamshad M, VanHeest AE, Pleasure D. Arthrogryposis: A Review and Update. *The Journal of Bone and Joint Surgery*. 2009 ;91 Suppl 4:40-6. doi: 10.2106/JBJS.1.00281.
5. Hall J G. Arthrogryposis (multiple congenital contractures): Diagnostic approach to etiology, classification, genetics, and general principles. *Eur Journal of Med Genet*. 2014;57(8):464-72. doi: 10.1016/j.ejmg.2014.03.008. Epub 2014 Apr 3.
6. Hall JG. Arthrogryposes (Multiple Congenital Contractures). Emery and Rimoin's Principles and practice of Medical Genetics. Figure 161-2. 2013. Pages 1-101. 6th edition Copyright © 2013 Elsevier Ltd.

INTRODUCTION

Dandy-Walker Malformation (DWM) is a congenital anomaly of the cerebellum and fourth ventricle characterized by hypoplasia of the cerebellum and hydrocephalus secondary to cystic expansion within the fourth ventricle.

Such malformations commonly result in increased intracranial pressure from hydrocephalus and facial anatomical distortions such as cleft lip/palate, hyperterlorism and micrognathia making airway management challenging.

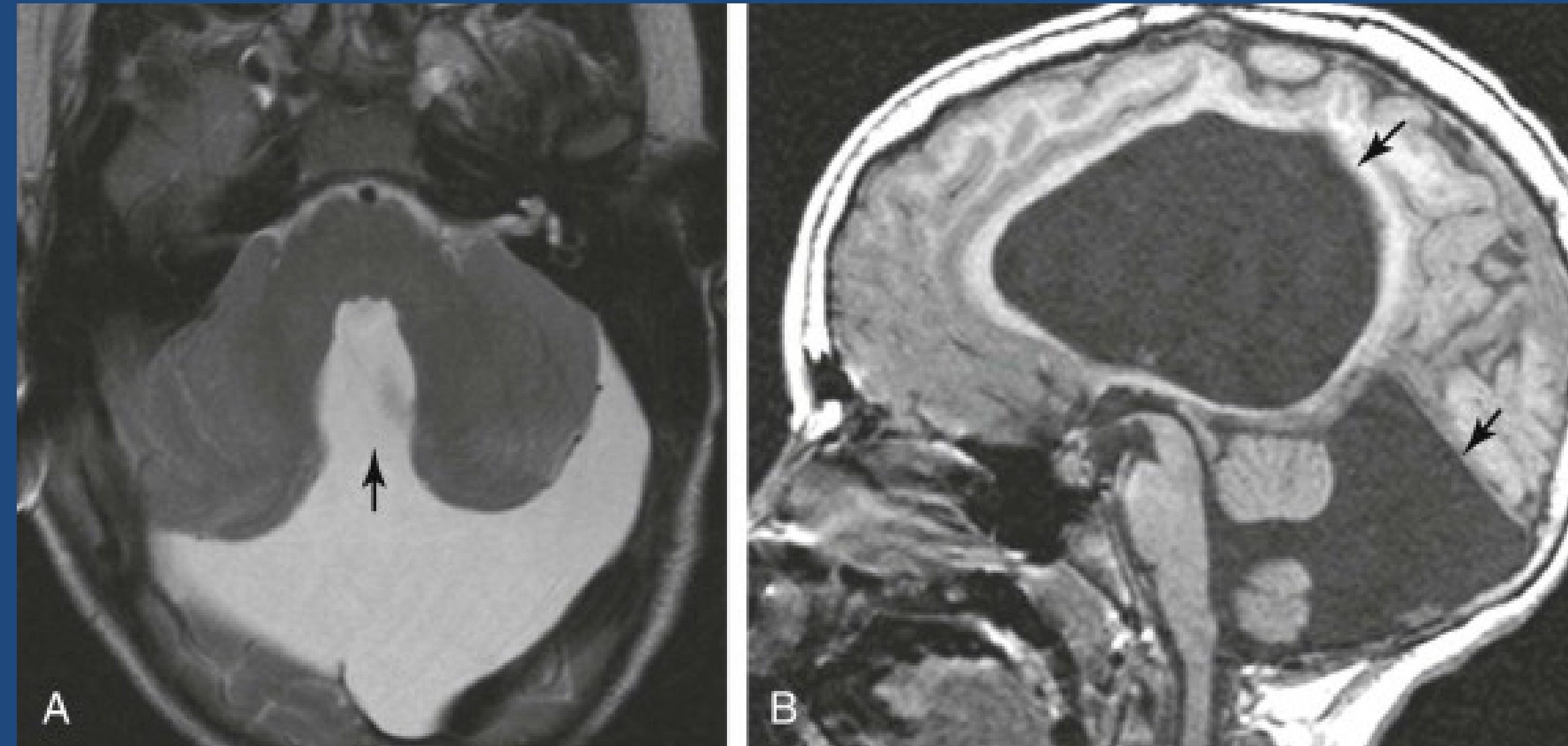


Figure 1. Dandy-Walker Malformation with Enlargement of Posterior Fossa. A) T2 Weighted MRI. Absence of cerebellar vermis (arrow). B) T1 weighted MRI. Elevation tentorium (bottom arrow) and Hydrocephalus.⁷ Image obtained from Clinical Key

CASE DESCRIPTION

A 10-year-old female with bilateral congenital talipes equinovarus and developmental delay secondary to underlying DWM who had shunted hydrocephalus in infancy presented for left foot osteotomy, calcaneocuboid fusion, and heel cord lengthening for recurrent left foot deformity.

After inhalational induction and placement of an intravenous line, airway was managed with a laryngeal mask airway (LMA). The perioperative course was uneventful.

Table 1: Clinical Aspects of Dandy Walker Syndrome^{1,2}

Obstructive Hydrocephalus	• Cranial nerve palsies
Raised intracranial pressure	• Irritability • Vomiting • Convulsions
Cerebellar signs	• Ataxia • Nystagmus
Agenesis of Corpus Callosum	• Developmental delay/Mental retardation • Medullary failure (respiratory regulation)
Seizures	

Table 2: Extracerebral Anomalies^{1,2}

✓ Cleft palate	✓ Congenital heart defects (VSD)
✓ Micrognathia	✓ Renal abnormalities
✓ Eye abnormalities (increased intraocular pressure)	✓ Infundibular hematomas
✓ Skeletal abnormalities (lumbar vertebrae)	✓ Posterior fossa lymphomas
✓ Polydactyly	✓ Syringomyelia

DISCUSSION

Dandy-Walker Malformation is a heterogeneous and in some cases auto recessive inheritance. Incidence of 1:25,000 newborns.¹ Affected children with hydrocephalus often present with bulging fontanelles and occiput, congenital neurodevelopmental and craniofacial anomalies.^{1,2} Therefore, patients with DWM often can present with potential challenging airway management requiring advance airway equipment preparation at bedside, such as rigid or flexible fiberoptic airway equipment.

A major concern in a patient with DWM is intracranial pressure (ICP) management. Endotracheal intubation should be done as gentle as possible. An LMA was used in our case to avoid increased sympathetic response from intubation. The use of succinylcholine is also often avoided as it has the potential to increase ICP. Inhalational agents cause a dose dependent rise in ICP, however isoflurane and sevoflurane <1 MAC concentration do not cause a significant rise in ICP. In addition, hypercarbia results in an increase in cerebral flow and as a result elevates ICP.²⁻⁵ End tidal CO₂ should be maintained at 30-35mmHg.

In addition to the 4th ventricle and cerebellum abnormalities, agenesis of Corpus Callosum in DWM patients increases their likelihood of apnea and respiratory failure.⁴ Confirm adequate oxygenation and ventilation prior to extubation. Precautions must be taken for post-operative respiratory decompensation.

CONCLUSION

Dandy-Walker Malformations are often associated with craniofacial abnormalities, elevated ICP, post-operative respiratory complications that could cause challenges in anesthetic management

Key to successful anesthetic management in these patients are careful assessment of airway anatomy with appropriate plan for difficult airway, ICP control and attentive post-operative care monitoring.

REFERENCES

1. Bissonnette B, Luginbuehl I, Marciniak, Dalens B. Syndromes: Rapid Recognition and Perioperative Implications. Dandy-Walker Malformation. McGraw-Hill Global Education Holdings, LLC. 2006 USA. McGraw-Hill Global Education Holdings, LLC. © 2006.
2. Kulkarni S, Kelkar V, Ruhatiya* S. Anesthetic Management of an Adolescent with Dandy Walker Malformation. Case Report. International Journal of Current Medical and Applied Sciences. Vol. 3. Issues: 2014:07-09 Copyright @ 2014 Logic Publications, IJCMAS, E-ISSN:2321-9335, P-ISSN:2321-9327.
3. Jang JS, Lee JJ, Park WJ, et.al. Anesthetic Management of an Adolescent with Dandy-Walker Syndrome. Case Report. Korean Journal of Anesthesiol. Web. 6 Sept. 2018. 2013 Feb;64(2):180-1. doi: 10.4097/kjae.2013.64.2.180. Epub 2013 Feb 15.
4. Woodward T. Anesthetic Management for a Patient with Dandy-Walker Syndrome. Westminster College Utah. Dec. 2014 cdmuntu.lib.utah.edu/utis/getfile/collection/wc-ir/id/121/filename/123.pdf
5. Singh R, Dogra N, Jain P, et al. Dandy Walker Syndrome with Giant Occipital Meningocele with Craniovertebral Anomalies: Challenges Faced during Anaesthesia. Letter to Editor. Indian Journal of Anaesthesia. 2016;Vol 60. (1):71-73
6. Datt V, Tempe D K, Lalwani P, Aggarwal S, Kumar P, Diwakar A, Tomar A S. Perioperative management of a patient with Dandy Walker malformation with tetralogy of Fallot undergoing total correction and fresh homologous pericardial pulmonary valve conduit implantation: Report of a rare case. Ann Card Anaesth 2015;Vol18.(3) 433-436
7. Gressens P, Huppi PS. Chapter 58, Normal and Abnormal Brain Development. Dandy-Walker Malformation. In: Martin's Neonatal-Perinatal Medicine. 10th ed. Elsevier-Saunders, Philadelphia, PA. 2015 Figure 58-25. Image courtesy of J. Delavelle, Department of Radiology, University Hospitals of Geneva, Geneva, Switzerland.



INTRODUCTION

I am pleased to present a case highlighting a rare complication of dexmedetomidine and describing: (1). Its relationship to the administration of dexmedetomidine; (2). A possible mechanism for dexmedetomidine-induced fever; and (3). Management of dexmedetomidine-induced fever in a critical care setting.

CASE HISTORY

A 79-year-old male with incarcerated umbilical hernia, afebrile and on broad spectrum antibiotics, underwent a right hemicolectomy for incarcerated inguinal hernia. Following uneventful surgery, the patient was transferred to ICU for postoperative management. Intravenous dexmedetomidine infusion (1mg/kg bolus followed by 0.4 mcg/kg/hr) was started for postoperative agitation. However, shortly after starting the infusion, the patient became febrile to 105.8° by esophageal temperature. Dexmedetomidine infusion was discontinued, one (1) gram of intravenous acetaminophen was given, and a cooling blanket was applied; the fever subsequently decreased with complete resolution to normal baseline at six hours.

DISCUSSION

Dexmedetomidine's primary site of action is the Locus Coeruleus, the major noradrenergic nucleus of the brain that communicates with a wide subset of neural structures and plays a central role in a number of physiologic functions.¹ The primary effect of dexmedetomidine on the Locus Coeruleus is regulation of arousal, making it a common choice for sedation in the ICU. Recently, however, it has been found to play a role in the control of autonomic function¹ with the rare side effect of pyrexia. Nuclei in the Caudal Raphe Magnus are involved in thermoregulation, causing increases in body temperature secondary to direct stimulation from the Locus Coeruleus.¹ Dexmedetomidine has been implicated in a small but growing number of case reports of drug-induced fever as a rare side effect.² In our case, after starting dexmedetomidine according to our institutional standards and established critical care guidelines³, an extreme fever was noted; dexmedetomidine was immediately suspect due to the timing of the fever and lack of other readily identifiable causes, therefore it was immediately discontinued and the fever treated.

CONCLUSION

Dexmedetomidine-induced fever is a rare side effect that clinicians should be aware of, especially in the ICU setting, where it is a common choice for sedation. Since there are so few documented cases and the fever can manifest at varying time intervals², dexmedetomidine fever should be considered in the differential diagnosis for fever for any patient receiving it for sedation. One possible explanation for the mechanism of fever is via direct stimulation of areas of the brain responsible for thermoregulation, such as the Caudal Raphe Magnus by the Locus Coeruleus.¹ The Locus Coeruleus, as the primary site of action of Dexmedetomidine, is implicated in many important physiologic functions, although why some patients develop fever and others do not is not understood.² Diagnosis of dexmedetomidine-induced drug fever should be treated immediately, since body temperature can become severely elevated. As with other cases of drug fever, the offending agent should be discontinued and active cooling measures initiated. IV acetaminophen and cooling blankets can be employed and other causes of fever must be considered since dexmedetomidine-induced fever is a diagnosis of exclusion.

References:

1. Samuels ER, Szabadi E. Functional neuroanatomy of the noradrenergic locus coeruleus: its roles in the regulation of arousal and autonomic function part I: principles of functional organisation. *Curr Neuropharmacol*. 2008;6(3):235–253.
2. Faust AC, Sutton SE. Dexmedetomidine-associated fever in the intensive care unit. *Ther Adv Drug Saf*. 2015;6(6):234-237. doi:10.1177/2042098615612661.
3. Barr J, Fraser G, Puntillo K, et al. Clinical practice guidelines for the management of pain, agitation, and delirium in adult patients in the intensive care unit. *Crit Care Med*. 2013;41(1): 263–306.

INTRODUCTION

Cysticercosis infection is associated with the larval stage of the tapeworm *Taenia Solium*. It is most commonly found in the developing world, is associated with the ingestion of *T. Solium* eggs shed in the stool of a human tapeworm carrier, and is often identified as the cause of adult onset seizure disorders.^{1,2} Associated clinical syndromes are neurocysticercosis and extraneural cysticercosis. Neurocysticercosis specifically describes a parasitic infection of the central nervous system caused by migration of larval cysts from the gastrointestinal tract into the vascular and, ultimately, the central nervous systems.³ Neurocysticercosis is further classified as parenchymal and extraparenchymal, with extraparenchymal neurocysticercosis specifically involving intraventricular, subarachnoid, spinal or ocular involvement.

CASE DESCRIPTION

A 59-year-old Nigerian male was transferred to our institution following initial workup at an outside hospital for acute onset gait changes, general malaise and urinary incontinence. Imaging at the sending hospital was concerning for parasitic infection given patient's clinical findings and recent immigration from Nigeria. Further imaging at Baystate was most concerning for obstructing hydrocephalus from cystic lesions in the third and fourth ventricles. Initial medical management focused on an anti-helminthic regimen and hourly neuro-monitoring in the intensive care unit. As the patient's clinical picture waxed and waned, the decision was made to proceed with surgical decompression of the obstructing lesion via a posterior fossa craniotomy.

IMAGES OF T. SOLIUM CYSTS

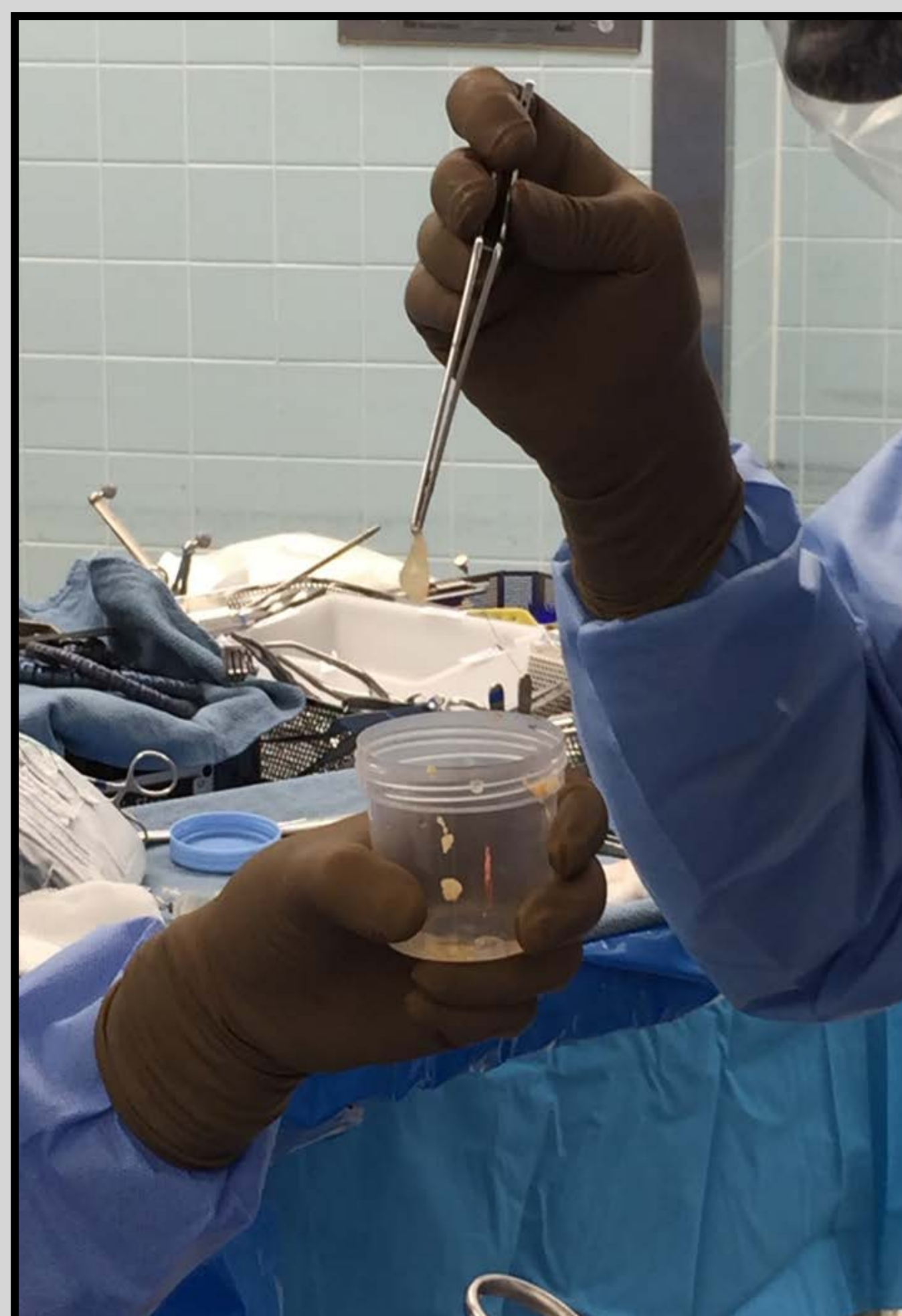


Figure 1. *T. Solium* Cysts being removed from patient. Photo by author.



Figure 2. Close-up of *T. Solium* Cysts removed from patient. Photo by author.

DISCUSSION

Anesthetic management of a patient with an active parasitic infection in the setting of obstructing hydrocephalus can be quite challenging. This patient presented with symptoms of increased intracranial pressure as well as systemic signs and symptoms of active infection requiring an urgent posterior fossa craniotomy. The patient underwent close neuro-monitoring throughout the case and was intubated using a glidescope to ensure appropriate placement of a NIM EMG monitoring endotracheal tube. The patient was maintained on remifentanyl, Precedex™ and propofol infusions; paralysis was avoided to ensure that appropriate motor monitoring could be achieved. Intraoperatively, the patient was given anti-seizure prophylaxis as well as agents to decrease cerebral edema. Close arterial monitoring was achieved by utilizing an arterial line. Two large bore intravenous catheters were placed following induction. The neurosurgeon entered the third and fourth ventricles, where hundreds of cysts were identified and removed. Postoperatively, the patient was transferred, intubated, to the surgical intensive care unit for hourly neurochecks. Interestingly, the clinical presentation typically associated with neurocysticercosis is one of later progression of the infection and adult onset seizures.^{2,4} This patient presented with what appeared to be an active parasitic infection and the most immediate symptoms requiring urgent surgical intervention were associated with obstruction and an acute iatrogenic inflammatory response related to the anti-helminthic regimen.

Unfortunately, the patient's clinical course was complicated by continued episodes of obstructive symptoms requiring multiple surgical re-explorations and placement of a lumbar drain, which was further complicated by *Klebsiella meningitis*. Although the patient initially showed signs of improvement and was discharged three months after his first admission, he was quickly readmitted and succumbed six months after initial presentation.

References

1. White, C. Cysticercosis: Epidemiology, Transmission and Prevention. <https://www.uptodate.com/contents/cysticercosis-epidemiology-transmission-and-prevention>. Accessed 8/25/18.
2. White, C. Cysticercosis: Clinical Manifestations and Diagnosis. <https://www.uptodate.com/contents/cysticercosis-clinical-manifestations-and-diagnosis>. Accessed 8/25/18.
3. DeGiorgio, CM, Medina MT, Duron R, Zee C, Escueta SP. Neurocysticercosis. *Epilepsy Curr.* 2004 ; 4(3): 107-111.
4. White, AC Jr, Garcia HH. Updates on the Management of Neurocysticercosis. *Curr Opin Infect Dis.* 2018;31(5):377-382.

INTRODUCTION

Radiofrequency ablation (RFA) has been used to treat a variety of pain conditions such as trigeminal neuralgia, cervicogenic headaches, and spinal pain.

In recent years, RFA procedures provided an alternative pain management for patients with chronic knee pain. This patient population often are refractory to conventional medical treatment, had failed surgical intervention, or are non-surgical candidates.

CASE DESCRIPTION

A 61 year old female with a history of Polio suffers from intractable left knee pain due to severe joint space narrowing secondary to her leg deformity. She failed conservative treatments including physical therapy, analgesic medications, repeated intra-articular injections of steroid and visco-supplementation. Total knee replacement was not recommended due to her gross deformity.

She presented for left genicular nerve cooled radiofrequency ablation under fluoroscopy guidance after successful diagnostic genicular nerve block with Bupivacaine 3 ml of 0.5%. Fluoroscopy (in anterior posterior and lateral views) was used to identify needle (17G, 100mm) placement at the superomedial, lateral, and inferomedial genicular nerves of the affected knee joint.

Lidocaine 2% 1 ml and Bupivacaine 0.25% 2 ml were injected to each site prior to cooled radiofrequency at 60° C for 2.5 minutes. Patient denies any paresthesia during procedure and tolerated procedure uneventfully.

On follow-up visit, patient reported more than 90% pain relief and relief lasting more than 8 weeks with improvement of daily activities such as ambulation, cooking, and cleaning.

Figure 1. Genicular Nerves Anatomy (Medial View) Medial view of the knee demonstrating the relative location of the superior medial genicular nerve and the inferior and medial genicular nerve and their corresponding articular arteries.

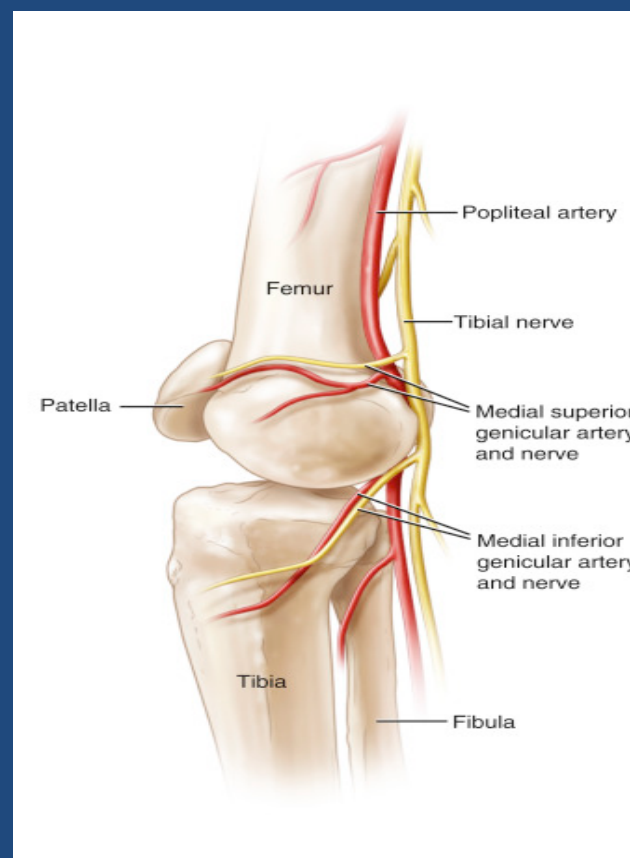


Figure 1. Obtained from Clinical Key Figure 134-4⁵.

Figure 2: Genicular Nerves Anatomy (Lateral View) Lateral view of the knee demonstrating the relative location of the superior lateral genicular nerve and the inferior lateral genicular nerve and their corresponding articular arteries.

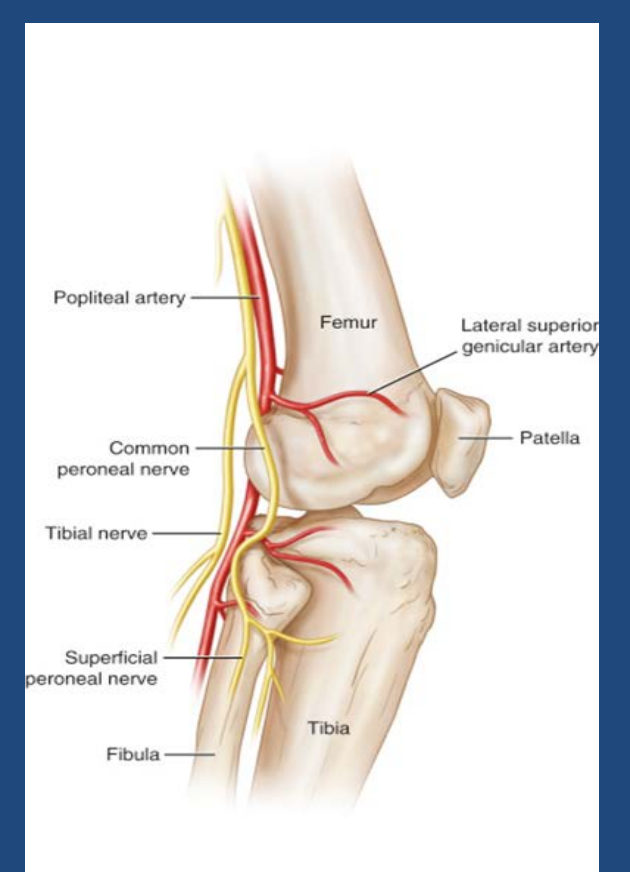


Figure 2. Obtained from Clinical Key Figure 134-5⁵.

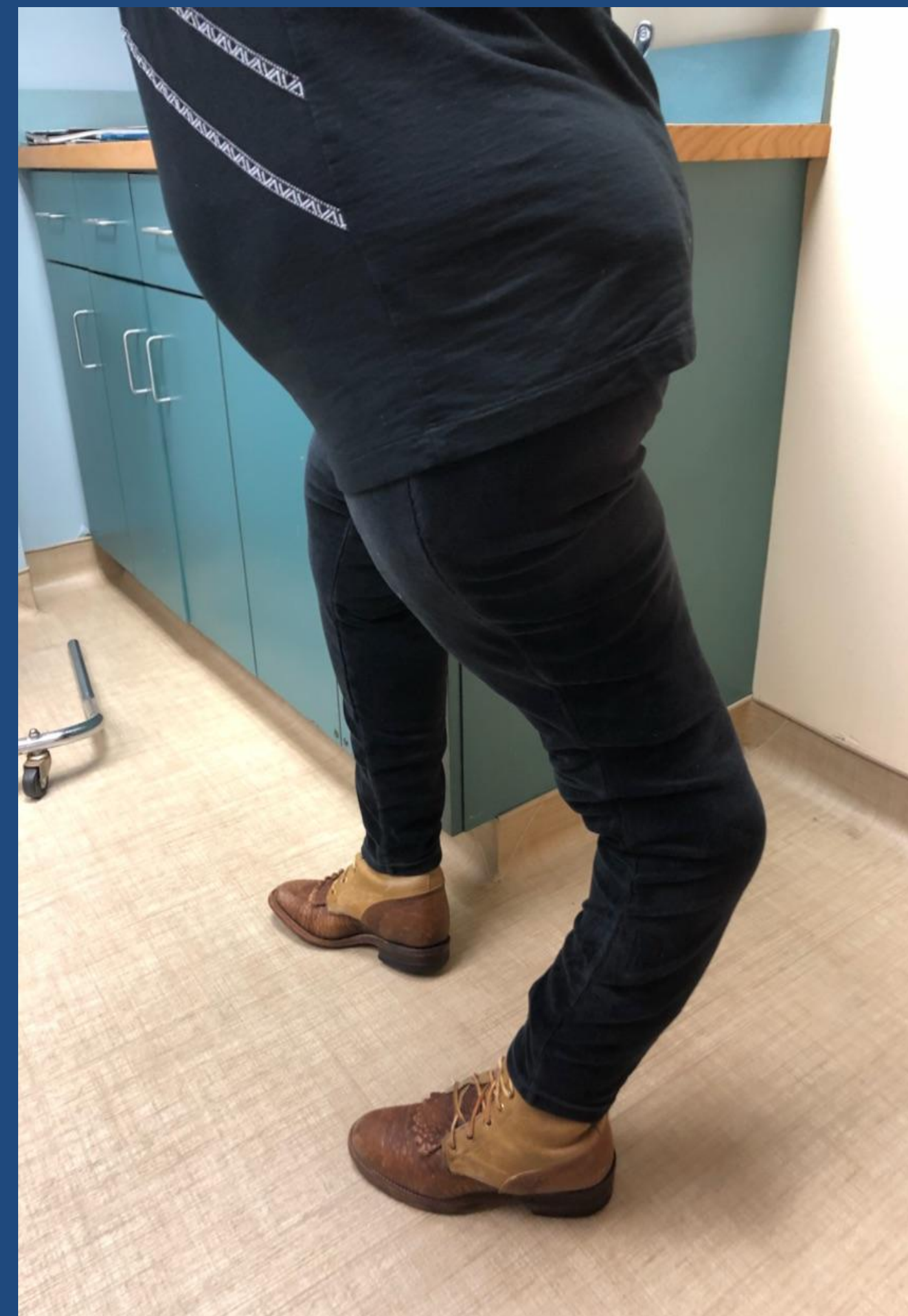

Image of patient taken with permission Baystate Medical Center

Figure 3. Genicular Nerve Block Needle Placement AP View. Fluoroscopic image taken from patient chart at Baystate Medical Center

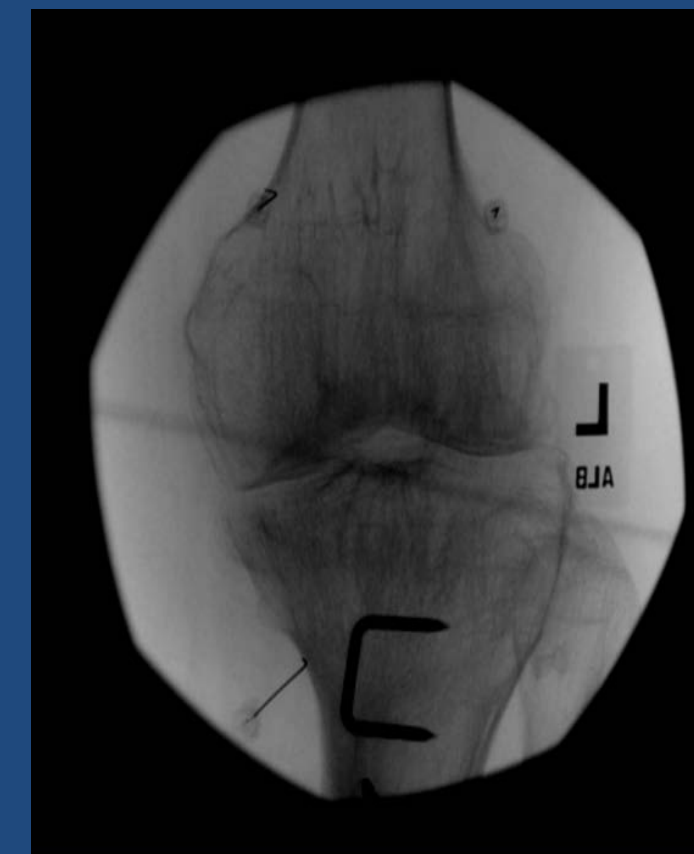
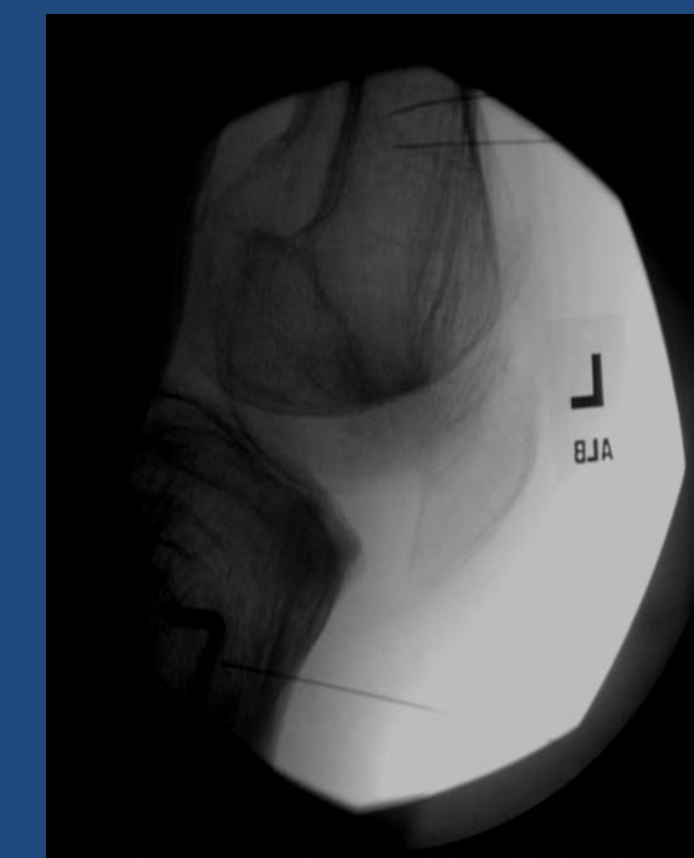


Figure 4. Genicular Nerve Block Needle Placement Lateral View. Fluoroscopic image taken from patient at Baystate Medical Center



DISCUSSION

Radiofrequency ablation at 40-70°C causes protein denaturation and coagulation necrosis at targeted nerve site. RFA is believed to stop nociceptive (A-δ and C-fibers) pain inputs without destroying the motor or sensory (A-β) fibers.¹⁻³ It has been shown that the Schwann cells may be preserved after RFA, which would allow nerve regeneration. Based on available evidences, RFA of genicular nerves can provide on average more than 60% pain relief for 3 to 6 months.¹

Current RFA modalities being used for chronic knee pain are Conventional RFA, Pulsed RFA, and Cooled RFA. Though literature regarding the efficacy of RFA is limited there is strong evidence that supports RFA in treating chronic knee pain especially in patients with pain from osteoarthritis and/or post-total knee arthroplasty. Due to different study methodologies and inconsistent patient assessment measures, there is a low level of certainty that one type of RFA procedure is more superior to the other in their benefit and safety profile.

A complex network of articular nerves from the tibial, common peroneal, femoral, and obturator supply the knee joint. Tributaries from these nerves form the RFA targeted genicular nerves (superior lateral, superior medial, and inferior medial).^{2,4} The inferior lateral nerve is not targeted due to its proximity to the common peroneal nerve, which can result in foot drop. As arteries travel with nerves, ablating nerves using bony landmark may lead to undesired vascular complication. Genicular artery injuries, though uncommon, can carry significant morbidities. Most often, these vascular injuries result in formation of pseudoaneurysm, AV fistula, hemarthrosis, and/or necrosis of the patella.² Injury to the neighboring saphenous nerve should also be considered when performing RFA on medial knee nerves.

Physical exam landmarks, fluoroscopy, ultrasonography, or a combination is used during procedures to determine anatomical structures. Currently, an open study by Mata J. et al postulates that the use of ultrasound-guided (US) genicular block has more advantages over fluoroscopically guided techniques. US provides visualization of neurovascular bundles and nerve identification. Also, US-guided approaches are less expensive, easily reproduced, and are without exposure to radiation.³ While studies that utilize visualization guidance tend to have positive outcomes, there is no current data to support the superiority of one imaging modality over another or that RFA procedures necessitates imaging.

CONCLUSION

Genicular RFA is an effective pain management alternative for patients with chronic knee pain refractory to pharmacologic and/or surgical intervention. While there is a lack of literature with head-to-head comparison of the specific RFA modalities, there are strong evidences that radioablation of the genicular nerves can alleviate knee pain and improve daily function.

Table 1: Types of Radiofrequency Ablation Therapeutic Technologies¹

	Conventional RFA	Pulsed RFA	Cooled RFA
Mechanism	<ul style="list-style-type: none"> Electrode tip (electromagnetic field frequency of 250kHz) heats targeted local tissue within a few millimeters to 47°C for 2 minutes. 	<ul style="list-style-type: none"> Pulse generator producing pulses amplitude of 45V lasting 20ms every 500ms (twice per second). RFA perform at 40-67°C with tissue temperature reaches maximum 42°C 	<ul style="list-style-type: none"> Thermal ablative mechanism: water circulates inside the probe removing heat, which modulates the thermal heat (60°C), and alters the size, shape, and projection of lesions.
Pros/Cons	<ul style="list-style-type: none"> Heat generation resulting in thermocoagulation and localized neuronal tissue destruction Ablative heat promote neuromodulation by inhibition of excitatory C-fibers 	<ul style="list-style-type: none"> Less neuro-destructive Patients experience less pain with procedure Less risk for development deafferentation pain Shorter duration of pain relief Requires more frequent procedure performed to achieve similar level of pain relief. 	<ul style="list-style-type: none"> Greater CRF lesion reduces the number of technical failures when addressing complex and variable neuronal innervation of the knee Ability to target greater amount of neuronal tissue producing longer duration of pain relief

Reference

- Gupta A, Huettner DP, Dukewich M. Comparative Effectiveness Review of Cooled Versus Pulsed Radiofrequency Ablation for the Treatment of Knee Osteoarthritis: Systematic Review. *Pain Physician* . 2017;20(3):155-171.
- Kim SY, Le Pu, Kosharsky B, Kaye AD et al. Is Genicular Nerve Radiofrequency Ablation Safe? A Literature Review and Anatomical Study. *Pain Physician* . 2016; 19(5):E697-705.
- Mata, J. Valenti P, Hernandez B. et.al. Study Protocol for a Randomized Controlled Trial of Ultrasound-Guided Pulsed Radiofrequency of the Genicular Nerves in the Treatment of Patients with Osteoarthritis Knee Pain. *BMJ Open*. 2017. 3;7(11):e016377. doi: 10.1136/bmjopen-2017-016377
- Lannaccone F, Dixon S, Kaufman A. Review of Long-Term Pain Relief after Genicular Nerve Radiofrequency Ablation in Chronic Knee Osteoarthritis. Retrospective Review. *Pain Physician* . 2017;20(3):E437-E444.
- Waldam SD. Chapter 134 Genicular Nerve Block. In: *Atlas of Pain Management Injection Techniques*. Genicular Nerve Block. 4th edition Elsevier, St. Louis Missouri. 2016. Figures 134-135. Pages 495-501. Clinical Key

Introduction

Perioperative pain management in chronic pain patients can present a challenge, especially if they are treated with long term opioids. This case describes the use of multimodal analgesia perioperatively in an opioid-dependent chronic pain patient.

Case Description

A 57-year-old male with a history of chronic pain and long term daily opioid use presented for a sternal hardware removal, open reduction and internal fixation and cadaveric bone graft for a nonunion of prior sternotomy. A multimodal approach was used for perioperative pain management with a combination of medications to address multiple different pain receptors and pathways. Patient received high dose fentanyl, dexmedetomidine, ketamine, intravenous acetaminophen, and continuous intercostal nerve blockade with local anesthetics via surgically placed On-Q pump. The perioperative course was uneventful and patient was comfortable in the postoperative period.

Multimodal Mechanism of Pain¹

- **Peripheral pain receptors:** Sensitive to capsaicin, moderate thermal stimuli, acid pH, adenosine, and other related phosphates
- **Ion channels:** Voltage-gated sodium channels, voltage-gated calcium channels
- **Inflammatory Mediators:** Substance P, bradykinin, cytokines, prostaglandins
- **Peripheral sensitization**
- **Central sensitization**

Multimodal Approach to Pain Management in an opioid-dependent chronic pain patient

Medication/Technique	Description
<i>Regional Anesthesia</i>	<i>Neuraxial block or peripheral nerve block</i>
<i>Acetaminophen</i>	<i>Inhibits the synthesis of prostaglandins</i>
<i>Non-steroidal anti-inflammatory drugs</i>	<i>Non-selective: Inhibits cyclooxygenase 1 and cyclooxygenase 2 (Ex: Ketorolac)</i> <i>Selective: Inhibits cyclooxygenase 2 only (Ex: Celecoxib)</i>
<i>Opiates</i>	<i>Acts on mu receptors which are primarily located in substantial gelatinosa of the spinal cord and periaqueductal gray matter in the brain</i>
<i>Gabapentin and Pregabalin</i>	<i>GABA B (1a,2) receptor subtype-selective agonist, and activates postsynaptic K channels and inhibits postsynaptic calcium channels</i>
<i>Intravenous Lidocaine (2)</i>	<i>Sodium channel blocker</i> <i>Inhibition of priming of polymorphonuclear granulocytes</i> <i>Inhibition of intracellular G protein signaling molecules.</i>
<i>Alpha 2 agonists (Dexmedetomidine, clonidine)</i>	<i>Presynaptic alpha 2 receptor agonist and decreases the release of norepinephrine. Alpha receptors are rich at locus coeruleus, pons.</i>
<i>Ketamine</i>	<i>Non-competitive antagonist of NMDA receptor calcium channel and a weak opiate receptor agonist.</i>
<i>Magnesium</i>	<i>Inhibits calcium influx into the cell and antagonist of NMDA receptors.</i>

Discussion

Chronic pain is a complex disease that can lead to dysregulation of one or more of the pain receptors within the pain pathway.^{3,4} These changes can cause increased spontaneous activity as well as hyperresponsiveness to noxious and non-noxious stimuli.³ Pain management in these patients can be a challenge and may lead to inadequate pain control. Multimodal analgesia can be useful in managing patient pain by addressing multiple receptors involved in the pain pathway.⁴

In addition, the use of pre-emptive analgesia by administering medication prior to incision to cause an imitation of the activation of the nociceptive pathways and central sensitization can be useful in managing pain in opioid-dependent chronic pain patients. However, at this time, clinical data does not show a benefit of preemptive analgesia compared to post-incisional administration of analgesic medications.⁵

Conclusion

The patient's perioperative pain was effectively managed with opiates, dexmedetomidine, ketamine, intravenous acetaminophen and continuous intercostal block. The use of multimodal analgesia is a way to provide pain management in a chronic pain patient.

References

1. Kidd BL, Urban LA: Mechanism of Inflammatory Pain. British J Anaesth. 2001; 87:3-11.
2. Dunn LK, Durieux ME: Perioperative Use of Intravenous Lidocaine. Anesthesiology 2017; 126:729-37.
3. Argoff, C., Albrecht, P., Irving, G., Rice, F. Multimodal Analgesia for Chronic Pain: Rationale and Future Direction. Pain Medicine. July 2009; 10:2 S53-S66. August 5, 2018
4. Coluzzi, F., Bifulco, F., Corcione, A. The Challenge of preoperative pain management in opioid tolerant patients. Ther Clin Risk Manag. Sept 2017; 13: 1163-1173. August 8, 2018.
5. Kissin, I: Preemptive analgesia. Anesthesiology 2000; 93:1138-43.

INTRODUCTION

The field of thoracic surgery is evolving and the invention of video-assisted thoracic surgery (VATS) has changed the way surgeons treat thoracic diseases by focusing on a minimally invasive approach. Similarly, less conventional thoracic anesthesia strategies have evolved to encompass less invasive surgical techniques and enhance fast track perioperative pathways.¹ The term non-intubated VATS refers to thoracic operations that are performed without general anesthesia and mechanical ventilation in spontaneously breathing subjects.² Research through the years has shown that non-intubated VATS is a safe and feasible technique for thoracic surgery.

CASE DESCRIPTION

A 76-year-old man with COPD, emphysema, and left recurrent pneumothorax presented with dyspnea and large basilar loculated left spontaneous pneumothorax. Despite initial chest tube placement, the pneumothorax persisted. He underwent a video-assisted thoracoscopic mechanical pleurodesis and larger bore thoracostomy tube placement. The procedure was performed under monitored anesthesia care with dexmedetomidine, propofol, and remifentanyl infusions. Patient remained sedated and comfortable throughout surgery. Preinduction oxygen saturation was 88% and during the case the patient maintained spontaneous ventilation with oxygen saturations of 99% on 15 liters via facemask. He tolerated the procedure well and transferred to the recovery room in satisfactory condition.

DISCUSSION

Non-intubated VATS has been extensively promoted and proven safe for treatment of pleural effusion, empyema, bullous emphysema, spontaneous pneumothorax, biopsy of interstitial lung disease, wedge resection of lung nodules, lobectomies, mediastinal biopsy and tumor excision.³

The main advantage of non-intubated thoracic surgery is to avoid the perioperative morbidity associated with the deleterious effects of general anesthesia and one lung ventilation. These include airway pressure induced injury, atelectasis, hypoxemia, ventilation/perfusion mismatch, throat pain, laryngeal/tracheal injuries, cognitive dysfunction, residual neuromuscular blockade, etc.

Non-intubated patients have been shown to have shorter total operating time, shorter duration of pleural fluid leakage, decreased postoperative hospital stay, lower postoperative morbidity and mortality, lower cost, earlier postoperative improvement in physical function and decreased mental confusion.⁵

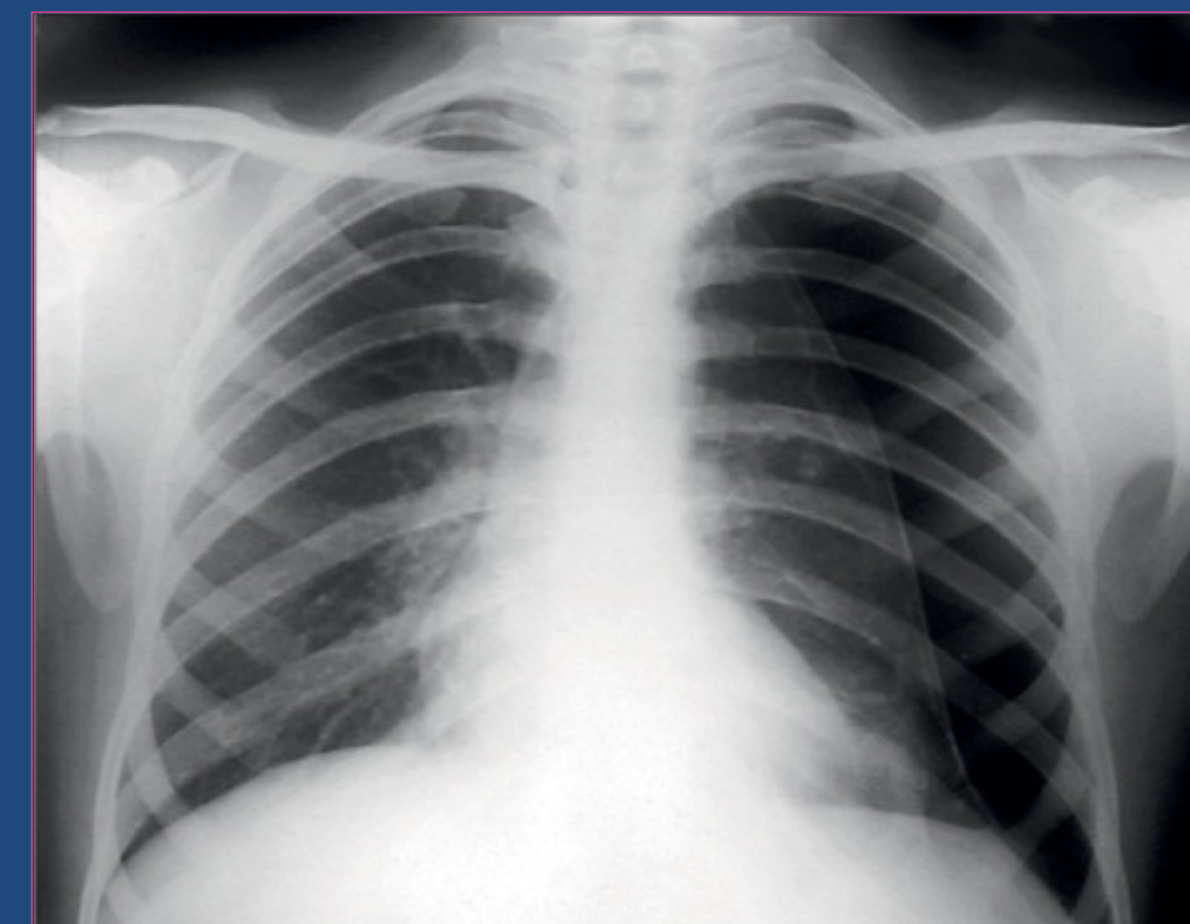


Fig. 1. Radiographic image of a patient with a left spontaneous pneumothorax

Lee, P. Primary spontaneous pneumothorax: to pleurodesis or not? *Lancet*. 2013;381 (9874):1252-1254. Copyright © 2013. Zephyr/Science Photo Library. Image obtained from Clinical Key .

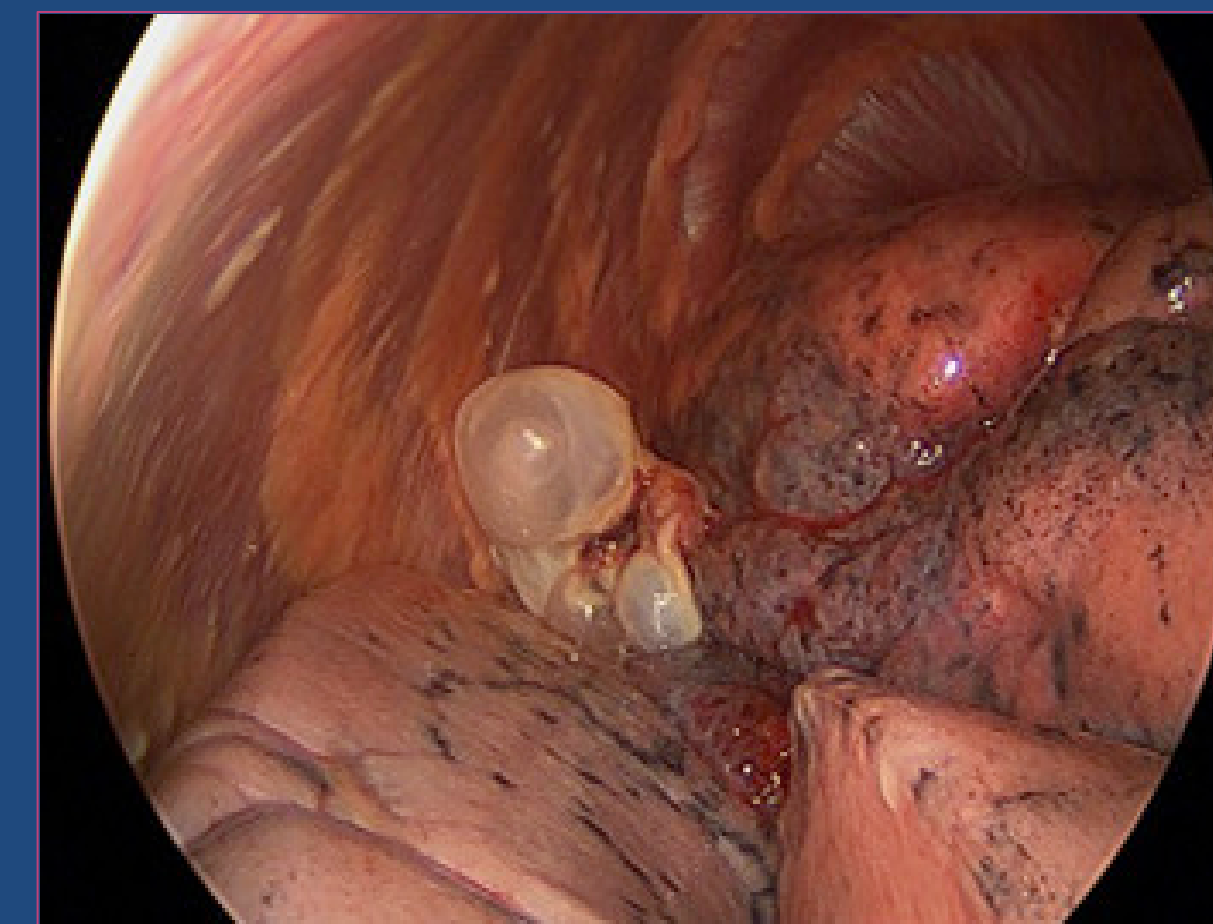


Fig. 2. Video assisted thoracoscopic surgery (VATS) showing blebs in patient with spontaneous pneumothorax

Segraves JM, Dulohery MM. Primary spontaneous pneumothorax due to high bleb burden. *Respir Med Case Rep*. 2016;19:109-111. Copyright © 2016 The Authors. Image obtained from Clinical Key .

PATHOPHYSIOLOGY

For non-intubated VATS to be successful, a thorough understanding of the underlying mechanisms of spontaneous ventilation during lung surgery is important.

- ✓ The match of ventilation and perfusion is better maintained in the dependent lung during spontaneous ventilation
- ✓ In the anesthetized patient, the non-dependent lung receives zero ventilation and perfusion decreases due to hypoxic pulmonary vasoconstriction. In non-intubated patients, perfusion to the dependent ventilated lung is better because of low/negative pressure in the lung. Intrapulmonary shunt and hypoxemia is reduced and lung recruitment is increased maintaining diaphragmatic function.
- ✓ During a non-intubated approach, there is a risk of experiencing carbon dioxide rebreathing effect however it is rare to need ventilatory support.⁴

CONCLUSION

For non-intubated VATS to be successful, minimizing pain and stress along with effortless spontaneous ventilation needs to be achieved. Anesthetic options include sedation with Propofol, remifentanyl, benzodiazepines, and dexmedetomidine infusions, thoracic epidural anesthesia, thoracic paravertebral block, intercostal nerve block, and local infiltration. To prevent coughing during the procedure, lidocaine inhalation, stellate ganglion block or a vagal nerve block can be performed to inhibit cough reflex.³ Now that feasible, reliable, and safer anesthetic modalities exist as an alternative to general anesthesia and one lung ventilation for VATS, the non-intubated approach is becoming more utilized in practice.

REFERENCES

1. Irons JF, Martinez G. Anesthetic considerations for non-intubated thoracic surgery. *J Vis Surg*. 2016;2:61.
2. Tacconi F, Pompeo E. Non-intubated video-assisted thoracic surgery: where does evidence stand? *J Thorac Dis*. 2016;8(Suppl 4):S364-S375.
3. Yang J-T, Hung M-H, Chen J-S, Cheng Y-J. Anesthetic consideration for nonintubated VATS. *J Thorac Dis*. 2014;6(1):10-13.
4. Gonzalez-Rivas D, Bonome C, Fieira E, et al; Non-intubated video-assisted thoracoscopic lung resections: the future of thoracic surgery? *Eur J Cardiothorac Surg*. 2016; 49(3):721-31.
5. Mineo TC, Sellitri F, Tacconi F, Ambrogi V. Quality of life and outcomes after nonintubated versus intubated video-thoracoscopic pleurodesis for malignant pleural effusion: comparison by a case-matched study. *J Palliat Med*. 2014;17:761-8.