

2019

Signs of Psychosis Leading to a Diagnosis of Progressive Multifocal Leukoencephalopathy: A Case Report

Bryan L. Walker
Maine Medical Center

Christina Holt MD, MSc
Maine Medical Center

Follow this and additional works at: <https://knowledgeconnection.mainehealth.org/jmmc>



Part of the [Family Medicine Commons](#), [Infectious Disease Commons](#), and the [Internal Medicine Commons](#)

Recommended Citation

Walker, Bryan L. and Holt, Christina MD, MSc (2019) "Signs of Psychosis Leading to a Diagnosis of Progressive Multifocal Leukoencephalopathy: A Case Report," *Journal of Maine Medical Center*. Vol. 1 : Iss. 1 , Article 11.

Available at: <https://knowledgeconnection.mainehealth.org/jmmc/vol1/iss1/11> <https://doi.org/10.46804/2641-2225.1009>

The views and thoughts expressed in this manuscript belong solely to the author[s] and do not reflect the opinions of the Journal of Maine Medical Center or MaineHealth.

This Case Report is brought to you for free and open access by Maine Medical Center Department of Medical Education. It has been accepted for inclusion in the Journal of Maine Medical Center by an authorized editor of the MaineHealth Knowledge Connection. For more information, please contact Dina McKelvy mckeld1@mmc.org.

CASE REPORT

Signs of Psychosis Leading to a Diagnosis of Progressive Multifocal Leukoencephalopathy: A Case Report

Bryan L. Walker, MD,¹ Christina Holt, MD, MSc¹

¹*Department of Family Medicine, Maine Medical Center, Portland, ME*

- Introduction:** Progressive multifocal leukoencephalopathy (PML) is a rare demyelinating process of the central nervous system that occurs in patients who are severely immunocompromised. Patients with PML develop varying focal neurological deficits and mental status changes that have not been well-described.
- Clinical findings:** We present a patient who was found wandering the lobby of this hospital by security. He was oriented only to self and unable to state a reason for presentation. Medical records were limited and included a visit to an outside hospital that documented a past medical history of human immunodeficiency virus (HIV) infection. He exhibited multiple signs of psychosis, such as thought blocking and a disorganized thought process.
- Diagnoses, Interventions, and Outcomes:** After thorough evaluation, he was diagnosed with HIV-associated PML based on a CD4 count of 68 cells/ μ L, signal abnormalities in subcortical white matter on brain MRI, and positive cerebrospinal fluid polymerase chain reaction (PCR) for JC virus (JCV). Despite initiation of antiretroviral therapy (ART), the patient clinically declined and was ultimately transitioned to hospice care.
- Conclusions:** While survival from PML has significantly improved with the advent of ART, the overall prognosis remains poor. This case report emphasizes that PML should be included in the differential diagnosis for immunocompromised patients with mental status changes, even if they do not present with overt focal neurological deficits. It also highlights the importance of continuous medical care for HIV to minimize the risk of patients developing such devastating complications.
- Keywords:** progressive multifocal leukoencephalopathy, HIV, AIDS, opportunistic infections, psychotic disorders
-

A 39-year-old male was found wandering the lobby of this hospital by security personnel. He appeared confused and was escorted to the emergency department. He was oriented only to self and unable to state a reason for presentation. His medical records revealed sparse, episodic care. In 2016, he was seen at an outside hospital that documented a history of human immunodeficiency virus (HIV) infection with last use of antiretroviral therapy (ART) one year prior.

In the emergency department, he was unable to follow instructions for a complete physical exam. Limited neurological exams were still performed

and generally documented as “nonfocal,” suggesting no easily perceptible muscle weakness, speech abnormality, or gait disturbance was present. However, several physicians noted that he exhibited multiple signs of psychosis, including a disorganized thought process, abrupt interruptions in speech consistent with thought blocking (e.g., patient stated “I just need you to...” and then would stop talking), apparent responses to internal stimuli (e.g., during an interview, patient suddenly pointed into space and said, “really want something else”), and nonsensical answers to providers’ questions (e.g., when asked if he had friends or family, patient responded, “other things to go - supposed to be. I’m already tracing everything”).

Head computed tomography (CT) showed patchy areas of hypodensity within subcortical white

Correspondence: Bryan L. Walker, MD
Dept. of Family Medicine, Maine Medical Center
272 Congress Street, Portland, ME 04102
blwalker@mmc.org

matter (Figure 1A, B). HIV-1 antibody was positive. CD4 count was 68 cells/ μ L (reference range 577–1623). Brain magnetic resonance imaging (MRI) showed areas of signal abnormality in subcortical white matter concerning for progressive multifocal leukoencephalopathy (PML) (Figure 1C, D). Polymerase chain reaction studies of cerebrospinal fluid were positive for JC virus, confirming the diagnosis of PML. ART was initiated with emtricitabine-tenofovir alafenamide (200–25 mg daily) and dolutegravir (50 mg daily).

The patient's clinical course was complicated by intermittent refusal of care, several attempts to elope from the unit, and marked behavioral dysregulation requiring antipsychotic therapy. Unfortunately, no personal contacts could be identified after extensive outreach attempts. Emergency guardianship was granted to the state. Despite treatment, his clinical condition declined with loss of mobility, dysphagia, and seizures. Given his progressive course and poor prognosis, care was transitioned to comfort measures and he was discharged with hospice services.

DISCUSSION

Progressive multifocal leukoencephalopathy is a demyelinating process of the central nervous system that was first described in 1958.¹ It is caused by the JCV, which is estimated to lie dormant in 39–91% of the world's population.² The virus is reactivated in the setting of severe immunocompromise due to either an underlying disorder (e.g., HIV) or immunomodulatory therapies (e.g., natalizumab, rituximab).³ The vast majority of patients with HIV infection who develop PML have CD4-positive T-cell counts < 200 per mm.³ Thus, the Centers for Disease Control and Prevention (CDC) classified PML as an acquired immunodeficiency syndrome (AIDS)-defining opportunistic illness (OI).⁴ In patients with at least one AIDS-defining OI, only 1.0% present with PML as the first OI to occur, making PML a rare initial complication of HIV infections.⁵

Patients with PML typically develop focal neurological deficits, depending on the specific brain regions affected by the demyelination. Thus, presenting symptoms can vary widely between patients and include hemiparesis, ataxia, aphasia, hemianopsia, and mental status changes.⁶ The precise characteristics of mental status changes are not well described in the literature. Most studies

have typically grouped together patients exhibiting confusion, dementia, or obtundation, and then simply reported the total as a percentage of patients with altered mentation or cognitive dysfunction.^{6,7} While such patients may have shared certain initial clinical features with the patient we present, the exact cognitive abnormalities they demonstrated remains unclear. Additionally, there are only a few case reports that highlight atypical presentations of PML, such as with HIV-associated dementia.⁸ To our knowledge, this case report is the first to thoroughly describe a patient with HIV-associated PML presenting to medical care with signs of psychosis.

To date, there are no specific targeted treatments for PML. The main approach to treatment is restoring the patient's immune system with effective ART to allow for normal host response to the JCV.⁹ Prior to the advent of effective ART in the mid-1990s, the one-year survival rate of patients with HIV-associated PML was just 10%.⁶ Now, initiation of effective ART significantly improves survival rates.^{10–13} In one study, the median survival time increased from 0.4 to 1.8 years in patients diagnosed with PML after 1997.¹³ The authors note that while survival has significantly improved, the overall prognosis for patients with PML remains poor, with a high mortality rate and high degree of neurological sequelae among survivors.

Unfortunately, this patient had previously received outpatient HIV treatment only briefly and was subsequently lost to follow-up. He was one of the hundreds of thousands of patients across the country who are not receiving ART through continuous HIV medical care. Recent surveillance data from the CDC shows that of the 794,145 teenage and adult patients with HIV infection in the United States, only 57.2% were retained in HIV care.¹⁴ In a large, population-based study in the United States, nearly half of all cases of the most common serious OI, *Pneumocystis carinii* pneumonia, occurred in persons not receiving medical care.¹⁵ Effective ART significantly protects against the development of all OIs, and since its introduction, the incidence of these diseases has declined precipitously in the US.^{15–19} Increased efforts are urgently needed to implement and develop effective interventions to help patients establish and remain in HIV care.²⁰ Without such ongoing care, patients will remain susceptible to devastating complications, as seen in this case report.

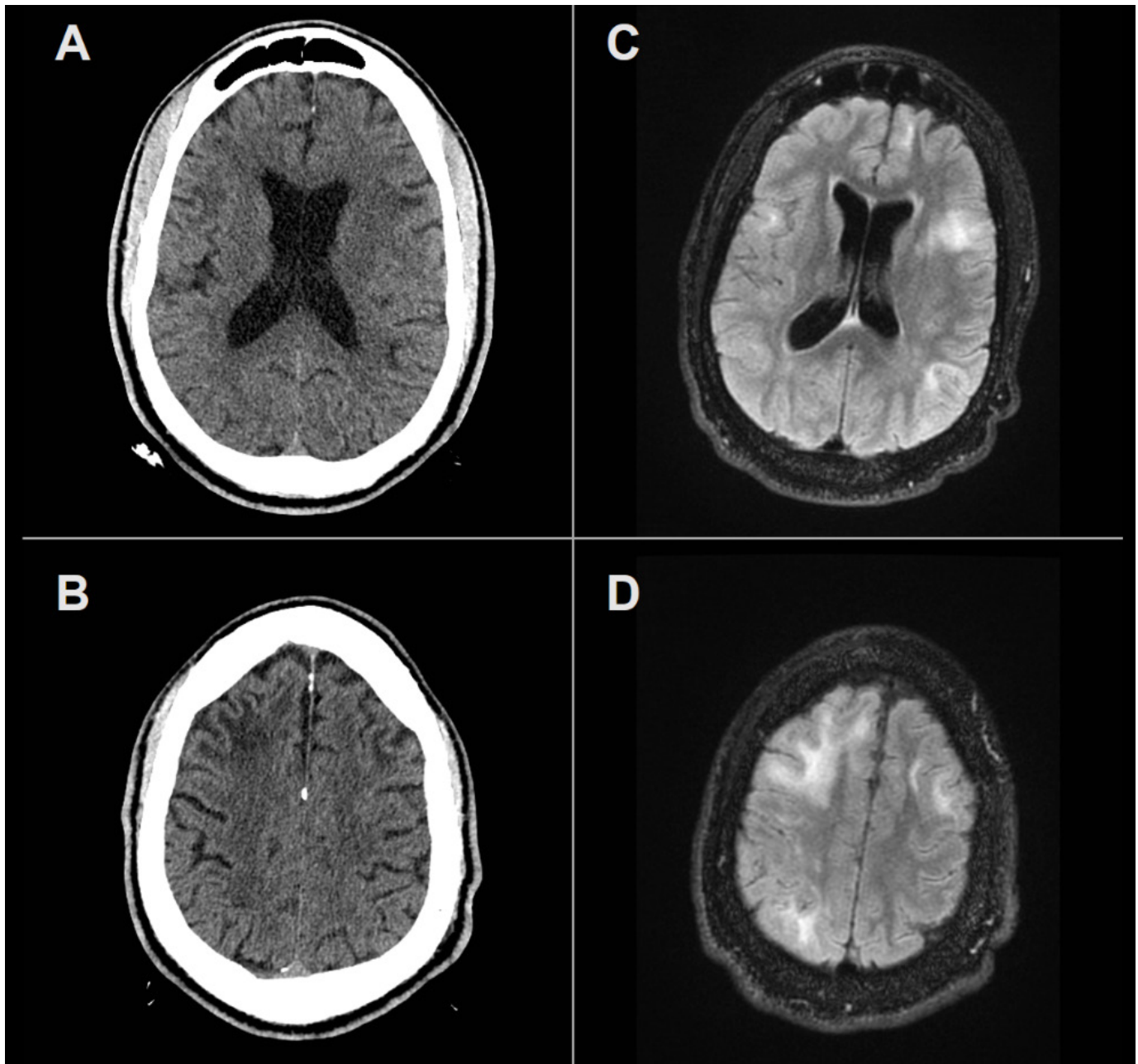


Figure 1. Neuroimaging

Panel A, B: Non-contrast axial CT head images showing patchy areas of hypodensity within the subcortical white matter of the bilateral temporal and anterolateral frontal lobes.

Panel C, D: Axial T2-weighted FLAIR MR images demonstrating confluent signal abnormalities in the subcortical white matter corresponding to the lesions identified on the CT.

CT, computed tomography; MR, magnetic resonance; FLAIR, fluid-attenuated inversion recovery

Conflicts of Interest: None

REFERENCES

1. Astrom KE, Mancall EL, Richardson EP, Jr. Progressive multifocal leuko-encephalopathy; a hitherto unrecognized complication of chronic lymphatic leukaemia and Hodgkin's disease. *Brain*. 1958;81(1):93–111.
2. Bozic C, Subramanyam M, Richman S, Plavina T, Zhang A, Ticho B. Anti-JC virus (JCV) antibody prevalence in the JCV Epidemiology in MS (JEMS) trial. *Eur J Neurol*. 2014;21(2):299–304.
3. Grebenciucova E, Berger JR. Progressive Multifocal Leukoencephalopathy. *Neurol Clin*. 2018;36(4):739–750.
4. Centers for Disease Control and Prevention (CDC). Revised surveillance case definition for HIV infection—United States, 2014. *MMWR Recomm Rep*. 2014;63(RR-03):1–10.
5. Jones JL, Hanson DL, Dworkin MS, et al. Surveillance for AIDS-defining opportunistic illnesses, 1992-1997. *MMWR CDC Surveill Summ*. 1999;48(2):1–22.
6. Berger JR, Pall L, Lanska D, Whiteman M. Progressive multifocal leukoencephalopathy in patients with HIV infection. *J Neurovirol*. 1998;4(1):59–68.
7. Gillespie SM, Chang Y, Lemp G, et al. Progressive multifocal leukoencephalopathy in persons infected with human immunodeficiency virus, San Francisco, 1981-1989. *Ann Neurol*. 1991;30(4):597–604.
8. Zunt JR, Tu RK, Anderson DM, Copass MC, Marra CM. Progressive multifocal leukoencephalopathy presenting as human immunodeficiency virus type 1 (HIV)-associated dementia. *Neurology*. 1997;49(1):263–265.
9. Panel on Opportunistic Infections in HIV-Infected Adults and Adolescents. Guidelines for the prevention and treatment of opportunistic infections in HIV-infected adults and adolescents: recommendations from the Centers for Disease Control and Prevention, the National Institutes of Health, and the HIV Medicine Association of the Infectious Diseases Society of America. http://aidsinfo.nih.gov/contentfiles/lvguidelines/adult_oi.pdf. Accessed December 18, 2018.
10. Albrecht H, Hoffmann C, Degen O, et al. Highly active antiretroviral therapy significantly improves the prognosis of patients with HIV-associated progressive multifocal leukoencephalopathy. *AIDS*. 1998;12(10):1149–1154.
11. Antinori A, Cingolani A, Lorenzini P, et al. Clinical epidemiology and survival of progressive multifocal leukoencephalopathy in the era of highly active antiretroviral therapy: data from the Italian Registry Investigative Neuro AIDS (IRINA). *J Neurovirol*. 2003;9 Suppl 1:47–53.
12. Cinque P, Casari S, Bertelli D. Progressive multifocal leukoencephalopathy, HIV, and highly active antiretroviral therapy. *N Engl J Med*. 1998;339(12):848–849.
13. Engsig FN, Hansen AB, Omland LH, et al. Incidence, clinical presentation, and outcome of progressive multifocal leukoencephalopathy in HIV-infected patients during the highly active antiretroviral therapy era: a nationwide cohort study. *J Infect Dis*. 2009;199(1):77–83.
14. Centers for Disease Control and Prevention. Monitoring selected national HIV prevention and care objectives by using HIV surveillance data—United States and 6 dependent areas, 2016. HIV Surveillance Supplemental Report 2018;23(No. 4). <http://www.cdc.gov/hiv/library/reports/hiv-surveillance.html>. Accessed December 18, 2018.
15. Kaplan JE, Hanson D, Dworkin MS, et al. Epidemiology of human immunodeficiency virus-associated opportunistic infections in the United States in the era of highly active antiretroviral therapy. *Clin Infect Dis*. 2000;30 Suppl 1:S5–S14.
16. Buchacz K, Lau B, Jing Y, et al. Incidence of AIDS-Defining Opportunistic Infections in a Multicohort Analysis of HIV-Infected Persons in the United States and Canada, 2000-2010. *J Infect Dis*. 2016;214(6):862–872.
17. Buchacz K, Baker RK, Palella FJ, Jr., et al. AIDS-defining opportunistic illnesses in US patients, 1994-2007: a cohort study. *AIDS*. 2010;24(10):1549–1559.
18. Podlekareva D, Mocroft A, Dragsted UB, et al. Factors associated with the development of opportunistic infections in HIV-1-infected adults with high CD4+ cell counts: a EuroSIDA study. *J Infect Dis*. 2006;194(5):633–641.
19. Schwarcz L, Chen MJ, Vittinghoff E, Hsu L, Schwarcz S. Declining incidence of AIDS-defining opportunistic illnesses: results from 16 years of population-based AIDS surveillance. *AIDS*. 2013;27(4):597–605.
20. Fleishman JA, Yehia BR, Moore RD, Korthuis PT, Gebo KA, HIV Research Network. Establishment, retention, and loss to follow-up in outpatient HIV care. *J Acquir Immune Defic Syndr*. 2012;60(3):249–259.