

Inova Health System IDEAS: Inova Digital e-ArchiveS

Cardiac Surgery Articles

Cardiac Surgery

4-2013

Modified “Trap Door” Approach for Thoracic Outlet Syndrome Complicated by Subclavian Artery Aneurysm

Elias Kfoury MD

Inova Health System, elias.kfoury@inova.org

Paul D. Kierman MD

Dipankar Mukherjee MD

Follow this and additional works at: http://www.inovaideas.org/cardiac_surgery_articles

 Part of the [Cardiology Commons](#), and the [Surgery Commons](#)

Recommended Citation

Kfoury E, Kiernan PD, Mukherjee D. Modified “Trap Door” approach for thoracic outlet syndrome complicated by subclavian artery aneurysm. *Vascular Disease Management*, 2013 April, 10(4), 75-78.

This Article is brought to you for free and open access by the Cardiac Surgery at IDEAS: Inova Digital e-ArchiveS. It has been accepted for inclusion in Cardiac Surgery Articles by an authorized administrator of IDEAS: Inova Digital e-ArchiveS. For more information, please contact Fairfax.Library@inova.org.

Vascular Disease Management

Published on *Vascular Disease Management* (<http://www.vascular-disease-management.com>)

[Home](#) > Modified "Trap Door" Approach for Thoracic Outlet Syndrome Complicated by Subclavian Artery Aneurysm

Modified "Trap Door" Approach for Thoracic Outlet Syndrome Complicated by Subclavian Artery Aneurysm

By *hmpeditor*

Created 04/03/2013 - 16:05

Modified "Trap Door" Approach for Thoracic Outlet Syndrome Complicated by Subclavian Artery Aneurysm

- [Volume 10 - Issue 4 - April 2013](#) [2]
- Posted on: 4/3/13
- 0 Comments
-

[1]

Section: Vascular Technique

Topics: Thoracic Outlet Syndrome

Issue Number: [Volume 10 - Issue 4 - April 2013](#) [3]

Start Page: 75

End Page: 78

Author(s):

Elias Kfoury, MD, Paul D. Kiernan, MD, Dipankar Mukherjee, MD

ABSTRACT: Arterial thoracic syndrome is a rare condition that usually presents in young patients with upper extremity thromboembolization. The traditional surgical approaches described are supraclavicular and transaxillary. We hereby present the case of a 46-year-old male with left arterial thoracic outlet syndrome and left subclavian artery aneurysm. We describe our technique in approaching his condition with a modified "trap door" approach.

VASCULAR DISEASE MANAGEMENT 2013;10(4):E75-E78

Key words: *subclavian artery, aneurysm repair, anomalies*

Arterial thoracic outlet syndrome accounts for less than 1% of thoracic outlet syndrome cases. The most common clinical presentation of this subset of patients is distal upper extremity arterial emboli in otherwise healthy patients.^{1,2} The traditional surgical approaches most commonly described for thoracic outlet syndrome have been transaxillary first rib resection or

supraclavicular first rib resection.¹⁻³ We hereby present a nontraditional surgical approach: the use of a modified "trap door" technique for the treatment of a left subclavian artery aneurysm in a patient with left thoracic outlet syndrome.

Case Report

A 44-year-old male presented to the emergency department with a progressively worsening 2-week history of numbness and a sense of coolness over his left hand. His past medical history was significant for hyperlipidemia and was otherwise noncontributory. Upon physical examination, the patient was found to have intact left hand sensory and motor function, and no pulse was felt over the left brachial artery, left radial artery, and ulnar artery. Duplex ultrasonography of the left upper extremity was performed and revealed distal brachial artery embolus extending into the proximal left radial and ulnar artery. The patient was taken to the operating room where he underwent left brachial, radial, and ulnar artery Fogarty balloon embolectomy through a brachial artery arteriotomy.

[4] The patient had a warm left hand postoperatively with left triphasic Doppler signals over the left brachial radial and ulnar artery. Postoperative workup performed to find the source of embolization included an electrocardiogram, echocardiogram, and a CT angiogram of the chest. Electrocardiogram revealed normal sinus rhythm; echocardiogram did not reveal any pathologic findings. A CT angiogram of the chest and left upper extremity revealed 1.5 cm [5] left subclavian artery aneurysm with mural thrombus along with thoracic outlet syndrome with left first rib compression over the left subclavian artery (Figures 1 and 2).

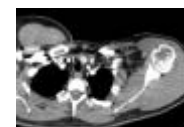

Figure 1. CT angiogram of chest. Black arrow is left subclavian artery aneurysm with mural thrombus. White arrow indicates first rib compressing over left subclavian artery.




Figure 2. CT angiogram reconstruction of chest. An aneurysm of the left subclavian artery is seen. The arrow indicates left subclavian artery compression with first rib thoracic outlet syndrome.

The patient was offered surgery to resect his left first rib and repair the subclavian aneurysm but he refused initially and wanted to think about it. He was discharged on postoperative day 1. He was discharged on antiplatelet therapy with aspirin and not started on anticoagulation because the source of the thrombus was found to be the left subclavian aneurysm, which needed to be addressed surgically. The patient presented back on postoperative day 5 with recurrent numbness and coolness over his left hand. Ultrasound duplex revealed recurrent left distal brachial artery embolus. The patient agreed to proceed with embolectomy but did not agree to left first rib resection and subclavian aneurysm repair. Left brachial, radial, and ulnar embolectomy was performed through the existing left forearm antecubital fossa incision. Patient had an uneventful postoperative course and subsequently agreed to proceed with a definite repair for his thoracic outlet syndrome and left subclavian aneurysm.


Given the clinical picture of left thoracic outlet syndrome complicated by left subclavian artery aneurysm and the need for exposure of the medial aspect of the left subclavian artery in order to perform the repair, the decision was made to proceed with a modified "trap door" approach because it allows first rib resection and at the same time provides superior visualization of the medial aspect of the subclavian artery as compared to supraclavicular and transaxillary approaches. The modified trap door approach also is a less invasive approach than a formal thoracotomy or median sternotomy.

Technique

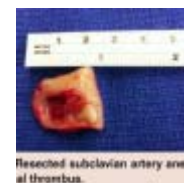[6] The patient was positioned supine and the incision site was marked (Figure 3). A vertical midline sternal incision was made down to the second rib level with the



cephalad incision extending laterally 5 cm along the left clavicle and the inferior portion extending 7 cm subperiosteally along the left second rib. Neither the clavicle nor the second rib was transected. Partial median sternotomy was done, which created a trap door by retracting the left first and second ribs. First rib resection was then performed. The thoracic duct, subclavian vein, and subclavian artery were exposed. Proximal and distal control was obtained after the left subclavian artery aneurysm was identified and poststenotic dilatation of the subclavian artery was noted distal to the left first rib. The first rib was noted to be compressing the artery along with the scalene muscles. The first rib was completely resected, along with anterior scalene muscles and the remaining costoclavicular attachments. The left subclavian vein was retracted cephalad.



Proximal and distal control of the left subclavian artery was then obtained after an intraoperative intravenous heparin bolus was given (100 units/kg). The left subclavian aneurysm was resected (Figure 4) and a 6 mm externally supported polytetrafluorethylene (PTFE) interposition graft was used for reconstruction (Figure 5).



A PTFE graft was chosen over autologous vein because of the support it provides to prevent graft compression in this particular location. Subsequently, the sternum was closed with simple interrupted wires. The ribs were approximated using interrupted periosteal buttresses with #1 Ethibond sutures. Because the operation was intrapleural, a Jackson-Pratt drain was left intrapleurally. The patient's left hand was assessed throughout the operation and was found to be cold but had adequate capillary refill and seemed to be improving after the subclavian artery was unclamped. The patient was given a chance to warm before left hand perfusion was reassessed.



While in the postoperative care unit, a duplex ultrasound of the left upper extremity was done because the patient's left hand continued to be cold, although it was warmer than it had been intraoperatively. The ultrasound duplex revealed left radial and ulnar artery occlusion. The patient was taken back to the operating room for left radial and ulnar embolectomy. The patient had a warm hand postoperatively and triphasic Doppler signal on the left ulnar and radial artery. The postoperative course was complicated by left pleural effusion requiring a chest tube on postoperative day 1. The chest tube was then discontinued on postoperative day 8 and the patient was discharged home the same day on aspirin and clopidogrel.

The patient will be on dual antiplatelet therapy for 1 month then he will stop clopidogrel only and continue aspirin for life. We use this regimen of antiplatelet therapy for all patients with PTFE grafts in whom antiplatelet therapy is not contraindicated.

At 30-day follow-up, the patient continued to do well with no left upper extremity symptoms.

Discussion

The mainstay of treatment for arterial thoracic outlet syndrome requires treatment of the ischemic sequelae of the condition and decompression of the involved area.¹ The traditional surgical approaches for thoracic outlet syndrome have been transaxillary first rib resection or supraclavicular first rib resection.³ Transaxillary first rib resection has the disadvantage of inadequate exposure of the subclavian artery as well as an increased incidence of brachial plexus injury.^{1,3} The supraclavicular surgical approach to thoracic outlet syndrome has been described as having fewer incidents of nerve injuries but the rib resection is generally more

difficult to perform,³ and exposure, resection, and arterial reconstruction of the subclavian artery would be more difficult still. Another minimally invasive approach that could be attempted in the setting of subclavian artery aneurysm and thoracic outlet syndrome is endovascular stent-graft along with first rib resection. In our case, given the patient's relatively young age, a definite repair with first rib resection and repair of subclavian artery aneurysm was felt to be a more durable option.

A modified trap door incision has been described for subclavian artery trauma, Paget-Schroetter syndrome, and subclavian artery aneurysm. This approach has the advantage of being relatively minimally invasive because it avoids full sternotomy, provides excellent exposure to upper mediastinum including a generous exposure from proximal subclavian artery to proximal axillary artery without a formal sternotomy.⁴⁻⁶ The approach is relatively easy to perform and has good cosmetic results because it avoids visible neck scars, which occur with supraclavicular exposure.⁴⁻⁶ Our approach did not necessitate transection of either the second rib or the clavicle for exposure.

Given the paucity of data regarding arterial thoracic outlet syndrome, it will be difficult to perform large-scale studies comparing supraclavicular and transaxillary approaches to a modified trap door technique. But for the above-stated reasons, a modified trap door technique may be the procedure of choice for first rib resection when exposure of subclavian artery for arterial reconstruction is required.

References

1. Patton GM. Arterial thoracic outlet syndrome. *Hand Clin.* 2004;20(1):107-111, viii.
2. Sanders RJ, Hammond SL, Rao NM. Diagnosis of thoracic outlet syndrome. *J Vasc Surg.* 2007;46(3):601-604.
3. Sanders RJ, Pearce WH. The treatment of thoracic outlet syndrome: a comparison of different operations. *J Vasc Surg.* 1989;10(6):626-634.
4. Molina JE, Hunter DW, Dietz CA. Protocols for Paget-Schroetter syndrome and late treatment of chronic subclavian vein obstruction. *Ann Thorac Surg.* 2009;87(2):416-422.
5. Ge PS, Imai TA, Van Natta TL. Versatility of a mini-trapdoor incision in upper mediastinal exposure. *Ann Thorac Surg.* 2011;91(3):938-940.
6. Kim PY, Klima U, Lichtenberg A, Kutschka I, Haverich A. A new minimally invasive approach to the subclavian artery. *Ann Thorac Surg.* 1998;66(6):2104-2106.

Editor's Note: *Disclosure: The authors have completed and returned the ICMJE Form for Disclosure of Potential Conflicts of Interest. The authors report no conflicts of interest regarding the content herein.*

Manuscript received September 18, 2012; provisional acceptance given October 29, 2012; manuscript accepted November 7, 2012.

Address for correspondence: Elias Kfoury, MD, 3300 Gallows Road, Department of Surgery, Inova Fairfax Hospital, Falls Church, Virginia, 22042, USA. Email: elias.kfoury@hotmail.com

Weight (Homepage):

3

Weight (Archive):

3

[image description](#) [9] [image description](#) [10] [Other Vascular Technique Articles](#) [11]



[Click here to get important email news and updates](#)

[12]

[Thoracic Outlet Syndrome](#) [Vascular Technique](#)

HMP Communications LLC (HMP) is the authoritative source for comprehensive information and education servicing healthcare professionals. HMP's products include peer-reviewed and non-peer-reviewed medical journals, national tradeshow and conferences, online programs and customized clinical programs. HMP is a wholly owned subsidiary of HMP Communications Holdings LLC. ©2010 HMP Communications

Source URL: <http://www.vascular-diseasemanagement.com/content/modified-%E2%80%99Ctrap-door%E2%80%9D-approach-thoracic-outlet-syndrome-complicated-subclavian-artery-aneurys>

Links:

- [1] <http://www.vascular-diseasemanagement.com/>
- [2] <http://www.vascular-diseasemanagement.com/issue/1718>
- [3] <http://www.vascular-diseasemanagement.com/issue/volume-10-issue-4-april-2013>
- [4] <http://www.vascular-diseasemanagement.com/files/uploads/TrapDoorFigure1.png>
- [5] <http://www.vascular-diseasemanagement.com/files/uploads/TrapDoorFigure2.png>
- [6] <http://www.vascular-diseasemanagement.com/files/uploads/TrapDoorFigure3.png>
- [7] <http://www.vascular-diseasemanagement.com/files/uploads/TrapDoorFigure4.png>
- [8] <http://www.vascular-diseasemanagement.com/files/uploads/TrapDoorFigure5.png>
- [9] <http://www.vascular-diseasemanagement.com/printmail/1721>
- [10] <http://www.vascular-diseasemanagement.com/print/1721>
- [11] <http://www.vascular-diseasemanagement.com/by-section/Vascular-Technique>
- [12] <http://www.vascular-diseasemanagement.com/e-news>