

Philadelphia College of Osteopathic Medicine DigitalCommons@PCOM

Otolaryngology (ENT) Resident Research

Graduate Medical Education Research

9-2018

Management of Enophthalmos from Silent Sinus Syndrome with a Customized Orbital Implant

Jason E. Cohn

Philadelphia College of Osteopathic Medicine

Mofiyinfolu Sokoya

Mohammad Hararah

Sameep Kadakia

Yadranko Ducic

Follow this and additional works at: https://digitalcommons.pcom.edu/ent_residents

 Part of the [Otolaryngology Commons](https://digitalcommons.pcom.edu/ent_residents)

Recommended Citation

Cohn, Jason E.; Sokoya, Mofiyinfolu; Hararah, Mohammad; Kadakia, Sameep; and Ducic, Yadranko, "Management of Enophthalmos from Silent Sinus Syndrome with a Customized Orbital Implant" (2018). *Otolaryngology (ENT) Resident Research*. 8.
https://digitalcommons.pcom.edu/ent_residents/8

This Article is brought to you for free and open access by the Graduate Medical Education Research at DigitalCommons@PCOM. It has been accepted for inclusion in Otolaryngology (ENT) Resident Research by an authorized administrator of DigitalCommons@PCOM. For more information, please contact library@pcom.edu.



Management of enophthalmos from silent sinus syndrome with a customized orbital implant

Jason E. Cohn^a, Mofiyinfolu Sokoya^b, Mohammad Hararah^b, Sameep Kadakia^{c,*}, Yadranko Ducic^c

^a Dept of Otolaryngology-Head and Neck Surgery, Philadelphia College of Osteopathic Medicine, Philadelphia, PA, USA

^b Dept of Otolaryngology-Head and Neck Surgery, University of Colorado School of Medicine, Aurora, CO, USA

^c Otolaryngology and Facial Plastic Surgery Associates, Fort Worth, TX, USA

ARTICLE INFO

Keywords:

Silent sinus syndrome
Enophthalmos
Endoscopic sinus surgery
Orbital reconstruction
Orbital implant
Ectropion repair

ABSTRACT

Background: We describe the surgical treatment of silent sinus syndrome, a disease characterized by progressive enophthalmos and hypoglobus due to orbital floor collapse with opacification of the maxillary sinus, in the presence of chronic maxillary sinusitis.

Methods: Case study of a 55-year-old male with persistent diplopia secondary to left-sided esotropia and enophthalmos from chronic maxillary sinusitis.

Results: Two stage procedure to treat the sinonasal and orbital symptoms, which include endoscopic sinus surgery to treat the underlying the ostial obstruction along with decompression of maxillary sinus. Then, reconstruction of the orbital floor with a customized implant.

Conclusions: Though the treatment of silent sinus syndrome can be challenging, we demonstrate the successful use of a customized orbital implant in the treatment of diplopia and enophthalmos from silent sinus syndrome using a two-stage approach.

Introduction

Silent sinus syndrome is a disease entity characterized by progressive enophthalmos and hypoglobus due to orbital floor collapse with opacification of the maxillary sinus, in the presence of subclinical maxillary sinusitis. Subsequently, gases are resorbed into the capillaries of the closed sinus cavity, creating negative pressure. As a result, secretions accumulate, and inflammation occurs, resulting in maxillary atelectasis and wall collapse [1,2]. Silent sinus syndrome was first described by Montgomery in 1964 [3], however, the term silent sinus syndrome was first described by Soparker in 1994 [4].

Case report

A 55-year-old male was referred to our practice by ophthalmology for persistent diplopia. His past medical history was only significant for a nasal fracture sustained 36 years ago. His past surgical history included bilateral laser refractive eye surgery. On physical examination, he was noted to have left-sided esotropia (Fig. 1A) and enophthalmos (Fig. 1B). Nasal endoscopy revealed mild crusting in the nasal cavity and a septal perforation, however, there was no edema, polyps or purulence. In summary, his enophthalmos was thought to be related to

negative pressure from chronic sinus disease.

The patient initially underwent endoscopic sinus surgery with wide maxillary antrostomy and ethmoidectomy to open the drainage pathways. He was noted to have some improvement following this, however, he continued to have persistent diplopia. Therefore, the decision was made to proceed with placement of a left orbital implant customized by DePuy Synthes[®] (Raynham, MA) and left lower lid ectropion repair. Pre-operatively, three-dimensional (3D) virtual planning was conducted with Materialise ProPlan CMF[®] (Plymouth, MI). A trans-conjunctival incision was made in order to access the orbital floor and place the orbital implant (Fig. 2). Following the procedure, the patient's esotropia (Fig. 3A) and enophthalmos (Fig. 3B) resolved as well as the diplopia. All photos of the patient have been approved for use by the patient as well as the IRB committee.

Discussion

Most patients with silent sinus syndrome will present in the third to fifth decade [1,2]. The incidence is equal in males and females. On physical examination, patients have orbital asymmetry, deepening of the superior orbital sulcus, and eyelid retraction [1]. All patients have hypoglobus, which ranges from 2 to 6 mm (mm). All patients have

* Corresponding author. Otolaryngology and Facial Plastic Surgery Associates, 923 pennsylvania avenue, Fort Worth, TX, 76104, USA.
E-mail address: sameep8779@gmail.com (S. Kadakia).

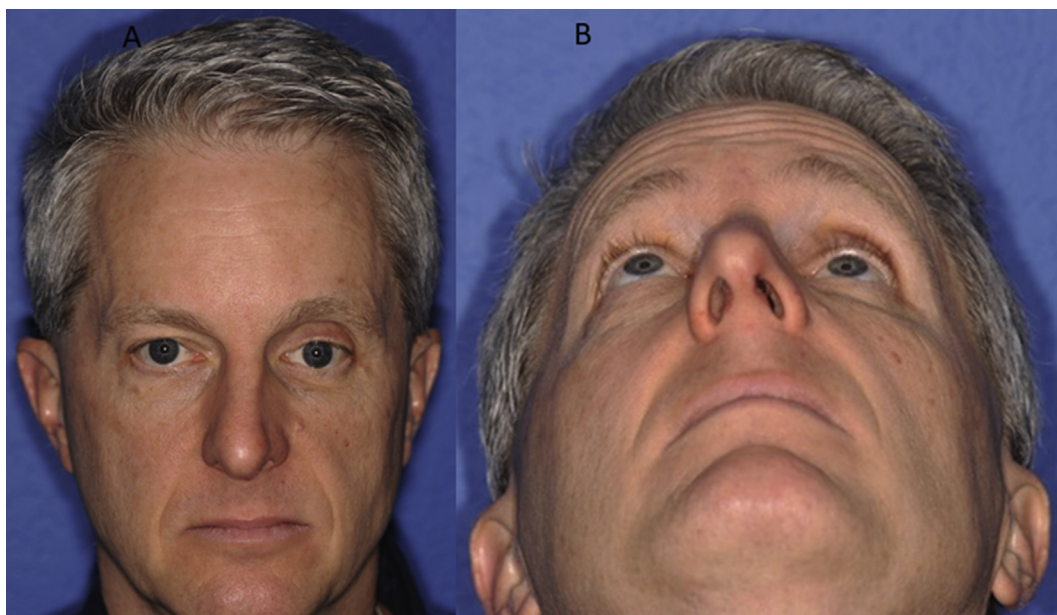


Fig. 1. A: Pre-operative frontal view of the patient revealing left-sided esotropia. 1B: Pre-operative basal view of the patient revealing left-sided enophthalmos.

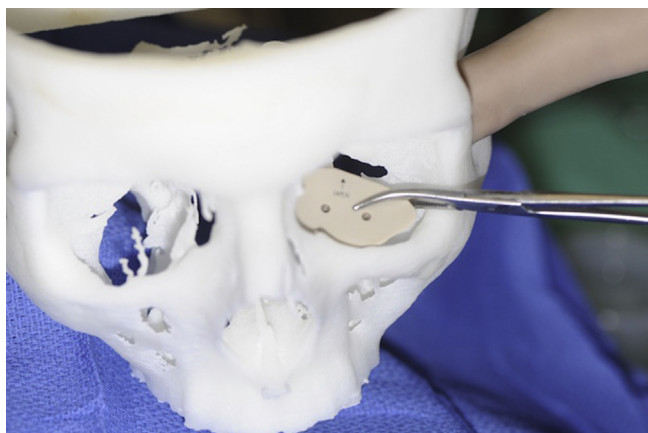


Fig. 2. Photo of pre-formed patient customized orbital implant.

enophthalmos, ranging from 2 to 5 mm [4]. Ocular motility and vision are usually not affected. Patients may complain of diplopia, however, most do not [1]. Our patient did display diplopia, which complicated and prolonged the treatment course.

Computed tomography is the imaging gold standard for evaluating silent sinus syndrome. Typical findings include complete or near complete unilateral obstruction of the maxillary sinus and obstruction of the ostiomeatal unit. Commonly, the uncinate process is retracted laterally resulting in enlargement of the middle meatus. There is also retraction and collapse of all the walls of the maxillary sinus. The reduction in maxillary sinus volume results in orbital volume enlargement. The globe is displaced inferiorly with displacement of the orbital contents in to the maxillary sinus, but the orbital soft tissue is normal in appearance [1].

The goals for treatment can be divided into sinonasal and orbital. The sinonasal goals include relieving the ostial obstruction and the decompression and evacuation of the maxillary sinus. The treatment of choice is an endoscopic uncinectomy and opening of the maxillary sinus ostium. The risk of injuring the orbital contents is much greater in patients with silent sinus syndrome due to the lower than normal position of the globe and orbital floor. Image-guided technology can be helpful [1]. Balloon sinuplasty has recently been described as a less invasive, alternative option to treat silent sinus syndrome by correcting

the position of the uncinate process and enlarging the maxillary sinus ostium without resecting tissue [5]. Our patient was first approached with endoscopic sinus surgery. However, his diplopia and enophthalmos were still present warranting further intervention.

The orbital goals involve reconstruction of the orbital floor. Both alloplastic and autogenous materials are available. The more common alloplastic materials are titanium plates, polyethylene implants (i.e. Medpor®), hydroxyapatite implants, supramid sheets, nylon sheets, and silicone implants [1,6,7]. The most common autogenous sources are septal cartilage, costochondral cartilage, and split calvarial bone [1,6]. The most common approach is either with a transconjunctival or subciliary incision [1]. Ultimately, our patient underwent pre-operative 3D virtual planning for a customized orbital implant via a transconjunctival approach. This resulted in improved diplopia and enophthalmos.

There is evidence to support the correction of the sinus and orbit as a two-stage repair. Several reports have shown resolution of enophthalmos and hypoglobus in the majority of patients treated with endoscopic sinus surgery without addressing the orbit [8–12]. These reports support waiting a several months between repair of the maxillary sinus and orbital defect to determine which patients do not correct on their own [1]. A two-stage approach has the potential advantages of avoiding placing an orbital implant in an infectious process and avoiding overcorrecting the globe position [8]. In our patient, we employed a two-stage procedure in order to see whether the diplopia corrected with endoscopic sinus surgery alone. However, others have advocate a single-surgical step for endoscopic surgery and orbital reconstruction [13–15]. The single-stage approach has the potential advantages of avoiding morbidities associated with a second hospital stay and second anesthesia event [13].

There are nonsurgical approaches described for treating residual enophthalmos with hyaluronic acid gel to improve the globe position [16,17]. This straightforward and safe technique offers another option to treat enophthalmos after sinus surgery but may not change hypoglobus [16].

Conclusion

Though the treatment of silent sinus syndrome can be challenging, with nonsurgical and single stage procedures available, we demonstrated the successful use of a customized orbital implant in the

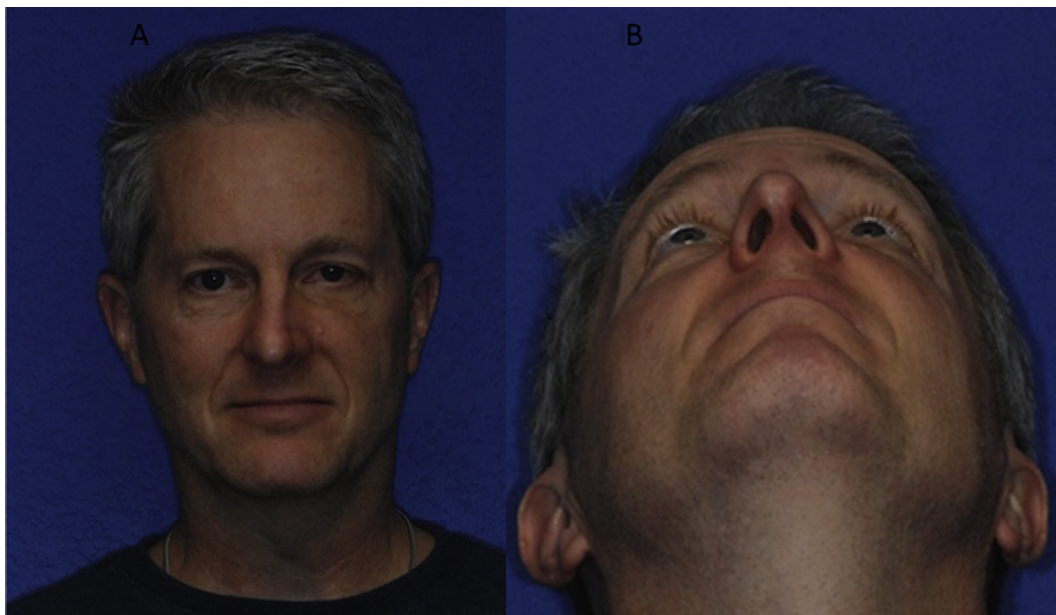


Fig. 3. A: Post-operative frontal view of the patient revealing resolution of left-sided esotropia. 3B: Post-operative basal view of the patient revealing resolution of left-sided enophthalmos.

treatment of diplopia and enophthalmos from silent sinus syndrome using a two-stage approach.

Declarations of interest

None.

Funding

This research did not receive any specific grant from funding agencies in the public, commercial, or not-for-profit sectors.

References

- [1] Annino Jr. DJ, Goguen LA. Silent sinus syndrome. *Curr Opin Otolaryngol Head Neck Surg* 2008;16(1):22–5.
- [2] Numa WA, Desai U, Gold DR, Heher KL, Annino DJ. Silent sinus syndrome: a case presentation and comprehensive review of all 84 reported cases. *Ann Otol Rhinol Laryngol* 2005;114(9):688–94.
- [3] Montgomery WW. Mucocoele of the maxillary sinus causing enophthalmos. *Eye Ear Nose Throat Mon* 1964;43:41–4.
- [4] Soparkar CN, Patrinely JR, Cuaycong MJ, et al. The silent sinus syndrome. A cause of spontaneous enophthalmos. *Ophthalmology* 1994;101:772–8.
- [5] Kilty SJ. Maxillary sinus atelectasis (silent sinus syndrome): treatment with balloon sinuplasty. *J Laryngol Otol* 2014;128:189–91.
- [6] Pula JH, Mehta M. Silent sinus syndrome. *Curr Opin Ophthalmol* 2014;25(6):480–4.
- [7] Clarós P, Ahmed H, Minka Ngom EG, et al. The silent sinus syndrome: a reconstruction of the orbital floor with Medpor implant. *Rev Laryngol Otol Rhinol* 2015;136(1):37–40.
- [8] Thomas RD, Graham SM, Carter KD, Nerad JA. Management of the orbital floor in silent sinus syndrome. *Am J Rhinol* 2003;17(2):97–100.
- [9] Vander Meer JB, Harris G, Toohill RJ, Smith TL. The silent sinus syndrome: a case series and literature review. *Laryngoscope* 2001;111(6):975–8.
- [10] Sivasubramaniam R, Sacks R, Thornton M. Silent sinus syndrome: dynamic changes in the position of the orbital floor after restoration of normal sinus pressure. *J Laryngol Otol* 2011;125:1239–43.
- [11] Babar-Craig H, Kayhanian H, De Silva DJ, Rose GE, Lund VJ. Spontaneous silent sinus syndrome (implosion antrum syndrome): case series of 16 patients. *Rhinology* 2011;49(3):315–7.
- [12] Martinez-Capoccioni G, Varela-Martinez E, Martin-Martin C. Silent sinus syndrome an acquired condition and the essential role of otorhinolaryngologist consultation: a retrospective study. *Eur Arch Oto-Rhino-Laryngol* 2016;273(10):3183–8.
- [13] Cardesin A, Escamilla Y, Romera M, et al. Single surgical step for endoscopic surgery and orbital reconstruction of a silent sinus syndrome. *Acta Otorrinolaringol Esp* 2013;64:297–9.
- [14] Behbehani R, Vacareza N, Bilyk JR, Rubin PA, Pribitkin EA. Simultaneous endoscopic antrostomy and orbital reconstruction in silent sinus syndrome. *Orbit* 2006;25(2):97–101.
- [15] Sesenna E, Oretti G, Anghinoni ML, Ferri A. Simultaneous management of the enophthalmos and sinus pathology in silent sinus syndrome: a report of three cases. *J Cranio-Maxillo-Fac Surg* 2010;38(6):469–72.
- [16] Mavrikakis I, Detorakis ET, Yiotakis I, Kandiloros D. Nonsurgical management of silent sinus syndrome with hyaluronic acid gel. *Ophthalmic Plast Reconstr Surg* 2012;28. e6–7.
- [17] Grusha Y, Khovrin V, Stoyukhina A, Sheptulin V. Hyaluronic acid gel Re-Injection for enophthalmos correction in silent sinus syndrome. *Orbit* 2015;34(6):351–3.