

Anterior Cervical Foraminotomy: Short Term Outcomes In Patients With Isolated Cervical Radiculopathy

Howard Eisenbrock, DO. Mark A. Rivkin, DO., Amir Dehdashti, MD.
Philadelphia College of Osteopathic Medicine, Philadelphia PA
Geisinger Medical Center, Danville PA

Introduction

Anterior cervical foraminotomy (ACF) is a novel approach involving direct decompression of nerve from an offending agent without fusion. Historically, several anterior and posterior approaches were utilized to treat cervical radiculopathy. Anterior cervical discectomy necessitates fusion and is subject to adjacent segment disease as well as loss of ROM. Posterior laminoforaminotomy seldom allows for removal of disc fragment and is associated with higher postoperative pain.

Patients and Methods

Between May 2010 and March 2013, 16 patients with one or two level cervical spondylosis with radiculopathy without myelopathy who failed conservative therapies such as anti-inflammatory medications, physical therapy or injections underwent anterior foraminotomy. All patients underwent pre-operative MRI that confirmed either a "soft" disc, spondylitic spur or a combination of the two. 15 of the 16 patients had no prior surgery. One had a prior ACDF at an adjacent level. All patients were assessed at two weeks for a wound check and again at two months. The visual analog score was used to assess their pre-operative and post-operative pain symptoms. A paired t test was used to compare pre- and post-operative VAS. Significance was accepted at a value of $p < 0.05$.

Surgical Procedure

A standard ACD approach was made with the skin incision located on the side of the lesion. After the longus colli was elevated, a cervical retractor was inserted. At this point the surgical microscope was introduced. On the pathological side the longus coli muscle was cut at the level of the uncus measuring 1x1 cm. A matchstick burr, centered on the uncovertebral joint, was used to drill straight down along the surface of the joint until the posterior surface was encountered. A thin layer of the cortical bone of the lateral wall of the uncinat process was preserved to protect the vertebral artery. The drill hole was elliptically widened in a rostro-caudal direction and then the postereo-lateral cortical layer was removed with a combination of 1-mm and 2-mm Kerrison punch. After removal, the herniated disc fragments were mobilized with a microhook and removed with a microforcep. Next the posterior longitudinal ligament was partly resected. When the path of the nerve root above and lateral to the pedicle of the lower vertebral body was finally decompressed and hemostasis was obtained, the retractor was removed. The platysma and the skin were closed with absorbable sutures.

Images

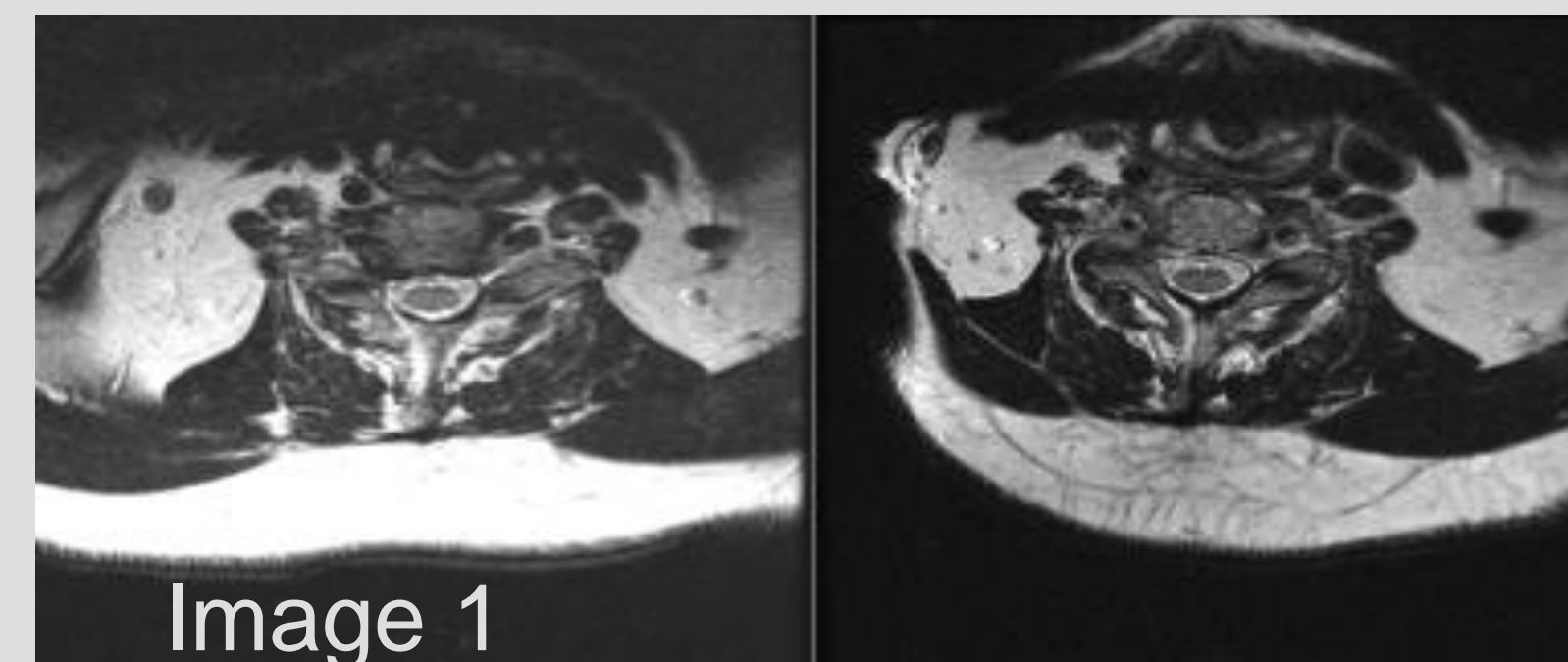


Image 1: Left figure shows pre-operative MRI in a patient with right sided foraminal stenosis at C5/6. Right figure shows immediate post-operative MRI of same patient. Note the residual in buckling of the PLL however there has been complete removal of the herniated disc

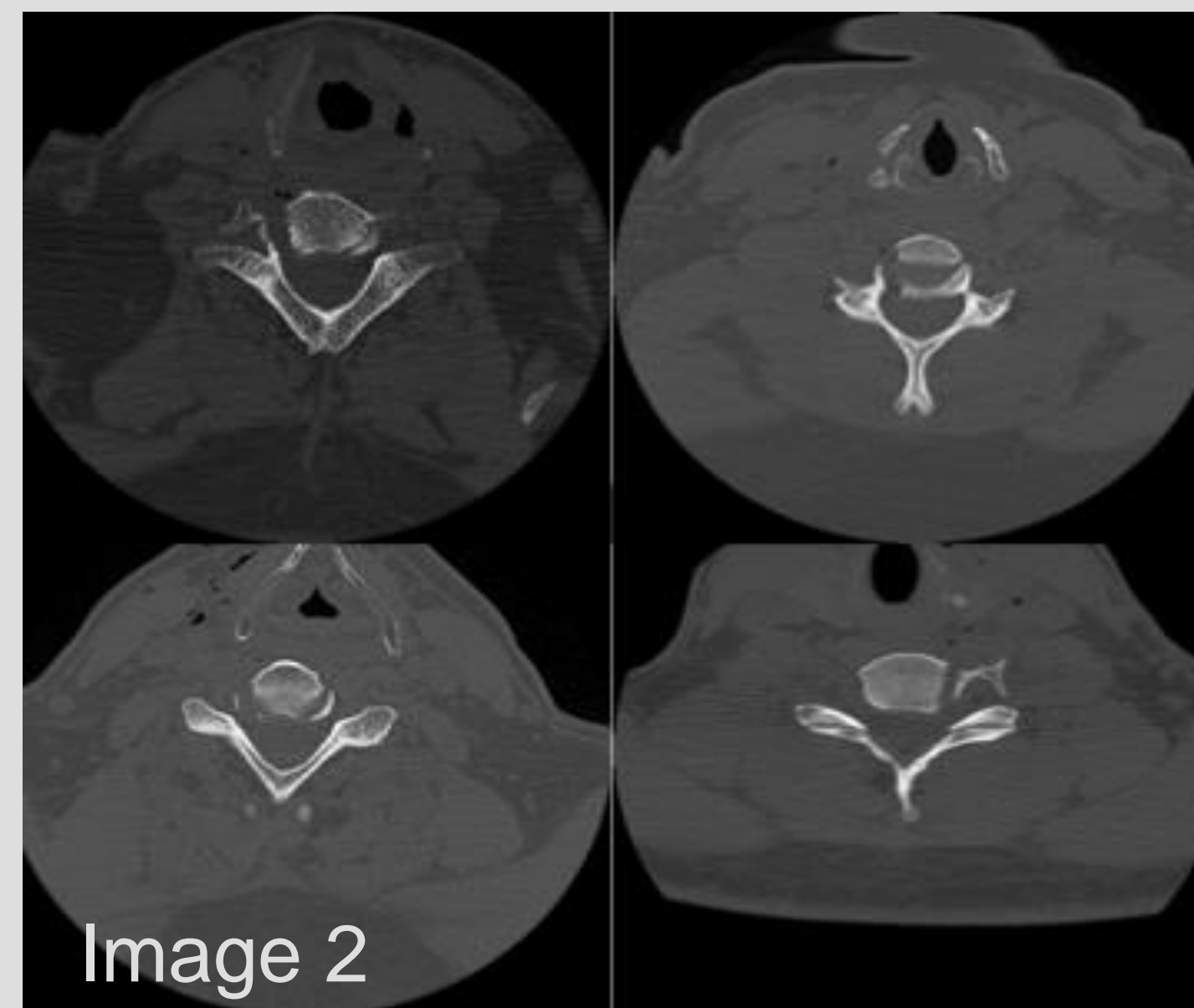
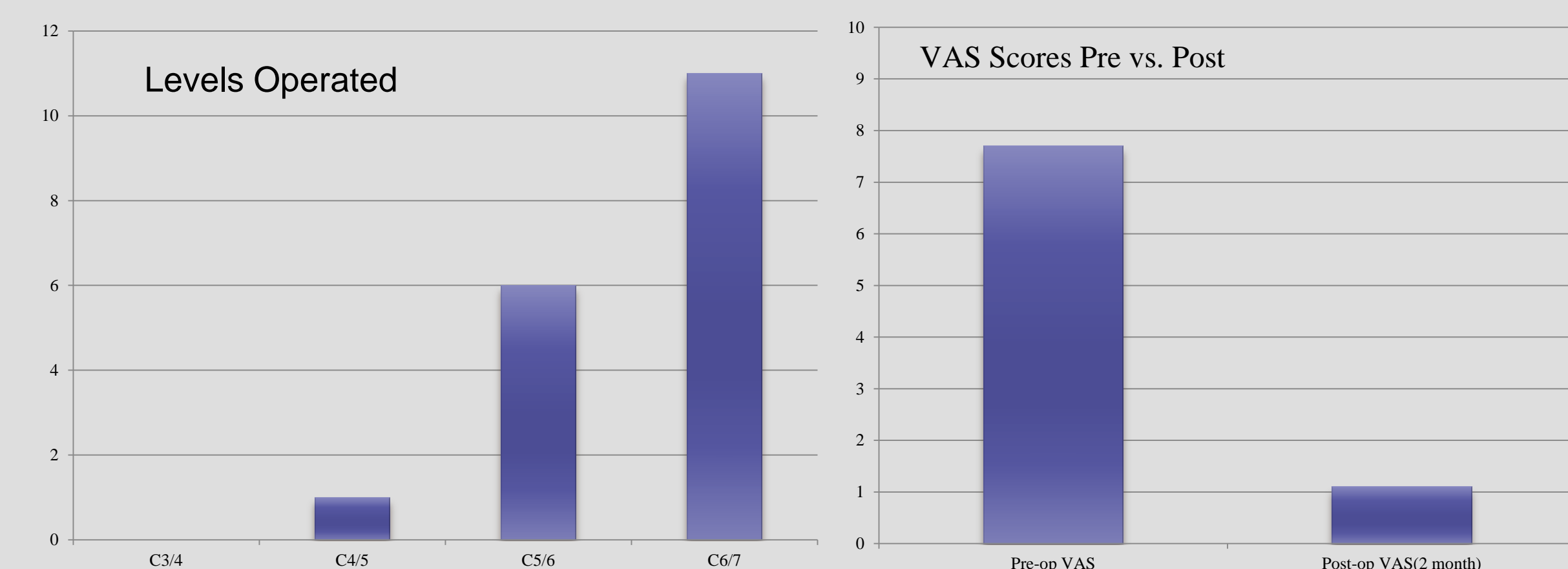


Image 2: four examples of postoperative CT in patients that underwent ACF. Note the narrow corridor of approach, with protection of the vertebral artery

Data Tables



Patient Characteristics	Count	mean
age(yr)	34-71	46.2
male	11	
female	5	
duration of symptoms		
<6 months	8	
6 months to 1 year	4	
1-3 years	2	
>3 years	2	
symptoms(%)		
neck pain	56%	
radicular pain	93%	
shoulder pain	19%	
parasthesia	81%	
signs(%)		
weakness	37%	
sensory loss	31%	
decreased reflexes	25%	

Results

- The average VAS pre-operatively was 7.75 and the average VAS score post-operatively was 1.1 (p value 0.02)
- All but two patients with weakness returned to normal strength
- Of the 13 patients that had pre-operative parasthesias only five had residual symptoms, all of which they described as improved compared to their pre-operative symptoms
- OR times ranged from 97-174 minutes with a mean of 124.6 minutes

Conclusion

ACF is an alternative to standard posterior and anterior cervical operations for the treatment of cervical radiculopathy. In our study patients had good short term outcomes, however long term data needs to be obtained. ACF is a motion preserving operation and comparative data should be obtained between cervical disc arthroplasty and ACF.

Disclosure

The authors have the no financial or personal relationships to disclose with commercial entities that may have a direct or indirect interest in the subject this presentation