

Introduction

Colonic varices appreciated on colonoscopy are extremely rare and typically indicative of portal hypertension or chronic hepatopathology. Even more rare are those cases with no underlying pathology, idiopathic colonic varices. Here we report a case of these unexplained varices.

Background

Even in the presence of advanced liver disease, colonic varices are a relatively rare occurrence. One endoscopic study noted colonic varices in only 31% of patients with cirrhosis of the liver (1). The prevalence of colonic varices is virtually unattainable, as it is possible the pathology could remain subclinical for a lifetime. The only data available regarding prevalence of the condition is an autopsy study performed in 1962, which found 2 cases of colonic varices out of 2,912 cadavers (0.0007%) (2).

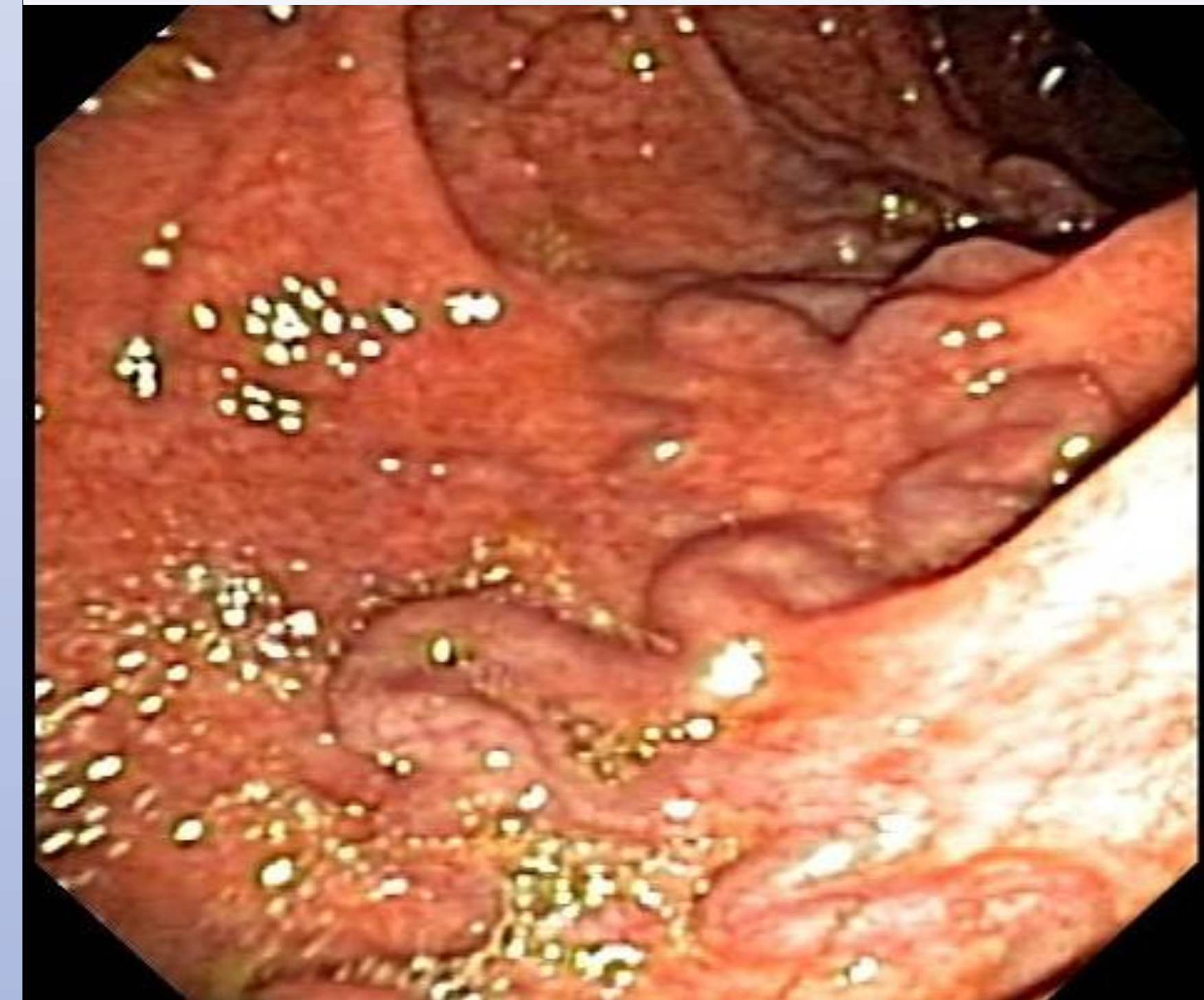


Figure A: Colonic Varices at Colonoscopy

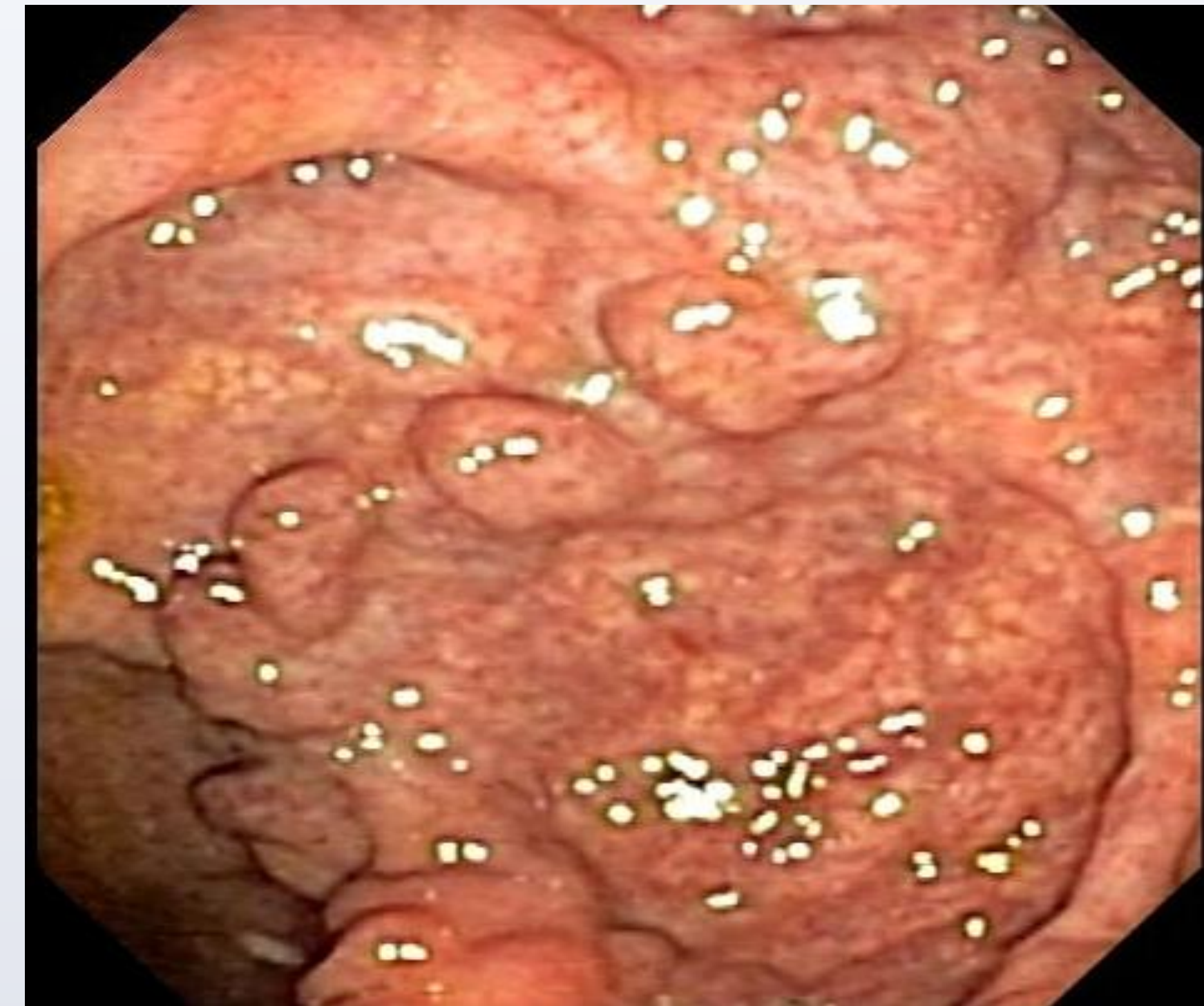

Figure B: Colonic Varices at Colonoscopy

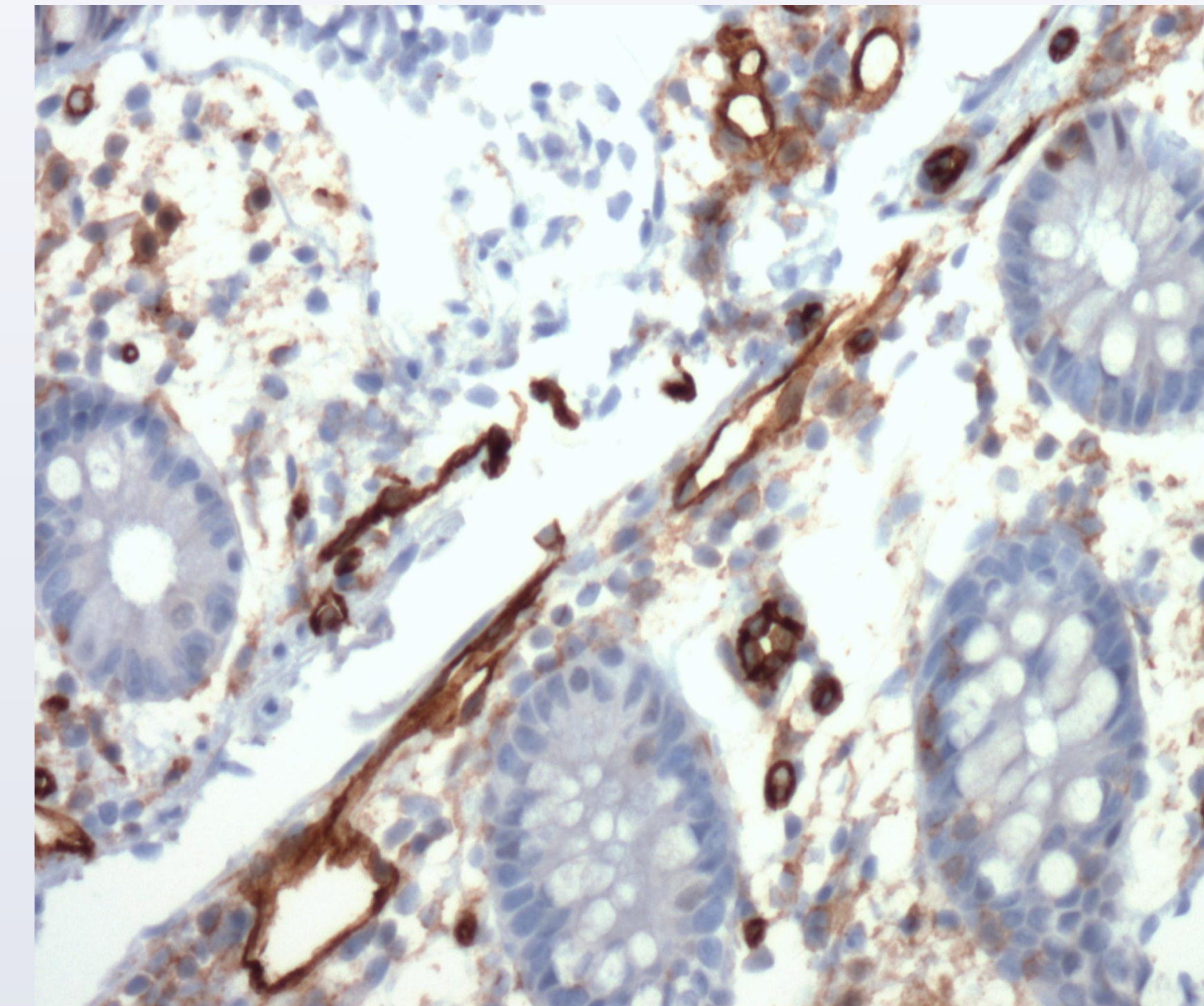


Figure C: Dilated Vessels w/ Hemorrhage

Case Report

A 30 year old male with a ten year history of chronic diarrhea, bloating, and occasional bloody stool presented with five days of abdominal discomfort, distention and diarrhea. An abdominal CT was obtained and showed a possible partial obstruction in the terminal ileum. Family history, social history, and physical exam were unremarkable. An inflammatory process was suspected and a colonoscopy was scheduled.

At colonoscopy, diffuse erythema and congestion were noted in the terminal ileum and throughout the colon. Markedly dilated, tortuous veins (varices) were appreciated throughout the colon and rectum (Figures A & B). From samples taken throughout the colon, pathology reported dilated thin walled vessels in the lamina propria with vascular congestion and hemorrhage (Figure C), but no indications of colitis. Due to the finding of varices throughout the colon, portal hypertension or liver disease was suspected.

A review of the patient's CT scan from his ER visit yielded no evidence of hepatopathology, and mesenteric arteries and veins appeared normal. Labs performed during his ER visits and after colonoscopy were also unremarkable.

Doppler studies found normal flow in the hepatic and portal veins, as well as the IVC. Hepatic and portal vein pressure measurements found a mean right atrial pressure of 10mm Hg, a mean free hepatic vein pressure of 10mm Hg, and a mean wedged hepatic vein pressure of 11mm Hg, ruling out hepatic outflow obstruction and portal hypertension. Abdominal ultrasound showed diffusely increased echogenicity consistent with diffuse fatty change. A core liver biopsy confirmed mild to moderate steatosis, but no significant cirrhosis, necrosis, or bridging fibrosis.

Upper endoscopy revealed no esophageal varices or signs of venous congestion.

At four weeks, the patient reports moderate improvement. He continues with two soft bowel movements per day, but denies pain. After an extensive work up, no clear explanation for his colonic varices emerged. The patient will be followed for possible recurrence and monitored for signs of liver disease.

Conclusions

Idiopathic colonic varices, those cases without an identifiable underlying pathology, are extremely rare. Only about 40 cases have been reported in the literature. Possible etiologies that must be ruled out include portal hypertension, both cirrhotic and non-cirrhotic liver disease, hepatic or portal vein thrombosis, vascular anomalies, and adhesions, which tend to cause localized varices. All of these causes were ruled out or deemed extremely unlikely during the workup of our patient.

Treatment of idiopathic colonic varices ranges from conservative management to total colectomy in cases of refractory bleeding. At least 12 of 40 documented cases have required surgical intervention.

References

1. Bresci G, Parisi G, Capria A. Clinical relevance of colonic lesions in cirrhotic patients with portal hypertension. *Endoscopy*. 2006 Aug;38(8):830-5.
2. Feldman M Sr, Smith VM, Warner CG. Varices of the colon. Report of three cases. *JAMA*. 1962 Mar 3;179:729-30.