

A case of Remitting Seronegative Symmetrical Synovitis with Pitting Edema Syndrome

Hideyuki Hasebe, Shigeru Kusuzaki, Yoshiyuki Suzuki
Hideaki Hattori, Takayoshi Soga¹⁾

Department of Cardiology, Shizuoka Red Cross Hospital

1) Department of Rheumatology, Shizuoka Red Cross Hospital

Abstract : A 74-year old woman with a history of hypertension admitted to the hospital because of dyspnea and leg edema. Hypertensive heart failure was suspected with the presence of pulmonary edema and left ventricular hypertrophy. But there was no improvement with the administration of oral furosemide. The patient had had arthralgia and morning stiffness. Serologic examination was negative for rheumatoid factor. Prednisolone provided a fairly good improvement in dyspnea and leg edema. The most likely diagnosis was Remitting Seronegative Symmetrical Synovitis with Pitting Edema syndrome. This syndrome is the third group of seronegative rheumatoid arthritis, and many things are obscure. Especially polymyalgia rheumatica is confused with this syndrome, so there are many things to make clear including differentiating from polymyalgia rheumatica. Remitting Seronegative Symmetrical Synovitis with Pitting Edema syndrome is not popular, so we should recognize this syndrome as one of the diseases that cause leg edema.

Key words : RS₃PE syndrome, edema, congestive heart failure

I . Introduction

Remitting Seronegative Symmetrical Synovitis with Pitting Edema (RS₃PE) syndrome represents some features; sudden onset of symmetrical synovitis and pitting edema, seronegativity of rheumatoid factor, sufficient response to steroid. Because of leg edema, RS₃PE syndrome is sometimes mistakenly diagnosed as congestive heart failure. We report here a case of RS₃PE that was difficult to make a diagnosis.

II . Case

Patient : 74 y/o, female

A 74-year-old woman was admitted to the hospital. One month before admission, She had had bilateral leg edema and consulted a local medical

doctor. She was made a diagnosis of hypertension and depressor was prescribed, but her leg edema developed later. And she developed swelling and morning stiffness of small hand joints in those days. She noted chest oppression at night and her leg edema got severe, so she was seen in consultation. She had had past history of hypertension.

Family History : nothing peculiar

Physical Examination : 139 cm in height and 58.3 kg in weight. Her vital signs were 112/57 mmHg in blood pressure, 80/min in heart rate, 36.6°C in body temperature. Her eyes were not anemic and not icteric. No goiter and superficial lymph node was detected. Her heart sounds and breath sounds were normal. She had severe bilateral pitting edema of lower extremities and no edema of upper arms. There were symmetrical pitting

edema and deformation in her 2nd~5th distal and proximal interphalangeal joints of bilateral hands. Neurological examination was normal. Laboratory data shows that serum albumin, renal function, thyroid function, renin-angiotensin system were all within normal limites. Serum matrix metalloproteinase-3 (MMP-3) was elevated (68.3 ng/ml), that suggested accelerated destruction of

membranous synovialis. And serum brain natriuretic peptides (BNP) was slightly elevated that means ventricular load was mild.

Electrocardiogram (figure 1) revealed sinus rhythm and negative T wave in lead V₂₋₅ lead. Chest X-ray (figure 2a) revealed cardiomegaly (cariothoracic ratio = 50%), and slight lung congestion. Transthoracic echocardiogram revealed normal

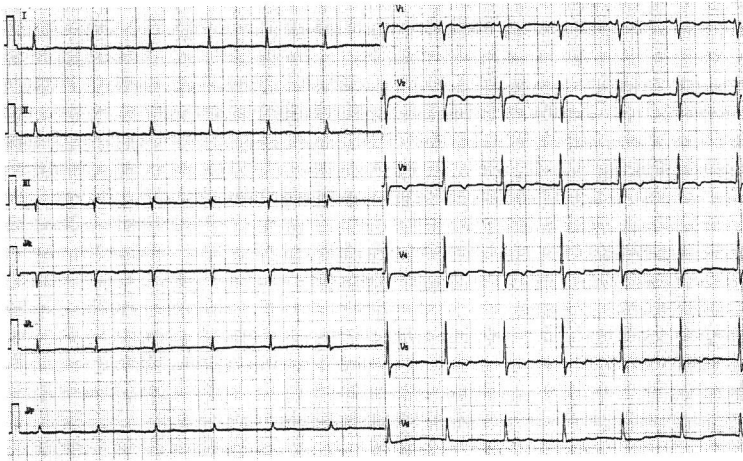
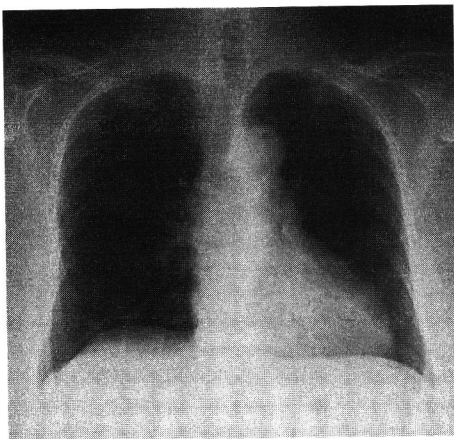
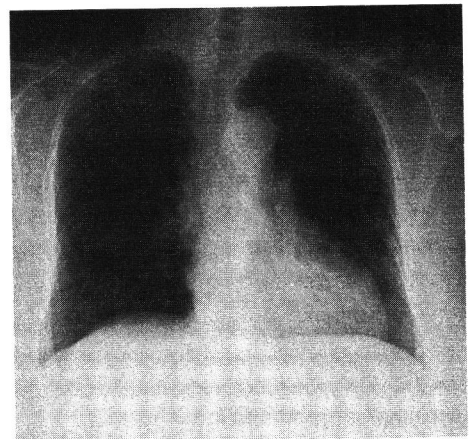


Figure 1 Electrocardiogram : rhythm is sinus and negative T wave were found in lead V₂₋₅



a



b

Figure 2 Chest X-ray

a : before taking furosemide

b : after taking furosemide (no change is seen compared to a)

contraction, normal chamber size, mild mitral valve regurgitation, mild tricuspid valve regurgitation, and no dilatation of inferior vena cava. Lung perfusion scintigraphy revealed no defect, so pulmonary embolism seemed negative.

Clinical course: At first, leg edema was considered to be caused by heart failure associated with sodium excess, because chest X-ray revealed cardiomegaly and slight lung congestion. Oral furosemide 20mg daily was prescribed. But leg edema had not be improved at all and chest X-ray revealed no change (Figure 2b). The patient also had morning stiffness and joint swelling. RS₃PE syndrome was suspected from clinical course and examinations. Oral prednisolone 10mg daily was prescribed. Her leg edema, morning stiffness of small hand joints started was disappeared immediately and went into complete remission in about one week. Oral prednisolone has been continued, and the patient has been in the state of complete remission.

III. Discussion

RS₃PE syndrome is first reported by McCarty in 1985¹⁾. This disease represent acute onset of symmetrical synovitis and pitting edema of extremities, and characteristically rheumatoid factor is negative. Evidence has been advanced in recent years suggesting that persistently seronegative polyarthritis differs in a number of ways from seropositive disease²⁾. It is clear that at least three subgroups of seronegative rheumatoid arthritis can be identified. One group show relative asymmetry, with prominent involvement of large joints such as hips and shoulders, resembling the pattern of seronegative juvenile rheumatoid arthritis. A second group present an erosive osteoarthritis picture, but the process involve the wrists, carpal joints, metacarpophalangeal joints, elbows and ankles-joints typically spared in and primary generalized osteoarthritis. Bony alkylosis and prominent osteophytes, both uncharacteristic of seropositive rheumatoid arthritis, are notable. The RS₃PE syndrome represents a third group. The entire problem of seronegative

“rheumatoid arthritis” seems ripe for additional aggressive, thoughtful, clinical and laboratory dissection. Pitting edema of the hands rarely occurs in seropositive rheumatoid arthritis, and when it does, it is almost always unilateral. The etiology of PS₃PE syndrome remains obscure. But it seems that this disease is associated with HLA-B7 (relative risk is 9.5)³⁾. And this syndrome is not established perfectly, therefore polymyalgia rheumatica is the only disease that might reasonably be confused with the RS₃PE syndrome. This condition, which occurs in elderly persons, may be associated with synovitis and nonspecific signs, symptoms, and laboratory tests indicative of inflammatory condition. This syndrome also remits spontaneously over several years. But to our knowledge, symmetrical pitting edema and an HLA association have never been found in polymyalgia rheumatica⁴⁾.

The therapy of this syndrome is low dose of prednisone, and when they are used, they result in dramatic clinical improvement. Almost all patients go into complete remission within days to 2weeks, and within 24hours in some cases. Empiric use of acetylsalicylate antipyrene (ASA) non-steroid anti-inflammatory drugs (NSAIDs), hydroxychloroquine, or remitting agents seemed to yield slower and more variable response⁵⁾.


IV. Conclusion

We reported a case of RS₃PE syndrome. This disease is classified in rheumatology, but the patients are sometimes seen in cardiology because it represents leg edema. So, we should keep it mind the possibility of RS₃PE syndrome in case of leg edema accompanied with peripheral synovitis and differentiate from congestive heart failure.

Reference

- 1) McCarty DJ, O'Duffy JD, Pearson L, et al. Remitting seronegative symmetrical synovitis with pitting edema RS₃PE syndrome. JAMA 1985 ; 254 : 2763-2767.
- 2) Bardin T, Legrand L, Nareau B, et al. HLA antigens and seronegative rheumatoid arthritis.

- Ann Rheum Dis 1985 ; 44 : 50-53.
- 3) Arnett FC. Immunogenetics and arthritis. In : McCarty DJ, editors. Arthritis and allied conditions a test of rheumatology. 10th ed. Philadelphia : Lea & Febiger ; 1985 ; p 405-414.
- 4) Russell EB, Hunter JB, Person L, et al. Remitting, seronegative, symmetrical synovitis with pitting edema-13 additional cases. J Rheumatol 1990 ; 17 : 633-639.
- 5) 福田孝昭. RS₃PE 症候群. 日内会誌 2000 ; 89 : 2110-2115



Address Correspondence :

Hideyuki Hasebe, Department of Internal Medicine, Shizuoka Red Cross Hospital,
8-2 Ohte-machi, Shizuoka-shi 420-0853, Japan
Tel : 054-254-4311