

◀症例報告▶

A case of a pregnant woman giving birth to a healthy neonate, complicated with a hypercoiled umbilical cord and umbilical artery thrombosis

Kenji Yorita,¹ Yohei Takahashi,² Yu Tanaka,² Yuka Kai,² Koki Hirano,²
Tetsuro Furumoto,³ Takanori Abe,³ Naoto Kuroda,¹ Keiko Mizuno,¹
Masahiko Ohara,¹ Kaori Yasuoka,¹ Yukari Wada,¹ Yoshiko Agatsuma,¹
Yuichiro Sato,⁴ Akihiko Mochizuki⁵

Abstract : The umbilical vessels have two arteries and one vein, and thrombosis rarely occurs in the umbilical vein and arteries. Umbilical artery thrombosis (UAT) has a low incidence rate compared with umbilical venous thrombosis. Discordant umbilical arteries (DUAs), wherein the size of the arteries is different, has rarely been reported, and the smaller umbilical artery has also been described as the hypoplastic umbilical artery (HUA). UAT and HUA/DUAs can be related to poor perinatal outcomes or fetus malformation. We herein present a case of a nulliparous and primigravid 37-year-old Japanese pregnant woman, with sonographic diagnosis of single umbilical artery at 24 weeks of gestation by the loss of left-sided umbilical artery. Subsequently, serological test showed elevated serum immunoglobulin M (IgM) and IgG antibodies for cytomegalovirus (CMV). Neither morphological nor growth abnormality of the fetus was sonographically found, and no CMV DNA was detected in the vaginal discharge. Clinical follow-up was performed, and the fetus was small for gestational age during the course of the observation. At 40 and 5/7 weeks of gestation, vaginal delivery was attempted, but cesarean delivery was performed because fetal distress was suspected by cardiotocography. An appropriate-for-age female neonate without anomaly was born, and the Apgar score was 8 and 9 after 1 and 5 min, respectively. Neither elevated serum anti-CMV IgM antibodies nor presence of CMV DNA in the urine was found in the neonate. Six days after cesarean section, the mother and neonate were discharged without any problems. A thin and hypercoiled umbilical cord was found macroscopically, and pathology confirmed that the umbilical cord had one vein and two arteries, which included an HUA showing occlusive thrombosis. The placenta showed no apparent abnormalities except for a small infarction at the marginal zone. CMV infection was not found in the umbilical cord and placenta. The pathogenesis of UAT was speculated to be related to the hypercoiled umbilical cord. This is the first case of a healthy, appropriate-for-age, full-term neonate born with UAT.

Key words : umbilical artery thrombosis, single umbilical artery, hypoplastic umbilical artery, discordant umbilical arteries, cytomegalovirus infection

¹Department of Diagnostic Pathology, Japanese Red Cross Kochi Hospital, Kochi-city, Kochi, Japan;

²Department of Obstetrics and Gynecology, Japanese Red Cross Kochi Hospital, Kochi-city, Kochi, Japan;

³Department of Pediatrics, Japanese Red Cross Kochi Hospital, Kochi-city, Kochi, Japan;

⁴Department of Diagnostic Pathology, University of Miyazaki Hospital, Faculty of Medicine, University of Miyazaki, Miyazaki-city, Miyazaki, Japan;

⁵Department of Obstetrics, Kanagawa Children's Medical Center, Yokohama-city, Kanagawa, Japan

Background

The umbilical cord normally has two arteries and one vein. Single umbilical artery (SUA) is only one artery in the umbilical cord and is considered as a major congenital cord abnormality. SUA can often accompany fetal malformations, with an average of approximately 20%,¹ and intrauterine growth retardation (IUGR) of the fetus. Our case sonographically showed SUA with loss of the left umbilical artery (UA). Abuhamad et al.² described that congenital anomalies occur in 20 of 77 (26%) fetuses with SUA, with 16 of 56 (29%) in those with absence of the left UA and 4 of 21 (19%) in those with absence of the right UA. Thus, clinical examination for fetal anomalies and careful follow-up are necessary when SUA is detected. However, umbilical cords with clinical diagnosis of SUA can histologically have one patent artery and one occlusive artery or a tiny muscular remnant. Umbilical artery thrombosis (UAT) is rare, with an incidence of 0.0275% of deliveries (11/40,000),³ can lead to a clinical diagnosis of SUA and can be associated with poor neonatal outcomes.³⁻⁷ We recently experienced a case of a nulliparous and primigravid woman with UAT. The thrombosed UA was much smaller than the patent UA, which suggested the presence of hypoplastic umbilical artery (HUA) or discordant umbilical arteries (DUAs). HUA/DUAs may be also related to poor perinatal outcomes and/or fetal anomalies.^{8,9} We herein present a previously undescribed case of a healthy neonate with a hypercoiled umbilical cord with UAT. Clinical examination and careful medical follow-up was required because of elevated serum immunoglobulin M (IgM) and IgG antibodies for cytomegalovirus (CMV) detected in the serum of the pregnant woman.

Case presentation

Clinical summary

We present a case of a 37-year-old nulliparous and primigravid Japanese woman. She was referred to our hospital due to clinical follow-up from the 31 and 5/7 weeks of gestation. She was healthy without risk factors, including diabetes mellitus. Maternal blood type was B positive.

When she was at 24 weeks of gestation, SUA was noted on ultrasonography due to the absence of the left UA (**Figure 1**). TORCH serology was negative except for elevated serum IgM and IgG antibodies against CMV with enzyme-linked immunosorbent assay; the titers of anti-CMV IgM and IgG antibodies were 1.49 (<0.8) and 15.5 (<2.0), respectively. Primary CMV infection or CMV reactivation of the mother during pregnancy was suspected. Ultrasound examination showed neither morphological abnormalities nor growth retardation of the fetus. On 28 weeks of gestation, the anti-CMV IgM antibody titer (1.68) was almost stable, and the DNA of CMV was not detected in the vaginal discharge. Thus, medical follow-up was performed, the fetus was small for gestational age at 35 and 38 weeks of gestation during the course observation.

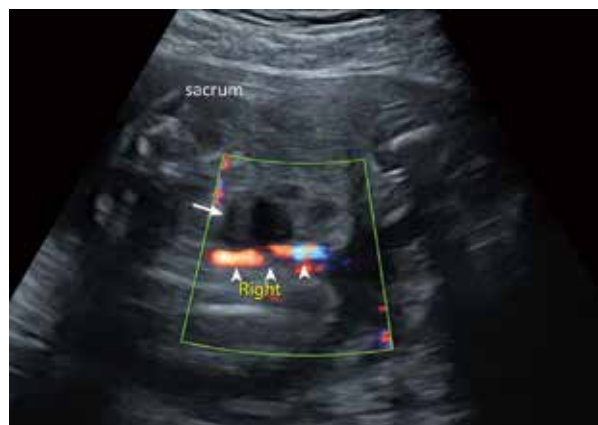

Figure 1 A sonographic image of the umbilical cord at 25 and 5/7 weeks of gestation. Right umbilical artery (arrowheads) is present around the urinary bladder (an arrow), whereas left umbilical artery is absent.

At 40 and 5/7 weeks of gestation, vaginal delivery was attempted by induction of labor, but cardiotocography confirmed severe variable decelerations in the first stage of labor, and emergency cesarean delivery was performed. A healthy female neonate without malformation was born, with a birth weight of 2732 g (appropriate for age), length of 49 cm, head circumference of 32 cm, and chest circumference of 31 cm. The Apgar scores were 8 and 9 after 1 and 5 min, respectively. Umbilical cord blood analysis showed an arterial pH of 7.29, and complete blood count was normal. CMV infection was unlikely in the neonate because the neonate had no CMV-related

complications, the neonatal serologic test showed titer of anti-CMV IgM antibody was 0.31 (<0.8), and no CMV DNA was detected by polymerase chain reaction using the urine. Six days after cesarean section, the patient and her neonate were discharged without any problems.

Macroscopic and microscopic findings of the umbilical cord and the placenta

Grossly, the placenta (**Figure 2**) was 14 × 13 × 1.5 cm, and its weight was 420 g. The umbilical cord diameter and length (**Figure 2**) were 8 mm and 58 cm, respectively, and 7 rotations were focally seen per 10cm. Although the placental weight and cord length were within normal limits, a thin and hypercoiled umbilical cord was found. The cord insertion was slightly eccentric and not velamentous. Infarction and hematoma were not seen in the placenta. Histologically, the umbilical cord includes three vessels (**Figure 3A-**

B), and the smallest vessel showed occlusive thrombosis with focal calcification (**Figure 3C-F**). The other non-occlusive two vessels were one artery (**Figure 3A, B, G**) and one vein (**Figure 3A, B, H**), and the thrombosed vessel was considered as an artery due to the loss of

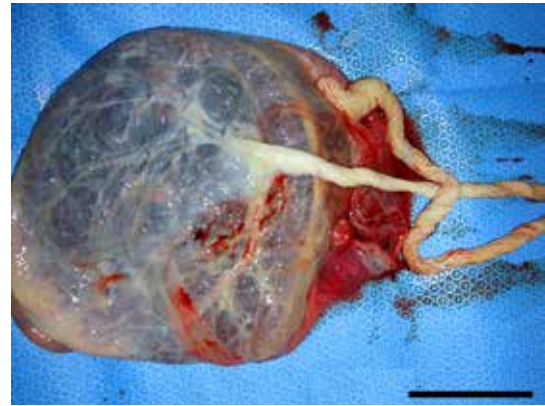


Figure 2 Macroscopic findings of the placenta and umbilical cord

A thin umbilical cord shows eccentric insertion and focal hypercoiling. The bar represents 5 cm.

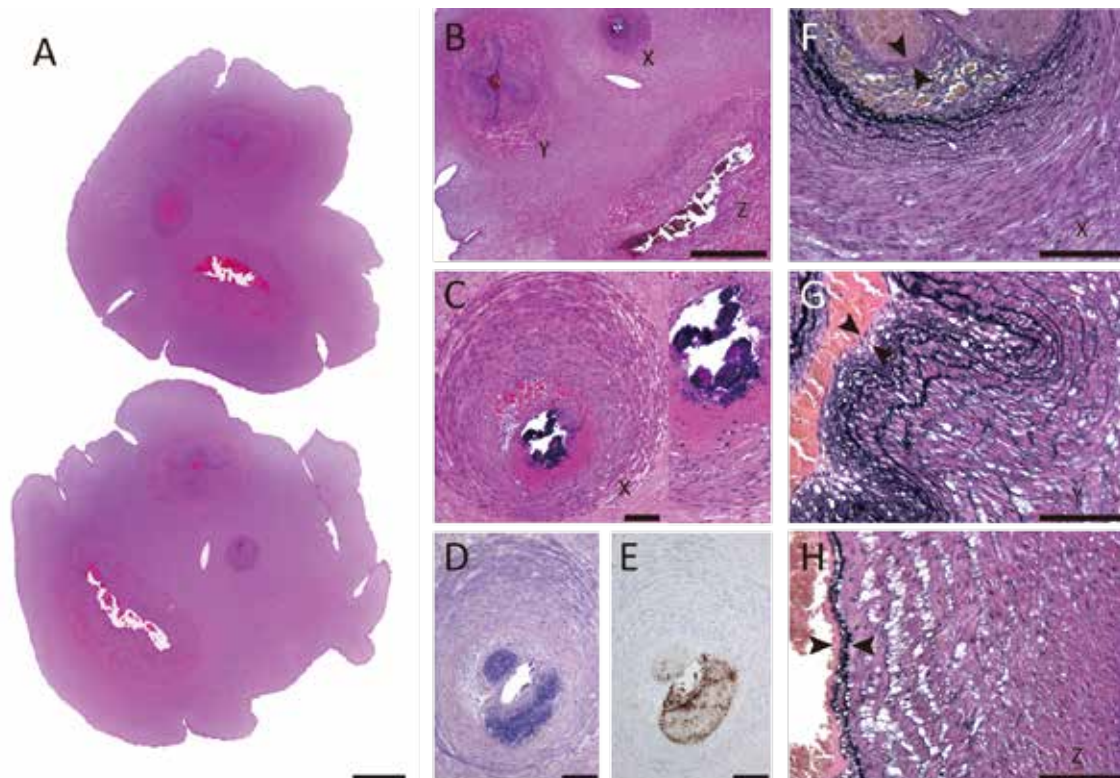


Figure 3 Microscopic findings of the umbilical cord

A-C, Microscopic findings of the middle portion of the umbilical cord with hematoxylin-and-eosin-stained sections. Three vessels are seen; the smallest artery indicated by X has occlusive thrombus with focal calcification (**Fig. 3C**), the largest vessel indicated by Z is an umbilical vein, and the other one vessel indicated by Y is an umbilical artery. **D**, A section stained by phosphotungstic acid-hematoxylin reveals fibrinous materials in the thrombus. **E**, A CD61 immunostain reveals aggregates of platelets in the thrombus. **F-H**, Sections stained with elastic-van Gieson. The thrombosed vessel (**Fig. 3F**) and the patent umbilical artery (**Fig. 3G**) have no internal elastic lamina in the possible site indicated by arrowheads, whereas the umbilical vein (**Fig. 3H**) has an internal elastic lamina indicated by arrowheads. Bars seen in **Figs. 3A-B** represent 1 mm, and bars seen in **Figs. 3C-H** represent 100 μ m.

the internal elastic lamina (**Figure 3F**). Thus, the two UAs showed discrepancy in the diameter; the larger UA had a minor axis of 1478 μm and the smaller UA had a minor axis of 712 μm . In the placenta, funisitis, chorioamnionitis, chronic villitis of unknown origin, acute atherosclerosis, and avascular villi were not observed, but a small infarction of 1 cm in size was seen in the marginal zone of the placenta. In the cord and placenta, CMV infection was not confirmed because of the lack of cytomegalic inclusion bodies and immunoreactivity for monoclonal anti-CMV antibody. Lymphoplasmacytic villitis, which is a histological hallmark of CMV infection, was absent. In summary, the hypercoiled umbilical cord with UAT was found, and HUA/DUAs was suggested.

Discussion

We present a case of a 37-year-old woman giving birth to a healthy neonate with a hypercoiled umbilical cord with UAT. The smaller UA was completely occlusive with thrombus. Thrombosis of umbilical cord vessels is rare (2.5-4.5/10,000)⁴ and is considered as a marker of poor fetal outcome.¹⁰ Umbilical venous thrombosis occurs more frequently than thrombosis of one or both UAs; umbilical venous thrombosis alone accounts for 70%, venous and arterial thrombosis at 20%, and arterial thrombosis alone at 10%.¹⁰ The incidence rate of UAT is 0.0275% (11/40,000)³ to 0.0825% (7/8480)⁵, and Avagliano et al.¹¹ described the incidence rate of UAT is 0.6309% (2/317) in cases of stillbirth. The literature review of UAT is summarized in **Table 1**. The causes of UAT includes umbilical artery catheter,¹² antiphospholipid syndrome,¹³ and umbilical cord abnormalities³⁻⁷. Among the causes, umbilical cord abnormalities, such as long cord (70cm or over), hypercoiled umbilical cord, and velamentous insertion appear to be the most related to the occurrence of UAT. The cord abnormalities appear to be related to reduced blood flow (stasis) in the umbilical arteries. Stasis, which includes the Virchow triad of conditions predisposing to thrombosis, is likely the main cause of UAT.

Other conditions of the Virchow triad, such as hypercoagulability status and endothelial dysfunction, are known, and the former may be rather minor in the cause of UAT because only several cases with high titer of anti-cardiolipin³ or anti-phospholipid antibodies¹³ were found. In the present case, thrombotic placental lesions, which can occur in antiphospholipid syndrome, were not observed, and endothelial dysfunction might be related to the UAT. In our case, maternal CMV infection during pregnancy might be possible. CMV infection can infect endothelial cells and damage endothelial function.¹⁴ Although cases with UAT and CMV infection were not found in the PubMed database, Lanari et al.¹⁵ described that aortic arch thrombosis was seen in the fetus as a result of congenital CMV infection. Thus, fetal CMV infection can be related to the formation of UAT. In our case, fetal CMV infection was suspected, but it was potentially unlikely because it was not found in the neonate, umbilical cord, and placenta. Kenneson et al.¹⁶ reported that vertical transmission of CMV is not seen in 68% of neonates born from mothers with primary infection during pregnancy.

It was unclear whether the mother of the present case showed primary infection, reactivation, or reinfection of CMV during pregnancy. False-positive results for anti-CMV antibodies may be attributed to some laboratory methods used.¹⁷ A positive result for anti-CMV IgM antibodies is assumed to be a marker of acute or recent CMV infection; however, elevated anti-CMV IgM antibodies does not necessarily mean acute or recent CMV infection, because anti-CMV IgM antibodies can persist for months after natural infection and have been detected in some pregnant women 6 to 9 months after the end of the acute phase of the primary CMV infection.¹⁸ We could not confirm the maternal seroconversion of anti-CMV specific antibodies. CMV-IgG avidity test is useful for evaluating primary CMV infection,¹⁹ but the test was not performed in the present case because no abnormality of the fetus was clinically found.

In Japan, congenital CMV infection was

estimated to be 0.39% and speculated to be increasing because the prevalence of serum anti-CMV antibodies was decreasing.²⁰ Maternal primary CMV infection during pregnancy is associated with a much higher rate of vertical transmission than recurrent infection.¹⁶ However, in the United States, the number of neonates with congenital CMV infection, born from mothers with CMV reactivation or reinfection during pregnancy, was approximately three times higher than those born from mothers with primary CMV infection during pregnancy.²¹ Thus, interventions, such as behavioral changes to avoid CMV exposure, will be beneficial for CMV-seronegative and CMV-seropositive pregnant women. Clinicians should keep in mind that congenital CMV infection can rarely occur in an immunocompetent pregnant woman with persistent anti-CMV IgM antibodies prior to conception.²²

Several researchers³⁻⁷ reported that UAT can influence fetal growth and can be related to the high incidence rate of IUGR and stillbirth, probably because UAT may be associated with placental hypoperfusion due to marked fetal thrombotic vasculopathy including avascular villi or thrombosis in placental surface vessels. Particularly, cases of UAT associated with sudden onset of fetal growth retardation resulted in cesarean section within 1 or 2 months from the diagnosis of UAT or the date of onset of fetal growth retardation.^{4, 6, 7} However, our case showed no findings of apparent IUGR, occlusive chorionic vessels, and avascular villi. Thus, the UAT of the present case did not reduce placental blood perfusion significantly. Nevertheless, the hypercoiled cord causing fetal blood flow disturbance and growth retardation²³ was complicated in our case. In the previously published cases with UAT, this is the first case that the fetus resulted in full-term birth and did not have any complication, such as IUGR or anomalies. The UAT itself may not indicate poor outcome of the neonate; however, careful medical follow-up should be recommended because a large number of UAT cases tend to have poor fetal outcome.

In our case, the occlusive UA diameter was approximately 50% or less compared with that of the patent UA. Hence, the occlusive UA suggested HUA. Focusing on the difference between the UAs with regard to size, the occlusive UA and patent UA in our case might be called DUAs. However, standardized definition of HUA and DUAs seems to be not reported yet. Petrikovsky et al.⁹ reported 12 cases with HUA that was sonographically defined by an artery-to-artery diameter difference of more than 50%. Dolkart et al.⁸ reported that six cases of DUAs showed a 2-mm difference in size between the arteries by ultrasonography, and Raio et al.²⁴ described that DUAs were considered to be present when sonographic evaluation confirmed that the difference between the diameter of the two arteries was at least 1 mm in all three portions of the umbilical cord in both the transverse and longitudinal sections. In our case, we could not confirm the small UA with ultrasonography; hence, we could not evaluate HUA and DUAs thoroughly; however, it was estimated by pathological evaluation that the thrombosed UA could be called HUA in accordance with the definition of Petrikovsky et al.⁹ HUA may be associated with maternal diabetes,²⁴ but diabetes mellitus was absent in this case. In the present case, the smaller artery showed thrombosis with calcification, which might occur in the early stage of gestation. Before 24 weeks of gestation, SUA was suspected at 22 and 2/7 weeks of gestation; however, further previous data was not obtained. HUA or DUAs have not been reported to tend to be thrombosed, and the two UAs in our case might be similar size in nature. UAs lack vasa vasorum¹ and appear to receive oxygen and nutrition directly via intraluminal blood and the surrounding amniotic fluid. Thus, the occlusive artery grew poorly without the supplies from the intraluminal blood, and might result in the formation of HUA. Two cases similar to our case were observed in the previously published literatures on UAT,^{3, 5} but the relationship between UAT and HUA/DUAs was not discussed.^{3, 5} HUA and DUAs may be associated with poor perinatal outcomes and/or

congenital abnormalities,^{8,9} but opposite data were present.²⁴

Conclusion

We report a case of a pregnant woman with clinical diagnosis of SUA and elevated anti-CMV IgG and IgM antibodies. She gave birth to a healthy female neonate, and a thin and hypercoiled umbilical cord with UAT was found. The occlusive artery was hypoplastic suggesting HUA/DUAs. Although UAT, HUA/DUAs, and hypercoiled umbilical cord can be related to poor fetal outcomes, the neonate of our case showed neither IUGR nor malformation. To the best of our knowledge, this is the first case wherein a healthy, appropriate-for-age, full-term neonate was born with UAT. CMV infection was not found in the neonate. Further accumulation of the cases will be needed to elucidate the clinicopathological significance and pathogenesis of UAT, HUA/DUAs, and hypercoiled umbilical cord.

Acknowledgement

The authors would like to thank Dr. Jun Iwata, Department of Diagnostic Pathology, Kochi Health Sciences Center, for valuable suggestion against the pathological diagnosis of the umbilical cord.

References

- 1 Fox H, Sebire NJ. Pathology of the Placenta 3rd ed. Saunders Elsevier, China, P473-509, 2007.
- 2 Abuhamad AZ, et al. Single umbilical artery: does it matter which artery is missing? *Am J Obstet Gynecol* 173: 728-732, 1995.
- 3 Sato Y, Benirschke K. Umbilical arterial thrombosis with vascular wall necrosis: clinicopathologic findings of 11 cases. *Placenta*. 2006; 27: 715-8.
- 4 Klaritsch P, et al. Spontaneous intrauterine umbilical artery thrombosis leading to severe fetal growth restriction. *Placenta* 29: 374-377, 2008.
- 5 Shilling C, et al. Umbilical artery thrombosis is a rare but clinically important finding: a series of 7 cases with clinical outcomes. *Pediatric Dev Pathol* 17: 89-93, 2014.
- 6 Oliveira GH, et al. Intrauterine thrombosis of umbilical artery - case report. *Sao Paulo Med J* 134: 355-358, 2016.
- 7 Tanaka K, et al. Prenatal diagnosis of umbilical artery thrombosis. *Fetal Diagn Ther* 35: 148-150, 2014.
- 8 Dolkart LA, et al. Discordant umbilical arteries: ultrasonographic and Doppler analysis. *Obstet Gynecol* 79: 59-63, 1992.
- 9 Petrikovsky B, Schneider E. Prenatal diagnosis and clinical significance of hypoplastic umbilical artery. *Prenat Diagn* 16: 938-940, 1996.
- 10 Heifetz SA. Thrombosis of the umbilical cord: analysis of 52 cases and literature review. *Pediatr Pathol* 8: 37-54, 1988.
- 11 Avagliano L, et al. Thrombosis of the umbilical vessels revisited. An observational study of 317 consecutive autopsies at a single institution. *Hum Pathol* 41: 971-979, 2010.
- 12 Seibert JJ, et al. Sonographic detection of neonatal umbilical-artery thrombosis: clinical correlation. *AJR Am J Roentgenol* 148: 965-968, 1987.
- 13 Le Thi Huong D, et al. The second trimester Doppler ultrasound examination is the best predictor of late pregnancy outcome in systemic lupus erythematosus and/or the antiphospholipid syndrome. *Rheumatology* 45: 332-338, 2006.
- 14 Kahl M, et al. Efficient lytic infection of human arterial endothelial cells by human cytomegalovirus strains. *J Virol* 74: 7628-7635, 2000.
- 15 Lanari M, et al. Neonatal aortic arch thrombosis as a result of congenital cytomegalovirus infection. *Pediatrics* 108: E114, 2001.
- 16 Kenneson A, Cannon MJ. Review and meta-analysis of the epidemiology of congenital cytomegalovirus (CMV) infection. *Rev Med Virol* 17: 253-276, 2007.
- 17 Lazzarotto T, et al. Search for cytomegalovirus-specific immunoglobulin M: comparison between a new western blot, conventional western blot, and nine commercially available assays. *Clin Diagn Lab Immunol* 4: 483-486, 1997.
- 18 Lazzarotto T, et al. Update on the prevention, diagnosis and management of cytomegalovirus infection during pregnancy. *Clin Microbiol Infect* 17: 1285-1293, 2011.
- 19 Ebina Y, et al. The IgG avidity value for the prediction of congenital cytomegalovirus infection in a prospective cohort study. *J Perinat Med* 42: 755-759, 2014.
- 20 Numazaki K, Fujikawa T. Prevalence of serum antibodies to cytomegalovirus in pregnant women in Sapporo, Japan. *Int J Infect Dis* 6: 147-148, 2002.
- 21 Wang C, Zhang X, Bialek S, Cannon MJ. Attribution of congenital cytomegalovirus infection to primary versus non-primary maternal infection. *Clin Infect Dis* 52: e11-13, 2011.
- 22 Nakajima Y, et al. Congenital cytomegalovirus

infection after maternal persistent immunoglobulin-M antibodies against cytomegalovirus prior to conception. Case Reports in Perinatal Medicine Vol. 2. 65, 2013.

23 Nishio J, et al. Characteristics of blood flow in intrauterine growth-restricted fetuses with

hypercoiled cord. Ultrasound Obstet Gynecol 13: 171-175, 1999.

24 Raio L, et al. The clinical significance of antenatal detection of discordant umbilical arteries. Obstet Gynecol 91: 86-91, 1998.

Table 1 Reviewed cases of umbilical artery thrombosis

First author (published year)	Mother (years)	GA at diagnosis of UAT/SUA (week)	GA of delivery (week)	Mode of delivery	Fetus/neonate	Apgar score	Cord (Length/insertion/other findings)	Placenta (weight and findings)
Sato (2006)*	44	NA	33	NA	IUGR/1235g	NA	40 cm/V	270 g, mural thrombi, infarction
	35	NA	37	NA	IUFD	NA	62cm/V	NA, mural thrombi, infarction
	17	NA	39	NA	IUGR/NA	8/9	53 cm/C	350 g, mural thrombi, infarction
	28	NA	34	NA	IUGR/NA	8/9	80 cm/C	320 g, mural thrombus
	33	NA	35	NA	Fetal distress/NA	6/9	22 cm/NA/HC	430 g, mural thrombi
	29	NA	35	NA	Proteinemia	NA	40 cm/M	400 g, infarction
	NA	NA	40	NA	NA	NA	76 cm/C	650 g, mural thrombi, CAM
	39	NA	39	NA	IUFD	NA	75 cm/C	NA, occlusion of stem vessels
	NA	NA	40	NA	NA	8/8	20 cm/C/HC	520 g
Klaritsch (2009)	28	32	34	C/S	IUGR/1,590 g	9/10	70 cm/C/HC	385 g, occlusion of stem villi arteries
Schilling (2014)	30	NA	38	NA	Caudate infarction/4,065 g	NA	39 cm/E	415 g, scattered AV
	26	NA	29	NA	IUGR/750 g	NA	38 cm/M	211 g
	27	NA	34	NA	IUGR/1990 g	NA	56 cm/M	281 g, scattered AV
	40	NA	38	NA	IUGR/1800 g	NA	76 cm/C	273 g, FTV
	35	NA	28	NA	Stillbirth, 1440 g	NA	15 cm/C	455 g, FTV
	25	NA	40	NA	Stillbirth, 2200 g	NA	97 cm/NA	345 g, FTV
	30	NA	39	NA	Schizencephaly, acrania/2630 g	NA	29 cm/E	246 g, FTV
Tanaka (2014)	30	35+5/7	36+2/7	C/S	FGR/a health neonate, 2142 g	NA	82 cm/NA/HC	NA
	37	NA (28?)	37+4/7	C/S	FGR/a health neonate, 1810 g	NA	Not elongated / NA/HC	NA
Oliveira (2016)	30	32	34	C/S	IUGR/1080 g	9/10	80 cm/E/HC	NA
Present case	37	24	40	C/S	NP/a healthy neonate, 2732 g	8/9	58 cm/E/HC	420 g, infarction

Abbreviations: GA, gestational age; UAT, umbilical artery thrombosis; SUA, single umbilical artery; Apgar score, estimated at 1 and 5 minutes; NA, not available; C/S, cesarean section; IUGR, intrauterine growth retardation; IUFD, intrauterine fetal death; FGR, fetal growth retardation; NP, nothing in particular; V, velamentous; M, marginal; E, eccentric; C, central; HC, hypercoiled; CAM, chorioamnionitis; AV, avascular villi; FTV, fetal thrombotic vasculopathy. * Two cases were excluded because clinicopathological data was hardly seen.