

## Alveolar Soft-part Sarcoma of the Retro Peritoneum: A Case Report and Review of the Literature

View metadata, citation and similar papers at [core.ac.uk](http://core.ac.uk)

brought to you by CORE

provided by Academic Journal of Surgery (AJS - Tehran University of Medical Sciences)

School of Medicine, Surgical Oncology Research Center, Imam Reza Hospital, Mashhad University of Medical Sciences,

Mashhad, Iran

Received: 16 Nov. 2015; Received in revised form: 26 May 2016; Accepted: 19 Jul. 2016

### Abstract

**Background:** Alveolar soft part sarcoma (ASPS) is a rare malignant neoplasm originating from soft tissue. It was initially described as a distinctive clinical entity by Christopherson et al. in 1952. The peak age of incidence is between 15 and 35 years with slight sex predominance among women. The most common sites involved include extremities and trunk and in young adults and head and neck in children. ASPS is a slow-growing tumor with unusual patterns of metastasis which runs a poor prognosis. The aim of this article was to present a case of ASPS of retroperitoneal origin along with its diagnostic and therapeutic workups.

**Case Report:** A 31-year-old patients with a chief complain of an abdominal mass in right lower quadrant, underwent surgical resection as a neuroendocrine tumor according to pre-operative imaging studies. Pathology reported the lesion as ASPS. The patient refused adjuvant chemotherapy and unfortunately he did not show up to continue his treatment and further follow-ups. A careful investigation would be required including clinical findings, clinicopathological correlation, with appropriate radiological studies, before definitive treatment of ASPS.

**Conclusions:** The main problem to gain an extended insight into clinical features and optimal treatment is the rarity of the disease. Given the ineffectiveness of current treatments in advanced ASPS, further future investigation to find new therapeutic options would be required.

© 2016 Tehran University of Medical Sciences. All rights reserved.

**Citation:** Moti M, Aliakbarian M, Rezapanah A. **Alveolar Soft-part Sarcoma of the Retro Peritoneum: A Case Report and Review of the Literature.** *Acad J Surg*, 2016; 3(1-2): 33-6.

**Keywords:** Neoplasms; Peritoneum; Sarcoma; Alveolar soft part; Soft tissue neoplasms

### Introduction

Alveolar soft part sarcoma (ASPS) is a rare malignant soft tissue neoplasm which accounts for < 1% of soft tissue sarcomas. It was initially described as a distinctive clinical entity by Zadnik et al. in 2014 (1). This highly vascular tumor has a distinct morphology that clinically mimics hemangioma or arteriovenous malformation (2,3). The tumor received its name from its pseudo-alveolar appearance created by polygonal cells lacking central adhesion and abundant sinusoidal vessels. The term soft part is used to distinguish these sarcomas from bone sarcomas (4,5).

It mainly affects adolescents and younger adults aged between 15 and 35 years, but the tumor can also occur in children as young as 2-year-old. There is a slight female predilection (6,7).

ASPS has been reported in a wide variety of locations and it can present in soft tissues anywhere in the body. In young adults, most of the cases presents in the lower extremities, followed by the trunk and the upper limbs. Head and neck, especially the tongue and orbit, are more commonly found in pediatric ASPS

(6,8). Certain other organs can be very unusually targeted by ASPS malignant cells including the female genital tract, mediastinum, breast, urinary bladder, gastrointestinal tract, retroperitoneum, and bones (8).

The natural history of ASPS is a slow-growing painless tumor which runs an indolent course with a poor prognosis (7). ASPS is also characterized by unusual patterns of metastasis. Widespread metastasis may already be present at the time of diagnosis, leading to high mortality. Pulmonary metastases are encountered in 42-65% of patients. The brain and the skeleton are the two next most commonly involved metastatic sites (6).

Here, we present a case of ASPS originated in the retroperitoneal space, along with radiological and pathological findings.

### Case Report

A 31-year-old man was admitted to Imam Reza Hospital with a history of abdominal mass, nausea, and vomiting. He denied any weight loss or urinary discomfort. His medical and surgical histories were negative. Family history was negative too. Physical

**Corresponding Author:** Alireza Rezapanah

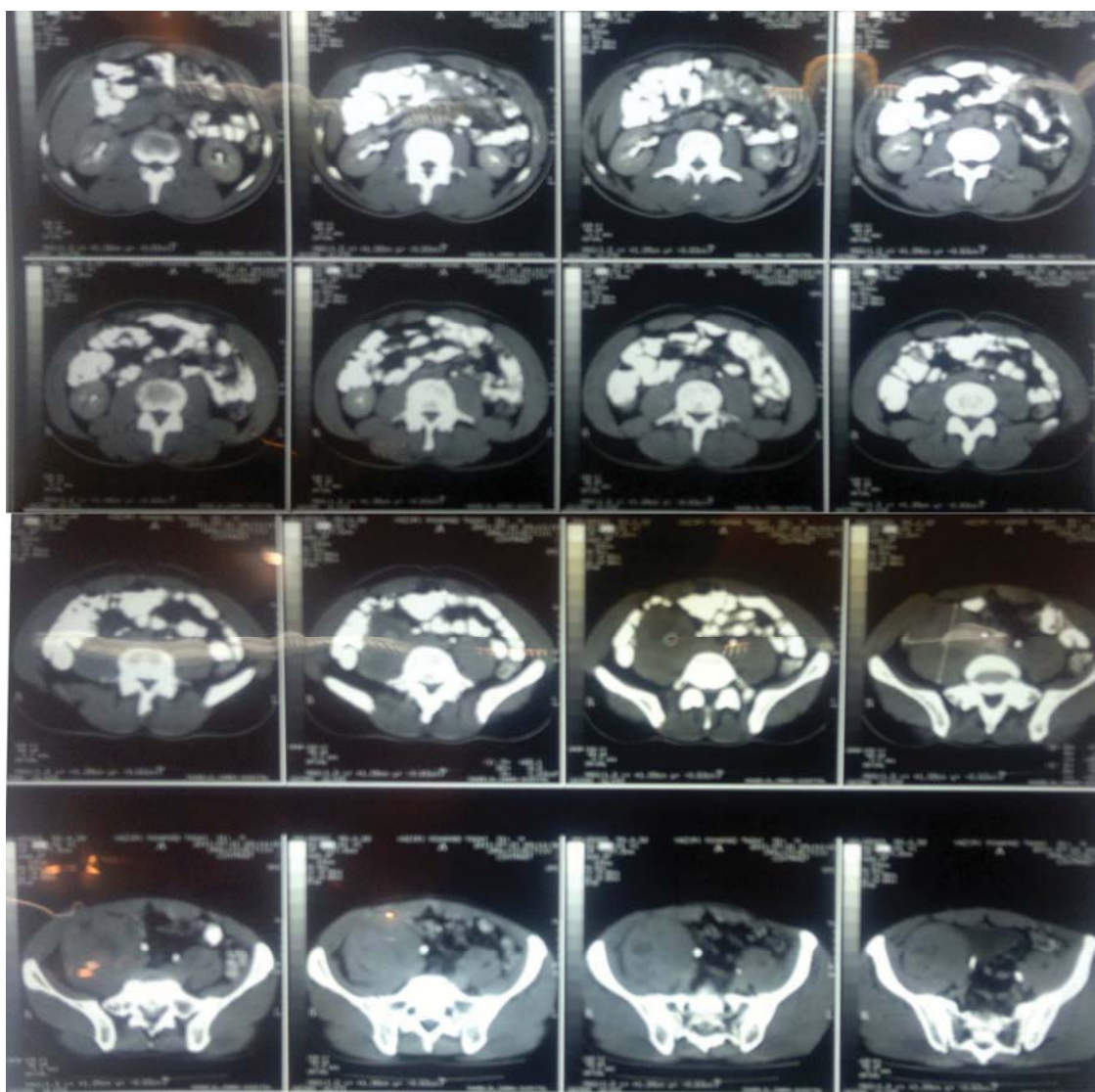
Department of General Surgery, Surgical Oncology Research Center, Imam Reza University Hospital, Ibn Sina Street, Mashhad, Iran. Tel: +98 511 8022677/Fax: +98 511 8525255, E-mail: rezapanahal@mums.ac.ir

## Alveolar Soft-part Sarcoma of the Retro Peritoneum

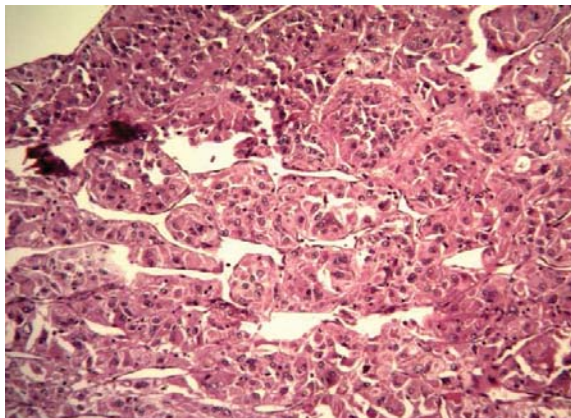
examination revealed an immobile mass with a smooth surface and about 10 cm × 5 cm in size, palpated in right lower quadrant (RLQ). His examinations were otherwise unremarkable. Laboratory findings were all within normal limits. Abdominal ultrasound revealed a mass measuring 8 cm × 5 cm × 7 cm in size at RLQ with hypervascularity. Both kidneys were normal in size and shape. Computed tomography (CT) scan studies demonstrated a hyper-dense mass with the necrotic center, 78 mm × 83 mm in diameter in the lower abdomen (Figure 1). Colonoscopy findings were normal. Ultrasound guided biopsy of the lesion was performed and revealed neuroendocrine tumor.

As a locally aggressive sarcoma, it was decided that complete resection would yield the best chance of patient recovery and survival; resection of the tumor

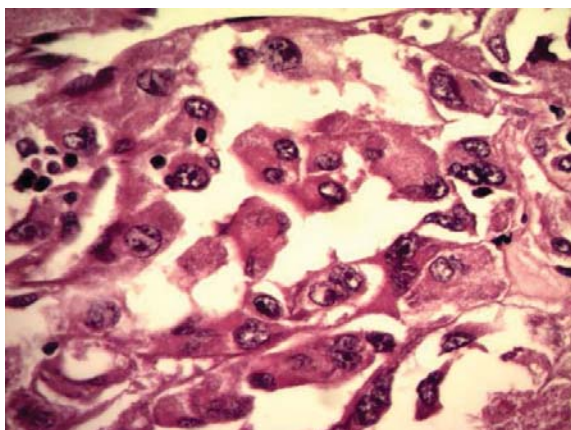
was performed via laparotomy; a well-defined mass in retroperitoneal space without adhesion to urethra or other organs was transected and sent to pathology for further analysis. Histopathology report was obtained as a poorly differentiated (high grade) adenocarcinoma consistent with high-grade renal cell carcinoma (RCC), which was incompatible with intraoperative and imaging data. There was no abnormality in both kidneys and no adhesion around the mass as it was observed during the operation. Therefore, we asked for a microscopic review and pathology then confirmed that the lesion was ASPS. All surgical margins also were free (Figures 2 and 3). The patient refused adjuvant chemotherapy and unfortunately he never showed up to continue his treatment and further follow-ups.



**Figure 1.** Coronal reformat images of abdominal and pelvic computed tomography scan show retroperitoneal primary mass that operated about 2 years ago quadrant with central necrosis



**Figure 2.** Organoid arrangement of tumor cells consist of sharply defined nests some with pseudoalveolar features separated by tiny sinusoidal vessels (H and E,  $\times 100$ )



**Figure 3.** Large polyhedral cells with sharp borders containing large round nuclei with prominent nucleoli and abundant granular and less vacuolar cytoplasm (H and E,  $\times 400$ )

## Discussion

ASPS has a characteristic histology with a nest-like organoid architecture separated by connective tissue septa that have a rich vascular network. Although these features are usually diagnostic of ASPS, on initial presentation, the ASPS may be difficult to distinguish from other tumors, especially when ASPS occurs in an unusual location, such as in the lung, stomach, retroperitoneum, and female genital tract. The following lesions should be considered in the differential diagnosis of ASPS, and they include paraganglioma, rhabdomyosarcoma, renal-cell carcinoma, metastatic adrenal carcinoma, clear-cell carcinoma, and melanoma. The ASPS needs to be differentiated from these tumors because the management strategy differs markedly for each tumor type. The discrimination of ASPS from these tumors is by demonstrating cytological uniformity, lack of nuclear atypia, and paucity of mitotic figures in ASPS

(3,6,7). In this article, we report a 31-year-old man with ASPS firstly diagnosed as RCC.

To accurate diagnosis and treatment of this unusual tumor careful investigation would be required, including clinical findings and clinicopathological correlation, with appropriate radiological studies. Histological workup includes the presence of characteristic periodic acid-Schiff and diastase-positive intracellular crystals, immunohistochemical staining for melanocytic markers, and immunoreactivity, e.g., antibodies, for S-100 protein (9). Recently, based on the fact that an unbalanced translocation, resulting in the ASPL-*TFE3* fusion gene, is characteristic of ASPS, antibodies against the internal region of the *TFE3* gene have been used to confirm the diagnosis of ASPS. Imaging workup including MRI, CT scan and vertebral X-ray may be mandatory in the diagnosis and further investigations of patients diagnosed with ASPS (10).

Alveolar soft-part sarcoma is a very rare in the retroperitoneal space. Portera et al. reported that only 6 (8%) of 70 ASPS patients treated from 1959 to 1998 at MD Anderson Cancer Center had ASPS of retroperitoneal space origin (11). According to a review done by Ishikawa et al., in 2006 (12), there were only four other cases of ASPS of retroperitoneal space origin in the literature.

Unlike most sarcomas, ASPSs are characterized by their prominent metastatic potential. Metastases to the lungs and brain appear to be the most common site of metastasis in previous studies (5,11). Metastasis as initial presentation is common in these patients; the patients without metastasis at presentation may develop metastatic disease within follow-up period (13).

The outcomes depend on factors such as a patient's age, tumor size, stage, location, and the presence of metastasis at the time of diagnosis. Larger tumors and brain metastases make a significant difference in prognosis (11). The median survival is significantly higher among patients with no metastases compared with others who develop recurrence or metastatic disease (5,11).

Early diagnosis, clinical staging are essential in the treatment of ASPS. In localized lesions with no metastases, surgical resection is the best option. The treatment options are limited when lesions are multiple, but for recurrence control, the first treatment option should be complete surgical resection as the single lesions. Although many studies showed no survival advantages from chemo or radiotherapy (10,11). Chemotherapy is commonly used in the treatment of unresectable advanced disease, with palliative intention. Adjuvant radiotherapy is also shown to be beneficial in this setting. Although it is impossible to draw conclusions definitely about the clinical value of adjuvant radiotherapy for ASPS treatment based on the rarity of the tumor (5). Therefore, it is apparent

alternative new therapeutic strategies, such as anti-angiogenic agents given the rich vascular histopathology of the tumor, are mandatory for management and improve survival of patients with advanced ASPS (4,9). The standard treatment for and metastatic lesions in the brain and lung is surgical excision aiming at obtaining tumor-free margins and improve outcome (9).

### Conclusion

Alveolar soft-part sarcoma is very rare in the retroperitoneal space. Due to its rarity, the diagnosis and treatment have been proven to be a challenge for the pathologist and the surgeon as well. The careful investigation would be required, including clinical findings, clinicopathological correlation, with appropriate radiological studies, before definitive treatment. Complete surgical excision with clear margins is the treatment of choice.

### Conflict of Interests

Authors have no conflict of interests.

### Acknowledgments

The authors want to thank Mehrabi Bahar M.D. the Head of Oncology Research Center at Mashhad University of Medical Sciences.

### References

1. Zadnik PL, Yurter A, DeLeon R, Molina CA, Groves ML, McCarthy E, et al. Alveolar soft-part sarcoma in the sacrum: a case report and review of the literature. *Skeletal Radiol.* 2014; 43(1): 115-20.
2. Sarkar P, Mukherjee S, Saha ML, Biswas RS. Alveolar soft part sarcoma: a rare diagnosis. *Indian J Dermatol.* 2013; 58(3): 244.
3. Setsu N, Yoshida A, Takahashi F, Chuman H, Kushima R. Histological analysis suggests an invasion-independent metastatic mechanism in alveolar soft part sarcoma. *Hum Pathol.* 2014; 45(1): 137-42.
4. Daigeler A, Kuhnen C, Hauser J, Goertz O, Tilkorn D, Steinstraesser L, et al. Alveolar soft part sarcoma: clinicopathological findings in a series of 11 cases. *World J Surg Oncol.* 2008; 6: 71.
5. Falkenstern-Ge RF, Kimmich M, Wohlleber M, Grabner A, Friedel G, Ott G, et al. Lung metastasis of primary alveolar soft-part sarcoma occurring 20 years after initial treatment. *Case Rep Oncol Med.* 2013; 2013: 690520.
6. Silas OA, Adoga AA, Manasseh AN, Echejoh GO, Vhritherhire RA, Mandong BM. Persistent alveolar soft-part sarcoma with liver metastasis: a case report. *J Med Case Rep.* 2010; 4: 233.
7. Kim JM, Im SA, Oh SN, Chung NG. Alveolar soft part sarcoma arising from the kidney: imaging and clinical features. *Korean J Radiol.* 2014; 15(3): 381-5.
8. Yavuz A, Goya C, Bora A, Beyazal M. Primary alveolar soft part sarcoma of the scapula. *Case Rep Oncol.* 2013; 6(2): 356-61.
9. Kayton ML, Meyers P, Wexler LH, Gerald WL, LaQuaglia MP. Clinical presentation, treatment, and outcome of alveolar soft part sarcoma in children, adolescents, and young adults. *J Pediatr Surg.* 2006; 41(1): 187-93.
10. Portera CA Jr., Ho V, Patel SR, Hunt KK, Feig BW, Respondek PM, et al. Alveolar soft part sarcoma: clinical course and patterns of metastasis in 70 patients treated at a single institution. *Cancer.* 2001; 91(3): 585-91.
11. Ishikawa M, Ishizuka O, Nakayama T, Kobayashi S, Igawa Y, Nishizawa O, et al. Alveolar soft-part sarcoma of the retroperitoneum. *Int J Urol.* 2006; 13(10): 1355-7.
12. Lorigan JG, O'Keeffe FN, Evans HL, Wallace S. The radiologic manifestations of alveolar soft-part sarcoma. *AJR Am J Roentgenol.* 1989; 153(2): 335-9.
13. Ogura K, Beppu Y, Chuman H, Yoshida A, Yamamoto N, Sumi M, et al. Alveolar soft part sarcoma: a single-center 26-patient case series and review of the literature. *Sarcoma.* 2012; 2012: 907179.