

## Asymptomatic Giant Left Atrium: Do Atrial Size Changes After Successful Valve Replacement? 7-Years Follow-up Case Report

Shirvan Salaminia<sup>1</sup>, Ahmad Ali Amirghofran<sup>2</sup>, Babak Sabet<sup>3</sup>

<sup>1</sup> Department of Cardiac Surgery, Imam Sajjad Hospital, Yasuj University of Medical Sciences, Yasuj, Iran

<sup>2</sup> Department of Cardiac Surgery, School of Medicine, Shiraz University of Medical Sciences, Shiraz, Iran

<sup>3</sup> Assistant Professor, Department of General Surgery, School of Medicine, Shahid Beheshti University of Medical Sciences, Tehran, Iran

Received: 1 Dec. 2015; Received in revised form: 17 Mar 2016; Accepted: 5 Jun. 2016

### Abstract

**Background:** Giant left atrium (GLA) associated with mitral valve surgery reported to have a mortality ranging from 8% to 32%. Most of the patients are symptomatic with that of shortness of breath, dysphagia, palpitations, chest pain, and thromboembolic events. Asymptomatic giant enlargement of the left atrium is rare. Either we must do or not do a reduction arterioplasty at the time of the mitral valve surgery is a controversy in the literature.

**Case Report:** The patient had mitral valve replacement with a with a 31 mm carbomedics mechanical valve prosthesis 7 years past during her last visit. No reduction arterioplasty was done with a valve operation. Her 7-years close follow-up was uneventful. In the last visit, echocardiography and spiral chest computerized tomography scanning were requested. In both of the requested images giant left atrial enlargement was seen, but the patient was without symptoms regarding her giant left atrium.

**Conclusions:** In this case report, it seems that if we want left atrial size decline, it is necessary to have reduction arterioplasty during mitral valve surgery. However, it does not mean a definite therapeutic efficacy, especially when considering future symptoms.

© 2016 Tehran University of Medical Sciences. All rights reserved.

**Citation:** Salaminia S, Amirghofran AA, Sabet B. **Asymptomatic Giant Left Atrium: Do Atrial Size Changes After Successful Valve Replacement? 7-Years Follow-up Case Report.** *Acad J Surg*, 2016; 3(1-2): 30-2.

**Keywords:** Giant left atrium; Atrioplasty; Mitral valve disease

### Introduction

Giant left atrium (GLA) defined as the left atrial diameter exceeds 65 mm. There are no established diagnostic criteria for GLA; however, Kawazoe et al. defined it as the following two echocardiographic (ECHO) criteria: (a) large left atrium depicted by M-mode ECHO with diameter > 65 mm and (b) left ventricular posterobasal wall bent inward and lying between the dilated left atrial cavity and left ventricular cavity (1).

Most of the time GLA is due to mitral valve regurgitation secondary to excess intracavitary pressure with resultant strain and dilation of the left atrial chamber. Discrete GLA has unknown mechanism but it is possibly related to inherent atrial wall weakening. Most of the patients are symptomatic with that of shortness of breath, dysphagia, palpitations, chest pain, and thromboembolic events (2).

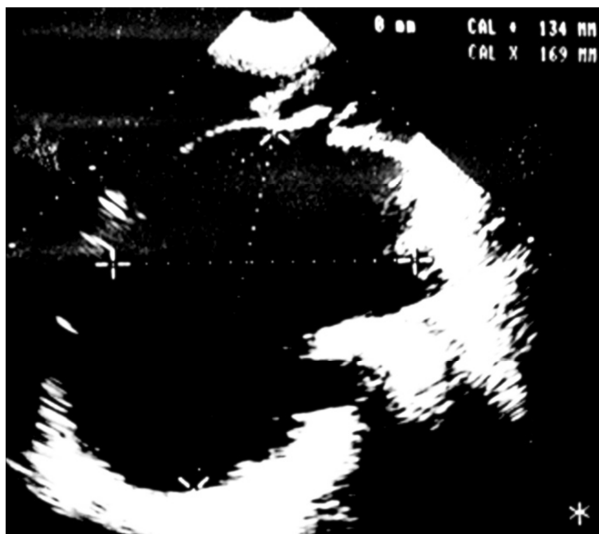Asymptomatic giant enlargement of the left atrium is rare. We decide to present patient with asymptomatic GLA and its 7-years follow-up with emphasis on the left atrial size changes after a successful mitral valve replacement (MVR).

### Case Report

A 70-year-old woman had open mitral commissurotomy 20 years before (1991), MVR with a 31 mm carbomedics mechanical valve prosthesis (Sorin Group, Arvada, CO, USA), and also tricuspid valve ring annuloplasty following rheumatic heart disease with predominant mitral regurgitation in 2004.

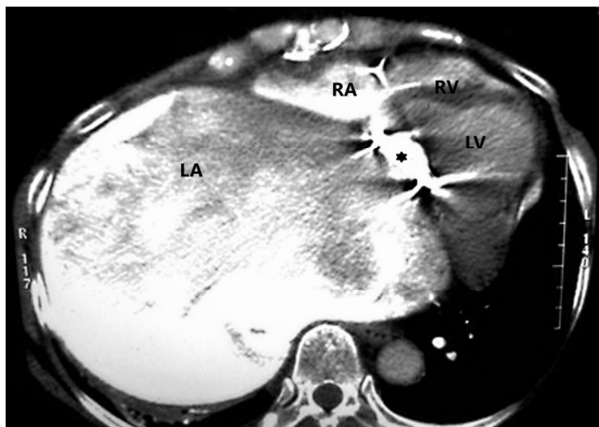
At the time of the operation, she had giant atriomegaly (16 × 11 cm) (Figure 1) and also significant left anterior descending artery (LAD) stenosis but due to very poor condition and unstable state, and also severe adhesion of pericardium and mediastinal organs, any other procedure including bypass graft and atrial size reduction was not done to decrease operation time and mortality. Her LAD stenosis was stented later by cardiologist. She was compliant with her medications, maintained therapeutic anticoagulation, and was completely asymptomatic. Physical examination revealed no jugular venous distension, a regular rhythm with 1/6 systolic murmur at the apex radiating to the axilla, a metallic S1, and no peripheral edema. She was referred to our institution based on a routine outpatient follow-up.

**Corresponding Author:** Babak Sabet  
Modaress Hospital, Sadat abad, Tehran, Iran.  
Tel: +98 913 1009078/Fax: +98 21 22360635, E-mail: [sabet@crc.mui.ac.ir](mailto:sabet@crc.mui.ac.ir)



**Figure 1.** Transthoracic echocardiography at the time of mitral valve replacement

Chest X-ray shows a markedly enlarged cardiac silhouette. A transthoracic ECHO demonstrated a severely enlarged left atrium without any thrombus. Computed axial tomography revealed a left atrium measuring  $20 \times 15$  cm (Figure 2) in maximum diameters. Transesophageal ECHO showed the severely enlarged left atrium and a normal functioning valve with no stenosis or regurgitation. This patient now is under follow-up without any disability.



**Figure 2.** Spiral chest computerized tomography scan of the same patient 7 years later. Arrow showed the prosthetic valve. RV: Right ventricle, LV: Left ventricle, RA: Right atrium, LA: Left atrium and asterisk is mitral prosthetic valve

## Discussion

In the review of the literature, the most cases of the GLA are treated at the time of mitral valve surgery. The main indications for its surgical interventions are the presence of compressive symptoms from

neighboring organs (3) and/or the presence of thrombus or a history of thromboembolic events. Some authors recommend for size reduction of GLA even when asymptomatic (4). Moreover, this is based mainly on the results obtained following the maze procedure.

It is a belief that successful mitral valve surgery alone will result in the reduction of left atrial size parallel to the volume and mean atrial pressure decline. However, this may be not true for some reasons: one of these reasons is that the left atrial wall changes observed in the patients with GLA are quite considerable and sometimes irreversible. In one study comparison (5) of GLA patients to another group of patients without GLA, postoperatively after the maze procedure showed decline in the size of the left atrium early post-operative, but no further decline was observed for the next 2 years on follow-up, which suggest a temporary change. Another study by Hagihara et al. (6) showed sustained early- and long-term surgical results considering the changes in the left atrial dimension among 30 GLA patients. Their study showed that the diameter of LA decreased significantly from  $69.0 \pm 8.5$  to  $53.7 \pm 9.1$  mm shortly after surgery, and was persistent at 5 years of follow-up. In one study by Darwazah and El Sayed (7), whilst agreement with this statement that the size of the left atrium will not change significantly after MVR, but they believe improving in hemodynamics after MVR regardless of the accompanied surgical plication arterioplasty.

Pande et al. (8) reported that in 116 patients who underwent isolated MVR with two different sizes of the left atrium; the reduction in the left atrial size was significant in both groups of different sizes left atrium. However, decline in size was more prominent in a group with left atrial size  $> 60$  mm.

These controversial results showed that the size reduction may be not clinically significant and may not be a relief for the symptoms caused by GLA. Furthermore, it is important to emphasize that the left atrial size may be not reduce in size without direct surgical arterioplasty.

GLA may progress within time after successful MVR without reduction atrioplasty. In spite of this fact reduction atrioplasty may be not possible in all conditions for example in our case. The benefits of the various surgical options should be considered in the management of the GLA.

## Conflict of Interests

Authors have no conflict of interests.

## Acknowledgments

The authors would like to thank the cardiac surgery ward of the Shahid Faghihi hospital at the Shiraz University of the Medical Sciences.

## References

1. Kawazoe K, Beppu S, Takahara Y, Nakajima N, Tanaka K, Ichihashi K, et al. Surgical treatment of giant left atrium combined with mitral valvular disease. Plication procedure for reduction of compression to the left ventricle, bronchus, and pulmonary parenchyma. *J Thorac Cardiovasc Surg.* 1983; 85(6): 885-92.
2. Apostolakis E, Shuhaiber JH. The surgical management of giant left atrium. *Eur J Cardiothorac Surg.* 2008; 33(2): 182-90.
3. Phua GC, Eng PC, Lim SL, Chua YL. Beyond Ortner's syndrome--unusual pulmonary complications of the giant left atrium. *Ann Acad Med Singapore.* 2005; 34(10): 642-5.
4. Scherer M, Therapidis P, Miskovic A, Moritz A. Left atrial size reduction improves the sinus rhythm conversion rate after radiofrequency ablation for continuous atrial fibrillation in patients undergoing concomitant cardiac surgery. *Thorac Cardiovasc Surg.* 2006; 54(1): 34-8.
5. Choo SJ, Park NH, Lee SK, Kim JW, Song JK, Song H, et al. Excellent results for atrial fibrillation surgery in the presence of giant left atrium and mitral valve disease. *Eur J Cardiothorac Surg.* 2004; 26(2): 336-41.
6. Hagihara H, Kitamura S, Kawachi K, Morita R, Taniguchi S, Fukutomi M, et al. Left atrial plication combined with mitral valve surgery in patients with a giant left atrium. *Surg Today.* 1995; 25(4): 338-42.
7. Darwazah AK, El Sayed H. Giant left atrium associated with massive thrombus formation. *Thromb J.* 2013; 11(1): 5.
8. Pande S, Agarwal SK, Mohanty S, Bansal A. Effect of mitral valve replacement on reduction of left atrial size. *Asian Cardiovasc Thorac Ann.* 2013; 21(3): 288-92.