

Media Medika Muda

Copyright©2016 by Medical Faculty of Diponegoro University

Volume 1, Nomor 3

ARTIKEL ASLI

September – Desember 2016



FACTORS AFFECTING POST-OPERATIVE PAIN AFTER DOPPLER GUIDED HEMORRHOID ARTERY LIGATION AND RECTO-ANAL REPAIR (DGHAL-RAR) OF INTERNAL HEMORRHOID

Sigit Adi Prasetyo, Ignatius Riwanto

FAKTOR-FAKTOR YANG MEMPENGARUHI NYERI PASCA OPERASI HEMOROID INTERNA
SETELAH DILAKUKAN HEMORRHOID ARTERI LIGATION AND RECTOANAL REPAIR (DGHAL-RAR)

ABSTRAK

Latar belakang: Dalam praktek klinis beberapa pasien DGHAL-RAR masih mengeluh nyeri dari sedang sampai berat. Penelitian ini bertujuan untuk mengetahui faktor-faktor yang mempengaruhi rasa sakit pasca operasi setelah DGHAL-RAR pada hemoroid interna.

Metode: Sebanyak 61 pasien hemoroid interna derajat II-IV menjalani DGHAL-RAR di RS St. Elizabeth, Semarang Indonesia, periode Agustus 2012 – Maret 2014 dianalisis secara prospektif. Usia, jenis kelamin, derajat hemoroid, menghilangnya trombus internal maupun eksternal, fisura anus, eksisi anal papilla hipertrofi, eksisi tag kulit, luka gores anal karena prosedur, dianalisis untuk mengetahui hubungannya dengan nyeri pasca operasi dalam 24 jam, 48 jam dan 7 hari pasca operasi. VAS untuk nyeri (0-10) digunakan untuk menilai tingkat rasa nyeri. Metode *Mann-Whitney* digunakan untuk analisis univariat, sementara *Kruskal-Wallis* dan metode *Median* digunakan untuk analisis multivariat.

Hasil: Setelah variabel dilakukan analisis multivariat, faktor-faktor yang signifikan terhadap nyeri pasca operasi di 24 jam yaitu menghilangkan trombosis internal, eksisi anal papilla hipertrofi dan laserasi anal, pada 48 jam menghilangkan trombosis eksternal, eksisi anal papilla hipertrofi dan laserasi anal dan pada hari ke 7 terdapat faktor-faktor yang sama dengan pengamatan setelah 24 jam pasca operasi.

Simpulan: Faktor yang mempengaruhi post operasi DGHAL-RAR untuk *hemoroid interna grade II-IV* adalah trombosis interna dan eksterna, eksisi anal papilla hipertrofi dan laserasi anal.

Kata kunci: hemoroid interna, DGHAL-RAR, trombosis, eksisi anal papilla hipertrofi, laserasi anal.

ABSTRACT

Background: In clinical practice some patients are complaint of moderate until severe pain. This study is intended to know factors affecting the post-operative pain after DGHAL-RAR of internal hemorrhoid.

Methods: A series of 61 grade II-IV internal hemorrhoid patients, underwent DGHAL-RAR in St Elizabeth Hospital, Semarang Indonesia, period of August 2012 - March 2014 were analyzed prospectively. Age, sex, grade, removing of thrombus either internal or external, anal fissure, removing of hypertrophic anal papilla, removing skin tag, anal laceration due to procedure, were analyzed to know it relation with post operative pain in 24 hours, 48 hours and 7 days post-operatively. VAS for pain (0-10) were used to assess the degree of pain. Mann-Whitney method was used for univariate analysis, while Kruskal-Wallis and Median method were used for multivariate analysis.

Results: After multivariate analysis variables that significantly influence post operative pain on 24 hours were removing of internal thrombosis, removing of anal papilla hypertrophy and anal laceration, on 48 hours were removing of external thrombosis, removing of anal papilla hypertrophy and anal laceration and on 7 days were the same with on 24 hours.

Conclusion: Factors that affecting post-operative pain after DGHAL-RAR for grade II-IV internal hemorrhoid were removing of both internal and external thrombosis, removing of anal papilla hypertrophy and anal laceration due to DGHAL-RAR procedure.

Key words: Internal hemorrhoid, DGHAL-RAR, thrombosis, anal papilla hypertrophy, anal laceration.

Staf Dept. of Surgery, Diponegoro Medical Faculty

INTRODUCTION

Hemorrhoids affect 4–5% of the population and traditionally the type of management is considered on the grade of prolapse and the severity of symptoms.¹ Surgery is the treatment of choice for grade III-IV, grade II who failed to respond to non-surgical treatments, and circumferential grade II haemorrhoids.² Surgical treatment of hemorrhoidal disease include classical hemorrhoidectomies (Milligan-Morgan, Fergusson), Longo-stapled hemorrhoidopexy, and doppler-guided hemorrhoidal artery ligation and Recto Anal Repair (DGHAL-RAR).³ DGHAL is firstly reported by Morinaga in 1995, due to high rate of prolapse recurrence, additional Recto Anal Repair (RAR) is added in 2005. DGHAL-RAR uses a specially designed proctoscope coupled with a Doppler transducer for identification and ligation of superior rectal arteries and its branches. Ligation of arteries will disrupts the inflow of blood to the hemorrhoidal venous plexuses and subsequently results in cessation of hemorrhoidal bleeding and shrinkage of hemorrhoidal tissue. Ligation of the arteries only is indicated for grade II hemorrhoids, while for grade III-IV the addition with mucopexy (recto-anal repair) is needed. The DGHAL proctoscope was designed to enable conventional arterial ligation as well as to facilitate simple insertion of the mucopexy sutures.¹⁻³ From several research reported that DGHAL RAR reducing post-operative pain significantly better compared to conventional hemorrhoidectomy and even compared to Stappler hemorrhoidopexy (SH).¹⁻⁴ However, in clinical practice some patients are complaint of moderate until severe pain. This study is intended to know factors affecting the post-operative pain after HAL-RAR of internal hemorrhoid.

METHODS

Between August 2012 and March 2014, 61 consecutive Grade II-IV hemorrhoid patients underwent DGHALRAR treatment at St Elizabeth hospital. Indications for surgery were symptomatic hemorrhoids (bleeding, prolapse). Patients were given an explanation of the details of procedures and were invited to participate to the study. Patients with a large external component were not

included. Furthermore, patients with under anticoagulation therapy, with coagulation disorders or refusing the DGHAL-RAR procedures were also excluded.

Surgery was performed electively by one surgeon (Ignatius Riwanto). All of the patients were investigated before surgery with rigid sigmoidoscopy or colonoscopy to exclude other causes of symptoms. A uniform protocol of pre- and intra-operative care was applied to all patients. All didn't received mechanical bowel preparation with antibiotic prophylaxis given. Following anesthetic assessment and discussion with the patient, spinal anesthesia was administered. Patients were placed in the lithotomy position, with iodine-based skin preparation. Identified any pathologist in anal canal including external thrombus (under anal canal skin), internal thrombus (covered by anal canal mucosa), anal fissure, skin-tag, hypertrophic anal papilla. We decided to remove thrombus, anal papil hypertrophy. After sufficient lubrication, Doppler Ultrasound Proctoscope (AMI-HAL proctoscope) was gently introduced into the anal canal. A conventional hemorrhoidal artery ligation was carried out in all terminal branches of the superior rectal artery that were identified circumferentially under Doppler guidance and transixed using a 2/0 polyglactin suture on a 5/8 curved tapered needle. Recto anal rectopexy (RAR) was then performed above the identified sites of hemorrhoidal prolapse. This involved a running suture, from proximal to distal. The proximal suture will be on the level of artery ligation and the lowest of bites being taken around 1cm proximal to the dentate line, to limit post-operative pain. Upon tying the two ends of the suture together, prolapsing tissue lifts back up into the anus.¹⁻³ After the procedure important to be checked the presence of bleeding and anal laceration.

Post-operative data were collected prospectively on all patients undergoing DGHALRAR. Age, sex, grade of hemorrhoid, the presence of anal fissure, removing of thrombus either internal or external, removing of hypertrophic anal papilla, removing skin tag, the presence of anal laceration due to procedure, number of HAL and number of RAR were analyzed to know it relations with post operative pain in 24 hours, 48 hours and 7 days post-operatively. Visual Analog Scale (VAS) were used to assess the degree

of pain. Post-operatively all patients got ketorolac 2x100 mg and diosmin-hesperidin 2x2 capsule, only patient with VAS score 4 or more got tramadol based on patient request. Patients were advised to eat high fiber food post-operatively to facilitate defecation. Patients went home on the post-operative day II, after 48 hours evaluation. Evaluation on day 7 were done on outpatients clinic. Only age and sex variables showed normal distribution, therefore the relationship between variables and VAS used Mann-Whitney for univariate analysis and Kruskal Wallis for multivariate analysis. Decided statistically significant if $p < 0.05$.

RESULTS

A series of 61 (33 female and 28 male) patients, mean of age 43.23 years of old, underwent DGHAL-RAR with indication grade II-IV internal hemorrhoid (grade II 4 patients, grade III 36 patients, grade IV 21 patients). Anal co-morbid were: external (5 patients) and internal thrombosis (5 patients); anal fissure (2 patients); hypertrophic anal papilla (6 patients); skin tag (3 patients) and anal laceration due to procedure (1 patients).

Figure 1. showed that pain significantly decrease by day ($p=0.000$). VAS 24 hours mean (range) 2.98 (1-6), VAS 48 hours 1.98 (0-5) and VAS 7 days 1.04 (0-3).

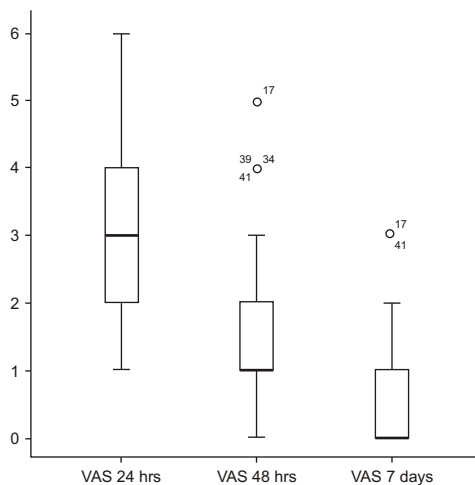


Figure 1. Distribution pain according to VAS for 24 hours, 48 hours and 7 days. (Friedman test $p=0.000$)

There were no post-operative bleeding, 3 cases showed non symptomatic small skin tag and 1 case (1.6%) on 7 days followed up showed mucosal prolapse due to breaking of the RAR suture but disappeared on 4 weeks followed up.

Mean of age of the patients was 43.23 years of old, for practical purposes cut-points 40 was used to evaluate its relationship with post-operative pain.

Table 1. The relationship between individual studied variable and VAS post-operatively

No. Variables	Category	Number	Mean		
			VAS 24 hrs	VAS 48 hrs	VAS 7 days
1 Sex	Female	33	3.03	1.61	0.58
	Male	28	2.86	1.68	0.54
2 Age	< 40	26	3.19	1.73	0.73
	≥ 40	35	2.77	1.57	0.43
3 Grade of hemorrhoid	Grade II	4	2.25	1.00	0.25
	Grade III	36	2.94	1.69	0.61
	Grade IV	21	3.10	1.67	0.52
4 External thrombosis	Yes	5	4.20*	2.60*	1.20
	No	56	2.84	1.55	0.50
5 Internal thrombosis	Yes	5	4.40*	2.60*	1.40*
	No	56	2.82	1.55	0.48
6 Anal Fissure	Yes	2	4.00	1.54	0.50
	No	59	2.92	1.64	0.56
7 Hypertrophic anal papilla	Yes	6	4.33*	3.00*	1.33
	No	55	2.80	1.49	0.47
8 Skin tag	Yes	3	4.33*	2.33	1.33
	No	58	2.88	1.60	0.52
9 Anal laceration	Yes	1	6.00*	4.00	3.00
	No	60	2.90	1.60	0.52
10 Number HAL	≥ 5	40	2.78	1.45	0.40
	≤ 6	21	3.29	2.00	0.86
11 Number RAR	≥ 3	24	2.58	1.29	0.33
	≤ 4	37	3.19	1.86	0.70

Mann-Whitney analysis : * $p < 0.05$

There were no significant difference on VAS 24 hours, 48 hours, and 7 days for age, sex, grade of hemorrhoid, anal fissure and number of HAL. Patients with removing external thrombosis and hypertrophic anal papilla showed significant difference on VAS 24 hours and 48 hours but not for VAS 7 days. Patients with anal laceration and skin tag showed significant difference only on VAS 24 hours. Patient with internal thrombosis showed significant difference on VAS 24 hours, 48 hours and 7 days. (Table 1).

Tabel 2. Variables that significantly affecting post-operative pain after multivariate Analysis (Kruskal-Wallis H Test)

	VAS 24 hrs	VAS 48 hrs	VAS 7 days
Anal Fissure	140	978	890
External thrombosis	095	032	217
Internal thrombosis	002	129	010
Anal papilla hypertrophy	014	002	018
Anal laceration	000	014	000
Skin tag	103	539	126
Number of RAR	250	243	387

After multivariate analysis variables that significantly influence post operative pain on 24 hours were removing of internal thrombosis, removing of anal papilla hypertrophy and anal laceration, on 48 hours were removing of external thrombosis, removing of anal papilla hypertrophy and anal laceration and on 7 days were the same with on 24 hours ($p < 0.05$) (Table 2).

DISCUSSION

DGHAL was first introduced in 1995 by Morinaga *et al.* Since then, there have been a number of reports of small series demonstrating the early efficacy of the procedure. Sample sizes were in the range of 30133 patients. The success rates reported vary from 80% to 92%.⁵ Some authors have reported success in treating various symptoms of hemorrhoids; Morinaga *et al.* had better resolution of bleeding (96%) than prolapse (78%),⁸ while Sohn *et al.* reported better results for prolapse (92%) than bleeding (88%).¹⁰ In order to justify the use of DGHAL, a direct comparison to the gold standard of haemorrhoidectomy was inevitable, though not necessarily relevant.^{1-3,5} Bursics *et al.* reporting that patients after DG-HAL operations need significantly less pain killer, their hospital stay is shorter, and they return to their normal daily activity much more quickly. This is not surprising, given that there is no real wound left after the operation. The operative trauma is minimal.^{5,8,10,12} DGHAL is a safe, relatively painless, and effective treatment for stage III hemorrhoids.^{5,9,11,12} Walega *et al.* RAR seems to be a safe method of treatment of III and IV grade hemorrhoidal disease with no major complications and a high rate of good short-term results.^{3,12} In our study showing that no significant

difference ($p > 0.05$) VAS scale on 24 hours, 48 hours, and 7 days for patients with hemorrhoid grade II IV and patient with or without anal fissure.¹³ Meanwhile, in other studies, the number of artery ligations was, on average, 5-10; particularly, the number of recto-anal repairs was a minimum of 1 and a maximum of 5.^{1,4,7} Postoperative pain was easily managed with NSAIDs administered i.v. or p.o. The hospital stay was standardized and lasted for a total of 48 hours, due to our aim of careful evaluation of postoperative course. fissure or anal canal polyp excision required analgesics for 1-2 days.¹² Multivariate analysis our study reporting that post operative pain on 24 hours after we removing of internal thrombosis, removing of anal papilla hypertrophy and anal laceration ($p < 0,05$), on 48 hours patients complaint pain after removing of external thrombosis, removing of anal papilla hypertrophy and anal laceration ($p < 0,05$) and on 7 days complaint pain were the same with on 24 hours ($p < 0,05$). Pain after DGHAL related with anatomical anal canal. The epithelium of the anatomical anal canal (between the anal verge and the dentate line) is described as anal skin as it looks like (pigmented) skin, is sensitive like skin. From a surgical perspective, the anal canal just above the dentate line for about 1-2 cm is called the transition zone. Beyond this transition zone, the (surgical) anal canal is lined with columnar epithelium (which is insensitive to cutting) (Fig.2)

Removing of the hypertrophic anal papilla and anal laceration were the factors that after multivariate analysis significantly influence the pain on evaluation 24 hours, 48 hours and 7 days post-operatively. Anal papilla located in the same region with anal valve and is the richer of the free nerve ending which very sensitive for pain (PUSTAKA). Anal laceration in this series (1 case) extending from anal verge to the anal papilla, therefore stimulate the area of richer nerve ending as well. Internal thrombosis was significantly influence the post-operative pain on 24 hours and 7 days. Internal hemorrhoid located in the transitional zone (until 1 cm above dentate line) which has nerve ending but lesser compared to anal papilla, while internal thrombus mostly located in the distal end of the hemorrhoid so closed to the anal papilla, therefore removing internal hemorrhoid thrombus more painful. External thrombus located in the anal canal skin, that also has

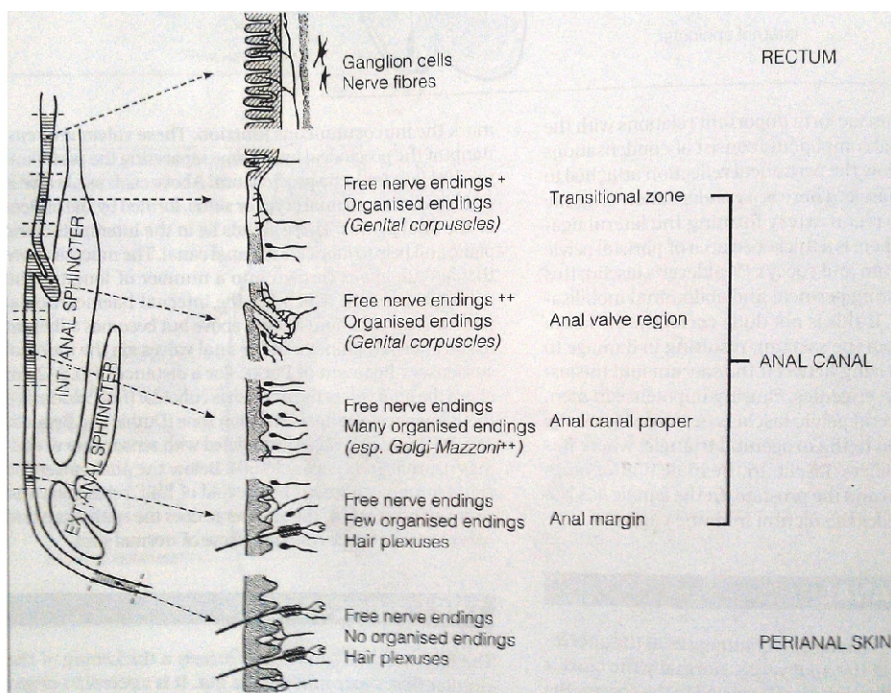


Figure 2. Anal Canal Description

nerve ending but lesser compared to anal valve. In this study on uni-variate analysis showed significantly influence the post-operative pain on 24 hours, 48 hours and 7 days, but its role on multivariate analysis was only on 48 hours post-operatively. RAR in 4 location or more was also factor influence post operative pain on 24 hours and 48 hours on univariate analysis but its role disappears after multivariate analysis. In patients with RAR of 4 or more location can be assumed that the prolapse was big enough so the last stich tend near to the dentate line.

CONCLUSION

Removing external and internal thrombosis, removing hypertrophic anal papilla and the presence of anal laceration after procedure were factors that influence post operative pain. Abundant lubrication and gentle insertion of Doppler anoscope is important step to prevent the anal laceration. The presence of factors that exaggerated post-operative pain consider medicate the patients with more potent analgesic rather than ketorolac.

REFERENCES

1. P. M. Wilkerson, et all, Doppler-guided haemorrhoidal artery ligation: long-term outcome and patient satisfaction, 2009 The Association of Coloproctology of Great Britain and Ireland. *Colorectal Disease*, 11, 394400
2. Neil P. Forrest, et all, Doppler-guided haemorrhoidal artery ligation with recto anal repair: a new technique for the treatment of symptomatic haemorrhoids, *Int J Colorectal Dis*, 2010
3. Piotr Walega, et all, Doppler-Guided Hemorrhoid Artery Ligation with Recto-Anal-Repair Modification: Functional Evaluation and Safety Assessment of a New Minimally Invasive Method of Treatment of Advanced Hemorrhoidal Disease, *The Scientific World Journal*, 2012
4. P. Giordano, et all, Prospective evaluation of stapled haemorrhoidopexy versus transanal haemorrhoidal dearterialisation for stage II and III haemorrhoids: three-year outcomes, *Tech Coloproctol* (2011) 15:6773
5. Attila Bursics, et all, Comparison of early and 1-year follow-up results of conventional hemorrhoidectomy and hemorrhoid artery ligation: a randomized study, *International Journal of Colorectal Disease*, 2003
6. Varut Lohsiriwat, Hemorrhoids: From basic pathophysiology to clinical management ; *World J Gastroenterol* 2012 May 7; 18(17): 2009-2017
7. Wan Jo Jeong, One Year Follow-up Result of Doppler-guided Hemorrhoidal Artery Ligation and Recto-Anal Repair in 97 Consecutive Patients, *J Korean Soc Coloproctol* 2011; 27(6): 298-302
8. Avital S, Outcome of stapled hemorrhoidopexy versus doppler-guided hemorrhoidal artery ligation for grade III

- hemorrhoids, *Tech Coloproctol.* 2011 Sep;15(3):267-71.
9. Avital S et al, Five-year follow-up of Doppler-guided hemorrhoidal artery ligation, *Tech Coloproctol.* 2012 Feb;16(1):61-5
 10. Nguyen V et al, French experience in the management of hemorrhoids by HAL™ Doppler. *J Visc Surg.* 2012 Dec;149(6):412-6
 11. Szmulowicz UM et al, Doppler-guided hemorrhoidal artery ligation: the experience of a single institution, *J Gastrointest Surg.* 2011 May;15(5):803-8.
 12. Walega P et al, Two-center experience in the treatment of hemorrhoidal disease using Doppler-guided hemorrhoidal artery ligation: functional results after 1-year follow-up, *Surg Endosc.* 2008 Nov;22(11):2379-83
 13. Robert A pol et al, Results of 244 consecutive patients with hemorrhoids treated with Doppler-guided hemorrhoidal artery ligation (DG-HAL), *Dig Surg.* 2010;27(4):279-84.