

Bilateral Inferior Altitudinal Defects Secondary to Stroke: A Case Series

Stacey Chong, BSc, OD, MSc

Tammy Labreche, BSc, OD

Patricia Hrynychak, OD,
MScCH(HPTE), FAAO

Michelle Steenbakkens, OD,
FAAO

University of Waterloo, School of
Optometry and Vision Science
stacey.chong.od@gmail.com

Abstract

Strokes or cerebrovascular accidents are the third leading cause of death in Canada, comprising 6% of all deaths in the country.¹ The elderly and the very young (fetus or newborn infants) are at highest risk for having a stroke with an associated increased risk of death or lasting neurological disability.²

According to the National Stroke Association recovery guidelines, 10% of stroke survivors will recover almost completely, 25% will recover with minor impairments, 40% will survive with moderate to severe impairments that require specialized care, 10% will require care in a long-term care facility, and 15% will die shortly after the stroke. The National Stroke Association estimates that there are 7 million people in the United States that have survived a stroke and are living with impairments. The Heart and Stroke Foundation's 2013 Stroke Report has estimated that 315,000 Canadians are living with the effects of stroke. This case series serves as a reminder that, although rare, bilateral inferior altitudinal visual field defects can also occur as the result of a stroke, to highlight the difficulties of orientation and mobility that can result, and to offer potential rehabilitative strategies.

KEY WORDS:

stroke, cerebrovascular accident, ischemic perinatal stroke, visual field

Résumé

Les crises cardiaques ou accidents vasculaires cérébraux sont au 3^e rang des principales causes de mortalité au Canada et représentent 6 % de tous les décès au pays¹. Les aînés et les jeunes enfants (fœtus ou nourrissons) sont les deux groupes qui présentent le plus grand risque d'une crise cardiaque pouvant mener au décès ou à des troubles neurologiques permanents².

Selon les lignes directrices en matière de rétablissement de la National Stroke Association, 10 % des survivants d'un AVC se rétablissent presque complètement, 25 % se rétablissent avec des déficiences légères, 40 % survivent avec des troubles des déficiences modérées à graves qui requièrent des soins spécialisés, 10 % ont besoin de soins dans un établissement de soins de longue durée et 15 % meurent peu de temps après la crise cardiaque. La National Stroke Association estime que 7 millions de personnes aux

États-Unis ont survécu à une crise cardiaque et vivent avec des déficiences. Le rapport de 2013 de la Fondation des maladies du cœur estime que 315 000 de Canadiennes et Canadiens vivent avec les séquelles d'une crise cardiaque. Cette série de cas nous rappelle que bien qu'elles soient rares, des pertes altitudinales bilatérales du champ visuel inférieur peuvent également survenir à la suite d'une crise cardiaque et met en évidence les difficultés d'orientation et de mobilité qui peuvent en résulter, puis offre des stratégies de réadaptation potentielles.

MOTS CLÉS:

crise cardiaque, accident vasculaire cérébral, AVC ischémique périnatal, champ visuel

INTRODUCTION

It is estimated that 50,000 strokes occur in Canada every year, approximately one stroke every 10 minutes.³ Strokes can occur at any age, but the incidence increases significantly over the age of 60 years.³ The incidence of strokes during the perinatal period is second to that of adult age groups. Ischemic perinatal stroke (IPS) is estimated to have an incidence of between 1 in 2300–5000 births^{4–6} and is 17 times more common in the perinatal period than in childhood or older.^{2,7} There are two forms of stroke, ischemic and hemorrhagic.¹ In adults, the ischemic type of stroke makes up 80% of strokes and involves the interruption of blood flow to the brain by a thrombus or embolus, in contrast to the other 20% of strokes that are hemorrhagic.¹ In children, the ischemic type can make up between 50–70% of perinatal strokes.^{8,9} In addition to hemiplegia, dysphasia, vertigo, ataxia, nystagmus, and cognitive impairment, a stroke can result in visual field loss, which can complicate rehabilitation efforts.

Visual field loss or visual impairment has been reported to occur in up to 70% of adult patients who have suffered from a stroke.^{10–14} Spontaneous visual field improvement in the first 3–6 months has been reported in up to 50% of patients, although after this period, recovery has been reported to be possible but occurs at a much slower rate.^{11,15} Recovery is dependent on the extent of damage, and its ability to be reversed relies on collateral circulation,¹⁵ although no correlation has been found between type of patient, stroke, field loss, and recovery outcome.^{10,11} Homonymous hemianopia, a loss of the same lateral half of the visual field in both eyes, is the most common and occurs in up to two-thirds of people with visual field loss.^{10–12} Other visual field defects that can occur include quadrantanopias, constricted visual fields, altitudinal defects, macular sparing hemianopia, and checkerboard defects.^{10,12–14} Damage to the occipital lobe has been associated most frequently (54%) with visual field loss secondary to stroke.^{10,11,15,16} The visual cortex is typically supplied by the calcarine artery, the terminal branch of the posterior cerebral artery (PCA).^{17,18} Supplementary branches to the visual cortex include the posterior temporal and parieto-occipital branches from the PCA and the occipital branches from the middle cerebral artery (MCA).^{17,18} The area of cortex representing the macula may be supplied by branches of the PCA, as well as the MCA. This allows for macular sparing when one of the two has been occluded.^{10,18–20}

PCA infarcts represent 5–10% of the documented strokes, and the leading symptom of PCA infarcts is visual (97%).²¹ Measurable visual field abnormalities are found in up to 93% of these patients, with the highest percentage having homonymous hemianopsia.²¹ Up to 8% are found to have bilateral visual defects, which are associated with multiple stroke events. Only up to 4% have a lower visual field deficit.²¹

Regardless of the type of stroke, it is necessary to determine the type of visual field defect in order to best help the patient develop coping strategies. Although bilateral inferior visual field defects may not be common, they cause significant difficulty with orientation and mobility, especially in unfamiliar environments. Two cases are presented with primarily inferior altitudinal visual field loss resulting from stroke in an elderly gentleman and in a young girl who had a perinatal stroke.

CASE REPORT 1

A 69-year-old man presented to the clinic on referral from a local hospital with a history of a cerebrovascular accident one month prior that resulted in visual perceptual changes. The preliminary in-hospital vision assessment revealed evidence of right-sided neglect and decreased visual tracking ability. His initial computerized axial tomography (CT) scan revealed bilateral cerebellar and occipital lobe hypodensity and hyperdensity of the ventricles. These findings were interpreted to represent posterior cerebral infarcts. An magnetic resonance imaging (MRI) was performed a few days later that suggested embolic stroke (bilateral cerebellar and occipital lobe) and possible posterior leukoencephalopathy. He was transferred to a facility for rehabilitation.

At the initial oculovisual assessment, he described that his central vision was clear but his peripheral vision was blurred. This represented an improvement over the total loss of vision that was experienced at the time of the stroke. The best-corrected visual acuity was 6/12-3 in the right eye and 6/6- in the left eye, with a refraction of OD: -3.00 -2.00 x 107 and OS: +1.25 -1.25 x 099. Eye movements were unrestricted, but pursuits were not smooth. Intraocular pressures were 15 mmHg in the right and 13 mmHg in the left eye. A dilated fundus exam revealed visually significant grade 1+ nuclear sclerosis, grade 2+ posterior subcapsular cataract and lens vacuoles in the right eye and grade 1+ nuclear sclerosis and lens vacuoles in the left eye. Pupils were round and reactive to light with no relative afferent pupillary defect. The posterior pole and peripheral examination were unremarkable. The optic nerves had cup-to-disc ratios of 0.5 horizontal/vertical (H/V) in the right eye and 0.45 H/V in the left eye. There was no evidence of any optic nerve pallor or hemorrhages and no nerve fibre layer defects. A Humphrey full field 120 degree visual field (Figures 1 and 2) was done and bilateral inferior altitudinal defects were detected, along with a diffuse superior defect and a tendency towards a right superior quadrantanopia in both eyes. The broad general loss detected on the visual field was attributed to cataracts, fatigue, and unfamiliarity with the test. A referral for a cataract surgery consultation and a repeat visual field were arranged.

Two weeks following the initial oculovisual assessment, the rehabilitation centre referred the patient back to our clinic because they were ready to discharge him from inpatient care, but he was still struggling with vision problems. He was continuing to have difficulty with peripheral vision and inferior visual field. Their concern was with navigating unfamiliar environments and their view was that he was unsafe to return home alone. Aided visual acuities were 6/15- in the right eye, 6/6- in the left eye, and 6/6-3 with both eyes together. The Humphrey full field 120 degree visual field was repeated with good reliability, revealing bilateral inferior altitudinal defects, less complete in the right eye, and the superior fields had more diffuse loss in both eyes (Figures 3 and 4). He was advised to actively tilt his chin to scan his inferior field, especially while walking, to help him navigate with more confidence. A referral for orientation and mobility training was suggested.

At one-month follow up post-cataract surgery, his unaided visual acuity in the right eye was 6/7.5, as reported by the ophthalmologist. Five months later he was living in a retirement home and satisfied with actively looking in his inferior field to help with orientation and mobility. He did not want further mobility training or visual field testing.

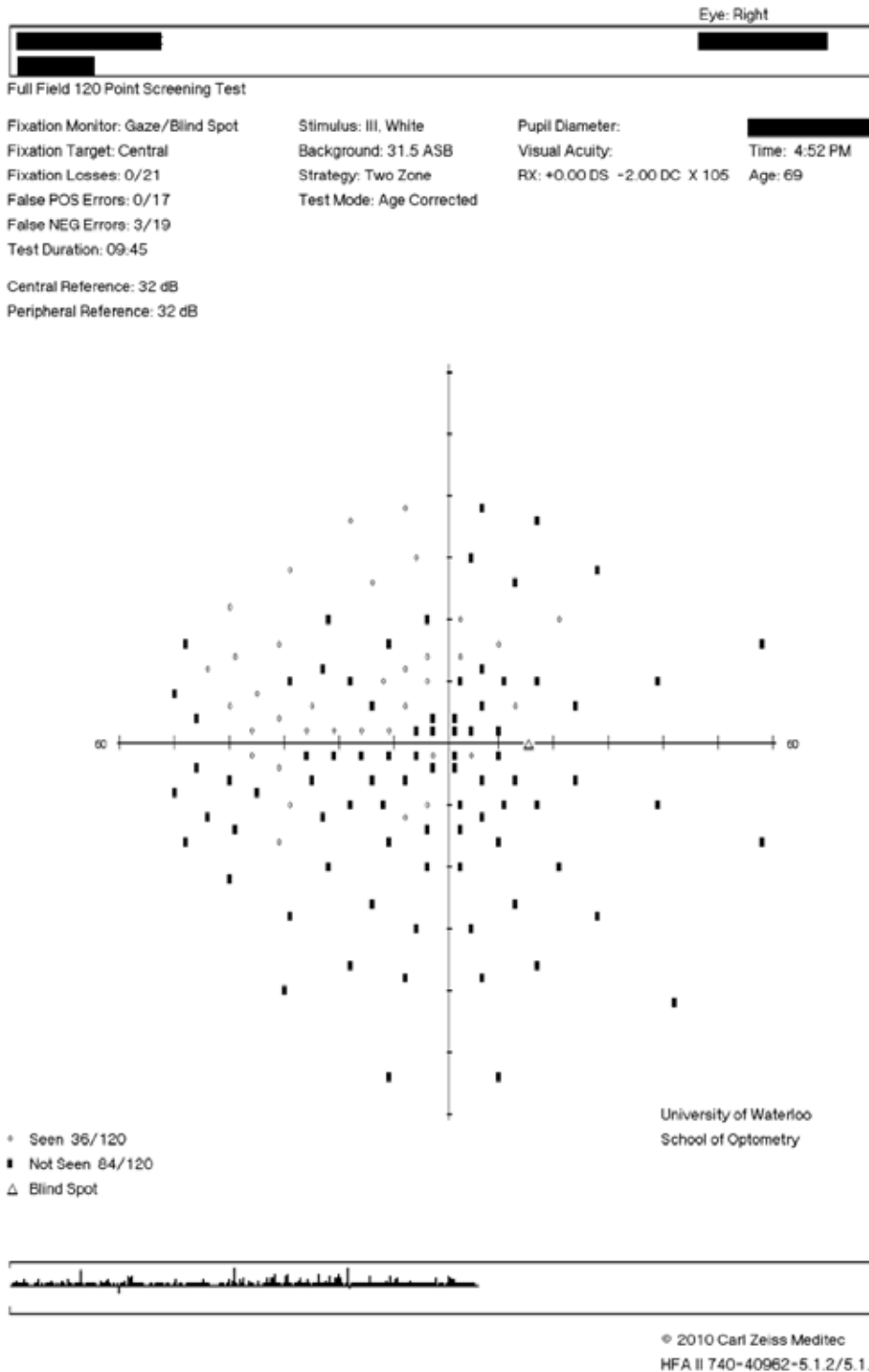


Figure 1. Initial visual field: right eye.

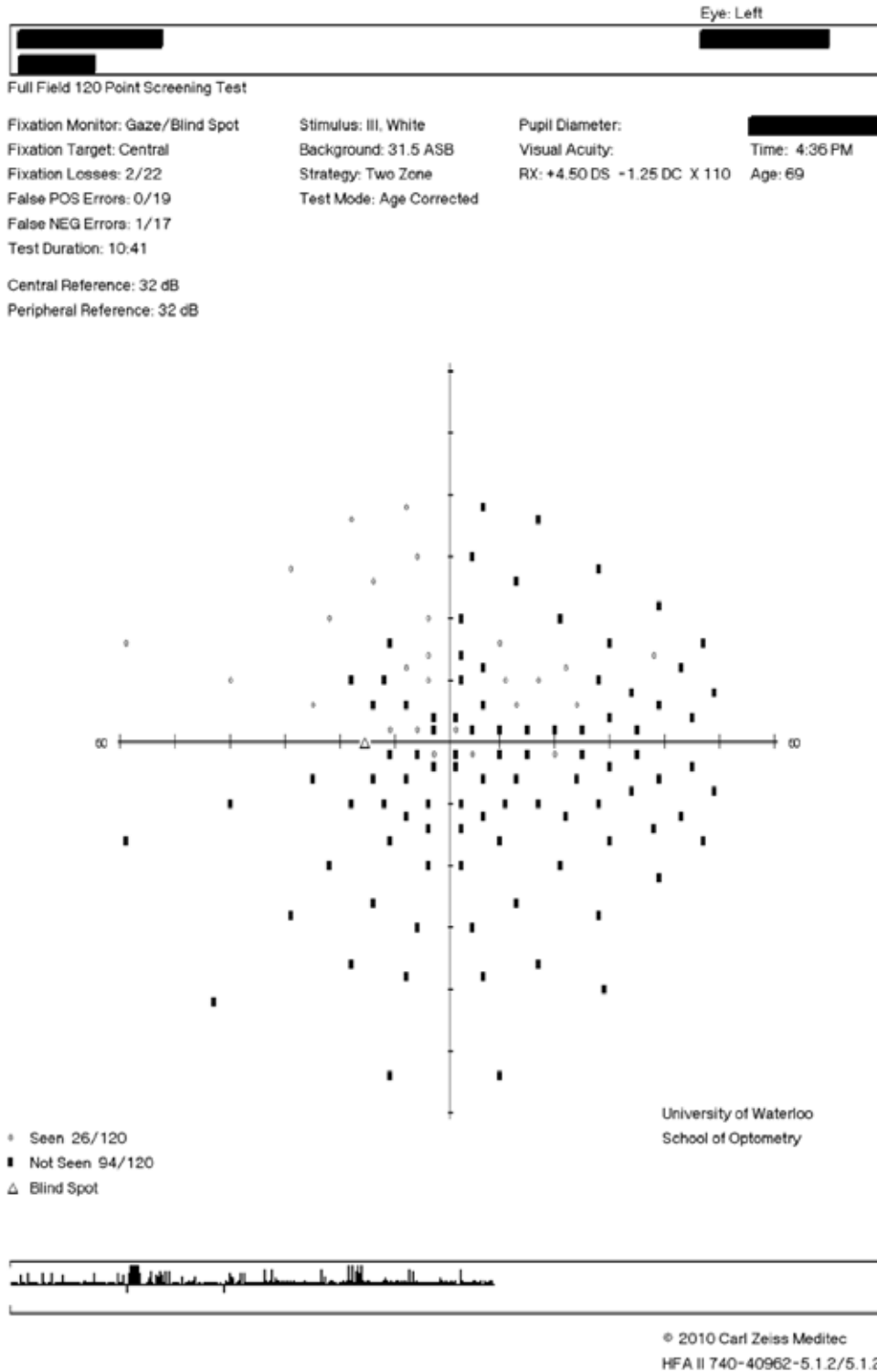


Figure 2. : Initial visual field: left eye.

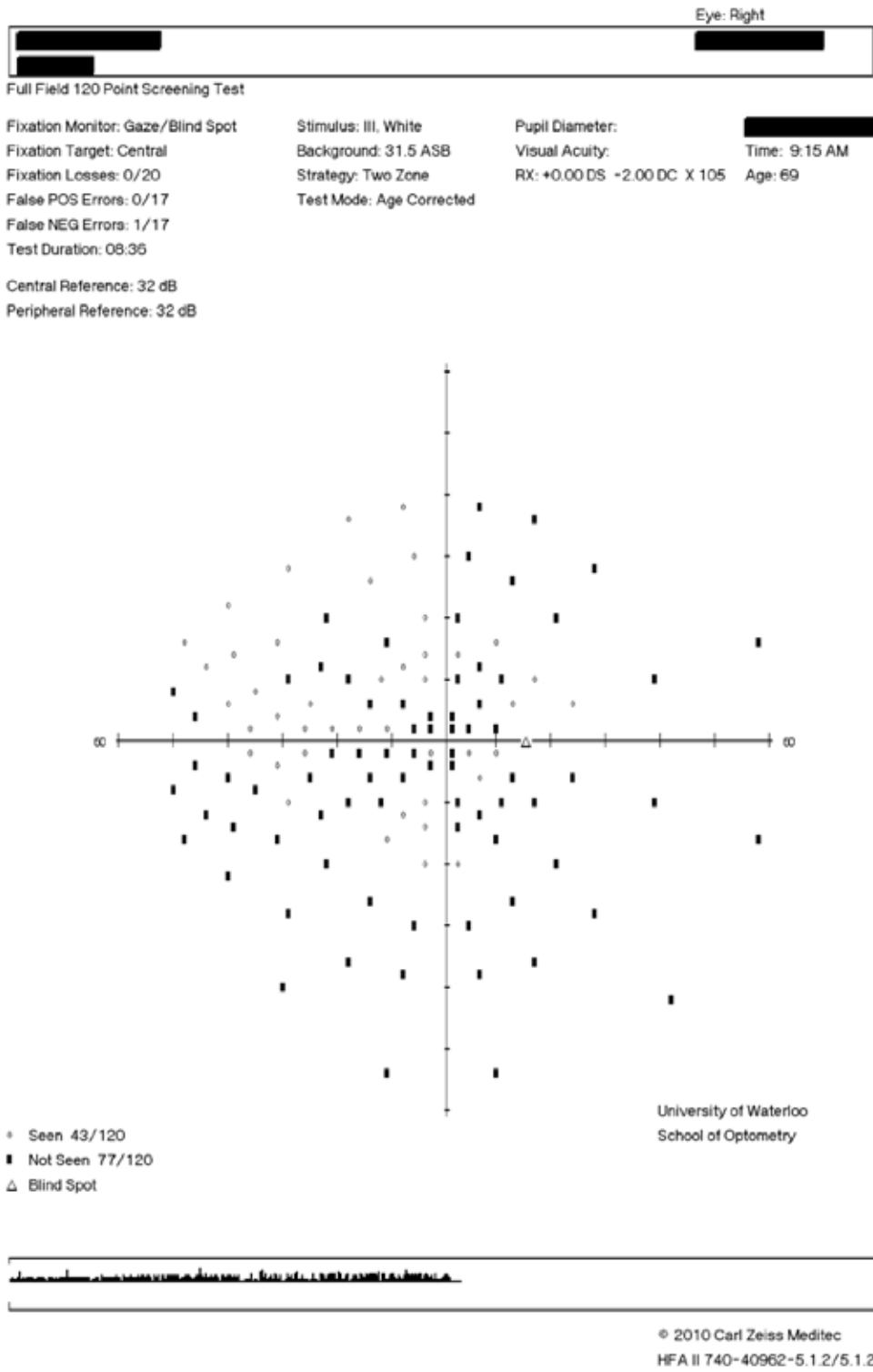


Figure 3. : Visual field of the right eye at follow-up.

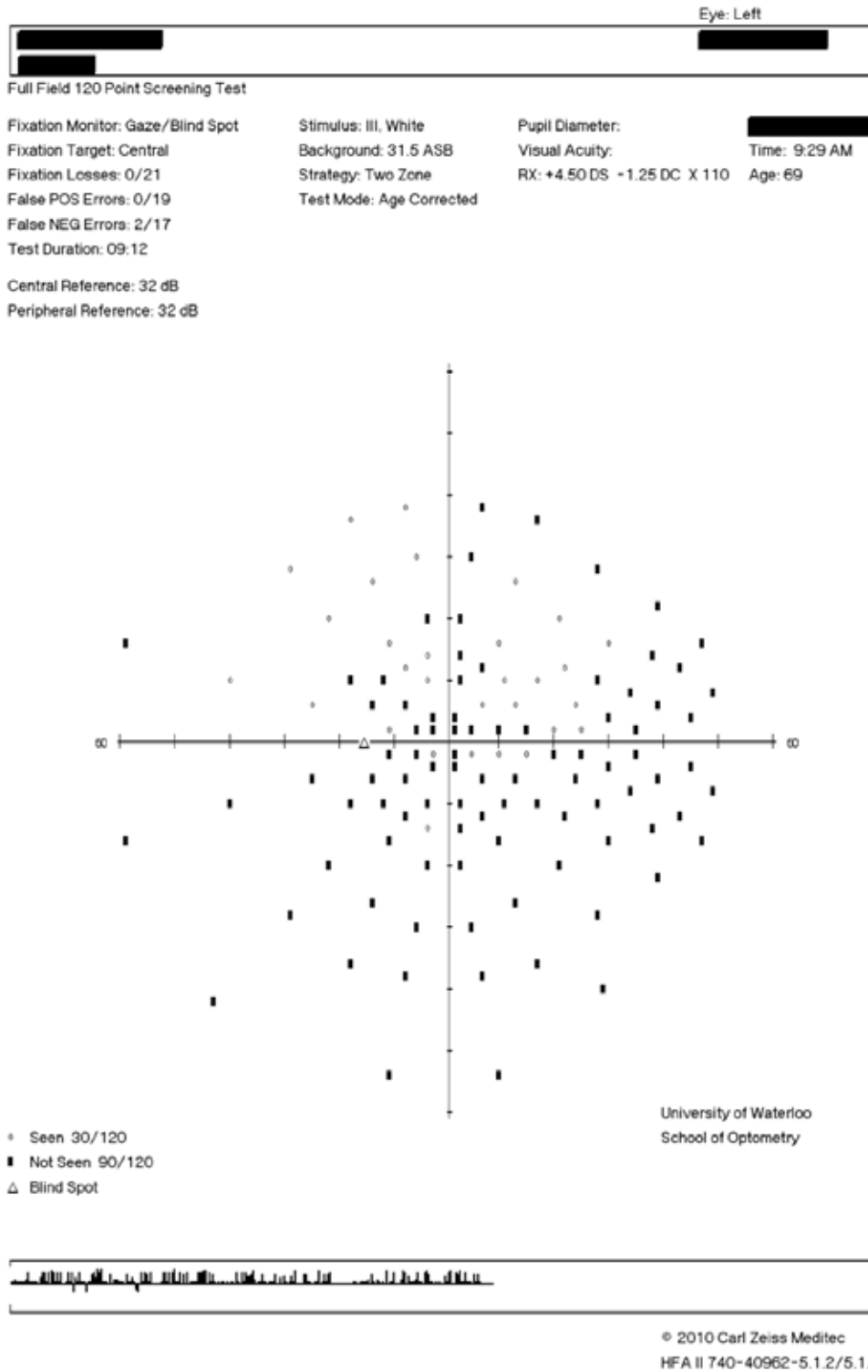


Figure 4. : Visual field of the left eye.

CASE REPORT 2

A 14-year-old girl presented for an assessment in the low vision clinic. She was born at full term, but during labour there was a drop in fetal heart rate, meconium in the amniotic fluid, and the chord was wrapped around her neck. Despite these issues there were no ocular or general health concerns at the time. Magnetic resonance angiography was performed at age three years due to concerns regarding developmental delay and strabismus (an alternating exotropia with inferior oblique overreaction). The results suggested hypoglycemia as the cause of the brain damage with encephalomalacia and damage to the frontal and occipital lobe. It was believed she suffered a stroke around the time of birth. Strabismus surgery was performed bilaterally at the age of four years that resulted in an esotropic overcorrection. Patching for amblyopia was done. It was noted that she was ignoring objects or light presented in her right field. At the age of five years, an assessment by an occupational therapy centre was completed. She was found to have low fine motor skills, inability to use both hands equally (right hand function was reduced), low visual attention and processing speed, weak graphomotor skills, and lower than average intellectual functioning. However, her expressive language functioning was in the 91st percentile, which included comprehension and effective use of language.

Her first assessment in the clinic was at the age of six years. A previous functional vision assessment performed by a vision itinerant teacher indicated that she had difficulty tracking, often lost her spot while reading, tripped over obstacles in the classroom (chairs, students), and was very cautious around stairs and curbs as a result of her constricted visual fields. Unaided visual acuities were 6/21 and 6/30. Motility testing revealed a slight restriction as well as nystagmus on left gaze. She had a 45 prism dioptre (pd) constant alternating esotropia at near becoming greater than 50 pd at distance, as well as a constant left hypertropia at distance and near latent nystagmus noted in the left eye. Fundus evaluation revealed optic nerve heads with symmetric healthy pink rim tissue in both eyes with cup-to-disc ratios of 0.2 in each eye. A low vision assessment was conducted to address school concerns, playing team sports (soccer), and navigating unfamiliar places. Goldmann visual fields revealed bilateral inferior visual field loss. Field expanding prisms were discussed for the future, as well as reverse telescopes (2.75X). High add readers (+4.00 D) were appreciated to help decrease strain and fatigue associated with prolonged near activities. A 1.7x dome magnifier allowed greater comfort with reading the finer print in a book that she had brought to the assessment. At age nine, she began treatment with a physician in Boston who had an interest in neurology and neural plasticity. She was using a computer-based program to improve her visual defects (13 sessions with improvement noted by neurologist).

At the most recent visit, the patient reported that her vision had been stable for a number of years. Despite demonstrating vast improvements in her independence at school, mobility was still a concern, although she reported that 90% of the time she felt comfortable with new surroundings. Aided visual acuities were OD 6/19+2 (-7.50 -2.50 x 180), OS 6/38+1 (-7.00 -2.50 x 180), OU 6/15-1. Goldmann visual fields were improved, although it was difficult to determine if there was true visual field improvement or better test performance due to increased age (Figures 5–8). Her vision was considered stable and she was doing well in school, was able to navigate her environment most of the time, and was continuing with the computer training. An appointment was offered to review field enhancement options.

DISCUSSION

The first patient suffered a bilateral posterior cerebral infarct that resulted in bilateral inferior field loss with macular sparing. To produce this type of field loss, the infarctions might have occurred in the calcarine terminal branches of the posterior cerebral arteries, above the calcarine fissure. The macular sparing was likely due to the dual supply of the macula by the middle cerebral arteries. For the second patient the MRI indicated bilateral occipital lobe damage along with smaller caliber middle cerebral arteries, which confirm the cause of her bilateral visual field defects with macular involvement. There was no indication of damage to her posterior cerebral arteries, but this would most likely be the cause of the inferior altitudinal defects. For both patients, pre-chiasmal or optic nerve head diseases were ruled out due to the healthy

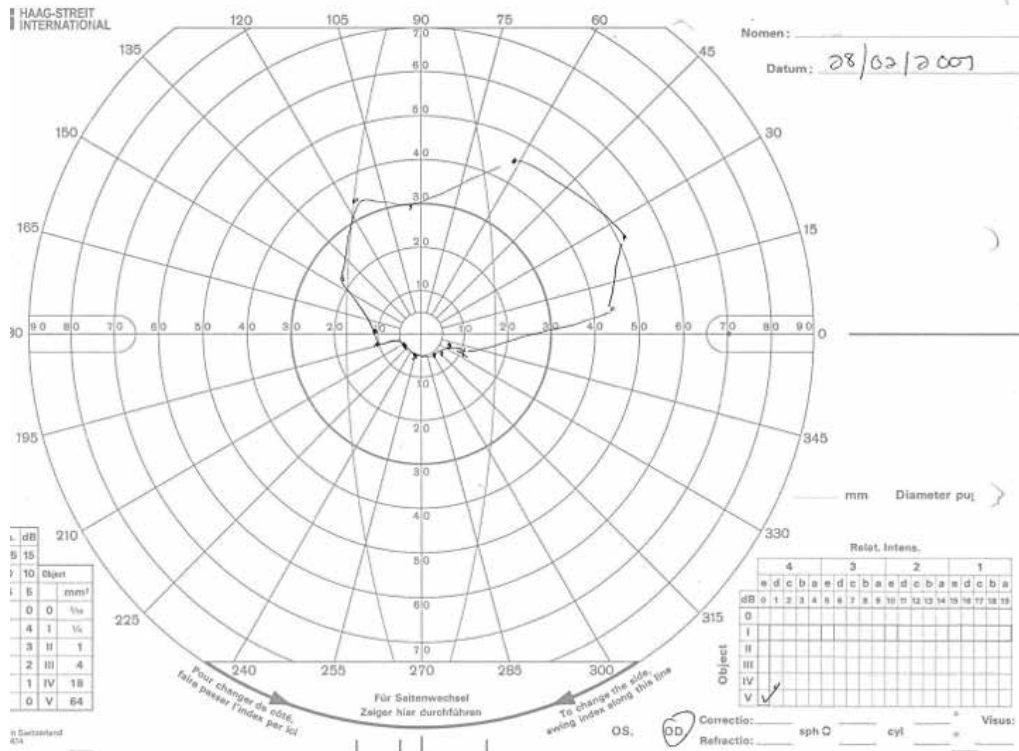


Figure 5.: Visual fields for AS at age 7 years, right eye.

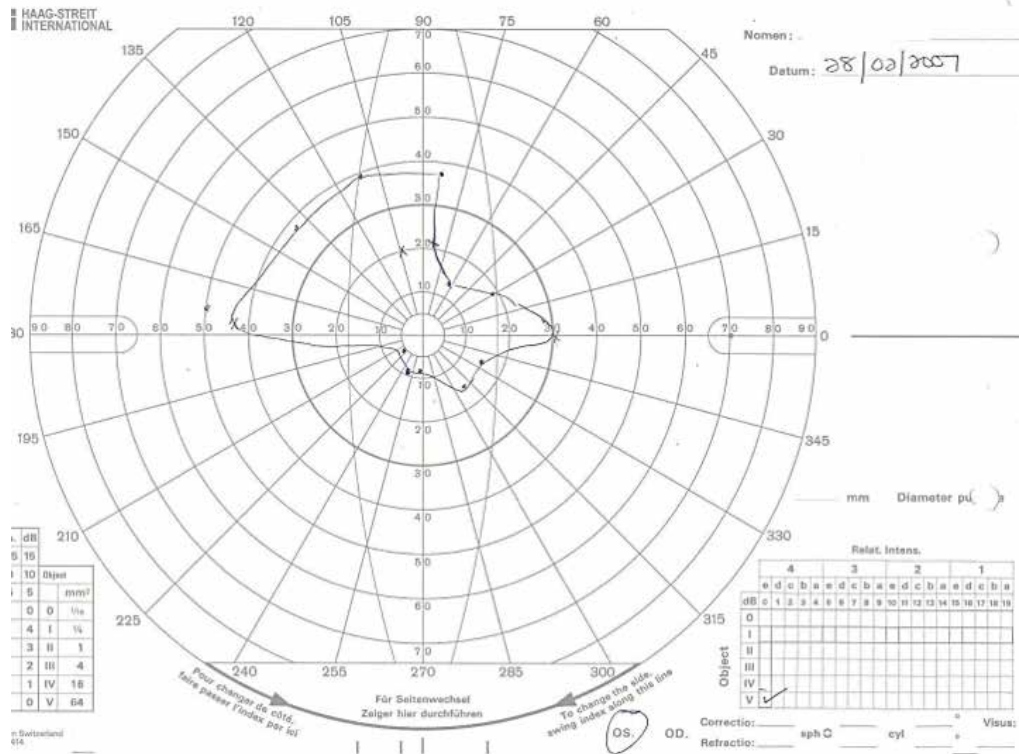


Figure 6.: Visual fields for AS at age 7 years, left eye.

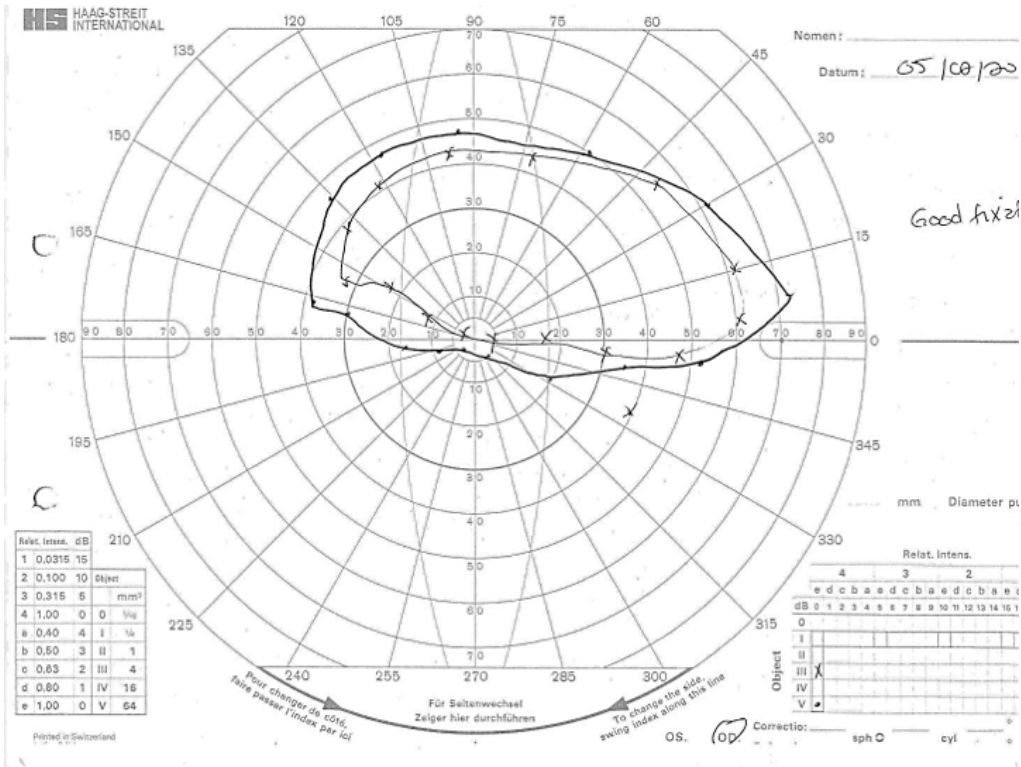


Figure 7 : Visual fields for AS at age 14 years, right eye.

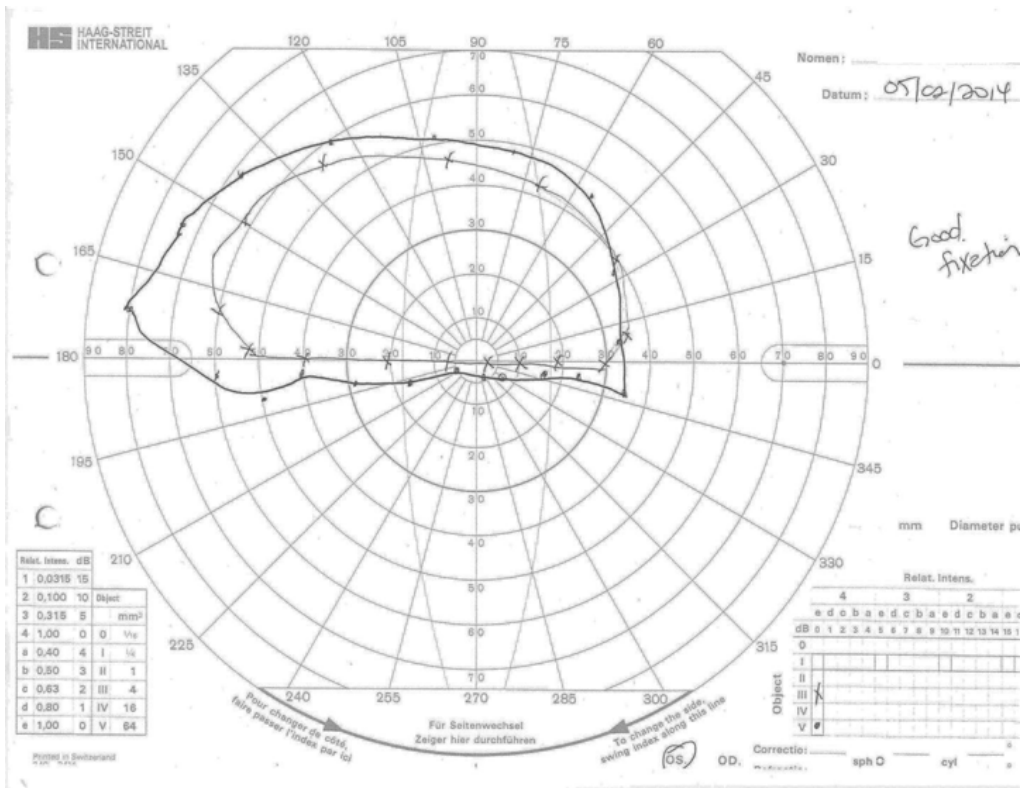


Figure 8 : Visual fields for AS at age 14 years, left eye.

appearance of the optic nerves and the absence of a relative afferent pupillary defect, although other supporting evidence that would be helpful for future diagnoses would include an optical coherence tomography scan and a Humphrey visual field including the mean deviation value.

Binocular inferior altitudinal visual field defects can be very debilitating, negatively impacting mobility, navigation, scanning, reading, and driving. Not only do visual field defects cause difficulty in activities of daily living, but they can also hinder a person's ability to seek help or participate in rehabilitation, decrease quality of life, and potentially cause depression and isolation. Detecting the full extent of a visual field defect in a young child may be difficult due to decreased attention, but attempts should be made to help facilitate rehabilitation. Automated perimetry is difficult in young children, although they can perform well with Goldmann perimetry, which is a form of kinetic perimetry. Goldmann perimetry permits the child to take frequent breaks. The perimetrist is able to modify the target size and number of points mapped, as well as monitor fixation directly during testing.

Plastic reorganization of the cortex after injury has been thought to be faster in children, which is demonstrated by the low incidence of abnormal vision after suffering from cortical damage.^{22,23} During the first few weeks of insult, it has been shown that there is a slight enlargement of the defective visual field that is a result of resolving tissue adjacent to the affected area or changes in the neural circuitry.^{24,25,18} With early brain damage, it is difficult to determine the extent of the vision loss, which is due to the low reliability of behavioural responses typically governed by attention.^{23,26} Knowledge of brain plasticity is currently limited and supported with non-human models, including the possibility of the development of new connections to by-pass damaged tissue and differentiation of functional tissue to compensate.²³

It has long been thought that structural changes in the primary visual cortex can only occur during the critical period of development (up to age 8 years).^{27,28} It has now been demonstrated that the cortical maps of adults are not fixed and can reorganize, resulting in changes in cortical topography.²⁹ Cortical plasticity allows for the ability to fill in images when there is a visual field defect and to spatially distort the field around scotomas to alter what is perceived.²⁹ There is no restoration of function of the destroyed tissue but compensation can occur in areas that are missing in our perception. This process of filling in causes a difference in the perceived defect, compared to the actual defect. The mechanisms that allow for cortical reshaping are thought to include changing the efficacy of pre-existing synapses, such as long-range horizontal connections, as well as creating new connections.³⁰⁻³² The expansion of the visual cortex is thought to be accomplished through bypassing the striate cortex to connect to areas such as the subcortical nuclei,²³ and it has been shown that the superior colliculus may be a key player in building connections for maintaining residual function as shown with functional MRI (fMRI).^{33,34} New areas of interest include the potential for implantation of stem cells or the use of progenitor cells for future rehabilitation.³⁵

Field enhancement and rehabilitation options can be considered if a homonymous hemianopic, inferior altitudinal, or overall constricted visual field defect remains following a stroke. Rehabilitation efforts endeavour to maximize the utility of the remaining vision and thereby lessen the associated impairment in function by using optical devices and/or visual training.

Optical devices used for rehabilitation include prisms to expand or relocate (enhance) the visual field and minification tools such as reverse telescopes. Prisms can be ground in or self-adhesive (Fresnel) and are effective for lateral hemifield loss. Ground-in prisms are optically clear but can be very thick, as the required prism magnitude for rehabilitation is rather large (20–40pd). Fresnel prisms are lighter; however, resolution and contrast sensitivity are reduced when viewing through the prism. A rigid Fresnel prism is another option that allows for the same permanency of a ground-in prism while retaining the other features. As the magnitude of the prism power required for field enhancement increases, the visual acuity and contrast sensitivity is compromised, as there are increased optical aberrations. Taken into conjunction with image shifting when the prism is engaged, it can be detrimental to mobility when applied inferiorly.

Traditionally, binocular sector prisms have been used for rehabilitation of field loss. They are placed on the spectacle lens over the affected half of the vision with the base oriented toward the hemianopic side, shifting images to the remaining field of functioning vision only when the individual looks through the prism^{36,37}; this creates an apical scotoma.³⁸ Alternatively, field expansion can be created with a monocular sector prism. It is placed over the half of the lens on the hemianopic side, with the same prism orientation as the binocular sector prisms. When the individual engages the prism, field expansion does occur, in conjunction with diplopia and visual confusion.³⁶ As the field defect demonstrated by the patients in this case report is located inferiorly, these common uses of prisms applied to glasses may not work as effectively as the resulting shift in perception or double vision, and visual confusion may act to further impair mobility and increase the risk of falls.

Peripheral prisms, also known as Peli prisms, are high-powered Fresnel prism segments (each 40 prism diopters) that are fit to the upper and lower portions of the lens on the hemianopic side, with the base of the prism in the direction of the field loss.³⁹ This use of prisms allows for double vision to only occur in the periphery and has been shown to expand the visual field by 22 degrees in both the upper and lower quadrants.³⁹ As the prisms extend on either side of fixation, the shifted image is always present, allowing for field expansion in all lateral gazes, as opposed to only direct gaze through the prism.³⁸

Subjectively, participants have rated the prisms helpful, particularly with obstacle avoidance and mobility.⁴⁰ Peli prisms are commonly used for temporal and nasal hemianopia. More recently, the oblique peripheral Peli prism design has been recommended, which allows for pericentral expansion of field. The 30-degree apex-base angle allows for responsiveness closer to the meridian while preserving single vision and circumventing central confusion and apical scotomas (with binocular viewing) when the prism is fit unilaterally. Peripheral visual confusion remains. When fit bilaterally, the peripheral confusion is minimized, but the apical scotoma is larger and there is some pericentral diplopia.³⁸ To our knowledge, there are no studies to date applying the Peli prism vertically for altitudinal defects. Monocular use of the Peli prism aligned vertically may provide some help but should be used with caution and may not be easy or intuitive to use.

Reverse telescopes can be used to minify the world to allow for a larger field of view to better identify obstacles and can also be used for any type of field loss. They may be handheld or spectacle-mounted in a bioptic position. They are typically used as a spotting tool in an unfamiliar environment in order to quickly locate obstacles. Minification results in a decrease in visual acuity and is tolerated well only by those individuals with good central acuity.⁴¹

Visual training techniques, such as modifications in visual behaviour, including increasing saccadic patterns and saccadic amplitudes into the blind field, have been a common method of compensating for visual field loss.⁴² These are incorporated into training programs to develop visual search strategies and for orientation and mobility. Training techniques include having patients perform exercises where they are directed to make repeated movements into the blind area in either a stepwise staircase method or in a manner that overshoots the target to bring it into the visual field. Saccades can also be trained with exercises to increase the size of the saccadic pattern, and this can be adopted into search pattern strategies. This is an intuitive training method to help patients with any type of field loss, including inferior field loss.

Computer training is another form of visual training rehabilitation that has been used to restore function and vision. Visual field restitution is a computer-based program using flicker to stimulate the border zone of the blind field to produce a reactivation in the cortical function of surviving neurons. It was developed based on the theory of neuroplasticity; however, the effectiveness of the treatment is debatable, as improvements in visual field have only been measured with the program and have not been repeated with perimetric testing.⁴³

The above strategies are designed to shift or increase the extent of the visual field; however, there is not enough evidence regarding benefits or the ability to improve daily living tasks.^{44,45}

At the moment it seems that training a person's ability to scan is the most promising method of treatment for inferior altitudinal defects, but more research is needed to confirm this.⁴⁵ Visual search strategies in conjunction with orientation and mobility training can help a patient to determine where they are in the space and to strategize how to get to where they want to go; they should be recommended to people with inferior field loss. This typically includes developing better sensory awareness, understanding relationships between objects, developing searching skills, and using aids like a walking stick, a guide, or a guide dog. Optical devices, including prisms for rehabilitation of inferior field defects, should be used with caution and with ample training on use.

Children with congenital visual field defects or defects that occurred at a young age, including those secondary to stroke, have the potential to adapt and overcome these deficits. If the defects are identified at an early age, modifications can be created to help with learning and ensuring a safe environment. Similar strategies for rehabilitation could be used for acquired and congenital forms of visual field loss, including mindfully placing objects in the field of good vision, optical enhancement, and computer training programs. However, patients with congenital field loss may not report as much improvement with various forms of rehabilitation if they have already developed their own strategy for compensation.

Further research is needed to develop rehabilitation strategies that will aid patients with inferior altitudinal visual field loss with their activities of daily living, to allow for safe reintegration into society.

REFERENCES

1. The Heart and Stroke Foundation. Statistics. 2014.
2. Nelson KB. Perinatal ischemic stroke. *Stroke*. 2007;38:742–5.
3. Canadian Stroke Network. The Quality of Stroke Care in Canada Canadian Stroke Network. 2011.
4. Raju TNK, Nelson KB, Ferriero D, et al. Ischemic perinatal stroke: summary of a workshop sponsored by the National Institute of Child Health and Human Development and the National Institute of Neurological Disorders and Stroke. *Pediatrics* 2007;120:609–16.
5. Hunt RW, Inder TE. Perinatal and neonatal ischaemic stroke: a review. *Thromb Res* 2006;118:39–48.
6. Lynch JK, Nelson KB. Epidemiology of perinatal stroke. *Curr Opin Pediatr* 2001;13:499–505.
7. Wu YW, Lynch JK, Nelson KB. Perinatal arterial stroke: understanding mechanisms and outcomes. *Semin Neurol* 2005;25:424–34.
8. Earley CJ, Kittner SJ, Feeser BR, et al. Stroke in children and sickle-cell disease: Baltimore-Washington Cooperative Young stroke study. *Neurology* 1998;51:169–76.
9. Govaert P, Ramenghi L, Taal R, et al. Diagnosis of perinatal stroke I: definitions, differential diagnosis and registration. *Acta Paediatr* 2009;98:1556–67.
10. Rowe FJ, Wright D, Brand D, et al. A prospective profile of visual field loss following stroke: prevalence, type, rehabilitation, and outcome. *Biomed Res Int* 2013;2013:1–12.
11. Zhang X, Kedar S, Lynn MJ, et al. Homonymous hemianopia in stroke. *J Neuroophthalmol* 2006;26:180–3.
12. Rowe F, Brand D, Jackson CA, et al. Visual impairment following stroke: do stroke patients require vision assessment? *Age Ageing* 2009;38:188–93.
13. Luu S, Lee AW, Daly A, et al. Visual field defects after stroke—a practical guide for GPs. *Aust Fam Physician* 2010;39:499–503.
14. Falke P, Abela BM, Krakau CE, et al. High frequency of asymptomatic visual field defects in subjects with transient ischaemic attacks or minor strokes. *J Intern Med* 1991;229:521–5.
15. Pambakian AL, Kennard C. Can visual function be restored in patients with homonymous hemianopia? *Br J Ophthalmol* 1997;81:324–8.
16. Trobe JD. Isolated Homonymous Hemianopia. *Arch Ophthalmol* 1973;89:377.
17. Margolis MT, Newton TH, Hoyt WF. Cortical branches of the posterior cerebral artery. Anatomic-radiologic correlation. *Neuroradiology* 1971;2:127–35.
18. Smith CG, Richardson WFG. The course and distribution of the arteries supplying the visual (striate) cortex. *American Journal of Ophthalmology* 1966;61:1391–6.
19. Francois J, Neetens A, Collette JM. Vascularization of the optic pathway. IV. Optic tract and external geniculate body. *Br J Ophthalmol* 1956;40:341–54.
20. Holt LJ, Anderson SF. Bilateral occipital lobe stroke with inferior altitudinal defects. *Optometry* 2000;71:690–702.
21. Brandt T, Steinke W, Thie A, et al. Posterior cerebral artery territory infarcts: clinical features, infarct topography, causes and outcome. *Cerebrovasc Dis* 2000;10:170–82.
22. Elbert T, Pantev C, Wienbruch C, et al. Increased cortical representation of the fingers of the left hand in string players. *Science* 1995;270:305–7.
23. Guzzetta A, D'Acunzio G, Rose S, et al. Plasticity of the visual system after early brain damage. *Dev Med Child Neurol* 2010;52:891–900.
24. Eysel U. Perilesional cortical dysfunction and reorganization. *Adv Neurol* 1997;73:195–206.
25. Sabel B, Kasten E, Kreutz M. Recovery of vision after partial visual system injury as a model of postlesion neuroplasticity. *Adv Neurol* 1997;73:251–76.
26. Mercuri E, Anker S, Guzzetta A, et al. Neonatal cerebral infarction and visual function at school age. *Arch Dis Child Fetal Neonatal Ed* 2003;88:F487–F491.
27. Van der Aa NE, Dudink J, Benders MJNL, et al. Neonatal posterior cerebral artery stroke: clinical presentation, MRI findings, and outcome. *Dev Med Child Neurol* 2013;55:283–90.
28. Seghier ML, Lazeyras F, Zimine S, et al. Visual recovery after perinatal stroke evidenced by functional and diffusion MRI: case report. *BMC Neurol* 2005;5:17.
29. Safran AB, Landis T. Plasticity in the adult visual cortex: implications for the diagnosis of visual field defects and visual rehabilitation. *Curr Opin Ophthalmol* 1996;7:53–64.

30. Darian-Smith C, Gilbert CD. Axonal sprouting accompanies functional reorganization in adult cat striate cortex. *Nature* 1994;368:737-40.
31. Darian-Smith C, Gilbert CD. Topographic reorganization in the striate cortex of the adult cat and monkey is cortically mediated. *J Neurosci* 1995;15(3 Pt 1):1631-47.
32. Das A, Gilbert CD. Long-range horizontal connections and their role in cortical reorganization revealed by optical recording of cat primary visual cortex. *Nature* 1995;375:780-4.
33. Leh SE, Pfito A, Schönwiesner M, et al. Blindsight mediated by an S-cone-independent collicular pathway: an fMRI study in hemispherectomized subjects. *J Cogn Neurosci* 2010;22:670-82.
34. Leh SE, Johansen-Berg H, Pfito A. Unconscious vision: new insights into the neuronal correlate of blindsight using diffusion tractography. *Brain* 2006;129(Pt 7):1822-32.
35. Johansson BB. Brain plasticity and stroke rehabilitation?: The Willis Lecture. *Stroke* 2000;31:223-30.
36. Peli E. Field expansion for homonymous hemianopia by optically induced peripheral exotropia. *Optom Vis Sci* 2000;77:453-64.
37. O'Neill EC, Connell PP, O'Connor JC, et al. Prism therapy and visual rehabilitation in homonymous visual field loss. *Opt Vis Sci* 2011;88:263-8.
38. Apfelbaum HL, Ross NC, Bowers AR, et al. Considering apical scotomas, confusion, and diplopia when prescribing prisms for homonymous hemianopia. *Trans Vis Sci Tech* 2013;2.
39. Giorgi RG, Woods RL, Peli E. Clinical and laboratory evaluation of peripheral prism glasses for hemianopia. *Optom Vis Sci* 2009;86:492-502.
40. Bowers AR, Keeney K, Peli E. Community-based trial of a peripheral prism visual field expansion device for hemianopia. *Arch Ophthalmol* 2008;126:657-64.
41. Rundquist J. Low vision rehabilitation of retinitis pigmentosa. *JVIB* 2004;98(11).
42. Pambakian AL, Wooding DS, Patel N, et al. Scanning the visual world: a study of patients with homonymous hemianopia. *JNNP* 2000;69:751-9.
43. Yevseyenkov V, Manastersky N, Jay WM. The role of low vision rehabilitation in neuro-ophthalmic disease. *Neuro-Ophthalmology* 2010; 34:331-41.
44. Bouwmeester L, Heutink J, Lucas C. The effect of visual training for patients with visual field defects due to brain damage: a systematic review. *JNNP* 2007;78:555-64.
45. Pollock A, Hazelton C, Henderson CA, et al. Interventions for visual field defects in patients with stroke. *Cochrane Data Syst Rev* 2011;(10):CD008388.

CO-MANAGEMENT: YOUR PATIENTS COME FIRST!

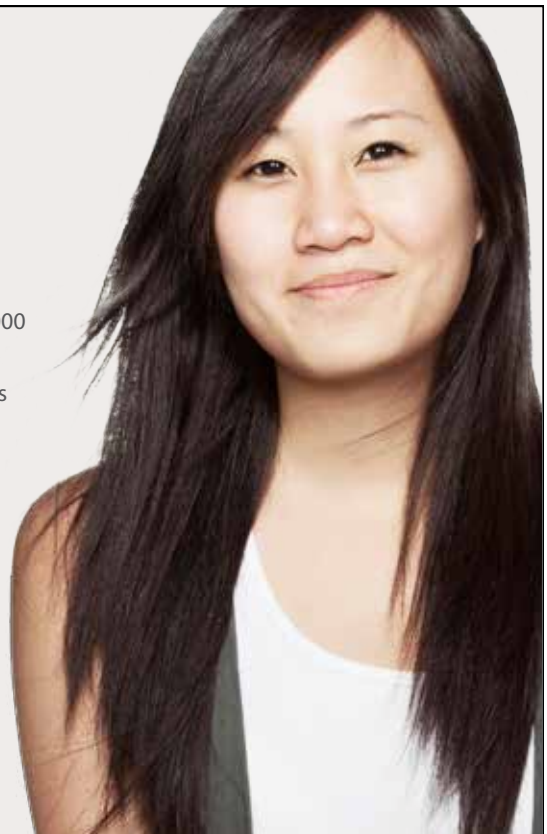Our Co-Management program offers many advantages:

- Over 30 clinics across Canada
- Experienced surgeons who have collectively performed over 750,000 procedures
- LASIK MD clinics annually perform over 60% of all laser vision correction procedures in Canada
- Affordable prices for your patients starting at \$490 per eye*
- More than 10 years experience

Direct access to our team: comanagement@lasikmd.com

Book your free consultation at 1-877-793-1515 or at lasikmd.com

LASIK MD
VISION



*Prices are subject to change without prior notice and vary based on prescription strength. Only applicable on a procedure for both eyes. Other conditions may apply.