

New Surgical Options in Glaucoma

Lisa V. Heckler, MD, FRCSC, Département d'ophtalmologie, Université de Montréal, Montreal, Quebec.

Michael W. Dorey, MD, FRCSC, Department of Ophthalmology and Visual Sciences, University of Alberta, Edmonton, Alberta.

Karim F. Damji, MD, FRCSC, MBA, Department of Ophthalmology and Visual Sciences, University of Alberta, Edmonton, Alberta.

Correspondence may be directed to: kdamji@ualberta.ca
2319, 10240 Kingsway Avenue NW, Edmonton, AB T5H 3V9 Canada

Abstract

The treatment of glaucoma is undergoing constant change. In the last decade, there has been a surge of novel surgical options that aim to lower intraocular pressure while providing improved safety profiles compared to traditional incisional glaucoma surgery. This article summarizes four such options—trabectome, iStent, canaloplasty and endocyclophotocoagulation—including descriptions of the procedures and evidence behind them.

Key Words: Micro-invasive glaucoma surgery, *ab interno* trabeculectomy, trabecular micro-bypass stent, canaloplasty, endocyclophotocoagulation

Résumé

Le traitement du glaucome est en constante évolution. Au cours de la dernière décennie, on a observé un afflux de nouvelles options chirurgicales qui visent à abaisser la pression intraoculaire tout en présentant une innocuité accrue par rapport à la chirurgie classique par incision. Cet article décrit quatre de ces options – atrabéculectomie endoculaire au Trabectome®, mise en place du micro-implant iStent®, canaloplastie et cyclophotocoagulation endoscopique –, y compris leur déroulement et les données qui les étayent.

Key Words: Chirurgie micro-invasive du glaucome, trabéculectomie endoculaire, micro-implant de dérivation trabéculaire, canaloplastie, cyclophotocoagulation endoscopique

Introduction

Glaucoma is the second leading cause of blindness globally after cataract.¹ Treatment of glaucoma aims to preserve visual function and maintain overall quality of life.² In Canada, a model of interprofessional collaboration between ophthalmologists and optometrists has been suggested.³ Management decisions are made based on the mechanism of glaucoma, the stage of disease, and the degree of intraocular pressure (IOP) elevation. Patients and care partners should be approached in an individualized manner, taking into account their biopsychosociospiritual (BPSS) profile and preferences.⁴ This approach considers various components of health, including systemic biology such as life expectancy, psychological factors, socioeconomic considerations, and spiritual/cultural values.

The standard treatment algorithm has typically employed medications, laser treatment, and eventually surgery. Medications available in Canada include single agents and combination agents involving prostaglandin analogues, beta-blockers, alpha-agonists, carbonic anhydrase inhibitors, and miotics. Laser treatment options include argon laser trabeculoplasty, selective laser trabeculoplasty, and in more severe cases cyclophotocoagulation. This paper discusses surgical options for glaucoma, in particular several newer and less invasive techniques. We will be focusing on the trabectome, iStent, and endocyclophotocoagulation, which are *ab interno* techniques, as well as canaloplasty, an *ab externo* technique. There are already several studies reviewing these techniques and any evidence supporting them, and we have referenced these works throughout this paper.⁵⁻⁷

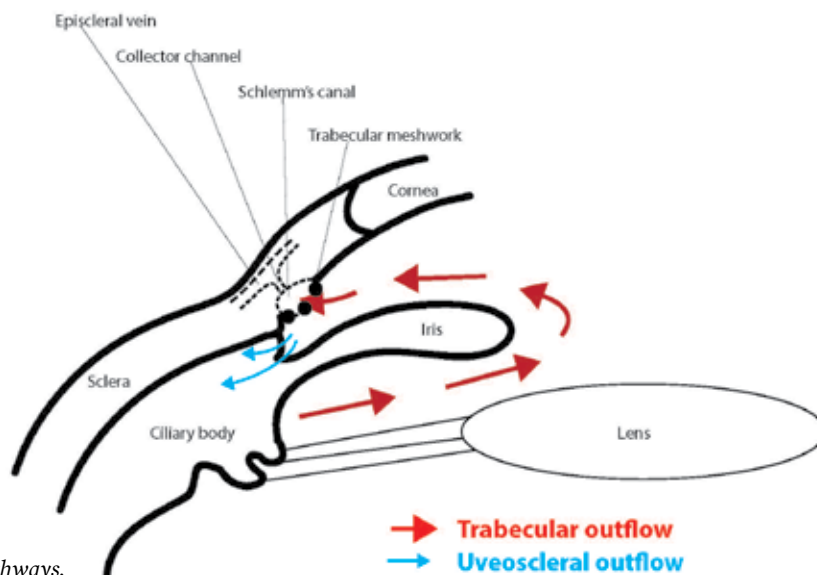


Figure 1. Aqueous outflow pathways.

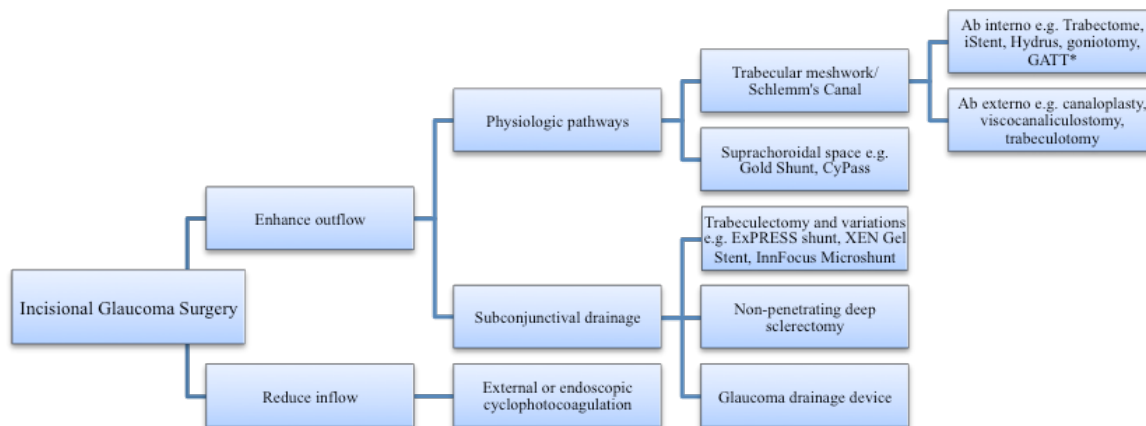


Figure 2. Classification of Incisional Glaucoma Surgery. * Gonioscopy-assisted transluminal trabeculotomy

Glaucoma Surgery: A Brief History

Since the 1950s, we have known that the major site of aqueous outflow resistance is the juxtacanalicular portion of the trabecular meshwork.⁸ Efforts were made as early as the 1950s to perforate this tissue with energy from light sources to allow for improved outflow.⁹ Moses studied microsurgical electro cautery techniques to the trabecular meshwork in enucleated eyes in 1971.¹⁰ Shortly thereafter, laser treatment of the trabecular meshwork became well studied and employed. Surgery to the angle has been well established in the congenital glaucoma population, but it was not until the last fifteen years that angle surgery in adults has come into favour.¹¹

A Review Of The Relevant Anatomy

The aqueous is produced by the ciliary processes and leaves the eye by two main pathways: the conventional or trabecular pathway,

accounting for 70–95% of aqueous egress from the eye, and the unconventional or uveoscleral outflow, accounting for the other 5–30% (see Figure 1).¹² The techniques described here will be focusing on the aqueous production and trabecular outflow. This consists of the trabecular meshwork, Schlemm’s canal, intrascleral channels, and the episcleral or conjunctival veins.

Classification Of Incisional Surgeries For Glaucoma

Incisional glaucoma surgery can be divided into procedures that reduce inflow of aqueous and procedures that enhance outflow (see Figure 2). Outflow procedures are the most common. Currently, trabeculectomy and glaucoma drainage devices remain the most frequently used techniques and several large-scale studies have demonstrated their efficacy.^{13–15} Over the last ten years, there has been a shift towards

alternative glaucoma surgeries, largely due to the high rate of complications associated with traditional glaucoma surgeries. These newer techniques have become known as “micro-invasive glaucoma surgery,” or MIGS, and play a different role in the glaucoma treatment algorithm.^{5,7,11}

Enhancing the Outflow Pathways: *Trabectome, iStent, and Canaloplasty Trabectome*

Description of the Procedure

The Trabectome (Neomedix Corp.) is composed of a disposable hand piece that supplies irrigation and aspiration and a tip that delivers high-frequency electro cautery. The hand piece is advanced across the anterior chamber through a temporal corneal incision towards the nasal angle with the irrigating fluid on. Under gonioscopic visualization, the footplate is inserted into the trabecular meshwork. The cautery is activated, and the surgeon advances the instrument in a clockwise and counterclockwise manner, thereby removing a 3–4 clock-hour arc of trabecular meshwork and the inner wall of Schlemm’s canal. This effectively creates a direct pathway for the aqueous to flow from the anterior chamber to the collector channels.⁶ The procedure is generally combined with cataract extraction, although there may be certain subgroups who do well with trabectome alone, such as exfoliation syndrome,¹⁶ and juvenile open angle glaucoma.¹⁷

The advantages of this procedure over traditional glaucoma surgeries include the faster recovery, due to the less invasive nature, the approach which leaves the conjunctiva intact for future surgeries, the lack of a filtering bleb, and the minimal added risk to the patient if combined with phacoemulsification.¹⁸ The disadvantages are that IOP lowering is generally not as substantial as it is with traditional glaucoma surgery, and there are some potential complications, the most common one being hyphema. This usually clears in a few days. Other complications include damage to the cornea, iris, or lens, as well as intraocular pressure elevation, but serious complications such as hypotony and suprachoroidal hemorrhage are very rare.¹⁹ Delayed hyphema has also been reported,²⁰ where blood refluxes through the trabectome cleft, which usually resolves within a few weeks but can recur.

Evidence

Several studies have evaluated the effectiveness of trabectome, the first ones being trabectome alone²¹ and later ones being trabectome combined with phacoemulsification.²² The first large study was a noncomparative prospective case series of 304 eyes with open-angle glaucoma undergoing trabectome combined with cataract extraction.²² Mean baseline IOP of 20

mmHg decreased at 12 months to 15.5 mmHg, and medications decreased from 2.65 to 1.76. Secondary glaucoma procedures were performed in 9 patients. A retrospective review of 88 cases of trabectome alone and 158 cases of combined trabectome and cataract from the Mayo Clinic, found a reduction in mean IOP from 21.6 mmHg to 15.3 mmHg and a decrease in number of glaucoma medications from 3.1 to 1.9 at 2 years. However, subsequent glaucoma surgery was required in 66 patients (26.8%), an average of 10 months after surgery.²³ The weakness of these studies is the lack of a comparison (e.g. phacoemulsification alone) to prove the effectiveness of the procedure, since prior studies have demonstrated the IOP-lowering benefit of phacoemulsification alone.^{24,25}

iStent

Description of the Procedure

The Glaukos micro-bypass trabecular iStent (Glaukos Corp.) is the smallest medical device to be implanted in the human body. It is made of nonferromagnetic heparin coated titanium and consists of an inlet (“snorkel”) connected at a right angle to the implantable portion (see Figure 3).⁶ The preloaded iStent inserter is advanced across the anterior chamber through a temporal corneal incision under gonioscopic visualization towards the nasal angle. The sharp tip of the iStent is used to engage and perforate the trabecular meshwork, and the stent then slides into the Schlemm canal. The device is then released from the inserter. Usage of the iStent has been studied in combination with cataract extractions. The advantages of the iStent are similar to the trabectome in terms of minimizing ocular tissue damage, and possibly lower risk of complications.²⁶

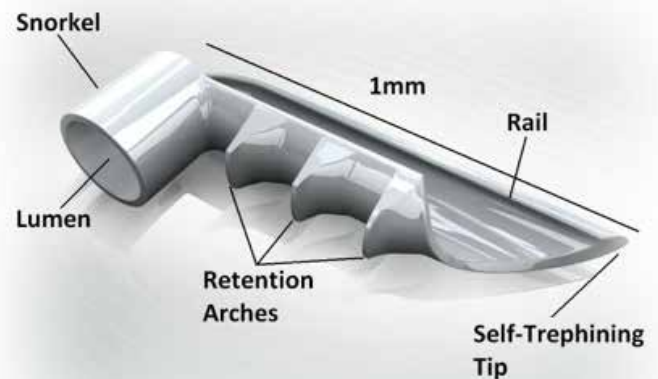


Figure 3. *iStent Trabecular Microbypass Stent.*
Courtesy of Glaukos Corporation, Laguna Hills, California, USA.

Evidence

Initial studies reported the use of a single iStent per eye, though subsequent studies found multiple stents to be more effective.²⁷ Spiegel et al. reported the successful use of the iStent in 2008 in a prospective, multicenter noncomparative interventional trial.²⁸ Since then, further validation has arisen from randomized control trials comparing phacoemulsification alone to phacoemulsification with iStents.^{29–31} In the two-year follow-up paper by the iStent Study Group, 240 eyes with mild to moderate glaucoma were randomized to receive one iStent combined with phacoemulsification or phacoemulsification alone. At both one and two years, the proportion of patients with unmedicated IOP of 21 or less was significantly higher in the iStent group.³¹ Amount of hypotensive medications were lower in the stent group at one year, but this did not reach statistical significance at two years. Complication rate was similar between the two groups, and there were no stent-related adverse effects reported after two years. More recently, Ahmed et al. evaluated the use of two iStents combined with travaprost post-operatively, to improve both conventional trabecular and uveoscleral outflow in 39 open angle glaucoma patients uncontrolled on two medications. Mean IOP decreased from 22.2 mmHg to 11.8 mmHg at 18 months, from two medications pre-operatively to one medication post-operatively.³²

Further expansion of the iStent's role and its long-term efficacy are yet to be determined. Some authors have suggested it may play a limited role in select patients with advanced disease or even prior filtering surgery.^{33,34}

Canaloplasty

Description of the Procedure

This technique is similar in concept to viscocanalostomy, which involves the creation of a deep sclerectomy followed by injection of viscoelastic into Schlemm's canal. In canaloplasty, a superficial and then deeper scleral flap is created, so that Schlemm's canal can be reached. The canaloplasty device (Ellex) contains a fiber optic light catheter that is then inserted into one end of the open Schlemm's canal. This is threaded around the canal for 360 degrees, with the aid of the light, such that a false passage is not created, until it exits from the other opening in Schlemm's canal. A prolene suture is then attached to the distal end of the catheter, and the catheter is withdrawn, thereby threading the suture through the canal. The ends of the suture are tied to distend the trabecular meshwork.

The advantages of this procedure are that it does not require a filtering bleb, though occasionally one forms,³⁵ and it has less complications compared to conventional trabeculectomy. The

disadvantages are that the learning curve is long, in some cases it is impossible to cannulate Schlemm's canal, and the IOP-lowering effect is not as dramatic as trabeculectomy.³⁶ It is also more invasive than the MIGS procedures, as it disrupts conjunctiva, although *ab interno* approaches are now also being explored.

Evidence

In a nonrandomized multicentre trial, Lewis et al. reported the three-year results of 157 patients undergoing canaloplasty or combined canaloplasty-cataract surgery.³⁵ Baseline IOP of 28.5 mmHg reduced to 15.2 mmHg, and medications decreased from 1.8 to 0.8. Most complications occurred intraoperatively or in the early post-operative period, including partial suture extrusion through the trabecular meshwork, Descemet's detachment, hyphema, and IOP elevation.

Brüggemann et al. also compared canaloplasty to trabeculectomy.³⁷ In this study of 15 patients with prior trabeculectomy in one eye, the contralateral eye underwent canaloplasty, and 6- and 12-month results were compared. Both procedures reduced the IOP significantly; however, the trabeculectomy group achieved lower IOP (11.64 vs. 13.21 mmHg), was on no medication, and required fewer additional interventions. However, they required longer initial hospitalization and more post-operative visits.

Reducing Inflow: Endoscopic Cyclophotocoagulation

Description of the Procedure

Cyclophotocoagulation was first used in the 1970s to lower intraocular pressure. It is usually done through a contact approach delivered over the area of the ciliary body, thereby reducing aqueous production. It is generally left as a last-resort to treat end-stage glaucoma due to its unpredictability and

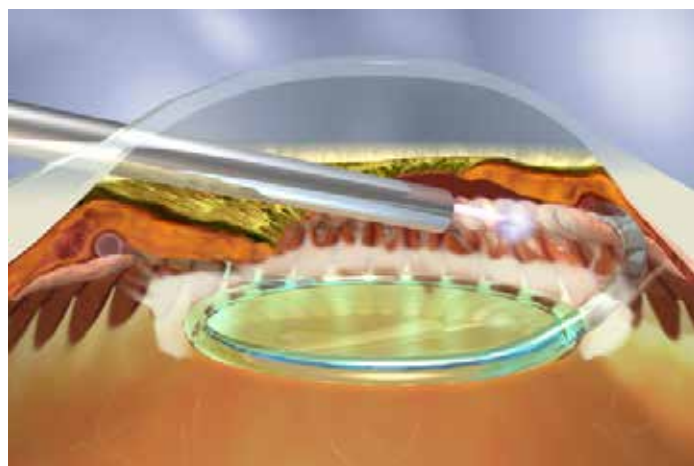


Figure 4. : Endoscopic Cyclophotocoagulation of the Ciliary Processes. Courtesy of Endo Optiks, Inc., Little Silver, New Jersey, USA.

possibility of complications like phthisis.³⁸ In 1992, however, Uram described the use of photocoagulation delivered to the ciliary body under direct visualization with endoscopy.³⁹

Endoscopic cyclophotocoagulation (ECP) has been used in several different types of glaucoma, including primary open angle, neovascular glaucoma, chronic angle closure, uveitic, angle recession,³⁸ and a less destructive version in plateau iris syndrome.⁴⁰ The laser unit contains a probe to deliver the diode laser that has a built-in endoscope and attached camera monitor. When this is combined with phacoemulsification, the ECP is generally done before or after the lens is inserted. The probe is inserted through a corneal incision and directed behind the iris until the ciliary processes come into view on the camera monitor. The laser is then fired with a foot pedal and the desired outcome is a whitening of the ciliary processes (see Figure 4). This treatment can be done for a circumference of 90–360 degrees, and a second incision may be required.³⁸

Evidence

A retrospective review of 368 eyes that underwent phacoemulsification combined with ECP found a 10.9 mmHg drop in IOP at two years post-operatively, with a mean decrease in number of medications of 1.1.⁴¹ The largest published study, by the same group, was a retrospective review of 539 patients.⁴² All eyes had at least one prior glaucoma surgery and IOP \geq 35 on maximal medical therapy or advanced glaucoma with IOP above target. The mean IOP decreased from a baseline of 38 mmHg to 12.1 mmHg, and an average number of medications of 1.9, after 5 years. Prospective studies have also evaluated the use of ECP. In a randomized trial, Gayton et al. compared ECP to trabeculectomy and found a 29% reduction in IOP after ECP vs. 32% following trabeculectomy, with similar baseline IOP of 25 mmHg.⁴³ Francis et al. evaluated ECP use after failed aqueous shunts. Twenty-five eyes received ECP for 360 degrees.⁴⁴ Success, defined as reduction in IOP of 3 mmHg and discontinuation of nontolerated glaucoma medications, was achieved in 88% of patients up to two years follow up. Murthy et al. studied 50 eyes of Indian patients with refractory glaucoma, including phakic, pseudophakic and phakic patients, in a prospective non-comparative study.⁴⁵ IOP decreased from 32.58 mmHg to 13.96 mmHg, with an average follow up of about one year. The average number of glaucoma medications decreased from 2.51 to 1.09.

How To Choose Which Procedure To Use On Each Patient?

The decision to proceed with glaucoma surgery is a complex one that should take into account different ocular and systemic

factors. In the Canadian model, where optometrists and ophthalmologists work together in the best interest of patients, effective and timely communication is essential.^{3,46} Treatment of glaucoma and glaucoma suspects is well summarized in the Canadian Ophthalmological Society evidence-based clinical practice guidelines for the management of glaucoma in the adult eye.² Indications for surgery include situations where other methods of lowering IOP have been unsuccessful and the optic nerve is failing or likely to fail. Furthermore, surgery should be considered when patients are intolerant to and/or non-compliant with medications. Referral to an ophthalmologist when progression is suspected is crucial in preventing glaucoma-related blindness.

The indications for some of the novel glaucoma surgeries described here are currently in evolution. The procedures that act by increasing outflow (trabectome, iStent, canaloplasty) have primarily been studied in the context of mild to moderate glaucoma and are usually combined with cataract surgery. Since they generally do not lower IOP to a level as low as traditional surgery, the authors favour their use in situations where there is a visually significant cataract and early or moderate glaucoma where the IOP is above target. ECP, however, may be a good option in more advanced or refractory glaucoma based on the available literature.

Other factors that might encourage a surgeon to proceed with a MIGS over a trabeculectomy or tube shunt include poor conjunctival or scleral tissue, where a trabectome or iStents would be safer than an external surgery, as well as risk factors for over-filtration (e.g. myopia) or suprachoroidal hemorrhage (e.g. older age, presence of hypertension, use of anticoagulants). Fortunately, most MIGS procedures do not seem to affect the future outcome of traditional glaucoma surgery.⁴⁷ Finally, patients and care partners should be involved in the discussion and decision-making regarding treatment.

Post-Operative Care

Post-operative care for microinvasive glaucoma surgeries is similar to post-operative cataract care; however, there are several added complications that should be watched for. Uveitis may be more prominent due to the added intraocular manipulation, in particular with ECP.³⁸ This can usually be managed with steroid drops and/or non-steroidal agents, especially to reduce the risk of cystoid macular edema. Hyphema or microhyphema is not uncommon and can be treated conservatively with steroid drops, reduced level of activity, and elevation of the head. If a hyphema is large (i.e. over one-half of the anterior chamber), not clearing after two weeks, or associated with elevated intraocular pressure,

consideration should be given to a surgical washout.

Intraocular pressure elevation may occur, with early pressure rise likely due to inflammation and later rise more likely from steroid usage, particularly after trabectome (author's personal experience) or iStent surgery.⁴⁸ The management of these two situations, therefore, differs. If the inflammatory response seems prominent, steroids should be increased; however, if steroid-induced pressure elevation is suspected and inflammation is minimal, lower-potency steroids or non-steroidal agents should be used and rapidly tapered off.

Since some of these procedures include the insertion of a device, there is also the potential for such device-related complications as obstruction or malposition, though these risks are low.⁵ Gonioscopy may be necessary to identify these issues. Finally, as is the case with all glaucoma surgeries, the pressure control may decrease or fail over time, at which point other methods must be employed (drops, laser, further surgery).

Conclusion And Summary

Surgical care of glaucoma is undergoing some major paradigm shifts. Larger scale randomized control trials will be important in better defining the role of MIGS in the treatment algorithms. Other MIGS procedures not discussed here have also been described, including Hydrus, CyPass, iStent inject (second-generation iStent), as well as other newer surgical treatments such as the Gold shunt. Finally, modifications of conventional surgeries have been studied and employed by many, including the Ex-PRESS Glaucoma Filtration Device (Alcon, Inc.), as an additive device to traditional trabeculectomy surgery. With continued collaboration among eye care specialists, individualized glaucoma care is becoming a reality.

References

- Resnikoff S, Pascolini D, Etya'ale D, et al. Global data on visual impairment in the year 2002. *Bull World Health Organ* 2004;82:844–51.
- Canadian Ophthalmological Society Glaucoma Clinical Practice Guideline Expert Committee, Canadian Ophthalmological Society. Canadian Ophthalmological Society evidence-based clinical practice guidelines for the management of glaucoma in the adult eye. *Can J Ophthalmol* 2009;44(Suppl 1):S7–S93.
- Canadian Glaucoma Society Committee on Interprofessional Collaboration in Glaucoma Care. Model of interprofessional collaboration in the care of glaucoma patients and glaucoma suspects. *Can J Ophthalmol* 201;46(6 Suppl):S1–S21.
- Gessesse GW, Damji KF. Advanced glaucoma: management pearls. *Middle East Afr J Ophthalmol* 2013;20:131–41.
- Saheb H, Ahmed II. Micro-invasive glaucoma surgery: current perspectives and future directions. *Curr Opin Ophthalmol* 2012;23:96–104.
- Francis BA, Singh K, Lin SC, et al. Novel glaucoma procedures: a report by the American Academy of Ophthalmology. *Ophthalmology* 2011;118:1466–80.
- SooHoo JR, Seibold LK, Radcliffe NM, et al. Minimally invasive glaucoma surgery: current implants and future innovations. *Can J Ophthalmol* 2014;49:528–33.
- Grant WM. Facilities of flow through the trabecular meshwork. *Arch Ophthalmol* 1955;54:245–8.
- Van Buskirk EM, Shields MB. 100 Years of Progress in Glaucoma. Philadelphia: Lippincott-Raven; 1997.
- Moses RA. Electrocautery puncture of the trabecular meshwork in enucleated human eyes. *Am J Ophthalmol* 1971;72:1094–6.
- Kahook MY, Salim S, Seibold LK. MIGS: Advances in Glaucoma Surgery. Thorofare: SLACK Inc.; 2014.
- Allingham RR, Damji KF, Freedman S, et al. Shields Textbook of Glaucoma. 6th ed. Philadelphia: Lippincott Williams & Wilkins; 2011.
- AGIS Investigators. The Advanced Glaucoma Intervention Study (AGIS): 9. Comparison of glaucoma outcomes in black and white patients within treatment groups. *Am J Ophthalmol* 2001;132:311–20.
- Musch DC, Gillespie BW, Niziol LM, et al. CIGTS Study Group. Intraocular pressure control and long-term visual field loss in the Collaborative Initial Glaucoma Treatment Study. *Ophthalmology* 2011;118:1766–73.
- Gedde SJ, Schiffman JC, Feuer WJ, et al. Three-year follow-up of the tube versus trabeculectomy study. *Am J Ophthalmol* 2009;148:670–84.
- Ting JL, Damji KF, Stiles MC, et al. Ab interno trabeculectomy: outcomes in exfoliation versus primary open-angle glaucoma. *J Cataract Refract Surg* 2012;38:315–23.
- Damji KF, Arora S, Masahiro M, et al. Efficacy and Safety of Ab Interno Trabeculectomy with Trabectome in Juvenile Open Angle Glaucoma (JOAG). Presented at: American Glaucoma Society (AGS) Annual Meeting; 2013 Feb 28–Mar 3; San Francisco, CA.
- Filippopoulos T, Rhee DJ. Novel surgical procedures in glaucoma: advances in penetrating glaucoma surgery. *Curr Opin Ophthalmol* 2008;19:149–54.
- Minckler D, Mosaed S, Dustin L, et al. Trabectome (trabeculectomy-internal approach): additional experience and extended follow-up. *Trans Am Ophthalmol Soc* 2008;106:149–59; discussion; pp. 159–60.
- Ahuja Y, Malihi M, Sit AJ. Delayed-onset symptomatic hyphema after ab interno trabeculectomy surgery. *Am J Ophthalmol* 2012;154:476–80.e2.
- Minckler D, Baerveldt G, Ramirez MA, et al. Clinical results with the Trabectome, a novel surgical device for treatment of open-angle glaucoma. *Trans Am Ophthalmol Soc* 2006;104:40–50.
- Francis BA, Minckler D, Dustin L, et al. Combined cataract extraction and trabeculectomy by the internal approach for coexisting cataract and open-angle glaucoma: initial results. *J Cataract Refract Surg* 2008;34:1096–103.
- Ahuja Y, Ma Khin Pyi S, Malihi M, et al. Clinical results of ab interno trabeculectomy using the trabectome for open-angle glaucoma: the Mayo Clinic series in Rochester, Minnesota. *Am J Ophthalmol* 2013;156:927–35.e2.
- Mathalone N, Hyams M, Neiman S, et al. Long-term intraocular pressure control after clear corneal phacoemulsification in glaucoma patients. *J Cataract Refract Surg* 2005;31:479–83.
- Damji KF, Konstas AG, Liebmann JM, et al. Intraocular pressure following phacoemulsification in patients with and without exfoliation syndrome: a 2 year prospective study. *Br J Ophthalmol* 2006;90:1014–8.
- Kurji K, Arora S, Rudnisky CJ, et al. Phaco-Trabectome vs. Phaco-iStent in Patients with Open-Angle Glaucoma. Poster session presented at: American Academy of Ophthalmology (AAO) Annual Meeting; 2013 Nov 16–19; New Orleans, LA.
- Belovay GW, Naqi A, Chan BJ, et al. Using multiple trabecular micro-bypass stents in cataract patients to treat open-angle glaucoma. *J Cataract Refract Surg* 2012;38:1911–7.
- Spiegel D, Garcia-Feijoo J, Garcia-Sanchez J, et al. Coexistent primary open-angle glaucoma and cataract: preliminary analysis of treatment by cataract surgery and the iStent trabecular micro-bypass stent. *Adv Ther* 2008;25:453–64.
- Fea AM. Phacoemulsification versus phacoemulsification with micro-bypass stent implantation in primary open-angle glaucoma: randomized double-masked clinical trial. *J Cataract Refract Surg* 2010;36:407–12.
- Samuelson TW, Katz LJ, Wells JM, US iStent Study Group, et al. Randomized evaluation of the trabecular micro-bypass stent with phacoemulsification in patients with glaucoma and cataract. *Ophthalmology* 2011;118:459–67.

31. Craven ER, Katz LJ, Wells JM, iStent Study Group, et al. Cataract surgery with trabecular micro-bypass stent implantation in patients with mild-to-moderate open-angle glaucoma and cataract: two-year follow-up. *J Cataract Refract Surg* 2012;38:1339–45.
32. Ahmed II, Katz LJ, Chang DF, et al. Prospective evaluation of microinvasive glaucoma surgery with trabecular microbypass stents and prostaglandin in open-angle glaucoma. *J Cataract Refract Surg* 2014;40:1295–300.
33. Arora S, Rudnisky C, Kurji K, et al. Phaco-Trabecular Micro-Bypass Stent in Management of Patients with Advanced Open-Angle Glaucoma. Paper presentation at: American Society of Cataract and Refractive Surgery (ASCRS) Symposium and Congress; 2014 Apr 25–29; Boston (MA); poster presentation at: American Glaucoma Society (AGS) Annual Meeting; 2014 Feb 22–Mar 2; Washington, (DC).
34. Roelofs K, Arora S, Dorey MW. Implantation of 2 trabecular microbypass stents in a patient with primary open-angle glaucoma refractory to previous glaucoma-filtering surgeries. *J Cataract Refract Surg* 2014;40:1322–4.
35. Lewis RA, von Wolff K, Tetz M, et al. Canaloplasty: three-year results of circumferential viscodilation and tensioning of Schlemm canal using a microcatheter to treat open-angle glaucoma. *J Cataract Refract Surg* 2011;37:682–90.
36. Brusini P. Canaloplasty in open-angle glaucoma surgery: a four-year follow-up. *ScientificWorldJournal* 2014 Jan 16;2014:469609.
37. Bruggemann A, Despouy JT, Wegent A, et al. Intraindividual comparison of Canaloplasty versus trabeculectomy with mitomycin C in a single-surgeon series. *J Glaucoma* 2013;22:577–83.
38. Kaplowitz K, Kuei A, Klenofsky B, et al. The use of endoscopic cyclophotocoagulation for moderate to advanced glaucoma. *Acta Ophthalmol* 2015;93:395–401.
39. Uram M. Ophthalmic laser microendoscope ciliary process ablation in the management of neovascular glaucoma. *Ophthalmology* 1992;99:1823–8.
40. Podbielski DW, Varma DK, Tam DY, et al. Endocycloplasty – a new technique for managing angle-closure glaucoma secondary to plateau iris syndrome. *Glaucoma Today* 2010;29–31.
41. Lima FE, Carvalho DM, Avila MP. Phacoemulsification and endoscopic cyclophotocoagulation as primary surgical procedure in coexisting cataract and glaucoma. *Arq Bras Oftalmol* 2010;73:419–22.
42. Lima FE, Neto JB, Toscano D, et al. Endoscopic cyclophotocoagulation in refractory glaucomas: a long-term study. *Rev Bras Oftalmol* 2009;68:146–51.
43. Gayton JL, Van Der Karr M, Sanders V. Combined cataract and glaucoma surgery: trabeculectomy versus endoscopic laser cycloablation. *J Cataract Refract Surg* 1999;25:1214–9.
44. Francis BA, Kawji AS, Vo NT, et al. Endoscopic cyclophotocoagulation (ECP) in the management of uncontrolled glaucoma with prior aqueous tube shunt. *J Glaucoma* 2011;20:523–7.
45. Murthy GJ, Murthy PR, Murthy KR, et al. A study of the efficacy of endoscopic cyclophotocoagulation for the treatment of refractory glaucomas. *Indian J Ophthalmol* 2009;57:127–32.
46. Eye Health Council of Ontario. EHCO Glaucoma Guidelines [pdf. through the Internet]. c2013 Feb Available from c2-preview.prosites.com/199272/wy/docs/EHCO%20Glaucoma%20Guidelines.27Feb2013.Final.pdf. Accessed 2014 Dec 7.
47. Jea SY, Mosaed S, Vold SD, et al. Effect of a failed trabectome on subsequent trabeculectomy. *J Glaucoma* 2012;21:71–5.
48. Le K, Saheb H. iStent trabecular micro-bypass stent for open-angle glaucoma. *Clin Ophthalmol* 2014;8:1937–45.

CO-MANAGEMENT: YOUR PATIENTS COME FIRST!

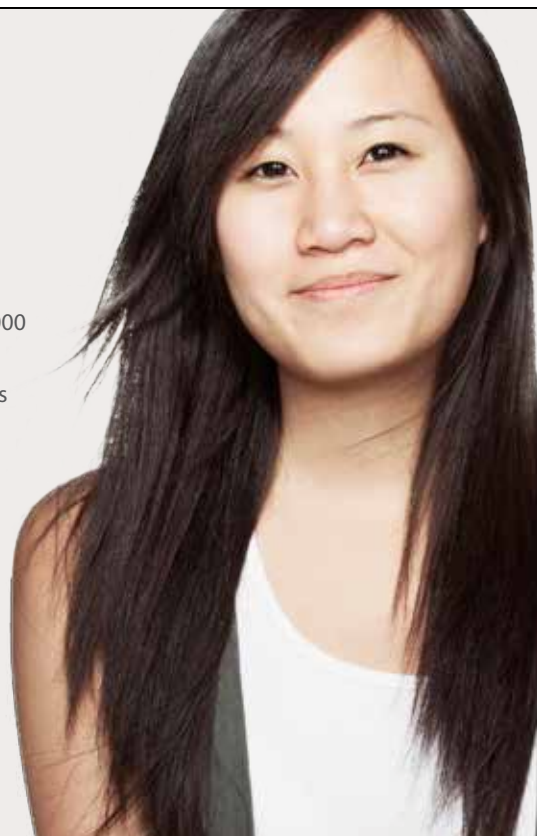Our Co-Management program offers many advantages:

- 30 clinics across Canada
- LASIK MD annually performs over 60% of all laser vision correction procedures in Canada
- More than 10 years of experience
- Experienced surgeons who have collectively performed over 750,000 procedures[†]
- Affordable prices for your patients starting at \$490 per eye*

Direct access to our team: comanagement@lasikmd.com

Book your free consultation at 1-877-793-1515 or at lasikmd.com

LASIK MD
VISION



[†]Based on the collective experience of all LASIK MD surgeons. *Prices are subject to change without prior notice and vary based on prescription strength. Only applicable on a procedure for both eyes. Other conditions may apply.