

Dietary Lutein Attenuates Bleomycin-Induced Pulmonary Fibrosis in Mice

Shanmuga Reddy Chilakapati^{1, 2}, Mamatha. Serasanambati^{1, 2}, Pavan Kumar¹, Manikonda¹, Jagadeeswara Reddy. Kanala^{1*}

*Corresponding author:

Reddy. Kanala

¹Sugen Life Sciences Pvt Ltd,
S.V.Nagar, Perumall Palli, India,
Tirupati-517 505

²Sri Venkateswara University,
Department of Biochemistry, India,
Tirupati- 517 502

A b s t r a c t

Idiopathic Pulmonary Fibrosis is a chronic lung disease characterized by lung inflammation and progression to fibrosis. Anti-fibrotic efficacy of lutein was studied in mouse model of bleomycin induced pulmonary fibrosis. The mice were orally administrated with 100 or 200 mg/kg of lutein three days prior to intra-tracheal instillation of bleomycin on day 0 and continued up to day 21. Total cell counts and protein levels in bronchoalveolar lavage fluid and superoxide dismutase, and hydroxyproline levels were evaluated. Treatment with lutein at 100 and 200 mg/kg prevented bleomycin induced mortality and body weight loss. Lutein administration attenuated bleomycin induced increase of total and differential cell count and myeloperoxidase, inflammatory cell infiltration in lung tissue. Similarly lutein administration restored superoxide dismutase activity lowered by bleomycin instillation. The combined results revealed the protective effect of lutein by suppressing the inflammation, oxidative stress and enhancing the antioxidant potential which may helps in pulmonary fibrosis.

Keywords: Bronchoalveolar lavage fluid, C57BL/6J mice, hydroxyproline, lutein, inflammation, oxidative stress, superoxide dismutase

Introduction

Idiopathic Pulmonary Fibrosis (IPF) is a chronic diffuse interstitial lung disease characterized by inflammation and fibrosis in lung parenchyma cells [1- 2]. The disease prevalence is estimated to be in the range of 3-5 per 100,000 people and the mean survival after diagnosis of the disease is 2.8-4.2 years [3]. Previous studies reported higher estimates of 20 per 100,000 males and 13 per 100,000 females based on an Interstitial Lung Registry in Bernalillo County, New Mexico [4]. The process of fibrosis is dynamic, which involves infiltration of leukocytes, activation and proliferation of fibroblasts and accumulation of extracellular matrix proteins due to repeated and/or aberrant repair events leading to impaired gas exchange and respiratory failure [4-5]. Further, lung injury and inflammation is caused by the reactive oxygen species (ROS) which are released from activated leukocytes [6]. ROS and activated cytokines, especially transforming growth factor (TGF)- β 1, stimulate the abnormal wound repair and remodeling of lung by accumulation of collagen [7-8]. TGF- β 1 stimulates the production of interstitial collagen through both activation of fibroblasts and transformation of fibroblasts to collagen producing myofibroblasts [9]. Although etiology of IPF is not known, cigarette smoking, environmental factors, infectious agents and exposure to certain chemotherapeutic drugs like bleomycin, etc. are some of the factors that cause IPF [10]. Since pulmonary fibrosis symptoms were observed in humans treated with bleomycin for various cancers, a number of studies have employed bleomycin-induced mice model for characterizing IPF [11]. Intra-tracheal administration

of bleomycin in rodents has become the most widely used experimental model of lung fibrosis, which mimics the inflammatory and fibrotic events to human IPF [12]. The current treatment using corticosteroids and cytotoxic agents has not improved the prognosis of the disease [13]. Hence, an alternative strategy to develop safe, affordable, effective and economically feasible drugs such as natural products and/or dietary supplements is required for the treatment of IPF. It is well known that naturally available hydroxyl carotenoid, lutein, which is found in dark green leafy vegetables such as kale and spinach, has shown neuro-protective effect during retinal inflammation [14], atherosclerosis [15], endotoxin-induced uveitis [16] and cerebral ischemia/reperfusion injury [17]. Further, lutein in combination with zeaxanthine protects the eye cortex in age-related macular degeneration [18]. In addition, lutein acts as strong antioxidant due to the presence of hydroxyl group attached at either end of the molecule, capable of strong reaction with singlet oxygen than other carotenoids [19]. In a recent study, the antioxidant role of lutein was elucidated in lipopolysaccharide-induced uveitis in mice [19]. As imbalance in redox equilibrium and inflammation are contributing factors in pathogenesis of pulmonary fibrosis, we hypothesized that administration of lutein may alleviate the effect of pulmonary fibrosis. Hence, the present study is designed to investigate the effect of lutein on bleomycin-induced pulmonary fibrosis in mice.

Materials and Methods

Reagents



Bleomycin sulfate and lutein were purchased from Sigma, St. Louis, USA. All other chemicals used in the present study were purchased from Hi-Media (Mumbai, India).

Experimental Animals and Dosing

A healthy female, pathogen free, C57BL/6J mice weighing 20-23g were purchased from National Institute of Nutrition (Hyderabad, India). All the animals were housed in polypropylene cages in pathogen-free experimental rooms, and were maintained at 22±3°C and relative humidity of 55±6%. Food and water were provided *ad libitum*. All experiments were performed in accordance with the Institutional Animal Ethics Committee. After randomization, the animals were divided into four groups (n=15 in each group) and anesthetized with intra-peritoneal injections of ketamine and xylazine (100 and 10 mg/kg body weight). Using aseptic techniques, a single incision was made at the neck, and the muscle covering the trachea was snipped to expose the tracheal rings. A single intratracheal instillation of 0.05 U bleomycin sulfate in 50 µl of sterile 0.9% NaCl saline was performed using a 27-gauge needle for groups II, III and IV. Group I animals administered orally with 0.5% carboxy methyl cellulose (CMC) three days prior to saline instillation. Group II animals administered CMC, while group III and IV animals orally administered with lutein at 100 and 200 mg/kg in CMC respectively three days before the instillation of bleomycin. Either CMC or lutein administration continued daily for 21 days. Appropriate numbers of mice were sacrificed on days 7 and 21 after bleomycin administration. Bronchoalveolar lavage fluid (BALF) was collected for cell and protein analysis. Right lung was excised and stored at -80°C for biochemical assays and left lung was collected and stored in 10% neutral buffered formalin for histological analysis.

BALF Cell Analysis

Mice were euthanized on day 7 and the trachea was cannulated with intravenous polyethylene catheter equipped with 24-gauge needle attached to 1 mL syringe. The lungs were lavaged for four times with 0.8 mL of phosphate buffered saline pH 7.4 (PBS) each and withdrawn from the lungs via an intratracheal cannula. The lavage fluids were pooled and centrifuged at 1000 rpm for 10 min at 4°C. Total protein levels in supernatants were determined by Bradford's reagent. Total cells present in pellet were enumerated using trypan blue stain. Differential counting was performed using 5% Giemsa stain by counting at least 400 cells from randomly chosen areas for each sample and the results were expressed as total number of cells/mL [20].

Analysis of Inflammatory Cell Infiltration and Severity of Fibrosis in Lung Tissues Using Histological Assessment

The animals were euthanized by CO₂ asphyxiation on 7th and 21st day after bleomycin instillation and lung tissues were collected. Tissues were fixed for one week in 10% (w/v) PBS-buffered formaldehyde solution at room temperature, dehydrated using

graded alcohol and embedded in paraffin wax. After tissues were embedded in paraffin the tissue sections were prepared and stained with hematoxylin and eosin for morphometric analysis. In addition, trichrome and picosirus red staining was performed for assessing the severity of fibrosis. The lung tissue sections were captured using light microscope (Olympus, C-7070, Japan). The severity of fibrosis was semi-quantitatively assessed as described earlier [21]. The grade of pulmonary fibrosis was scored on a scale of 0 to 8 by examining the randomly chosen sections at 40X-magnification. The grading of pulmonary fibrosis was based on the following criteria: 0-normal lung; 1-minimal fibrous thickening of alveolar or bronchial walls; 3-moderate thickening of walls without obvious damage to lung architecture; 5-increased fibrosis with definite damage to lung structure and formation of fibrous bands or small fibrous masses; 7-severe distortion of structure and large fibrous areas and 8-total fibrous obliteration of the fields.

Myeloperoxidase Assay (MPO)

Tissue homogenates (10%) were prepared in 50 mM phosphate buffer (pH 6) containing 0.5% of hexadecyl trimethyl ammonium bromide and centrifuged at 20,000xg for 20 min at 4°C. The change in optical density (OD) in the reaction mixture (3 mL) containing 0.1 mL of the supernatant, 0.167 mg/mL O-dianisidine hydrochloride and 0.0005% of hydrogen peroxide was measured for 5 min at 465 nm in UV-Vis spectro photometer (Shimadzu, Japan). One unit of MPO activity is defined as enzyme that degrades 1 µmole of peroxide/min at 25°C. Results were expressed as milli units/g tissue [22].

Collagen Assay

The collagen levels in lung tissues were determined by SIRCOL collagen assay (Biocolor Ltd., UK) according to the manufacturer's instructions. Briefly, lungs were diced and washed in cold PBS. The samples were subjected to acid-pepsin extraction at 4°C. Acid extracts were incubated with sirius red dye and absorbance was determined at 540 nm in UV-Visible spectrophotometer (Shimadzu, Japan).

Superoxide Dismutase Assay (SOD)

SOD activity was estimated using 10% homogenates by determining the enzyme ability to inhibit superoxide anion dependent pyrogallol autoxidation [16]. The increase in OD was measured in reaction mixture (3 mL) containing cytosolic extracts (400 µg of protein), 50 mM Tris (pH 8.0) 10 mM diethylamine triamine pentaacetic acid and 10 mM pyrogallol for 3 min at 420 nm with UV Visible spectrometer (Shimadzu, Japan). One unit of OD represents the amount of SOD inhibits 50% pyrogallol auto oxidation per min. Results were expressed as units/g tissue [23].

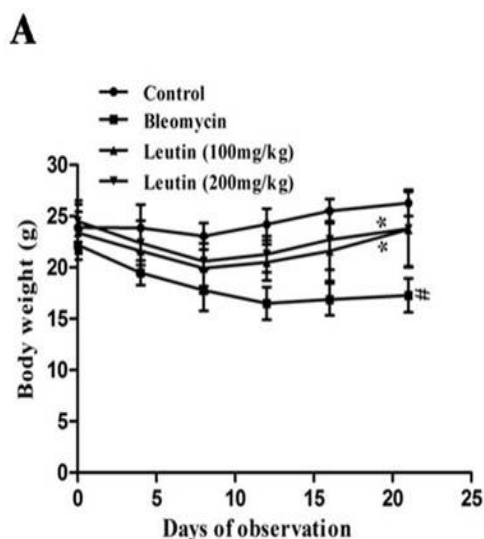
Measurement of Glutathione Levels

Lung tissues were homogenized (10%) in buffer (0.2 M Tris-0.02 M EDTA, pH 8.2) and centrifuged at 15,000 g for 30 min at 4°C. Cell-



free extract (0.3 ml containing 1.2 mg protein) was treated with 60 μ L of 25% phosphoric acid and centrifuged at 10,000 g for 30 min at 4°C to collect clear supernatant. Different aliquots of the protein-free filtrate were made up to 0.1 mL with cold distilled water, followed by addition of 1.8 mL of 0.1 M sodium phosphate buffer (pH 8.0) containing 5 mM EDTA for glutathione or 1.8 mL of 0.1 N NaOH for oxidized glutathione (GSSG). To this, 0.1 mL of 1 mg/mL o-phthalaldehyde (OPT) was added, mixed and incubated at room temperature for 15 min and fluorescence intensity was measured at excitation and emission wave lengths of 350 and 420 nm, respectively using Fluoromax-3 spectrofluorimeter (Horiba Jobin Yvon Inc., USA). Standards ranging from 0 to 2 μ g for GSSG and 0-10 μ g for GSH were evaluated simultaneously. GSH and GSSG react with OPT to yield a fluorescent complex and the Reduced glutathione (GSH) was obtained by subtracting GSSG from total glutathione, and molecular ratio of GSH/GSSG was calculated.

Results and Discussion

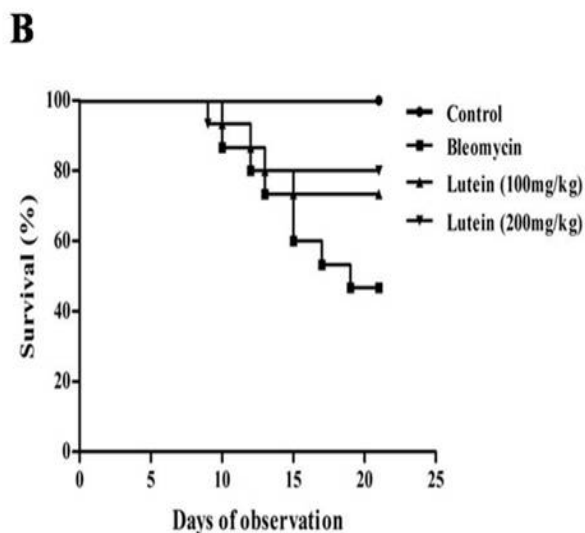


Effect of Lutein Administration on BALF Inflammatory Cells in Bleomycin-Induced Mice

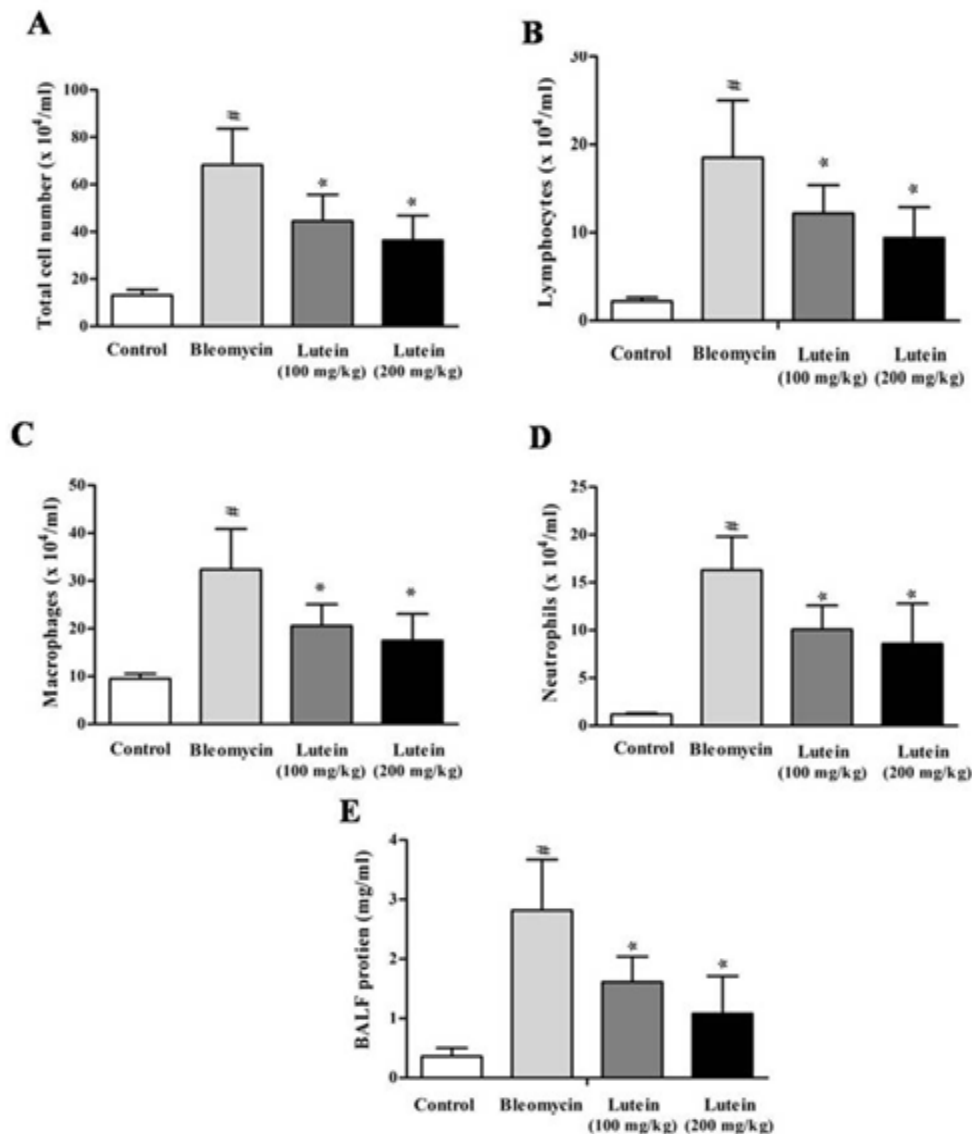
To evaluate the effect of lutein in bleomycin-induced inflammation, the number of inflammatory cells in BALF at day 7 after bleomycin instillation were measured. The total number of inflammatory cells in BALF were significantly ($p < 0.05$) increased by 5 fold in group II when compared to respective controls (Figure. S2A). However, lutein administration at 100 and 200 mg/kg significantly ($p < 0.05$) decreased the inflammatory cells to 46.7% and 34.8% respectively when compared to group II animals. In addition, the differential

Effect of Lutein on Body Weights and Survival rate in Bleomycin-Induced Mice

The severe lung injury caused by the bleomycin instillation was associated with high mortality and reduction of body weight. 0.05 U bleomycin instillation reduced the survival rate (48%; 7 survived out of 15 animals) of mice (Figure. 1A) during 10 to 21 days. In contrast, lutein administration at 100 and 200 mg/kg increased the survival rate of bleomycin-induced pulmonary fibrotic mice (group II) to 73% and 80%, respectively. Similarly, bleomycin instillation caused significant ($n=15$ for control, $n=7$ for bleomycin, $p < 0.05$) reduction (25%) in mean body weight during 21 days of observation when compared to controls (group I) (Figure. S1B). However, the loss of body weight was insignificant in mice administered with lutein compared to bleomycin alone instilled mice.



count of cells present in BALF has shown a significant increase in lymphocytes (8.4 fold), macrophages (2.8 fold), and neutrophils (13.5 fold) ($p < 0.005$) in group II compared to respective controls (Figure. 2B, 2C, and 2D). While the treatment with lutein at 100 and 200 mg/kg significantly ($p < 0.05$) decreased the lymphocytes, macrophages and neutrophils by 34 and 49%, 36 and 46% and 38 and 47% respectively. In addition, total protein levels in BALF significantly ($p < 0.05$) increased by 7.8 fold in group II comparing to respective controls (Figure. 2E). Such an elevated protein levels was significantly decreased ($p < 0.05$) by 43 and 62% at 100 and 200 mg/kg lutein administration, respectively.

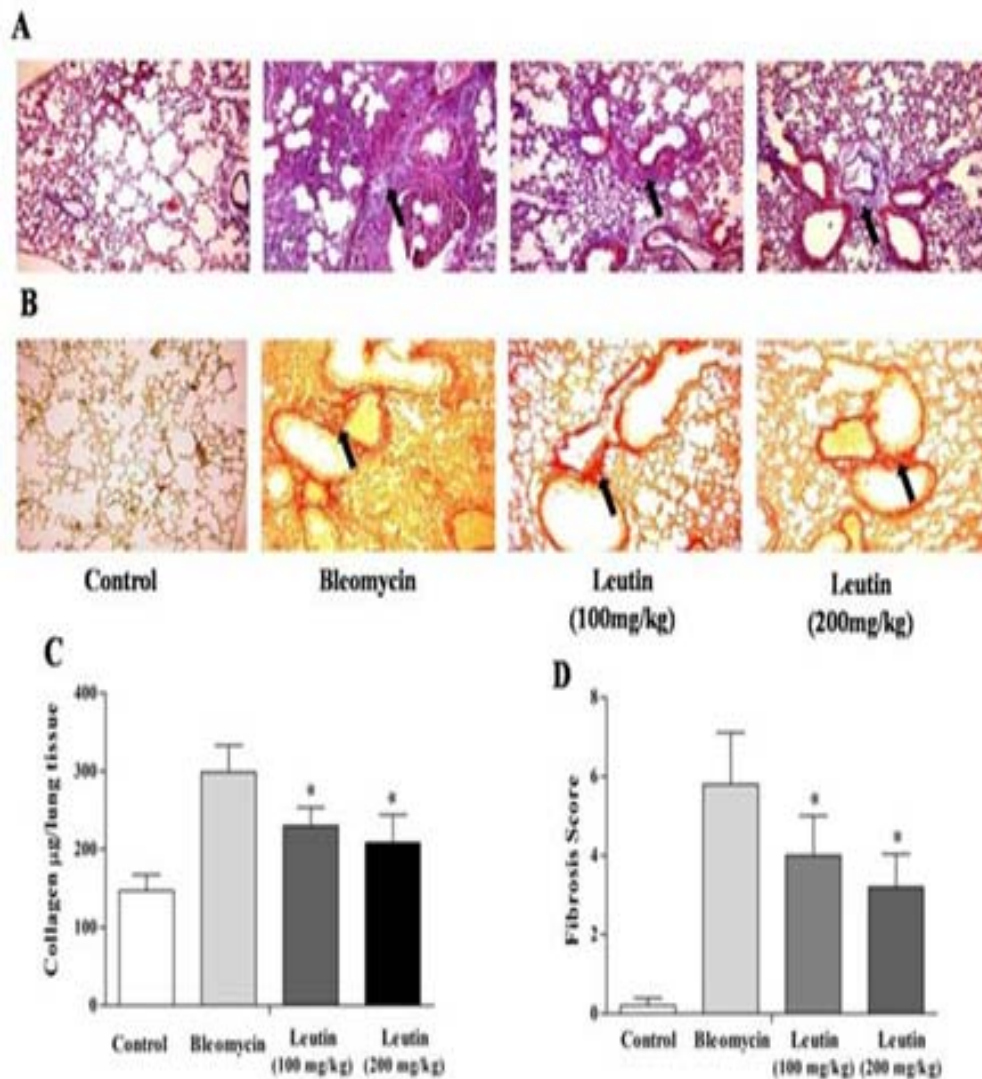


Effect of Lutein Administration on Collagen Deposition in Lung Tissues of Bleomycin-Induced Mice

Accumulation of collagen is a characteristic feature of bleomycin-induced pulmonary fibrosis. Masson's trichrome staining of lung tissues on day 21 showed an excessive deposition of collagen in group II with respective controls (blue color, Figure. 3A). On the contrary, collagen accumulation was attenuated in lutein-administered mice at 100 or 200 mg/kg. The fibrosis score in bleomycin-induced mice increased up to 5.8 and was reduced to 4.0 and 3.2 in lutein administered mice at 100 and 200 mg/kg,

respectively (Figure. 3D). Picosirus red staining showed similar pattern of collagen deposition in group II (Figure. 3B). This collagen deposition was reduced in lutein administered mice at 100 and 200 mg/kg. Further, we analyzed the collagen content in lung extracts (Figure. 3C), which was significantly ($p < 0.05$) increased by 2 fold in group II compared to controls. However, collagen content in mice administered with lutein at 100 and 200 mg/kg showed significant ($p < 0.05$) decrease by 22.9 and 30.2% respectively when compared to group II.





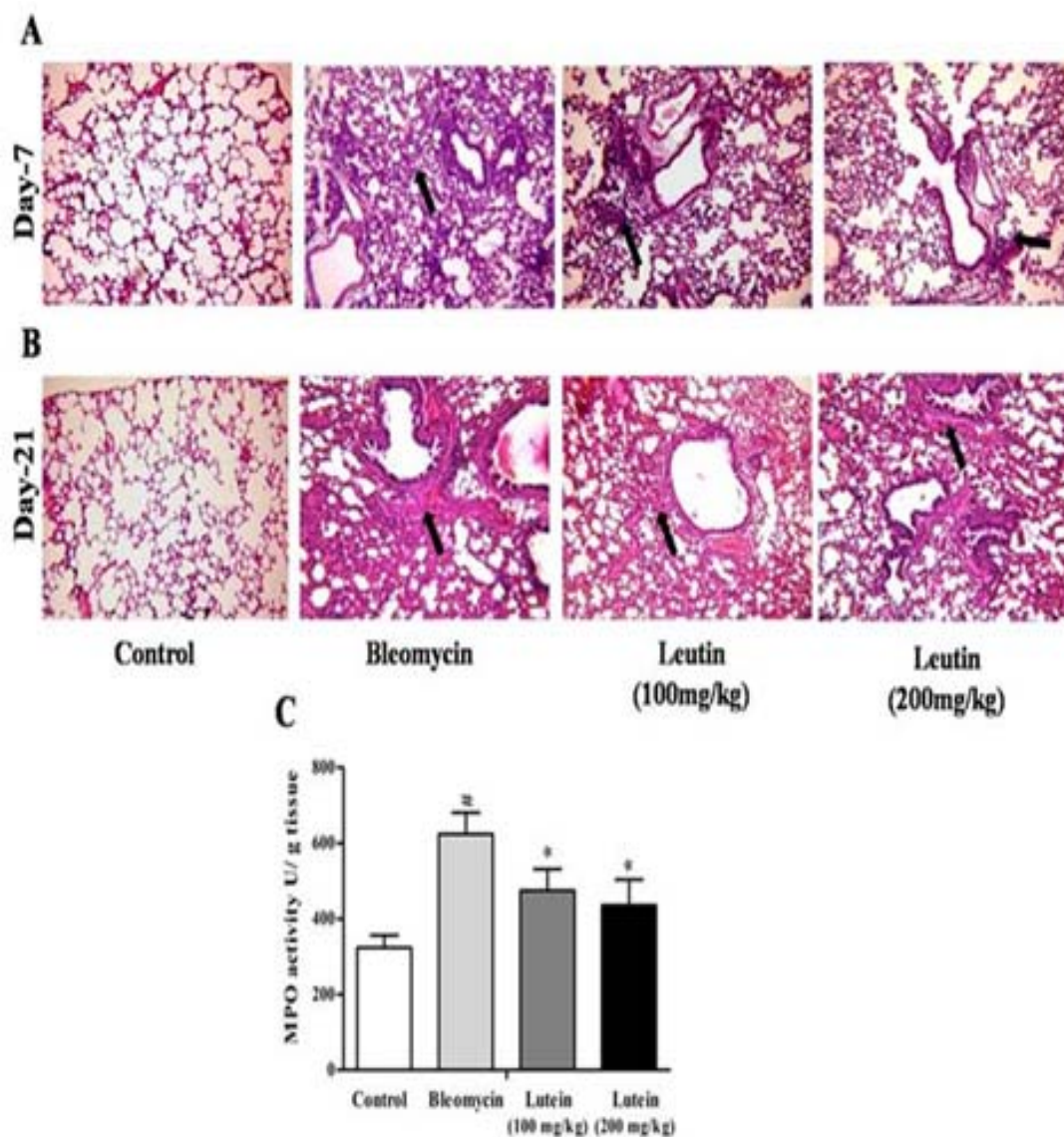
Effect of Lutein Administration on Lung Infiltration in Bleomycin-Induced Mice

Hematoxyline and Eosin staining of lung tissues revealed that bleomycin-induced mice showed evidences of tissue damage and extensive infiltration of inflammatory cells on day 7 (Figure. 4A). On the contrary, this massive infiltration of inflammatory cells was reduced in bleomycin-induced mice administered with lutein at 100 and 200 mg/kg. A well alveolized normal lung structure was seen in mice instilled with saline. While severe epithelial degeneration, excessive deposition of extracellular matrix proteins and distorted alveolar architecture were observed in lungs after 21 days of

bleomycin instillation (Figure. 4B), lungs of lutein-treated mice showed reduced epithelial degeneration, extracellular matrix deposition and restored alveolar architecture.

In addition, the MPO activity was measured in the lungs of bleomycin-induced pulmonary fibrotic mice because it is the marker of polymorphonuclear neutrophils infiltration (Figure. 4C). Bleomycin caused 92.8% increase in MPO activity significantly (p 0.05) when compared to controls. However, lutein administration decreased the MPO activity by 24 and 30% at 100 and 200 mg/kg, respectively when compared to group II (p 0.05).



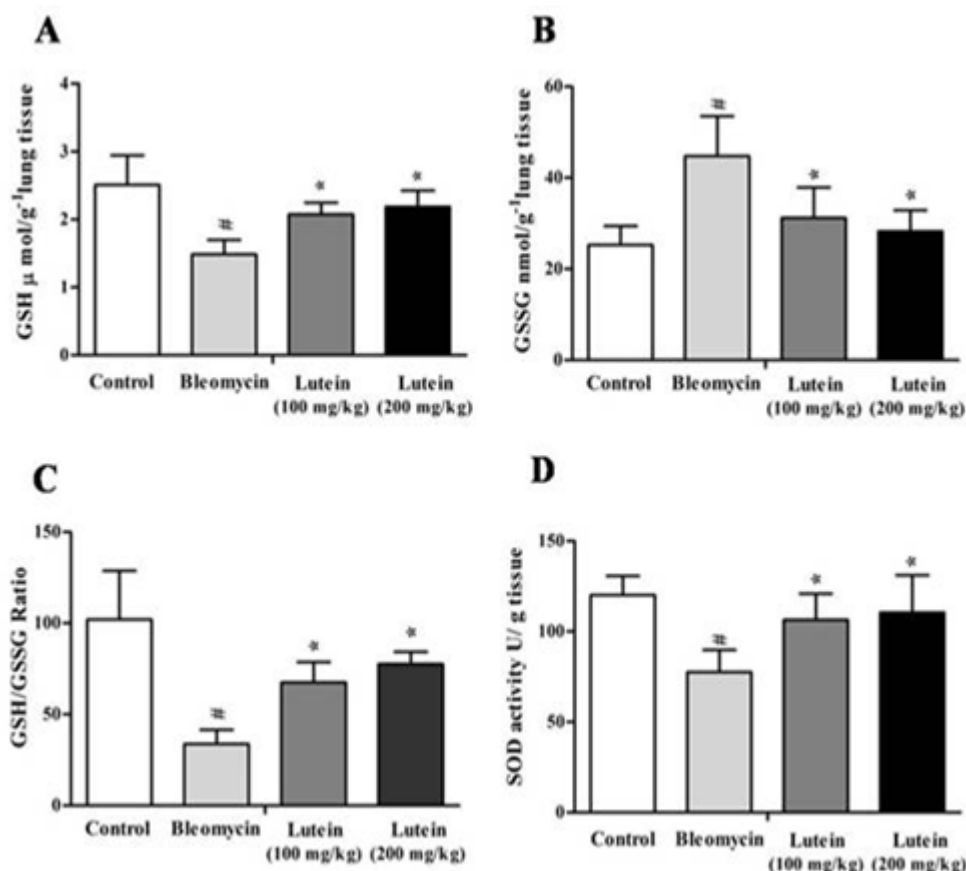


Effect of Lutein on Oxidative Stress Induced by Bleomycin

Oxidative stress indicators such as SOD, GSH, and GSSG in bleomycin-induced lung fibrotic mice were measured. It was observed that GSH levels were significantly ($p < 0.05$) decreased by 40.8% and GSSG levels were significantly ($p < 0.05$) increased by 77% in the lungs of group II animals when compared to group I (Figure. S5B and 5C). But the GSH levels were significantly ($p < 0.05$) attenuated by 40 and 47% at 100 and 200 mg/kg lutein administration, respectively when compared to group II. However,

GSSG levels significantly ($p < 0.05$) decreased by 30.1 and 36.8% at 100 and 200 mg/kg lutein, respectively in group II. GSH/GSSG levels were decreased by 66.8% in group II compared to controls. However, the GSH/GSSG ratio was restored up to 1.9 and 2.2 folds in 100 and 200 mg/kg lutein-administered mice compared to group II (Figure. 5C). Further, SOD activity was significantly ($p < 0.05$) decreased by 35% in group II compared to controls (Fig. 5D). However, the SOD activity was restored by 37% and 43% at 100 and 200 mg/kg of lutein in bleomycin-induced lung fibrotic mice when compared to group II.





Idiopathic pulmonary fibrosis is a progressive incurable disorder with a poor prognosis and the molecular mechanisms lying to cause are poorly understood. Previous reports suggested that inflammatory response and excessive deposition of extracellular matrix proteins within the pulmonary interstitium in bleomycin-treated animals are similar to pulmonary fibrosis patients [24]. Hence, in the present study bleomycin was used to induce the pulmonary fibrosis in mice. The pulmonary fibrosis was characterized by significant decrease in body weights, survival rates, increase in inflammatory cells, including lymphocytes, macrophages and neutrophils, total protein in BALF, infiltration of polymorpho-nuclear cells in lung tissues, increase in myeloperoxidase activity, collagen levels, fibrosis score and deprival of antioxidants such as glutathione and SOD activity. Previous reports suggested that anti-inflammatory, anti-fibrotic and immunosuppressive therapies might be helpful in the treatment of pulmonary fibrosis, but are not effective in improving survival rate or quality of life [25]. However, such an altered inflammatory, fibrotic and oxidative stress indicators could be minimized in pulmonary fibrosis through natural compounds or food supplements, which may prevent the cause of pulmonary fibrosis at the initial stage of the disease. Recent studies have employed natural compounds extracted from various plant resources such as neferine, an alkaloid from *Nelumbo mucifera* [26], a traditional

Chinese herbal extract of *Panax notoginseng* [27] and *Boswellia serrata* [28] in attenuation of bleomycin-induced pulmonary fibrosis in rodents. Other agents like pirfenidone, PG490-88, LLDT-8, taurine, niacin and corticosteroids have also shown similar effects in the treatment of pulmonary fibrosis because they exerted anti-inflammatory, anti-fibrotic and antioxidant effects [26]. In the present study, lutein, a naturally available hydroxyl carotenoid has been used for determining the efficacy in preventing pulmonary fibrosis in bleomycin-induced mice. It was widely used as a protective agent in various inflammatory dysfunctions [14], atherosclerosis [1], endotoxin-induced uveitis [16], etc. Lutein administration at 100 or 200 mg/kg three days prior to intratracheal instillation of bleomycin has protected the mice from inflammatory symptoms by reducing the number of inflammatory cells, including lymphocytes, macrophages and neutrophils as well as total protein in BALF. Further, MPO activity in lungs was decreased in bleomycin-induced mice administered with lutein in dose-dependent manner. In addition, the present investigation demonstrated lutein treatment attenuated the bleomycin induced increase of inflammatory cells infiltration on 7th day, fibrosis score and collagen accumulation on 21st day. Such an anti-fibrotic effect was demonstrated by significant decrease of collagen levels in lutein-administered mice. In addition, antioxidant property of lutein was evidenced by dose-dependent restoration of GSH/GSSG, a



measure of intracellular thiol status and oxidative stress which was decreased followed by bleomycin instillation. It is well known that oxidative stress was substantiated in fibrosis lungs [8] induced by bleomycin administration showing symptoms of intracellular oxidative injury, reduction of antioxidant enzyme activities, DNA damage and the destruction of alveolar epithelial cells [29]. In the present study, depletion of GSH levels and SOD activity in bleomycin-induced mice indicated oxidative damage. Such imbalances of intracellular antioxidants in bleomycin-induced mice were ameliorated by lutein treatment. Similarly, previous reports revealed the strong antioxidant nature of lutein in lipopolysaccharide-induced uveitis in mice [19]. In addition, certain antioxidants including N-acetylcysteine, erdosteine [29] and SOD [6] can decrease collagen deposition and protect lungs from

oxidative damage in variety animal models of pulmonary fibrosis and in human IPF.

The results in present study suggested the anti-inflammatory, anti-fibrotic and antioxidant role of lutein in prevention of bleomycin-induced pulmonary fibrosis. Hence, the dietary intake of lutein may, perhaps, be helpful in prevention of pulmonary fibrosis.

Statistical analysis

Acknowledgement

The authors would like to thank Sugan Life Sciences Pvt. Ltd. for extending its financial support to the present study.

References

- [1]. King TE. Idiopathic pulmonary fibrosis. In: Schwarz MI, King TE, eds. Interstitial lung disease. St. Louis, MO: Mosby Year Book Inc; 1993, p. 367-403.
- [2]. Mapel DW, Hunt WC, Utton R, Baumgartner KB, Samet JM, Coultas DB. Idiopathic pulmonary fibrosis: survival in Population based and hospital-based cohorts. *Thorax*. 1998; 53(6): 469-476.
- [3]. Crystal RG, Bitterman PB, Rennard SI, Hance AJ, Keogh BA. Interstitial lungdiseases of unknown cause. Disorders characterized by chronic inflammation of the lower respiratory tract. *N Engl J Med*. 1984; 310(3): 154-66.
- [4]. Coultas DB, Zumwalt RE, Black WC, Sobonya RE. The epidemiology of interstitial lung diseases. *Am J Respir Crit Care Med*. 1994; 150(4):967-72.
- [5]. Thannickal VJ, Toews GB, White ES, Lynch JP, Martinez FJ. Mechanisms of pulmonary fibrosis. *Annu Rev Med*. 2004; 55: 395-417.
- [6]. Tanaka K, Ishihara T, Azuma A, Kudoh S, Ebina M, Nukiwa T, Sugiyama Y, Tasaka Y, Namba T, Ishihara T, Sato K, Mizushima Y, Mizushima T. Therapeutic effect of lecithinized superoxide dismutase on bleomycin-induced pulmonary fibrosis. *Am J Physiol Lung Cell Mol Physiol*. 2010;298(3):348-360.
- [7]. Sheppard D. Transforming growth factor beta: a central modulator of pulmonary and airway inflammation and fibrosis. *Proc Am Thorac Soc*. 2006; 3(5): 413-417.
- [8]. Kinnula VL, Myllarniemi M. Oxidant-antioxidant imbalance as a potential contributor to the progression of human pulmonary fibrosis. *Antioxid Redox Signal*. 2008; 10(4):727-738.
- [9]. Willis BC, Borok Z. TGF β 1 induced EMT: mechanisms and implications for fibrotic lung disease. *Am J Physiol Lung Cell Mol Physiol*. 2007; 293(3): 525-534.
- [10]. Khalil N, O Connor R. Idiopathic pulmonary fibrosis: current understanding of the pathogenesis and the status of treatment. *CMAJ*. 2004;171(2):153-160.
- [11]. Chua F, J Gaudie, Laurent GJ. Pulmonary fibrosis: searching for model answers. *Am J Respir Cell Mol Biol*. 2005; 33(1): 9-13.
- [12]. Phan SH, Thrall RS, Ward PS. Bleomycin-induced pulmonary fibrosis in rats:biochemical demonstration of increased rate of collagen synthesis. *Am Rev Respir*. 1995; 121(3): 501-506.
- [13]. Luppi F, Cerri S, Beghe B, Fabbri LM, Richeldi L. Corticosteroid and immuno modulatory agents in idiopathic pulmonary fibrosis. *Respir Med*. 2004; 98 (11):1035-1044.
- [14]. Sasaki M, Ozawa Y, Kurihara T, Noda K, Imamura Y, Kobayashi S, Ishida S, Tsubota K. Neuroprotective effect of an antioxidant, lutein,during retinal inflammation. *Invest Ophthalmol Vis Sci*. 2009; 50 (3):1433-1439.
- [15]. Kim JE, Leite JO, DeOgburn R, Smyth JA, Clark RM, Fernandez ML. A lutein-enriched diet prevents cholesterol accumulation and decreases oxidized LDL and inflammatory cytokines in the aorta of guinea pigs. *J Nutr*. 2011;141 (8):1458-1463.
- [16]. Jin XH, Ohgami K, Shiratori K, Suzuki Y, Hirano T, Koyama Y, Yoshida K, Iieva I, Iseki K, Ohno S. Inhibitory effects of lutein on endotoxin-induced uveitis in Lewis rats. *Invest Ophthalmol Vis Sci*. 2006; 47: 2562-2568.
- [17]. Li SY, Fu ZJ, Ma H, Jang WC, So KF, Wong D, Lo AC. Effect of lutein on retinal neurons and oxidative stress in a model of acute retinal ischemia/reperfusion. *Invest Ophthalmol Vis Sci*. 2009; 50(2):836-43.
- [18]. Krinsky NI, Landrum JT, Bone RA. Biologic mechanisms of the protective



- role of lutein and zeaxanthin in the eye. *Annu Rev Nutr.* 2003; 23:171-201.
- [19]. He RR, Tsoi B, Lan F, Yao N, Yao XS, Kurihara H. Antioxidant properties of lutein contribute to the protection against lipopolysaccharide-induced uveitis in mice. *Chinese Medicine* 2011; 6(1):38.
- [20]. Furonaka M, Hattori N, Tanimoto T, Senoo T, Ishikawa N, Fujitaka K, Haruta Y, Yokoyama A, Kohno N. Suplatast tosilate prevents bleomycin-induced pulmonary fibrosis in mice. *J Pharmacol Exp Ther.* 2009;328:55-61.
- [21]. Ashcroft T, Simpson JM, Timbrell V. Simple method of estimating severity of pulmonary fibrosis on a numerical scale. *J Clin Pathol.* 1988; 41(4):467-70.
- [22]. Yan XT, Tumpey TM, Kunkel SL, Oakes JE, Lausch RN. Role of MIP-2 in neutrophil migration and tissue injury in the herpes simplex virus-1- infected cornea. *Invest Ophthalmol Vis Sci.* 1998; 39(10):1854-1862.
- [23]. Manikonda PK, Jagota A. Melatonin administration differentially affects age-induced alterations in daily rhythms of lipid peroxidation and antioxidant enzymes in male rat liver. *Biogerontology.* 2012;13:511-524.
- [24]. Molina-Molina M, Pereda J, Xaubet A. Experimental models for the study of pulmonary fibrosis: current usefulness and future promise. *Arch. Bronconeumol.* 2007; 43(9): 501-507.
- [25]. Raghu G, Brown KK, Bradford WZ, Starko K, Noble PW, Schwartz DA, King TE Jr. Idiopathic Pulmonary Fibrosis Study Group. A placebo-controlled trial of interferon gamma-1b in patients with idiopathic pulmonary fibrosis. *N Engl J Med.* 2004; 350:125-133.
- [26]. Zhao L, Wang X, Chang Q, Xu J, Huang Y, Guo Q, Zhang S, Wang W, Chen X, Wang J. Neferine, a bisbenzylisoquinoline alkaloid attenuates bleomycin-induced pulmonary fibrosis. *Eur J Pharmacol.* 2010; 627:304-312.
- [27]. Tsai KD, Yang SM, Lee JC, Wong HY, Shih CM, Lin TH, Tseng MJ, Chen W. Panax notoginseng Attenuates Bleomycin-Induced Pulmonary Fibrosis in Mice. *Evid Based Complement Alternat Med.* 2011; 402761.
- [28]. Ali EN, Mansour SZ. Boswellic acids extract attenuates pulmonary fibrosis induced by bleomycin and oxidative stress from gamma irradiation in rats. *Chinese Medicine.* 2011; 6:36.
- [29]. Boyaci H, Maral H, Turan G, Basyigit I, Dillioglugil MO, Yildiz F, Tugay M, Pala A, Ercin C. Effects of erdosteine on bleomycin-induced lung fibrosis in rats. *Mol Cell Biochem.* 2006; 281(1-7): 129-137.

