
ISSN - 2277 - 2755
© UNAAB 2009

Journal of
Agricultural Science
and Environment

STUDIES ON GENITAL DISORDERS OF COWS SLAUGHTERED AT ZURU, KEBBI STATE, NIGERIA

M.O. OLANIYI¹*, A.A. OLOYE², O.O. ALAKA³ AND O. L., AJAYI¹

¹College of Agriculture, P.M.B 1018, Zuru, Kebbi State. Nigeria.

² Department of Veterinary Public Health and Reproduction, University of Agriculture, Abeokuta, Nigeria.

³Department of Veterinary Pathology, University of Ibadan, Ibadan, Nigeria

*Corresponding author: mosh_unaab@yahoo.com; olaniyimoshood@gmail.com

ABSTRACT

In a survey carried out between April and December, 2003 to investigate the incidence of reproductive pathology among cows slaughtered at Zuru central abattoir and some selected slaughter slabs within Zuru emirate, Kebbi State, a total of 84(16.8%) abnormalities were recorded from 500 female genitalia examined. The incidence of various abnormalities observed included bilateral Ovarian follicular cysts (1.6%), Endometritis (0.4%), Uterine hypoplasia (1.0%), Pyometra(1.2%), Ovarian tumour (0.2%), Cystic endometrial hyperplasia (0.4%), Para ovarian cyst (0.2%), Vulvo-vaginitis (1.6%), Salpingitis (2.0%), Ovarian abscess (0.2%), Ovarian agenesis (2.0%) and vulva tick infestation (6.0%). From this study, tick infestation of the vulva ranked the highest genital pathological condition recorded and the ticks were identified as *Boophilus* spp. This was closely followed by Salpingitis and Ovarian agenesis. These conditions most times result into conception failures, abortions or still births, situations that often lead to the culling of the animals by their owners. It is suggested that timely medical interventions to diagnose and treat these genital disorders will however save some of these economic losses. This study provides information on the diseases affecting reproductive tracts as well as their adverse effects and significance in cattle production and breeding in Nigeria. It recommends a close watch on the cattle industry by relevant stake holders with a view to preventing unwarranted slaughter of viable cows erroneously believed to be unproductive.

Key Words: Cows, Genital, Disorders

INTRODUCTION

Cattle generally play a significant role in the development of agricultural sector of national economy in addition to providing the human population with protein gotten from milk and meat. The meat protein intake of the European and North American averages 27.3g and 38.3g per caput per day, respectively. These are higher than the African average of 4.5g (Ndi *et al.*, 1993). Cattle population in Nigeria, according to RIM report (1993) was put at 13.9million with

North-West geographical zone contributing about 6.1 million; North East, 4.2 million; Central zone, 3.1million; South West, 383,000 and South East, 84,000. Despite the economic importance of the *Bos indicus* the productivity of this breed of cattle in the tropics is low, this has been reported to be as a result of low genetic potential of indigenious breeds, poor husbandry and a variety of environmental factors, including high ambient temperature and humidity, seasonal shortages of feed and water, diseases and

parasites (FAO, 1993). The productivity of cattle has been shown to be largely dependent on their reproductive performance (FAO, 1993). Reproductive failure is considered as inability to produce offspring which may be as a result of failure to cycle, to conceive or to carry the foetus to full term following conception (Kahn, 2005). Infertility on the other hand, can be caused by anatomical factors, infectious agents, functional abnormalities and management problems (Arthur *et al.*, 1977).

Studies on the pathology of genitalia of slaughtered cows in Nigeria are scanty and there has been no previous study on the reproductive disorders of cow from Zuru where this study was carried out, a locality with a very high density of cattle population. In a similar survey by Ribadu *et al.* (1998), 12% genital disorders were recorded in a work carried out on camels in Maiduguri, Northeastern Nigeria.

The study therefore was aimed at investigating and documenting the incidence of reproductive tract lesions of cows slaughtered at Zuru with a view to contributing to scientific information and advancement as regards female genital diseases in cattle.

MATERIALS AND METHODS

A total of 500 reproductive organs of slaughtered cows were collected from Zuru central abattoir and some selected slaughter slabs at Dabai, Ribah, Fakai and Dirindaji; all within Zuru Emirate between April and December, 2003. These organs were examined thoroughly for presence of abnormalities and examination involved assessment of the relative anatomical conformation of the genital tracts after removal from the pelvis with all the structures of the tract intact. Examination was carried out in a progres-

sive ascending sequence (vulva, vagina, cervix, uterus, oviducts, and ovaries). The tract was then incised and opened for examination of the lumen.

Thorough gross pathological examinations were carried out and tissue sections from pathological sites were fixed in 10% buffered formalin solution and processed routinely for histopathology as described by Humason (1979). Vulva tick infestation assessment was based on the counting of 10 ticks per 1.5cm² area of the vulva. Identification of the ticks was as described by Hendrix and Robinson (2006).

RESULTS

Out of the total 500 genitalia examined only 84 showed gross abnormalities representing 16.8%. The summary of the results is as presented in Table 1.

Of these 8 cases (1.6%), of ovarian follicular cysts were recorded, 3 were bilateral and 5 unilateral. The walls of the cysts were thin in all cases. There was presence of variable quantity of amber coloured fluid in all the cysts and the size varies from case to case (Fig.1).

Uterine tubes in most of the closed pyometra were thin walled, flabby and exuding thick tenacious pus on incision. In the cases of endometritis reported, the uterine wall was thickened and the lumen contained foul smelling pus. Cystic endometrial hyperplasia however only showed hyper plastic endometrial glands with presence of eosinophilic proteinaceous materials in the lumen of the cyst (arrow), in addition there was infiltration with mononuclear inflammatory cells marked F in Fig. 2.

In the Uterine hypoplasia, uterine tubes were

grossly reduced in size when compared to the normal size, while Parar ovarian cysts reported had their cysts located in the mesosalpinx. There were 10 cases (unilateral and 8 bilateral) of ovarian agenesis and the ovaries in all the cases were either absent or

reduced to functionless mass. Vulva tick infestation was observed in 30 cases (6.0%). This was ranked highest in the array of genital disorders studied and the ticks were identified as *Boophilus* spp.

Table 1: Incidence of genital disorders of slaughtered cows at Zuru (n=500)

S/N	Type of Disorder	Frequency of Occurrence	Incidence (%)
1	Ovarian follicular cysts	8	1.6
2	Endometritis	2	0.4
3	Uterine hypoplasia	5	1.0
4	Pyometra	6	1.2
5	Ovarian tumour	1	0.2
6	Cystic endometrial hyperplasia	2	0.4
7	Vulvo vaginitis	8	1.6
8	Salpingitis	10	2.0
9	Ovarian abscess	1	0.2
10	Paraovarian cysts	1	0.2
11	Ovarian agenesis	10	2.0
12	Vulva tick infestation	30	6.0
	Total	84	16.8

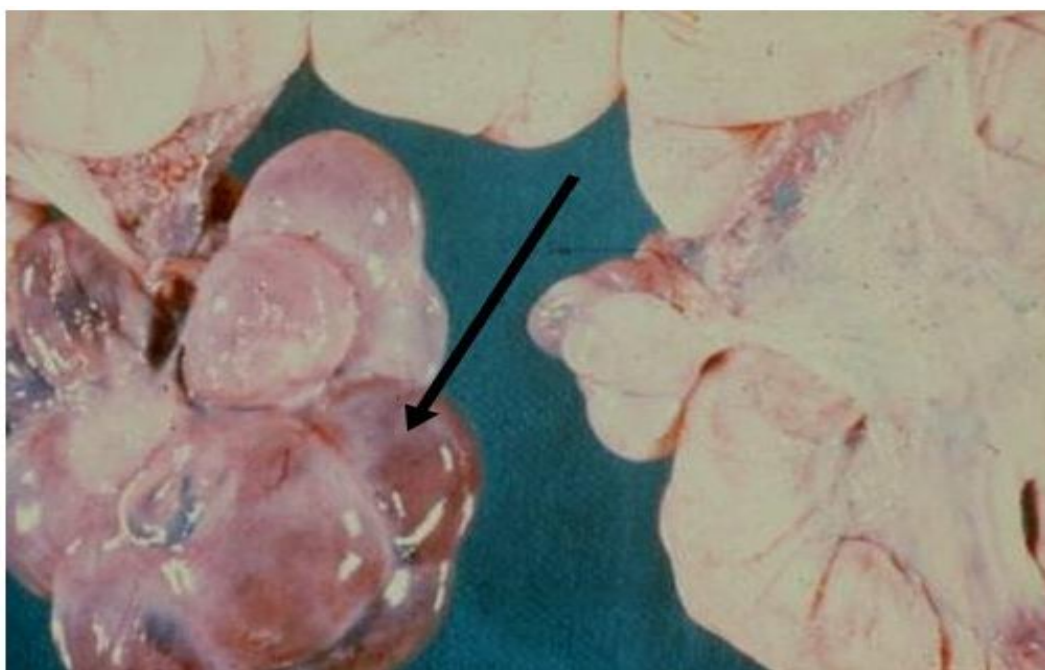


Fig 1: Gross appearance of bovine ovary showing multiple ovarian cysts with sizes varying from 2–4cm in diameter. (Arrowed)

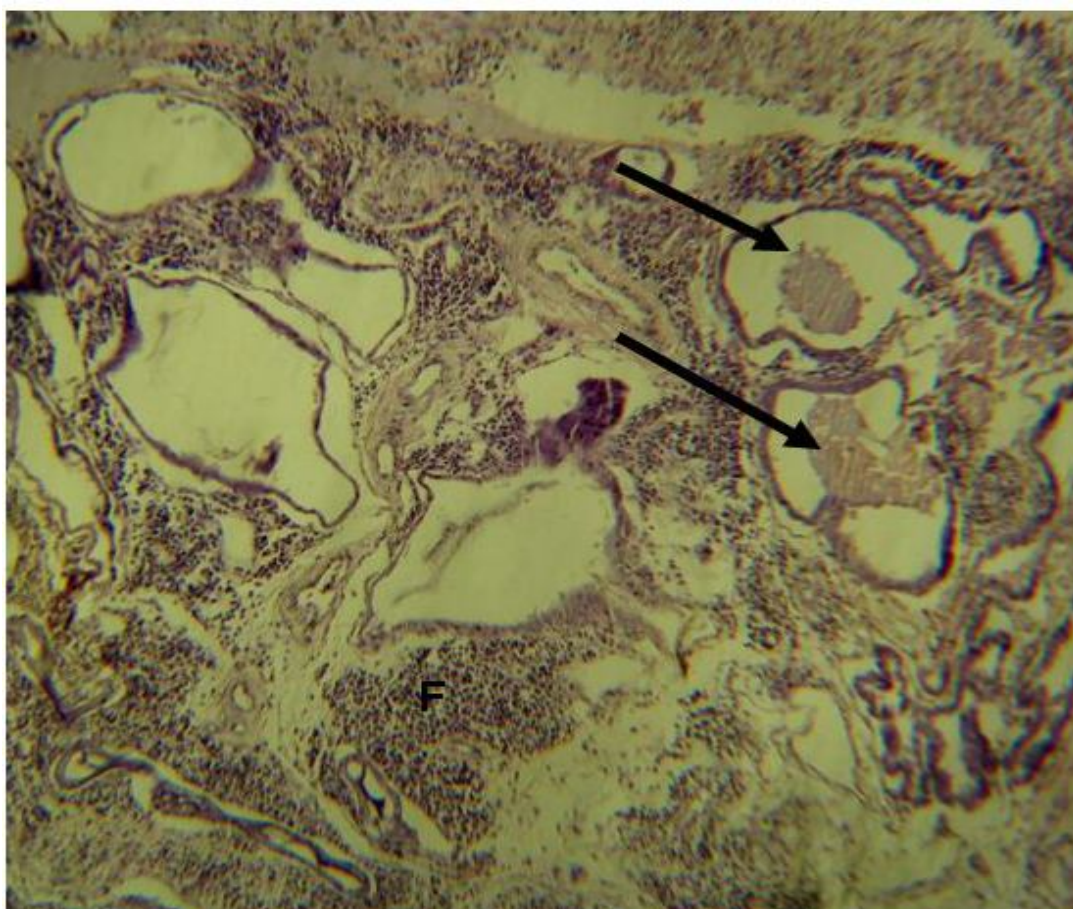


Fig.2: Histological section of Cystic Endometrial Hyperplasia showing distended endometrial glands (Arrowed) with tall epithelial cells and focal area of mononuclear cell infiltration (F)

DISCUSSION

The result of 16.8% reproductive disorders is slightly higher than 13.02% obtained by Al-Dahash and David (1977) for cattle and 12% for camel as reported by Ribadu *et al.* (1998) but lower than 19.46% obtained by Shalash (1965) for camels in Cairo, Egypt and close to 16.72% reported by Nawito *et al.* (1967) in camels.

The incidence of vulva tick infestation was absent in AL- Dahash and David's work (1977) while Ribadu *et al.* (1998) recorded

high incidence. Probable causes of these infestations as recorded in this work are environment and husbandry system. The high incidence recorded in this study was directly related to the period of the year the study was carried out. Tick parasitism is known to be high during rainy season. The reproductive implication of this is seen in the cows being infertile to natural service as a result of bruising of the vulva arising from the tick infestation (Noakes *et al.*, 2001a).

Cystic ovaries are known to depress fertility in the cow by extending the calving interval (Noakes *et al.*, 2001b), however, parovarian cysts bear little significance as far as reproduction is concerned. The cysts could however impinge on the oviduct and reduce its lumen thereby causing the obstruction of the oviduct. (Noakes *et al.*, 2001c). The conditions arising from inflammation of the various aspects of the reproductive parts with attendant bacterial infection are consistent with reports of various authors. Al-Dahash and David (1977) had earlier reported pyometra (1.0%), Cystic ovaries (3.23%) and ovarian tumours (0.23%) while Noakes *et al.* (2001d) reported vaginitis, cervicitis and endometritis in cattle.

CONCLUSION

There is urgent need for stakeholders in the cattle industry to salvage reproductive wastages if Africa and indeed Nigeria desire increase in protein production through this all important livestock. This study has helped to highlight some of the likely reproductive lesions that may forestall this prospect with the hope that a good percentage of affected animals will be treated and preserved for propagation.

REFERENCES

- Al-Dahash, S.Y.A., David, J.S.E.** 1977. Incidence of reproductive abnormalities. *Vet records*. 101: 296
- Arthur, G. H.** 1977. *Veterinary Reproduction and Obstetrics*. Publ. Bailliere Tindall, New York, USA. 4th ed. 373pp.
- FAO.** 1993. A review of reproductive performance of female *Bos indicus*. *FAO Corporate Document Repository*. <http://www.fao.org/Wairddocs/ILRI>
- Hendrix, M.C., Robinson, E.D.** 2006. *Diagnostic Parasitology for Veterinary Technicians*. Publ. Mosby Inc. Philadelphia, USA. 194pp.
- Humason, G. L.** 1979. *Animal tissue technique*. 4th ed. W.H. Freeman and Company, USA.
- Khan, C.M.** 2005. Reproductive System. In: *Merck's Veterinary Manual*, ninth edition. Cynthia M. Kahn and Scott Line (Eds): Merck & Co., Inc., White House Station, N.J. U.S.A. 1092pp.
- Nawito, M.F., Shalash, M.R., Hoppe, R., Rakha, A.M.** 1967. Reproduction in the female camel, Bulletin 2, *Animal Science Research Institute*, Cairo, Egypt, 82pp.
- Ndi, C., Tambi, N. E., Agharih, N. W.** 1993. Reducing wastage from the slaughtering of pregnant cows in Cameroon: In *FAO Corporate Document Repository*. <http://www.fao.org/DOCREP/V1650T/v1650TOF.htm>.
- Noakes, D.E., Parkinson, T.J., England, G. C. W.** 2001a. *Arthur's Veterinary Reproduction and Obstetrics*. Publ. Harcourt Publishers Limited. The Curtis Center Independence Square West Philadelphia, Pennsylvania 19106. 8th ed. 398pp.
- Noakes, D.E., Parkinson, T.J., England G. C. W.** 2001b. *Arthur's Veterinary Reproduction and Obstetrics*. Publ. Harcourt Publishers Limited, The Curtis Center Independence Square West Philadelphia, Pennsylvania 19106. 8th ed. 442pp.
- Noakes, D.E., Parkinson, T.J., England G. C. W.** 2001c. *Arthur's Veterinary Reproduction and Obstetrics*. Publ. Harcourt Publishers

Limited, the Curtis Center Independence Square West Philadelphia, Pennsylvania 19106. 8th ed. 392pp. 16: 155-159.

Noakes, D.E., Parkinson, T.J., England G. C. W. 2001d. *Arthur's Veterinary Reproduction and Obstetrics*. Publ. Harcourt Publishers Limited, the Curtis Center Independence Square West Philadelphia, Pennsylvania 19106. 8th ed. 398 - 402pp.

Ribadu, A.Y., Waziri M. A., Mairiga I.A. 1998. An Abattoir survey of genital disorders of one – humped Camels (*Camelus dromedarius*) in Maiduguri. *Tropical Veterinarian*.

Resource Inventory and Management's Report. 1993. *Nigerian Livestock Reserves RIM Report*; Vol. I-IV. Federal Livestock Department and Pest-control services, FMA, Garki, Abuja.

Shalash, M.R. 1965. Some reproductive aspects in female camel. *World. Rev. Anim. Prod.* 1(4):103-108.

(Manuscript received: 23rd December, 2008; accepted: 29th December, 2009).