

Case Report

A rare case of myofibroblastoma in the nipple of a male patient and review of literature

Premkumar Daivasikamani*

Department of Surgery, Karpaga Vinayaga Institute of Medical Sciences and Research Center, Chinna Kolambakam, Maduranthagam, Kanchepuram, India

*Corresponding Author

Prof. Premkumar Daivasikamani
Department of Surgery,
Karpaga Vinayaga Institute of Medical Sciences
and Research Center, Chinna Kolambakam,
Maduranthagam, Kanchepuram, India
E-mail: dr.premkumar52@gmail.com

Keywords:

Benign tumor,
Nipple, Breast, Myofibroblastoma,
Stromaltumor, Solitary fibrous tumor,
Myofibroblast, Excision

Abstract

Myofibroblastoma of breast is described both in male and female breast but myofibroblastoma of the nipple is so far not reported. We are reporting a case of myofibroblastoma of nipple in a male which was treated by wide excision of nipple. Myofibroblastoma of the breast is an uncommon benign stromal tumor encountered predominantly in men in their sixth to seventh decades and in post-menopausal women. Myofibroblasts are spindle shaped or fusiform mesenchymal cells derived from fibroblasts and are present in small numbers in all tissues. Mammographic findings consist of a well-delimited, round to oval dense mass, variable in size but usually 1-4 cm in diameter. Although FNA cytology may support the diagnosis, surgical biopsy should be performed. A simple surgical excision is required for this benign lesion. No recurrence has been observed.

1. Introduction

Myofibroblastoma of breast is described both in male and female breast but myofibroblastoma of the nipple is so far not reported. We are reporting a case of myofibroblastoma of nipple which was treated by wide excision of nipple.

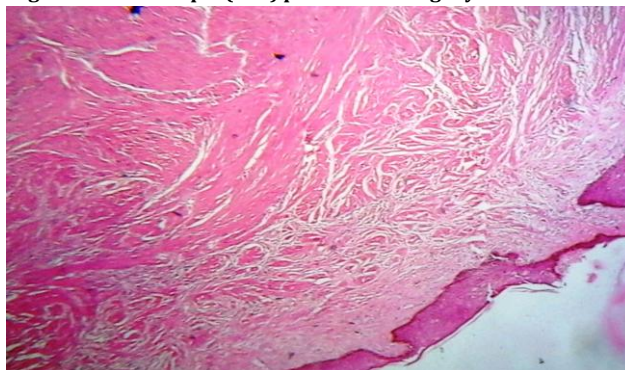
2. Case report

A 58yearoldman presented with a swelling of the right nipple for 3 months. Clinical examination revealed a firm 1.2 cm hemispherical lump occupying the whole of the right nipple with overlying redness. Areola and breast were normal. No lymph nodes were palpable. FNAC was inconclusive. So a decision was taken to do excision of the nipple and areola with underlying breast tissue. Fig1. Histopathology showed stratified squamous epithelium and sub epithelium shows adnexal structure and collagen bundles fairly circumscribed neoplasm composed of intersecting fascicles and bundles of spindle shaped cells with abundant eosinophilic cytoplasm and elongated blunt ended nuclei with cytoplasmic vacuoles separated by collagen fibers and chronic inflammatory cells surrounding margins shows fibrofatty tissue with congested blood vessels and areas of hemorrhage. Benign spindle cell lesion possibility of myofibroblastoma.

Figure 1: Showing excised specimen with nipple and areola.

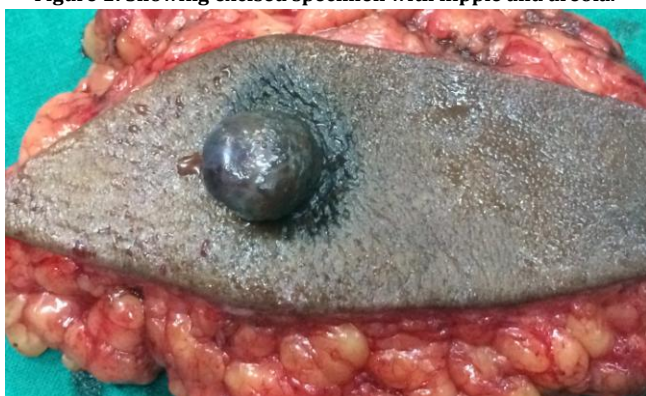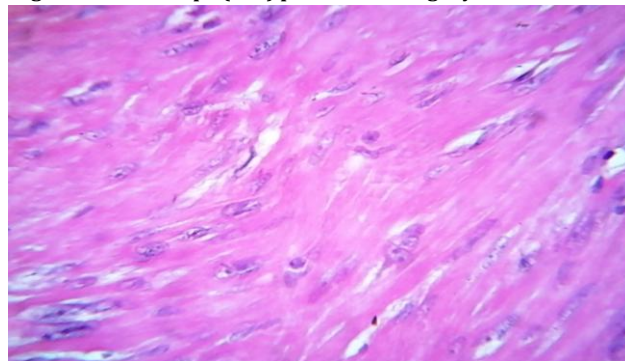


Figure 2: Microscopic (10x) picture showing myofibroblastoma



Section shows stratified squamous epithelium and sub epithelium shows adnexal structure and collagen bundles fairly circumscribed neoplasm composed of intersecting fascicles and bundles of spindle shaped cells with abundant eosinophilic cytoplasm and elongated blunt ended nuclei with cytoplasmic vacuoles separated by collagen fibers and chronic inflammatory cells surrounding margins shows fibrofatty tissue with congested blood vessels and areas of hemorrhage.

Figure 3: Microscope (40x) picture showing myofibroblastoma



Stratified squamous epithelium and sub epithelium shows adnexal structure and collagen bundles fairly circumscribed neoplasm composed of intersecting fascicles and bundles of spindle shaped cells with abundant eosinophilic cytoplasm and elongated blunt ended nuclei with cytoplasmic vacuoles separated by collagen fibers. Benign spindle cell lesion possibility of myofibroblastoma.

3. Discussion

Myofibroblastoma of the breast is an uncommon benign stromal tumor encountered predominantly in men in their sixth to seventh decades and in post-menopausal women. Myofibroblastoma was first described by Wargotz in 1987 as they are of mesenchymal in origin and exhibit a wide spectrum of histological features and a varied cellularity that can be misinterpreted as a sarcoma. They reported 16 cases of a distinctive stromal tumor of the breast and designated them as "myofibroblastoma".[1]

Myofibroblasts are spindle shaped or fusiform mesenchymal cells derived from fibroblasts and are present in small numbers in all tissues. Ultrastructurally, myofibroblasts have features resembling myoepithelial cells. Microscopically, myofibroblastomas can be divided into five subtypes; classical, epithelioid, collagenised, cellular and infiltrative.[2] Based on histological, immunohistochemical and ultrastructural observations, tumor cells have mesenchymal origin and show myofibroblastic differentiation.[3]

The detection of smooth muscle cells in breast myofibroblastoma is easily explained if we postulate its histogenesis from the CD34+ fibroblasts of mammary stroma capable of multidirectional mesenchymal differentiation, including smooth muscle.[4] Most cases of MFB are typically positive to vimentin, desmin, and CD34. Immunoreactivity for smooth muscle actin, bcl-2, and CD99 is frequently obtained, but with a variable extension in different tumors and also in different areas of the same tumor.[5] Some cytogenetic studies have shown chromosome 13 rearrangements associated with the loss of the 13q14 chromosomal region in 2 cases of mammary MFBs70 and in 1 case of soft tissue MFB71; in one of the mammary cases was also documented a partial loss of 16q.[6] Morgan et al immunohistochemically tested for estrogen and androgen receptors in 5 cases of myofibroblastoma of the breast of male and female breasts and each showed strong nuclear antibody staining for the androgen receptor. They postulated that the androgen receptor or its ligands may be pathologically related to the development of myofibroblastoma of the breast and diagnostically useful in differentiating it from other spindle cell lesions.[7] The in-situ detection of ER, PR and AR suggests that steroid hormones and their receptors are implicated in the pathogenesis of breast MFB. The consistent demonstration of bcl-2 protein, associated with a positive ER/PR status, provides evidence that bcl-2 may be an oestrogen-regulated protein also in MFB and that probably plays a role in the tumorigenesis. Finally, it is postulated that the ER/PR and bcl-2 positive immunoprofile of MFB of the breast, in contrast to the negative profile of other rare primitive benign spindle cell lesions of the breast herein studied, might be exploited as an ancillary diagnostic aid in differential diagnosis of doubtful cases.[8] Good demarcation, lack of necrosis and nuclear atypia argue for the benign nature of the lesion. It is made up of spindle cells (mainly myofibroblasts) which are positive for vimentin and not for S 100 protein or epithelial markers. Alpha-smooth muscle cell actin and desmin labelling are heterogeneous. A simple surgical excision is required for this benign lesion. No recurrence has been observed.[9] FNAC could suggest the diagnosis of this distinctly uncommon tumor if evaluated together with the clinical and radiologic finding.[10] Mammographic findings consist of a well-delimited, round to oval dense mass, variable in size but usually 1-4 cm in diameter. No microcalcifications were observed. Ultrasonography confirms the solid nature of the lesion, showing a well-circumscribed, homogeneous, hypoechoic mass, compressible with pressure. Although FNA cytology may support the diagnosis, surgical biopsy should be performed.[11] Treatment for myofibroblastoma is excisional biopsy and disease does not recur.

References

- [1] Wargotz ES, Weiss SW, Norris H Myofibroblastoma of the breast. Sixteen cases of a distinctive benign mesenchymal tumor. *J Am J Surg Pathol.* 1987 Jul; 11(7):493-502.
- [2] Abeywardana MS Abeysekera1, HP Priyantha Siriwardana, K F Abbas, Peter Tanne2 and Akin A Ojo, *Journal of Medical Case Reports* 2008, 2:157.
- [3] Marco Mele Vibeke Jensen, Adam Wronecki, and Giedrius Lelkaitis Int Myofibroblastoma of the breast: Case report and literature review. *J Surg Case Rep.* 2011; 2(6): 93–96.
- [4] Magro G, Gurrera A, Bisceglia M H-caldesmon expression in myofibroblastoma of the breast: evidence supporting the distinction from leiomyoma. *Histopathology.* 2003 Mar; 42(3):233-8.
- [5] Magro G, Bisceglia M, Michal M, Eusebi V. Spindle cell lipoma-like tumor, solitary fibrous tumor and myofibroblastoma of the breast: a clinicopathological analysis of 13 cases in favor of a unifying histologic concept. *Virchows Arch.* 2002; 440:249–260.
- [6] Pauwels P, Sciot R, Croiset F, Rutten H, van den Berghe H, Dal Cin P. Myofibroblastoma of the breast: genetic link with spindle cell lipoma. *J Pathol.* 2000; 191:282–28.
- [7] Morgan MB1, Pitha JV Myofibroblastoma of the breast revisited: an etiologic association with androgens? *Hum Pathol.* 1998 Apr; 29(4):347-51.
- [8] Magro G1, Bisceglia M, Michal M Expression of steroid hormone receptors, their regulated proteins, and bcl-2 protein in myofibroblastoma of the breast. *Histopathology.* 2000 Jun; 36(6):515-21.
- [9] Julien M1, Trojani M, Coindre JM. Myofibroblastoma of the breast. Report of 8 cases. [Article in French] *Ann Pathol.* 1994; 14(3):143-7.
- [10] Ríos F1, Burgos F, Madero S, Ballestin C, Martinez-Gonzalez MA, de Agustin P. Fine needle aspiration of breast myofibroblastoma. A case report. *Acta Cytol.* 2001 May-Jun; 45(3):381-4.
- [11] Pina L1, Apesteguia L, Cojo R, Cojo F, Arias-Camison I, Rezola R, De Miguel C. Myofibroblastoma of male breast: report of three cases and review of the literature. *Eur Radiol.* 1997; 7(6):931-4.