

Case Report

Surgeon's perspective on rare yet potentially fatal complication of GI perforation following endoscopy

Prateek Thakur, Shekhar Gogna* and Priya Goyal

Department of General Surgery, PGIMS Rohtak, Haryana India-124001

*Corresponding Author

Dr. Shekhar Gogna
Assistant Professor
Department of General Surgery,
PGIMS Rohtak, India- 124001
E-mail: Drshkhar23@hotmail.com

Keywords:

Endoscopy,
Perforation,
UGIE

Abstract

Gastrointestinal endoscopy plays an essential role in the diagnosis, staging, and treatment of pathologies of the GI tract. New-generation endoscopes, advanced imaging technologies, the introduction of new therapeutic devices into clinical practice, and modification of old techniques have expanded both the diagnostic and therapeutic armamentarium of the endoscopist. Complications are rare with a rate of less than 1 per 5000 cases. Perforations are either due to therapeutic dilatation, coagulation or passage of side viewing instrument into the duodenum. Here we present a case of 56 yr old male who underwent diagnostic endoscopy for peptic ulcer. It lead to endoscopy induced large duodenal perforation of about 10 cms in its long axis recognized at laparotomy 10 days after the intervention. It is important to mention the perforation was repaired surgically and patient developed no post operative complications. Undesired complications though rare, are potentially fatal and risks need to be evaluated before performing all endoscopic procedures

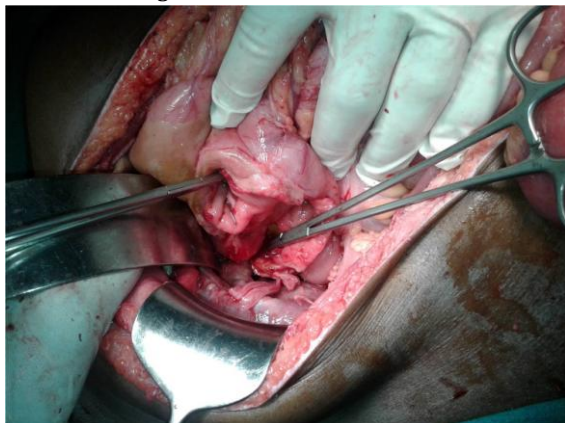
1. Introduction

Gastrointestinal endoscopy plays an essential role in the diagnosis, staging, and treatment of pathologies of the GI tract. New-generation endoscopes, advanced imaging technologies, the introduction of new therapeutic devices into clinical practice, and modification of old techniques have expanded both the diagnostic and therapeutic armamentarium of an endoscopist. Complications are rare with a rate of less than 1 per 5000 cases.

2. Case Report

A 56yr male presented to us with c/o pain upper abdomen for 1 day, acute in onset, severe and continuous which radiated to whole of the abdomen, associated with multiple episodes of vomiting. The patient had history of medical treatment for duodenal ulcer for past 1 month. The patient had undergone an upper GI endoscopy for bleeding duodenal ulcer 10 days before presenting to us. Records available mentioned use of electrocautery to achieve haemostasis in the bleeding ulcer.

Figure 1: Distended Abdomen



2.1. Examination

Patient was Febrile, PR was 108/min, BP-98/60, Abdomen was distended, with diffuse tenderness and guarding.

2.2 Investigations

Erect Skiagram of the chest revealed gas under diaphragm. Patient was taken up for emergency laparotomy.

2.3 Operative Findings

Around one litre of bilious fluid present in the peritoneal cavity with pus flakes present over the small bowel and parieties.

A perforation of size around 10 cm present in the long axis of duodenum over 1st and 2nd part.

Peritoneal lavage was done thoroughly. Billiroth II Roux-Y gastrojejunostomy was performed and patient had satisfactory postoperative course.

3. Discussion

Perforation related to diagnostic and therapeutic upper GI endoscopy is uncommon with an estimated frequency of 0.03 and mortality of 0.001% [1]. A history of recent trauma or instrumentation followed by pain and tenderness should alert the clinician to the potential for injury. Early identification and expeditious management of a perforation have been shown to decrease associated morbidity and mortality [2,3] Patients with gastroduodenal perforation usually present with abdominal pain and peritoneal irritation from leakage of acidic gastric contents. However, physical examination findings may be equivocal, and peritonitis may be minimal or absent, particularly in patients with contained leaks [4]. Unlike the more common spontaneous perforation resulting from peptic ulcer disease, iatrogenic perforations have a relatively lower chance of bacterial contamination due to the fasting patient [5]. Though less invasive procedures are preferred, in traumatic perforations of the second and third portions of the duodenum, resection with reconstruction is required.

4. Conclusion

Undesired complications though rare, are potentially fatal and risks need to be evaluated before performing all endoscopic procedures.

References

- [1] Silvis SE, Nebel O, Rogers G, Sugawa C, Mandelstam P. Endoscopic complications. Results of the 1974 American Society for Gastrointestinal Endoscopy Survey. *JAMA* 1976; 235:928.
- [2] Abbas G, Schuchert MJ, Pettiford BL, et al. Contemporaneous management of esophageal perforation. *Surgery* 2009; 146:749-55.
- [3] Lai CH, Lau WY. Management of endoscopic retrograde cholangiopancreatography-related perforation. *Surgeon* 2008; 6:45-8.
- [4] Fakhry S, Watts D, Daley B, et al. Current diagnostic approaches lack sensitivity in the diagnosis of perforating blunt small bowel injury (SBI): Findings from a large multi-institutional study. *J Trauma* 2001;51:1232
- [5] Solomon M, Schlachterman A, Morgenstern R. Iatrogenic Duodenal Perforation Treated with Endoscopic Placement of Metallic Clips: A Case Report. *Case Reports in Medicine*, vol. 2012, article 609750.