

QR CODE



Single Canal in a Single-Rooted Mandibular Second Molar: A Paradox

ANIL K TOMER¹, AKANKSHITA BEHERA^{*2}, NITISH MITTAL³, NUTAN INDWAR⁴A
B
S
T
R
A
C
T

During endodontic diagnosis multirooted teeth morphologically, shows variable root canal system. This case report explains the anatomical variations of root and root canals. Here it is shown that a single canal is present in mandibular second molar. Therefore we should be aware that a single canal can also be present in mandibular molar.

KEYWORDS: Mandibular second molar, C- shaped canal, Single canal

INTRODUCTION

For successful root canal treatment one must know the variation of canal systems. A clinician should have a thorough idea about the shape, form, and structure of the tooth. Taking proper radiographs can help us to know exact number of canals, length and any radiolucencies of the root. A define and clear radiograph is achieved by Radiovisiography (RVG) system.¹

The most captivating factor of RVG is we can manipulate the image after being captured. The only disadvantage is it provides a two dimensional image of a three dimensional object. The anatomical configuration is generally of two roots, mesial and distal. But due to varying in internal anatomy the mandibular molar can have a configuration of single c-shaped canal.²

Weine classified the root canal systems in any root into four types. Sometimes the canals may join giving a C-shaped canal.³ Vertucci type I canals were most frequently seen in these C-shaped molars.⁴

CASE REPORT

A 42 year-old male was referred for endodontic treatment. Patient had pain left mandibular posterior region. Intraoral periapical radiograph of the teeth revealed deep caries approximating the pulp (Figure 1).

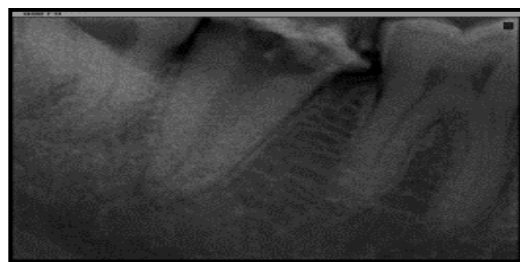


Figure 1. Pre-operative radiograph

Radiograph showed the presence of a single root with a wide canal. Access opening was done under local anaesthesia. A single round shaped orifice was seen. Working length was determined. Cleaning and shaping was done with proper irrigation (Figure 2).

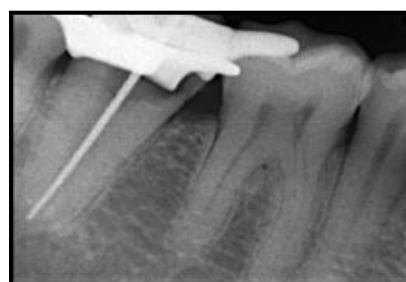


Figure 2. Working length determination

Obturation of the canal was done with obtura and warm vertical condensation technique (Figure 3). A post obturation radiograph showed a well obturated canal.

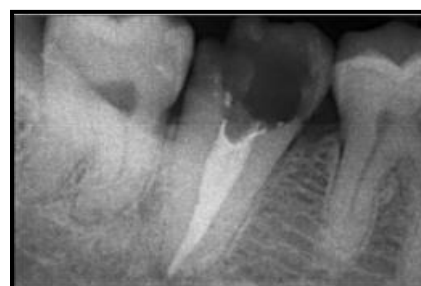

Figure 3. Obturation

DISCUSSION

The presence of web interconnecting the canals is the classic feature of a c- shaped canal.⁵ Pansiera & Milano studied 102 extracted human mandibular second

molars and described six teeth (5.88%) possessing one root and one root canal.⁶

On access opening the pulpal floor shows one canal with a round orifice. On further exploration the pulpal floor did not show any other orifice. The canals were wide. With copious irrigation, cleaning and shaping was done and the canals were then obturated with obtura with warm vertical compaction.

CONCLUSION

Proper knowledge of canal configuration and its variation in morphology is of great importance. The extra canals is not always the variation. The root canal morphology can also be in the form of single c-shaped canal. In order to achieve successful endodontic treatment we need to achieve a thorough cleaning and shaping of canals along with proper irrigation protocols.

REFERENCES

1. Fan W, Fan B, Gutmann JL, Fan M. Identification of a C-shaped canal system in mandibular second molars-Part III: Anatomic features revealed by digital substration radiography. *J Endod* 2008 ;34:1187-90.
2. Ingle's Endodontics, 6th edition, BC Decker Inc 2008; pp 209.
3. Cimilli H, Cimilli T, Mumcu G, Kartal N, Wesselink P. Spiral computed tomographic demonstration of C-shaped canals in mandibular second molars. *Dentomaxillofacial Radiology* 2005;34:164-7.
4. Rahimi S, Shahi S, Lotfi M, Zand V, Abdollahi M, Eshaghi R. Root canal configuration and prevalence of C-shaped canals in Mandibular second molars in an Iranian population. *J of Oral Sci* 2008;50:9-13.
5. Min Y, Fan B, Gary SP, Cheun G, Gutmann JL, Fan M. C-shaped canal system in mandibular molars part III: The morphology of the pulp chamber floor. *J Endod* 2006;32:1155-9.
6. Fan B, Cheung GSP, Fan M, Gutmann JL, Fan W. C-Shaped Canal System in Mandibular Second Molars: Part II—Radiographic Features. *J Endod* 2004;30:904-8.

Source of support: Nil, **Conflict of interest:** None declared

Cite this article as:

Tomer AK, Behera A, Mittal N, Indwar N. Single canal in a single-rooted mandibular second molar: A paradox. *Int Healthcare Res J* 2018;2(6):131-132. doi: 10.26440/IHRJ/02_06/195

AUTHOR AFFILIATIONS:

1. Professor and Head
2. PG Student
3. PG Student
Department of Conservative Dentistry and Endodontics, Divya Jyoti College of Dental Sciences and Research, Modinagar
4. BDS, Institute of Dental Sciences, Bhubaneswar, Odisha.

*Corresponding Author:

Dr. Akankshita Behera
PG Student
Department of Conservative Dentistry and Endodontics
Divya Jyoti College of Dental Sciences and Research
Modinagar, Ghaziabad, Uttar Pradesh 201204, India

For article enquiry/author contact details, e-mail at:
manuscriptenquiry.ihrj@gmail.com