


QR CODE



# Atraumatic Restorative Treatment: Review and a Case Report

VIKRAM ARORA<sup>1</sup>, RAVNEET MALHI<sup>2</sup>, VISHNU KARTHIK<sup>3</sup>, NASHI KAUL<sup>4</sup>, KHUSHBU BHAT<sup>5</sup>A  
B  
S  
T  
R  
A  
C  
T

Atraumatic Restorative Treatment (ART), which was introduced as field trials, have gained popularity among clinicians for their ease, minimal use of instrumentation and hence can be done in remote areas with little or no resources and can be used in patients with special needs, anxious and apprehensive patients in the dental setting. The present paper presents a case of modified ART (ARTm) with full patient satisfaction after a 3 month follow up, with a review of the same and the differences between ART and ARTm.

**KEYWORDS:** Atraumatic Restorative Treatment(ART), Modified ART(ARTm), GIC restoration.

## INTRODUCTION

Globally, tooth decay is one of the most chronic childhood diseases and is a major public health problem. Dental caries is the most widely spread oral disease, yet in underserved communities in both developing and industrialized countries, it tends to remain untreated. Dental caries (DC) is defined as “an infectious microbiologic disease of the teeth that results in localized dissolution and destruction of the calcified tissues”.<sup>1</sup> In order to meet the need for treatment of dental caries, Minimal invasive approaches such as partial caries removal techniques and Atraumatic Restorative Treatment (ART) present increased evidence of improved outcome over the conventional complete caries removal technique.<sup>2</sup> Atraumatic restorative treatment is actively promoted by the World Health Organization and is currently used in 25 countries and is part of regular oral personnel training.<sup>3</sup>

Atraumatic restorative treatment involves manual excavation of dental caries, which eliminates the need for anesthesia and restores the cavity with glass ionomer cement (GIC), an adhesive material that bonds chemically to the tooth structure and involves release of fluoride as it stimulates remineralization.<sup>4</sup> It is a non-invasive procedure due to which, it is highly acceptable to patients. It has therefore become possible to apply more conservative dental procedures, which allow preserving more dental tissues than in the

past.<sup>5</sup> Various studies document high survival rates of one-surface restorations<sup>6-9</sup> of ART in comparison to amalgam restorations.<sup>10</sup>

It is an exclusive method for prevention and control of dental caries in rural areas using hand instruments and in the absence of power supply .It act as an effective restorative practice; conserves more dental tissue than conventional dental treatment. In addition, it refutes the use of rotary equipment and local anaesthesia, which may contribute anxiety during dental treatment procedures.<sup>11-12</sup> This approach is a forward step towards achieving the goal that all people should retain as many teeth as possible: "Teeth for life".<sup>13</sup> The cost-effectiveness of this treatment also has been recognised,<sup>14-16</sup> considering costs of materials, equipment and wages. Therefore the Atraumatic Restorative Treatment (ART) was adopted not only because of its less discomfort, but also because of its minimal destruction of tooth structure and low cost.

## HISTORY OF ART

Approximately 25 years ago in Dar es Salaam, Tanzania, extraction was the preferred choice for carious teeth. However, after the results of the first pilot study, in which excavators were used to remove soft, completely demineralised dentine from 28 painful, dentine cavities that were then filled with polycarboxylate cement(which later

was changed to Glass Ionomer Cement) changed the dental scenario and the ART Technique was appreciated all over the globe. It was later observed that of the 28 teeth filled, only one needed to be extracted and while the 27 restorations showed signs of wear and tear, they were still functioning well, even after 9 months of follow-up.<sup>5</sup>

### CONCEPT OF ART

Defined as a minimally invasive care approach, ART helps in preventing dental caries, its further progression and related consequences. It consists of two components:<sup>7</sup>

- a) Sealing caries-prone pits and fissures, as well as,
- b) Restoring cavitated dentine lesions with the help of sealant/restorative materials(GIC).

For sealing of caries prone pit and fissures, a high-viscosity glass ionomer that is pushed into the suspected pits and fissures under firm finger pressure and allowed to dry. In a proper ART restoration, the use of hand instruments is advised which leads to the creation of sufficient access to the cavity for the removal of soft, completely demineralised (decomposed) carious tooth tissues followed by restoration of the cavity with an adhesive dental material (which chemically bonds to the tooth surface i.e. GIC) which simultaneously seals any remaining pits and fissures that remain at risk.

### ADVANTAGES OF ART

In areas especially where getting electricity is a challenge, or providing adequate dental manpower is not possible, this technique helps patients as it is a quick and efficient technique. Also, it prevents further progression of dental caries which, if left untreated, could lead to painful extractions. This technique was also found to be helpful in treating children, adults, people with special needs and apprehensive patients as there was no need to use an airtor, whose sound firstly causes fear in these people and secondly, even a slight movement of the patient could cause serious injury to the oral tissues.

### The new debate: ART Vs Modified ART (ARTm)

The term Modified Atraumatic Restorative Treatment (ARTm) was first introduced in the dental community in early 2000.<sup>17,18</sup> In this technique, a high-speed rotating diamond burr is allowed restricted use on enamel, as it lacks sensitivity and requires no use of anesthesia. This eliminates two main drawbacks of the original ART: manual fatigue of the operator and discomfort of the patient. These benefits were later confirmed by various authors and they documented that the use of dental equipment leads to better results.<sup>19,20</sup> It is to be noted that, just as in the original ART technique, removal of the affected dentinal tissue is done with hand instruments only.

Certain authors however, disagree to this fact and state that "Opening the cavity with rotating instruments, followed by cleaning it with hand instruments and restoring it with an adhesive restorative material, is not considered ART nor can calling it modified ART be justified".<sup>21</sup>

### CASE REPORT

A female, 18 years of age came to a dental setting situated in Panchkula, with a chief complaint of sensitivity in her lower back left tooth region. She was having a history of the same from past one year. The sensitivity increased with the consumption of both hot and cold beverage and relieved itself upon removal of stimuli. Test for Percussion (both horizontal and vertical) were negative. Upon clinical examination, a visible, carious lesion extending upto dentin was observed. (Figure 1). And hence, a treatment of Atraumatic Restorative Treatment (ART) was carried out, to cause least discomfort to the patient and cause minimal destruction to the tooth structure.

### TREATMENT DONE

After isolating the oral cavity, the soft caries was removed by the excavator. However, the distal wall comprised of undermined enamel, which could not be cleaned with the help of hand instruments. Therefore, in order to remove the

caries distally, a little enamel structure was removed with the help of an airotor, thus, making the technique a Modified ART (ARTm). After modifying the walls & excavating the caries (Figure 2), GIC restoration was done (Figure 3) and excess GIC was removed with finger pressure. Post operation instructions were given to the patient and the patient was asked to report back after 3 months. The patient was contacted after three months, and it was found out that she got married in another state, and she was happy with the treatment and did not report of any dislodgement or of any sensitivity in the concerned tooth.

## DISCUSSION

The present review and case report presents a case report of modified ART (ARTm) and discusses the current advantages and disadvantages of this procedure. ARTm is a beneficial procedure that sometimes, is needed as proper cleaning of the dental cavity and removal of undermining enamel cannot be done with the use of hand instruments. In the present case, the distal wall needed removal of the undermining enamel, and hence, ARTm was advised which was reported with full patient satisfaction after 3 months follow up.

It is suggested that in situations where proper cleaning of the dental cavity cannot be done due to undermining enamel, or any other reason, an airotor can be used only to remove the undermining enamel, and rest of the cavity preparation can be done with the help of hand instruments only.

## REFERENCES

- Barnes DE. Foreword: Proceedings of the International Association of Dental Research Symposium on Minimal Intervention Techniques for Dental Caries. *J Public Health Dent.* 1996;56(3 special issue):131.
- Santamaria R, Innes N. Trial shows partial caries removal is an effective technique in primary molars. *Evid Based Dent* 2014;15:81-2.
- Lopez N. Atraumatic Restorative Treatment for Prevention and Treatment of Caries in an Underserved Community. *American Journal of Public Health.* 2005; 95(8): 1338-9.
- Hat PK, Kumar A. Atraumatic Restorative Treatment A rural prospective. *Journal of health sciences and research.* 2011; 2(1): 29-32.
- Frencken JE, Leal SC, Navarro MF. Twenty-five-year atraumatic restorative treatment (ART) approach: A comprehensive overview. *Clin Oral Investig* 2012;16:1337-46.
- Phantumvanit P, Songpaisan Y, Pilot T, Frencken JE. Atraumatic restorative treatment (ART): a three-year community field trial in Thailand—survival of one-surface restorations in the permanent dentition. *J Public Health Dent.* 1996;56:141-5.
- Frencken J, Holmgren C. *Atraumatic Restorative Treatment for Dental Caries.* Nijmegen, The Netherlands: STI b.v.; 1999.
- Frencken JE, Makoni F, Sithole WD, Hackenitz E. Three-year survival of one-surface ART restorations and glass-ionomer sealants in a school oral health programme in Zimbabwe. *Caries Res.* 1998;32:119-6.
- Holmgren CJ, Lo EC, Hu D, Wan H. ART restorations and sealants placed in Chinese school children— results after three years. *Community Dent Oral Epidemiol* 2000;28:314-20.
- Mandari GJ, Frencken JE, Van't Hof MA. Six-year success rates of occlusal amalgam and glass-ionomer restorations placed using three minimal intervention approaches. *Caries Res.* 2003;37:246-53.
- Gonçalves CF, Silva MV, Costa LR, de Toledo OA. One-year follow-up of atraumatic restorative treatment (ART) for dental caries in children undergoing onco hematological treatment: A pragmatic trial. *BMC Oral Health* 2015;16:127.
- Costa LR, Cozac CD, Alves RT, Cortines AA. Tratamiento restaurador atraumatico para niños hospitalizados. *Rev Odontopediatr Latinoam* 2011;1:160-9.
- Frencken J, Pilot T, van Amerongen E, Phantumvanit P, Songpaisan Y: *Manual for the Atraumatic Restorative Treatment Approach to Control Dental Caries*, 3rd Ed. Groningen: WHO Collaborating Centre for Oral Health Services Research, 1997.
- Mjor IA, Gordan VV. A review of atraumatic restorative treatment (ART). *Int Dent J* 1999;49:127-31.
- Mickenausch S, Munshi I, Grossman ES. Comparative cost of ART and conventional treatment within a dental school clinic. *SADJ* 2002;57:52-8.
- Putthasri W, Pitiphat W, Phantumvanit P, et al. Cost-effectiveness analysis of using atraumatic restorative treatment (ART) technique compared

to conventional amalgam treatment. *J Dent Res.* 1998;77:1354.

17. Massara ML, Alves JB, Brandão PR. Atraumatic restorative treatment: clinical, ultrastructural and chemical analysis. *Caries Res.* 2002 Nov-Dec;36(6):430-6.

18. Massara MLA, Bönecker M. Modified ART: why not?. *Braz Oral Res.* 2012; 26(3):187-9.

19. Faccin ES, Ferreira SH, Kramer PF, Ardenghi, TM, Feldens CA. Clinical performance of ART restorations in primary teeth: a survival analysis. *J Clin Ped Dent.* 2009 Summer;33(4):295-8.

20. Honkala E, Behbehani J, Ibricevic H, Kerosuo E, Al-Jame G. The atraumatic restorative treatment (ART) approach to restorative primary teeth in a standard dental clinic. *Int J Paediatr Dent.* 2003 May;13(3):172-9.

21. Frencken JE, Leal SC. The correct use of the ART approach. *J Appl Oral Sci* 2010; 18(1):1-4.

**Cite this article as:**

Arora V, Malhi R, Karthik V, Kaul N, Bhat K. Atraumatic Restorative Treatment: Review and a Case Report. *Int Healthcare Res J* 2017;1(4):24-7.

**Source of support:** Nil, **Conflict of interest:** None declared

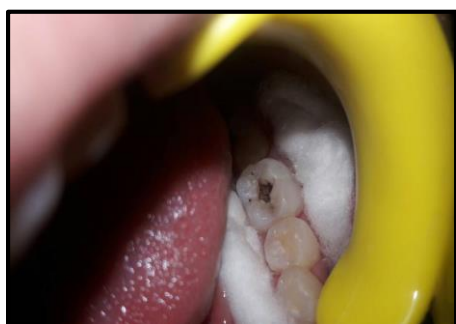**AUTHOR AFFILIATIONS:**

1. MDS(Public Health Dentistry), Private practitioner, New Delhi
2. Senior lecturer , Department of Public Health Dentistry, BRS Dental College and General Hospital, Sultanpur (Panchkula), India
- 3,4,5 Intern, Swami Devi Dyal Hospital and Dental College, Panchkula, India

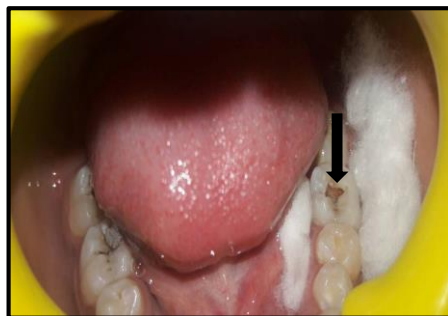**Corresponding Author:**

Dr. Vikram Arora  
B-2/11, Mandir Marg, Lal Quarter  
Krishna Nagar, Delhi, 110051  
+91 931111060  
[docvikarora@yahoo.in](mailto:docvikarora@yahoo.in)

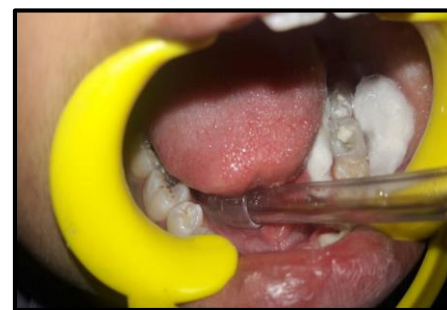**LEGENDS**



**Figure 1.** Clinical view of the carious lesion



**Figure 2.** Removal of caries using spoon excavator. The black arrow depicts undermining enamel on the distal wall.



**Figure 3.** Restoration of the cavity using GIC