

The College at Brockport: State University of New York Digital Commons @Brockport

Senior Honors Theses

Master's Theses and Honors Projects

5-14-2018

Distal Biceps Tendon Ruptures: A Comparison of Surgical Techniques and Outcomes

Alexandra Bednarz

The College at Brockport, alex7449@gmail.com

Follow this and additional works at: <https://digitalcommons.brockport.edu/honors>



Part of the [Exercise Science Commons](#)

Repository Citation

Bednarz, Alexandra, "Distal Biceps Tendon Ruptures: A Comparison of Surgical Techniques and Outcomes" (2018). *Senior Honors Theses*. 228.

<https://digitalcommons.brockport.edu/honors/228>

This Honors Thesis is brought to you for free and open access by the Master's Theses and Honors Projects at Digital Commons @Brockport. It has been accepted for inclusion in Senior Honors Theses by an authorized administrator of Digital Commons @Brockport. For more information, please contact kmyers@brockport.edu.

Distal Biceps Tendon Ruptures: A Comparison of Surgical Techniques and Outcomes

A Senior Honors Thesis

Submitted in Partial Fulfillment of the Requirements
for Graduation in the Honors College

By
Alexandra Bednarz
Athletic Training Major

The College at Brockport
May 14, 2018

Thesis Director: Dr. Timothy Henry, Associate Professor, Athletic Training

Educational use of this paper is permitted for the purpose of providing future students a model example of an Honors senior thesis project.

Introduction:

Distal biceps tendon ruptures are sustained when an elbow is in a flexed and supinated position and is subjected to a rapid eccentric load, forcing the elbow into extension while the biceps brachii muscles are actively contracting.^{4,5,6,8,10,13} When this force is applied the distal biceps tendon usually will detach cleanly from the radial tuberosity, otherwise known as a tendon rupture.^{5,6}

This injury is considered to be rather uncommon, occurring in approximately 1.2- 5.4 per 100,000 people in the general population, and makes up only 3% of all bicep tendon ruptures.^{2,3,4,5,7,8,9,10,13,14,} Distal biceps tendon ruptures are most typically seen in males who are in their 4th to 6th decade of life and are heavy laborers, weight lifters, use anabolic steroids, or smoke.^{4,5,14,3,6} It has also been noted that when a distal biceps tendon rupture occurs, it is most likely to occur in the dominant arm.¹³ Additionally, in part because of how uncommon distal biceps tendon ruptures occur, diagnosis of the injury may be delayed as opposed to other similar, but more common orthopedic injuries.² In order to diagnose this injury, special tests, diagnostic imaging, and an arthroscopic evaluation may be done.

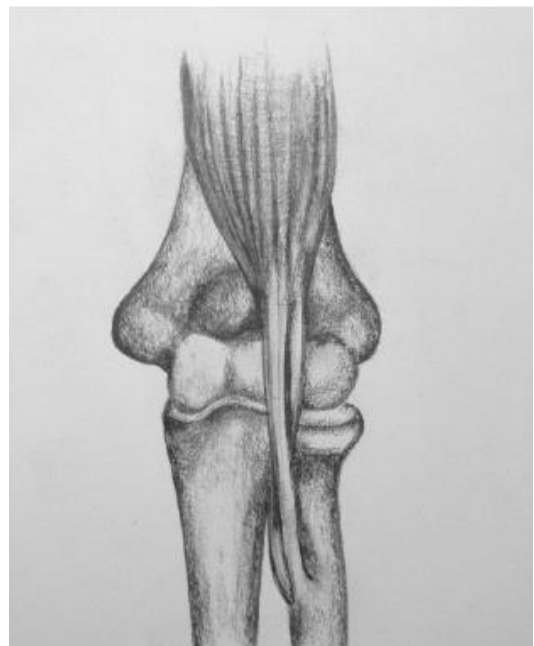
Once a person has been diagnosed with a distal biceps tendon injury, they can either pursue a conservative non-operative treatment or surgical repair. While both options have their pros and cons, the needs of the patient are a major consideration when making the decision of which route to take. For those who choose to have a surgical repair, they may receive one of the many surgical techniques available.¹¹ Because of the rarity of this injury, there is no one surgical method that is considered to be a “go to” standard fixation technique, additionally there are new methods of fixation that have been developed.⁶ The goal of this thesis is to determine which surgical method may be the ideal fixation technique for the distal biceps tendon rupture, this is to

be done by reviewing current literature discussing the many options available and using this information in conjunction with the anatomy and pathology involved with the injury.

Overview of Anatomy:

The distal biceps tendon is the tendon that attaches the biceps brachii to the lower arm. The point of attachment is on the radial tuberosity, which is a bony prominence on the proximal radius just below the radial head and neck.⁶ The biceps brachii is made up of two muscles, which may or may not present as one solid muscle.⁷ The muscle has two points of origination, with the long head originating from the supraglenoid tubercle and the short head originating from the coracoid process.⁷ Below the origination points of the two heads of the muscle, they will typically merge near the area of the deltoid tuberosity of the humerus, although as mentioned previously, this does not occur in every person.⁷ Due to the muscle's points of origin and insertion, it acts on three joints of the body: the glenohumeral, ulnohumeral, and proximal radio-ulnar.⁷

The distal biceps tendon was once thought to be one singular homogenous tendon, although recent studies have shown that it is comprised of two individual tendons, that may be clearly separated or appear to be more cohesive as a singular unit.^{6,7,10} The attachment sites of the two parts of the tendon, regardless of if they present as a single tendon or as two separate tendons, are very distinct and allow different forces to be applied to the arm. The tendon of the short head of the biceps has been found not



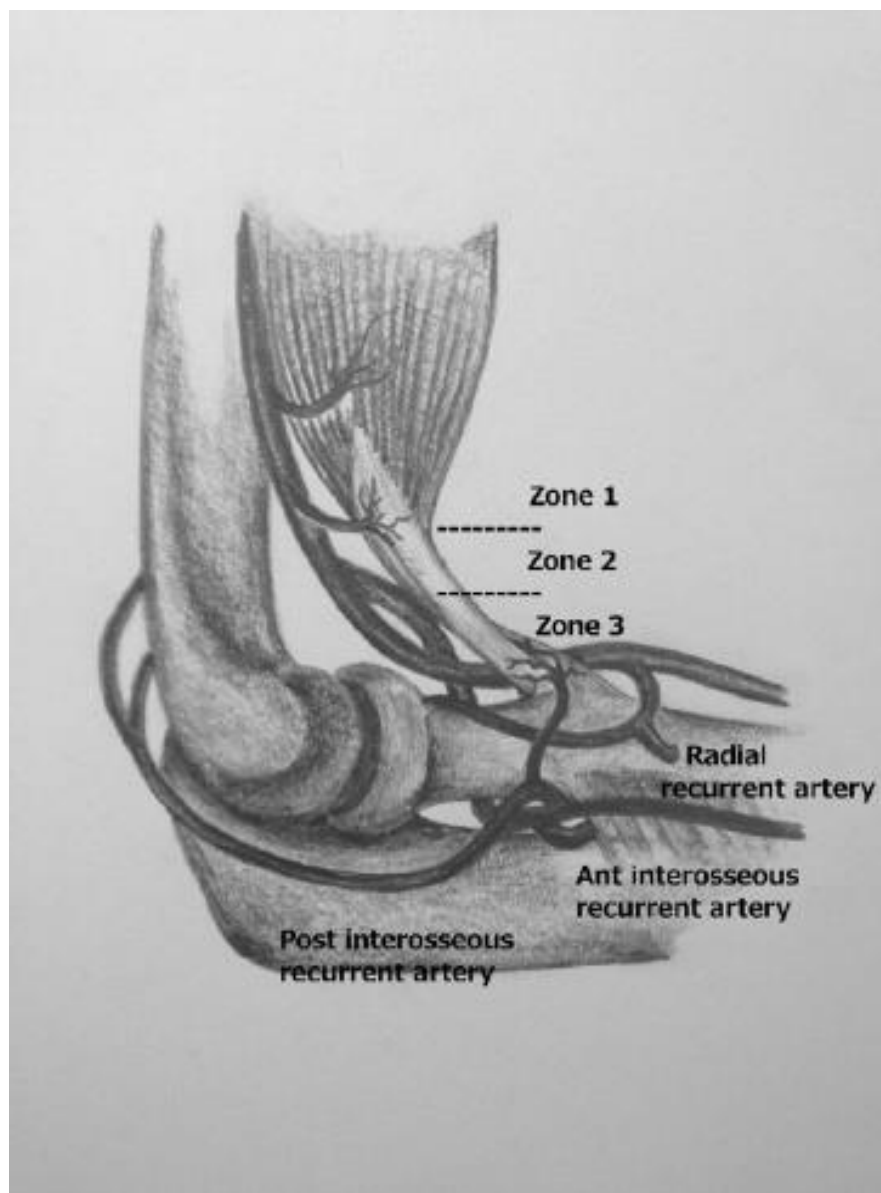
only to have a larger insertional footprint, but to also insert more distally and anteriorly on the radial tuberosity, and cover more of the apex of the tuberosity than the long head.^{6,7,10} Because of the short heads position on the radial tuberosity, it supinates the forearm most efficiently in a neutral or pronated position and has increased strength during elbow flexion.^{6,10} The long head is believed to have a larger strength contribution to supination of the elbow, but because of the more proximal location of its insertion onto the tuberosity, it acts most efficiently when the lower arm is in an already supinated position.^{6,10} Because of the separate nature of the tendons and the differing contributions to arm movement, restoring the tendon back to its original anatomical arrangement during surgical fixation is very important.⁷

At the proximal end of the distal biceps tendon at the musculotendinous junction, is the bicipital aponeurosis or lacertus fibrosus.^{6,7,10} The bicipital aponeurosis is made up of three layers. The first layer is the thickest one and originates for the anterior aspect of the long head of the biceps brachii and travels diagonally towards the musculotendinous junction of the short head.⁷ The second and middle layer, which may or may not be present, and acts as a small mesentery.⁷ The third and deepest layer follows the same path as the first layer, but passes along to the short head tendon.⁷ After this, all the layers join and pass distally to its large point of insertion.⁷ The insertion of the bicipital aponeurosis consists of completely encircling the forearm flexors and antebrachial fascia.⁷ Because of the area covered by the bicipital aponeurosis, it serves as a stabilizer of the distal biceps tendon.⁷ Although it can act as a stabilizer for the distal biceps tendon, when the forearm flexors contract the bicipital aponeurosis becomes tense, and due to its non-elastic nature, a medial pull is placed on the distal biceps tendon, which may play a contributing role to a rupture of the tendon.⁷ It has also been

suggested, that due to the supportive nature of the bicipital aponeurosis, when a distal biceps tendon reconstruction is done, repairing the bicipital aponeurosis would also be beneficial and strengthen the repair done to the tendon.⁷ At the point of insertion, the distal biceps tendon is surrounded by the bicipito-radial bursa.⁷ The bursa is tear drop shaped and is located directly over the tendon, during elbow extension the bursa lays below the brachialis muscle and the distal tendons, when the forearm is pronated the bursa is then located between the proximal radius and biceps tendon.⁷ Like all other bursas within the body, its main function is to provide smooth, reduced friction, movement between the structures it comes in contact with.⁷

The nerves that pass through the biceps brachii and the cubital space are significant factors to the surgical repair of the distal biceps tendon.⁷ The biceps brachii muscle is innervated by the musculocutaneous nerve, which is a branch of the brachial plexus.⁷ Another nerve that is in close proximity to the distal biceps tendon is the radial nerve, which is located between the brachialis and brachioradialis in the cubital space.⁷ The radial nerve divides into the radial sensory and posterior interosseous nerve.⁷ The posterior interosseous nerve travels through the supinator muscle and wraps around the radial tuberosity near its midpoint.⁷ The posterior interosseous nerve acts purely as a motor nerve, as it supplies the extensors of the forearm and fingers.⁷ When the posterior interosseous nerve is damaged the finger and wrist cannot fully extend properly.⁷ Additionally, in the area of the cubital space is the lateral antebrachial cutaneous nerve, which is the terminal branch of the musculocutaneous nerve.⁷ The lateral antebrachial cutaneous nerve runs alongside the cephalic vein in the anterolateral aspect of the elbow and is located on the deep fascia and within the adipose tissue of the area.⁷

Blood supply to the tendon is unique and in a way similar to the blood supply of the meniscus, as the whole tendon is not directly vascularized.⁷ The blood supply is divided into



three areas. The first and most proximal zone receives blood from the brachial artery via branches that reach across the musculotendinous junction in a distally moving direction.⁷ The branches of the brachial artery within the first zone, supply blood to the main part of the tendon.⁷ The third and most distal zone receives a blood supply from branches of the posterior interosseous recurrent artery and is limited to the insertion

site of the tendon.⁷ The second and middle zone is supplied by both the first and third zones indirectly through a sheath covering the tendon.⁷

Pathology:

With an understanding of the anatomy that pertains to the distal biceps tendon, including the biceps brachii muscle, the tendon composition of two unique tendons, and the other surrounding structures, the anatomy that is damaged with the injury can be understood. Because this injury is specific to one tendon and its junction with its boney insertion, there is little other anatomy involved directly with the injury. Additionally, while reviewing literature pertaining to the injury, there was very little mention of any additional tissues and structures that may be damaged along with the distal biceps tendon. Because of this, it should be safe to assume that the body would respond to this injury the same way it would to many other orthopedic injuries. As with any acute traumatic injury there are additional bodily reactions that will occur as a part of the acute inflammatory response. When the injury initially occurs, it is rather common for the tendon to separate cleanly from the radial tuberosity, as opposed to rupturing at the musculotendinous junction or avulsing a part of the radial tuberosity along with the rupture.^{5,6} When the tendon fully separates away from the radial tuberosity it is likely that the muscle will retract up into the arm, as it no longer has the attachment site maintaining its constant normal length.⁶ This retraction later becomes a problem if a surgery is delayed for an extended period of time, such as if the person who sustained the injury is being treated through a workman's compensation case.^{1,6} With more retraction of the muscle into the arm, the muscle tissue can develop a muscle contracture and become shorter in length. Additionally, as the muscle retracts up into the arm the tendon will follow, therefore when the surgery begins, the surgeon will need to be more invasive to grasp the tendon.

Etiology:

Although this injury is rare, the mechanism that causes the injury is very well understood. The typical mechanism for this injury is a sudden eccentric, downward, force placed on the lower arm when the elbow is being actively flexed and supinated.^{4,5,6,8,10} The rupture of the tendon is the result of the forces acting on the taut tendon. In biomechanical testing to evaluate the strength of the distal biceps tendon, it was observed that an intact tendon can withstand forces up 210 to 221 N.¹ With this knowledge, it can be understood that when the forces from the active biceps brachii contraction and the sudden eccentric forces placed on the lower arm combine to exceed 221 N, a ruptured distal biceps tendon is likely to result.

Risk Factors:

As with any injury, there are certain risk factors that may predispose or increase the likelihood that a person will sustain this specific injury. With distal biceps tendon ruptures there are some risk factors that are known to be associated with a higher risk of rupture, and there are other risk factors that are not yet proven to be directly associated with the injury, but show a high correlation.

The largest risk factors that are very well known to increase the likelihood that a person will have a distal biceps tendon rupture are, being a male and being between the ages of 40 and 60.^{3,4,5,6,14} These risk factors are so highly associated with this injury because, males account for 96% of the population seen with this injury and approximately two thirds of all distal bicep tendon ruptures occur in people between the ages of 35 and 54.⁴ Although males account for such a large percentage of the patients that sustain this injury, it has been suggested that distal biceps tendon ruptures in women are more likely to be partial tears which may present with more

gradual symptoms, this could make diagnosis more difficult and result in a large number of cases going unrecorded.⁴ The correlation between this injury and age has been shown to be due to the degenerative changes that take place in the body. Studies have shown that degenerative changes to tendon have been seen in people as early as 40 years old, which directly impacts the chances of a person having a distal biceps tendon rupture.⁴

Because distal biceps tendon ruptures are orthopedic injuries, physical activity level has a degree of association. Ruptures of the distal biceps tendon have been seen to occur more often in heavy laborers and weight lifters, as they are more likely to place high forces on their arms that the tendon cannot withstand.⁵ While it is known that males are far more likely to have this injury, as discussed previously, a fairly recent increase in females rupturing their distal biceps tendon has been seen.⁸ It is suggested that a reason for the increase in elbow injuries, especially of the distal biceps tendon, may be due to an increase in physical activity.⁸

Some of the risk factors that have been seen to be associated with distal biceps tendon ruptures, but have yet to be proven to correlate as strongly as the previous risk factors, include cigarette use, anabolic steroid use, and an elevated body mass index (BMI).^{4,5,6,14} Tobacco use has been associated with a 7.5 times greater risk of rupture, but records have not been maintained well enough in databases to allow for an accurate value of risk association.⁴ It is believed that when a person has a habit of smoking, the hypovascular zone located between the distal and proximal portion of the tendon, will actually increase in size.⁴ This increased zone of hypovascularity could lead to unhealthy changes in the tendon. Additionally, smoking has been seen to increase the risk of rerupture following the surgical repair.¹⁴ This increased risk due to smoking is once again linked to tobacco's effect on the blood supply to the tendon. Following the surgical repair of the ruptured distal biceps tendon, when nicotine is used, the development of

new blood vessels needed for proper tissue healing is compromised.¹⁴ Because of this disrupted blood supply, there is a 5 times higher risk of rerupture in smokers, when compared to non-smokers.¹⁴ Another drug that has been thought to be a risk factor for tendon rupture, although not proven, is the use of anabolic steroids.^{5,6} Obesity, also has been shown to be a possible predisposition. One study, consisting of 69 patients, recorded the BMI of their patients and found that only six of the patients had a healthy BMI, while 17 were considered over weight, and the remaining 46 were considered obese.⁴ It has been suggested that maintaining an increased BMI will increase the load placed on the on the tendon, resulting in a predisposition for a tendon rupture.⁴

In addition to the previously discussed risk factors, it has been suggested that the actual anatomy of the junction between the distal biceps tendon and the radial tuberosity may lead to ruptures of the tendon.⁷ Researchers have hypothesized that the shape of the radial tuberosity, which may lead to impingement and inflammation, can predispose a person to a distal biceps tendon rupture.⁷ Mazzucca et al.⁷ has described three different types of radial tuberosities: the first being made up of two separate ridges, the second being entirely smooth and having no ridges, and the third having only one ridge. The presence of the ridge on the radial tuberosity has been shown to act as a pulley, which will actually increase the mechanical advantage of the musculotendinous unit.⁷ To add on to this finding, it has been noted that when the lower arm moves into pronation, not only does the radius rotate over the ulna, but the distal ulna actually moves laterally in relation to the radius.⁷ When this movement occurs during pronation, the space available between the ulna and radial tuberosity will decrease by up to 50%.⁷ With this naturally decreased space taken into consideration, when a person has an exceptionally large

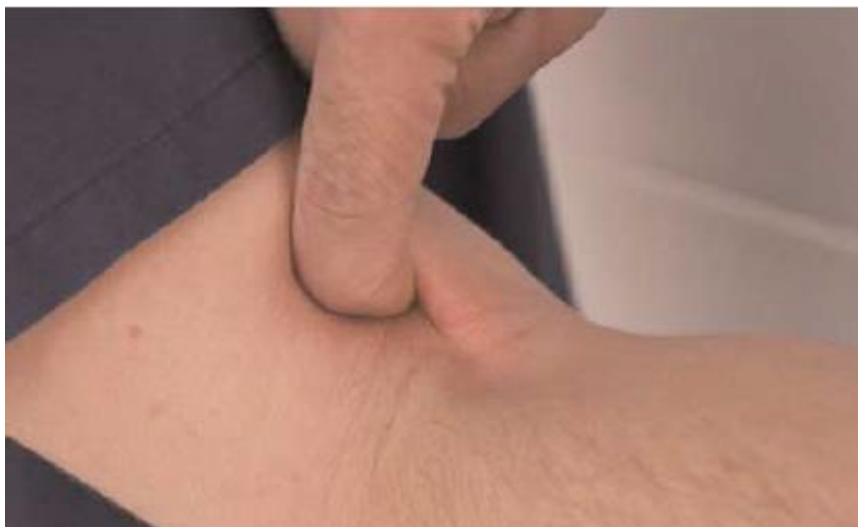radial tuberosity or any inflammation of the tendon, further impingement can occur reducing the space available even more and increasing the possibility of rupture of the distal biceps tendon.^{6,7}

Diagnosis:

When any serious injury occurs, proper diagnosis is necessary for a proper treatment and return to normal function. The diagnosis of a distal biceps tendon rupture is fairly simple and has some very reliable methods of testing. Before any tests are done, because of how unique, and also traumatic, the injury is once the history and symptoms of the injury are known, a health care provider may already know exactly what the diagnosis will be.

The signs and symptoms a person that has ruptures their distal biceps tendon would present with include: pain, swelling, ecchymosis, weakness with elbow flexion and forearm supination, possible cramping in their arm, and also a deformity if the tendon has fully separated from the radius, although even with a full rupture, an intact bicipital aponeurosis may limit the retraction of the tendon.^{6,10} When a patient describes these symptoms and how the injury was sustained, the examiner should know what the injury is or have it included in their differential diagnosis. During the examiner's evaluation one special test should be done, which specifically

test for the presence of an intact distal biceps tendon, this test is known as the hook test.^{4,10} The hook test is very reliable, having a 100% sensitivity, which is the ability of the test to identify If a person has a



specific injury or not.⁴ To perform the hook test, the examiner will flex the patient's elbow 90 degrees, with the patient's arm in this position from the lateral side, the examiner should be able to hook their finger under the distal biceps tendon.¹⁰

Even though the hook test has such a high level of sensitivity, prior to arranging a surgery to repair the distal biceps tendon, the doctor will most likely require some form of diagnostic imaging to see the damaged tissues. The most common methods of diagnostic imaging used are ultrasound and magnetic resonance imaging (MRI).^{2,10,6} When an MRI is requested, the technician will typically place the patient's arm in a position referred to as FABS, which means a flexed elbow, abducted shoulder, and the forearm fully supinated.^{6,10} With the arm in the FABS position, the doctor is able to see a full longitudinal view of the distal biceps tendon, which may be very useful when diagnosing partial tears.^{6,10} Typically, the findings seen in an MRI or ultrasound will show absence of the tendon at its insertion on the radial tuberosity, a large mass in the antecubital fossa, fluid in the distal biceps tendon sheath, reduced thickness of the tendon itself, and an altered texture of the actual tendon.⁶

Unfortunately, due to how rare this injury is, and although the history, signs and symptoms are rather unique, diagnosis is often delayed.² This may be attributed in part to the rarity, which could cause the initial examiner to not even think of considering a distal biceps tendon rupture in their differential diagnosis during their evaluation. When the diagnosis is delayed, the tendon is likely to retract up substantially, resulting in a more difficult surgical repair.² Early detection and therapy of this injury is essential to obtain the best clinical and functional outcomes possible.²

Treatment Options:

As with most traumatic injury which results in significant anatomical damage, there are surgical options as well as a conservative non-operative option, a ruptured distal biceps tendon is no different. When surgery is chosen, there are two variables associated with the actual surgical repair: incision type and method of tendon fixation. When the injury is more complicated, such as when it is a chronic re-rupture or if an allograft or autograft is needed, there may be more variables, but this paper is focusing on a simple acute rupture. The incision options available consist of a single incision method or a double incision method. The options available for fixation method is where more variety exist. The most common choices for fixation of the distal biceps tendon include interosseous tunnel, interference screw, cortical button, or a cortical button with an interference screw. With each option available for the surgical repair, there remains the same final goal and result, to repair the damaged tissue and restore to the natural anatomy and function as much as possible. It has been reported that to deem a surgical repair of the distal biceps tendon rupture as satisfactory it must meet the following criteria: less than 30° of motion lost in elbow flexion, extension, pronation, or supination and return of strength within 80% of the uninjured arm.¹

When anyone sustains an injury, they naturally have the option to seek treatment or not based on their own thoughts, the same goes for surgical treatment. With distal biceps tendon ruptures, this stays true. When the rupture consists of less than 50% of the thickness of the distal biceps tendon, it is recommended that the injury is treated non-operatively.¹⁰ Conservative treatment of a tendon rupture consists of temporary immobilization followed up with rehabilitation, with a focus on active and passive range of motion and strengthening exercises.⁶ As discussed previously, the main function of the biceps brachii is supination and elbow flexion,

so naturally when the muscle is no longer attached to the radius, these movements will be significantly limited. Fortunately, elbow flexion and supination would not be totally lost with a distal biceps tendon rupture, as muscles such as the brachioradialis, supinator, and brachialis. It has been shown that with conservative treatment a person can expect to experience strength similar to those that have had a surgical repair, although strength will be reduced, especially with supination.¹⁰ One study found that when compared to patients that had undergone surgery to repair the ruptured tendon, the patients that did not have a surgery performed displayed supination strength 63% when compared to the uninjured arm, while the surgical repair patients displayed 92% supination strength compared to the other arm.^{8,10} Additionally, patients who were treated non-operatively may expect residual pain that would not exist if they had gone through the surgery.¹⁰ Those that wish to choose the conservative route are usually in their later stages of life and can continue get through their activities of daily living, with this limitation. Because this injury is likely to occur in men who are at least 40 years of age, it is likely that some of those that rupture their distal bicep tendon have reached an age where undergoing a surgery and the follow up rehabilitation is not worth risking surgical complications, that include heterotopic ossification, nerve injury, or scar formation.

If a patient decides that the surgical route is the better option for their needs, there are many options for the surgeon to pick from in order to repair the ruptured tendon. The first large decision is which method of fixation to use for the re-attachment of the tendon to its anatomical position, with the fixation method determined the appropriate incision method will be known.¹ The most common methods available for distal biceps tendon fixation include, interosseous tunnel, interference screw, cortical button, or a cortical button with an interference screw. Regardless of how rare a distal biceps tendon rupture is, the surgical repair of the rupture is a

well-accepted procedure and the standard care for the injury, and the fixation provided by the multiple varying options available has overall been shown to provide the patient with both a good clinical outcome and level of function.^{2,4} With how many options are available it would be beneficial to know which one could act as the preferred method, based on multiple factors such as complications associated, strength of the fixation, invasiveness, and even cost.

Although the incision method is known based on which fixation technique is used, the two different incision methods will be discussed before the surgical methods. The two different incision methods are single incision and double incision, each method has its own benefits and downfalls and is associated with specific fixation methods.^{1,2,3,6,8,9,14,10} The single incision method can be used with the cortical button, cortical button and interference screw, and suture anchor fixation techniques.^{1,2,3, 9,10,11,12,14} The double incision method is used for the interosseous tunnel fixation technique.^{1,2,3,9,10,11,14}

The single incision method was the original method used for distal biceps tendon ruptures.^{3,6} The single incision is made in the just distal to the antecubital fossa, in either an S shape, horizontal line, or vertical line.^{2,6,10} The variation in the shape of the incision is based on surgeon preference and has no connection to outcome measures. The largest downfall that is most commonly associated with the single incision method is a high occurrence of nerve injuries, due to the requirement of the extensive degree of dissection and traction placed on the nearby tissues.^{3, 9,10,14,16} When a single incision method is used the most commonly effected nerve is the lateral antebrachial cutaneous nerve, and the second most effected nerve is the superficial branch of the radial nerve.^{1,3,6,9,10} Studies have shown that there is approximately a 30% chance of the patient developing a nerve palsy, as opposed to the 11% chance that is associated with the double incision method.³ Although, there is a higher chance of a nerve injury occurring with the

use of a single incision, the damage is usually just temporary. When a patient experiences this transient nerve damage, it can be expected to last up to about 5 months, and it has been noted that most of the nerve injuries will completely resolve without treatment by the time the patient is discharged of all medical care for their distal biceps tendon rupture.³

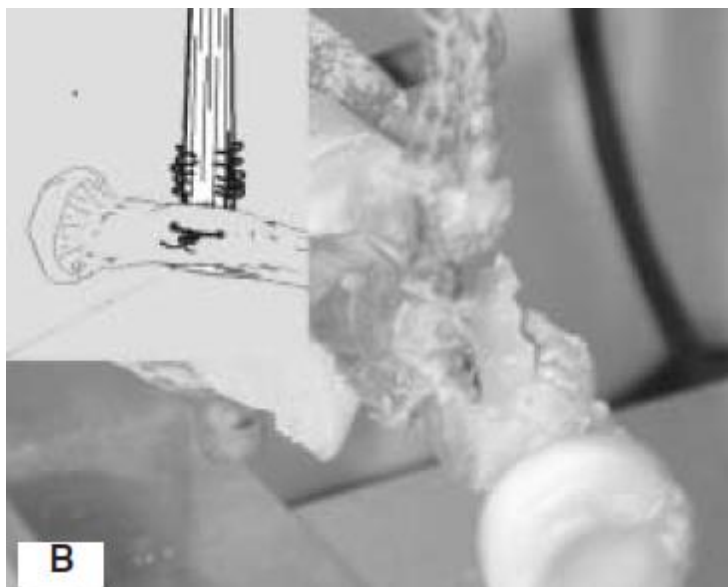
The double incision method was developed in 1961 by Boyd and Anderson with the intention of reducing the amount of injury causing stress on the lateral antebrachial cutaneous and superficial radial nerves while also allowing a more anatomical repair of the distal biceps tendon.^{1,2,3,5,6,9,10,13,14} It is believed that a more anatomical repair is possible with the double incision method, because of the posterior approach that is allowed due to the second incision made during the repair.¹⁰ The double incision method is performed by beginning with one single incision just distal to the antecubital fossa, in the same manner as the single incision method.² The second incision is made on the posterolateral aspect of the elbow with the arm in full pronation.² Because the second incision allows for posterior access to the fixation site of the ruptured tendon, less traction needs to be placed on to the tissues near the anterior incision. Although the double incision method is associated with a lower risk of damage to the lateral antebrachial cutaneous and superficial radial nerves, there are other complications more commonly seen with the use of this method. The most common complications associated with the double incision method include heterotopic ossification, radioulnar synostosis, posterior interosseous nerve palsy, and a reduction in supination range of motion.^{1,3,5,6,9,10,14} Heterotopic ossification and radioulnar synostosis stem from the aggressive handling of the interosseous membrane during the fixation of the distal biceps tendon.¹⁴ Heterotopic ossification can present in a patient as ectopic bone formation in the tissues surrounding the fixation site or as an incomplete or even complete radioulnar synostosis, the development of heterotopic ossification

can result in varying degrees of forearm stiffness.⁶ The rate of heterotopic ossification formation ranges from 2% to 10%, with an average of 7.6%, although this number may be low as patient do not typically receive radiographs following the surgery unless they are symptomatic.³ Although heterotopic ossification is considered a complication, it may not always be considered a complication. When the heterotopic ossification is asymptomatic, meaning it is not a cause of pain or results in a loss of motion greater than 30 degrees in any plane of movement, it is not to be considered a complication.¹ Reduction in supination range of motion as a result of a double incision method is believed to be due to the dissection of the space between the posterior radius and ulna.¹ Studies have shown that 9% of distal biceps tendon repair patients will develop some degree of supination range of motion restriction, 6% of this can be attributed to the development of heterotopic ossification.¹ Similarly to the nerve palsy complications that result from the single incision method due to the traction placed on the nerves near the incision, transient nerve palsy of the posterior interosseous nerve is a complication associated with the double incision method.^{3,5,6} The rate of a patient developing posterior interosseous nerve palsy as a result of the double incision method is 1.3%.³

Both of the incision methods available for the many fixation methods for distal biceps tendon ruptures have their unique qualities and downfalls. Although they have differing complications, both the single and double incision methods have complication rates with no statistically difference.¹⁴ The overall complication rate associated with the single incision method is 18%, while with the double incision method the complication rate is 16%.¹⁴

The first method to be discussed would be the interosseous tunnel. This option of fixation uses the double incision method.^{1,2,3,9,10,11,14} When this method of fixation is used, there are slight variations that may occur, but they all still use the same basic method. Other names

that may be associated with this fixations technique include: bone bridge, transosseous, or bone tunnel.^{1,2,3,5,6,9,11,14} The interosseous tunnel method of fixation is performed by first making an anterior incision, as described previously, which allows the surgeon to find and freshen the stump of the distal biceps tendon by passing sutures through the end of it.² After the tendon is found and prepared for the fixation, the radial tuberosity is cleaned of any residual tissue and a ¼ inch drill bit is used to create the bone tunnel in the center of the radial tuberosity.^{5,9} Then two smaller holes are drilled on the radial side of the tuberosity, which connect to the larger hole previously made.^{5,9} In order to ensure that the two smaller holes are strong enough to serve as a proper method of fixation, the holes are made exactly 7 mm from the edge of the bone tunnel and 8mm of space is left between the two holes.^{5,9} Once the holes are made in the radial tuberosity, the ends of the sutures which had already been placed into the tendon, are passed between the radius and ulna through the second incision on the posterolateral aspect of the forearm while it is in a position of full pronation.^{2,9} The suture ends are then pulled into the bone tunnel and out through the two smaller drill holes.⁹ The ends of the sutures are then tied across bone bridge that



now exist between the bone tunnel and the smaller holes on the radial tuberosity, consistent tension is placed on the ends of the sutures to pull the tendon into the bone tunnel to ensure a secure fixation.^{5,9} The interosseous tunnel fixation technique is used in approximately 15% of distal biceps tendon rupture

surgeries.¹⁴ Following the repair of the ruptured tendon with the interosseous tunnel technique, biomechanical testing has shown that when tested to failure, the ultimate tensile load is 125-210 N with a stiffness of 15.9 N/mm.¹ When the same tests were done on an intact distal biceps tendon, the ultimate tensile load to failure was 210-221 N and a stiffness of 30 N/mm.¹ This biomechanical testing demonstrates that the interosseous tunnel method may not be as strong as the original distal biceps tendon was before the rupture, but the new method of fixation will allow the tendon to now withstand forces similar to that of the original tendon.

Although the interosseous tunnel fixation method may not be as strong as a natural intact distal biceps tendon, there is still a very low rate of rerupture. Studies have shown either zero reruptures in their patients or at the highest, 2.8%.^{2,3} Reruptures will most often occur within the first three weeks following the surgery, and is attributed to patient compliance and excessive force placed on the new repair.³

In a study done by Lemos et al.⁵, to observe the strength of the interosseous tunnel fixation technique, the repair was considered to be a failure when there was a displacement of 10 mm or greater, suture breakage, tendon-suture interface disruption, or bone tunnel fracture. When failures were seen, they occurred as a result of bone failure at the bone bridge.⁵ This is thought to happen because the largest hole drilled into the radial tuberosity creates a stress riser that weakens the entire radial cortex.⁵ Although this study was performed using cadaveric arms, the researchers believe that if a large stress is placed onto the repair shortly after the repair, and the tendon returns to contact with the radial tuberosity, healing will likely occur and result in no long term damage.⁵ Because the failure of the repair would occur at the site of the bone bridge, in patients with a higher bone density, fixation would remain stronger.⁵

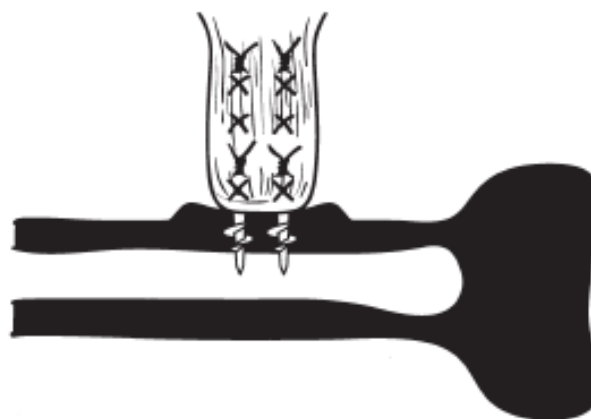
When the interosseous tunnel fixation method was used to repair the ruptured distal biceps tendon, 69% of the patients were satisfied with their outcomes while 31% of the patients were not satisfied.¹ The unsatisfactory outcomes with were attributed to a loss of forearm rotation or loss of rotational strength.¹ Even at the one year follow up, the interosseous tunnel had many dissatisfied patients, which was still related to the loss of forearm strength or rotational strength.¹ The average post-operative arc range of motion seen following the interosseous tunnel technique was seen to be 3.5 to 132.9 degrees.³

The Disabilities of the Arm, Shoulder, and Hand (DASH) scores have been recorded following a surgical repair of a distal biceps tendon rupture, the score consists of measuring range of motion, strength measurements, and patient ratings of pain with daily activities.¹¹ When scores are calculated, 0 is the preferred score meaning there is no disability or symptoms, with 100 being the highest score meaning there is a high level of disability or symptoms.² The DASH scores recorded following an interosseous tunnel fixation have been to seen to vary from as high as 15.4 to as low as 5.7.^{2,11}

The next surgical option to discuss is the interference screw fixation method. This paper will combine the suture anchor and interference screw methods into one category, because they are very similar as they both anchor a suture originating from the distal biceps tendon into the radial tuberosity in a similar manner. Additionally, often times when a suture anchor fixation method is used, it is referred to by the name of the brand of the anchor used.⁹ The interference screw fixation method uses a single anterior incision to gain access to the ruptured distal biceps tendon.^{1,2,3,6,9,13} The interference screw method is done by first making the single incision in the antecubital fossa, as mentioned previously.^{2,5,9,13} The radial tuberosity is cleaned and debrided of any soft tissue remaining from the tendon rupture.⁹ Once the anchor or screw, which already has

the sutures used for the fixation attached, is inserted into the radial tuberosity.^{2,9,13} Once the anchor is in place, the ruptured end of the distal biceps tendon is retrieved and the stump of the tendon is freshened and distal 2.5 mm is sutured with five stitches made on each side, using the ends of the sutures that are attached to the anchors.^{2,5,9,13} With the sutures in place, they can be tightened and knots tied completing the contact between the tendon and the radial tuberosity.^{2,5,9,13} Some of the different options of interference screws and anchors that can be used include corkscrews or Mitek.^{2,9} The use of suture anchors for the repair of a ruptured distal biceps tendon is used approximately 34% of all surgical repairs.³

When the ultimate tensile load of the interference screws was tested, it was found that the repair can withstand 131-192 N and has a stiffness of 30.4 N/mm.¹ The Ultimate tensile load of suture anchors was found to be only 105-263 N and the stiffness of this fixation method was not recorded.¹ When these



13

findings are compared to the ultimate tensile load and stiffness of an intact distal biceps tendon, which as mentioned before is 210-221 N and a stiffness of 30 N/mm, and the interosseous tunnel which is 125-210 N and a stiffness of 15.9 N/mm, it can be seen that all of the fixation options have a wide range of force they can withstand, but are not likely to reach the same level of strength of the original intact distal biceps tendon.¹ The fixation method that has the potential to hold up to heavier forces than the original uninjured distal biceps tendon, would be the suture anchor fixation method.¹ Although, the suture anchors may be stronger than the uninjured tendon, this fixation method also has the potential to be the weakest method of fixation

available.¹ Many studies, with one exception, have shown the suture anchors having inferior biomechanical properties when compared to the other methods of fixation of the distal biceps tendon.¹

Unlike the double incision interosseous tunnel fixation technique, which as previously discussed, has the chance of restricting the forearm range of motion, the post-operative range of motion seen with the single incision used for interference screw fixation is 2.2 to 135.1 degrees.³ This increased range of motion may be one the main reasons why the patient satisfaction rate following a fixation method using a single incision is 94%, as opposed to the 69% satisfaction rate seen in patients who receive the double incision interosseous tunnel method.¹

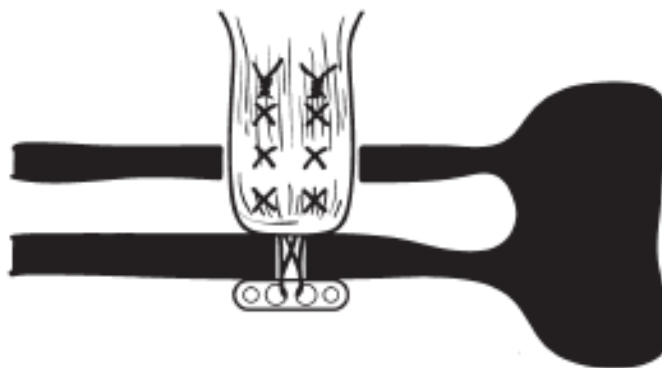
When the strength of the suture anchor fixation technique was tested by Lemos et al.⁵ with the same measure of failure used as mentioned above, it was found that when a suture anchor fixation does fail, it will more often than not be due to a failure of the suture. Although if a failure occurs it will likely occur within the sutures, the failure seen in the interosseous tunnel fixation method at the point of the bone bridge, failed sooner than the sutures.⁵ This means that when stress is placed directly on the junction of the tendon and bone, the bone bridge will break before the sutures used for the suture anchor fixation fail.⁵ This finding may be one to show variation depending on the materials chosen by the surgeon.

Once again similarly to the interosseous tunnel fixation technique, patient outcome were rated using the DASH questionnaire. Because the interference screw fixation can have variation based on anchor option, there are different DASH scores associated with some of the different anchor methods. The average score for the patients who received a corkscrew anchor reported a score of 3.7, while the patients who received a Mitek anchor reported a score of 10.5.² These scores demonstrate that according to the patient's self-reported scores, being the recipient of a

single incision suture anchor distal biceps tendon rupture, may lead to a happier patient.²

Although the DASH scores show that patients report, complications occurred more often the most often in those that received a Mitek anchor, and second most often in those that received corkscrew anchors.² In addition to having a higher complication rate, the Mitek anchor group also was shown to have the rate of ruptures following the repair.² The rate of ruptures seen in the Mitek anchor group was 5.6%.²

The cortical button is another readily used method of fixation for a ruptured distal biceps tendon rupture that is fairly new. The fixation of a ruptured distal biceps tendon, uses a single anterior incision to gain access to the tendon and radial tuberosity.^{1,3,11,12,13,14} The cortical button, or also referred to as a BicepsButton or Endobutton, is a titanium button that is placed through the radius.^{11,12} The surgery begins with the single incision in the antecubital fossa, once the incision is made the radial tuberosity is exposed and prepared for the fixation.¹² With the radial tuberosity prepared, a 4 mm hole is drilled through the radial tuberosity.¹³ The cortical button, which would already be loaded with the sutures to use later, is passed through the hole in the radial tuberosity and is flipped as the sutures are pulled to set the button in place.^{12,13} After the cortical button is in place, the distal biceps tendon is then cleaned up and prepared for the sutures, one of the suture ends from the button is passed through the tendon.^{12,13} The remaining end of the suture from the cortical button, is used to tightly pull the tendon into place securely against the radial tuberosity and the cortical button tight up against the radius.^{12,13}



Because this fixation method uses the single anterior incision, it maintains the same complications as mentioned previously, but since the cortical button passes through the radius and near the posterior interosseous nerve one would think damaging this nerve should also be an associated complication. Damage to the posterior interosseous nerve is prevented because the posterior cortex at the radial tuberosity remains intact with this fixation method.¹² A additional complication that is not typically associated with a single incision fixation method would be the development of heterotopic ossification, but because of the hole created through radius and subsequent trauma to the bone, there is a 4.7% rate of developing this complication.³

The use of cortical buttons as a fixation method for the ruptured distal biceps tendon has been discussed in two differing reports. Dunphy et al.³ had found that out of 784 surgical repairs, 33.2% received the cortical button as the method of repair. According to Waterman et al.¹⁴ in the military population, it was recorded that cortical button fixation accounted for 73.4% of all distal biceps tendon repairs.

When the cortical button underwent strength testing, it was found to be a significantly stronger than other method of fixation.⁶ The Ultimate tensile load was measured to be 274.77 N, which surpasses all of the other fixation methods discussed so far and also surpasses the strength of an intact distal biceps tendon.^{1,13} Not only did the cortical button prove to be stronger, but it also was found to absorb more of the forces placed on the forearm.¹³ When compared to a suture anchor fixation method, the cortical button absorbed 2919.02 mJ while the suture anchor only absorbed 1399.83 mJ.¹³ In addition to the cortical button being shown to be a very strong method of fixation, one study that recorded outcomes of patients who had a cortical button fixation method used for their repair, found that at the 6 month point, all patients in the study had regained full range of motion in their forearm.¹² Additionally, the average DASH

score seen in patients with the cortical button is 4.46, which shows significant patient satisfaction.¹¹ With this information known, it is easy to realize that the cortical button fixation method is a very strong option.

The final fixation method to be discussed, is very closely related to the cortical button fixation technique. This method would be the cortical button with the use of an interference screw. As the name would indicate, this fixation technique uses the same cortical method described above, plus the use of an interference screw.^{3,6,11,14,}

Because the cortical button plus interference screw, or also known as hybrid, fixation technique uses the combination of two fixation methods, the installation of each aspect is very similar to the installation of them when their independent.⁶ When the hybrid fixation technique is chosen the surgery begins with a single anterior incision, done in the same way as it is done with the other single incision fixation methods.^{1,3,11,12,13,14} After the incision is made, a cortical button is inserted in the same manner as previously described.⁶ Following the placement of the cortical button, the interference screw is then inserted into the hole created for the cortical button.⁶ As discussed previously, it is known that sutures pass through the interference screw as a part of the fixation method, because of the combination of the two fixation techniques, the sutures used with the interference screw are the sutures that are placed within the cortical button.

The use of the hybrid technique has not been shown to be consistent. One study which looked at the fixation techniques used in the military population, found that a cortical button with an interference screw was only used in 5.8% of distal biceps tendon rupture repairs.¹⁴ Another study, which collected data from distal biceps tendon ruptures of the general population, found that 33% of the ruptures were treated with the hybrid technique.³ The exact reason for the significant difference among the two populations is not known.

The addition of an interference screw has not been shown to add any additional strength to the already notably strong cortical button.¹¹ The use of the interference screw does, however, allows the repair of the ruptured distal biceps tendon to be more anatomic, and replicate the insertion of the two tendon bundles.¹¹ The more anatomic repair may allow the patient to have improved clinical outcomes.¹¹

Since the hybrid fixation method uses a single anterior incision, cortical button, and interference screw, the complications associated with this fixation method would be a combination of the complications associated with all of these factors. An additional complication, which out of 784 patients only occurred once, is the possibility of this fixation method leading the patient to have a predisposition to fracture the radial neck.³ One patient who received the hybrid fixation technique fractured the radial neck as the result of a fall six weeks postoperatively.³ For this patient it was noted that the fixation of the tendon was too close to the radial neck, this is believed to have predisposed the patient to the fracture.³ Although, this method carries the same complications associated with all of its individual components, it does reduce the rate of heterotopic ossification. The rate of developing heterotopic ossification with the use of the cortical button alone is 4.7%, while the rate with the hybrid fixation is only 1.4%.¹³ It is thought that the addition of the interference screw creates a tight seal between the screw, tendon, and bone which may limit the escape of heterotopic ossification forming marrow elements.¹³

Because the use of a cortical button and interference screw maintains the same strength of a cortical button, while also reducing the rate of developing heterotopic ossification, the use of this method may become more commonly used as a method of fixation.

Suggested Treatment Option:

Currently because of the rarity of distal biceps tendon ruptures, controversy exists over which incision and fixation method to use, when the injury does occur. The optimal fixation method would need to be a simple surgically and also strong enough to allow movement of the arm immediately following the surgery, while the optimal surgical method should have a low rate of complications and be very simple.¹ With the ideal guidelines and the information about each surgical technique known, a suggested standard repair method for a distal biceps tendon repair would be a single incision using the hybrid fixation technique. When compared to the double incision method, the single incision method does have a high rate of nerve damage, but it is more often than not short lived, while the double incision complications would be long lasting. The use of the cortical button with an interference screw would be a great standard method of fixation. The hybrid method is a rather simple surgery, as opposed to a more complicated surgery associated with the interosseous tunnel. Also, the strength of the fixation is significantly stronger with the use of a cortical button, even surpassing the strength of an intact distal biceps tendon. The addition of the interference screw, not only allows the repair to be more anatomical, but it also will significantly reduce the risk of heterotopic ossification developing following the surgery. Although the information demonstrates that the use of the hybrid fixation method could be the most suitable option currently available for the repair of a distal biceps tendon rupture, all of the techniques available have been shown to produce good clinical results, and no functional differences have been seen between incision options.^{3,11} Because all of the options available will produce a proper repair of the distal biceps tendon, the true success of the surgery will be based on the surgeons comfort level with the method they will be using, and thus should choose the option they are the most comfortable with. When surgeon experience was recorded and

compared to surgical outcome, those with more experience had fewer patients that experienced nerve damage and they were also more likely to select a form of cortical button fixation.³ A variable that may choose the fixation technique with less consideration of statistics would be cost, as a patient may for any reason have a limited budget for the operation. If a cost efficiency is a major deciding factor, the patient and doctor may choose the double incision interosseous tunnel technique or the single incision suture anchor technique, this is because the average cost of the cortical button is \$775.¹¹ The standard cost for the sutures needed for the interosseous tunnel technique is \$15, and the cost of the sutures or interference screw would be estimated to be a similar cost.¹¹

Postoperative Protocol:

Following the completion of the surgery to repair the ruptured distal biceps tendon, the patient will be bandaged up in a way that is expected of a medical professional. While postoperative care varies widely among doctors, there are still standard practices that are used commonly.³ Immediately following the surgery, patients are placed in a splint in an immobilized position of 90 degree elbow flexion and a neutral forearm rotation.^{2,3,6,11,12} Depending on the doctor overseeing the patient and the rehabilitation protocol to be followed, the patient may remain in the splint anywhere from two days to three weeks.^{2,6,11,12} Following the period of immobilization, and after the rehabilitation has begun, the patient may then be placed in a mobile hinge brace set to restrict elbow extension, or the patient may be allowed to move their arm freely, but have a restriction on the amount of weight they are allowed to lift.^{2,6,11,12}

Rehabilitation:

Following any injury where the proper function of tissue is disrupted, rehabilitation can be very beneficial for restoring normal function, and the distal biceps tendon is no exception. Currently, it is common practice for early movement and weight to be restricted, but some are now suggesting the use of a more aggressive rehabilitation protocol.¹ As with any surgery, the exact rehabilitation protocol will differ with how the damaged tissue was repaired and which doctor performed the surgery. Currently, rehabilitation protocols for surgical repairs of the distal biceps tendon, are not very specific and simply provide general guidelines for the physical therapists and athletic trainers to follow.^{2,6,10,11,12}

Following the post-operative protocol achieving full range of motion in the elbow and forearm would be the first goal. Once a full range of motion, or as close to a full range of motion as possible, is achieved, strengthening can become the focal point of the rehabilitation. Currently, it is recommended by many surgeons that the patient remain immobilized for at least one week and up to four weeks.^{2,6,11,12} During and after the period and immobilization the patient is to begin passive range of motion with the assistance of a physical therapist or athletic trainer.^{6,11,12} The range of motion would include pain free flexion, extension, and rotation.⁶ Active range of motion is not recommended until six week following the surgery.^{2,6,11,12} For the first six weeks of active range of motion, the patient may be restricted to a weight limit of 10 pounds.^{11,12} During this period the patient should focus on strengthening the joints above and below the injury, for this injury that would be the wrist and shoulder. In order to strengthen the wrist, with in the weight restriction, wrist curls and weighted wrist rotations could be done. To strengthen the shoulder, again while staying within the weight restrictions, the patient can do exercises such as shoulder presses. As the patient and the healing progress, the rehabilitation

may also progress to provide a constant appropriate level of stress on the tissues to encourage proper healing and strengthening. Once area of strengthening that should be addressed would be, eccentric strength. Developing eccentric strength is very important, because forced rapid eccentric extension is the mechanism of this injury.⁸ Once the rehabilitation has progressed the patient to a level of strength and stability as close as possible to pre-injury levels, within 3-6 months following the surgery, they may return to normal unrestricted activities.⁶

Conclusion:

To conclude, the rupture of a distal biceps tendon is a traumatic acute injury, that is also relatively rare. Because of this rarity, there remains a significant amount of controversy over which method of fixation is the preferred option. In addition to the controversy over which surgical method to use, it has been recently discovered that the distal biceps tendon actually consists of two tendons, which contribute individually to the movements of the forearm. The current most common methods of fixation include: interosseous tunnel, interference screw, cortical button, and cortical button with an interference screw. Although all of the options available serve as appropriate methods of fixation for the ruptured distal bicep tendon, the use of the cortical button with the interference screw has shown to be significantly stronger than the other options, while also allowing a more anatomical repair. Because of this, the cortical button with an interference screw fixation method may be able to become the standard protocol to repair the ruptured distal biceps tendon. After the surgery postoperative protocol consists of elbow immobilization for up to three weeks, followed by a rehabilitation with a focus on achieving full range of motion and normal strength and stabilization of the arm. Currently the surgical repair of ruptured distal biceps tendons is a standard practice with 97% of all patients returning to full pre-injury activity.¹⁴ With the continuing improvement in surgical procedures, one day there may be

one standard surgical option available that has few complications, is minimally invasive, and has an extremely high success rate.

Resources:

1. Chavan, P. R., Duquin, T. R., & Bisson, L. J. (2008). Repair of the Ruptured Distal Biceps Tendon. *The American Journal of Sports Medicine*, 36(8), 1618-1623.
doi:10.1177/0363546508321482
2. Citak, M., Backhaus, M., Seybold, D., Suero, E. M., Schildhauer, T. A., & Roetman, B. (2011). Surgical repair of the distal biceps brachii tendon: A comparative study of three surgical fixation techniques. *Knee Surgery, Sports Traumatology, Arthroscopy*, 19(11), 1936-1941. doi:10.1007/s00167-011-1591-0
3. Dunphy, T. R., Hudson, J., Batech, M., Acevedo, D. C., & Mirzayan, R. (2017). Surgical Treatment of Distal Biceps Tendon Ruptures: An Analysis of Complications in 784 Surgical Repairs. *The American Journal of Sports Medicine*, 45(13), 3020-3029.
doi:10.1177/0363546517720200
4. Kelly, M. P., Perkinson, S. G., Ablove, R. H., & Tueting, J. L. (2015). Distal Biceps Tendon Ruptures. *The American Journal of Sports Medicine*, 43(8), 2012-2017.
doi:10.1177/0363546515587738
5. Lemos, S. E., Ebrahimzadeh, E., & Kvitne, R. S. (2004). A New Technique. *The American Journal of Sports Medicine*, 32(2), 406-410. doi:10.1177/0363546503261720
6. Mazzocca, A. D., Virk, M. S., & DiVenere, J. (2017). Distal Biceps Tendon Injuries: Treatment of Partial and Complete Tears. *Operative Techniques in Sports Medicine*, 25(4), 156-163. doi:10.1053/j.otsm.2014.03.002
7. Michel P. J. Van Den Bekerom, Kodde, I. F., Aster, A., Bleys, R. L., & Eygendaal, D. (2014). Clinical relevance of distal biceps insertional and footprint anatomy. *Knee*

- Surgery, Sports Traumatology, Arthroscopy, 24(7), 2300-2307. doi:10.1007/s00167-014-3322-9
8. Nyland, J., Causey, B., Wera, J., Krupp, R., Tate, D., & Gupta, A. (2015). Distal biceps brachii tendon repair: A systematic review of patient outcome determination using modified Coleman methodology score criteria. *Knee Surgery, Sports Traumatology, Arthroscopy*, 25(7), 2293-2297. doi:10.1007/s00167-015-3899-7
9. Pereira, D. S., Kvitne, R. S., Laing, M., Giacobetti, F. B., & Ebrahimzadeh, E. (2002). Surgical Repair of Distal Biceps Tendon Ruptures A Biomechanical Comparison of Two Techniques. *The American Journal of Sports Medicine*, 30(3), 432-436. doi:10.1006/ajsm.2002.0000
10. Sethi, P. M., Rubin, E., & Radler, K. (2017). Distal biceps tendon ruptures and repairs. *Current Orthopaedic Practice*, 28(2), 168-172. doi:10.1097/bco.0000000000000485
11. Shields, E., Olsen, J. R., Williams, R. B., Rouse, L., Maloney, M., & Voloshin, I. (2015). Distal Biceps Brachii Tendon Repairs. *The American Journal of Sports Medicine*, 43(5), 1072-1076. doi:10.1177/0363546515570465
12. Siebenlist, S., Elser, F., Sandmann, G. H., Buchholz, A., Martetschlager, F., Stockle, U., & Lenich, A. (2011). The Double Intramedullary Cortical Button Fixation for Distal Biceps Tendon Repair. *Knee Surgery, Sports Traumatology, Arthroscopy*, 19, 1925-1929. doi:10.1007/s00164-011-1569-y
13. Spang, J. T., Weinhold, P. S., & Karas, S. G. (2006). A biomechanical comparison of EndoButton versus suture anchor repair of distal biceps tendon injuries. *Journal of Shoulder and Elbow Surgery*, 15(4), 509-514. doi:10.1016/j.jse.2005.09.020

14. Waterman, B. R., Navarro-Figueroa, L., & Owens, B. D. (2017). Primary Repair of Traumatic Distal Biceps Ruptures in a Military Population: Clinical Outcomes of Single-Versus 2-Incision Technique. *Arthroscopy: The Journal of Arthroscopic & Related Surgery*, 33(9), 1672-1678. doi:10.1016/j.arthro.2017.02.008