

★ BRIEFS ★

Revisiting Lenneberg's Hypotheses About Early Developmental Plasticity: Language Organization After Left-Hemisphere Perinatal Stroke

Elissa L. Newport, Barbara Landau, Anna Seydell-Greenwald,
Peter E. Turkeltaub, Catherine E. Chambers, Alexander W.
Dromerick, Jessica Carpenter, Madison M. Berl, &
William D. Gaillard

1. Introduction

A prominent theme in the literature on brain injury and recovery has been the notion of early developmental plasticity (Kennard 1940, Kolb et al. 2000). This has been a particular focus in work on language. In healthy adults, language is virtually always lateralized to the left hemisphere (LH; Broca 1861, Gazzaniga & Sperry 1967). However, Bassler (1962) and Lenneberg (1967) compiled published case studies, their own patient histories, and available medical records of children and adults with left and right hemisphere lesions or hemispherectomy to determine whether there were systematic effects of hemisphere and age of insult on the development or recovery of language. From these data, Lenneberg (1967) concluded that, when even massive injuries to one hemisphere occurred before age 2, most children developed language normally or with only some delay; and these outcomes were the same regardless of which hemisphere was affected. This led him to argue that initially, before cerebral dominance was fully established, the two hemispheres were equipotential for language. This was less true for older children and was definitively no longer true for adults, who showed strong LH specificity for language interference and some recovery from mild aphasias, but did not recover completely from severe aphasias or left hemispherectomies. Using the Wada test (briefly anesthetizing one hemisphere and then the other; see Loring et al. 1992) to determine which hemisphere controls speech, Rasmussen & Milner (1977) showed that in children, depending on the age at injury, speech that is ordinarily in the left hemisphere could be controlled successfully by the right hemisphere or by an alternate region of the damaged left hemisphere. Similar reorganization was not observed in adults,

This work is supported by funds from Georgetown University, MedStar Health, the Solomon James Rodan Pediatric Stroke Research Fund and the Feldstein Veron Innovation Fund to the Center for Brain Plasticity and Recovery; by NIH grants K18DC014558 to ELN, K23NS065121 to MMB, and R01NS244280 to WDG; by American Heart Association grant 17GRNT33650054 to ELN; by U10 NS086513 to the SCANR node of StrokeNet at MedStar Health and Georgetown University; and by M01RR020359 and P30HD040677 to the IDDRRC U54 HD090257 at Children's National Health System and Georgetown University.



even decades after injury. These generalizations have long formed the classic picture of recovery of language function.

However, recent research on organization after early injury in children has not always found such consistent outcomes. Some studies have found good language abilities after focal brain injury in children, but others have not (Banich et al. 1990, Ballantyne et al. 2007, Levine et al. 2005, Moesch, Max, & Tranel 2005, Montour-Proulx et al. 2004, Stiles et al. 2012, Westmacott et al. 2010). Relatively few studies of neural reorganization have been done with children, also with somewhat inconsistent outcomes (see, e.g., Mbwana et al. 2009, Rosenberger et al. 2009, and You et al. 2011 for language reorganization with epilepsy, and Booth et al. 2000, Dick et al. 2013, Fair et al. 2006, 2010, Jacola et al. 2006, Liégeois et al. 2004, Raja et al. 2010, Staudt et al. 2002, 2007, and Tillema et al. 2008 on perinatal stroke). This variation of outcomes may be due to true variation among children, or to the inclusion of children with a variety of types and causes of focal brain injuries (e.g., periventricular leukomalacia, moya moya, vasculitis, tumors, and hemorrhagic or arterial ischemic strokes) or the effects of other medical problems that are often comorbid with stroke in children (e.g., seizures and seizure medications, heart disease and reduced cortical perfusion, or sickle cell anemia). It might also be due to variation in the ages at which participants were evaluated (see Bates et al. 2001, showing that children with focal brain injuries may show developmental delays but later reach normal levels of performance).

There has also been little consistency in investigators' views of the principles governing developmental plasticity for language. Only a few researchers have proposed hypotheses about what areas or networks in the brain are capable of subserving language in the face of early brain injury, and these proposals are in sharp conflict. Vargha-Khadem et al. (1985) suggested that the left hemisphere is uniquely suited for language and that successful reorganization of language is limited to LH brain areas. (See also Raja et al. 2010, who have argued that the remaining left hemisphere voxel activity correlates best with language proficiency after left hemisphere perinatal stroke). Staudt (2002) and Gaillard and colleagues (Gaillard et al. 2007, Berl et al. 2014, Mbwana et al. 2009) have argued that left hemisphere areas or their precise right hemisphere homologues can subserve language when there are early left hemisphere abnormalities. In contrast, Bates et al. (1997) have suggested that the young brain is highly plastic; they argue that "the human capacity for language is not localized at birth," implying that reasonably normal language skills might be able to develop in numerous other brain regions. Bedny et al. (2011) have argued that congenitally blind individuals utilize even occipital cortex (including V1) during spoken language processing. Can this wide range of brain areas indeed support language? In our ongoing work we seek to understand the forces that lead language to develop in only certain brain areas in the healthy child and also to understand what areas can support language after early brain injury.

An important literature is the work of the Gaillard lab (Gaillard et al. 2007, Berl et al. 2014, Mbwana et al. 2009) using functional magnetic resonance imaging (fMRI) to examine the organization of language over development and how it is affected by early and continuing epilepsy (and the brain abnormalities that cause them). In response to chronic epilepsy, cortical processing of language is frequently restructured, with some or all language function shifted to the right hemisphere.

Their work has shown a limited number of ways in which language is organized across a very large number of children: in the usual left hemisphere areas, in the precisely homotopic right hemisphere areas, or in the usual left hemisphere temporal areas combined with the homotopic right hemisphere frontal areas. No other patterns of language organization appear in their subjects.

However, while chronic seizures can be clinically devastating for children, they apparently exert relatively mild effects on cortical organization: 75 % of children with early chronic seizures retain the typical left hemisphere pattern of language organization. To examine language after very early damage to the brain, we are focusing on perinatal arterial ischemic stroke, a relatively rare neurological event but one whose characteristics may provide an excellent model for examining the neural organization of language after early brain injury and for gaining insight into important principles of neural plasticity for language. In perinatal stroke, the injuries are typically much larger than in pediatric epilepsy but are relatively stereotyped in anatomy; approximate time of onset is clear; and in most patients there are not continuing seizures or long periods of time on antiepileptic medications. This makes our perinatal population an important contrast to Gaillard et al.'s work on epilepsy.

2. The Perinatal Stroke Project

Until recently, distinctions among the types of stroke that occur in children were not well understood. The availability of new imaging techniques and the establishment of the International Pediatric Stroke Study (deVeber 2005), with investigators around the world contributing case histories and data to a large repository, has only recently made it possible for investigators and physicians to establish a typology of arterial ischemic stroke (AIS) in children (Sébire, Fullerton, Riou, & deVeber 2004). Fortunately, stroke in children is uncommon; and it often occurs from different mechanisms than stroke in adults, including congenital heart disease, sickle cell anemia, or other disorders that can affect stroke outcomes in complex ways. In contrast, perinatal AIS has become a focus of research due to its occurrence often without other health problems. Many children with perinatal strokes are born after a healthy, full-term pregnancy, without birth complications, and without subsequent disease. They suffer from a sudden ischemic event whose causes are not well understood (thought perhaps to be a clot from the placenta or clots formed during changes from fetal to neonatal circulation) and then will often go on to develop without continuing seizures (some infants may have an early seizure, but many have none or only one).

Following Lenneberg's lead, our *Perinatal Stroke Project* re-examines the important issues he raised by studying language in teenagers and young adults who had such a perinatal stroke, many years before. Thanks to our collaboration with some of the largest and best known pediatric stroke programs in the United States (at Children's National Medical Center and Children's Hospital of Philadelphia), our research project is able to focus on this highly selected and uniform population: those who had a perinatal arterial ischemic stroke (defined as onset between 28 weeks gestation to 28 days postnatal (Lynch 2009), though most of our participants had their stroke within a few days of birth). Perinatal stroke to the middle

cerebral artery (MCA) provides an excellent model for this work: lesions are well defined, damaging LH language areas or their right hemisphere (RH) homologues, and often occur without other medical problems. While perinatal stroke occurs in only one out of 4,000 live births (Lynch 2009), we have been able to recruit a good number of participants with very similar injuries and fairly clean medical histories (born after full-term healthy pregnancies; no significant additional disease, such as sickle cell anemia, congenital heart defects, or multiple strokes; no medically refractory seizure disorders). We are not following our participants longitudinally (though see Stiles et al. 2012, Bates & Roe 2001, and Bates et al. 1997, for information about the course of language development in infants and toddlers after focal brain injuries). Rather, our question is how language abilities and their neural organization turn out, many years after the stroke, when they are teenagers or young adults. This is many years after most assessments have been conducted—an important question since other research has shown that they may develop language abilities more slowly than healthy controls. As Lenneberg asked, does their language develop successfully, despite their injuries to the left hemisphere brain areas normally dedicated to language, and does it do this by successfully reorganizing to healthy brain areas? Lenneberg suggested that the right and left hemispheres in very young children were equipotential for language and that, after left hemisphere injury, the right hemisphere could support normal language development. However, others since that time have argued that the left hemisphere is specialized and privileged for language and that the right hemisphere cannot support complex syntax (e.g., Dennis & Whitaker 1976, Raja Beharelle et al. 2010). Our project aims at addressing these important questions once more.

There are also important clinical questions that our research can address. While many children perform well after perinatal strokes, 25–45 % have some long-term impairments (often to motor or executive functions) that restrict their success in academic and everyday life (Lynch 2009). The common clinical picture for perinatal stroke is usually a mild hemiparesis—many of our participants walk with a slight limp and may have limited control of their hand and fingers on the affected side; but for most there is good cognitive and language development, even with very large infarcts. Our participants are at grade level in school, and some are honors students, though many require extra time on tests in school. Recent studies have demonstrated some language impairments, particularly for high-level language (Ballantyne et al. 2007), and some evidence that remaining LH areas (rather than homotopic areas of the RH) may be crucial for these skills (Raja et al. 2010). A better understanding of outcomes and the variables that correlate with outcome variations can provide a foundation for developing improved treatments.

We address these questions—Is the young brain successfully plastic? Can language be successfully acquired by the RH if the LH is damaged?—by testing a group of teenagers and young adults who have had a large perinatal stroke to the LH MCA territory; and, for comparison, teenagers and young adults with comparable infarcts to the RH, and healthy controls (including their siblings) who are matched to these groups in age and socio-economic status. Each participant and their families spend 3–4 days with us and are given a large battery of behavioral tests (verbal and performance IQ tests, tests of executive function and ADHD, and carefully selected tests of processing and producing linguistic syntax, morphology,

and prosody) and are also given a battery of fMRI tasks we have developed to examine neural activation for these same skills. In the next section we provide an overview of our results thus far for language.

3. Our Participants' Injuries and Their Neural Activations for Language

All participants undergo an anatomic MRI scan (an MP-RAGE), which provides a picture of the structure of their brain, and a functional scan examining their activation for language using a task called the Auditory Definition Decision Task (ADDT), along with other fMRI tasks. The ADDT was developed by Gaillard and colleagues (Gaillard et al. 2004, 2007, Berl et al. 2014) as part of an fMRI battery used to examine the neural activation for language in healthy children and in children with chronic seizure disorders. The ADDT involves a block design in which sentences like *A large gray animal is an elephant*. (the forward speech condition) are contrasted with the same sentences played backwards (the backward speech condition) and with blocks of silence. In the forward condition, participants push a button if the sentence is true; in the backwards condition they push a button when they hear a beep (which are matched in distribution and frequency to the button pushes required in the forward condition). The similarities between these conditions thus control for auditory and motor activation; the activation differences between conditions are thus due to processing and understanding the sentence. Task difficulty is kept constant across groups and individuals, at 90 % correct or better for all participants, by selecting one of 4 levels of word frequency for the target words (e.g. elephant). We administer other fMRI language tasks to our participants as well, but this task has the advantage of activating virtually all of the LH language network in healthy controls and therefore also reveals where this network is localized after a LH or RH stroke.

The activation pattern from a group of healthy children (Gaillard et al. 2007, Berl et al. 2014) is shown in Figure 1. Voxels with significantly greater activation for forward speech over backward speech in the ADDT are indicated in yellow/orange. The left panel shows a side view of the LH, with activation throughout the frontal and temporal lobe language areas; the right panel shows the complementary view of the RH, where there is minimal activation. This is the typical pattern of strong LH lateralization for language in healthy individuals.

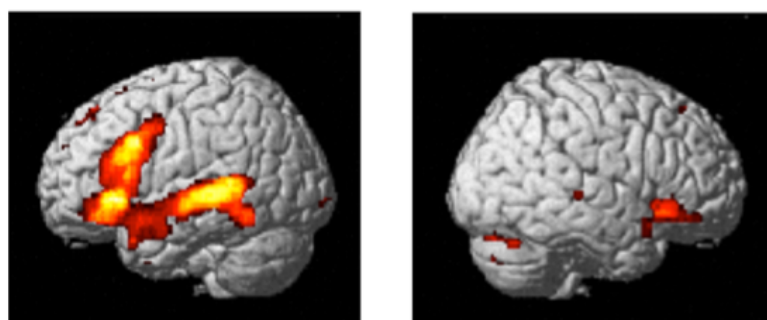


Figure 1: Activation for forward > backward speech in the ADDT for healthy children ages 4–12 (n = 68). (Based on Berl et al. 2014.)

The ADDT elicits such robust and reliable activation that we can also examine patterns of activation in individual participants, which is important for understanding neural plasticity and patterns of language organization after stroke. Figure 2 shows some example ADDT scans from 6 individuals tested in our ongoing research. These are axial scans (horizontal slices, with the front of the head at the top, back of the head at the bottom) and are in neurological orientation (the LH is on the left). Voxels with significantly greater activation for forward speech over backward speech are colored in yellow/orange. On the left top and bottom are two participants who are healthy controls (siblings of the patients); on the right top and bottom are two participants who have had a RH perinatal stroke. Both the healthy controls and the participants with RH strokes show the expected activation in LH temporal and frontal language areas. (The blob of activation in the LH toward the front is in the frontal region; the blob toward the back is in the LH temporal region.)¹ In contrast, the participants with LH strokes (in the middle) both show their language activation in the *right hemisphere homotopic areas*. Thus far we find this pattern of activation in the RH areas homotopic to the normal LH language network for all of the participants who have sizeable LH infarcts. (Only those with very small LH infarcts retain language activation in the typical areas of the LH). No other patterns of language activation appear across the 12 participants we have tested to date.

These results for language activation accord with what Lenneberg suggested on the basis of the clinical literature, well before imaging was available: after major left-hemisphere injury during very early infancy, language apparently ‘shifts’ to the right hemisphere.² (It is important to note, however, that this may not actually be a ‘shift’ but rather the maintenance and enhancement of early bilateral language, as Lenneberg also suggested; see a brief discussion of this hypothesis at the end of this paper, and see Berl et al. 2014a and Olulade et al., in preparation, for evidence.) This ‘shift’ of language to the right hemisphere does not successfully occur after stroke in adults (Turkeltaub et al 2011).

An important follow-up question, then, is whether the RH can fully support language processing and do so as well as—or almost as well as—the left hemi-

¹ The box around the frontal regions in the RH stroke patients indicate that we have combined a slice showing frontal activation with a different slice showing temporal activation. This is not an important feature of the imaging; in many individuals the strongest activations for frontal and temporal regions do not appear on the same brain slice.

² An important question is whether atypical fMRI activations reflect atypical neural organization for language, or rather whether activations arise from compensatory strategies, errorful performance (Fair et al. 2010), increased difficulty of the tasks, or feed forward/feedback (Price & Crinion 2005). For example, Raja Beharelle et al. (2010) showed that LH voxel activation best predicts language performance, even when the main activations are in the RH. Unfortunately, other techniques for testing language localization (e.g., using TMS to temporarily inactivate areas hypothesized to be crucial for language) are not safe for participants at higher seizure risk. However, several findings suggest that our fMRI activation patterns do reveal cortical language organization. First, we have selected participants for this research who have relatively large LH MCA infarcts with little or no healthy tissue in relevant LH areas for supporting language. Many of our patients have complete LH MCA infarcts (one has an infarct that encompasses the entire LH), and yet all show normal conversational language abilities and test scores. We have also designed our fMRI tasks to reduce such problems. We adjust task difficulty across participants to achieve over 90 % correct performance, reducing the likelihood that RH activation arises from task difficulty differences across groups.

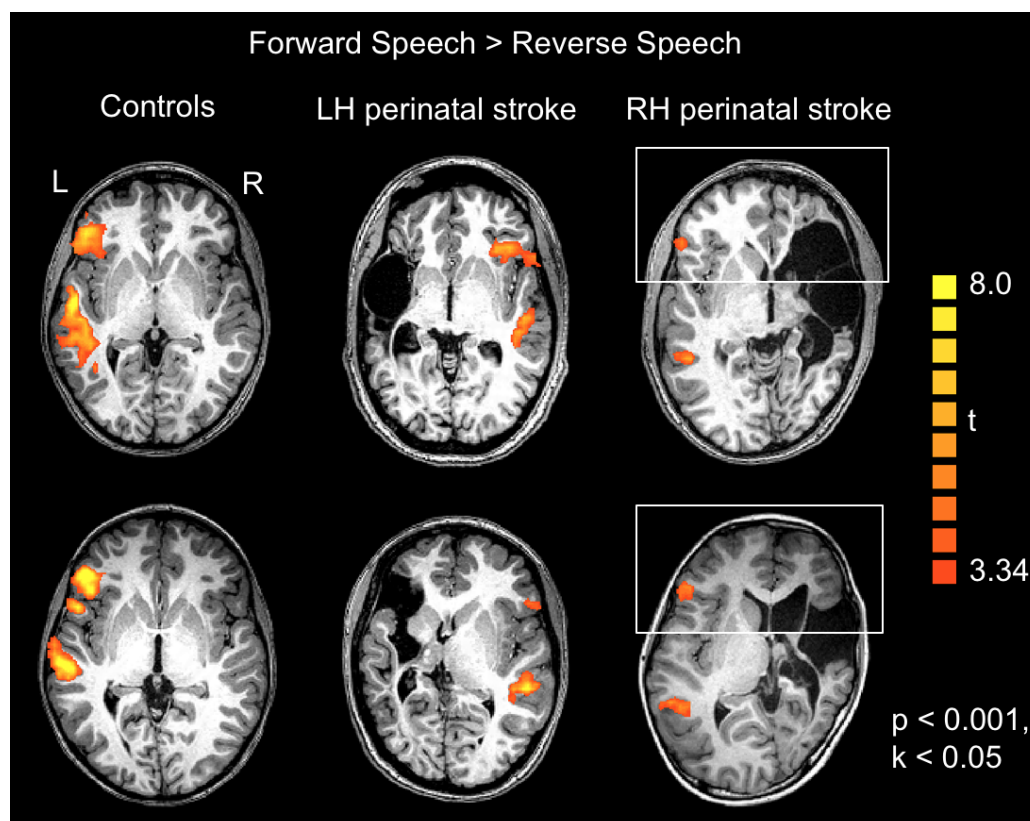


Figure 2: Example individual scans from the AADDT task, with orange/yellow showing voxels that are activated significantly more for forward than for backward speech. The leftmost scans are from two healthy controls; the rightmost scans are from two participants who had a RH perinatal stroke; and the scans in the middle are from two participants who had a LH perinatal stroke. All participants were teenagers at the time of testing.

sphere. Research on patients with a hemispherectomy during infancy (Dennis & Whitaker 1976) has argued that the LH is privileged for processing syntax and that patients who had LH surgery (even early in life) are less able to process complex syntax than those who had RH surgery. Lidzba et al. (2013) have suggested that there is a comparable result for children with perinatal stroke, although they have compared children with LH stroke only to healthy controls. In contrast, others have found no difference in language skills after early LH versus RH injury (Bates et al. 2001, Ballantyne et al. 2007, Feldman et al. 2002, Liégeois et al. 2008).

Dennis & Whitaker's findings predict that teenagers and young adults with RH language (LH stroke) will score comparably on simple sentences but will show greater deficits on complex syntax than those with LH language (RH stroke). Figure 3 shows our participants' performance on two different types of language tasks: on the left, in simple sentence comprehension and use of English morphology (two subtests from the Clinical Evaluation of Language Fundamentals; CELF-5), and on the right, in a more complex syntax task testing the comprehension of affirmative and negative active versus passive sentences (a task developed in our lab as a reconstruction of the Active-Passive task used by Dennis & Whitaker (1976) for testing hemispherectomy patients). It is important to note that these tasks, and others we

are using, have been chosen carefully to assess linguistic skills through tasks that are as free as possible of extraneous executive function demands (which we know are impaired in individuals who have had a stroke). While our research is still in progress, thus far the LH perinatal stroke group (with RH language) scores almost exactly as well as their healthy siblings (with LH language) and the RH perinatal stroke group (also with LH language, but with brain injuries comparable in size to those of the LH stroke group). These results do suggest, then, that the left hemisphere and the right hemisphere may be relatively equipotential for language early in life and that either one can successfully support language development after very early injuries to the opposite hemisphere.

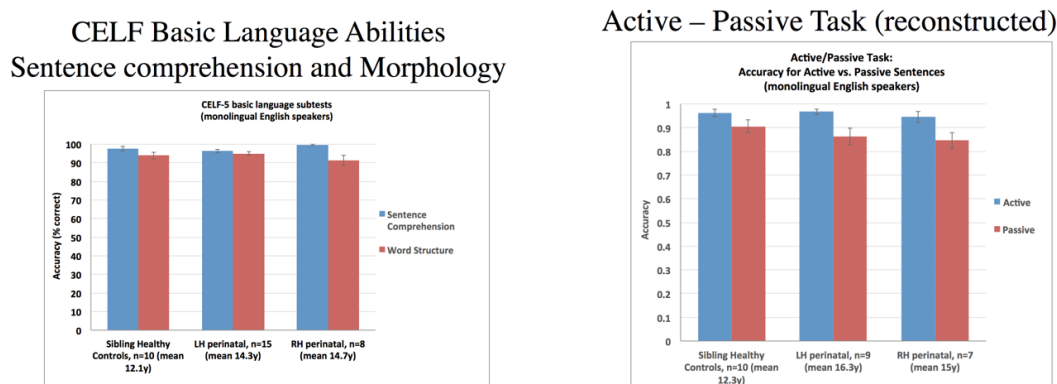


Figure 3: Language abilities of our three participant groups. On the left, language abilities in two subtests from the CELF; on the right, in the Active-Passive Test

4. Discussion and Conclusions of our Results to Date

Taken together, these results fully support Lenneberg's original suggestions about language and its representation in the brain after early injury. First, virtually all of the participants we have studied—those with fairly large perinatal strokes to left hemisphere frontal and temporal lobes—show their activation for sentence processing in the *right hemisphere homotopic regions* as teenagers or young adults. (See the same result also in 7 participants tested on the same task after perinatal stroke, included in a larger study of language laterality in individuals with chronic epilepsy by Berl et al. 2014b.) Second, their performance on both simple and complex language processing tasks, testing syntax and morphology, is very good and even equal to their healthy siblings and to matched participants with damage to the right hemisphere, as long as we test them with fairly natural language production or comprehension tasks that do not require extensive executive function demands. Overall, then, these results suggest that the infant brain does have a high degree of plasticity for supporting language in either the left or the right hemisphere, as Lenneberg suggested.

However, it is also extremely important to emphasize that the plasticity we see for language is highly constrained. After left hemisphere injuries, language does not develop in a wide range of alternative locations. Rather, as suggested by Gaillard and colleagues for atypical language after early chronic seizures and by

Booth and colleagues, Feldman and colleagues, Holland and colleagues, Szaflarski and colleagues, as well as Staudt, Lidzba, Wilke and colleagues for perinatal stroke, in the face of severe early left hemisphere injuries to the normal language areas, language virtually always and only develops in the right hemisphere homologues.

Why might atypical neural organization for language be restricted to these right hemisphere areas? Many researchers have referred generally to the high degree of plasticity apparent in the young brain and have talked about ‘reorganizing’ language to the right hemisphere. While a mechanism for such ‘reorganization’ is not often articulated, the implication is that, in the young brain, areas not ordinarily subserving language can *take on new functions* in the face of injury. (See, for example, Finger 2009 for a discussion of *vicariation*.) In contrast, our own hypothesis, again following Lenneberg’s original suggestions, is what we call the *Developmental Origins Hypothesis*. This hypothesis suggests that much of what appears to be reorganization of cognitive functions may actually be the outcome of more distributed functional representations in the healthy young brain. In particular, we and others have found that early language abilities are more bilateral than those of older children and adults (Berl et al 2014a; Szaflarski et al 2006; Newport et al in preparation; Olulade et al in preparation). We believe that this initially bilateral representation of language permits the *maintenance and enhancement of right hemisphere language development* when the left hemisphere is injured. But again, our research is still ongoing and investigates other accounts as well.

4.1. *Questions for the Future*

Our initial results also serve as an entrée to research on a number of further questions: What are the consequences of atypical organization of language in children? In particular, what are the effects on typically right hemisphere cognitive functions when language is also controlled in part or in whole by the RH?

4.2. *Potential Effects on Right Hemisphere Language Functions*

While we often say that language is left lateralized in the healthy brain, we usually mean to refer in this statement to only certain aspects of language. In reality, of course, ‘language’ is comprised of a number of coordinated functions, not all of which are ordinarily lateralized to the left hemisphere. The most well studied of these—naming and word recognition, sentence production and comprehension—are indeed ordinarily lateralized to the left hemisphere in healthy adults (Broca 1861, Gazzaniga & Sperry 1967), as noted above. But there are also some linguistic functions that are ordinarily lateralized to the homotopic regions of the right hemisphere, including the processing of vocal emotion and of linguistic intonation (e.g., tonal contrasts indicating statement vs. question; Ross & Monot 2008, Wildgruber et al. 2004, 2005). If early left hemisphere injury results in left-hemisphere language functions being reorganized to the right hemisphere, how are they integrated with the other functions of the right hemisphere? Does one set of functions dominate, resulting in savings to those but impairments to the others? Do the functions mix, with impairments to all? Or do they each find their own distinct territories in the right hemisphere, through normal Hebbian processes of competition, and peacefully coexist? Yet another possibility is that there are individual differences

in neural outcomes, leading to the individual differences in functional outcomes described in the clinical literature. We are still in the process of investigating these questions.

4.3. Potential Effects on Other Right Hemisphere Functions

The Crowding Hypothesis (Teuber 1974) posed a similar question regarding the effects of atypical language organization on right-lateralized visual-spatial functions. This hypothesis suggests that, due to its importance for human cognition, language will take priority in either hemisphere that is available, but then potentially leaves less neural territory or computational power for visual-spatial functions if crowded into the same hemisphere. Since visual-spatial functions are generally attributed to the parietal lobe (not the frontal and temporal areas involved in language processing), it is unclear why there would necessarily be such an interaction, but available evidence has suggested impaired visual-spatial cognitive abilities after LH perinatal injury (Lidzba et al. 2006, Stiles et al. 2012). However, only a few tasks have previously been used to assess visual-spatial functions in the context of the Crowding Hypothesis, so our research is re-examining these questions as well.

4.4. Principles and Mechanisms of Developmental Plasticity

Finally, the overarching questions that arise from Lenneberg's original suggestions and our own and others' evidence on these hypotheses concern the principles and mechanisms underlying developmental plasticity. Is the young brain endlessly plastic, with the capability for drastic reorganization of function, or are there important constraints and principles of developmental plasticity that have not been extensively addressed in the literature? Our results, combined with those already in the clinical literature, suggest that there are very limited and patterned ways in which language develops in the human brain. In the healthy brain, virtually everyone (approximately 99 % of right handers and 75 % of left handers; altogether approximately 95 % of the population) develops language in the same frontal and temporal lobe regions of the left hemisphere. When there is early left hemisphere injury, language develops in these regions if the lesion is very small, or in the homotopic regions of the right hemisphere if the injury is large. In Gaillard and Berl's work (Berl et al. 2014b, Mbwana et al. 2009), chronic seizure in middle childhood may result in an unusual combination of these two patterns (left hemisphere temporal activation; right hemisphere frontal activation). No other patterns of atypical language organization have been well documented.

Again following Lenneberg, we have also suggested a reason why the right hemisphere regions homotopic to the normal language network are capable of supporting language after early left hemisphere injury. Very young children show more bilateral representation of language than is seen in older children and adults (Lenneberg 1967, Szaflarski et al. 2006, Holland et al. 2001, Berl et al. 2014a, Newport et al., in preparation, Olulade et al., in preparation); that is, early in life, the right hemisphere homotopic regions are heavily involved in language processing even in the healthy brain. We hypothesize, then, that this forms the basis for the enhancement of these regions' involvement in language processing in the face of early injury.

It is important to note that these findings and hypotheses require further evidence. Even 50 years after Lenneberg's suggestions, these issues regarding developmental plasticity remain unresolved. But, with gratitude to Lenneberg for his remarkable insights and for his stimulation of 50 years of fascinating discussion and controversy, these questions continue to be a hot topic on the cutting edge of the science of neural plasticity.

References

- Ballantyne, Angela O., Amy M. Spilkin, & Doris A. Trauner. 2007. Language outcome after perinatal stroke: Does side matter? *Child Neuropsychology* 13, 494–509.
- Banich, Marie T., Susan C. Levine, Hongkeun Kim, & Peter Huttenlocher. 1990. The effects of developmental factors on IQ in hemiplegic children. *Neuropsychology* 28, 35–47.
- Basser, L. S. 1962. Hemiplegia of early onset and the faculty of speech with special reference to the effects of hemispherectomy. *Brain* 85, 427–460.
- Bates, Elizabeth, Donna Thal, Doris Trauner, Judi Fenson, Dorothy Aram, Julie Eisele, & Ruth Nass. 1997. From first words to grammar in children with focal brain injury. *Developmental Neuropsychology* 13, 447–476.
- Bates, Elizabeth, Judy S. Reilly, Beverly Wulfeck, Nina Dronkers, Meiti Opie, Judi Fenson, Sarah Kriz, Rita Jeffries, LaRae Miller, & Kathryn Herbst. 2001. Differential effects of unilateral lesions on language production in children and adults. *Brain and Language* 79, 223–265.
- Bates, Elizabeth & Katherine Roe. 2001. Language development in children with unilateral brain injury. In Charles A. Nelson & Monica Luciana (eds.), *Handbook of Developmental Cognitive Neuroscience*, 281–307. Cambridge, MA: MIT Press.
- Bedny, Marina, Alvaron Pascual-Leone, David Dodell-Feder, Evelina Fedorenko, & Rebecca Saxe. 2011. Language processing in the occipital cortex of congenitally blind adults. *Proceedings of the National Academy of Sciences of the United States of America* 108, 4429–4434.
- Berl, Madison M., Jessica Mayo, Erin N. Parks, Lisa R. Rosenberger, John VanMeter, Nan Bernstein Ratner, Chandan J. Vaidya, & William D. Gaillard. 2014a. Regional differences in the developmental trajectory of lateralization of the language network. *Human Brain Mapping* 35, 270–284.
- Berl, Madison M., Lauren A. Zimmaro, Omar I. Khan, Irene Dustin, Eva Ritzl, Elizabeth S. Duke, Leigh N. Sepeta, Susumu Sato, William H. Theodore, & William Gaillard. 2014b. Characterization of atypical language activation patterns in focal epilepsy. *Annals of Neurology* 75, 33–42.
- Booth, James R., Brian MacWhinney, Keith R. Thulborn, Kelley Sacco, James T. Voyvodic, & Heidi M. Feldman. 2000. Developmental and lesion effects in brain activation during sentence comprehension and mental rotation. *Developmental Neuropsychology* 18, 139–169.
- Broca, Paul. 1861. Remarques sur le siège de la faculté du langage articulé, suivies

- d'une observation d'aphémie (perte de la parole) [Remarks on the seat of the faculty of articulated language, following an observation of Aphemia (loss of speech)]. *Bulletin de la Société Anatomique* 6, 330–357.
- Dennis, Maureen & Harry A. Whitaker. 1976. Language acquisition following hemidecortication: Linguistic superiority of the left over the right hemisphere. *Brain and Language* 3, 404–433.
- DeVeber, Gabrielle. 2005. In pursuit of evidence-based treatments for paediatric stroke: The UK and Chest guidelines. *The Lancet: Neurology* 4, 432–436.
- Dick, Anthony S., Anjali Raja Beharelle, Ana Solodkin, & Steven L. Small. 2013. Interhemispheric functional connectivity following prenatal or perinatal brain injury predicts receptive language outcome. *Journal of Neuroscience* 33, 5612–5625.
- Fair, Damien A., Timothy T. Brown, Steven E. Peterson, & Bradley L. Schlaggar. 2006. fMRI reveals novel functional neuroanatomy in a child with perinatal stroke. *Neurology* 67, 2246–2249.
- Fair, Damien A., Alexander H. Choi, Yannic B. L. Dosenbach, Rebecca S. Coalson, Francis M. Miezin, Steven E. Petersen, & Bradley L. Schlaggar. 2010. The functional organization of trial-related activity in lexical processing after early left hemispheric brain lesions: An event-related fMRI study. *Brain and Language* 114, 135–146.
- Feldman, Heidi M., Brian MacWhinney, & Kelley Sacco. 2002. Sentence processing in children with early unilateral brain injury. *Brain and Language* 83, 335–352.
- Finger, Stanley. 2009. Recovery of function: Redundancy and vicariation theories. In Stanley Finger, François Boller, Kenneth L. Tyler (eds.), *Handbook of Clinical Neurology* (vol. 95), 833–841. New York, NY: Elsevier.
- Gaillard, William D., L. Balsamo, B. Xu, C. McKinney, P. H. Papero, S. Weinstein, J. Conry, P. L. Pearl, B. Sachs, S. Sato, L. G. Venzina, C. Frattali, & W. H. Theodore. 2004. fMRI language task panel improves determination of language dominance. *Neurology* 63, 1403–1408.
- Gaillard, William D., Madison M. Berl, E. N. Moore, E. K. Ritzl, L. R. Rosenberger, ..., & W. H. Theodore. 2007. Atypical language in lesional and nonlesional complex partial epilepsy. *Neurology* 69, 1761–1771.
- Gazzaniga, Michael S. & Roger W. Sperry. 1967. Language after section of the cerebral commissures. *Brain* 90, 131–148.
- Holland, Scott K., Elana Plante, Anna Weber Byars, Richard H. Strawsburg, Vince J. Schmithorst, William S. Ball, Jr. 2001. Normal fMRI brain activation patterns in children performing a verb generation task. *NeuroImage* 14, 837–843.
- Jacola, Lisa M., M. B. Schapiro, Vince J. Schmithorst, Anna Weber Byars, Richard H. Strawsburg, J. P. Szaflarski, Elana Plante, & Scott K. Holland. 2006. Functional magnetic resonance imaging reveals atypical language organization in children following perinatal left middle cerebral artery stroke. *Neuropediatrics* 37, 46–52.
- Kennard, Margaret A. 1940. Relation of age to motor impairment in man and in subhuman primates. *Archives of Neurology and Psychiatry* 44, 377–397.
- Kolb, Bryan, Robin Gibb, & Grazyna Gorny. 2000. Cortical plasticity and the development of behavior after early frontal cortical injury. *Developmental Neuropsychology* 18, 423–444.

- Lenneberg, Eric H. 1967. *Biological Foundations of Language*. New York, NY: Wiley.
- Levine, Susan C., Ruth Kraus, Erin Alexander, Linda W. Suriyakham, & Peter R. Huttenlocher. 2005. IQ decline following early unilateral brain injury: A longitudinal study. *Brain and Cognition* 59, 114–123.
- Lidzba, Karen, Andreas Konietzko, Eleonore Schwilling, Inge Krägeloh-Mann, & Susanne Winkler. 2013. Processing of non-canonical word-order: A case-series on lesion-induced reorganized language and age-effects in typical development. *Brain and Language* 127, 377–387.
- Lidzba, Karen, Martin Staudt, Marko Wilke, & Ingeborg Krageloh-Mann. 2006. Visuospatial deficits in patients with early left hemispheric lesions and functional reorganization of language: Consequence of lesion or reorganization? *Neuropsychologia* 44, 1088–1094.
- Liégeois, Frédérique, A. Connolly, J. Helen Cross, S. G. Boyd, D. G. Gadian, Faraneh Vargha-Khadem, & T. Baldeweg. 2004. Language reorganization in children with early-onset lesions of the left hemisphere: An fMRI study. *Brain* 127, 1229–1236.
- Loring, David W., Kimford J. Meador, Gregory P. Lee, & Don W. King. 1992. *Amobarbital effects and lateralized brain function: The Wada Test*. New York, NY: Springer.
- Lynch, John K. 2009. Epidemiology and classification of perinatal stroke. *Seminars in Fetal & Neonatal Medicine* 14, 245–249.
- Mbwana, J., M. M. Berl, E. K. Ritzl, L. Rosenberger, J. Mayo, . . . , & W. D. Gaillard. 2009. Limitations to plasticity of language network reorganization in localization related epilepsy. *Brain* 132, 347–356.
- Moesch, Sonja C., Jeffrey E. Max, & Daniel Tranel. 2005. A matched lesion analysis of childhood versus adult-onset brain injury due to unilateral stroke: Another perspective on neural plasticity and recovery of social functioning. *Cognitive and Behavioral Neurology* 18, 5–17.
- Montour-Proulx, Isabelle, Claude M J. Braun, Sylvie Daigneault, Isabelle Rouleau, Sally Kuehn, & Jean Bégin. 2004. Predictors of intellectual function after a unilateral cortical lesion: Study of 635 patients from infancy to adulthood. *Journal of Child Neurology* 19, 935–943.
- Raja Beharelle, Anjali, Anthony Steven Dick, Goulven Josse, Ana Solodkin, Peter R. Huttenlocher, Susan C. Levine, & Steven L. Small. 2010. Left hemisphere regions are critical for language in the face of early left focal brain injury. *Brain* 133, 1707–1716.
- Rasmussen, Theodore & Brenda Milner. 1977. The role of early left-brain injury in determining lateralization of cerebral speech functions. *Annals of the New York Academy of Sciences* 299, 355–369.
- Rosenberger, L. R., J. Zeck, M. M. Berl, E. N. Moore, E. K. Ritzl, . . . , & W. D. Gaillard. 2009. Interhemispheric and intrahemispheric language reorganization in complex partial epilepsy. *Neurology* 72, 1830–1836.
- Ross, Elliott D. & Marilee Monot. 2008. Neurology of affective prosody and its functional-anatomic organization in right hemisphere. *Brain & Language* 104, 51–74.
- Sébire, Guillaume, Heather Fullerton, Emilie Riou, & Gabrielle deVeber. 2004. Toward the definition of cerebral arteriopathies of childhood. *Current Opinion*

- in Pediatrics* 16, 617–622.
- Stiles, Joan, Judy S. Reilly, Susan C. Levine, Doris A. Trauner, & Ruth Nass. 2012. *Neural Plasticity and Cognitive Development: Insights from Children With Perinatal Brain Injury*. New York, NY: Oxford University Press.
- Staudt, Martin, Karen Lidzba, Wolfgang Grodd, Dirk Wildgruber, Michael Erb, & Ingeborg Krägeloh-Mann. 2002. Right-hemispheric organization of language following early leftsided brain lesions: Functional MRI topography. *NeuroImage* 16, 954–967.
- Staudt, Martin. 2007. (Re-)organization of the developing human brain following periventricular white matter lesions. *Neuroscience and Biobehavioral Reviews* 31, 1150–1156.
- Szaflarski, Jerzy P., Scott K. Holland, Vincent J. Schmithorst, & Anna W. Byars. 2006. fMRI study of language lateralization in children and adults. *Human Brain Mapping* 27, 202–212.
- Teuber, Hans L. 1974. Why two brains? In F. O. Schmitt & F. G. Worden (eds.), *The Neurosciences: Third Study Program*, 71–74. Cambridge, MA: MIT Press.
- Tillema, Jan-Mendelt, Anna W. Byars, Lisa M. Jacola, Mark B. Schapiro, Vince J. Schmithorst, Jerzy P. Szaflarski, & Scott K. Holland. 2008. Cortical reorganization of language functioning following perinatal left MCA stroke. *Brain and Language* 105, 99–111.
- Turkeltaub, Peter E., Samuel Messing, Catherine Norise, & Roy H. Hamilton. 2011. Are networks for residual language function and recovery consistent across aphasic patients? *Neurology* 76, 1726–1734.
- Vargha-Khadem, Faraneh, A. M. O’Gorman & G. V. Watters. 1985. Aphasia and handedness in relation to hemispheric side, age at injury, and severity of cerebral lesion during childhood. *Brain* 108, 677–696.
- Westmacott, Robyn, Rand Askalan, Daune Macgregor, Peter Anderson, & Gabriele Deveber. 2010. Cognitive outcome following unilateral arterial ischaemic stroke in childhood: effects of age at stroke and lesion location. *Developmental Medicine & Child Neurology* 52, 386–393.
- Wildgruber, D., I. Hertrich, A. Riecker, M. Erb, S. Anders, W. Grodd, W., & H. Ackermann. 2004. Distinct frontal regions subserve evaluation of linguistic and emotional aspects of speech intonation. *Cerebral Cortex* 14, 1384–1389.
- Wildgruber D, A. Riecker, I. Hertrich, M. Erb, W. Grodd, T. Ethofer, & H. Ackermann. 2005. Identification of emotional intonation evaluated by fMRI. *NeuroImage* 24, 1233–1241.
- You, Xiaozhen, Malek Adjouadi, Magno R. Guillen, Melvin Ayala, Armando Barreto, . . . , & William D. Gaillard. 2011. Sub-patterns of language network reorganization in pediatric localization related epilepsy: A multisite study. *Human Brain Mapping* 32, 784–799.

Elissa L. Newport
Georgetown University
Center for Brain Plasticity and Recovery
4000 Reservoir Road, N.W.
Washington D.C. 20057
United States of America
eln10@georgetown.edu

Anna Seydell-Greenwald
Georgetown University
Center for Brain Plasticity and Recovery
4000 Reservoir Road, N.W.
Washington D.C. 20057
United States of America
as2266@georgetown.edu

Catherine E. Chambers
Georgetown University
Center for Brain Plasticity and Recovery
4000 Reservoir Road, N.W.
Washington D.C. 20057
United States of America
catherine.chambers@georgetown.edu

Jessica Carpenter
Children's National Medical Center
111 Michigan Ave N.W.
Washington D.C. 20010
United States of America
jcarpent@childrensnational.org

William D. Gaillard
Children's National Medical Center
111 Michigan Ave N.W.
Washington D.C. 20010
United States of America
wgaillard@childrensnational.org

Barbara Landau
Johns Hopkins University
Department of Cognitive Science
241 Krieger Hall
Baltimore, MD. 21218
United States of America
landau@jhu.edu

Peter E. Turkeltaub
Georgetown University
Center for Brain Plasticity and Recovery
4000 Reservoir Road, N.W.
Washington D.C. 20057
United States of America
turkelt@georgetown.edu

Alexander W. Dromerick
MedStar National Rehabilitation Hospital &
Georgetown University
Center for Brain Plasticity and Recovery
4000 Reservoir Road, N.W.
Washington D.C. 20057
United States of America
alexander.w.dromerick@medstar.net

Madison M. Berl
Children's National Medical Center
111 Michigan Ave N.W.
Washington D.C. 20010
United States of America
mberl@childrensnational.org