

Manual and Electronic Detection of Subgingival Calculus: Reliability and Accuracy

Masud M., Zahari H. I. M., Sameon A. S. N., Mohamed N. A. H.
University Teknologi MARA, Malaysia

Abstract- Calculus consists of mineralised dental biofilm on the surfaces of teeth and dental prosthesis, the location of which can be detected by using a periodontal or an electronic probe. Detection of subgingival calculus is critical for successful treatment outcome in the management of periodontal patients. The aim of this study was to detect subgingival calculus using manual and electronic probe and to compare the reliability and the accuracy of both methods. The study was carried out in vitro on thirty-two extracted teeth with calculus mounted in frasaco model. A total of 192 sites on six surfaces of the teeth buccally and lingually were recorded for the presence of subgingival calculus. Manual probing of calculus depended on tactile sensation and experience; where as electronic probing gave sound and light signal. The results showed that at the depth of 1-3mm, manual probing could detect 62.7% of calculus and electronic probing could detect more at 77.1%. At the deeper sites of 4-6mm, the ability for detection using electronic probing reduced to 14.1% with failure for detection at ≥ 7 mm depth. However manual probing recorded more at 25% for 4-6mm calculus and 4.7% at ≥ 7 mm. Manual and electronic probing has different sensitivity in detecting subgingival calculus with electronic probing being more sensitive at shallow sites and failed to detect calculus at deeper sites. It also has difficulty to differentiate between calculus and other roughness on tooth surfaces. These findings highlighted the accuracy and reliability of manual detection for deeper calculus. Redesigning calibration and length of electronic probe can improve its usage. Further study on clinical application to assess the impact of both probing may benefit clinical teaching of subgingival calculus detection and the outcome of periodontal patient's management.

Keywords: accuracy and reliability, detection, electronic and manual, subgingival calculus.

I. INTRODUCTION

Calculus consists of mineralized bacterial plaque formed on the surfaces of natural teeth and dental prosthesis. It is classified as supragingival or subgingival according to its relation to the gingival margin. The presence of supragingival calculus can be directly observed clinically, however subgingival calculus which is located apically below the margin of gingiva is not visible on clinical examination. The location and extent of subgingival calculus can be detected by clinical examination with a dental instrument such as an explorer or a periodontal probe, visually by blowing air down

the gingival crevice and to a certain extent visible on a radiograph, however radiographic presentation of calculus is not always reliable.

Detection of subgingival calculus is essential for future treatment plan and critical to successful treatment outcome in the management of periodontal patients. Manual probe can detect calculus but depend more on the operator tactile sensation, skill and experience. Electronic probe detect calculus by giving sound and light signal with green for no calculus and blue for the presence of calculus.

II. LITERATURE REVIEW

Dental calculus is calcified dental plaque (biofilm), composed primarily of calcium phosphate mineral salts deposited between and within remnants of formerly viable microorganisms (White D.J. 1997). Subgingival calculus is undoubtedly largely responsible for the chronicity and progression of periodontal disease although its role in periodontal tissue breakdown is still far from understood (Lindhe *et al.* 1984). A study using light microscopy and transmission electron microscopy (TEM) described subgingival calculus as homogeneous with crystals of small size (Friskopp & Isacson 1983).

A periodontal probe is an instrument used by the dentist to determine the health of the gums. There are different types of probes one of which is WHO probe. It has 0.5 mm diameter ball-ended at its tip and is primarily used in a screening procedure to assess the presence or absence of periodontal pockets, calculus and gingival bleeding. The ball-ended tip assist in feeling subgingival calculus and help to prevent the probe from being pushed through the inflammatory tissue at the base of a pocket.

Orban as far back as in 1958 characterised the periodontal probe as "the eyes of the operator beneath the gingival margin" and it was the most widely used tool in periodontal diagnosis and reevaluation. Since 1970s, there has been a minimal improvement in the general shape and diameter of the probe. The ability to clinically detect initial or residual subgingival calculus using subjective tactile sense, with a probe or explorer has come into question many times. The

dentist still relied upon his tactile sensitivity with the periodontal probe (Low 1995).

Studies about automated probing dated from 1996 to 2009 were limited and evaluated only on pocket depth and or clinical attachment level around the teeth and implants in patients with untreated periodontitis or in periodontal maintenance patients. More clinical studies that evaluate the reliability and validity of automated probes alone, or in comparison to manual probes for assessment of pocket depth, clinical attachment level in patients with periodontitis, and periodontal maintenance cases were needed (Calley & Hodges, 2011).

Subgingival calculus detection and removal were difficult for both novice and experienced clinicians (Pippin and Feil 1992). Findings from previous studies indicated that tactile cues available at the end of finger movements provide a powerful stimulus for the control of the finger muscles (Johansson *et al.* 1992). The study by Atilla *et al.* 1994 concluded that decisions about the smoothness of a surface using a periodontal probe and the sense of touch were reliable for clinical use.

In vitro results for calculus detection using ultrasound-based compared with tactile probing showed that the ultrasound-based is superior. The study demonstrated percentage of pocket area with residual calculus ranged from 0.9% to 69% for samples which were tested with an explorer while on diode radiation, residual calculus was found 1.2 % to 16.3% of the entire pocket area (Matthias *et al.* 2004).

Clinical curriculum in periodontology revolves around teaching students how to detect and remove subgingival calculus. Reliable and accurate detection of the calculus is a difficult skill which relies on subjective tactile sensation for determination and may cause error in the investigation process thus lead to inadequate treatment. Though it can be effectively detected manually or electronically, there may be significant differences in reliability and accuracy.

Therefore, the purpose of the present study was to compare detection ability of both manual and electronic probes. The reliability and accuracy of the detection were determined for both manual and electronic probe.

III. METHODOLOGY

Experimental model and measurement

The in vitro study was carried out to identify the presence of the calculus on the root of the teeth. Thirty two extracted permanent human teeth with subgingival calculus were mounted in a frasaco model for upper and lower quadrant and labeled from 1 to 32. The teeth selected were representatives of incisors, canines, premolar and molars of both maxilla and mandible. Three surfaces (mesial, middle, and distal) of the

buccal, palatal or lingual side of the teeth were probed respectively. A total of 192 surfaces were probed at 90° angle and depth of calculus detected measured in mm from the cemento enamel junction (CEJ). A double blinded probing of the subgingival calculus was carried out by an operator and the six point detection was systematically recorded at 0 mm, 1-3mm, 4-6mm and ≥7mm.

Detection device: Probes

The manual detection techniques described in this study was used WHO probe) and A Sirona dental system (Perioscan) for electronic probing.

(i) WHO probe for manual tactile sensation. The probe has a spherical ball-like tip with a diameter of 0.5mm (Figure 1) and a black band for visibility between 3.5 & 5.5 mm and circular markings at 8.5 mm and 11.5 mm. The Purpose of the ball was to assist in feeling subgingival calculus and in clinical condition to help prevent the probe from being pushed through inflammatory tissue at the base of the periodontal pockets (Cutress *et al.* 1987).

(ii) Electronic probe from SiRona dental system Perioscan using sound and light signal (Figure 2 and 3) detected calculus in subgingival areas. A blue light indicated presence of calculus and green light indicated no calculus.



Fig. 1: WHO Probe



Fig. 2: Electronic Probe

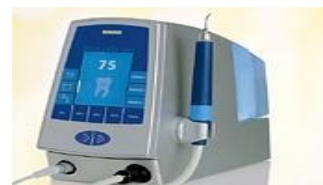

Fig. 3: PerioScan with Electronic Probe

The sites with calculus was detected at mm from the CEJ were used as the unit of analysis for the two probing methods. Data was analyzed using SPSS.

IV. RESULT AND DISCUSSION

Since the study was an in vitro study, most of the variables involved in instrumentation procedure were standardized. However, there were also several disadvantages to this experimental design since it lacks some of the characteristics of the clinical condition. The detection of the presence of calculus is significantly affected by the nature of the frasco where the teeth were being embedded, probing depths and root surface texture and anatomy. The potential of the method depends to a great extent on the skill and the experience of the operator which markedly influenced the final outcome (Meissner *et al.* 2004).

The result of the depth of the detection of calculus by both manual and electronic probing was grouped into 0 mm, 1-3mm, 4-6 mm and ≥ 7mm (Table 1).

Depth of probing From CEJ (mm)	Number of sites			
	Manual probing		Electronic probing	
	N	%	N	%
0mm	6	3.1	17	8.9
1-3mm	129	67.2	148	77.1
4-6mm	48	25.0	27	14.1
≥ 7mm	9	4.7	0	0
Total	192	100	192	100

The mean for manual probing was 1.31 ± 0.61 and for electronic probing was 1.05 ± 0.48 . There was a significant difference in between manual and electronic probing with p value <0.05.

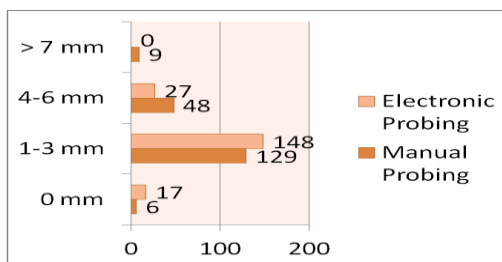


Fig. 4: Number of sites of teeth with depth of calculus detection

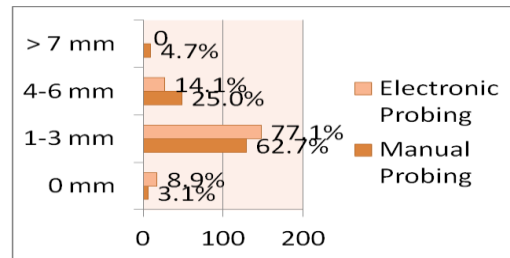


Fig. 5: Percentage of sites with depth of calculus detection

Figure 4 and 5 showed that calculus detected at (1-3 mm) for manual probing was 67.2% (n = 129) and for electronic probing was 77.1% (n= 148). However at 4-6 mm, 25.0% (n = 48) of calculus detected for using manual probe and 14.1% (n = 27) for electronic probe. Manual probing detected 4.7% of surfaces at ≥7 mm (n = 9) which were not detected at all by electronic probe.

Benhamou 2003 reported that the chances of detecting subgingival calculus were fairly good if the probing depth was ≤3mm. At probing of 3 - 5mm, the chance of failure became greater. At probing depth ≥5mm, the chance of failure was more dominant. This was found to be true in this study with most of the detection for both methods of probing to be within the range of 1-3mm. This was applicable for both manual and electronic probing. Bushari *et al.* 2013 in his review paper on the latest advances in calculus detection and removal technologies summarized that most techniques were capable of identifying calculus which include detection only system as well as combined calculus detection and removal. Electronic probe seemed to have the advantage as it was designed to do both decreasing chair side time, efficient scaling and probably avoid overzealous instrumentation.

However in our study, the length of electronic probe which was less than 7mm and unmarked offered a setback in the detection and removal of calculus at a much deeper pocket. This finding was also in agreement with and also reported by Srinivas *et al.* in 2009 when the optical detection system relying on detecting the specific calculus presented with limited maneuverability in deep pockets and restricting its efficiency. Whereas WHO probe is marked and calibrated up to ten mm and able to detect 9 sites with ≥ 7mm . Thus manual detection still remains the “gold standard” for subgingival calculus detection (Becherer *et al.* 1993).

Manual probing was shown to be as sensitive as the electronic probe. Other factors that can affect the findings were operator’s experience in subgingival calculus probing manually and also the operator’s ability to feel the roughness of the calculus. Study by Ray in 2006 on the possibility of accurate calculus detection concluded that the procedure may be more subjective than educators could realize and

calibration was essential. The three examiners involved in the study had an agreement of 69.8% of areas where there was no calculus and 4.6% of areas where calculus remained. They concluded that there was more agreement on areas with no deposits and total agreement was less likely in surfaces having remaining deposits (residual calculus). More definitive techniques need to be used when calibrating supervisors in the detection of subgingival calculus in order to achieve accurate feedback for clinical instruction.

It has to be considered that the potential of the detection method also depends on the scanning skills of the dentist. Furthermore, electronic probe was as sensitive as manual probe in detecting calculus but it can give a false positive detection. This is due to the fact that it cannot differentiate between roughness of the calculus and also roughness due to other factors. Thus, in addition to the equipment used, the skills and experience of the dentist markedly influenced the final outcome (Meissner et al. 2006). This was also discovered in our study that electronic probe could not differentiate between roughness of the calculus or due to other factors thus, giving false positive results.

The length of the probe can also be a factor. WHO probe is marked and calibrated up to ten mm but electronic probe is not calibrated at all, so when measured against WHO probe, its length showed less than 7 mm. That was why electronic probe did not detect calculus of 7 mm and manual probing presented with better detection at 7 mm and more. The study by Mascarenhas *et al.* 2006 stated that that manual detection still remains the 'gold standard' for subgingival calculus detection and optical detection method had significantly lower sensitivity, limited maneuverability in deep pockets thus restricting its efficiency.

V. CONCLUSION AND RECOMMENDATION

Manual probing using tactile sensation was as sensitive but has different sensitivity as compared to electronic probing using sound indicator. Manual probing has better detection ability at 7mm and more which was not applicable for electronic probe. However the use of electronic probing has the advantage of sound detection and the system can scale the calculus with an indicator of its removal. Its disadvantage was the possibility of detecting rough surfaces which may not be calculus and that was found to give false positive results. Therefore, detection using manual probe (tactile) may avoid this problem. Calibrating and redesigning the length of the electronic probe can improve its effectiveness at the same time be able to differentiate rough surfaces and calculus thus provide answer to its reliability and accuracy in the future. Furthermore, its multifunctional applications such as for scaling, fillings and for endodontic treatment provide its cost effectiveness.

The impact of these findings also highlighted the importance and the effectiveness of manual probing and

periodontal charting for periodontal patients management in public health setting as the use of electronic probing is more expensive to be extensively used in such setting.

ACKNOWLEDGMENT

The authors sincerely thank the Dean and the staff of the Faculty of Dentistry Universiti Teknologi MARA, Malaysia for their help in this study.

REFERENCES

- [1] D. J. White, "Dental calculus: recent insights into occurrence, formation, prevention, removal and oral health effect of supragingival and subgingival deposits". *Eur J Oral Sci.* 1997;105:pp. 508-522.
- [2] J. Lindhe, E. Westfelt, S. Nyman, "Long term effect of surgical and non-surgical treatment of periodontal disease". *Journal of Clinical Periodontology* 1984;11: pp. 448-58.
- [3] J. Friskopp, G. A. Isacson, "Quantitative icroradiographic study of the mineral content of supragingival and subgingival dental calculus". *Scandinavian Journal of Dental Research* 1984;92: pp.25-32.
- [4] B. Orban, F. M. Wentz, F. G. Everett, D. A. Grant, "Periodontics, A Concept Theory and Practice ". St Louis : CV Mosby Co; 1958:103.
- [5] S. B. Low, "Clinical considerations in non surgical mechanical therapy", *Periodontology* 2000, 1995;9: pp. 23-26.
- [6] K. H. Calley and K. O. Hodges, " Automat your probing process: how technical advances are changing the way probing depths are measured and recorded, *The Journal of Professional Excellence – Dimention of Dental Hygiene* 2011;9(2): pp.44-47.
- [7] D. J. Pippin and P. Feil, "Intepreter agreement on subgingival calculus detection following scaling", *J Dent Educ* 1992;56: pp.322-6.
- [8] R. S. Johansson and K.J. Cole, "Sensory-motor coordination during grasping and manipulative actions". *Curr Opin Neurobiol* 1992;2 (June): pp.815-23.
- [9] G. Atilla and S. Kandemir, "Evaluation of surface smoothness detected by a periodontal probe", *J. Nihon Univ Sch Dent* 1994;36(Apr): pp. 261-5.
- [10] F. Matthias, H. Richard, M. Albert M, and R. Hickel, " The effectiveness of InGaAsp Diode Laser Radiation to detect subgingival calculus as compared to an explorer", *J Periodontol* 2004;75:pp.744-749.
- [11] Perioscan Sirona Australia – Ultrasonic instrument; Code 6030337 "The first ultrasonic unit for diagnosis and therapy all-in-one.
- [12] T. W.Cutress, J. Ainam, J. Sardo-Infirri, " The community periodontal index of treatment need (CPITN) procedure for population groups and individuals, *International Dental Journal* 1987; 37(4): pp. 222-233.
- [13] G. Meissner, B. Oehme, J. Strackeljan and T. Kocher, "A new system to detect residual subgingival calculus: in vitro detection limits", *Journal of Clinical Periodontology* 2006;33(March): pp.195-199.

- [14] V. Benhamou, "Calculus detection goes high tech." Dimensions of dental hygiene 2003;1(March): pp. 16-18.
- [15] B. M. Bushari, P. J. Chitnis and K. A. Banavali, "Advances in calculus detection and removal technologies - a review", Indian Journal of Research 2013 ; Volume 2(January) issue 1: pp.124-125.
- [16] S. R. Srinivas, S. M. Dhoom, S. Nagarajappa, B. Vidya and A. Janardhan, "A periodontal probing", Dentistry India Compendium 2009;3(May): pp. 32-40.
- [17] C. F. Becherer, K. H. Rateitschak and A. F. Hefli, "Comparative probing with an electronic and a manual periodontal probe", Pubmed 2008;8: 651-657.
- [18] C. H. Ray, "Accurate calculus detection: is it possible?", ADEA /AADR/CADR Meeting and Exhibition 2006: Educational Research Presentation.
- [19] J. Mascarenhas, S. Blanchard, D. Newell, B Hancock, M. Kowolick, and G. Eckert, "Use of optical detection system for detecting subgingival calculus":<http://iadr.confex.com/iadr/2006Orld/techprogramforcd/A76347.htm>.



Mahyunah Masud graduated with the Bachelor of Dental Surgery from the University of Malaya in 1977 and Master of Science in Periodontology at the University of London in 1984. She has 30 years of working experience with the Ministry of Health Malaysia and joined the academic since 2008. Currently she is teaching in Periodontology for year 3, 4 and 5 at the Faculty of Dentistry, Universiti Teknologi MARA, Malaysia.