

บทความรายงานผู้ป่วย  
(Case report)

# แผลขนาดใหญ่ในหลอดอาหาร ที่มีลักษณะคล้ายมะเร็งหลอดอาหาร ซึ่งเป็นผลของยา Doxycycline

ปิยนันท์ ชนไมตรี<sup>1</sup> อศวิน สุดเจริญ<sup>1</sup> ปิยกรณ์ พูลรัมย์<sup>1</sup> เทิดเกียรติ ตรงวงศา<sup>2</sup><sup>1</sup> ภาควิชาอายุรศาสตร์ คณะแพทยศาสตร์ มหาวิทยาลัยศรีนครินทรวิโรฒ<sup>2</sup> ภาควิชาพยาธิวิทยา คณะแพทยศาสตร์ มหาวิทยาลัยศรีนครินทรวิโรฒ

## บทคัดย่อ

จากรายงานทางการแพทย์พบว่ามียามากกว่า 100 ชนิดที่สามารถทำให้เกิดแผลในหลอดอาหาร ยาที่พบบ่อยที่สุดคือ doxycycline อาการที่พบบ่อย คือ เจ็บหน้าอก กลืนเจ็บ กลืนลำบากและแสบร้อนกลางอก ผู้นิพนธ์รายงานการเกิดแผลในหลอดอาหารขนาดใหญ่จากการใช้ยา doxycycline ในแพทย์ ซึ่งลักษณะแผลคล้ายมะเร็งหลอดอาหาร ผู้ป่วยอาการดีขึ้นหลังรักษาด้วยยา sucralfate และ xylocaine viscous ภายใน 1 สัปดาห์ ดังนั้น บุคลากรทางการแพทย์และผู้ป่วยควรตระหนักถึงภาวะนี้

**คำสำคัญ:** แผลในหลอดอาหารจากยา doxycycline แผลในหลอดอาหาร

### ผู้นิพนธ์หลัก:

ปิยนันท์ ชนไมตรี

ภาควิชาอายุรศาสตร์ คณะแพทยศาสตร์ มหาวิทยาลัยศรีนครินทรวิโรฒ

62 หมู่ 7 ถ.รังสิต-นครนายก ต.องครักษ์ อ.องครักษ์ จ.นครนายก 26120

อีเมล: [piyanant\\_n@yahoo.co.th](mailto:piyanant_n@yahoo.co.th)

# Doxycycline-induced large esophageal ulcer resembling esophageal cancer

Piyanant Chonmaitree<sup>1</sup>, Asawin Sudcharoen<sup>1</sup>, Piyakorn Poonyam<sup>1</sup>, Therdkiat Trongwongsa<sup>2</sup>

<sup>1</sup> Division of Gastroenterology, Department of Medicine, Faculty of Medicine, Srinakharinwirot University

<sup>2</sup> Department of Pathology, Faculty of Medicine, Srinakharinwirot University

## Abstract

More than 100 medications are reported to cause pill-induced esophagitis (PIE). Doxycycline is the most common cause. Common symptoms are chest pain, odynophagia, dysphagia and heartburn. The authors report a young female internist presenting with a large esophageal ulcer resembling esophageal cancer caused by doxycycline. She was successfully treated with sucralfate and xylocaine viscous. Her symptoms improved within 1 week. Thus, medical personnel and patients should be aware of PIE.

**Keywords:** pill-induced esophagitis, doxycycline, esophageal ulcer

### Corresponding author:

Piyanant Chonmaitree

Department of Medicine, Faculty of Medicine, Srinakharinwirot University

62 Moo 7, Rangsit Nakhon Nayok Road, Ongkharak, Nakhon Nayok, 26120 Thailand

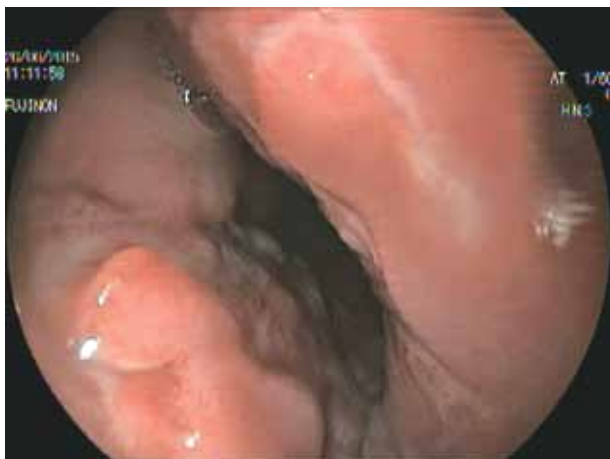E-mail: piyanant\_n@yahoo.co.th

## ■ Introduction

Esophageal ulcer can cause by infection, reflux, medication, corrosive agent, and cancer. Candida, Herpes simplex virus, Cytomegalovirus and Human Immunodeficiency virus are common infectious causes of esophageal ulcer. Pill-induced esophageal ulcer is usually overlooked.

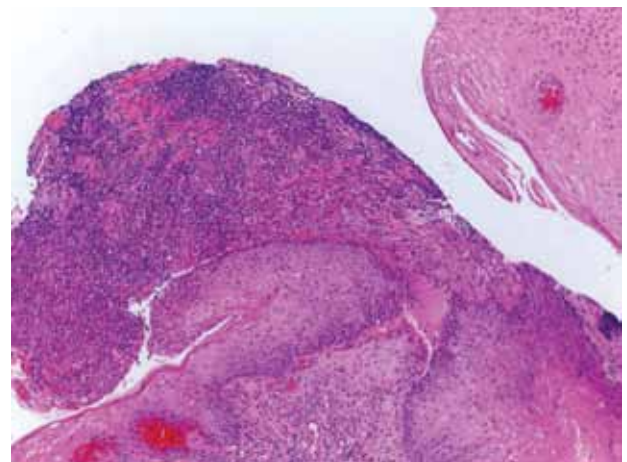
## ■ Case Report

A 28-year-old female internist was evaluated due to insidious onset of chest discomfort and odynophagia for 1 week. The pain was radiated to the back. She also had dyspepsia for 1 month and 2-kg weight loss. She denied history of esophageal motility disease. Two weeks before her symptoms had occurred, she had taken a 5-day course of doxycycline ingestion to treat acne vulgaris. She took the pills with less than 100 cc water. Physical examination was unremarkable. Complete blood count, liver function test, and radiology of chest were normal. Endoscopy revealed a large ulcer at the lower esophagus. It involved about 80% of circumferential area (Figure 1).

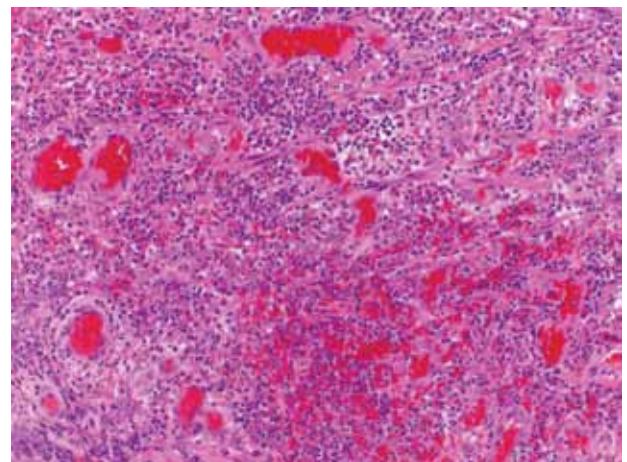


**Figure 1** Endoscopic finding demonstrated a large esophageal ulcer

Stomach and duodenum were normal. Using biopsy technique, pathological examination demonstrated a reactive squamous hyperplasia with ulcerations and granulation tissue, indicating severe active inflammation. There was acute and chronic inflammatory cell infiltration. No definite atypical cell, viral cytopathic change or microorganisms were detected in Haematoxylin and Eosin stain (H&E), Acid Fast stain (AFB), Gomori methenamine silver stain (GMS) and Periodic acid Schiff stain( PAS) slide (Figure 2-3).



**Figure 2** Ulcer with granulation tissue



**Figure 3** Acute and chronic inflammatory cell infiltration

Because of concerns about malignancy, Computer Tomography chest and upper abdomen was performed and the result was normal. She was treated with sucralfate and xylocaine viscus. Her symptoms completely resolved within 1 week. Re-endoscopy was done 2 months later revealed complete healing of the esophageal ulcer.

## ■ Discussion

Pill-induced esophagitis (PIE) is a condition that usually remains underdiagnosed. PIE was first documented in 1970.<sup>1</sup> Nowadays, more than 100 medications have been reported to cause PIE.<sup>2</sup> It can occur at any age. Many mechanisms have been proposed including production of caustic or alkaline solution, creation of hyperosmolar solution, and direct toxicity and induction of gastroesophageal reflux. Risk factors of PIE are old age, large pill size, capsule formulation, left atrial enlargement, esophageal stricture, esophageal dysmotility, esophageal diverticulum, and extrinsic compression of the esophagus.<sup>3,4</sup> However, most of the patients had no risk factors.<sup>2</sup> Patients with PIE usually had a history of incorrect methods of taking pills (recumbent position after pills ingestion and insufficiency amount of water). Typical symptom of PIE is acute onset of chest pain that increases with inspiration. Pain may radiate to the back. Other symptoms are odynophagia, dysphagia, and heartburn. PIE rarely presents with hematemesis, abdominal pain, and weight loss. These symptoms can occur within a few hours or up to 1 month after ingestion. Esophagogastroduodenoscopy is the investigation of choice. Typical endoscopic finding of PIE is discrete ulcer surrounding with normal mucosa. Solitary or multiple ulcers can be found. Ulcer varies from several millimeters to more than 10 cm. It may be found as kissing ulcers. PIE presents rarely as esophageal denticulate superficialis, stricture, and tumor-like appearance.<sup>3</sup> Histology is nonspecific. Radiology is less sensitive than endoscopy. Diagnosis

of PIE is based on typical clinical features, history of pills usage, and endoscopic findings. PIE is diagnosed with confidence if intact pills or its residues are found. Complications of PIE are rare. Esophageal respiratory fistula, esophageal perforation, stricture, neoplasia, and fatal injury have been reported.<sup>2,3</sup> There is no specific treatment for PIE. Discontinuation of the causative pill is the mainstay of treatment. Changing to a liquid formulation is advised in cases that the medication is required to be continued. Most of PIE recovers spontaneously. Symptoms usually improve within several weeks.<sup>3,5</sup> Endoscopic recovery usually occurs within 2-5 weeks.<sup>5</sup> PPI, sucralfate, viscous lidocaine solution, and narcotics have been reported to treat PIE.<sup>3</sup> There is however no study comparing the efficacy of these medications. Some patients may require hydration or parenteral nutrition. Endoscopic dilation should be considered in PIE with stricture. Prevention of PIE should be advised. Pills should be swallowed with at least 8 oz of water and patient should be remains in upright position for at least 30 minutes after ingestion.

Doxycycline is the most common cause of PIE. It occurs about 27% of PIE.<sup>1</sup> Most of PIE is found in young female without history of esophageal motility disorder.<sup>6</sup> Doxycycline produces acidic solution which leads to esophageal injury and inhibit protein synthesis. Doxycycline-induced esophagitis (DIE) usually found in mid to lower esophagus. It can occur within the first hour or up to 10 days after ingestion and last for several days or up to 6 weeks.<sup>1,3</sup> The most common symptom of DIE is dysphagia and sudden odynophagia. Endoscopy usually demonstrates mild esophagitis.

The authors report a young female internist with doxycycline-induced esophagitis. She presented with large esophageal ulcer resembling esophageal cancer. Pathology and computer tomography helped us to exclude malignancy. DIE can occur in persons who incorrectly ingest the pills. Medications commonly cause DIE are doxycycline, tetracycline,

NSAIDs, bisphosphonate, potassium chloride, quinidine and iron compound. Knowledge about PIE should be emphasized in medical personnel and patients.

---

## References

---

1. Al-Mofarreh MA, Al Mofleh IA. Esophageal ulceration complicating doxycycline therapy. *World J Gastroenterol* 2003;9:609-11.
2. Weston BR, Thosani N, Bektas M, et al. Pill esophagitis masquerading as esophageal cancer on endoscopy and endoscopic ultrasound. *VHJOE* 2010;9:1-3.
3. Katzka DA. Esophageal disorders caused by medications, trauma, and infection. In: Mark Feldman LSFaLJB, ed. *Sleisenger and Fordtran's gastrointestinal and liver disease*. 10<sup>th</sup> ed. Philadelphia: Elsevier Inc.; 2016:763-73.
4. Fernandez A, Gonzalez-Portela C, Vazuquez S, et al. Doxycycline-induced wide esophageal ulcer. *Res Esp Enferm Dig* 2007;99:556-7.
5. Dag MS, Ozturk ZA, Akin I, et al. Drug-induced esophageal ulcers: Case series and the review of the literature. *Turk J Gastroenterology* 2014;25:180-4.
6. Tahan V, Sayrak H, Bayar N, et al. Doxycycline-induced ulceration mimicking esophageal cancer. *Case J* 2008;1:144.
7. Kikendall JW. Pill-induced esophagitis. *Gastroenterol Hepatol* 2007;3:275-6.
8. Fernandopulle ANR, Navarathne NMM. Oesophageal injury suspected to be due to doxycycline ingestion. *Ceylon Med J* 2011;56:162-3.
9. Tankurt IE, Akbaylar H, Yenicierioglu Y, et al. Severe, long-lasting symptoms from doxycycline-induced esophageal injury. *Endoscopy* 1995;27:626.
10. Saravanan T, Telisinghe PU, Chong VH. Oesophageal ulcers secondary to doxycycline and herpes simplex infection in an immunocompetent patient. *Singapore Med J* 2012;53:e69-e70.

