

Optometric Clinical Practice

Volume 1 | Issue 1

2019

Welder's Maculopathy; a Case Report

Christina E. Morettin OD
Illinois College of Optometry, cmorettin@ico.edu

Bruce A. Teitelbaum OD
Illinois College of Optometry, bteitelb@ico.edu

Follow this and additional works at: https://athenaeum.uiw.edu/optometric_clinical_practice

 Part of the [Optometry Commons](#)

The Athenaeum provides a publication platform for fully open access journals, which means that all articles are available on the Internet to all users immediately upon publication. However, the opinions and sentiments expressed by the authors of articles published in our journal does not necessarily indicate the endorsement or reflect the views of the University of the Incarnate Word and its employees. The authors are solely responsible for the content of their work. Please address questions to athenaeum@uiwtx.edu.

Recommended Citation

Morettin CE, Teitelbaum BA. Welder's Maculopathy; a Case Report. *Optometric Clinical Practice*. 2019; 1(1):40.

This Article is brought to you for free and open access by The Athenaeum. It has been accepted for inclusion in *Optometric Clinical Practice* by an authorized editor of The Athenaeum. For more information, please contact athenaeum@uiwtx.edu.

Welder's Maculopathy; a Case Report

Abstract

Background: Outer retinal damage can occur when excessive ultraviolet (UV) radiation reaches the retina. The most common etiology is from the sun, known as solar retinopathy, especially when individuals observe solar eclipses without appropriate eye protection. Another cause of UV retinopathy that is not frequently encountered in practice is arc welding, causing Welder's Maculopathy. Fortunately, the prognosis of the UV retinopathies is quite favourable, as many fully recover after the initial insult to the retina. This retrospective case review aims to outline the clinical manifestation of this maculopathy and current opinions on its etiology and diagnosis.

Case Report: A 45-year-old patient presented for a comprehensive eye examination with an occupational history of arc welding. Best corrected visual acuities were 20/20 OD, OS. Dilated fundus examination revealed central red macular retinal pigment epithelium (RPE) disruption in the right and left eyes. Spectral domain optical coherence tomography (SD-OCT) demonstrated no defects OD and foveal loss of the ellipsoid portion of the photoreceptor inner segment (ISe) band with atrophy in the RPE OS.

Conclusion: Welder's Maculopathy is an established, but infrequently encountered, cause of UV retinopathy. Most cases are self-limiting and cause no long-term functional sequelae. SD-OCT findings from photochemical injury to the photoreceptors and RPE lead to a box-shaped outer retinal hole that can interrupt the ISe band; which is a determinant of visual prognosis. Careful occupational education should be discussed with each patient.

Keywords

UV retinopathy, Welder's Maculopathy

Creative Commons License



This work is licensed under a [Creative Commons Attribution-Noncommercial 4.0 License](https://creativecommons.org/licenses/by-nc/4.0/)

Background

Outer retinal damage can occur when excessive ultraviolet (UV) radiation reaches the retina. The most common etiology is from the sun, known as solar retinopathy, especially when individuals observe solar eclipses without appropriate eye protection. Another cause of UV retinopathy that is not frequently encountered in practice is arc welding, causing Welder's Maculopathy. Fortunately, the prognosis of the UV retinopathies is quite favorable, as many fully recover after the initial insult to the retina. This retrospective case review aims to outline the clinical manifestation of this maculopathy and current opinions on its etiology and diagnosis.

Case Report

A 45-year-old patient presented to our clinic for a comprehensive eye examination. He reported blurred vision at distance and near OU. He was using over the counter reading glasses for near work. His last eye examination was in childhood. The patient reported a history of corneal compromise from arc welding, approximately a dozen times. His last medical examination was years ago, and he reported no general systemic health problems. He had no known drug allergies. Family history for ocular disease was unremarkable. He was a former smoker for 7 years.

The patient was oriented to time, place and person with a normal affect. Entering uncorrected visual acuities were 20/40 OD and 20/60 OS. Pupils were equal, round and reactive to light, without a relative afferent pupillary defect (RAPD). Confrontation visual fields were full to finger count OD, OS and extraocular motility was full and extensive OD, OS. HRR (Hardy Rand and Rittler) standard pseudoisochromatic screening was normal OD, OS. His refraction was +1.50 -1.00 x 095 OD and +2.00 -1.00 x 080 OS with a +1.50 add at near. Best-corrected visual acuities after refraction were 20/20 OD, OS at distance and near. Slit lamp examination was remarkable for mild meibomian gland dysfunction. Intraocular pressure with Goldmann applanation tonometry was 13mmHg OD and 15mmHg OS. Manual blood pressure in office was 98/62. The patient was dilated with tropicamide 1% and phenylephrine 2.5%. Dilated fundus examination revealed central red macular retinal pigment epithelium (RPE) disruption in the right and left eyes (see Figure 1). The patient was imaged with Cirrus spectral domain optical coherence tomography (SD-OCT) that demonstrated no defects OD and foveal loss of the ellipsoid portion of the photoreceptor inner segment (ISe) band with atrophy in the RPE OS (see Figure 2). Amsler grid was performed, and revealed no scotomas OD, OS.

Differential Diagnoses

Differential diagnoses for this patient included ultraviolet (UV) retinopathy secondary to arc welding (Welder's Maculopathy), UV retinopathy secondary to sun gazing (solar retinopathy), and cone dystrophy. All three differential diagnoses lead to outer retinal damage, as seen on SD-OCT. A patient with solar retinopathy will have a history of increased retinal exposure to UV radiation from the sun. The majority of cases are a consequence of viewing a solar eclipse or sun gazing without appropriate eye protection.¹⁻⁶ Our patient denied viewing the sun for extended periods of time; however, he reported a history of arc welding and approximately a dozen episodes of photokeratitis. Arc welding is a rarer cause of UV retinopathy.⁷ In cases of UV retinopathy within days of insult to the retina, there is variable retinopathy from none to marked intraretinal edema. Usually, the edema resolves in days and leaves behind a mottled yellow lesion in the macula, which usually evolves into a red lesion,⁸⁻¹³ which was noted in our patient. Patients with cone dystrophy (without rod involvement) can also demonstrate central retinal thinning and segmental foveal loss of the ISe band. Cone dystrophies can have highly variable clinical retinal changes with progressive reduced best-corrected visual acuity, photophobia, inability of clear vision in bright light (hemeralopia), difficulty with colour vision discrimination, and central scotomas. A bull's eye maculopathy or demarcated severe macular atrophy may be seen on ophthalmoscopy.¹⁴⁻¹⁷ The diagnosis of cone dystrophy is determined by a full-field electroretinogram¹⁷ (ERG); however, based on the clinical examination and presentation, this diagnosis was ruled out. In addition, inherited maculopathies tend to produce symmetrical foveolar lesions and cone-rod dystrophies produce larger lesions than those seen with the UV retinopathies.¹⁸

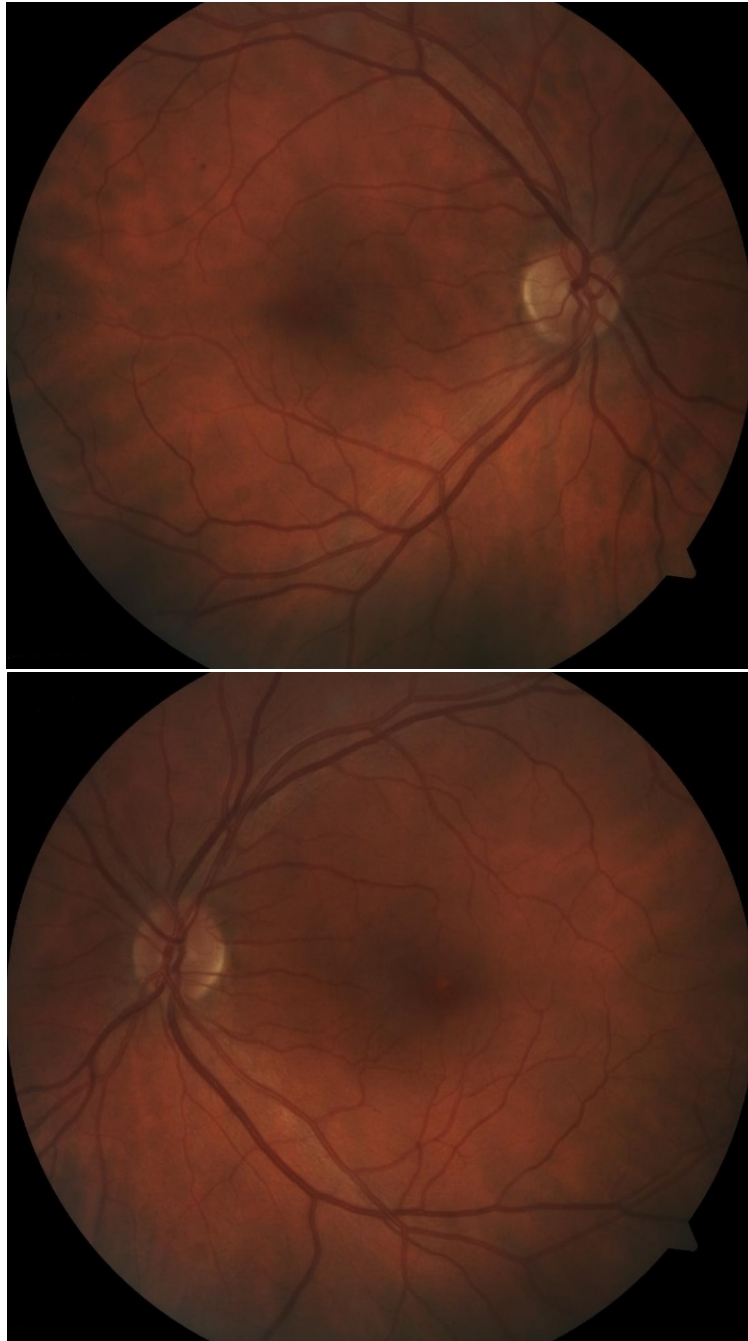


Figure 1. Fundus photographs of the right and left eyes, demonstrating a very subtle red macular lesion. It is difficult to appreciate the irregular macula clearly in these photos with low magnification.

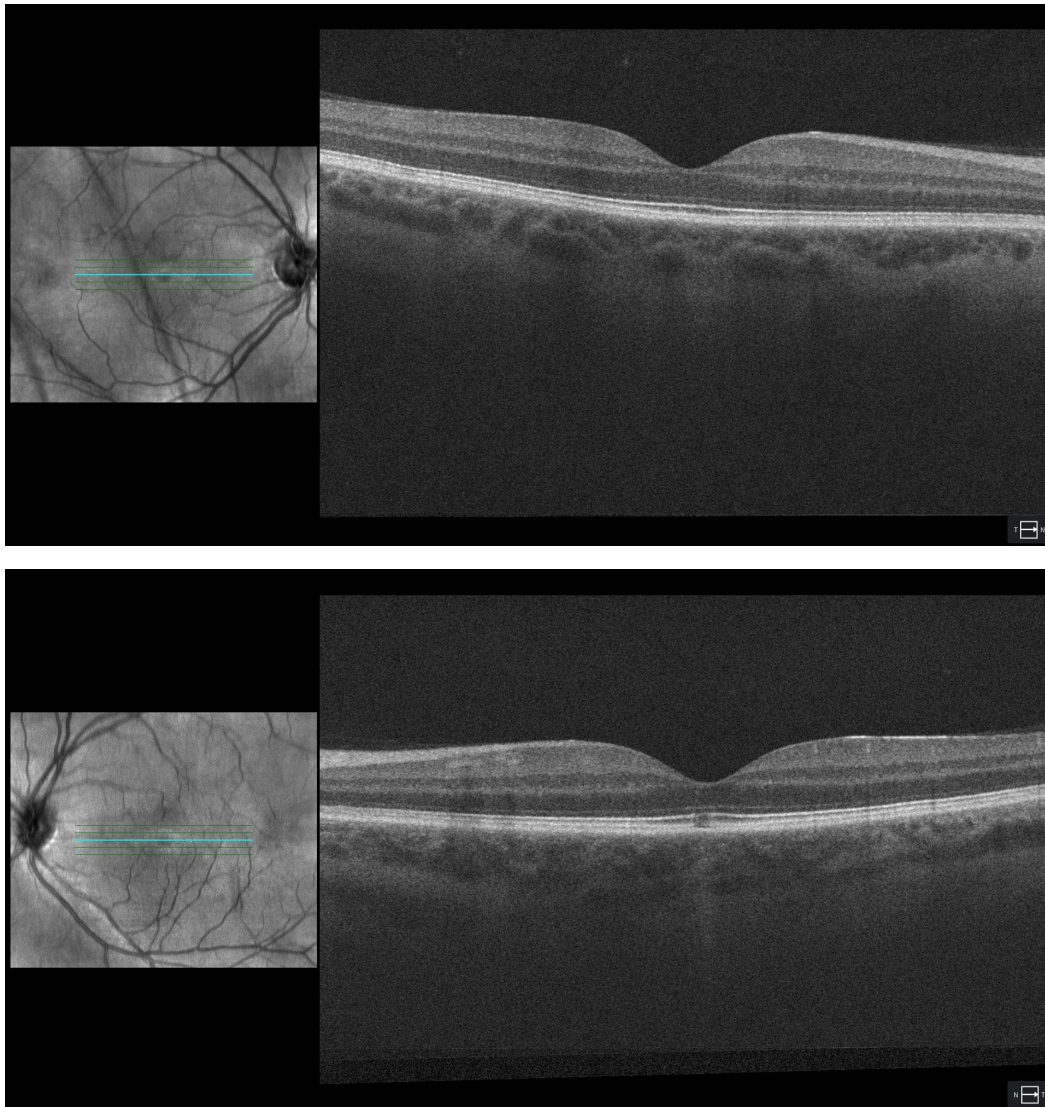


Figure 2. Cirrus SD-OCT (Carl Zeiss Meditec) images of the normal outer retinal layers OD and the outer retinal disruption OS. There is fragmentation subfoveally at the level of the inner segment ellipsoid band.

A diagnosis of Welder's Maculopathy was made, and the findings were discussed with the patient, along with the recommendations of reducing sun and light exposure with sunglasses, wide brimmed hats when outside, and the appropriate protective eyewear when in the workplace and/ or when welding. Yearly comprehensive eye examinations were recommended.

Discussion

Arc welding is a process that fuses metal to metal with a high-current electric arc. This process produces large quantities of UV to infrared (IR) radiation⁷, with a high spectral irradiance between 200 and 400 nm, mainly UV-A and UV-B. UV radiation has been classified into three subgroups, UV-A (315-400nm), UV-B (280-315nm) and UV-C (100-280nm). The human eye ensures minimal harmful radiation reaches the retina; however, small percentages of harmful rays can still reach the fundus. The cornea filters UV-C, which is already almost all absorbed by the ozone.^{19,20} Aqueous humor absorbs UV-B with some UV-A (range 280-360nm) and long infrared rays (1200-2300nm).²¹ The lens in young individuals absorbs UV-A and due to the yellowing of the lens with age, older individuals also have UV-B absorbed by the lens.^{22,23} The retina receives near infrared (700-1200nm), visible light (400-700nm) and in young persons, a small percentage of UV-A and UV-B due to the cloudless lens.²⁴ A traditional sunburn is caused by UV-B and the cornea is most sensitive to photo-damage by UV-C.²⁵⁻³⁰ As UV is toxic to the retinal photoreceptors and the RPE, high energy UV-B with prolonged exposure can cause photochemical damage to these outer retinal layers.³¹

Light toxicity can cause three types of damage: photothermal, photomechanical and photochemical. Photothermal and photomechanical processes by UV radiation make small contributions to retinal damage. The majority of retinal compromise is from photochemical pathways, as it is hypothesized to produce free radicals in retinal tissue from long exposure times to lower wavelength (higher energy) radiation.³²

The most common of the UV retinopathies is solar retinopathy,⁷ as most individuals develop this from directly observing solar eclipses. In one study, Stokkermans and Dunbar over a 2-year period discovered 20 cases (26 eyes), where 60% of UV retinopathy cases were due to sun gazing and 15% to arc welding.³³

Historical clues may also give guidance on the etiology of the UV retinopathy. Some patients disclose details on the source of the optical radiation; however, many are not aware. In our patient, the initial insult was many years prior and not recognized at the time that it could cause damage to him. Careful questioning regarding sun gazing (especially of a solar eclipse), hobbies (high sunlight reflection as in skiing, sailing), and occupational history (arc welding), can lead to the source of the UV retinopathy. In this case, the patient recalled about a dozen incidents of "Welder's flash" or UV keratitis during his time as an arc welder.

Patients with UV retinopathy usually present acutely with symptoms of decreased vision, metamorphopsia, dyschromatopsia, central/paracentral scotomas and/or

frontal headaches. Best-corrected visual acuities are typically in the range of 20/30 to 20/60, but have been reported to be as poor as count fingers.^{34,35} When visual acuities are dramatically reduced, patients seek medical advice acutely (days, weeks); however, as in our case, when there is chronic exposure, it can take months, years, or decades to present for medical attention.

As the time from initial UV insult to seeking medical help can vary from hours to decades, the ophthalmic examination findings vary as well. In the acute phase of UV insult to the outer retinal layers, there may be no retinal defects; however, macular edema may be present. The edema usually resolves in a few days. In the early phase, retinopathy may present as a central yellow-white macular lesion with surrounding mottled pigment. Over time, this lesion usually evolves to a well-circumscribed red lesion.⁸⁻¹³

The advent of SD-OCT has allowed clinicians to have a better understanding of this maculopathy. Numerous studies have used SD-OCT to examine patients with UV retinopathies, including Welder's Maculopathy. After exposure, the acute stages demonstrate hyperreflectivity of the photoreceptors and hyporefectivity of the RPE, due to photochemical disruption of these layers. This causes the characteristic loss of the outer retinal layers, described by many as a square shaped hole in the outer retinal layers that extends from the RPE band to the external limiting membrane (ELM) that includes the segmental foveal loss of the ISe band.^{7,36-44} The characteristic fragmented loss of the ISe band (also known as the photoreceptor inner segment/outer segment junction) has been shown to correlate with visual function in the case of solar retinopathy, as noted by Klemencic, et al.⁴⁰ UV retinopathy from welders and sungazing have a similar clinical and SD-OCT appearance, with SD-OCT being the most sensitive test in identifying chronic macular lesions.

Fluorescein angiography is not currently utilized as a diagnostic tool for Welder's Maculopathy, or for any of the UV retinopathies, as most are angiographically normal. It can be useful when ruling out other conditions, such as concern if there is concomitant choroidal neovascularization. A few studies have demonstrated window defects and parafoveal leakage,^{10,45,46} but this is not common. SD-OCT is the most sensitive test in identifying chronic macular lesions,⁴⁷⁻⁵⁰ even when asymptomatic.

In many cases of Welder's Maculopathy, the retinal injury spontaneously resolves without loss of vision; however, more severe cases can cause reduced best-corrected visual acuity or central scotomas. Maier et al found in a case-control study that there were no functional differences between welders, and non-welders.

Interestingly, they noted that on average, visual acuity was better in the welder group, compared to the control group.⁴⁹

Recommendations for welders should include occupational tinted lenses to filter UV-A and UV-B radiation with side shields to prevent oblique light rays from entering the pupil. Currently, there is no standard treatment for this condition. Systemic corticosteroids have been studied in the acute phase with macular edema, without success.⁵¹ As most cases are self-limiting, novel therapeutic approaches are limited.

Conclusion

Welder's Maculopathy is an established, but infrequently encountered, cause of UV retinopathy. Careful case history will aid the clinician in determining the appropriate cause of this characteristic retinopathy. Although most cases can acutely cause decreased vision, metamorphopsia, dyschromatopsia, central/paracentral scotomas and/or frontal headaches, most cases are self-limiting and cause no long-term functional sequelae. Chronic conditions may be an incidental finding, usually characterized by a central red macular lesion. SD-OCT findings from photochemical injury to the photoreceptors and RPE lead to a box-shaped outer retinal hole that can interrupt the ISe band. The interruption of the ISe band can be a determinant of visual prognosis. Careful occupational education should be discussed with each patient to ensure no future occurrences, which demonstrates the importance of a thorough case history to determine the underlying etiology.

References

1. Wu CY, Jansen ME, Andrade J, et al. Acute Solar Retinopathy Imaged with Adaptive Optics, Optical Coherence Tomography Angiography, and En Face Optical Coherence Tomography. *JAMA Ophthalmol* 2018;136(1):82-5. DOI: [10.1001/jamaophthalmol.2017.5517](https://doi.org/10.1001/jamaophthalmol.2017.5517)
2. Sheemar A, Takkar B, Temkar S, Venkatesh P. Solar Retinopathy: The Yellow Dot and the Rising Sun. *BMJ Case Rep* 2017;2017. DOI: [10.1136/bcr-2017-222690](https://doi.org/10.1136/bcr-2017-222690)
3. Birdsong O, Ling J, El-Annan J. Solar Retinopathy. *Ophthalmology* 2016;123(3):570. DOI: [10.1016/j.ophtha.2016.01.003](https://doi.org/10.1016/j.ophtha.2016.01.003)
4. Berus T, Turno-Krecicka A, Kwiatkowska E. Solar Retinopathy. *Klin Oczna* 2016;117(4):271-4.
5. Moran S, O'Donoghue E. Solar Retinopathy Secondary to Sungazing. *BMJ Case Rep* 2013;2013. DOI: [10.1136/bcr-2012-008402](https://doi.org/10.1136/bcr-2012-008402)

6. Levy S, Sheck L, Guest S. OCT Appearances in Acute Solar Retinopathy. *Arch Ophthalmol* 2012;130(12):1540. DOI: [10.1001/archophthalmol.2012.714](https://doi.org/10.1001/archophthalmol.2012.714)
7. Begaj T, Schaal S. Sunlight and Ultraviolet Radiation-Pertinent Retinal Implications and Current Management. *Surv Ophthalmol* 2018;63(2):174-92. DOI: [10.1016/j.survophthal.2017.09.002](https://doi.org/10.1016/j.survophthal.2017.09.002)
8. Bechmann M, Ehrt O, Thiel MJ, et al. Optical Coherence Tomography Findings in Early Solar Retinopathy. *Br J Ophthalmol* 2000;84(5):547-58. DOI: [10.1136/bjo.84.5.546b](https://doi.org/10.1136/bjo.84.5.546b)
9. Berus T, Turno-Krecicka A, Kwiatkowska E. High-Definition Optical Coherent Tomography Findings in Acute Solar Retinopathy - a Case Series. *Klin Oczna* 2016;118(1):29-31.
10. Dhir SP, Gupta A, Jain IS. Eclipse retinopathy. *Br J Ophthalmol* 1981;65(1):42-5.
11. Leys A, Swinnen T, Hannon L, Van Wing F. Solar Retinopathy and Foveal Cysts. *Bull Soc Belge Ophtalmol.* 1978;182:74-81. DOI: [10.1136/bjo.65.1.42](https://doi.org/10.1136/bjo.65.1.42)
12. Tarr KH, Clemett RS. Late Features of Solar Retinopathy. *Trans Ophthalmol Soc NZ* 1983;35:26-8.
13. Verma L, Sharma N, Tewari HK, Gupta S. Retinopathy After Solar Eclipse, 1995. *Natl Med J India* 1996;9(6):266-7.
14. Cho SC, Woo SJ, Park KH, Hwang JM. Morphologic Characteristics of the Outer Retina in Cone Dystrophy on Spectral-Domain Optical Coherence Tomography. *Korean J Ophthalmol* 2013;27(1):19-27. DOI: [10.3341/kjo.2013.27.1.19](https://doi.org/10.3341/kjo.2013.27.1.19)
15. Gill JS, Georgiou M, Kalitzeos A, et al. Progressive Cone and Cone-Rod Dystrophies: Clinical Features, Molecular Genetics and Prospects for Therapy. *Br J Ophthalmol* 2019. DOI: [10.1136/bjophthalmol-2018-313278](https://doi.org/10.1136/bjophthalmol-2018-313278)
16. Prokofyeva E, Troeger E, Bernd A, Zrenner E. Visual Acuity Changes in Cone and Cone-Rod Dystrophies. *Ophthalmic Physiol Opt* 2012;32(1):53-9. DOI: [10.1111/j.1475-1313.2011.00883.x](https://doi.org/10.1111/j.1475-1313.2011.00883.x)
17. Simunovic MP, Moore AT. The Cone Dystrophies. *Eye (Lond)* 1998;12(Pt 3b):553-65. DOI: [10.1038/eye.1998.145](https://doi.org/10.1038/eye.1998.145)
18. Hamel CP. Cone Rod Dystrophies. *Orphanet J Rare Dis* 2007;2:7. DOI: [10.1186/1750-1172-2-7](https://doi.org/10.1186/1750-1172-2-7)
19. Dillon J. The Photophysics and Photobiology of the Eye. *J Photochem Photobiol B.* 1991;10(1-2):23-40.
20. Dillon J, Zheng L, Merriam JC, Gaillard ER. The Optical Properties of the Anterior Segment of the Eye: Implications for Cortical Cataract. *Exp Eye Res* 1999;68(6):785-95. DOI: [10.1006/exer.1999.0687](https://doi.org/10.1006/exer.1999.0687)
21. Sliney DH. How Light Reaches the Eye and its Components. *Int J Toxicol* 2002;21(6):501-9. DOI: [10.1080/10915810290169927](https://doi.org/10.1080/10915810290169927)

22. Broendsted AE, Hansen MS, Lund-Andersen H, et al. Human Lens Transmission of Blue Light: a Comparison of Autofluorescence-Based and Direct Spectral Transmission Determination. *Ophthalmic Res* 2011;46(3):118-24. DOI: [10.1159/000323576](https://doi.org/10.1159/000323576)
23. Kessel L, Lundeman JH, Herbst K, et al. Age-Related Changes in the Transmission Properties of the Human Lens and Their Relevance to Circadian Entrainment. *J Cataract Refract Surg* 2010;36(2):308-12. DOI: [10.1016/j.jcrs.2009.08.035](https://doi.org/10.1016/j.jcrs.2009.08.035)
24. Lai K, Di Girolamo N, Conway RM, et al. The Effect of Ultraviolet Radiation on Choroidal Melanocytes and Melanoma Cell Lines: Cell Survival and Matrix Metalloproteinase Production. *Graefes Arch Clin Exp Ophthalmol* 2007;245(5):715-24. DOI: [10.1007/s00417-006-0444-x](https://doi.org/10.1007/s00417-006-0444-x)
25. Bergmanson JP, Soderberg PG. The Significance of Ultraviolet Radiation for Eye Diseases. A Review with Comments on the Efficacy of UV-Blocking Contact Lenses. *Ophthalmic Physiol Opt* 1995;15(2):83-91.
26. Cullen AP. Photokeratitis and Other Phototoxic effects on the Cornea and Conjunctiva. *Int J Toxicol* 2002;21(6):455-64. DOI: [10.1080/10915810290169882](https://doi.org/10.1080/10915810290169882)
27. Jones TR, Gillen JP. Ultraviolet Light-Induced Keratitis Secondary to Germicidal Lamp Exposure Resulting in Corneal Epithelial Sloughing. *Am J Emerg Med* 1992;10(5):508-9. DOI: [10.1016/0735-6757\(92\)90079-d](https://doi.org/10.1016/0735-6757(92)90079-d)
28. Millodot M, Earlam RA. Sensitivity of the Cornea After Exposure to Ultraviolet Light. *Ophthalmic Res* 1984;16(6):325-8. DOI: [10.1159/000265338](https://doi.org/10.1159/000265338)
29. Mitchell J, Cenedella RJ. Quantitation of Ultraviolet Light-Absorbing Fractions of the Cornea. *Cornea* 1995;14(3):266-72.
30. Young RW. The Family of Sunlight-Related Eye Diseases. *Optom Vis Sci* 1994;71(2):125-44.
31. Wu J, Seregard S, Algvere PV. Photochemical Damage of the Retina. *Surv Ophthalmol* 2006;51(5):461-81. DOI: [10.1016/j.survophthal.2006.06.009](https://doi.org/10.1016/j.survophthal.2006.06.009)
32. Youssef PN, Sheibani N, Albert DM. Retinal Light Toxicity. *Eye (Lond)* 2011;25(1):1-14. DOI: [10.1038/eye.2010.149](https://doi.org/10.1038/eye.2010.149)
33. Stokkermans TJ, Dunbar MT. Solar Retinopathy in a Hospital-Based Primary Care Clinic. *J Am Optom Assoc* 1998;69(10):625-36.
34. Kleinmann G, Hoffman P, Schechtman E, Pollack A. Microscope-Induced Retinal Phototoxicity in Cataract Surgery of Short Duration. *Ophthalmology* 2002;109(2):334-8. DOI: [10.1016/s0161-6420\(01\)00924-1](https://doi.org/10.1016/s0161-6420(01)00924-1)
35. Hossein M, Bonyadi J, Soheilian R, et al. Spectral-Domain Optical Coherence Tomography Features of Mild and Severe Acute Solar Retinopathy.

- Ophthalmic Surg Lasers Imaging* 2011;42 Online:e84-6. DOI: [10.3928/15428877-20110901-05](https://doi.org/10.3928/15428877-20110901-05)
36. Park DW, Alonzo B, Faridi A, Bhavsar KV. Multimodal Imaging of Photic Maculopathy from Arc Welding. *Retin Cases Brief Rep* 2018. DOI: [10.1097/ICB.0000000000000823](https://doi.org/10.1097/ICB.0000000000000823)
37. Sheth J, Vidhya N, Sharma A. Spectral-Domain Optical Coherence Tomography Findings in Chronic Solar Retinopathy. *Oman J Ophthalmol* 2013;6(3):208-9. DOI: [10.4103/0974-620X.122281](https://doi.org/10.4103/0974-620X.122281)
38. Rusu I, Sherman J, Gallego-Pinazo R, et al. Spectral-Domain Optical Coherence Tomography and Fundus Autofluorescence Findings in a Case of Laser Pointer-Induced Maculopathy. *Retin Cases Brief Rep* 2013;7(4):371-5. DOI: [10.1097/ICB.0b013e3182965291](https://doi.org/10.1097/ICB.0b013e3182965291)
39. Mahindrakar A, Toshniwal S, Doongerwala MI, Anthony H. Spectralis Optical Coherence Tomography Findings in Welder's Maculopathy. *Indian J Ophthalmol* 2013;61(5):238-40. DOI: [10.4103/0301-4738.113318](https://doi.org/10.4103/0301-4738.113318)
40. Klemencic S, McMahon J, Upadhyay S, Messner L. Spectral Domain Optical Coherence Tomography as a Predictor of Visual Function in Chronic Solar Maculopathy. *Optom Vis Sci* 2011;88(8):1014-9. DOI: [10.1097/OPX.0b013e31821de819](https://doi.org/10.1097/OPX.0b013e31821de819)
41. Comander J, Gardiner M, Loewenstein J. High-Resolution Optical Coherence Tomography Findings in Solar Maculopathy and the Differential Diagnosis of Outer Retinal Holes. *Am J Ophthalmol* 2011;152(3):413-9 e416. DOI: [10.1016/j.ajo.2011.02.012](https://doi.org/10.1016/j.ajo.2011.02.012)
42. Pilli S, Ogoti M, Kalluri V. Fourier-Domain Optical Coherence Tomography Findings in Welder's Maculopathy. *Ophthalmic Surg Lasers Imaging* 2010:1-5. DOI: [10.3928/15428877-20100215-93](https://doi.org/10.3928/15428877-20100215-93)
43. Lucas RS, Harper CA, McCombe MF, et al. Optical Coherence Tomography Findings in Welder's Maculopathy. *Retin Cases Brief Rep* 2007;1(3):169-71. DOI: [10.1097/01.ICB.0000279652.22196.70](https://doi.org/10.1097/01.ICB.0000279652.22196.70)
44. Vedantham V. Optical Coherence Tomography Findings in a Case of Chronic Welder's Maculopathy. *Eye (Lond)* 2006;20(2):269-71. DOI: [10.1038/sj.eye.6701846](https://doi.org/10.1038/sj.eye.6701846)
45. Arda H, Oner A, Mutlu S, et al. Multifocal Electroretinogram for Assessing Sun Damage Following the Solar Eclipse of 29 March 2006: Multifocal Electroretinography in Solar Maculopathy. *Doc Ophthalmol* 2007;114(3):159-62. DOI: [10.1007/s10633-007-9049-x](https://doi.org/10.1007/s10633-007-9049-x)
46. Atmaca LS, Idil A, Can D. Early and Late Visual Prognosis in Solar Retinopathy. *Graefes Arch Clin Exp Ophthalmol* 1995;33(12):801-4. DOI: [10.1007/bf00184094](https://doi.org/10.1007/bf00184094)
47. Brittain GP. Retinal burns caused by exposure to MIG-Welding Arcs: Report of Two Cases. *Br J Ophthalmol* 1988;72(8):570-5. DOI: [10.1136/bjo.72.8.570](https://doi.org/10.1136/bjo.72.8.570)

48. Power WJ, Travers SP, Mooney DJ. Welding Arc Maculopathy and fluphenazine. *Br J Ophthalmol* 1991;75(7):433-5. DOI: [10.1136/bjo.75.7.433](https://doi.org/10.1136/bjo.75.7.433)
49. Maier R, Heilig P, Winker R, et al. Welder's Maculopathy? *Int Arch Occup Environ Health* 2005;78(8):681-5. DOI: [10.1007/s00420-005-0013-3](https://doi.org/10.1007/s00420-005-0013-3)
50. Yang X, Shao D, Ding X, et al. Chronic Phototoxic Maculopathy Caused by Welding Arc in Occupational Welders. *Can J Ophthalmol* 2012;47(1):45-50. DOI: [10.1016/j.cjco.2011.12.001](https://doi.org/10.1016/j.cjco.2011.12.001)
51. Rosner M, Lam TT, Tso MO. Therapeutic Parameters of Methylprednisolone Treatment for Retinal Photoc Injury in a Rat Model. *Res Commun Chem Pathol Pharmacol* 1992;77(3):299-311.