

2000

# The Chattanooga Procedure: A New Technique Used for Anterior Multi-level Cervical Fusions

Elizabeth Van Horn

Scott D. Hodges

S. Craig Humphreys

Jason Eck

Laurie Covington

*See next page for additional authors*

Follow this and additional works at: [https://knowledge.e.southern.edu/senior\\_research](https://knowledge.e.southern.edu/senior_research)



Part of the [Biology Commons](#)

---

## Recommended Citation

Van Horn, Elizabeth; Hodges, Scott D.; Humphreys, S. Craig; Eck, Jason; Covington, Laurie; and Peterson, Joseph E.D., "The Chattanooga Procedure: A New Technique Used for Anterior Multi-level Cervical Fusions" (2000). *Senior Research Projects*. 76. [https://knowledge.e.southern.edu/senior\\_research/76](https://knowledge.e.southern.edu/senior_research/76)

This Article is brought to you for free and open access by the Southern Scholars at KnowledgeExchange@Southern. It has been accepted for inclusion in Senior Research Projects by an authorized administrator of KnowledgeExchange@Southern. For more information, please contact [jspears@southern.edu](mailto:jspears@southern.edu).

---

**Authors**

Elizabeth Van Horn, Scott D. Hodges, S. Craig Humphreys, Jason Eck, Laurie Covington, and Joseph E.D. Peterson

# **The Chattanooga Procedure: A New Technique Used for Anterior Multi-level Cervical Fusions**

**Scott D. Hodges, D.O., S. Craig Humphreys, M.D., Jason Eck, M.S., Laurie A. Covington, B.S., Elizabeth R. Van Horn\*, Joseph E.D. Peterson**

The Center for Sports Medicine and Orthopaedics, Foundation for Research, Chattanooga, TN 37404, \*Department of Biology, Southern Adventist University, Collegedale, TN 37315

Mailing address: Elizabeth Van Horn  
Department of Biology  
Southern Adventist University  
P.O Box 370  
Collegedale, TN 37315  
Telephone number: (423) 238-2926  
Fax number: (423) 238-2197

Key words: cervical fusions, anterior cervical discectomy, cervical degenerative disease, cervical disc surgery, anterior cervical plate, anterior cervical fusion, multilevel cervical fusions, cervical instrumentation

Running title: ANTERIOR MULTI-LEVEL CERVICAL FUSION

**ABSTRACT**

**STUDY DESIGN:** A preliminary assessment of anterior cervical fusion performed with interbody cage and DOC plate.

**OBJECTIVES:** To describe and evaluate the efficacy and safety of the “Chattanooga Procedure”, a modified technique in achieving anterior cervical fusion.

**SUMMARY OF BACKGROUND DATA:** Anterior cervical fusion with interbody bone graft and anterior plating is commonly performed. Unfortunately, the plate has been reported to shield the graft from loading thus reducing fusion rates. The use of interbody fusion cages has been effective in the lumbar spine and has gained acceptance in the cervical spine.

**METHODS:** Twenty-five patients received “The Chattanooga Procedure” between 7/24/98 and 4/8/99. All patients had anterior discectomies and corpectomies, placement of a Harms cage packed with corpectomy bone, and application of DePuy-Acromed DOC. Fusion was defined by radiographic evidence of trabecular bone bridging across the Harms cage. CT scans were performed on twelve randomly chosen patients to verify fusion. No external bracing was used except a soft collar as needed. Pre- and post-operative pain and functional capacity data were collected and statistically analyzed using paired t-tests.

**RESULTS:** There were no cases of pseudoarthrosis, major neurological, vascular, or wound complications. Only one case of unresolved dysphasia was noted. The average operative time (110 minutes) was comparable to standard instrumented multi-level anterior cervical fusion surgeries. The average estimated blood loss was 113 ml (range, 50-750 ml). Both visual analog pain scale and Oswestry functional capacity data were significantly improved post-operatively ( $p < 0.01$ ).

## ANTERIOR MULTI-LEVEL CERVICAL FUSION

**DISCUSSION:** Advantages of the “Chattanooga Procedure” include immediate stability, support, elimination of donor site pain to iliac crest bone autograft, and a decrease in pseudoarthrosis by dividing the fusion surfaces by half. Concerns regarding this technique include an increased risk for dysphasia due to the DOC’s high profile. Pseudoarthrosis or instrumentation migration could also become problematic since the removal of the Harms cage could be difficult if necessary.

## INTRODUCTION

Since the introduction of an anterior approach to cervical discectomy and fusion surgery in the 1950's by Bailey and Badgley<sup>1</sup>, Smith and Robinson<sup>25</sup>, and Cloward<sup>3</sup>, it has become widely successful in achieving arthrodesis, relieving pain, radiculopathy and myelopathy<sup>1-4,6,10,11,18,20,21,25,31</sup>. Surgical indications for an anterior cervical discectomy and fusion include fractured, degenerated, and herniated cervical disc diseases<sup>2,5,7,9,19,23,24</sup>. Anterior cervical discectomy relieves the pain resulting from compression of the spinal cord or nerve roots as they exit the foramen. In order to retain spinal stability, an interbody fusion is generally performed. Traditionally, fusion has been performed using autograft bone harvested from the iliac crest<sup>2,47</sup>. The high rate of donor site complications including hematoma, dysesthesias, nerve injuries, pain, and fracture<sup>15,19,22</sup> have prompted the search for a new source of graft material<sup>12,13,28,32</sup>. To avoid some of these complications, fibular allografts<sup>16,22</sup>, or the patient’s own corpectomy bone<sup>14</sup> have been substituted.

The use of interbody titanium cages has been effective in the lumbar spine in terms of increasing stability and load bearing capacity while maintaining proper sagittal plane alignment and disc height. Bone graft from the corpectomy can be packed into and around the cage thus reducing the need for an alternative graft source.

## ANTERIOR MULTI-LEVEL CERVICAL FUSION

Presently there are several plating options available to spinal surgeons for anterior multilevel cervical fusions. Among these are the Sofamor Danek-Orion plate and Synthes AO locking plate. These are each rigid, locked plating systems that provide a stable environment for achieving fusion<sup>10,26,27,29</sup>. One major criticism of the anterior plating system is that the bone graft may be shielded from mechanical loading due to the presence of the plate. Previous biomechanical studies have reported increased stiffness measured in segments with interbody bone grafts and anterior cages as compared to grafts alone<sup>30,33</sup>. The increased stiffness of the implant supports a greater portion of the axial load thus interfering with active bone remodeling at the graft site. However, another study reported that the intervertebral bone graft was not subjected to load shielding but rather to load sharing<sup>17</sup>. This would suggest that the graft is still supporting sufficient axial load to stimulate bone growth.

In an effort to enhance the occurrence of anterior cervical fusion the authors have utilized a new technique, the “Chattanooga Procedure”, combining two different instrumentation systems: The DePuy-AcroMed DOC anterior cervical plating system and the Harms cage. The purpose of this article is to describe this new surgical technique and to provide a preliminary assessment of patient outcomes and the advantages and disadvantages of this technique.

## MATERIALS AND METHODS

### *Surgical Background*

Two orthopaedic spinal specialists from the middle-Tennessee valley area, with a combined 15-years of surgical experience have devised and incorporated the following operative procedure into their practice for anterior multi-level cervical fusion surgeries. Entitled the “Chattanooga Procedure”

## ANTERIOR MULTI-LEVEL CERVICAL FUSION

this surgical technique combines the DePuy-AcroMed DOC anterior cervical plating system with the Harms cage.

### *Surgical Technique*

Antibiotic prophylaxis was given prior to surgery. Electrophysiology monitors and leads were inserted and used throughout the procedure. In some three-level or upper cervical level fusions skeletal traction was utilized to increase stability.

The longitudinal Smith-Robinson<sup>25</sup> approach was utilized. The anterior portion of the cervical spine was then identified and the fascia bluntly dissected away. Markers were placed in the vertebral body and interoperative x-rays were taken to verify levels. Retractors and Caspar distraction pins were placed at the appropriate levels. A microscope was used during exposure and throughout the remainder of the case. Beginning with the first level, anterior osteophytes were removed when present and distraction carried out across the disc space. The anterior lip of the superior vertebral body was removed with a 2-mm Kerrison rongeur. The disc space was entered with sharp incision through the anterior annulus. The anterior longitudinal ligament and the anterior portion of the annulus fibrosis were released. A complete discectomy was carried out back to the posterior longitudinal ligament using a combination of curettes, rongeurs and elevators. The lateral portions of the uncinat process were visualized bilaterally. The posterior longitudinal ligament was taken down with 1-mm and 2-mm Kerrison rongeurs, and epidural space was inspected for loose disc fragments. Discectomies were usually wide - 18-mm from uncinat process to uncinat process.

After identical discectomies were performed at the other involved levels, and all wounds were irrigated, the distractor pins were removed. A rongeur was used to carry out a partial corpectomy

#### ANTERIOR MULTI-LEVEL CERVICAL FUSION

removing approximately 75% or 80% of the vertebral body. This bone was ground for packing the intervertebral cage. The bone was removed with a 4-mm bur and a Kerrison rongeur. After corpectomies and decompression were completed, the wounds were again irrigated and meticulous hemostasis was obtained.

Calipers were used to measure the distance between the inferior upper portion of the superior most vertebra and the superior portion of the inferior most vertebra and a 12 to 14-mm Harm's cage was then cut to the appropriate height. The Harm's cage was filled with cancellous bone graft from the previous corpectomies. Distraction was gently applied across the neck, and the cage was inserted. Distraction was released allowing firm fixation, and the area was assessed for fit and feel of the cage. Additional bone graft was packed to the sides of the cage.

The DePuy-AcroMed DOC anterior segmental system was set to the appropriate length and depth, allowing for compression. The implant was placed over the anterior surface of the vertebral bodies. The lockable platform is adjusted to allow the platform fins to rest against the vertebral endplates. The rods were visible in both windows of the lockable platforms and did not extend more than 3-mm beyond the caudal platform. After proper placement, the system was temporarily secured in position with the construct securing pins to ensure implant position. Holes were drilled, 14-mm outer bone screws were inserted securing the implant to the vertebral bodies. Inner locking screws were then inserted into the outer bone screws. The amount of axial settling could be adjusted by changing the distance between the cross connector and the platform. The maximum amount of axial settling did not exceed 3-mm per disc level. An intraoperative x-ray was taken confirming proper positioning and alignment of the implants and the cage.



## ANTERIOR MULTI-LEVEL CERVICAL FUSION

The wounds were copiously irrigated, and a small drain was placed in the wound. The platysmas was re-approximated with 2 Vicryl suture. Subcuticular 4-0 Monocryl was used for skin closure. Steri-strips and a sterile dressing were applied. No external bracing was used except a soft collar was used as needed dependent upon patient.

### *Clinical Methods*

Patient outcomes were determined based on four specific areas: clinic evaluation, radiographic review, surgical notes and patient questionnaires/phone interviews. A comprehensive analysis of these data, pre- and post-operatively, allowed for a complete picture of surgical success and patient satisfaction.

Post-operative radiographs were utilized to monitor fusion, which was defined as radiographic evidence of trabecular bone bridging across the Harms cage. Computer tomography (CT) scans were also obtained for 12 randomly chosen patients to verify fusion rates (Figures 1: A &B).

Patients rated their pre- and post-operative pain using a classic 10-point visual analog pain scale (VAS);(Center for Sports Medicine, Foundation for Research, Chattanooga, TN). Although designed for the low back, the Oswestry Low Back Pain and Disability Questionnaire (Center for Sports Medicine, Foundation for Research, Chattanooga, TN) was also used as an additional tool to help measure patient's functional disability level. Data for the VAS and OSW were statistically analyzed using a paired t-test to identify any significant changes following surgery (Table 1).

## RESULTS

### *Patients*

Twenty-five patients (Table 1) underwent the "Chattanooga Procedure" between July 1998

## ANTERIOR MULTI-LEVEL CERVICAL FUSION

and April 1999 for a variety of indications including herniated disc, spondylosis, myelopathy, radiculopathy, spinal stenosis, and central cord syndrome. Patients included 15 males (60%) and 10 females (40%). The average patient age was 55.8 years (range 35-73 years). Three patients were smokers, four were worker's compensation cases, and one was involved in litigation (Table 1).

### ***Outcomes***

The mean follow-up period for the "Chattanooga Procedure" patients was 13 months (range, 9-17 months) and they have shown to have very positive results. Both VAS and OSW scores were significantly decreased following surgery ( $p < 0.01$ ). The mean improvement in the VAS was 58.4% and the OSW improved by a mean 49.9%. There were no cases of pseudoarthrosis, no major neurological, vascular or wound complications. There was one case of mild dysphasia unresolved at follow-up.

Hospital stay was a mean of 2.3 days (range, 1-7 days), the mean operative was 110 minutes (range, 80-180 minutes), and the estimated blood loss was 113 ml (range, 50 to 750 ml). The mean cost for a multi-level cervical surgery was \$15,392.32 (range, \$11,229.84-29,967.48), which includes hospital admission to discharge.

CT scans were performed on twelve randomly chosen patients to evaluate fusion rates. All patients showed fusion (Figures 1: A & B). The mean number of levels fused was 2.2 (range 2-4), the most common being C5-C7 (range of C4-T1).

## **DISCUSSION**

Of the 25 patients in this study with the mean follow-up of 13 months (range, 9-17 months), they have shown very positive results. Both the pain and functional capacity scores were significantly

## ANTERIOR MULTI-LEVEL CERVICAL FUSION

reduced followed surgery. There were no serious complications encountered, however, there was one case of mild dysphasia that remained unresolved at follow-up.

The VAS rating scale measures overall pain severity. As a 10-cm horizontal line, it represents a symptom continuum of two extremes. The 0-cm end rates “no pain at all” and the 10-cm end rates “total agony.” The Oswestry Low Back Pain Disability Questionnaire is divided into ten sections meant to assess various daily living activity limitations. Each section contains six statements of which the patient elects one best choice describing his limitations accurately. Each section is scored from 0-5; 5 depicts maximum disability. The Oswestry is scored as followed: a) 0-20 reflects minimal disability; b) 20-40 reflects moderate disability; c) 40-60 reflects severe disability; and d) 60-80 reflects crippled disability; and 80-100 reflects bed-bound or exaggerating disability<sup>8</sup>.

There are several options available to spine surgeons to achieve anterior decompression and fusion. Anterior cervical plates are useful in providing a stable environment for fusion. Additionally, interbody cages increase stability and load bearing capacity while maintaining proper alignment and disc height. It is our belief that the ideal technique for achieving anterior cervical fusion would make use of both of these devices.

The “Chattanooga Procedure” is similar to that described by Majd et al. who also combined interbody titanium cages with anterior cervical plating<sup>14</sup>. An important distinction in these two techniques is the choice of anterior plating system. The AcroMed DOC Ventral Cervical Stabilization System provides a dynamic implant system, allowing load sharing between the instrumentation and graft. This design allows for a controlled lordotic settling of the graft during the fusion process. The settling of the implant allows the device to adapt to the changing mechanics as the fusion develops

## ANTERIOR MULTI-LEVEL CERVICAL FUSION

and decreases the amount of load shielding by the plate, thus allowing the graft to support a greater portion of the axial load leading to improved possibilities of fusion.

As described by Martin et al. an advantage to using autogeneic grafts is their ability to participate actively in the bone healing process through osteogenesis. Osteogenesis requires live bone cells in the graft along with a few mature osteoblasts and osteocytes to remain viable after transplantation via diffusion. Allogeneic bone grafts cannot promote bone growth through osteogenesis<sup>15</sup>. Martin et al. also notes that the maintenance of graft height may also be affected by the bone resorption. Cancellous bone grafts and cortical grafts are contrasted in their rate and completeness depending upon their bone resorption. Cortical bone from fibular allografts take 1 to 2 months for incorporation, whereas cancellous bone from iliac crest or corpectomies lead to complete vascularization within 2 weeks. The shorter time is thought to be impetus to more complete incorporation of cancellous bone for fusion<sup>15</sup>.

Advantages in using the DOC system with the Harms cage include immediate stability, support, complete decompression of nerve roots, reestablishment/maintenance of disc height, elimination of donor site pain to iliac crest autograft, and a decrease in pseudoarthrosis by dividing the fusion surfaces by half. Also believed is the unique ability of the DOC plate to settle during the healing process to promote improved fusion by decreasing the load shielding at the graft site. Concerns regarding this technique include an increased risk for dysphasia due to the DOC's high profile. Ensuring that the plate is seated in the midline of the vertebral bodies can minimize its' profile. Pseudoarthrosis or instrumentation migration could also become problematic since removal of Harms cage could be difficult if necessary.

ANTERIOR MULTI-LEVEL CERVICAL FUSION

**A**

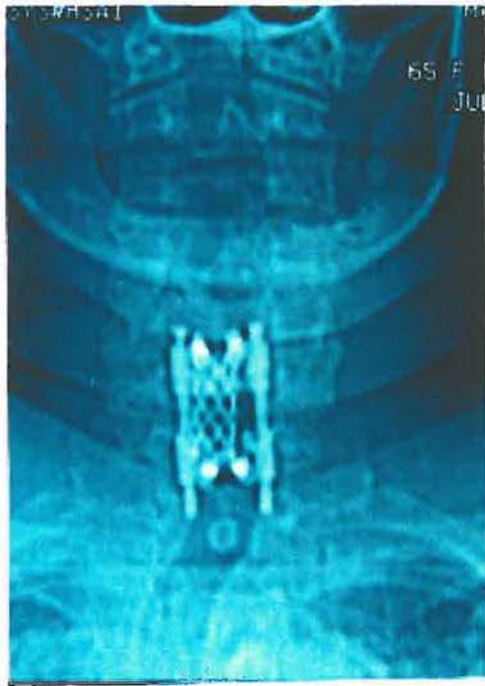
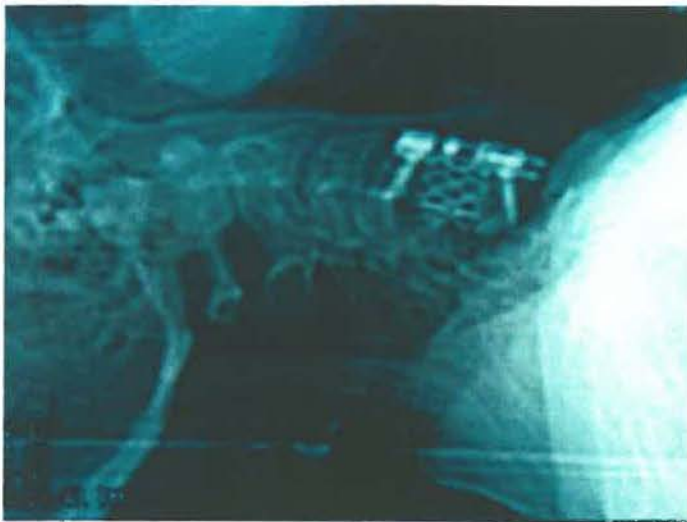

Figure 1: **A**, An anteriorly viewed CT scan of a two-level DePuy-AcroMed DOC Ventral plating system and the titanium Harms cage verifying fusion. **B**, Another two-level DePuy-AcroMed DOC Ventral plating system and the Harms cage from a lateral view also verifying fusion.

**B**





ANTERIOR MULTI-LEVEL CERVICAL FUSION

**Table 1: Clinical and Demographic Data on 25 Patients who underwent the “Chattanooga Procedure”.** (Stay = hospital stay, Lit = litigation, WC = worker’s compensation, VAS = visual analog pain scale, OSW = Oswestry functional disability index, \* Plus sign indicates exacerbation; minus sign indicates improvement).

Patient No.	Gender/ Age	Levels	Stay (days)	Lit	WC	Smoke	Pre-VAS	Post-VAS	% Change	Pre-OSW	Post-OSW	% Change
1	M/42	C5-7	2	N	Y	Y	8.0	4.0	-50	52	52	0
2	F/35	C5-7	1	N	N	N	5.0	0.0	-100	18	0	-100
3	M/38	C4-6	2	N	N	Y	4.0	3.0	-25	40	26	-35
4	M/60	C4-7	3	N	Y	Y	6.0	5.0	-16.7	23	38	65.2
5	M/58	C5-7	2	N	N	N	10.0	8.5	-15	74	70	-54
6	M/60	C4-6	3	N	N	N	6.5	8.0	23.1	56	44	-21.4
7	M/63	C4-6	2	N	N	N	10.0	5.0	-50	/	58	/
8	M/49	C5-7	5	N	N	N	10.0	7.5	-75	50	49	-2
9	F/61	C5-7	2	N	N	N	9.0	5.0	-44.4	26	0	-100
10	M/56	C4-7	2	N	N	N	4.5	0.0	-100	4	0	-100
11	F/52	C5-7	7	N	N	N	5.5	0.0	-100	38	10	-73.7
12	M/60	C4-6	2	N	N	N	2.0	0.0	-100	14	0	-100
13	F/61	C5-7	2	Y	N	N	7.0	3.0	-57.1	/	0	/
14	M/47	C5-7	1	N	Y	N	9.0	6.0	-33.3	50	46	-8
15	F/41	C4-6	2	N	N	N	10.0	3.0	-70	34	11	-67.6
16	F/55	C4-6	2	N	N	N	10.0	4.0	-60	4	0	-100
17	F/59	C5-7	1	N	N	N	9.5	8.0	-15.8	24	0	-100
18	F/55	C6-T1	2	N	N	N	10.0	3.0	-70	24	14	-41.7
19	M/59	C5-7	2	N	N	N	/	0.0	/	16	0	-100
20	M/71	C5-7	2	N	N	N	5.0	0.0	-100	22	0	-100
21	F/73	C4-6	3	N	N	N	8.0	0.0	-100	22	46	109.1
22	M/54	C5-7	2	N	N	N	8.0	0.0	-100	2	/	/
23	M/50	C5-7	1	N	Y	N	6.0	0.0	-100	28	6	-78.6
24	F/67	C4-6	2	N	N	N	4.0	3.0	-25	23	14	-39.1
25	F/69	C3-7	3	N	N	N	/	0.0	/	/	8	/
						<b>Means</b>	7.0	3.0	-58.4	29	21	-49.9

## ANTERIOR MULTI-LEVEL CERVICAL FUSION

### REFERENCES

1. Bailey RW, and Badgley CE. Stabilization of the cervical spine by anterior fusion. *J Bone Joint Surg [Am]* 1960;42:565-94.
2. Bohlman HH, Emery SE, Goodfellow DB, and Jones PK. Stabilization of the cervical discectomy and arthrodesis for cervical radiculopathy. *JBJS [Am]* 1993;75:1298-307.
3. Brodke DS, Zdeblick TA. Modified Smith-Robinson procedure for anterior cervical discectomy and fusion. *Spine* 1992;17(10 Suppl):S427-S430.
4. Cloward RB. The anterior approach for removal of ruptured discs. *J Neurosurg* 1958;15:602-614.
5. Clements DH, and O'Leary PF. Anterior cervical discectomy and fusion. *Spine* 1990;15:1023-1025.
6. DePalma AF, Rothman Lh, Lewinnek GE, Kanale TA. Anterior interbody fusion for severe cervical disc degeneration. *Surg Gynecol Obstet* 1972;134:755-758.
7. Dohn DF. Anterior interbody fusion for treatment of cervical disc conditions. *JAMA*.1996; 97:897-900.
8. Fairbanks FC., Couper TJ, Davies JB, and O'Brien JP. The Oswestry Low Back Pain Disability Questionnaire. *Physiotherapy*.1980;66:271-272.
9. Gore DR, and Sepic SB. Anterior cervical fusion for degenerated or protruded discs: A review of one-hundred forty six patients. *Spine* 1984;9:667-671.
10. Heidecke V, Rainov Ng, Burkert W. Anterior cervical fusion with the Orion locking plate system. *Spine* 1998;23(16):1796-1803.
11. Herkowitz HN. Comparison of anterior cervical fusion, cervical laminectomy, and cervical laminoplasty for the surgical spondylotic radiculopathy. *Spine* 1988;13:774-780.
12. Kurz LT, Garfin SR, and Booth RE Jr. Harvesting autogenous iliac bone grafts: A review of complication and techniques. *Spine*. 1989;14;1324-31.
13. Laurie SW, Kaban LB, Mulliken JB, Murray JE. Donor-site morbidity after harvesting rib and iliac crest bone. *Plast Reconstr Surg* 1984;73:933-938.
14. Majd ME, Vadhva M, and Holt RT. Anterior cervical reconstruction using titanium cages with anterior plating. *Spine* 1999;24(15):1604-1610.
15. Martin GJ Jr, Regis HW Jr, MacMillan M, Rodts, GE, and Berkman R. Anterior cervical discectomy with freeze-dried fibula allograft. *Spine* 1999;24(9):852-859.

## ANTERIOR MULTI-LEVEL CERVICAL FUSION

16. Molinari RW, Bridwell KH, Klepps SJ, and Baldus C. Minimum 5-year follow-up of anterior column structural allografts in the thoracic and lumbar spine. *Spine* 1999;24:967-972.
17. Rapoff AJ, O'Brien TJ, Ghanayem AJ, Heisey DM, Zdeblick TA. Anterior cervical graft and plate load sharing. *J Spinal Disord* 1999;12(1):45-49.
18. Riley LH, Robinson RA, Johnson KA, Walker AE. The results of anterior interbody fusion of the cervical spine. *J Neurosurg* 1969;30:127-133.
19. Ripa DR, Kowall MG, Meyer PR, and *et al*: Series of ninety two traumatic cervical spine injuries stabilized with anterior ASIF plate fusion technique. *Spine* 1991;16:S46-S55.
20. Robinson RA, Walker AE, Ferlic DC, and Wickling DK. The results of anterior interbody fusion of the cervical spine. *J Bone Joint Surg* 1962;44a:1569-1587.
21. Rosenorn J., Hansen EB, and Rosenorn M-A. Anterior cervical discectomy with and without fusion: A prospective study. *J Neurosurg* 1983;59:252-255.
22. Saunders R L, and Wilson DH. The surgery of cervical disk disease. New perspectives. *Clin Orthop* 1980;146:119-126.
23. Schnee CL, Freese A, Weil RJ, and Marcotte PJ. Analysis of harvest morbidity and radiographic outcome using autograft for anterior cervical fusion. *Spine* 1997;22:2222-2227.
24. Simmons EH, and Bhalla SK. Anterior cervical discectomy and fusion. A clinical and biomechanical study with 8-year follow-up. *J Bone Joint Surg [Br]* 1969;51:225-236, 1969.
25. Smith GW, Robinson RA. The treatment of certain cervical spine disorders by anterior removal of the intervertebral disc and interbody fusion. *J Bone Joint Surg [AM]* 1958;40:607-624.
26. Smith SA, Lindsey RW, Doherty BJ, Alexander J, Dickson JH. An in-vitro biomechanical comparison of the Orosco and AO locking plates for anterior cervical spine fixation. *J Spinal Disord* 1995;8(3):220-223.
27. Spivak JM, Chen D, Kummer FJ. The effect of locking fixation screws on the stability of anterior cervical plating. *Spine* 1999;24(4):334-338.
28. Summers BN, Eisenstein SM. Donor site pain from the ilium: A complication of lumbar spine fusion. *J Spine Surg [Br]* 1989;71:667-680.
29. Taha JM, Zuccarello M. ORION anterior cervical plating system. *Neurosurgery* 1996;38(3):607-610.
30. Takahashi T, Tominaga T, Yoshimoto T, Koshu K, Yokobori AT Jr, Aizawa Y. Biomechanical evaluation of hydroxyapatite intervertebral graft and anterior cervical plating in a porcine cadaveric



#### ANTERIOR MULTI-LEVEL CERVICAL FUSION

model. *Biomed Mater Eng* 1997;7(2):121-127.

31. Thalgott JS, Fritts K, Giuffre JM, Timlin M. Anterior interbody fusion of the cervical spine with coralline hydroxyapatite. *Spine* 24(13):1295-1299.
32. Younger EM, Chapman MW. Morbidity at bone graft donor sites. *J Orthop Trauma* 1989;3:192-195.
33. Zdeblick TA, Cooke ME, Wilson D, Kunz DN, McCabe R. Anterior cervical discectomy, fusion, and plating. A comparative animal study. *Spine* 1993;18(14):1874-1883.

SOUTHERN SCHOLARS SENIOR PROJECT

Name: Elizabeth Van Horn Date: 10-10-99 Major: Biology, B./I

SENIOR PROJECT

A significant scholarly project, involving research, writing, or special performance, appropriate to the major in question, is ordinarily completed the senior year. The project is expected to be of sufficiently high quality to warrant a grade of A and to justify public presentation.

Under the guidance of a faculty advisor, the Senior Project should be an original work, should use primary sources when applicable, should have a table of contents and works cited page, should give convincing evidence to support a strong thesis, and should use the methods and writing style appropriate to the discipline.

The completed project, to be turned in in duplicate, must be approved by the Honors Committee in consultation with the student's supervising professor three weeks prior to graduation. Please include the advisor's name on the title page. The 2-3 hours of credit for this project is done as directed study or in a research class.

Keeping in mind the above senior project description, please describe in as much detail as you can the project you will undertake. You may attach a separate sheet if you wish:

Signature of faculty advisor Jinda Ann Foster Expected date of completion April, 2000

Approval to be signed by faculty advisor when completed:

This project has been completed as planned: yes of

This in an "A" project: yes "A" g'rat.

This project is worth 2-3 hours of credit: yes - of course

Advisor's Final Signature Jinda Ann Foster

Chair, Honors Committee \_\_\_\_\_ Date Approved: \_\_\_\_\_

Dear Advisor, please write your final evaluation on the project on the reverse side of this page. Comment on the characteristics that make this "A" quality work.

## **A NEW TECHNIQUE USED FOR ANTERIOR MULTI-LEVEL CERVICAL FUSIONS -- "THE CHATTANOOGA PROCEDURE"**

Scott D. Hodges, DO; S. Craig Humphreys, MD; Laurie A. Covington, BS; Elizabeth R. Van Horn; Joseph E.D. Peterson; Chattanooga, TN

**INTRODUCTION:** Anterior multi-level cervical fusion surgeries have various instrumentation options available including: Sofamor Danek-Orion plate, Synthes AO locking plate, DePuy-Acromed DOC system, and interbody fusion cages. The purpose of this study is to report a new surgical technique called "The Chattanooga Procedure" for anterior multi-level cervical fusions. "The Chattanooga Procedure" utilizes the DePuy-Acromed DOC anterior cervical system in combination with the Harms cage. Advantages and disadvantages will be assessed and reported.

**METHODS:** A retrospective review of 35 patients who underwent "The Chattanooga Procedure" between 7/24/98 and 4/8/99 was conducted. There were 18 males (51.4%) and 17 females (48.6%). The average age was 51.6 years (range of 35-73 years). All patients had anterior discectomies and corpectomies, placement of Harms cage packed with corpectomy bone, and application of DePuy-Acromed DOC. The average number of levels fused was 2.29 (range of 2-4), the most common being C5-C7 (range of C3-T1). Fusion was defined by trabecular bone bridging across Harms cage. CT scans were performed on twelve randomly chosen patients to verify fusion rates. All patients were followed up clinically and radiographically. No external bracing was used except soft collar as needed.

**RESULTS:** Of the 35 "Chattanooga Procedure" patients, there was no pseudoarthrosis noted. No major neurological, vascular, or wound complications were reported. There was one case of unresolved dysphasia at eight months post-op. The average operative time was comparable to standard instrumented multi-level anterior cervical fusion surgeries. The average estimated blood loss was 117 cc's (range of 25-750 cc's).

**DISCUSSION:** Advantages in "The Chattanooga Procedure", using the DOC system with the Harms cage include immediate stability and support, elimination of donor site pain to iliac crest bone autograft, and a decrease in pseudoarthrosis by dividing the fusion surfaces by half. Concerns regarding "The Chattanooga Procedure" include an increased risk for dysphasia due to the DOC's high profile. Pseudoarthrosis or instrumentation migration could also become problematic since the removal of the Harms cage could be difficult if necessary.

**CONCLUSION:** "The Chattanooga Procedure" is a surgical technique with advantages to consider for multi-level cervical fusions such as an increase in fusion rate and a decrease in graft site morbidity.