

Yale University
EliScholar – A Digital Platform for Scholarly Publishing at Yale

Yale Medicine Thesis Digital Library

School of Medicine

January 2012

Role Of Active Surveillance And Volume Monitoring In Patients With Small Renal Masses

Kiavash Nikkhou

Follow this and additional works at: <http://elischolar.library.yale.edu/ymtdl>

Recommended Citation

Nikkhou, Kiavash, "Role Of Active Surveillance And Volume Monitoring In Patients With Small Renal Masses" (2012). *Yale Medicine Thesis Digital Library*. 1747.

<http://elischolar.library.yale.edu/ymtdl/1747>

This Open Access Thesis is brought to you for free and open access by the School of Medicine at EliScholar – A Digital Platform for Scholarly Publishing at Yale. It has been accepted for inclusion in Yale Medicine Thesis Digital Library by an authorized administrator of EliScholar – A Digital Platform for Scholarly Publishing at Yale. For more information, please contact elischolar@yale.edu.

**Role of Active Surveillance and Volume Monitoring in Patients
with Small Renal Masses**

A Thesis Submitted to the
Yale University School of Medicine
in Partial Fulfillment of the Requirements for the
Degree of Doctor of Medicine

by
Kiavash Nikkhou
2012

ABSTRACT

Introduction: Current standard treatment of small renal masses (SRM) is surgical resection, but it is not plausible in all patients. Since the behaviors of SRM are not completely understood, the management of such lesions remains controversial. We evaluated the rates of linear and volumetric growth and metastasis of solid SRM in patients followed by active surveillance (AS).

Materials and Methods: We performed a retrospective medical records review of 38 patients followed by AS for solid SRM. We reviewed radiographic imaging and hospital records. Extracted variables included size of lesions at diagnosis and surveillance, duration of surveillance, available pathology and progression to metastasis.

Results: Of the original 44 lesions, 36 lesions in 32 patients were included. Mean lesion size at initial presentation was 1.73cm. Mean duration of surveillance was 34.3 months. Benign and malignant lesions demonstrated mean linear growth rates of 0.19cm/yr vs. 0.31cm/yr and volumetric growth rates of 0.95cm³/yr vs. 2.91cm³/yr, respectively. Seven patients crossed over to surgery due to patient preference or significant interval lesion growth. Pathology was obtained in 25% of lesions, of which 44% proved to be malignant renal tumors known as renal cell carcinoma (RCC). There was no correlation between initial lesion size and growth rate. Progression to metastasis was not seen in any of the subjects. Neither of two deaths during surveillance was due to renal cancer.

Conclusions: Most enhancing SRM grow slowly, making active surveillance a safe alternative to surgery in nonsurgical candidates. Changes in lesion volume may be a better predictor of cancer cell growth than linear growth.

Acknowledgements

I would like to acknowledge:

My thesis advisor and mentor, Dr. Dinesh Singh, for all of his support and guidance throughout the last few years. Dr. Singh has been involved from the beginning of this project to the end of this thesis and has provided me with all the necessary support to complete this thesis. I am also grateful for all of his support and mentorship in my pursuit of a career in Urology.

Yale Department of Surgery and Section of Urology for providing research funds for expert statistical analysis; the urology administrative staff for providing me various spaces to work in and your help with collection of medical records.

Dr. Maria Ciarleglio, Associate Research Scientist and Statistician for performing an in-depth statistical analysis.

Yale School of Medicine, Office of Student Research for all the support and encouragement of student research as well as providing me with research stipends to complete this study; Mae Geter for your hard work in coordinating the documents for student research, as well as the warm conversations.

My family and friends for their support and warm wishes, especially throughout medical school, as I pursue this long journey in medicine; my mother, Jahanara Nouri for instilling in me the sense of enthusiasm and dedication; my father, Soleyman Nikkhou for all the encouraging words; My brother Siavash Nikkhou for always keeping me on my toes and not letting me take things too seriously; and my girlfriend, Carolina Benavides for being so supportive, for being the rock that I needed to lean on, and for having all the right words when I needed them the most.

Table of Contents

Abstract	2
Acknowledgments	3
INTRODUCTION.....	5
Types of Kidney Tumors	6
<i>Renal Cysts</i>	6
<i>Benign Solid Tumors</i>	9
<i>Malignant Tumors</i>	10
Epidemiology and Risk Factors for RCC	11
Clinical Findings and Evaluation	12
Biopsy of Renal Masses	13
Tumor Stage and Grade	15
Treatment Options	16
<i>Radical and Partial Nephrectomy</i>	
<i>Ablative Therapy</i>	
<i>Active Surveillance</i>	
<i>Treatment Algorithm</i>	
STATEMENT OF PURPOSE & HYPOTHESIS	20
CLINICAL SIGNIFICANCE	21
METHODS	21
Data Collection	22
Statistical Analysis	23
RESULTS	24
Linear and Volumetric Growth	26
Comorbidity Effect	29
Mortality	29
DISCUSSION	30
CONCLUSION	36
ABBREVIATIONS	37
WORKS CITED	38

Introduction

The incidental detection of small solid renal tumors (4cm or smaller) has gradually increased in frequency in the last two decades as a result of the widespread use of body imaging during work up for unrelated medical issues. Schlomer et al. (1) reported that up to 74% of the newly diagnosed cases of renal tumors are discovered incidentally. In contrast, earlier detection of these renal masses has led to a decrease in tumor size at presentation (2), putting practicing urologists and their patients in a difficult position to make clinical decisions about the management of low stage disease.

Renal tumors are generally heterogeneous with an 80% potential for malignancy and 20-25% exhibiting aggressive behavior at time of diagnosis (3). Lesions with solid components on ultrasound or those with enhancement on CT or MRI are considered malignant until proven otherwise. The most common malignant renal tumor accounting for 80% of all kidney tumors is renal cell carcinoma (RCC), a yellow-to-orange tumor that originates in the lining of the proximal convoluted tubules. Although the current gold standard for the treatment of enhancing solid small renal masses is surgical resection by nephron-sparing surgery (4), the appropriate management of small renal masses, especially in patients with significant surgical risk, remains controversial. Over the last several years, there has been significant debate on the role of active surveillance (AS) in management of small renal masses. Under the current general practice of active surveillance, patients undergo routine abdominal and pelvic imaging with CT or MRI with linear size monitoring of their renal tumors over time.

While there are studies that have reported on outcomes of active surveillance of localized small renal masses (5,6,7,8,9,10,11,12), these studies remain few in number, contain small cohorts of patients, and only investigate the linear growth of such lesions. To our knowledge, this is the first study to evaluate the role of volumetric change, in addition to change in linear size, in small renal lesions under long-term active surveillance.

Types of Kidney Tumors

Renal Cysts

The widespread use of radiographic imaging has resulted in an increase in detection of benign kidney tumors. The most common benign kidney lesion is a benign simple cyst, accounting for over 70% of all asymptomatic renal masses. Renal cysts are found in more than 50% of patients over 50 years old (13), and are generally clinically insignificant. Cystic lesions are best characterized by ultrasound or CT scan imaging to assess for lesion shape, wall thickness, internal echoes and signal transmission. Renal cysts that meet the following criteria are characterized as benign simple cysts: 1) round or ovoid in shape, 2) smooth and thin cyst wall, 3) sharply demarcated, and 4) homogenous with no calcifications, septations, or internal echoes. Simple cysts do not enhance with intravenous contrast. Complex cysts, on the other hand, have an irregular shape or contour with evidence of calcification, internal septation, and contrast enhancement with contrasted CT imaging (figure 1).

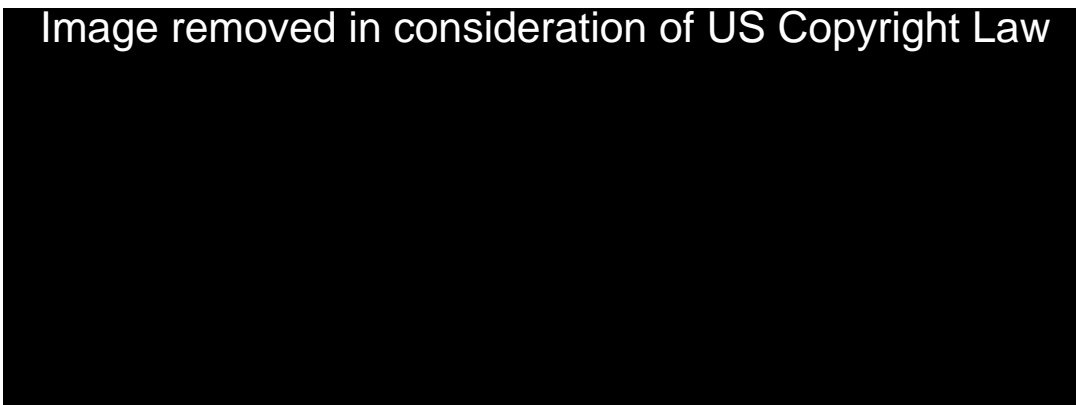


Figure 1. Ultrasonography of renal cysts. *Left:* Simple renal cyst (Cy) with sharp interfaces with renal parenchyma, no internal echoes, and increased through signal transmission. *Right:* Complex renal cyst (arrow) with lobulated margins and thick wall. [From Smith's general urology, 2008 (16)].

The Bosniak classification (16) of renal cysts can be used to differentiate the spectrum of simple to complex cysts, and to determine the potential risk for malignancy based on ultrasound imaging (figure 2):

- Bosniak type I renal cysts, also known as benign simple cysts are homogenous, smooth, thin-walled lesions with distinct cyst wall-renal parenchymal interface, no internal echoes or signs of calcification, septation, or contrast enhancement.
- Bosniak type II renal cysts are benign lesions ≤ 3 cm in diameter. They are characterized as having minimal central septations (≤ 1 mm thick), or a thin peripheral calcification without contrast enhancement.
- Bosniak IIF renal cysts contain multiple thin central septations, thickened peripheral calcifications, and can be hyperdense and minimally enhancing lesions. These lesions are minimally complex and require follow up to monitor changes in lesion characteristics, and carry a 20% risk for malignancy (37).
- Bosniak III renal cysts are complex lesions with irregular borders, extensive calcifications and septations, and a thicker contrast enhancing cyst walls (≥ 1 mm). These lesions have a high potential for malignancy ($> 33\%$), and therefore, surgical resection is recommended.

- Bosniak type IV renal cysts are complex lesions with thick septations and cyst walls, and often contain significant calcifications. These lesions often demonstrate large enhancing nodules or solid components within the cystic lesion. They are considered malignant (> 92.5%) and should undergo surgical resection.

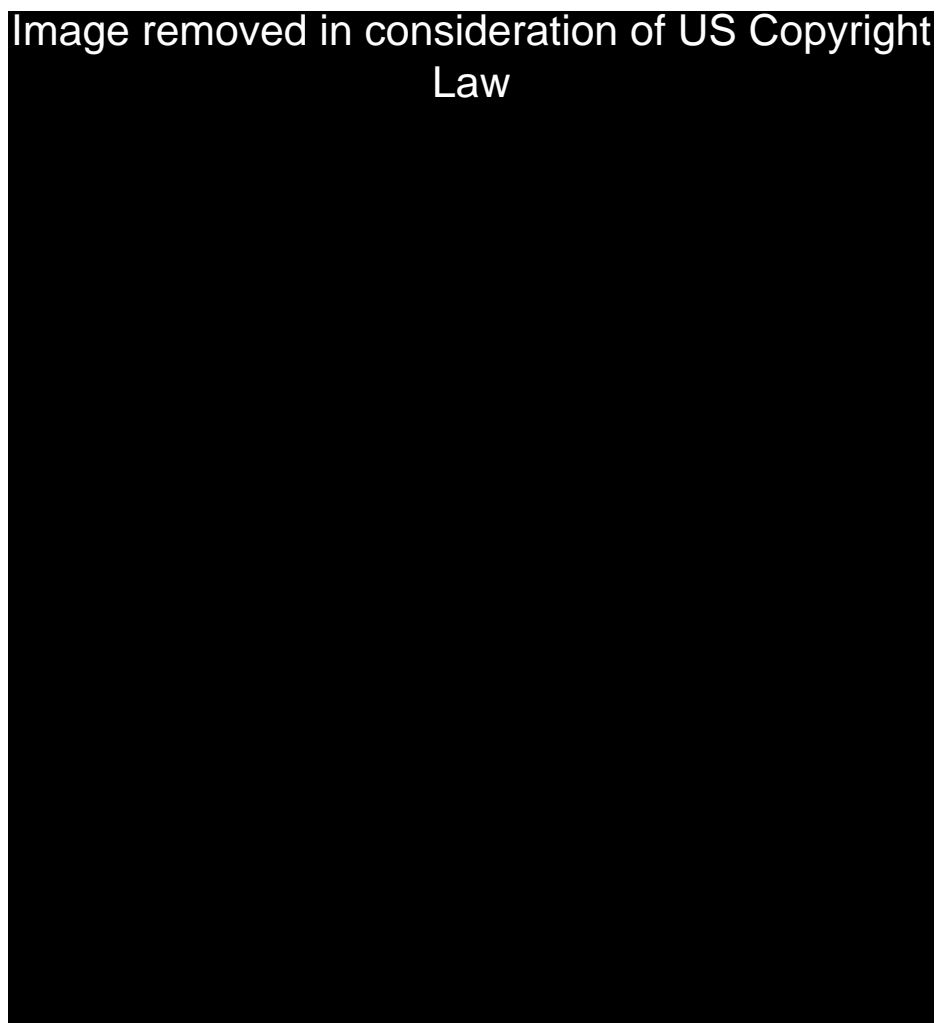


Figure 2. Contrast-enhanced CT scan of renal cysts at various Bosniak stages. *Top left:* Bosniak II cyst with minimally thickened but smooth linear calcification (arrow) within a septum without concomitant tissue enhancement. *Top right:* 2-cm Bosniak IIF renal mass (straight arrows) with thick mural calcification (curved arrows), but no enhancing soft-tissue components. A Bosniak I simple cyst (C) is also present posteriorly. *Bottom Left:* Bosniak III, complex cystic lesion with thick mural calcification (straight arrows) and a thick, enhancing wall (curved arrow). *Bottom right:* Bosniak IV, complex cystic mass with mural calcification (long arrow), wall enhancement, and obvious enhancing soft-tissue components (short arrow) adjacent to the wall. [From Israel et al. Classification in cystic renal masses (56)].

Benign Solid Tumors

The most common benign solid renal tumor is a renal adenoma, a small (<5mm), highly differentiated glandular tumor arising from the proximal tubule of the renal cortex. Although the radiological incidence of renal adenoma is less than 1%, these lesions have an incidence of 7-23% in autopsy series (14). Papillary adenomas are microscopically and macroscopically similar to low grade papillary RCC (defined below), however, they are considered benign due to the low frequency and metastatic rates of adenomas less than 5mm in diameter.

Renal oncocytoma is another type of benign renal tumor seen in 3-7% of all solid renal tumors (15). Grossly, oncocytomas are light brown or tan lesions surrounded by a fibrous capsule and contain a central scar without necrosis. These lesions, however, cannot be clearly differentiated from RCC based on clinical, radiological imaging or biopsy; therefore they are treated as RCC until proven otherwise.

Angiomyolipoma (AML) is a benign nonencapsulated, yellow-to-gray, typically round-to-oval lesion containing various amounts of fat, smooth muscle and blood vessels. AML may be seen alone or in 40-80% of patients with tuberous sclerosis, an autosomal-dominant inherited disorder characterized by adenoma sebaceum skin lesions, mental retardation, epilepsy and multi-organ AML (16). Presence of fat within the lesion signifies AML, since RCC does not contain fat. The appropriate management of AML is based on lesion size and patient symptoms. AML lesions greater than 4cm are more likely to grow and be symptomatic (pain, hematuria, bleeding). For this reason, lesions

that are <4cm are generally managed conservatively while lesions >4cm or those that are symptomatic are treated with nephron-sparing surgery (17).

Other rare benign renal tumors include leiomyomas, renal hemangiomas, lipomas and juxtaglomerular cell tumors. These lesions are usually clinically insignificant with the exception of juxtaglomerular cell tumors, which can cause significant hypertension secondary to renin secretion by the tumor. Leiomyomas are seen in the renal capsule and pelvis which contain smooth muscle. Renal hemangiomas are vascular lesions that are usually solitary and rarely bilateral.

Malignant Tumors

Renal cell carcinoma (figure 3) is a characteristically yellow-to-orange tumor that originates in the renal cortex and can extend into the perinephric tissue. Histologically RCCs are mixed adenocarcinomas that involve two or more tumor subtypes including clear cell, papillary, chromophobe, and collecting duct. Seen in 70-80% of RCC, clear cell subtype is the most common type of RCC and is characterized by a low nuclear-to-cytoplasmic ratio and clear cytoplasm. Papillary (chromophil) tumor is seen in 10-15% of RCC and arises from the proximal tubule. Two subtypes of papillary RCC exist: low-grade type I with a basophilic cytoplasm, and high-grade type II with an eosinophilic cytoplasm, which carries a worse prognosis (18). Chromophobe tumors account for less than 1% of RCC cases and have distinct cell borders and abundant cytoplasm that stains with Hale's colloidal iron (19). Collecting duct carcinoma is a rare (<1%) but highly malignant tumor usually located in the renal medulla or papilla. Patients with collecting

duct tumors rarely survive beyond five years, and an estimated 40% of these tumors present with metastasis. With the exception of collecting duct carcinoma, tumor type is not an independent predictor of prognosis among RCC subtypes with similar stage and grade. However, without regard to stage or grade, chromophobe tumors have a better prognosis because they are usually low stage and low grade (20).

Epidemiology and Risk Factors for RCC

Accounting for 2% of all adult malignancies, RCC is the 10th most common malignancy among males and the 14th most common malignancy among females. RCC is also the 3rd most common urologic tumor after prostate and bladder cancer (21). The incidence of renal cell carcinoma has been increasing steadily in the last three decades, with average annual percentage increase of 2-3% (22). The National Cancer Institute has estimated that in 2012, over 64,770 new cases of kidney cancer will be diagnosed, and over 13,570

Image removed in consideration of US Copyright Law

Figure 3. Renal Cell Carcinoma. (A) CT scan showing a 6-cm solid heterogeneous lesion of the right kidney at the inferior pole (thin arrow) with osteoblastic vertebral lesion (thick arrow) suggestive of metastatic disease. (B) Gross surgical specimen showing a well-circumscribed tumor, located at the inferior pole, with a heterogeneous aspect with white and yellow areas. [From Bressenot et al, 2010 (57)].

people will die from kidney cancer (23). The peak incidence of kidney cancer is among the 55-64 year old population, while the greatest number of deaths from kidney cancer has been reported among the 75-84 year old group (22).

Many preventable and non-preventable factors have been associated with a higher risk for development of RCC, including tobacco smoking, obesity, hypertension, acquired cystic kidney disease and chronic renal failure, as well as genetic factors such as a von Hippel Lindau disease, Tuberous sclerosis, Birt-Hogg-Dube, adult polycystic kidney disease, and a family history of renal cancer. Of these risk factors, tobacco smoking has shown to be the most important in development of renal cancer and is seen in 20% of RCC cases (24,25). Tobacco smokers have an estimated 2.3 fold greater risk for RCC than nonsmokers, with a dose-response pattern with respect to the number of cigarettes (26). Smoking cessation decreases the risk for RCC, but their risk is not equivalent to nonsmokers' risk until more than ten years after quitting tobacco (27). Chronic tissue hypoxia with carbon monoxide exposure and smoking related respiratory conditions such as chronic obstructive pulmonary disease are two mechanisms by which tobacco smoking increases the risk of RCC (28). Consumptions of moderate alcohol, fruits and vegetables, and fatty fish have been reported to reduce the risk of RCC development (29).

Clinical Findings and Evaluation

Renal tumors are often asymptomatic which explains the high rate of incidental detection of these tumors during abdominal imaging. The classic triad of flank pain, gross hematuria, and palpable flank mass is only observed in 7-10% of cases, and often

signifies advanced disease (16). Other presenting signs or symptoms may include weight loss, fever, anemia, dyspnea, cough and bone pain secondary to distant metastasis. RCC is also associated with a variety of paraneoplastic syndromes including paraneoplastic erythrocytosis in 3-10% (30), hypercalcemia in 20% (31), hypertension (up to 40%), and Stauffer syndrome of hepatic dysfunction in 3-20% of patients (32).

Patients suspected of having a renal tumor undergo radiographic imaging with renal ultrasound, CT or MRI to better characterize the lesion. Renal ultrasound is a noninvasive and inexpensive technique to distinguish simple cysts from solid tumors. CT scan is the primary imaging modality at this time because of its high sensitivity in detection of renal masses. MRI, although more expensive, is equivalent to CT scan for RCC staging and does not require contrast material or expose patients to ionizing radiation. CT imaging of RCC typically demonstrates a solid tumor with decreased Hounsfield units at baseline compared to normal renal parenchyma, which enhances with administration of intravenous contrast (figure 3A). In addition, patients with a suspected renal tumor should also receive a chest x-ray to evaluate for metastatic disease. A routine bone scan is not indicated in patients without bone pain since the incidence of bony metastasis in such patients with normal alkaline phosphatase levels is very low (33).

Biopsy of Renal Masses

The role of biopsy in management of renal masses has been limited in the past due to the high sensitivity of diagnostic imaging as well as the risks and complications of needle biopsy. Some studies also suggested that percutaneous biopsy was nondiagnostic in 10-

15% of cases, with false negative rates of 1-2% when adequate tissues were obtained. Furthermore, there are rare reports of tumor seeding along the needle tract as well as tumor spillage in cystic lesions. Other complications of needle biopsy include hematoma, infection and hemorrhage, with serious side effects in < 2% of patients. For these reasons, percutaneous biopsy was primarily performed in patients with suspected of having metastatic disease, lymphoma or a renal abscess (34,35).

In the last few years, however, percutaneous biopsy of renal masses has gained support in in follow-up surveillance and in ablative therapy. There has also been a shift in general recommendations as the 2012 National Comprehensive Cancer Network (NCCN) and 2010 European Association of Urology guidelines now state that biopsy “should be considered before ablative and systemic therapy without previous histopathology, and in surveillance strategies” (36,37). The changes in recommendations are driven by the ability to distinguish and conservatively manage biopsy-proven benign disease (20% of all renal tumors) as well as improvements in accuracy and safety of renal mass biopsy. Although general recommendations now support percutaneous needle biopsy of renal masses, the decision to perform a biopsy should be made on a patient specific basis. The American Urology Association guidelines (2009) state that biopsy should not be considered in “healthy patients unwilling to accept the uncertainty associated with this procedure or for older patients who will only consider conservative management options regardless of biopsy results” (38).

Tumor Stage and Grade

Staging

Tumor stage is the most important factor in predicting prognosis of RCC and reflects the tumor size and extension beyond the kidney. The Tumor-Node-Metastasis (TNM) system describes the tumor size and direct extension (T), number of regional lymph nodes involved (N), and extent of distant metastasis (M). The most recent (2010) version of the TNM system by the American Joint Committee on Cancer (AJCC) is described in table 1 (39).

Grading

Fuhrman nuclear grading can also be used to evaluate clear cell and papillary RCC, and is most effective in predicting metastasis. It is based on the tumor's nuclear characteristics including size, contour and nucleoli appearance. Tumors are given a grade of 1 through 4, with higher grades suggesting a worse prognosis. A Fuhrman grade I tumor is characterized by a small nucleus, with a round, smooth and uniform contour and non-prominent nucleoli. A grade II lesion has a medium-sized nucleus with minor contour irregularities and non-prominent nucleoli. Fuhrman grade III lesions have large nuclei with major contour irregularities and prominent nucleoli. Fuhrman grade IV lesions have even larger nuclei with greater contour irregularities (mutilobulated, pleomorphic) and prominent nucleoli.

Image removed in consideration of US Copyright Law

Table 1. TNM classification for staging of renal cell carcinoma. [From AJCC Cancer Staging Manual, 2010 (39)].

Treatment Options

Several options exist for the treatment of renal cell carcinoma and the appropriate therapy depends on the tumor location and stage. However, the only truly curative therapy with known long-term follow up is surgical excision. Therefore, surgical excision of tumor by nephron-sparing surgery or radical nephrectomy has become the primary treatment for

localized RCC. Surgical excision can be performed by an open approach, classic laparoscopic technique, or robotic-assisted laparoscopic surgery.

Radical and Partial Nephrectomy

In the past, radical nephrectomy (RN) has been the principal treatment for localized RCC. RN involves the removal of the entire kidney, Gerota's fascia, perirenal fat, regional lymph nodes, proximal ureter, and ipsilateral adrenal gland, and has demonstrated excellent tumor control and disease-free survival rates (40). The significant negative impact of RN on renal function and its association with chronic kidney disease (41), however, is the main concern with this therapy and indicates the need for alternative treatment options.

The goal of partial nephrectomy (PN) is to remove the tumor with a margin of normal tissue while preserving as much renal function as possible. The appropriate size of negative margins is controversial and has not shown to impact prognosis (42). Complications of PN include positive surgical margins, hemorrhage, warm ischemia and urine leak. However, techniques to avoid such complications can be taken including frozen section sampling of tumor base, hilar vessel clamping, use of mannitol and diuretics, cold ischemia, and careful closure of the collecting system. Although the absolute indications for PN include treatment of patients with poor baseline renal function, solitary kidney, bilateral renal tumors, or hereditary renal cancer, PN is now used as the primary surgical therapy for most peripherally located, clinical stage T1 renal tumors (tumor \leq 7cm) (20). Studies comparing partial vs. radical nephrectomy have

demonstrated equivalent disease-free survival rates. Local tumor recurrence, however, is higher in PN (5% vs. 1%) (43), while long-term overall survival in T1 stage tumors is greater with PN, secondary to decreased cardiovascular morbidity and preserved renal function (44,45).

Ablative Therapy

Energy-based ablative therapies such as cryoablation and radiofrequency ablation (RFA) exist with the goal of tumor destruction without excision. Tumor ablation can be performed by an open, laparoscopic, or percutaneous approach. Although some studies have demonstrated some short-term success with ablative therapy (46), others have shown greater local recurrence rates compared with partial nephrectomy, and difficulties with salvage tumor excision following ablative therapy (47). Moreover, long-term data about the efficacy of ablation therapy is still lacking. Given the greater risk of recurrence, ablative therapy is generally reserved for patients with small peripheral tumors or those who cannot tolerate surgical excision. As mentioned previously, tumor biopsy is recommended prior to ablative therapy.

Active Surveillance

Active surveillance (AS) with delayed or no treatment has become a viable alternative for treatment of clinical stage T1a renal cell carcinoma in the last several years. Indications for AS include elderly patients, those who do not desire intervention, those with limited life expectancy, and patients with significant comorbidity with surgical risk greater than risk of death from renal cancer (38). A short period of active surveillance with delayed

intervention can also be used to observe the growth rate of patients' renal tumor with minimal risk of disease progression or metastasis (48). Few studies have reported on the growth rate of small renal masses $\leq 4\text{cm}$ under long-term active surveillance. A meta-analysis by Chawla et al. reported an average growth rate of 0.28cm per year in lesions with a mean follow up of 34 months. They also reported progression to metastasis in 1% of lesions (5). In contrast, a retrospective study by Zini et al. demonstrated a 9.4% greater five-year cancer-specific survival in patients who underwent surgical excision compared to those under AS (49). Further long-term studies of small renal masses under active surveillance are necessary to better understand the behavior of small renal masses and better define the role of AS in management of these lesions.

Treatment Algorithm

Although the current gold standard for the treatment of renal tumors is surgical resection by radical or partial nephrectomy, there is no clear standard of care regarding the appropriate management of small renal tumors (clinical stage T1a). Based on the literature available on the behavior of clinical stage T1 tumors, expert opinions and panel consensus, the AUA developed an algorithm incorporating standards, recommendations and options for the management of small renal tumors (figure 4) (38). Urologists can utilize this algorithm to reach an individualized treatment plan with their patients, taking into consideration each individual's preferences and comorbidities.

Image removed in consideration of US Copyright Law

Figure 4. Treatment algorithm from AUA guidelines for management of patient with clinical T1 renal mass. [From *Guideline for management of the clinical stage 1 renal mass* by American Urological Association, 2009 (38)].

STATEMENT OF PURPOSE & HYPOTHESIS

The primary goal of this study is to determine the rates of linear and volumetric growth in small renal lesions under long-term active surveillance. A secondary goal of this study is to observe the rate of progression to metastasis based on the current practice at our institution of offering active surveillance in patients with significant comorbidities and surgical risk. Therefore, the hypothesis of this study is: If small renal masses (<4cm) demonstrate slow rates of linear and volumetric growths and metastasis, then AS is a reasonable and safe alternative to surgical resection for management of small renal tumors in elderly patients, or those with competing comorbidities or high surgical risk.

CLINICAL SIGNIFICANCE

Currently there are only a few studies reporting on the long-term growth rates of small renal tumors and all involve a small cohort of subjects. Furthermore, there are no studies in the literature that report on the rate of volumetric growth in benign and malignant small renal tumors. Conceptually, monitoring a lesion's change in volume over time is more reflective of the three-dimensional growth of renal tumors and is a more effective tool in surveillance of these tumors than linear growth evaluation. In addition, due to the limited literature available on the behavior on small renal masses, the appropriate management of such lesions is unclear. This study sheds further light on the long-term natural behavior of benign and malignant renal lesions and can be used by urologist to make informative clinical decisions with patients diagnosed with small renal tumors.

METHODS

In this retrospective study, we reviewed the medical records for 38 subjects who underwent outpatient active surveillance of their small solid renal mass at Yale New Haven Hospital between June 2001 and June 2011. The subjects' medical records included all clinical notes, hospital documents, discharge summaries, operative notes, pathology results, and results for all radiographic imaging during the period of active surveillance. Surveillance imaging was scheduled every 6 to 12 months with CT or MRI. Subjects with delayed follow up or imaging were contacted per standard clinical care. No subject received additional imaging or follow up solely for this study.

Data Collection

We created a database of patient information that included the following data:

- Demographics
- Known medical history
- Family history of kidney disease
- Age at initial presentation with renal mass
- Date and results of initial and subsequent radiographic imaging
- Number and size of lesion(s) at each follow up
- Reason for active surveillance
- Date and type of surgical intervention (if any) and findings
- Pathological data (if any)
- Metastasis (if any), and
- Cause of death (if applicable)

We included subjects with small renal masses, characterized by lesion diameter ≤ 5 cm, demonstrating solid components and enhancement on post-contrast CT or MRI imaging. Subjects were screened for our inclusion criteria, which included patient age ≥ 18 years old, initial lesion size ≤ 5 cm, period of active surveillance ≥ 6 months, and radiographic finding of one or more solid enhancing renal lesions. We excluded all subjects with benign cystic diseases, or those with hereditary renal tumor syndromes or metastasis at initial presentation.

Once the database was completed we evaluated the following parameters for our subject population:

- Mean age at diagnosis
- Mean lesion size at presentation
- Average number of subject comorbidity
- Mean period of active surveillance

- Mean linear growth rate per year (cm/yr), and
- Mean volumetric growth rate per year (cm^3/yr), using the formula $(4/3)*\pi r^3$ to estimate the volume for each lesion, with the assumption that most renal lesions are spherical in nature.
 - Of note, the same primary data were used for calculating mean linear growth rate per year and mean volumetric growth rate per year

Kiavash Nikkhou performed all significant components of this research under the supervision of research advisor, Dr. Dinesh Singh. Kiavash Nikkhou submitted the application for review of the study by the Yale Institutional Review Board and Human Investigation Committee, reviewed all the subjects' medical records, created the study's database, performed basic statistical analysis, and wrote the manuscript that was submitted to the highly recognized and peer-reviewed journal "Urology" in January 2012. Kiavash Nikkhou and Dr. Singh met on numerous occasions to discuss the progress of the study and the database, and to review the written abstracts and manuscripts. The Urology administrative staff helped with obtaining medical records, and Dr. Maria Ciarleglio, a statistician for the Department of Surgery performed additional in-depth statistical analysis. The protocol was approved and was given a waiver of informed consent by the Yale Institutional Review Board and Human Investigation Committee.

Statistical Analysis

SAS, version 9.2 was used for all statistical analyses. Data was stratified by initial size, malignancy status, presence or absence of surgical intervention, and number of co-morbidities. ANOVA, T-Test, and Kruskal-Wallis (K-W) non-parametric test were used to evaluate the equality of distributions for these variables due to the non-normal nature

of the data, with significance represented by p -value < 0.05 . A Pearson correlation test was used to evaluate for any correlation among variables. Linear mixed effects models were used to model the repeated measures of lesion size and volume over time based on lesion malignancy. These plots show the model-estimated mean change in linear size and volume from baseline at various time points by lesion malignancy, exploring the significant interactions and adjusting for other variables in the model.

RESULTS

We identified a total of 36 renal lesions in the 32 subjects who met the inclusion criteria mentioned previously. Two subjects had two renal lesions and one subject had three lesions under active surveillance. The mean patient age at initial diagnosis was 70.9 years (median 73, range 47 to 90 years). The cohort consisted of 50% men and 50% women. Subjects were predominantly white (Table 1). The mean lesion size at initial diagnosis was 1.73cm (median 1.5, range 0.3 to 4.6cm). Six of the 36 lesions (17%) were malignant, 7 (19%) were benign, and 23 (64%) remain unknown. Of the 36 lesions, 33 (91.7%) were ≤ 4 cm at initial presentation. The mean period of active surveillance was 34.3 months (median 22, range 6 to 97 months). Reasons for active surveillance included: significant patient comorbidity, patient opposition to undergo surgery, or a combination of both.

Seven patients eventually crossed over to surgical intervention following a period of active surveillance. Of these, five (16%) patients underwent surgical resection and 2 (6%) underwent percutaneous cryoablation. Reasons for crossover to surgical intervention

Table 1. Demographics. Characteristics of the 32 subjects under active surveillance for small renal mass.

Characteristic	N = 32
Age	
Mean – yr	70
<50 – no. (%)	3 (9)
50-65 – no. (%)	9 (28)
66-80 – no. (%)	12 (38)
> 80 – no. (%)	8 (25)
Sex – no. (%)	
Male	16 (50)
Female	16 (50)
Race or ethnicity – no. (%)	
White	26 (81)
Black	4 (13)
Hispanic	2 (6)
Number of Comorbidities	
< 2	14 (44)
2-5	16 (50)
>5	2 (6)
Family history of renal cancer	1 (3)

included patient preference without interval change in lesion size in 2 patients, of whom one underwent surgical resection and the other percutaneous cryoablation. Among the 5 subjects with significant lesion growth as the reason for surgical intervention, 4 underwent surgical resection and 1 underwent percutaneous cryoablation.

Patients who underwent surgical treatment were younger (mean age of 61.4 years, median 57, range 47 to 80 years) compared to nonsurgical patients (mean age of 73.5 years, median 76 years, range 47 to 90 years, $p=0.01$). They also demonstrated a greater mean lesion growth rate of 0.29cm/yr, compared with 0.08cm/yr seen in nonsurgical

patients ($p < 0.05$), confirming our institution's practice of earlier surgical intervention in fast growing lesions.

Pathological data was obtained in 9 (25%) lesions. Surgical resection accounted for 5 and biopsy specimens accounted for the remaining 4 pathological samples [percutaneous biopsy (2), laparoscopic biopsy prior to percutaneous cryoablation (2)]. Of the 9 lesions with pathological confirmation, 4 (44%) proved to be RCC, 3 (33%) oncocytoma, 1 (11%) mucinous cystadenoma, and 1 (11%) metanephric adenoma. Histological analysis of the four RCC lesions showed Papillary RCC in all four lesions. All RCC variants were low grade (Fuhrman 1 to 2). In addition to the four pathology-confirmed RCC lesions, two other malignant lesions were observed by radiographic imaging, of which one was a Bosniak III renal cyst and the other a Bosniak IV renal cyst.

Linear and Volumetric Growth

The mean linear growth rate of lesions was 0.12cm/yr (median 0.08, range -0.29 to 1.03cm). Malignant lesions demonstrated a significantly higher mean growth rate of 0.31cm/yr compared to benign and unknown lesions, which showed growth rates of 0.19cm/yr and 0.05cm/yr, respectively ($p = 0.02$). A linear mixed effects model of change in linear growth over time comparing benign, malignant, and unknown lesions and adjusting for other variables is shown in figure 5, demonstrating a greater mean growth rate in malignant tumors than benign tumors. There was no correlation between initial tumor size and growth rate in all tumors (Pearson correlation coefficient 0.01, $p = 0.9$).

We also evaluated the change in tumor burden as reflected by the change in tumor volume per year, with the assumption that most small renal masses are spherical in nature. The mean increase in tumor volume per year among all lesions was $1.07\text{m}^3/\text{yr}$ (median 0.22 , range -7.47 to $15.29\text{m}^3/\text{yr}$). Malignant lesions demonstrated a more than three-fold greater growth in volume per year as compared with benign and unknown lesions ($2.91\text{cm}^3/\text{yr}$ vs. $0.95\text{cm}^3/\text{yr}$ and $0.62\text{cm}^3/\text{yr}$, respectively). A linear mixed effects model of change in lesion volume over time comparing benign, malignant, and unknown lesions and adjusting for other variables is shown in figure 6, demonstrating a greater mean volumetric growth rate in malignant tumors than benign tumors.

The three lesions that were $>4\text{cm}$ on initial presentation had a mean growth rate of $0.41\text{cm}/\text{yr}$ (median 0.45 , range 0.32 to 0.45cm) as compared with $0.11\text{cm}/\text{yr}$ (median 0.08 , range -0.29 to 1.03cm) in lesions that were $\leq 4\text{cm}$. The larger than 4cm lesions also demonstrated a greater mean change in volume per year of $5.89\text{cm}^3/\text{yr}$ compared with $0.63\text{cm}^3/\text{yr}$ in lesions $\leq 4\text{cm}$ ($P<0.009$). These lesions were also treated more aggressively as demonstrated by the lower period of AS of 11.7 months vs. 36.1 months in lesions $\leq 4\text{cm}$. Of these three lesions, one was radiologically determined as Bosniak IV cystic RCC, and 2 remain unknown and are continuing with AS.

Figure 5. Model estimated mean change in lesion size from baseline over time by lesion malignancy status

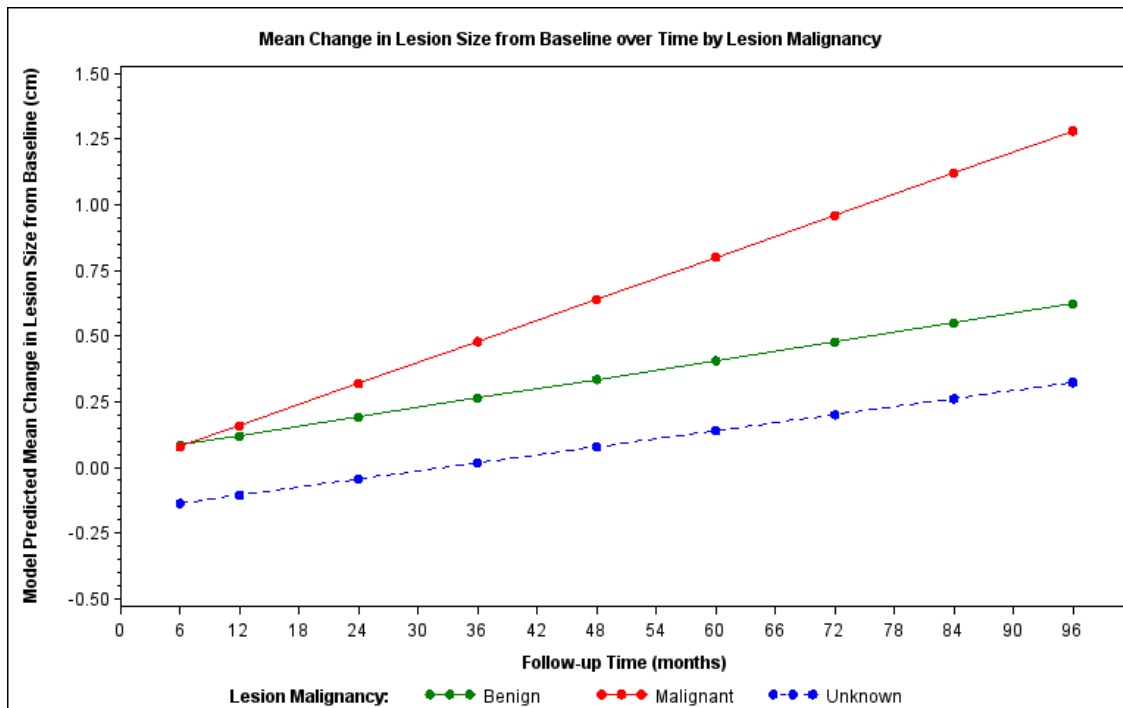
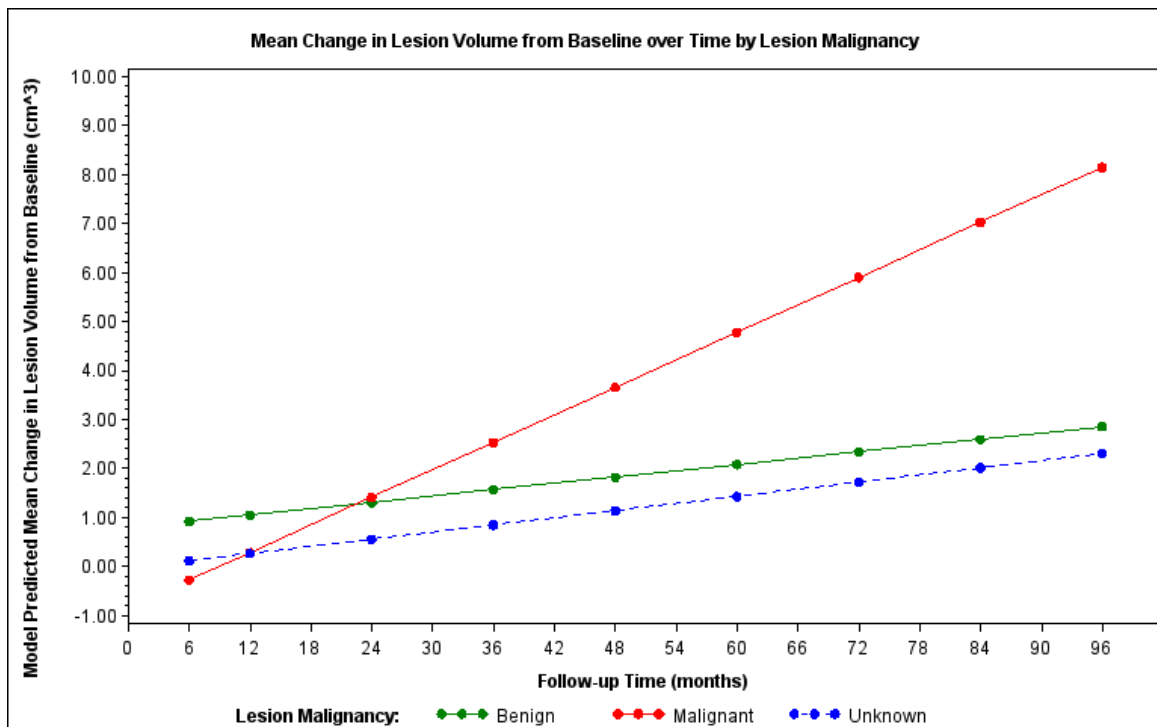


Figure 6. Model-estimated mean change in lesion volume from baseline over time by lesion malignancy status



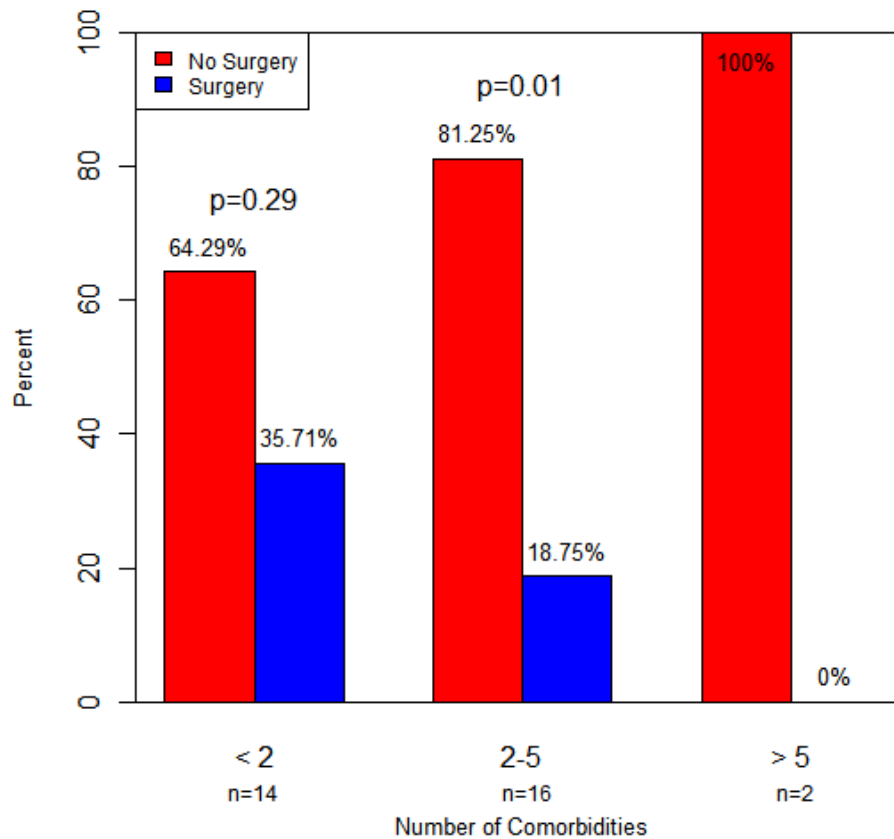
Comorbidity Effect

The mean number of comorbidities was 2.16 (median 2, range 0 to 7). Fourteen of 32 (44%) subjects had less than two comorbidities, 16 (50%) had 2-5 comorbidities and 2 subjects (6%) had more than 5 comorbidities (Table 1). The most prevalent comorbidities among the cohort were hypertension, diabetes and cardiovascular disease. Other comorbidities included peripheral vascular disease, COPD, renal failure, and history of myocardial infarction or stroke. The effect of patient comorbidity in the decision to undergo surgical intervention is reflected in the percentage of subjects who underwent surgery in each comorbidity category. There was no significant difference among patients with fewer than two comorbidities, of whom 35.7% underwent surgery while 64.3% did not ($p=0.29$). Among patients with 2-5 comorbidities, 18.75% underwent surgery while 81.25% did not ($p=0.01$), and neither of the two subjects with >5 comorbidities underwent surgery (Figure 7).

Mortality

No subject in our study had metastatic disease at initial presentation, and none demonstrated progression to metastatic disease during their period of active surveillance. Two patients (6.3%) died while on active surveillance of their small renal mass, with none having renal cancer as the cause of death. The causes of death for these two subjects were reported as heart disease, and organ failure secondary to sepsis.

Figure 7. Bar plot comparing percentage of subjects undergoing surgical intervention in each comorbidity count category.



DISCUSSION

The widespread use of radiographic imaging for medical diagnosis has led to a significant increase in the detection of renal masses, in particular small tumors in the early stages. As the long-term behavior of small enhancing renal masses continues to remain unclear, practicing urologists and patients with such tumors continue to struggle with the most appropriate management of such lesions. Currently, surgical excision of renal tumors is the only curable treatment option available. However, many patients diagnosed with small enhancing tumors are elderly and have significant comorbidities with significant surgical risk.

Several small, published studies have reported on their experiences with small renal masses. Studies supporting the role of AS argue that most SRM grow slowly and demonstrate that 85% of lesions less than 4cm are low grade (50). A large meta-analysis that included 225 lesions less than 4cm showed a mean growth rate of 0.28cm/yr and 1% progression to metastasis (5). Another report showed no significant difference in the long-term risk of progression to metastasis in patients under AS compared with those treated with surgical excision, cryoablation, or radiofrequency ablation (51). In contrast, higher metastasis rates were reported by two studies. Using the Surveillance, Epidemiology and End Results (SEER) data, one study demonstrated greater prevalence of metastasis and mortality with increasing tumor size (52). This study however, reported the prevalence of metastasis at presentation rather than progression to metastasis, and the greatest mortality and prevalence of metastasis was noted in lesions greater than 4cm. In another study, distal metastasis was reported in 8.2% of symptomatic RCC. This study, however, classifies lesions based on TNM staging rather than size, with 23% of symptomatic RCC having stage I, 23% stage II or III, and 54% having stage IV disease, and a mean tumor size of 7.3 cm (53).

With the current data on active surveillance, many urologists are hesitant to incorporate active surveillance into their practice not only due to the fear of harming patients, but also because of medical-legal concerns. This study adds to the previously published data validating the safety of active surveillance by confirming the slow growth rate and low rates of progression to metastasis in small renal lesions with appropriate follow up.

Radiographic monitoring of small renal tumors at scheduled intervals can safely be used to monitor and guide the management of these lesions.

The 36 lesions included in our cohort had a linear growth rate of 0.12cm/yr with a mean AS period of 34.3 months. Confirmed RCC lesions had a significantly greater mean linear growth rate compared to benign lesions (0.31 vs. 0.19 cm/yr). The 23 unknown lesions had a linear growth rate of 0.05cm/yr, which may suggest a benign nature of such tumors. Without pathological data, however, we cannot confirm such assumption, as small lesions with minimal growth can still be malignant. The mean growth rate of small renal masses among our patient population is consistent with the currently published data in the literature. Volpe et al. (54) reported an average of 0.1cm/yr growth in 32 lesions measuring < 4cm with a mean surveillance of 35 months. Wehle et al. (9) reported a mean growth rate of 0.12cm/yr in 29 lesions < 3.5 cm under a mean surveillance period of 32 months. Bosniak et al. (7) investigated the behavior of incidentally detected renal masses \leq 3.5cm in 40 lesions and reported a growth rate of 0.36cm/yr with a mean surveillance of 39 months. These studies reported no progression to metastatic disease among their subject population. Our results support these studies and confirm the current recommendations that active surveillance may be safely practiced in patients with significant comorbidities or those who are poor surgical candidates where the risks of surgery outweigh the risks of mortality from renal cancer.

This study is also the first known study to investigate changes in tumor volume over time and demonstrate its importance as a marker of disease progression and prognosis.

Although the rate of volumetric growth was obtained from the linear size measurements and converted using the volume formula for spheres $[(4/3)\pi r^3]$, it best estimates the three-dimensional change that occurs in renal lesions that simple linear measurements does not. Using volume derivations improves clinical predictive value of renal tumors by providing the urologist with a more accurate reflection of increase in tumor burden over time, and can lead to better assessment of small growing malignant tumors.

By evaluating the change in volume per year we can demonstrate the exponentially greater change in the number of cells than seen in linear measurements. For example, as a 1-cm renal mass grows to 1.5cm in 1 year, it undergoes a 0.5cm/yr (50%) increase in linear size but a 1.24cm³/yr (238%) increase in volume. Although the precise number of renal cancer cells per cubic centimeter is unknown, one can appreciate how a relatively small change in the radius, when cubed to reflect the three-dimensional growth, reflects the exponentially greater number of cancerous cells present. With only a 50% increase in linear size in a year, the lesion in this example may continue to be watched with active surveillance, while a 238% increase in volume in that year demands a closer attention and may result in earlier intervention of potentially malignant tumors.

According to the “two hit” Knudson hypothesis, mutations in 2 alleles are required for tumorigenesis. Furthermore, Michaelson et al. reported that progression to metastasis is a function of the number of tumor cells, with a rate of 1 metastasis per 1 billion tumor cells seen in breast cancer (55). Therefore, one can reasonably hypothesize that with an

exponential increase in the number of tumor cells, there is an exponentially greater potential for genetic mutations to generate aggressive-behaving cancer cells.

Our data supports the advantages of evaluating volumetric growth rates during AS of small renal masses. Known RCC lesions demonstrated a more than three-fold greater increase in tumor volume ($2.91\text{cm}^3/\text{yr}$) compared to benign lesions ($0.95\text{cm}^3/\text{yr}$). In addition, lesions $>4\text{cm}$ at presentation which are generally considered to have greater potential for malignancy had a significantly greater change in volume per year of $5.89\text{cm}^3/\text{yr}$ compared with $0.63\text{cm}^3/\text{yr}$ in lesions $\leq 4\text{cm}$ ($p<0.009$). The advantage of evaluating volume growth over linear growth is also highlighted by the significant difference in the slopes of malignant and benign tumors in figures 5 vs. 6. Based on these arguments and the findings from our study, we strongly feel that lesion volume is a better indicator for disease progression than is linear diameter measurement.

Active surveillance of slow growing renal lesions offers many advantages, especially in patients who are more likely to die of their competing comorbidities. It can also prevent an unnecessary procedure on an otherwise healthy and functioning kidney. Such benefit was observed in one patient in our cohort with two ipsilateral renal lesions measuring 1.2cm and 0.7cm with growth rates of $0.11\text{cm}/\text{yr}$ and $-0.08\text{cm}/\text{yr}$, respectively. After a 97-month surveillance period, this patient discontinued follow up when the final MRI distinguished the presence of fat within the lesions consistent with Angiomyolipoma (AML). Fat within the lesion was not detectable in any previous imaging. AS, in this

case, allowed time for the benign features in this lesion to become apparent, thus preventing an unnecessary surgery and future consequences of renal surgery.

It is important to note that lesion sizes and descriptions for our subjects were recorded from radiology reports, and that a single radiologist did not review all lesions. The interpretation of lesion size carries an inherent margin of error based on the placement of the measuring cursor by the radiologist. Having a single radiologist review all radiographic imaging would provide a more consistent interpretation of results and minimize the inherent error of cursor placement. However, this study was designed to replicate real life experiences of practicing urologists. Other limitations of this study include a small subject population and the limited percentage of lesions with pathological data.

As noted previously, the mean volumetric growth rate for the lesions in our study was obtained from the same data as linear growth rates because it was not initially considered as a primary endpoint for this study. However, after approximating the lesions volumes and evaluating the mean change in volume per year, volumetric data promises to be a better clinical predictive value than linear measurements. Studies collecting true renal tumor volume data are important in verifying the predictive power of volume calculations proposed in this study as well as to better understand the behavior of small renal tumors.

Although the current gold standard for treatment of renal tumors is surgical excision, we strongly believe that small enhancing renal tumors are being highly overtreated. Patient

selection for surgery should be based on the patient's age, risk of death from renal cancer, competing comorbidities, and risk of surgical morbidity or mortality. We believe that our data in conjunction with other published results supports the role of active surveillance as a reasonable alternative for management of small renal tumors (<4cm) in patients with greater age and competing comorbidities. With active surveillance of enhancing renal lesions the urologist and patient assume a calculated risk of growth and metastasis. However, any surgical intervention also carries a given risk of morbidity and even mortality. In certain patients, the risk of surgery far outweighs the risk associated with AS of their renal lesion.

As the distinguished urologist Dr. Willet Whitmore once said, "Is cure necessary in those for whom it is possible, and is cure possible in those for whom it is necessary?" His prophetic words with respect to the overdiagnosis of prostate cancer can be applied to renal cancer and the current trends of overdiagnosing and overtreating of slow growing small renal lesions. Ultimately, it is likely that molecular biomarkers will enable us to better predict the behavior of renal cancers. Until such time, however, urologists should be mindful about the patients they are selecting for surgery and consider active surveillance with delayed or no treatment as a viable alternative for management of small renal tumors in older or high surgical risk patients.

CONCLUSION

Small enhancing renal masses grow at a slow rate of 0.12cm/yr during observation, with malignant lesions growing at a faster rate than benign lesions. Although linear growth has

been used for evaluation of lesion growth, we strongly believe that tumor volume may be a better predictor of disease progression as it more directly correlates with the exponential increase in the number of potentially cancerous cells. Active surveillance can be used as a safe alternative to surgery in properly selected patients.

ABBREVIATIONS:

RCC = Renal Cell Carcinoma

AS = Active Surveillance

SRM = Small renal mass

CT = Computed Tomography

MRI = Magnetic Resonance Imaging

NCCN = National Comprehensive Cancer Network

AUA = American Urological Association

EAU = European Association of Urology

WORKS CITED:

- 1) Schlomer B, Figenshau RS, Yan Y, Venkatesh R and Bhayani SB. Pathological features of renal neoplasms classified by size and symptomatology. *J Urol* 2006 Oct; **176(4 Pt 1)**:1317-20.
- 2) Patard JJ, Tazi H, Bensalah K, Rodriguez A, Vincendeau S et al. The changing evolution of renal tumours: a single center experience over a two-decade period. *Eur Urol* 2004 Apr; **45(4)**: 490-3.
- 3) Campbell SC, Novick AC, Belldegrun A, Blute ML, et al. Guidelines for management of clinical T1 Renal Mass. *J Urol* 2009 Oct; **182(4)**: 1271-9.
- 4) Uzzo RG, and Novick AC. Nephron sparing surgery for renal tumors: indications, techniques and outcomes *J Urol* 2001; **166**: 6.
- 5) Chawla SN, Crispen PL, Hanlon AL, Greenberg RE, Chen DYT and Uzzo R. The natural history of observed enhancing renal masses: meta-analysis and review of the world literature. *J Urol* 2006; **175**: 425-31.
- 6) Rendon RA, Staneitzky N, Panzarella T, Robinette M., et al. The natural history of small renal masses. *J Urol* 2000; **164**: **1143**.
- 7) Bosniak MA, Birnbaum BA, Krinsky GA and Waisman J. Small renal parenchymal neoplasms: further observations on growth. *Radiology* 1995; **197**: 589.
- 8) Oda T, Miyao N, Takahashi A, Yanase M., et al. Growth rates of primary and metastatic lesions of renal cell carcinoma. *Int J Urol* 2001; **8**: 473.
- 9) Wehle MJ, Thiel DD, Petrou SP, et al. Conservative management of incidental contrast-enhancing renal masses as safe alternative to invasive therapy. *Urology* 2004; **64**: 49.
- 10) Kato M, Suzuki T, Suzuki Y, Terasawa Y, et al. Natural history of small renal cell carcinoma: evaluation of growth rate, histological grade, cell proliferation and apoptosis. *J Urol* 2004; **172**: 863.
- 11) Kassouf W, Aprikian AG, Laplante M and Tanguay S. Natural history of renal masses followed expectantly. *J Urol* 2004; **171**: 111.
- 12) Sowery RD and Siemens DR. Growth characteristics of renal cortical tumors in patients managed by watchful waiting. *Can J Urol* 2004; **11**: 2407.
- 13) Kissane JM. The morphology of renal cystic disease. *Perspect Nephrol Hypertens* 1976; **4**:31-63.

- 14) Licht MR. Renal adenoma and oncocytoma. *Semin Urol Oncol* 1995 Nov; **13(4)**:262-6.
- 15) Perez-Ordóñez B, Hamed G, Campbell S, Erlandson RA, Russo P et al. Renal oncocytoma: a clinicopathologic study of 70 cases. *Am J Surg Pathol* 1997 Aug;**21(8)**:871-83.
- 16) Tanagho EA, McAninch JW 2008. Smith's general urology, 17th Edition. New York: McGraw Hill Companies. 756 pp.
- 17) Steiner MS, Goldman SM, Fishman EK, Marshall FF. The natural history of renal angiomyolipoma. *J Urol* 1993 Dec; **150(6)**:1782-6.
- 18) Chiong E, Consigliere D, Esuvaranathan K. Renal tumours: a common incidental finding. *Singapore Med J* 2007;**48(6)**:495-503.
- 19) Thoenes W, Störkel S, Rumpelt HJ, Moll R, Baum HP. Chromophobe cell renal carcinoma and its variants—a report on 32 cases. *J Pathol* 1988 Aug;**155(4)**:277-87.
- 20) Wieder JA. 2010. *Pocket guide to urology* (4th Edition). United States of America: Griffith Publishing. 538pp.
- 21) Pascual D, Borque A. Epidemiology of kidney cancer. *Adv Urol* 2008:782381. Epub 2008 Nov 4.
- 22) Howlader N, Noone AM, Krapcho M, Neyman N, Aminou R et al. SEER Cancer Statistics Review, 1975-2008, National Cancer Institute. Bethesda, MD, http://seer.cancer.gov/csr/1975_2008/, based on November 2010 SEER data submission, posted to the SEER web site, 2011. Accessed Jan 11, 2012.
- 23) "Kidney Cancer". National Cancer Institute, U.S. National Institutes of Health. Available at www.cancer.gov/cancertopics/types/kidney. Retrieved Jan 11, 2012.
- 24) Lipworth L, Tarone RE, McLaughlin JK. The epidemiology of renal cell carcinoma. *J Urol* 2006 Dec; **176(6 Pt 1)**: 2353-8. Review.
- 25) McLaughlin JK, Lipworth, Tarone RE. Epidemiologic aspects of renal cell carcinoma. *Semin Oncol* 2006 Oct; **33(5)**: 527-33. Review.
- 26) Vogelzang NJ, Stadler WM. Kidney cancer. *Lancet* 1998 Nov; **352(9141)**:1691-6.
- 27) Hunt JD, van der Hel OL, McMillan GP, Boffetta P, Brennan P. Renal cell carcinoma in relation to cigarette smoking: meta-analysis of 24 studies. *Int J Cancer* 2005 Mar;**114(1)**:101-8.

- 28) Sharifi N, Farrar WL. Perturbations in hypoxia detection: a shared link between hereditary and sporadic tumor formation. *Med Hypotheses* 2006;**66(4)**:732-5.
- 29) Chow W, Dong LM, Devesa SS. Epidemiology and risk factors for kidney cancer. *Nat Rev Urol* 2010 May;**7(5)**:245-57.
- 30) Sufrin G, Chasan S, Golio A, Murphy GP. Paraneoplastic and serologic syndromes of renal adenocarcinoma. *Semin Urol* 1989 Aug; **7(3)**:158-71.
- 31) Muggia FM. Overview of cancer-related hypercalcemia: epidemiology and etiology. *Semin Oncol* 1990 Apr; **17(2 Suppl 5)**:3-9.
- 32) Gold PJ, Fefer A, Thompson JA. Paraneoplastic manifestation of renal cell carcinoma. *Semin Urol Oncol* 1996 Nov; **14(4)**:216-22.
- 33) Henriksson C, Haraldsson G, Aldenborg F, Lindberg S, Pettersson S. Skeletal metastases in 102 patients evaluated before surgery for renal cell carcinoma. *Scan J Urol Nephrol* 1992; **26(4)**:363-6.
- 34) Herts BR, and Baker ME: The current role of percutaneous biopsy in the evaluation of renal masses. *Semin Urol Oncol* 1995 Nov; **13(4)**: 254-61.
- 35) Dechet CB, Zincke H, Sebo TJ, King BF, LeRoy AJ, Farrow GM, et al: Prospective analysis of computerized tomography and needle biopsy with permanent sectioning to determine the nature of solid renal masses in adults. *J Urol* 2003 Jan; **169(1)**: 71-4.
- 36) "NCCN Clinical Practice Guidelines in Oncology, Kidney Cancer." National Comprehensive Cancer Network. Version 1.2012. Updated October 18, 2011. Available at www.nccn.org/professionals/physician_gls/pdf/kidney.pdf. Accessed January 11, 2012.
- 37) Ljungberg B, Cowan NC, Hanbury DC, Hora M, Kuczyk MA et al. EAU guidelines on renal cell carcinoma: the 2010 update. *Eur Urol* 2010; **58**:398-406.
- 38) "Guideline for management of the clinical stage 1 renal mass." American Urological Association. Updated 2009. Available at www.auanet.org/resources.cfm?ID=442. Accessed January 11, 2012.
- 39) Edge SB, Byrd DR, Compton CC, et al., eds.: AJCC Cancer Staging Manual. 7th ed. New York, NY: Springer, 2010, pp 479-89.
- 40) Itano NB, Blute ML, Spotts B, Zincke H. Outcome of isolated renal cell carcinoma fossa recurrence after nephrectomy. *J Urol* 2000 Aug;**164(2)**:322-5.

- 41) Huang WC, Levey AS, Serio AM, Snyder M, Vickers AJ, et al. Chronic kidney disease after nephrectomy in patients with renal cortical tumours: a retrospective cohort study. *Lancet Oncol* 2006; **7(9)**: 735-40.
- 42) Castilla EA, Liou LS, Abrahams NA, Fergany A, Rynicki LA. Prognostic importance of resection margin width after nephron-sparing surgery for renal cell carcinoma. *Urology* 2002 Dec; **60(6)**:993-7.
- 43) Lau WK, Blute ML, Weaver AL, Torres VE, Zincke H. Matched comparison of radical nephrectomy vs nephron-sparing surgery in patients with unilateral renal cell carcinoma and a normal contralateral kidney. *Mayo Clin Proc* 2000 Dec; **75(12)**:1236-42.
- 44) Huang WC, Elkin EB, Levey AS, Jang TL, Russo P. Partial nephrectomy versus radical nephrectomy in patients with small renal tumors—is there a difference in mortality and cardiovascular outcomes? *J Urol* 2009 Jan; **181(1)**:55-61; discussion 61-2.
- 45) Thompson RH, Boorjian SA, Lohse CM, Leibovich BC, Kwon ED. Radical nephrectomy for pT1a renal masses may be associated with decreased overall survival compared with partial nephrectomy. *J Urol* 2008 Feb; **179(2)**:468-71.
- 46) Joniau S, Tsivian M, Gontero P. Radiofrequency ablation for the treatment of small renal masses: safety and oncologic efficacy. *Minerva Urol Nefrol* 2011 Sept; **63(3)**:227-36.
- 47) Nguyen CT, Lane BR, Kaouk JH, Hegarty N, Gill IS, Novick AC, Campbell SC. Surgical salvage of renal cell carcinoma recurrence after thermal ablative therapy. *J Urol* 2008 Jul; **180(1)**:104-9.
- 48) Crispen PL, Viterbo R, Fox EB, Greenberg RE, Chen DY, Uzzo RG. Delayed intervention of sporadic renal masses undergoing active surveillance. *Cancer* 2008 Mar; **112(5)**:1051-7.
- 49) Zini L, Perrotte P, Jeldres C, Capitanio U, Duclos A, et al. A population-based comparison of survival after nephrectomy vs nonsurgical management for small renal masses. *BJU Int* 2009 Apr; **103(7)**:899-904.
- 50) Rothman J, Egleston B, Wong YN. Histopathological characteristics of localized renal cell carcinoma correlate with tumor size: a SEER analysis. *J Urol* 2009 Jan; **181(1)**: 29-33.
- 51) Kunkle DA, Egleston BL and Uzzo RG. Excise, ablate, or observe: the small renal mass dilemma- a meta-analysis and review. *J Urol* 2008 Apr; **179(4)**: 1227-33.
- 52) Nguyen MM and Gill IS. Effects of renal cancer tumor size on the prevalence of metastasis at diagnosis and mortality. *J Urol* 2009 Mar; **181(3)**: 1020-7.

- 53) Tsui KH, Shvarts O, Smith RB, Figlin R, de Kernion JB, Belldegrun A. Renal cell carcinoma: prognostic significant of incidentally detected tumors. *J Urol* 2000 Feb; **163(2)**: 426-30.
- 54) Volpe A, Panzarella T, Rendon RA, Haier MA, Kondylis FI, et al. The natural history of incidentally detected renal masses. *Cancer* 2004 Feb; **100(4)**:738-45.
- 55) Michaelson JS, Silverstein M, Wyatt J, Weber G, Moore R, Halpern et al. Predicting the survival of patients with breast carcinoma using tumor size. *Cancer* 2002 Aug; **95(4)**:713-23.
- 56) Israel GM, Bosniak MA. Calcification in cystic renal masses: is it important in diagnosis? *Radiology*. 2003 Jan;**226(1)**:47-52.
- 57) Bressenot A, Delaunay C, Gauchotte G, Oliver A, Boudrant G, et al. Composite renal cell carcinoma with clear cell renal cell carcinomatous and carcinoid tumoral elements: a first case report. *J Clin Pathol* 2010;**63**:174-176.