

Yale University
EliScholar – A Digital Platform for Scholarly Publishing at Yale

Yale Medicine Thesis Digital Library

School of Medicine

2-11-2008

Efficacy of Neoadjuvant Chemotherapy Regimens Prior to Resection of Colorectal Liver Metastases

Farrah Mikhail Datko
Yale University

Follow this and additional works at: <http://elischolar.library.yale.edu/ymtdl>

Recommended Citation

Datko, Farrah Mikhail, "Efficacy of Neoadjuvant Chemotherapy Regimens Prior to Resection of Colorectal Liver Metastases" (2008).
Yale Medicine Thesis Digital Library. 318.
<http://elischolar.library.yale.edu/ymtdl/318>

This Open Access Thesis is brought to you for free and open access by the School of Medicine at EliScholar – A Digital Platform for Scholarly Publishing at Yale. It has been accepted for inclusion in Yale Medicine Thesis Digital Library by an authorized administrator of EliScholar – A Digital Platform for Scholarly Publishing at Yale. For more information, please contact elischolar@yale.edu.

EFFICACY OF NEOADJUVANT
CHEMOTHERAPY REGIMENS PRIOR TO
RESECTION OF COLORECTAL LIVER
METASTASES

A Thesis Submitted to the
Yale University School of Medicine
in Partial Fulfillment of the Requirements for the
Degree of Doctor of Medicine

Farrah Mikhail Datko

2007

EFFICACY OF NEOADJUVANT CHEMOTHERAPY REGIMENS PRIOR TO RESECTION OF COLORECTAL LIVER METASTASES.

Farrah M. Datko (Sponsored by M. Wasif Saif). Yale Cancer Center, Department of Internal Medicine, Yale University School of Medicine, New Haven, CT.

While new treatments for metastatic colorectal cancer continue to be developed, the ideal neoadjuvant regimen prior to resection of liver metastases is still unknown. The primary goal of this study was to compare disease-free survival outcomes in patients who received oxaliplatin- or irinotecan-based neoadjuvant chemotherapy regimens prior to resection of colorectal liver metastases.

A retrospective chart review was performed of all 27 patients who underwent liver resection of colorectal cancer metastases at Yale-New Haven Hospital between January 2003 and December 2005. Records were reviewed for details of initial diagnosis, treatment regimen(s) prior to resection of hepatic metastases, results of surgical liver resection, adjuvant treatment after liver resection, post-operative disease recurrence and overall survival. Median disease-free survival calculations were based on survival curves drawn according to Kaplan-Meier methods.

Out of 15 patients with at least one year of follow-up, six were treated with neoadjuvant FOLFOX prior to liver resection, three with first-line FOLFOX followed by second-line FOLFIRI, two with FOLFIRI, one with IFL, and three patients had no neoadjuvant chemotherapy. Median disease-free survival was 15.5 months in patients treated with neoadjuvant FOLFOX, 16.3 months in patients treated with first-line FOLFOX followed by second-line FOLFIRI, 16.3 months in patients treated with irinotecan-based neoadjuvant therapy, and was not reached in the group who did not receive any neoadjuvant treatment ($p=0.84$). Actual one-year disease-free survival rate was 67% regardless of neoadjuvant treatment group. The sample size was too small to determine which patient, tumor, and treatment variables were associated with disease recurrence.

The majority of patients undergoing liver resection of colorectal metastases at Yale-New Haven Hospital in recent years were treated with neoadjuvant FOLFOX. Median disease-free survival and actual one-year disease-free survival was almost identical among patients receiving FOLFOX, irinotecan-based regimens, or first-line FOLFOX followed by second-line FOLFIRI, although analysis was limited by a small sample size. Larger prospective trials are needed to compare oxaliplatin- and irinotecan-based neoadjuvant chemotherapy regimens for patients with either resectable or unresectable colorectal hepatic metastases.

ACKNOWLEDGEMENTS

I would first like to express my heartfelt gratitude to my advisor, Dr. Wasif Saif. His infinite patience and dedication to his work have been an inspiration.

Thank you to Dr. Ronald Salem, for his expert advice and for allowing me to study his patients. Thank you also to patient MN, who first taught me about this disease through her own personal story and inspired this research project.

Love and thanks to my friends, family, and husband, Joshua, who have accompanied me on this journey and provided constant encouragement.

“To our God and Father be glory for ever and ever.” –Philippians 4:20

TABLE OF CONTENTS

INTRODUCTION.....	5
Surgical resection of colorectal metastases to the liver.....	5
Defining resectability.....	7
Oxaliplatin and irinotecan in advanced colorectal cancer.....	9
Bevacizumab, cetuximab and panitumumab in advanced colorectal cancer.....	14
Role of neoadjuvant chemotherapy in patients with colorectal liver metastases.....	16
Neoadjuvant chemotherapy regimens for patients with colorectal liver metastases...	22
PURPOSE, HYPOTHESIS AND SPECIFIC AIMS.....	28
METHODS.....	28
RESULTS.....	30
DISCUSSION.....	36
REFERENCES.....	38

INTRODUCTION

Colorectal cancer is the third leading cause of cancer deaths in the United States, estimated at 55,000 in 2006 [1]. Nearly one million new cases are diagnosed every year around the world, making colorectal cancer the third most prevalent type of cancer worldwide. In the United States, one in 17 men (5.9%) and one in 18 women (5.5%) will be diagnosed with colorectal cancer during their lifetime [2].

The liver is the most common site of colorectal metastases. Over half of all patients with colorectal cancer will have metastatic disease to the liver either at diagnosis (15-25%) or during the course of their disease (another 35-45%) [3]. In fact, many of these patients will have liver-only metastases. This predilection is largely due to the portal venous system, which drains blood directly from colorectal capillary beds to the liver. Colorectal cancer cells that have penetrated a blood vessel at the primary tumor site will encounter the liver before any other organ, where they are most likely to lodge and grow into a new focus. This is in contrast to liver metastases from other primary tumors (e.g., breast, lung, melanoma), which are generally an indication of much more widespread disease. In these cases, surgical resection of liver metastases is considered futile. Resection of colorectal metastases to the liver, however, can be curative.

Surgical resection of colorectal metastases to the liver

Even in the absence of prospective analysis, it is now well-established that hepatic resection of colorectal metastases is essential for any chance of long-term survival. Several studies have retrospectively compared survival outcomes after surgical resection of colorectal liver metastases with chemotherapy alone. In 1990, Scheele et al. looked at

a large cohort of patients with colorectal liver metastases treated between 1960 and 1987. There were no 5-year survivors out of 921 patients with unresectable disease. In comparison, the five-year survival rate was 31% for the group of 226 resected patients [4]. A later update in 469 resected patients reported a five-year survival rate of 39% [5]. Since patients with resectable disease often have lower tumor burden and thus more favorable prognosis than those considered unresectable, this study also looked at patients with potentially resectable disease who did not undergo surgery for various reasons. This subgroup of 62 patients also failed to reach 5-year survival [4]. More recently, Kato et al. analyzed a cohort of patients treated between 1992 and 1996, demonstrating a 5-year survival rate of 3.4% for unresected patients (n=178) compared to 32.9% for patients undergoing hepatectomy for hepatic metastases (n=585) [6]. An epidemiologic study of patients with metachronous colorectal liver metastases between 1976 and 2000 reported a 5-year survival rate of 3.1% in pts receiving chemotherapy alone (n=82) and 29.0% in pts undergoing resection (n=79) [7]. Additional studies that have reported five-year survival rates in large cohorts of patients after hepatic resection include Nordlinger et al (28%, n=1568), Fong et al. (37%, n=1001), and Figueras et al. (36%, n=235) [8-10]. In summary, historical five-year overall survival with chemotherapy alone has been rare, compared to survival rates in the range of 28-39% after resection of liver metastases. Indeed, with such convincing data, it would be very difficult to design a prospective study which randomizes patients to receive chemotherapy only, as offering what is considered palliative treatment when a curative option exists would be considered unethical.

It is important to note that the patients included in the above studies were treated before recent advances in chemotherapeutic agents. Long-term survival in patients receiving newer and more effective therapeutics are clearly improving but just now being published. With the adjuvant use of these newer agents, 5-year survival rates after resection of colorectal liver metastases are now in the range of 50-60% [11, 12]. Although unlikely, it is possible that treatment with newer combination chemotherapy alone can result in similar 5-year survival rates. This data will be difficult to ascertain, however, as all patients who become resectable must now be considered for surgery. For now, we only have scattered accounts of long-term remission in patients who declined surgery [13] or who responded so dramatically to neoadjuvant chemotherapy that one or more liver metastases could not be found intraoperatively for resection [14].

Defining resectability

Patients must be carefully selected for resection of colorectal liver metastases. Only complete tumor removal (R0 resection) results in a survival benefit. In contrast, patients who undergo resections with positive microscopic margins (R1 resections) or grossly positive margins (R2 resections) have survival outcomes comparable to unresected patients [5]. Therefore, the goal is to maximize the rate of complete resections while avoiding morbidity from unnecessary surgeries.

The definition of resectability has evolved over time and still remains to be definitively established. In the 1970s and 1980s, resection was often limited to selected younger patients with only one liver metastasis. With accumulating evidence that surgical resection offered much improved long-term survival, the criteria for resectability

began to expand. Nevertheless, approximately 80% of patients have hepatic metastases considered unresectable at the time of presentation, due to a combination of factors including tumor size, number, extent and location [15].

Two landmark studies published in 1986 established the first contraindications to resection of colorectal liver metastases. The first, by Ekberg et al, analyzed factors influencing survival after liver resection, while the second, by Hughes et al, sought to determine which variables increased the likelihood of recurrence after resection [16, 17]. From these and similar studies, the classic contraindications to resection became the following: four or more liver metastases, metastasis diameter >5cm, bilobar metastases, the presence of extrahepatic disease, and proximity to vital structures that would preclude resection margins of at least 1cm. Resections were preferably offered to patients with 1-3 unilobar metastases presenting metachronously (i.e., not present at diagnosis of the primary colorectal tumor).

Two decades later, these contraindications are no longer valid. Patient with resection of multiple (≥ 4) liver metastases have been shown to have favorable outcomes after surgery (five-year survival rate 33%, n=98) [18], as well as patients with resectable extrahepatic disease (five-year survival rate 28%, n=84) [19]. Although wide resection margins remain the goal, even patients who can be resected with minimal margins should be offered surgery [20, 21]. A recent retrospective analysis demonstrated that patients with large metastases (>8cm) also benefit from surgery, with 5-year survival rates of 38% (n=88) compared with 42% in those with smaller metastases (n=396, not a statistically significant difference, p=0.303) [22].

The most up to date criteria for resectability were established during the American Hepato-Pancreato-Biliary Association consensus conference early 2006 and outlined in the 2005 OncoSurge therapeutic decision model [20, 23]. Using existing evidence and an expert panel, the following absolute contraindications to resection were defined: “unresectable extrahepatic disease (such as peritoneal carcinomatosis, multifocal lung metastases, and distant lymph nodes in the preaortic and celiac axis N2 nodal basin for the liver, bone, or brain metastases), extensive liver involvement (more than six liver segments involved, >70% liver invasion or all three hepatic veins involved), major liver insufficiency or Child B or C liver cirrhosis with complications, and patients unfit for or declining surgery” [23].

While each patient must still be evaluated individually, it is important to have established criteria of resectability and non-resectability for comparative analysis across the literature. With such a high percentage of patients considered unresectable at initial presentation, one of the goals of neoadjuvant chemotherapy is to shrink tumors to the point of resectability. Unfortunately, the majority of studies evaluating the efficacy of various neoadjuvant regimens in this regard use considerably different definitions of resectability or fail to define any criteria at all [13].

Oxaliplatin and irinotecan in advanced colorectal cancer

For decades, the mainstay of chemotherapy in metastatic colorectal cancer has been the thymidylate synthase inhibitor fluorouracil (5-FU), given in combination with the potentiator folinic acid (leucovorin, LV). Although randomized trials demonstrated improved overall survival and quality of life compared to best supportive care, actual

response rates were disappointingly low (18-44%), with a median overall survival of just 11-15 months in eight randomized trials [24]. With few new drug prospects, research focused on comparing various treatment delivery schedules in order to minimize toxicity while optimizing survival outcomes. For example, one large meta-analysis demonstrated that continuous intravenous infusion of 5-FU is superior to intravenous bolus [25]. More recently, capecitabine, an oral prodrug of 5-FU, has been shown to be as effective as bolus 5-FU/LV in a phase III trial of 1987 patients with advanced colorectal cancer [26]. The oral prodrug capecitabine is associated with less neutropenia but an increased incidence of hand-foot syndrome.

After years of disappointing outcomes in patients treated with 5-FU/LV alone, there now are two newer cytotoxic agents which have substantially improved prognosis in patients with advanced colorectal cancer when given in combination with 5-FU/LV. The first of these is oxaliplatin, a third generation platinum analog, which works synergistically with infusional 5-FU/LV in the FOLFOX regimen. One phase III trial randomized 420 patients with previously untreated metastatic colorectal cancer to receive 5-FU/LV with or without oxaliplatin. The addition of oxaliplatin resulted in better median progression-free survival (9.0 vs. 6.2 months, $p=0.0003$) and superior response rates (50.7% vs. 22.3%, $p=0.0001$), although overall survival did not reach statistical significance (16.2 vs. 14.7 months, $p=0.12$) [27]. In the MOSAIC trial, 1347 patients with stage III colon cancer were randomized to receive six months of adjuvant infusional 5-FU/LV with or without oxaliplatin. Patients in the oxaliplatin-containing arm demonstrated a statistically significant improvement in disease-free survival at three years (72.2% with oxaliplatin vs. 65.3% without oxaliplatin, hazard ratio for relapse 0.76

with 95%CI 0.62 to 0.92) [28]. Oxaliplatin-associated toxicity includes neutropenia, diarrhea, and sensory neuropathy [27].

Irinotecan, a topoisomerase I inhibitor, is another cytotoxic agent now regularly used for the treatment of advanced colorectal cancer. The combination of infusional 5-FU/LV with irinotecan (FOLFIRI) is now more commonly used than bolus 5-FU/LV with irinotecan (IFL) because of more favorable toxicity data. The addition of irinotecan has been shown to improve progression-free survival in patients with advanced colorectal cancer. In one study, 683 patients were randomized to receive either IFL, bolus 5-FU/LV alone, or irinotecan alone. When compared with the group receiving bolus 5-FU/LV alone, patients treated with the IFL combination demonstrated a 40% improvement in median progression-free survival (7.0 months vs. 4.3 months, $p=0.004$) as well as better overall survival (14.8 vs. 12.6 months, $p=0.04$) [29]. This combination was synergistic, as patients receiving irinotecan alone had median survival comparable to patients receiving only bolus 5-FU/LV. A second study randomized 387 patients with metastatic colorectal cancer to receive either FOLFIRI or infusional 5-FU/LV alone. The FOLFIRI arm demonstrated significantly longer median time to progression (6.7 vs. 4.4 months, $p<0.001$) and better overall survival (17.4 vs. 14.1 months, $p=0.031$) [30]. The most commonly reported toxic effect of irinotecan in both studies was diarrhea, which can be severe [29, 30].

Table 1. Randomized trials comparing oxaliplatin- and irinotecan-based regimens

Study	Regimen	n	overall RR	median TTP	median OS
<i>Goldberg et al. 2004</i> [31]	IFL	264	31%	6.9mo	15.0mo
	FOLFOX	267	45% p=0.002	8.7mo p=0.0014	19.5mo p=0.0001
<i>Colucci et al. 2005</i> [32]	FOLFIRI	164	31%	7mo	14mo
	FOLFOX4	172	34% p=0.60	7mo p=0.51	15mo p=NS
<i>Kalofonos et al. 2003</i> [33]	FOLFIRI	147	32%	7.6mo	17.4mo
	FOLFOX	148	33% p=0.20	8.9mo p=NS	17.6mo p=0.85
<i>Tournigand et al. 2004</i> [34]	FOLFIRI → FOLFOX6	109	56%	8.5mo	21.5mo
	FOLFOX6 → FOLFIRI	111	54% p=NS	8.0mo p=0.26	20.6mo p=0.99
<i>Souglakos et al. 2006</i> [36]	FOLFIRI	146	34%	6.9mo	19.5mo
	FOLFOXIRI	137	43% p=0.17	8.4mo p=0.17	21.5mo p=0.34

RR = response rate, TTP = time to progression, OS = overall survival, NS = not significant.

Several randomized trials have directly compared the efficacy of oxaliplatin and irinotecan in patients with advanced colorectal cancer. These studies are summarized in Table 1. Goldberg et al. randomized 795 patients to receive either IFL, FOLFOX, or irinotecan and oxaliplatin (IROX). Patients receiving FOLFOX had a median overall survival of 19.5 months, compared to 17.4 months in the IFL group (p=0.0001) and 17.4 months in the IROX group (p=0.09). Those in the FOLFOX arm also benefited from increased response rates and longer time to progression [31]. Unfortunately, it is difficult to draw useful conclusions based on these results because 5-FU/LV was administered in different schedules. Two other studies, however, randomized patients to receive either FOLFOX or FOLFIRI, both of which use infusional 5-FU/LV [32, 33]. In both, there was no significant difference in response rate, time to progression or overall survival between the two study arms (see Table 1). Finally, Tournigand et al designed a unique study to evaluate both FOLFOX and FOLFIRI as first- and second-line therapies in advanced colorectal cancer. In this study, patients randomized to the first arm received

FOLFIRI until either disease progression or prohibitive toxicity, at which point patients were switched to FOLFOX. Patients randomized to the second arm received the opposite sequence. Again, there was no significant difference between the two regimens.

FOLFIRI as first line therapy resulted in response rates of 56% with median progression free survival of 8.5 months, which compared with 54% and 8.0 months when FOLFOX was given first line [34]. Toxicity profiles were fairly similar between the two agents in all four studies.

These trials suggest that there is no significant survival advantage between FOLFIRI and FOLFOX in patients with metastatic colorectal cancer. In a recent consensus statement, Bartlett et al. conclude that “treatment decisions for first-line therapy can be made based on the toxicity profile of individual drugs or on personal preference but not because of significant differences in efficacy” [35]. While oxaliplatin and irinotecan have comparable effects in advanced colorectal cancer, it is interesting to note that FOLFIRI has been significantly less effective than FOLFOX in patients with more localized stage III disease, although it is unclear why this is the case [35].

The four-drug combination of oxaliplatin, irinotecan, and infusional 5FU/LV (FOLFOXIRI) has also been evaluated in metastatic colorectal cancer. In a phase III trial by Souglakos et al., patients randomized to receive FOLFOXIRI had slightly better response rates, time to disease progression and overall survival compared to patients treated with FOLFIRI (see Table 1), although this trend was not statistically significant [36]. The toxicity profile was significantly worse in the FOLFOXIRI arm, however, with much higher rates of grade 3/4 diarrhea and sensory neuropathy ($p < .001$ for both when compared to the FOLFIRI arm). The authors suggest that sequential treatment with

FOLFOX and FOLFIRI (as in the study by Tournigand et al. [34]) may be preferable to treatment with FOLFOXIRI, especially when targeted agents are to be added to the regimen [36].

Bevacizumab, cetuximab and panitumumab in advanced colorectal cancer

In addition to the cytotoxic agents oxaliplatin and irinotecan, a set of targeted agents now have an established role in the treatment of metastatic colorectal cancer. Bevacizumab is a humanized monoclonal antibody against vascular endothelial growth factor (VEGF), which is often expressed by cancer cells seeking to promote angiogenesis. Cetuximab and panitumumab are chimerized and fully human monoclonal antibodies, respectively, both designed to target the epidermal growth factor receptor (EGFR).

Two major randomized phase III trials have evaluated the efficacy of bevacizumab in patients with advanced colorectal cancer, one as first-line and the other as second-line therapy. The first, by Hurwitz et al., compares bevacizumab given with IFL (n=402) to treatment with IFL plus placebo (n=411). Bevacizumab significantly increased response rates (44.8% vs. 34.8%, p=0.004), progression-free survival (10.6 vs. 6.2 months, p<0.001) and overall survival (20.3 vs. 15.6 months, p<0.001) [37]. Similar results were produced in the second study, which looked at 579 patients previously treated with irinotecan-containing regimens. In this second-line setting, patients receiving bevacizumab in combination with FOLFOX had improved overall survival compared to patients receiving FOLFOX alone (12.5 vs. 10.7 months, p=0.0024) [38].

There is less data available on the efficacy of cetuximab. The only completed phase III trial randomized patients who had failed prior treatment to receive cetuximab

monotherapy or cetuximab plus irinotecan. Although patients in the combination arm had statistically significant improvement in response rates and median time to progression, there was no significant effect on overall survival [39]. With two cetuximab-containing arms, it is difficult to draw conclusions on the efficacy of cetuximab itself based on these results. However, multiple phase II studies have demonstrated significantly better response rates in patients receiving cetuximab in combination with FOLFOX or FOLFIRI [40-42]. These are promising results, but trials establishing survival outcomes are still in progress. The ongoing EPIC trial randomizes patients who have failed first-line FOLFOX to receive either cetuximab plus irinotecan or irinotecan alone.

Recently, panitumumab was also approved for use in advanced colorectal cancer. In a phase III randomized trial of 463 patients with progression of disease after standard treatment, patients receiving panitumumab monotherapy had a 46% lower tumor progression rate compared to patients receiving only supportive care [43]. Ongoing trials are currently evaluating panitumumab as first-line treatment in combination with FOLFIRI [44] or with FOLFOX and panitumumab (PACCE: Panitumumab Advanced Colorectal Cancer Evaluation study) [45]. The most frequently reported adverse event in patients treated with panitumumab is a skin rash.

Bevacizumab is currently the only targeted therapy with a demonstrated survival benefit in the first-line setting, although both cetuximab and panitumumab have shown promise and are awaiting results of further investigation. While these results are pending, current standard of care for first-line therapy according to a recent consensus statement is either FOLFOX or FOLFIRI in combination with bevacizumab. If FOLFOX is used

first-line, then FOLFIRI should be used as second-line treatment, and vice-versa, and cetuximab should be added to the regimen upon progression of disease [35].

Role of neoadjuvant chemotherapy in patients with colorectal liver metastases

The development of these newer therapeutic agents has significantly improved prognosis in patients who present with unresectable colorectal liver metastases. Only a decade ago, these patients were typically treated with palliative intent; currently, up to a third of patients with initially unresectable hepatic metastases experience enough tumor shrinkage to become candidates for surgical resection [15]. In one series, the five-year survival rate was 50% in 77 patients who underwent hepatic resections after neoadjuvant FOLFOX. Of the 58 patients who had either R0 or R1 resections, 58% and 50% were alive at five and seven years [46]. Five-year survival was 40% in another series of 53 patients with liver metastases rendered resectable by neoadjuvant FOLFOX [47]. Many authors have compared these commendable results to the 28-39% five-year survival rates previously reported in resectable patients who underwent primary liver resections [4-10]. However, it must be noted that five-year survival rates after primary resections are now in the range of 50-60% with the adjuvant use of oxaliplatin, irinotecan and targeted agents [11, 12]. In a more contemporary analysis, Adam et al. recently looked at a large cohort of 1439 consecutive patients treated at a single institution over an 11-year period. Survival was 33% at five years and 23% at ten years after secondary hepatic resections made possible by systemic chemotherapy, compared to 48% and 30% in primarily resected patients ($p=0.01$). The lower survival rates in patients who present with initially unresectable metastases are not surprising as these patients often have more aggressive

and/or widespread disease. Regardless, patients with secondary hepatic resections now have a good chance at long-term disease-free survival (17% at 10 years) [15].

There are no studies evaluating the optimal timing of surgery once unresectable colorectal liver metastases become resectable on neoadjuvant chemotherapy. However, current consensus recommends that surgery be scheduled as soon as liver metastases become resectable on follow-up imaging [48, 49]. The most compelling concern is that prolonged exposure to cytotoxic agents may injure the remnant liver, potentially increasing the risk of intraoperative and postoperative complications. The EORTC Intergroup 40983 study is the first prospective randomized trial to examine the extent and impact of hepatic injury after neoadjuvant chemotherapy for colorectal liver metastases. In this study, patients with potentially resectable metastases were randomized to receive six neoadjuvant cycles of FOLFOX-4 or undergo immediate surgical resection. Patients who received FOLFOX were significantly more likely to have sinusoidal lesions (48% vs. 11%, $p=0.0032$) and sinusoidal dilatation (41% vs. 0%, $p<0.0001$), but not at increased risk of steatosis (41% vs. 25%, $p=0.26$) or steatohepatitis (24% vs. 21%, $p=NS$), the latter two of which have been generally more associated with irinotecan. Liver damage did not appear to correlate with surgical complications or outcomes, although the authors note that the number of patients with surgical complications (7 of 57 patients) may have been too low to detect an association [50]. Importantly, this study did not address how long chemotherapy was discontinued prior to hepatic resection and whether this had an affect on liver toxicity. Furthermore, everyone in this trial received 6 cycles of neoadjuvant chemotherapy, so the affect of the duration of neoadjuvant chemotherapy can not be determined. Larger prospective studies are needed, as well as

investigation of the other chemotherapeutic and biologic agents. Since VEGF plays a role in wound healing, the timing of bevacizumab in particular has been a theoretical concern, although again, there is minimal data. Nevertheless, until more is known, it is recommended that bevacizumab be discontinued at least eight weeks prior to hepatic resection [35, 51].

While neoadjuvant chemotherapy has a clear role in enhancing resectability of liver metastases, its use is less established for patients who present with already resectable liver metastases. Without much evidence either way, some patients may be offered immediate surgical resection, while many others are first treated with neoadjuvant chemotherapy of varying regimens and duration. Comparative survival data is needed to establish a clear standard, and to perhaps determine whether any factors can predict which patients, if any, have better outcomes without neoadjuvant chemotherapy.

Only preliminary results are available for ongoing trials evaluating neoadjuvant chemotherapy for potentially resectable colorectal liver metastases. In 2006, the EORTC Intergroup provided interim results of their randomized phase III trial comparing immediate surgical resection only (no chemotherapy) to six cycles of FOLFOX-4 before and after surgery in 364 patients. Neoadjuvant chemotherapy led to a 30% decrease in size of metastatic lesions. Although more patients in the surgery-only arm made it to the operating room (95% vs. 88%), less of these patients were able to undergo complete resection (89% vs. 96%). As a result, there was no significant difference in overall resection rate (84% in both arms) [52]. Survival data should be available soon and will be crucial to understanding the impact of neoadjuvant chemotherapy. Unfortunately, however, it will be impossible to attribute any survival advantage to the neoadjuvant

chemotherapy alone, as postoperative chemotherapy probably also improves survival [53]. There are no studies to date which randomize patients with resectable liver metastases to receive only adjuvant chemotherapy or both neoadjuvant and adjuvant treatment.

There are several reasons why neoadjuvant chemotherapy is hypothesized to be beneficial even in patients with already resectable colorectal liver metastases. First, tumor reduction by neoadjuvant chemotherapy may allow for smaller, less difficult resections, thus helping to limit intraoperative complications and postoperative morbidity. Furthermore, systemic chemotherapy can treat invisible hepatic micrometastases as well as subclinical extrahepatic disease before these tumor foci have time to grow. Since patients with known hepatic metastases are at high risk of having disease elsewhere, in the liver especially, early systemic chemotherapy would therefore be expected to improve long-term survival. Second, patients often respond better to one regimen than another, although this is almost impossible to predict. It is also difficult to assess a regimen's efficacy in the adjuvant setting after lesions are surgically resected. A neoadjuvant course allows for in vivo assessment of anti-tumor activity and feasibility in terms of toxic effects. In turn, this information can help guide the selection of postoperative chemotherapy [51]. Finally, the response or lack of response to neoadjuvant chemotherapy may have prognostic value. Of 131 patients with at least four liver metastases in one series, 58 (44%) responded to neoadjuvant chemotherapy, 39 (30%) had stable disease, and 34 (26%) progressed. Five-year overall survival after hepatic resection was 37% in responders and 30% in patients with stable disease but only 8% in patients with progression on neoadjuvant chemotherapy ($p < 0.0001$) [54]. In

another retrospective analysis, 17 patients with progressive disease on neoadjuvant chemotherapy had significantly lower five-year disease specific survival than 29 patients who did not progress (38% vs. 87%, $p=0.03$) [55]. Since all patients in these two series underwent resection, it is unclear whether patients who progress on neoadjuvant chemotherapy still benefit enough from surgical resection to justify the risk of associated morbidity.

There are also several theoretical drawbacks to neoadjuvant chemotherapy for patients with resectable colorectal liver metastases. As discussed earlier, liver injury from cytotoxic neoadjuvant therapy is worrisome in patients undergoing hepatectomy, although this has not yet been shown to affect surgical morbidity and mortality. Another concern is that patients may progress to the point of unresectability while on preoperative chemotherapy and miss a window of opportunity for potentially curative resection. Fortunately, this has not been the case in the literature. All patients with resectable disease remained resectable in the two retrospective studies described above, even though progression while on neoadjuvant chemotherapy did lead to poorer outcomes after liver resection [54, 55]. In the prospective EORTC Intergroup 40983 study, preliminary results revealed that 7 of 182 patients randomized to receive neoadjuvant chemotherapy were not operated due to progression of disease, but this was similar to 5 of 182 patients in the surgery-only arm who also progressed to unresectability between randomization and surgery [52]. Frequent follow-up evaluation during neoadjuvant treatment and good communication between oncologists and surgeons during this critical time are probably important factors in maintaining resectable status.

Finally, although counterintuitive, another concern has been that patients may respond so well to chemotherapy that one or more colorectal liver metastases can not be found at the time of surgery but still harbor radiographically invisible tumor cells. Two small retrospective studies have addressed whether it is safe not to resect the sites of previously diagnosed liver metastases which become undetectable after neoadjuvant chemotherapy. In the first study, 9 of 38 patients (24%) with presumed complete response were found to have detectable macroscopic disease by inspection, palpation, or intraoperative ultrasound. Of the remaining 29 patients, the sites of original lesions were resected in 15 patients and found to harbor microscopic disease in 12 (80%). At one year of follow-up, disease recurred in situ in 11 of 14 patients (79%) who did not have resection of the original sites of metastases, although it is not stated whether these patients received adjuvant chemotherapy. In summary, 32 of 38 patients (84%) did not have true “cure” despite complete radiographic response to neoadjuvant chemotherapy [56]. In the second study, 7 of 15 patients (47%) with complete radiological response had macroscopic disease at surgery or postoperative recurrence in situ, while the remaining eight patients had no evidence of recurrence at a mean follow-up of three years [14]. Results were slightly better in the second series, but there is clearly a considerable risk of tumor recurrence when the sites of previously detectable metastases are left unresected. This has led to the recommendation that patients receiving neoadjuvant chemotherapy should be re-evaluated frequently and referred for resection before achieving complete radiographic response of metastatic lesions, so that all pre-treatment sites can be accurately localized and resected [15, 49]. Although this suggestion is reasonable given the evidence currently available, it is still possible that patients with

such highly responsive tumors may have better outcomes with uninterrupted chemotherapy, rather than having treatment suspended for at least several months in order to undergo surgical resection.

Neoadjuvant chemotherapy regimens for patients with colorectal liver metastases

While research has focused extensively on developing new therapeutic agents and increasing the resectability of hepatic colorectal metastases, there have been few studies comparing the efficacy of different treatment regimens prior to surgery. Thus, the optimal treatment regimen prior to resection of hepatic colorectal metastases remains unclear, as does the appropriate timing of treatment prior to surgery. Although results are pending for trials of neoadjuvant chemotherapy in patients with potentially resectable liver metastases [52], all currently available data comes from studies in patients with initially unresectable metastases. In these studies, the proportion of patients converted to resectable status is often used as an indication of therapeutic efficacy. As already discussed, definitions of resectability vary from one center to another, making a direct comparison of results more difficult. There are no randomized controlled trials to date comparing FOLFOX and FOLFIRI in the neoadjuvant setting, or comparing the efficacy of these regimens with and without targeted agents such as bevacizumab. At least one such phase III trial was closed early due to slow patient accrual [57].

The first landmark study demonstrating that neoadjuvant chemotherapy had the potential to downstage unresectable colorectal metastases was published by Bismuth and colleagues in 1996 [47]. This group continued to follow a large cohort of patients and reported updated results in 2001 [58] and most recently in 2004 [15]. As of 2004, 1104

patients initially considered unresectable had been treated with chemotherapy, mainly consisting of FOLFOX (70%), and another 335 patients with resectable disease had undergone primary resections. Of these, 138 patients (12.5%) were eventually able to undergo secondary hepatic resections of colorectal metastases, most of which (93%) were R0 resections. Long-term survival following secondary resection was realized, with 5- and 10-year survival rates at 33% and 22%, respectively, although these rates were higher in patients who underwent primary resections (48% and 30% respectively, $p=0.01$). At a mean follow-up of 49 months (range 1-127 months), 111 of 138 patients (80%) had relapsed, and median overall survival was 39 months. Preoperative factors associated with worse prognosis included rectal primary, more than two metastatic lesions, maximum tumor size $>10\text{cm}$, and CA 19-9 $>100\text{ IU/L}$ [15]. This study did not separate results according to neoadjuvant regimen, presumably because the majority of patients received FOLFOX, although this information would have been helpful.

In 1999, Giacchetti et al. performed a retrospective analysis of 151 patients with initially unresectable colorectal liver metastases who were treated with oxaliplatin and infusional 5-FU/LV. After a median 5.5 months of treatment, 77 patients underwent liver surgery with curative intent, and complete macroscopic resection was achieved in 58 of the original 151 patients (38%). Of these, 42 patients (72%) had recurrent disease and median time to progression was 12 months. Median overall survival had not been reached in the subset of 58 patients with complete macroscopic resections, although an estimated 5-years survival rate was 58% [46].

As part of Intergroup Study 9741, 795 patients with unresectable colorectal liver metastases were randomly assigned to receive IFL ($n=264$), FOLFOX4 ($n=267$), or

IROX (irinotecan and oxaliplatin, n=265). Curative resection was achieved in 24 patients. With a median postoperative follow-up of 34 months in this subset, median time to progression was 18.4 months with 17 patients relapsing and median overall survival was 42.4 months. Of the resected patients, 22 (92%) had received one of the oxaliplatin-containing regimens (11 in each of the FOLFOX4 and IROX arms), while only 2 patients were treated neoadjuvantly with IFL [59]. Although a direct comparison can not be made between IFL and FOLFOX4 because of the different 5-FU administration schedules, the increased efficacy of IROX over IFL can only be attributed to oxaliplatin.

The North Central Cancer Treatment Group also studied the efficacy of FOLFOX4 in patients with liver-only metastases that were considered unresectable. In this study, 14 of the 42 patients (33%) treated with FOLFOX4 were able to undergo complete R0 resection. At a median follow-up of 22 months, recurrence rate was similar to other studies with 10 patients (71%) having recurrent disease. Median time to recurrence was 19 months and median overall survival had not been reached for the subset of resected patients [60].

Two studies published in 2004 evaluated irinotecan-based regimens for treatment of unresectable colorectal liver metastases. In a phase II trial, 40 patients treated with FOLFIRI achieved a response rate of 48% and surgical resection was attempted in 16 patients (40%) who were downsized to the point of resectability. Of these, 13 patients underwent R0 resections. At a median follow-up of 19 months, all resected patients were still alive and median time to progression was 14.3 months (range 2 to 21 months), compared to 5.2 months in unresected patients [61]. The second looked retrospectively at

56 patients who were able to undergo liver resection after responding to treatment with irinotecan-based neoadjuvant chemotherapy. In this study, the majority of patients were treated with FOLFIRI (n=42), while 7 patients also received oxaliplatin and 5 patients were treated with irinotecan monotherapy. R0 resection was achieved in 42 patients (75%) and median overall survival was 42 months with tumor recurrence in 41 patients (73%) at a median follow-up of 23.1 months [62].

The most important disadvantage to neoadjuvant irinotecan has been its association with steatohepatitis. In a recent study of 406 patients who underwent hepatic metastectomy, Vauthey and colleagues demonstrated that 20% of patients who received neoadjuvant irinotecan had steatohepatitis compared to only 6% in patients with prior oxaliplatin exposure (odds ratio 3.7; 95% CI 1.3 to 10.5, p=0.02). Unfortunately, 90-day mortality rates were significantly higher in patients with steatohepatitis compared to patients who did not have steatohepatitis (14.7% vs. 1.6%, odds ratio 10.5, 95% CI 2.0 to 36.4, p=0.001). In contrast, although oxaliplatin was associated with sinusoidal injury, there was no increased morbidity or mortality when compared to patients who did not receive any neoadjuvant chemotherapy [63].

The only study to randomize patients with unresectable colorectal liver metastases to either FOLFOX6 or FOLFIRI was published in 2004 by Tournigand and colleagues. In this study, patients randomized to the first arm (n=109) received FOLFIRI until either disease progression or prohibitive toxicity, at which point patients were switched to FOLFOX. Patients randomized to the second arm (n=111) received the opposite sequence. Response rates were similar; FOLFIRI as first line therapy resulted in response rates of 56% with median progression free survival of 8.5 months, which

compared with 54% and 8.0 months when FOLFOX was given first line. Interestingly, however, secondary resection was able to be performed in 9% of patients (n=10) after just first-line FOLFIRI (mean 12 cycles) compared to 22% of patients (n=24) treated with FOLFOX (mean 10 cycles). This difference was statistically significant (p=0.02), suggesting that FOLFOX may have better efficacy in the neoadjuvant setting. The proportion of R0 resections did not reach statistical significance, however, with 8 patients in the FOLFIRI arm and 14 in the FOLFOX arm able to undergo R0 resections (p=0.26). Only three patients were able to undergo surgical resection after second-line therapy (two after receiving FOLFOX second-line, and one after receiving FOLFIRI second-line) [34].

Finally, several studies have assessed the efficacy of FOLFOXIRI in downstaging unresectable colorectal liver metastases to the point of resectability. In one phase III trial, 9 of 137 patients randomized to FOLFOXIRI were able to undergo secondary R0 resection of liver metastases, compared to just 2 of 146 patients in the FOLFIRI arm [36]. A similar phase III trial of 244 patients reported that 14% of patients randomized to receive FOLFOXIRI were able to undergo R0 secondary resection, compared to 6% in the FOLFIRI arm (p=0.05) [64]. The same group reported a median overall survival of 36.8 months in a subset of 19 of 74 patients (26%) who were able to undergo curative secondary resection after treatment with FOLFOXIRI [65]. Of 24 patients treated with FOLFOXIRI in another study, 9 (37.5%) underwent R0 secondary resections [66].

Studies are underway to evaluate the safety and efficacy of bevacizumab as part of neoadjuvant treatment for colorectal liver metastases. The ongoing First BEAT trial enrolled 1927 patients with metastatic colorectal cancer, in which all patients were treated with bevacizumab in combination with FOLFOX (28%), FOLFIRI (26%),

XELOX (17%), or other (29%). At the time of report, 81 patients were able to undergo metastectomy (34 after FOLFOX + bevacizumab, 19 after FOLFIRI + bevacizumab, 20 after XELOX + bevacizumab). Bevacizumab was stopped 6-8 weeks (two half-lives) prior to surgery and only one patient had wound healing complications which were not described in detail and another patient had intra-operative bleeding. Long-term survival data is not yet available [67, 68]. In a retrospective study assessing surgical complication rates in patients treated with neoadjuvant bevacizumab, the use of bevacizumab did not increase wound healing complications (28% vs. 24% in patients not treated with neoadjuvant bevacizumab, $p=0.66$), and the interval from bevacizumab to surgery also did not affect wound healing complications ($p=0.71$) [69]. Although it has been shown that bevacizumab increases response rates and survival in combination with IFL [37] or FOLFOX [38], neither study provided results for subsequent resection rate.

In summary, while new treatments for metastatic colorectal cancer continue to be developed, the ideal neoadjuvant regimen prior to resection of liver metastases is still unknown. The best neoadjuvant regimen should combine a high response rate with the lowest peri-operative complication rate. Some evidence supports the use of oxaliplatin-based regimens over those containing irinotecan, although completed randomized studies are lacking. Treatment with irinotecan has been shown to have increased incidence of steatohepatitis with associated operative morbidity, making oxaliplatin a more attractive choice in the neoadjuvant setting. Bevacizumab has also shown promise in the neoadjuvant setting, although many surgeons are still cautious due to the theoretical risk of wound-healing complications. The use of neoadjuvant chemotherapy in the setting of initially resectable metastases is even less established.

PURPOSE, HYPOTHESIS AND SPECIFIC AIMS

In light of this uncertainty, the present study was designed to determine which neoadjuvant chemotherapy regimens, specifically oxaliplatin-based vs. irinotecan-based, led to most successful outcomes after resection of colorectal liver metastases at Yale-New Haven Hospital in recent years. I hypothesized that oxaliplatin-based neoadjuvant chemotherapy would lead to better disease-free survival after surgical resection of colorectal liver metastases.

The primary aim for this study was to determine which neoadjuvant chemotherapy regimens lead to most successful resection of colorectal cancer metastases to the liver, measured in terms of disease-free survival outcomes. The secondary aim was to determine whether any of the following factors were associated with disease recurrence: primary tumor site, timing of liver metastases, number of liver metastases, neoadjuvant chemotherapy regimen, use of targeted biological agents, treatment duration, treatment response, time from chemotherapy to liver resection and treatment with adjuvant chemotherapy.

METHODS

A retrospective chart review was performed of all patients who underwent liver resection of colorectal cancer metastases at Yale-New Haven Hospital between January 2003 and December 2005. January 2004 was initially chosen as the starting date for this study, as this was the date FOLFOX was approved for first-line treatment of metastatic colorectal cancer. However, this resulted in too few patients for analysis, so inclusion was expanded to January 2003. No patients were excluded from the study. All liver

resections were performed by the same hepatobiliary surgeon. Patient records were evaluated for patient characteristics (age, sex, race), initial diagnosis (location, histology, stage, lymph node involvement, vascular invasion, metastases, tumor marker levels), initial treatment (adjuvant chemotherapy, radiation), recurrence / metastases (location, sites, number and location in liver, lymph node involvement), treatment regimen(s) prior to resection of hepatic metastases, results of surgical liver resection (complete or partial resection, histopathology), adjuvant treatment after liver resection and post-operative disease recurrence and survival. This retrospective study was approved by the Yale Humans Investigation Committee.

Synchronous metastases were defined as metastases diagnosed before or at the same time as the primary cancer, or within 6 months of diagnosis of the primary cancer. Radiographic response was categorized according to Response Evaluation Criteria in Solid Tumors (RECIST) guidelines. R0 resection was defined as complete tumor removal including negative histological removals, R1 resection was defined as positive microscopic margins, and R2 resection was defined as positive gross margins. All patients were taken to the operating room with curative intent with the goal of R0 resection.

All statistical analysis was performed with MedCalc software version 9.3.0 (MedCalc Software, Mariakerke, Belgium). Calculations of median disease-free survival and actuarial 3-year disease-free survival rates were based on survival curves drawn according to Kaplan-Meier methods. The log-rank test was used to compare the survival curves of four neoadjuvant treatment groups. Trends in neoadjuvant treatment choices over time were assessed using Chi-squared analysis.

Table 2. All patients with liver resection of colorectal metastases at YNHH 2003 – 2005

Patient	Primary	Number of liver mets	Timing of liver mets	Neoadjuvant Regimen	Resection	Follow-up (months)	Outcome
1	Junctional	1	Metachronous	None	R0	<4	
2	Colon	1	Metachronous	None	R0	<4	
3	Colon	1	Synchronous	FOLFOX	R0	34.6	Disease-free
4	Colon	1	Metachronous	None	R0	16.5	Recurrence
5	Rectal	2	Metachronous	FOLFIRI	R0	44.4	Recurrence
6	Colon	3	Synchronous	FOLFOX	R0	40.7	Disease-free
7	Rectal	2	Synchronous	IFL	R0	26.3	Recurrence
8	Colon	1	Metachronous	None	R0	34.9	Disease-free
9	Colon	2	Synchronous	FOLFOX	R2	<4	
10	Rectal	3	Synchronous	5-FU with radiotherapy	R0	<4	
11	Colon	2	Synchronous	FOLFOX	R0	21.5	Recurrence
12	Colon	1	Metachronous	None	R0	31.1	Disease-free
13	Rectal	1	Synchronous	Xeloda and Irinotecan	R0	<4	
14	Rectal	1	Synchronous	FOLFOX and Bevacizumab	R0, pCR	30.4	Recurrence
15	Rectal	3	Metachronous	FOLFOX	R0	<4	
16	Colon	2	Synchronous	FOLFIRI	R0	<4	
17	Colon	5	Metachronous	FOLFOX	R0	25.0	Recurrence
18	Junctional	1	Synchronous	FOLFOX → FOLFIRI	R0	24.6	Recurrence
19	Colon	2	Metachronous	FOLFOX → FOLFIRI	R0	20.7	Disease-free
20	Colon	1	Synchronous	FOLFIRI	R0	<4	
21	Colon	1	Synchronous	FOLFOX and Cetuximab → FOLFIRI and Bevacizumab	R0	12.5	Recurrence, deceased
22	Colon	1	Metachronous	FOLFIRI	R0	16.8	Disease-free
23	Colon	1	Synchronous	FOLFOX	R0	<4	
24	Rectal	1	Metachronous	None	R0	<4	Postop mortality
25	Colon	1	Metachronous	FOLFOX and Bevacizumab	R0, pCR	<4	
26	Rectal	1	Metachronous	FOLFOX and Bevacizumab	R0	<4	
27	Colon	3	Synchronous	FOLFOX and Bevacizumab	R0	13.8	Recurrence

R0 resection = complete removal of tumor with negative histological margins, R2 resection = grossly incomplete removal of tumor, pCR = complete pathological response (no evidence of viable tumor cells)

RESULTS

Twenty-seven patients underwent resection of colorectal liver metastases at Yale-New Haven Hospital between January 2003 and December 2005 (Table 2). The mean age of patients at the time of liver resection was 56.9 years (range 38 to 76 years), and the majority of patients (17, 63%) were male. Most patients had colon adenocarcinoma primary lesions (17, 63%), although 8 patients had rectal primaries and 2 had junctional primaries. About half of the patients (14, 52%) presented with synchronous liver metastases. Of the 13 patients with metachronous liver metastases, all had been treated with adjuvant chemotherapy after resection of the primary tumor, except for the two

patients with Stage II disease. Median time from diagnosis of colorectal primary to resection of liver metastases was 9.6 months in patients with synchronous metastases (range 4 to 31 months), 27.6 months in patients with metachronous metastases (range 9 months to 7 years), and 19.2 months in all patients. Sixteen patients presented with only one metastatic focus in the liver, and the rest had either two or three foci on imaging except for one patient with five. None of the patients had known extrahepatic metastases.

Almost all patients in this study had resectable colorectal liver metastases at the time of initial presentation. Only patient #14, with a single liver metastasis impinging on the right and middle hepatic veins as well as the main portal vein, was considered unresectable at initial presentation. This patient was rendered resectable after a complete radiologic and ultimately histologic response to neoadjuvant FOLFOX and bevacizumab.

Neoadjuvant chemotherapy regimens varied from patient to patient. Six patients did not receive any neoadjuvant chemotherapy; each of these six patients had a single metachronous metastatic lesion in the liver and one patient had been offered neoadjuvant FOLFOX but refused. One patient (patient #10), diagnosed with three liver metastases on postoperative imaging immediately after abdomino-perineal resection of a rectal primary, was treated with adjuvant 5-FU as a chemosensitizer for local radiotherapy. This patient received no other systemic chemotherapy and was therefore categorized as not receiving any neoadjuvant treatment for this analysis.

The most common neoadjuvant regimen was FOLFOX, given as first-line neoadjuvant chemotherapy to 14 patients. Four of these patients were treated with FOLFOX in combination with bevacizumab. Of the 14 patients initially treated with FOLFOX, 10 patients experienced a partial response (71%, included all 4 patients

receiving bevacizumab), one patient had stable disease, two patients had progressive disease and were switched to FOLFIRI (patient #19 and patient #21), and another patient was switched to FOLFIRI because of an allergic reaction (patient #18). The 11 patients treated only with first-line neoadjuvant FOLFOX received an average of 9 cycles prior to liver resection (range 5 to 14 cycles).

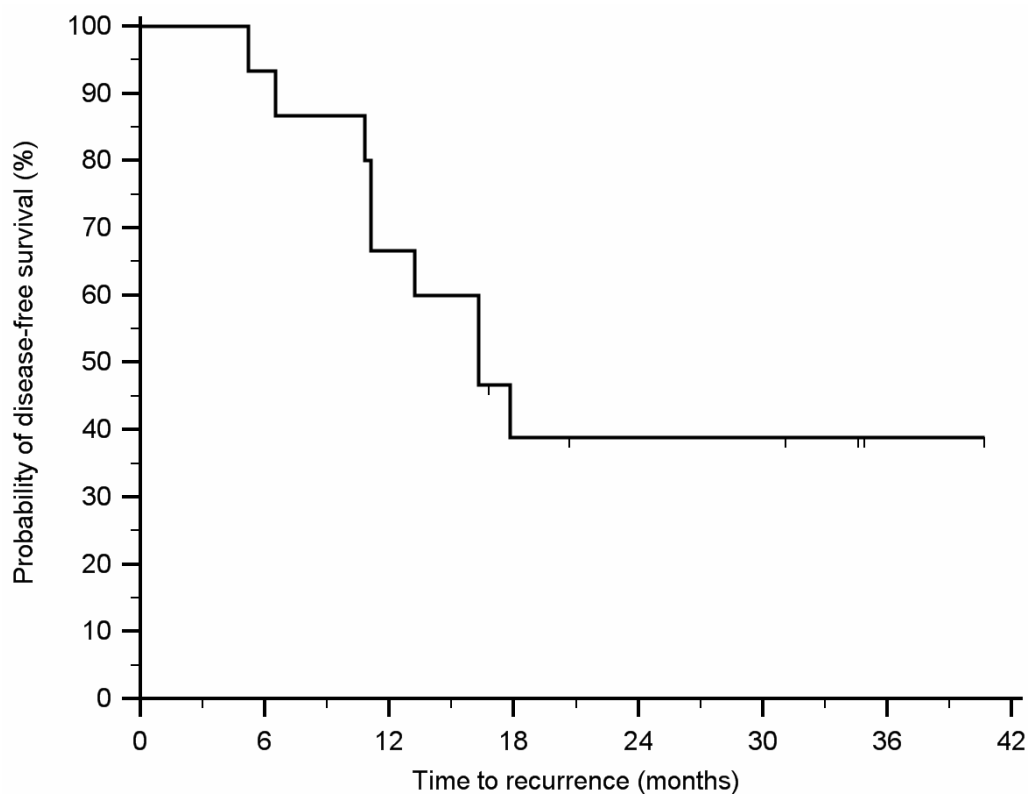
The remaining six patients were all treated with first-line irinotecan-based regimens. Four patients received an average of 8 cycles of FOLFIRI (range 3 to 12 cycles), one patient received several cycles of IFL, and another was treated with ten months of irinotecan in combination with capecitabine (Xeloda). One patient (patient #22) had progressive disease after a 6-week course of FOLFIRI, so chemotherapy was discontinued and the patient was referred for liver resection. Two other patients had stable disease: one after FOLFIRI and the other after irinotecan in combination with capecitabine. Information on the clinical response to treatment was not available for the other three patients treated with irinotecan-based first-line regimens.

During the three years studied, 2003 through 2005, there were some trends in the use of neoadjuvant chemotherapy in patients who underwent liver resection of colorectal metastases. In 2003, of 8 patients who underwent liver resection, all with initially resectable disease, only half received neoadjuvant chemotherapy (2 with FOLFOX, 1 with FOLFIRI and 1 with IFL) while the other half had immediate liver resection. By 2005, of 11 patients who underwent liver resection for initially resectable colorectal metastases, only one patient did not receive neoadjuvant chemotherapy. Eight of the remaining 10 patients (80%) who underwent liver resection in 2005 were treated with neoadjuvant FOLFOX first-line, compared to just 2 patients (20%) treated with first-line

FOLFIRI. This trend did not reach statistical significance, however ($p=0.08$ by Chi-squared analysis).

All patients underwent R0 resections, except for patient #9, who underwent R2 resection with gross positive margins after right hepatic trisegmentectomy (liver segments 4,5,6,7,8). Two patients, both treated with combination FOLFOX and bevacizumab, had complete histological response with no viable tumor cells seen on histology. One patient (patient #24) died on post-operative day 33 after hemoperitoneum from splenic capsule tear during hepatectomy. This patient did not receive any neoadjuvant chemotherapy or targeted treatment. There were no other incidents of post-operative mortality; thus, the overall mortality rate in this study group of 27 patients was 3.7%

Figure 1. Kaplan-Meier disease-free survival curve for all patients with >1 year of follow-up after hepatic resection of colorectal metastases (n=15)



Outcome data (>1 year) could be obtained for 15 of the 26 patients who survived hepatic resection. Of the 11 patients lost to follow-up, two had moved out-of-state, and nine had local private oncologists who could not be reached for follow-up data. At a median follow-up of 25.0 months (range 13 to 44 months), 6 of 15 patients (40%) had no evidence of recurrent disease while 9 patients (60%) had relapsed. Median time to recurrence was 11.1 months (range 5 to 17 months). Five patients (33%) had recurrent disease in the liver (three of whom also had extra-hepatic disease), two patients (13%) had lung metastases, and two patients (13%) had anastomotic recurrence in the colon. The Kaplan-Meier disease-free survival curve for all 15 patients with follow-up data is shown in Figure 1. Median disease-free survival was 16.3 months, actual 1-year disease-free survival was 67% and actuarial 3-year disease-free survival was 39%. One patient with extensive disease recurrence in the liver, lungs and retroperitoneum died 12 months after liver resection. The other 14 patients were alive at most recent follow-up; therefore, the overall actual 1-year survival rate for patients with outcome data was 93%.

Table 3. Outcome data by neoadjuvant chemotherapy regimen

	All patients with follow-up > 1 year	FOLFOX	FOLFOX 1 st line → FOLFIRI 2 nd line	Irinotecan- based*	None
<i>n</i>	15	6	3	3	3
Mean treatment duration, months	6.3	5.1	12.0	3.2	n/a
Mean chemo to resection time, days	46.3	50.3	45.3	39.3	n/a
Bevacizumab, <i>n</i> (%)	3 (20)	2 (33)	1 (33)	0 (0)	n/a
Adjuvant chemotherapy, <i>n</i> (%)	12 (80)	6 (100)	2 (67)	3 (100)	1 (33)
Median disease-free survival, months [†]	16.3	15.5	16.3	16.3	not reached
Median time to recurrence, months (<i>n</i>)	11.1 (9)	12.2 (4)	11.4 (2)	10.8 (2)	11.1 (1)
Actual 1-year disease-free survival, % ±SE	67 ±12	67 ±19	67 ±27	67 ±27	67 ±27
Actuarial 3-year disease-free survival, % ±SE	39 ±13	33 ±19	33 ±27	33 ±27	67 ±27

SE = standard error

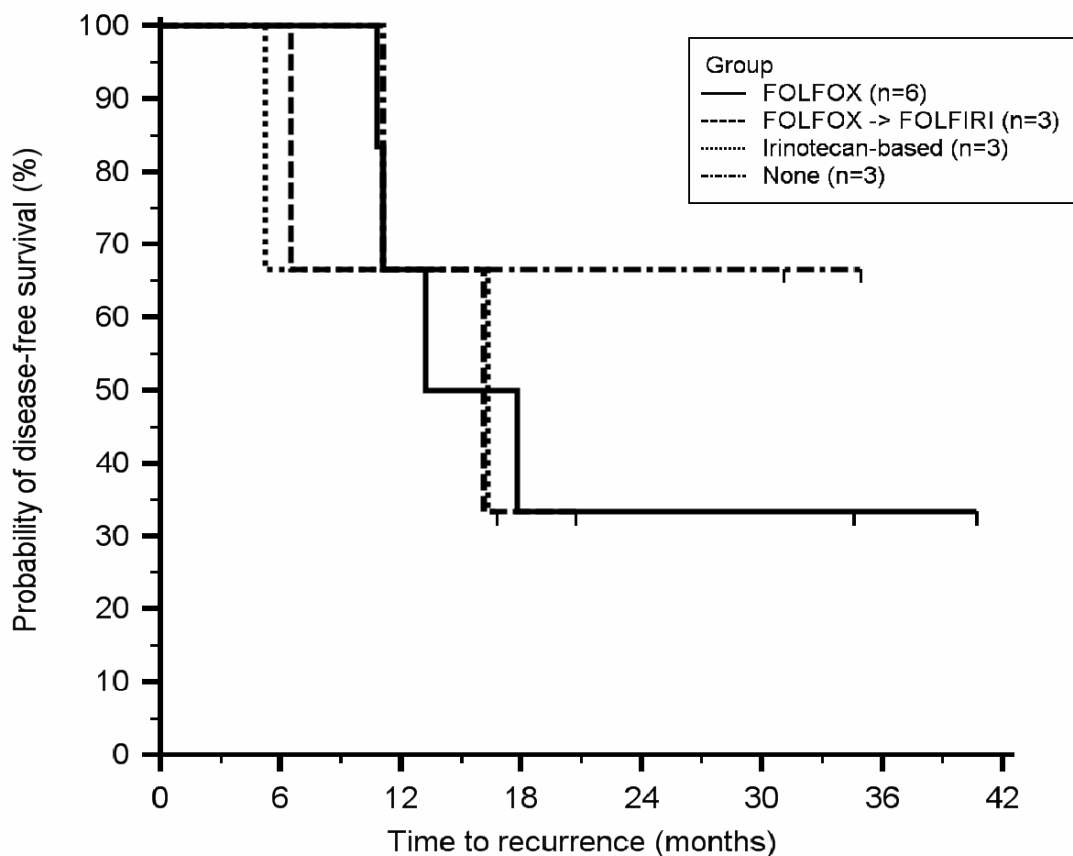
*2 patients received FOLFIRI and 1 patient received IFL

[†]p=0.84 by the log-rank test for comparison between the four treatment groups

Outcome data for each type of neoadjuvant chemotherapy regimen is presented in Table 3. Out of the 15 patients with follow-up, six were treated with neoadjuvant FOLFOX prior to liver resection, three with first-line FOLFOX followed by second-line FOLFIRI, two with FOLFIRI, one with IFL, and three patients had no neoadjuvant chemotherapy. The Kaplan-Meier disease-free survival curves according to neoadjuvant treatment group are shown in Figure 2. Median disease-free survival was 15.5 months in patients treated with neoadjuvant FOLFOX, 16.3 months in patients treated with first-line FOLFOX followed by second-line FOLFIRI, also 16.3 months in patients treated with irinotecan-based neoadjuvant therapy, and was not reached in the group who did not receive any neoadjuvant treatment ($p=0.84$ by log-rank test). Actual 1-year disease-free survival rate was 67% regardless of neoadjuvant treatment group. Median time to recurrence after liver resection was 12.2 months in patients treated with FOLFOX (10, 11, 13 and 17 months), 11.4 months in patients treated with first-line FOLFOX followed by second-line FOLFIRI (6 and 16 months), 5 months in the patient who relapsed after FOLFIRI, 16 months in the patient who relapsed after IFL, and 11 months in the patient who relapsed after no neoadjuvant chemotherapy.

The sample size was too small to determine which factors were associated with disease recurrence. Out of the 15 patients with follow-up, all three patients treated with bevacizumab had recurrent disease (Table 2). Otherwise, the study lacked the statistical power to detect whether outcome was associated with primary tumor site, timing of liver metastases, number of liver metastases, neoadjuvant chemotherapy regimen, treatment duration, treatment response, time from chemotherapy to liver resection, or treatment with adjuvant chemotherapy.

Figure 2. Kaplan-Meier estimates of disease-free survival according to neoadjuvant chemotherapy regimen



DISCUSSION

This retrospective study compares the efficacy of oxaliplatin- and irinotecan-based neoadjuvant chemotherapy regimens in patients who underwent liver resection of colorectal metastases at Yale-New Haven Hospital between 2003 and 2005. Only patients who underwent liver resection were included. Patients who never achieved resectable status despite systemic chemotherapy were not accounted for in this study.

Therefore, almost all patients in the present study had resectable disease at initial presentation. This is in contrast to the currently available literature, which almost exclusively focuses on neoadjuvant chemotherapy for unresectable liver metastases.

The majority of patients undergoing liver resection of colorectal metastases at Yale-New Haven Hospital in recent years were treated with neoadjuvant FOLFOX. This may either represent the local preferences of medical oncologists or be a reflection of the literature, which has shown a bias towards neoadjuvant FOLFOX over irinotecan-based regimens. This bias is supported by the observation that neoadjuvant irinotecan has been associated with steatohepatitis and increased surgical morbidity and mortality [63]. Chemotherapy-induced liver toxicity was not noted in the present study, although the sample size was small.

Also notable was the evolving trend towards the use of neoadjuvant chemotherapy in patients with already resectable colorectal liver metastases. The percentage of these patients receiving neoadjuvant chemotherapy increased from 50% in 2003 to 87% by 2005, perhaps associated with the increased availability of FOLFOX and FOLFIRI after 2003. As there are still no clear recommendations for the use of neoadjuvant chemotherapy in patients with resectable disease, it would be interesting to know whether this is a more widespread trend. Prospective studies are needed to establish clear recommendations. Survival data should be available soon from the EORTC Intergroup study, a randomized phase III trial comparing immediate surgical resection to neoadjuvant and adjuvant FOLFOX [52].

Unfortunately, there were not enough patients in the study to adequately compare oxaliplatin- and irinotecan-based neoadjuvant chemotherapy regimens for patients

undergoing resection of colorectal liver metastases. With outcome data on 15 patients, disease recurrence, time to recurrence, and one-year disease-free survival was almost identical among patients receiving FOLFOX, irinotecan-based regimens, or first-line FOLFOX followed by second-line FOLFIRI. Although all three patients with follow-up data who received bevacizumab eventually had recurrent disease, this is unlikely to be a real finding given the low patient number. This study also lacked the statistical power to determine which patient, tumor, and treatment factors were associated with recurrence of disease.

As with any retrospective study, there are some drawbacks to this study design. Many biases can be introduced when treatment providers, patients and the person collecting data know which treatment regimen is being used. Furthermore, follow-up data could not be obtained for all patients. This study only emphasizes the need for prospective trials comparing oxaliplatin- and irinotecan-based neoadjuvant chemotherapy regimens for patients with either resectable or unresectable colorectal hepatic metastases. Future translational research should also focus on determining whether tumor molecular profiling can be used to more accurately tailor treatment decisions to each individual patient.

REFERENCES

1. *Colorectal Cancer*. Available from: American Cancer Society, <http://www.cancer.org/downloads/PRO/ColorectalCancer.pdf>. [Accessed: Jan 20, 2007].
2. *Colorectal Cancer Facts & Figures 2005*. Available from: American Cancer Society, http://www.cancer.org/docroot/MED/content/MED_2_1x_Colorectal_Cancer_Facts__Figures_2005.asp. [Accessed: Jan 20, 2007].

3. Kemeny, N. and Fata, F. 1999. Arterial, portal, or systemic chemotherapy for patients with hepatic metastasis of colorectal carcinoma. *J Hepatobiliary Pancreat Surg.* **6**(1): 39-49.
4. Scheele, J., Stangl, R., and Altendorf-Hofmann, A. 1990. Hepatic metastases from colorectal carcinoma: impact of surgical resection on the natural history. *Br J Surg.* **77**(11): 1241-1246.
5. Scheele, J., Stang, R., Altendorf-Hofmann, A., and Paul, M. 1995. Resection of colorectal liver metastases. *World J Surg.* **19**(1): 59-71.
6. Kato, T., Yasui, K., Hirai, T., Kanemitsu, Y., Mori, T., et al. 2003. Therapeutic results for hepatic metastasis of colorectal cancer with special reference to effectiveness of hepatectomy: analysis of prognostic factors for 763 cases recorded at 18 institutions. *Dis Colon Rectum.* **46**(10 Suppl): S22-31.
7. Manfredi, S., Lepage, C., Hatem, C., Coatmeur, O., Faivre, J., et al. 2006. Epidemiology and management of liver metastases from colorectal cancer. *Ann Surg.* **244**(2): 254-259.
8. Nordlinger, B., Guiguet, M., Vaillant, J.C., Balladur, P., Boudjema, K., et al. 1996. Surgical resection of colorectal carcinoma metastases to the liver. A prognostic scoring system to improve case selection, based on 1568 patients. Association Francaise de Chirurgie. *Cancer.* **77**(7): 1254-1262.
9. Fong, Y., Fortner, J., Sun, R.L., Brennan, M.F., and Blumgart, L.H. 1999. Clinical score for predicting recurrence after hepatic resection for metastatic colorectal cancer: analysis of 1001 consecutive cases. *Ann Surg.* **230**(3): 309-318; discussion 318-321.
10. Figueras, J., Valls, C., Rafecas, A., Fabregat, J., Ramos, E., et al. 2001. Resection rate and effect of postoperative chemotherapy on survival after surgery for colorectal liver metastases. *Br J Surg.* **88**(7): 980-985.
11. Abdalla, E.K., Vauthey, J.N., Ellis, L.M., Ellis, V., Pollock, R., et al. 2004. Recurrence and outcomes following hepatic resection, radiofrequency ablation, and combined resection/ablation for colorectal liver metastases. *Ann Surg.* **239**(6): 818-825; discussion 825-817.
12. Fernandez, F.G., Drebin, J.A., Linehan, D.C., Dehdashti, F., Siegel, B.A., et al. 2004. Five-year survival after resection of hepatic metastases from colorectal cancer in patients screened by positron emission tomography with F-18 fluorodeoxyglucose (FDG-PET). *Ann Surg.* **240**(3): 438-447; discussion 447-450.

13. Folprecht, G., Grothey, A., Alberts, S., Raab, H.R., and Kohne, C.H. 2005. Neoadjuvant treatment of unresectable colorectal liver metastases: correlation between tumour response and resection rates. *Ann Oncol.* **16**(8): 1311-1319.
14. Elias, D., Youssef, O., Sideris, L., Dromain, C., Baton, O., et al. 2004. Evolution of missing colorectal liver metastases following inductive chemotherapy and hepatectomy. *J Surg Oncol.* **86**(1): 4-9.
15. Adam, R., Delvart, V., Pascal, G., Valeanu, A., Castaing, D., et al. 2004. Rescue surgery for unresectable colorectal liver metastases downstaged by chemotherapy: a model to predict long-term survival. *Ann Surg.* **240**(4): 644-657; discussion 657-648.
16. Ekberg, H., Tranberg, K.G., Andersson, R., Lundstedt, C., Hagerstrand, I., et al. 1986. Determinants of survival in liver resection for colorectal secondaries. *Br J Surg.* **73**(9): 727-731.
17. Hughes, K.S., Simon, R., Songhorabodi, S., Adson, M.A., Ilstrup, D.M., et al. 1986. Resection of the liver for colorectal carcinoma metastases: a multi-institutional study of patterns of recurrence. *Surgery.* **100**(2): 278-284.
18. Kornprat, P., Jarnagin, W.R., Gonen, M., Dematteo, R.P., Fong, Y., et al. 2007. Outcome after hepatectomy for multiple (four or more) colorectal metastases in the era of effective chemotherapy. *Ann Surg Oncol.* **14**(3): 1151-1160.
19. Elias, D., Ouellet, J.F., Bellon, N., Pignon, J.P., Pocard, M., et al. 2003. Extrahepatic disease does not contraindicate hepatectomy for colorectal liver metastases. *Br J Surg.* **90**(5): 567-574.
20. Charnsangavej, C., Clary, B., Fong, Y., Grothey, A., Pawlik, T.M., et al. 2006. Selection of patients for resection of hepatic colorectal metastases: expert consensus statement. *Ann Surg Oncol.* **13**(10): 1261-1268.
21. Walsh, L. and Poston, G. 2002. The potential to increase curative liver resection rates in metastatic colorectal cancer. *Eur J Surg Oncol.* **28**(8): 812-814.
22. Hamady, Z.Z., Malik, H.Z., Finch, R., Adair, R., Al-Mukhtar, A., et al. 2006. Hepatic resection for colorectal metastasis: impact of tumour size. *Ann Surg Oncol.* **13**(11): 1493-1499.
23. Poston, G.J., Adam, R., Alberts, S., Curley, S., Figueras, J., et al. 2005. OncoSurge: a strategy for improving resectability with curative intent in metastatic colorectal cancer. *J Clin Oncol.* **23**(28): 7125-7134.
24. Isacoff, W.H. and Borud, K. 1997. Chemotherapy for the treatment of patients with metastatic colorectal cancer: an overview. *World J Surg.* **21**(7): 748-762.

25. 1998. Efficacy of intravenous continuous infusion of fluorouracil compared with bolus administration in advanced colorectal cancer. Meta-analysis Group In Cancer. *J Clin Oncol.* **16**(1): 301-308.
26. Twelves, C.J. 2006. Xeloda in Adjuvant Colon Cancer Therapy (X-ACT) trial: overview of efficacy, safety, and cost-effectiveness. *Clin Colorectal Cancer.* **6**(4): 278-287.
27. de Gramont, A., Figuer, A., Seymour, M., Homerin, M., Hmissi, A., et al. 2000. Leucovorin and fluorouracil with or without oxaliplatin as first-line treatment in advanced colorectal cancer. *J Clin Oncol.* **18**(16): 2938-2947.
28. Andre, T., Boni, C., Mounedji-Boudiaf, L., Navarro, M., Tabernero, J., et al. 2004. Oxaliplatin, fluorouracil, and leucovorin as adjuvant treatment for colon cancer. *N Engl J Med.* **350**(23): 2343-2351.
29. Saltz, L.B., Cox, J.V., Blanke, C., Rosen, L.S., Fehrenbacher, L., et al. 2000. Irinotecan plus fluorouracil and leucovorin for metastatic colorectal cancer. Irinotecan Study Group. *N Engl J Med.* **343**(13): 905-914.
30. Douillard, J.Y., Cunningham, D., Roth, A.D., Navarro, M., James, R.D., et al. 2000. Irinotecan combined with fluorouracil compared with fluorouracil alone as first-line treatment for metastatic colorectal cancer: a multicentre randomised trial. *Lancet.* **355**(9209): 1041-1047.
31. Goldberg, R.M., Sargent, D.J., Morton, R.F., Fuchs, C.S., Ramanathan, R.K., et al. 2004. A randomized controlled trial of fluorouracil plus leucovorin, irinotecan, and oxaliplatin combinations in patients with previously untreated metastatic colorectal cancer. *J Clin Oncol.* **22**(1): 23-30.
32. Colucci, G., Gebbia, V., Paoletti, G., Giuliani, F., Caruso, M., et al. 2005. Phase III randomized trial of FOLFIRI versus FOLFOX4 in the treatment of advanced colorectal cancer: a multicenter study of the Gruppo Oncologico Dell'Italia Meridionale. *J Clin Oncol.* **23**(22): 4866-4875.
33. Kalofonos, H.P., Aravantinos, G., Kosmidis, P., Papakostas, P., Economopoulos, T., et al. 2005. Irinotecan or oxaliplatin combined with leucovorin and 5-fluorouracil as first-line treatment in advanced colorectal cancer: a multicenter, randomized, phase II study. *Ann Oncol.* **16**(6): 869-877.
34. Tournigand, C., Andre, T., Achille, E., Lledo, G., Flesh, M., et al. 2004. FOLFIRI followed by FOLFOX6 or the reverse sequence in advanced colorectal cancer: a randomized GERCOR study. *J Clin Oncol.* **22**(2): 229-237.

35. Bartlett, D.L., Berlin, J., Lauwers, G.Y., Messersmith, W.A., Petrelli, N.J., et al. 2006. Chemotherapy and regional therapy of hepatic colorectal metastases: expert consensus statement. *Ann Surg Oncol*. **13**(10): 1284-1292.
36. Souglakos, J., Androulakis, N., Syrigos, K., Polyzos, A., Ziras, N., et al. 2006. FOLFOXIRI (folinic acid, 5-fluorouracil, oxaliplatin and irinotecan) vs FOLFIRI (folinic acid, 5-fluorouracil and irinotecan) as first-line treatment in metastatic colorectal cancer (MCC): a multicentre randomised phase III trial from the Hellenic Oncology Research Group (HORG). *Br J Cancer*. **94**(6): 798-805.
37. Hurwitz, H., Fehrenbacher, L., Novotny, W., Cartwright, T., Hainsworth, J., et al. 2004. Bevacizumab plus irinotecan, fluorouracil, and leucovorin for metastatic colorectal cancer. *N Engl J Med*. **350**(23): 2335-2342.
38. Giantonio, B., Catalano, P., Meropol, N., Mitchell, E., MA, S., et al. 2005. High-dose bevacizumab in combination with FOLFOX4 improves survival in patients with previously treated advanced colorectal cancer: Results from the Eastern Cooperative Oncology Group (ECOG) study E3200. *J Clin Oncol*. **23**(16S): abstr 2.
39. Cunningham, D., Humblet, Y., Siena, S., Khayat, D., Bleiberg, H., et al. 2004. Cetuximab monotherapy and cetuximab plus irinotecan in irinotecan-refractory metastatic colorectal cancer. *N Engl J Med*. **351**(4): 337-345.
40. Saltz, L.B., Meropol, N.J., Loehrer, P.J., Sr., Needle, M.N., Kopit, J., et al. 2004. Phase II trial of cetuximab in patients with refractory colorectal cancer that expresses the epidermal growth factor receptor. *J Clin Oncol*. **22**(7): 1201-1208.
41. Tabernero, J., Van Cutsem, E., Sastre, J., Cervantes, A., Van Laethem, J.-L., et al. 2004. An international phase II study of cetuximab in combination with oxaliplatin/5-fluorouracil (5-FU)/folinic acid (FA) (FOLFOX-4) in the first-line treatment of patients with metastatic colorectal cancer (CRC) expressing Epidermal Growth Factor Receptor (EGFR). Preliminary results. *J Clin Oncol*. **22**(14S): abstr 3512.
42. Lutz, M.P., Schöffski, P., Folprecht, G., Haag, C., Seufferlein, T., et al. 2002. A phase I/II study of cetuximab (C225) plus irinotecan (CPT-11) and 24h infusional 5FU/folinic acid (FA) in the treatment of metastatic colorectal cancer (MCRC) expressing the epidermal growth factor receptor (EGFR). *Ann Oncol*. **13**(Suppl 5): 73.
43. Peeters, M., Van Cutsem, E., Siena, S., Humblet, Y., Hendlisz, A., et al. 2006. A phase 3, multicenter, randomized controlled trial (RCT) of panitumumab plus best supportive care (BSC) vs BSC alone in patients (pts) with metastatic colorectal cancer (mCRC). *Proc Amer Assoc Cancer Res*. April 2006: abstr CP-1.

44. Hecht, J., Posey, J., Tchekmedyian, S., Hu, E., Chan, D., et al. 2006. Panitumumab in combination with 5-fluorouracil, leucovorin, and irinotecan (IFL) or FOLFIRI for first-line treatment of metastatic colorectal cancer (mCRC). Paper presented at: 2006 Gastrointestinal Cancers Symposium: Multidisciplinary Approaches to the Prevention, Diagnosis, and Therapy of GI Cancers. January 2026-2028, 2006; San Francisco, CA. Abstract 2237.
45. *PACCE: Panitumumab Advanced Colorectal Cancer Evaluation study*. Available from: National Cancer Institute [web site] <http://www.cancer.gov/search/ViewClinicalTrials.aspx?cdrid=439483&version=HealthProfessional&protocolsearchid=2135832>. [Accessed: Jan 20, 2007].
46. Giacchetti, S., Itzhaki, M., Gruia, G., Adam, R., Zidani, R., et al. 1999. Long-term survival of patients with unresectable colorectal cancer liver metastases following infusional chemotherapy with 5-fluorouracil, leucovorin, oxaliplatin and surgery. *Ann Oncol.* **10**(6): 663-669.
47. Bismuth, H., Adam, R., Levi, F., Farabos, C., Waechter, F., et al. 1996. Resection of nonresectable liver metastases from colorectal cancer after neoadjuvant chemotherapy. *Ann Surg.* **224**(4): 509-520; discussion 520-502.
48. Nordlinger, B. and Benoist, S. 2006. Benefits and risks of neoadjuvant therapy for liver metastases. *J Clin Oncol.* **24**(31): 4954-4955.
49. Abdalla, E.K., Adam, R., Bilchik, A.J., Jaeck, D., Vauthey, J.N., et al. 2006. Improving resectability of hepatic colorectal metastases: expert consensus statement. *Ann Surg Oncol.* **13**(10): 1271-1280.
50. Julie, C., Lutz, M.P., Aust, D., Kandutsch, S., Collette, L., et al. 2007. Pathological analysis of hepatic injury after oxaliplatin-based neoadjuvant chemotherapy of colorectal cancer liver metastases: Results of the EORTC Intergroup phase III study 40983. Paper presented at: 2007 Gastrointestinal Cancers Symposium. January 2025-2027, 2007; Orlando, FL. Abstract 2241.
51. Bilchik, A.J., Poston, G., Curley, S.A., Strasberg, S., Saltz, L., et al. 2005. Neoadjuvant chemotherapy for metastatic colon cancer: a cautionary note. *J Clin Oncol.* **23**(36): 9073-9078.
52. Gruenberger, T., Sorbye, H., Debois, M., Bethe, U., Primrose, J., et al. 2006. Tumor response to pre-operative chemotherapy (CT) with FOLFOX-4 for resectable colorectal cancer liver metastases (LM). Interim results of EORTC Intergroup randomized phase III study 40983. *J Clin Oncol.* **24**(18S): abstr 3500.
53. Portier, G., Rougier, P., Milan, C., Bouché, O., Gillet, M., et al. 2002. Adjuvant systemic chemotherapy (CT) using 5-fluorouracil (FU) and folinic acid (FA) after

resection of liver metastases (LM) from colorectal (CRC) origin. Results of an intergroup phase III study (trial FFCD - ACHBTH - AURC 9002). *Proc Am Soc Clin Oncol*. **21**: abstr 528.

54. Adam, R., Pascal, G., Castaing, D., Azoulay, D., Delvart, V., et al. 2004. Tumor progression while on chemotherapy: a contraindication to liver resection for multiple colorectal metastases? *Ann Surg*. **240**(6): 1052-1061; discussion 1061-1054.
55. Allen, P.J., Kemeny, N., Jarnagin, W., DeMatteo, R., Blumgart, L., et al. 2003. Importance of response to neoadjuvant chemotherapy in patients undergoing resection of synchronous colorectal liver metastases. *J Gastrointest Surg*. **7**(1): 109-115; discussion 116-107.
56. Nordlinger, B., Brouquet, A., Penna, C., Julié, C., El Hajjam, M., et al. 2006. Complete radiological response of colorectal liver metastases (LM) after chemotherapy: Does it mean cure? *J Clin Oncol*. **24**(18S): abstr 3501.
57. Venook, A., Niedzwiecki, D., Hollis, D., Sutherland, S., Goldberg, R., et al. 2006. Phase III study of irinotecan/5FU/LV (FOLFIRI) or oxaliplatin/5FU/LV (FOLFOX) ± cetuximab for patients (pts) with untreated metastatic adenocarcinoma of the colon or rectum (MCRC): CALGB 80203 preliminary results. *J Clin Oncol*. **24**(18S): abstr 3509.
58. Adam, R., Avisar, E., Ariche, A., Giachetti, S., Azoulay, D., et al. 2001. Five-year survival following hepatic resection after neoadjuvant therapy for nonresectable colorectal. *Ann Surg Oncol*. **8**(4): 347-353.
59. Delaunoy, T., Alberts, S.R., Sargent, D.J., Green, E., Goldberg, R.M., et al. 2005. Chemotherapy permits resection of metastatic colorectal cancer: experience from Intergroup N9741. *Ann Oncol*. **16**(3): 425-429.
60. Alberts, S.R., Horvath, W.L., Sternfeld, W.C., Goldberg, R.M., Mahoney, M.R., et al. 2005. Oxaliplatin, fluorouracil, and leucovorin for patients with unresectable liver-only metastases from colorectal cancer: a North Central Cancer Treatment Group phase II study. *J Clin Oncol*. **23**(36): 9243-9249.
61. Pozzo, C., Basso, M., Cassano, A., Quirino, M., Schinzari, G., et al. 2004. Neoadjuvant treatment of unresectable liver disease with irinotecan and 5-fluorouracil plus folinic acid in colorectal cancer patients. *Ann Oncol*. **15**(6): 933-939.
62. Pascal, G., Nordlinger, B., Douillard, J.-Y., Rivoire, M., Ducreux, M., et al. 2004. Resection after chemotherapy (CT) with irinotecan (CPT) for initially unresectable liver metastasis (LM) from colorectal cancer (CRC). *J Clin Oncol*. **22**(14S): abstr 3692.

63. Vauthey, J.N., Pawlik, T.M., Ribero, D., Wu, T.T., Zorzi, D., et al. 2006. Chemotherapy regimen predicts steatohepatitis and an increase in 90-day mortality after surgery for hepatic colorectal metastases. *J Clin Oncol.* **24**(13): 2065-2072.
64. Falcone, A., Masi, G., Brunetti, I., Benedetti, G., Bertetto, O., et al. 2006. The triplet combination of irinotecan, oxaliplatin and 5FU/LV (FOLFOXIRI) vs the doublet of irinotecan and 5FU/LV (FOLFIRI) as first-line treatment of metastatic colorectal cancer (MCRC): Results of a randomized phase III trial by the Gruppo Oncologico Nord Ovest (G.O.N.O.). *J Clin Oncol.* **24**(18S): abstr 3513.
65. Masi, G., Cupini, S., Marcucci, L., Cerri, E., Loupakis, F., et al. 2006. Treatment with 5-fluorouracil/folinic acid, oxaliplatin, and irinotecan enables surgical resection of metastases in patients with initially unresectable metastatic colorectal cancer. *Ann Surg Oncol.* **13**(1): 58-65.
66. Quenet, F., Nordlinger, B., Rivoire, M., Delpero, J.R., Portier, G., et al. 2004. Resection of previously unresectable liver metastases from colorectal cancer (LMCRC) after chemotherapy (CT) with CPT-11/L-OHP/LV5FU (Folfinirox): A prospective phase II trial. *J Clin Oncol.* **22**(14S): abstr 3613.
67. Kretschmar, A., Cunningham, D., Berry, S., Michael, M., Di Bartolomeo, M., et al. 2007. Feasibility of metastasectomy in patients treated with first-line bevacizumab for mCRC: Preliminary results from the First BEAT study. Paper presented at: 2007 Gastrointestinal Cancers Symposium. January 2025-2027, 2007; Orlando, FL. Abstract 2343.
68. Van Cutsem, E., Michael, M., Berry, S., Dibartolomeo, M., Rivera, F., et al. 2007. Preliminary safety and efficacy of bevacizumab with first-line FOLFOX, XELOX, FOLFIRI, and capecitabine for mCRC: First BEATrial. Paper presented at: 2007 Gastrointestinal Cancers Symposium. January 2025-2027, 2007; Orlando, FL. Abstract 2346.
69. Kesmodel, S.B., Ellis, L.M., Lin, E., Chang, G.J., Abdalla, E.K., et al. 2007. Complication rates following hepatic surgery in patients receiving neoadjuvant bevacizumab (BV) for colorectal cancer (CRC) liver metastases. Paper presented at: 2007 Gastrointestinal Cancers Symposium. January 2025-2027, 2007; Orlando, FL. Abstract 2234.