



2019

## Group A Streptococcus Brain Abscess in a Patient on Adalimumab Therapy

Ryan Carroll, Ahmad Abu-Hashyeh, James Gainer, Kara Willenburg, and Charles Meadows

### Author Affiliations

Ryan Carroll (*Marshall University, Huntington, West Virginia*)

Ahmad Abu-Hashyeh (*Marshall University, Huntington, West Virginia*)

James Gainer (*Marshall University, Huntington, West Virginia*)

Kara Willenburg (*Marshall University, Huntington, West Virginia*)

Charles Meadows (*Marshall University, Huntington, West Virginia*)

### Corresponding Author

Ryan Carroll MD

Follow this and additional works at: <https://mds.marshall.edu/mjm>  
Marshall University



Part of the [West Virginia Disease Commons](#)

Email: [dick23@live.marshall.edu](mailto:dick23@live.marshall.edu)

## Recommended Citation

Carroll, Ryan; Abu-Hashyeh, Ahmad; Gainer, James; Willenburg, Kara; and Meadows, Charles (2019) "Group A Streptococcus Brain Abscess in a Patient on Adalimumab Therapy," *Marshall Journal of Medicine*: Vol. 5: Iss. 3, Article 4.

DOI: [10.33470/2379-9536.1230](https://doi.org/10.33470/2379-9536.1230)

Available at: <https://mds.marshall.edu/mjm/vol5/iss3/4>

DOI: [10.33470/2379-9536.1230](https://doi.org/10.33470/2379-9536.1230)

Author Footnote: Ryan Carroll participated in care of the patient, performed literature review, and drafted the final version of the manuscript. Ahmad Abu-Hashyeh performed literature review and assisted with drafting the final version of the manuscript. James Gainer participated in care of the patient, drafted the case presentation, and assisted with drafting of the final version of the manuscript. Kara Willenburg assisted with drafting of the final version of the manuscript. Charles Meadows participated in care of the patient and assisted with drafting of the final version of the manuscript.

Open Access | 

## Group A streptococcus brain abscess in a patient on adalimumab therapy

### Abstract

Brain abscesses represent a group of dangerous infections typically caused by a number of classic organisms. Group A streptococcus is a rare cause of brain abscesses and those patients that do have this particular condition will typically have a distal source of infection. We present a case of patient with a biopsy confirmed group A streptococcal without a distal source of infection. His only identifiable risk factor was his adalimumab therapy for ankylosing spondylitis. While adalimumab has not been linked to streptococcal infection in the past, it has been associated with multiple atypical infections and some of the consequences of its mechanism as a tissue necrosis factor alpha inhibitor can theoretically predispose patients to streptococcal infection when considered in conjunction with known streptococcal virulence factors. This case raises the question of whether the patient's adalimumab therapy may have contributed to his unusual presentation of streptococcal infection and prompts further consideration and study of the risks of adalimumab and other similar immunosuppressant monoclonal antibodies.

### Keywords

Streptococcus, brain abscess, adalimumab

### Introduction

Brain abscesses represent a fairly rare infectious process with a significant risk of morbidity and mortality. Many brain abscesses have a clear predisposing factor and result from a select group of common organisms. We present a case of an abscess caused by *Streptococcus pyogenes* (*S. pyogenes*), an organism not classically associated with abscess formation and only found as the causative agent of brain abscess a handful of times, in a patient without typical predisposing factors. Additionally, the previously reported cases have been in pediatric patients and have been linked to contiguous spread of infection.<sup>1</sup> We examine whether the patient's long-term adalimumab, a tissue necrosis factor alpha (TNF- $\alpha$ ) inhibitor therapy, could have contributed to his presentation.

### Case Report

Our patient is a 62-year-old male with prolonged history of ankylosing spondylitis on adalimumab therapy for seven months who presented with a subacute history of progressive headaches and right-sided scotomas. He otherwise was asymptomatic and denied fevers or other infectious symptoms. Magnetic resonance imaging (MRI) exhibited a 3.2 cm ring-enhancing lesion in the left posterior occipital lobe with perilesional edema (Figures 1 and 2). He underwent left occipital craniotomy with intraoperative findings significant for purulent material within a well-defined capsule and intraoperative cultures grew pansensitive *Streptococcus pyogenes*. Therapy with penicillin G 24 million units given via a daily continuous infusion was initiated. The patient was discharged home after eight days in the hospital and continued antibiotic therapy for a total duration of eight weeks. At follow-up, he had no residual neurologic deficits or complaints.

Figure 1. Transverse MRI image showing ring-enhancing lesion

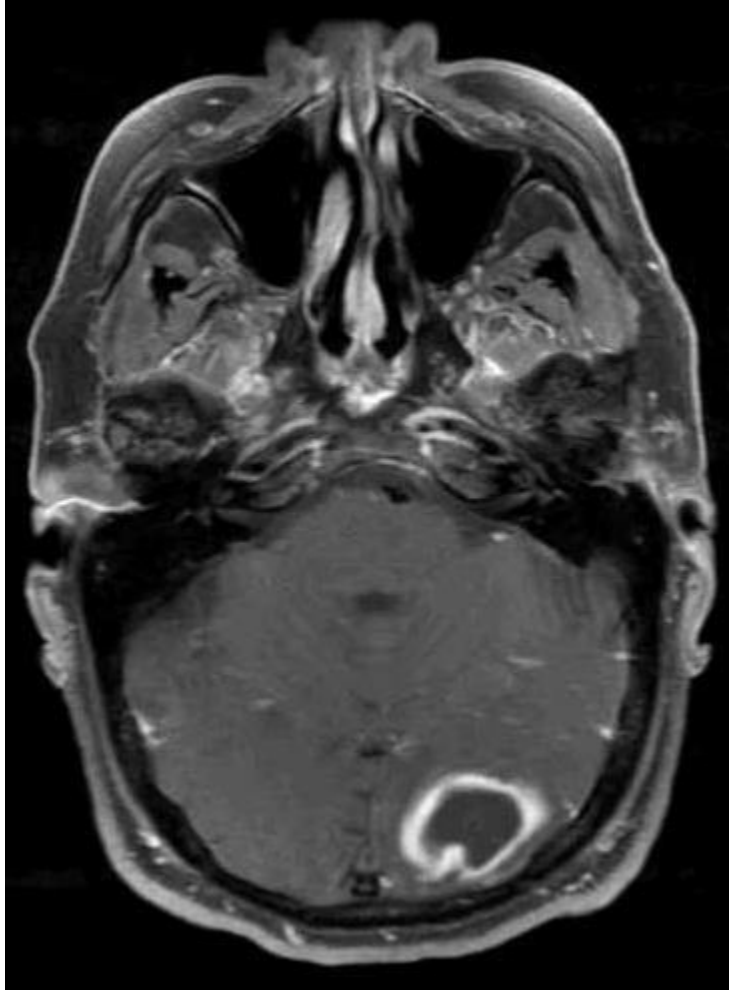
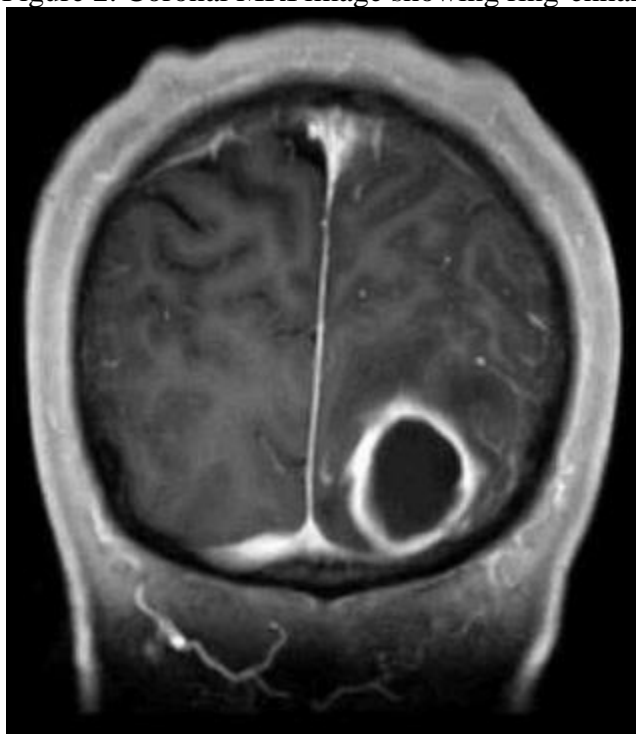


Figure 2. Coronal MRI image showing ring-enhancing lesion



## Discussion

A brain abscess is defined as a pocket of infection within the brain parenchyma and is believed to originate from cerebritis which progresses to a well-vascularized capsule.<sup>2</sup> Risk factors for its development include neurosurgical introduction of pathogens, penetrating trauma, contiguous spread from local infections, and hematogenous spread from sources such as endocarditis, pneumonia, or soft tissue infections.<sup>2,3</sup> However, as many as 40% of brain abscesses have no obvious predisposing factor.<sup>2</sup> Classical causal relationships between risk factors and certain organisms include: dental caries and anaerobic bacteria, trauma with either *Staphylococcus aureus* (*S. aureus*) or *Pseudomonas aeruginosa*, and hematogenous spread with *S. aureus*. Notably, abscesses of hematogenous origin tend to be multifocal and in the distribution of the middle cerebral artery. Symptoms may include: headache (72-92%), nausea and vomiting (31-40%), seizure (21-25%), and neurologic deficits including hemiparesis (14-20%).<sup>4,5</sup> Given that these symptoms are nonspecific, brain imaging and subsequent biopsy are required for diagnosis. Initial empiric therapy typically includes a third generation cephalosporin, metronidazole, and vancomycin and total duration of therapy depends upon whether complete surgical excision was performed and the causative organism.<sup>6</sup> Use of steroids and anticonvulsants remains controversial.<sup>7</sup>

*S. pyogenes* is not a commonly reported abscess-forming pathogen aside from the formation of peritonsillar abscesses as a complication of pharyngitis. However, a small number of case reports describe *S. pyogenes* abscesses and postulate on their causative factors. Genetic mutations including CovR and RopB, two virulence factor regulators, have been considered and SLO mutations, a trigger of neutrophil deactivation and apoptosis, have been identified in *S. pyogenes* cultured from patients with invasive infections.<sup>8</sup> Non-steroidal anti-inflammatory drugs

(NSAIDs), which our patient had been taking, have also been identified as a potential risk factor for invasive *S. pyogenes* infections.<sup>9</sup>

Adalimumab, a TNF- $\alpha$  inhibitor used in many inflammatory conditions including ankylosing spondylitis, Crohn's disease, and rheumatoid arthritis can predispose users to multiple opportunistic infections. The most common opportunistic infections seen with adalimumab therapy include fungi, cytomegalovirus, *Nocardia*, and reactivation of mycobacteria. TNF- $\alpha$  promotes neutrophil activation, stimulates macrophage phagocytosis, and increases production of interleukin-1 and its blockade hinders these processes. Less predictable effects of TNF- $\alpha$  inhibitors have also been documented including apoptosis of monocytes, CD4, and CD8 T cells.<sup>10</sup> A Cochrane review of adalimumab therapy for ankylosing spondylitis demonstrated its efficacy and revealed no statistically different insignificant adverse events.<sup>11</sup> Literature review yields many reports of the typical opportunistic infections seen with TNF- $\alpha$  inhibitors but no reports of unusual streptococcal abscess formation. One case report did note an intra-abdominal abscess caused by *Kocuria kristinae*, a bacterium considered normal skin flora and not known to be virulent in humans.<sup>12</sup> Given that our patient developed an atypical infection from a common organism we question whether some of these immunologic effects of TNF- $\alpha$  inhibitors could have predisposed him to his condition. Although *S. pyogenes* abscesses have not been reported as a complication of TNF- $\alpha$  inhibitors, our patient lacked typical risk factors for brain abscess formation and also lacked a distal source of *S. pyogenes* infection. This case report certainly does not establish a causal link but does raise questions for further study and analysis of future cases to determine if a link exists between TNF- $\alpha$  inhibitors and unusual streptococcal infections.

## Conclusion

*S. pyogenes* has only rarely been reported as the cause of a brain abscess. Our patient lacked typical predisposing factors for brain abscess formation including an extracranial site of *Streptococcal* infection but was on an immunosuppressive medication. The possible contribution of adalimumab to our patient's illness must be considered and the implications of a causal relationship would be crucial in the evaluation of patients with an intracranial lesion in the future. This case report not only provides an interesting example of an uncommon infection, but also prompts further consideration and discussion of the risks associated with novel biologic agents.

## References

1. Capua T, Klivitsky A, Bilavsky E, Askenazi-Hoffkung L, Roth J, Constantini S, Grisaru-Soen G. Group A streptococcal brain abscess in the pediatric population: case series and review of the literature. *Pediatric Infectious Disease Journal*. 2018; 7(10):967-970.
2. Miranda HA, Castellar-Leones SM, Elzain MA, Moscote-Salazar, LR. Brain abscess: current management. *Journal of Neuroscience in Rural Practice*. 2013;4(1):S67-S81.
3. Nathoo N, Nadvi SS, Narotam PK, Van Dellen JR. Brain abscess: management and outcome analysis of a computed tomography era experience with 973 patients. *World Neurosurgery*. 2011;75:716–726.
4. Mace SE. Central nervous system infections as a cause of an altered mental status? What is the pathogen growing in your central nervous system? *Emergency Medicine Clinics of North America*. 2010;28:535–570.
5. Loeser E, Scheinberg L. Brain abscesses; a review of ninety-nine cases. *Neurology*. 1957;7:601–609.
6. Shachor-Meyouhas Y, Bar-Joseph G, Guilburd JN, Lorber A, Hadash A, Kassis I. Brain abscess in children-epidemiology, predisposing factors and management in the modern medicine era. *Acta Paediatrica*. 2010;99:1163–1167.
7. Lu CH, Chang WN, Lui CC. Strategies for the management of bacterial brain abscess. *Journal of Clinical Neuroscience*. 2006;13:979–985.
8. Kamiya Y, Hasegawa T, Takegami, Y, et al. Primary psoas abscess caused by group A streptococcus in a child: case report with microbiologic findings. *Journal of Infection and Chemotherapy*. 2016; 22(12):811-814.
9. Demeslay J, DeBonnecaze G, Vairel B, et al. Possible role of anti-inflammatory drugs in complications of pharyngitis. A retrospective analysis of 163 cases. *European Annals of Otorhinolaryngology, Head and Neck Diseases*. 2014;131(5):299-303.
10. Harris J and Keane J. How tumor necrosis factor blockers interfere with tuberculosis immunity. *Clinical Experimental Immunology*. 2010;161(1):1-9.
11. Maxwell LJ, Zochling J, Boonen, A et al. TNF-alpha inhibitors for ankylosing spondylitis. *The Cochrane Database of Systemic Reviews*. 2015;18(4):CD005468.
12. Kolikonda MK, Jayakumar P, Sriramula S, Lippmann S. *Kocuria kristinae* infection during adalimumab treatment. *Postgraduate Medicine*. 2017;129(2):296-298.