



---

Volume 5 | Issue 1

Manuscript 1208

---

2019

## Statin Autoimmune Necrotizing Myopathy Diagnosed After a Motor Vehicle Accident

Julia Poe, Dominika Lozowska, and Stacy Dixon

Follow this and additional works at: <https://mds.marshall.edu/mjm>

 Part of the [Medicine and Health Sciences Commons](#)

---

### Recommended Citation

Poe, Julia; Lozowska, Dominika; and Dixon, Stacy (2019) "Statin Autoimmune Necrotizing Myopathy Diagnosed After a Motor Vehicle Accident," *Marshall Journal of Medicine*: Vol. 5: Iss. 1, Article 6.

DOI: [10.33470/2379-9536.1208](https://doi.org/10.33470/2379-9536.1208)

Available at: <https://mds.marshall.edu/mjm/vol5/iss1/6>

DOI: [10.33470/2379-9536.1208](https://doi.org/10.33470/2379-9536.1208)

Author Footnote: We acknowledge Dr. Joshua Gibson (Marshall department of radiology) for his expertise.

Open Access | 

## **Statin autoimmune necrotizing myopathy diagnosed after a motor vehicle accident**

Julia Poe BA<sup>1</sup>, Dominika Lozowska MD<sup>1</sup>, Stacy Dixon MD<sup>2</sup>

### **Author Affiliations:**

1. Marshall University Joan C. Edwards School of Medicine, Huntington, West Virginia
2. University of Colorado, Denver, Colorado

The authors have no financial disclosures to declare and no conflicts of interest to report.

### **Corresponding Author:**

Julia Poe BA  
Marshall University Joan C. Edwards School of Medicine  
Huntington, West Virginia  
Email: poe46@marshall.edu

## Abstract

One of the most commonly prescribed lipid lowering medications are statins. In the majority of cases, statins are generally well tolerated. In rare instances, statin induced necrotizing autoimmune myositis (SINAM) can occur. The following case presents a patient with a fifteen year history of simvastatin use who developed SINAM following a motor vehicle accident.

## Keywords

necrotizing myositis, autoimmune myopathy, inflammatory myopathy, HMGcoA ab, proximal weakness, SINAM, statin

## Case report

A 71-year old white male with a history of hypertension and hyperlipidemia (treated with simvastatin for fifteen years) was seen in the electromyography (EMG) lab to work up severe muscle weakness which he reported began three days after an MVA that occurred three months prior. He also complained of fatigue, but denied dysphagia, rashes, pigmenturia, delayed motor milestones when growing up, or family history of neuromuscular disease. The emergency room evaluation after his MVA focused on a hypertensive crisis and chest pain, but cardiac workup was negative and the patient was discharged. Physical examination prior to the EMG showed symmetric proximal weakness in both upper and lower extremities with neck and distal muscle strength preserved. Power was 4/5 in bilateral biceps brachii and triceps brachii, 3/5 in deltoids, 4-/5 in pectoralis, 3/5 in infraspinatus, and 3/5 in hip flexors. Reflexes were 1+ throughout with absent patellar and achilles reflexes. In all four extremities, sensation remained intact and there was no tenderness to palpation. We were unable to assess the patient's gait due to the extent of weakness.

EMG of the right arm and leg showed an acute on chronic myopathic process with evidence of irritability of muscle membranes (abundant waning discharges) and diffuse fibrillations including in the L4 and C7 paraspinal muscles. Creatinine phosphokinase (CPK) was 11,353, LDH 997, AST 405, ALT 512, ESR 27, GGT 130. At this time, a decision to discontinue the patient's statin was made. Jo1 antibody, urine myoglobin, hemoglobin A1c, and myositis panel were negative. Limb girdle muscular dystrophy genetic panel was negative. MRI of the cervical and lumbar spine showed diffuse degenerative changes, but no abnormal cord signal. MRI of the left femur showed diffuse, abnormal, increased STIR signal and mild fatty atrophy of the thigh musculature that was most prominent in the anterior aspect (Figure 1). Light microscopy of the left deltoid and quadriceps muscle showed acute myopathy (Figure 2). Trichrome and H&E stains showed mild variation in fiber size. Moderately increased internal nuclei were seen. ATPase stains showed atrophy of both fiber types. Acid phosphatase stain showed macrophage activity in necrotic fibers and connective tissues.

Figure 1. MRI with and without of the left femur.

A) T1 sequence showing mixed age edema, fatty replacement and atrophy in anterior hamstrings.

B) FatSat sequence showing soft tissue fluid and edema with increased heterogeneity.

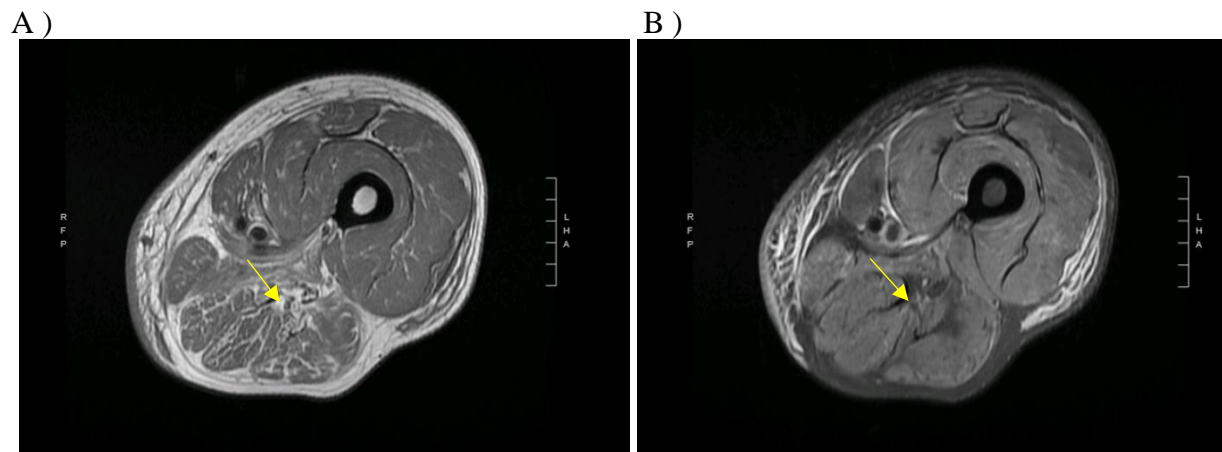
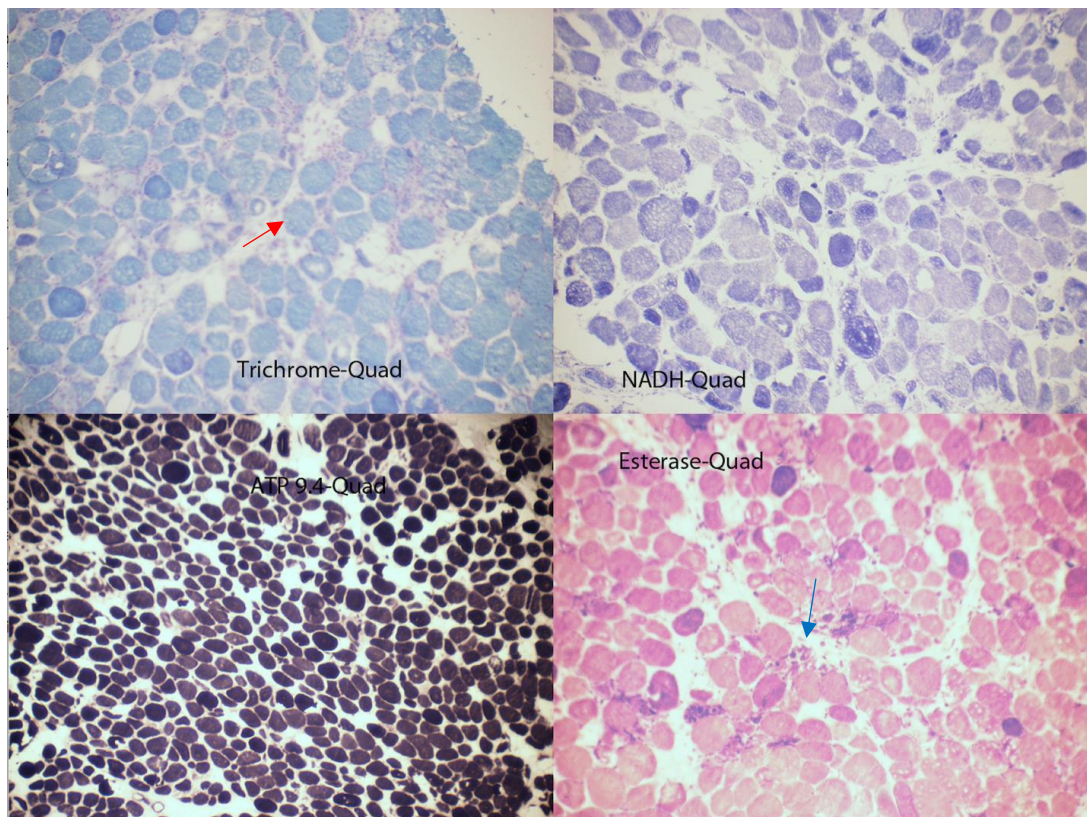


Figure 2. Histochemistry of left quadriceps and deltoid muscle biopsy. Modified Trichrome, Verhoeff Van Gieson, and H&E stains revealed mild variation in fiber size.

Moderately increased internal nuclei, moderate degenerating, basophilic, and necrotic fibers were seen, some round (red arrow).

ATPase series (pH 9.4 and 4.6) revealed variation in fiber size due to atrophy in both fiber types. Non-specific esterase and acid phosphatase reactions reveal macrophages actively in necrotic fibers and connective tissue (blue arrow).



Given the EMG and imaging findings and high suspicion for statin induced necrotizing autoimmune myopathy (SINAM), an anti-HMG CoA reductase antibody (HMGCR ab) was sent which was high (>200 units). He was started on empiric corticosteroids (prednisone 1mg/kg). He showed improvement in symptoms over the next several days. One month later he could ambulate with a walker, and later strength returned to baseline. Due to adverse steroid effects

prednisone was stopped and patient was started on weekly methotrexate 7.5mg with folic acid, which he has tolerated well for over 2 years.

Consent was obtained from the patient.

## Discussion

Statin therapy is commonly prescribed for hyperlipidemia. In 2005, reports estimated that 29.7 million people were taking statins.<sup>4</sup> Approximately 20% of patients taking statins will develop myalgias.<sup>5</sup> Myotoxicity is usually self-limited, resolving after stopping the offending drug or switching from atorvastatin or simvastatin to another statin, which may have a lower propensity for inducing symptoms.<sup>1</sup>

SINAM is seen in 2-3 out of 100,000 patients taking statins.<sup>1</sup> SINAM is characterized by progressive proximal muscle weakness, significantly elevated CPK levels (1000-10 000 units/L), abnormal EMG and muscle biopsy, and presence of a marker of autoimmune injury called anti-HMGCoA ab, which has 94.4% sensitivity and 99.3% specificity.<sup>2</sup> CPK normalizes and symptoms of SINAM improve after administration of immunosuppressants. Symptoms fail to resolve by just stopping the statin alone in most cases.<sup>2</sup> Some patients with mild weakness from SINAM will improve with the cessation of statin alone.<sup>2</sup>

Diagnosis of SINAM can be confirmed with serology for the HMGCoA ab, muscle biopsy (showing scattered necrotic muscle fibers undergoing myophagocytosis and scant inflammation) and EMG (showing increased spontaneous activity, myopathic motor unit action potentials (MUAPs) with low amplitude, short duration, polyphasia and early recruitment).<sup>3</sup>

Typically, the first line treatment for SINAM is a combination of a steroid with a secondary immunosuppressive agent such as methotrexate, azathioprine, or mycophenolate.<sup>4</sup> Intravenous immunoglobulin (IVIG) is highly efficacious as a monotherapy and in cases of refractory SINAM. Our patient was treated for over 2 years with methotrexate and remained stable. Long term immunosuppression is suggested in SINAM patients as regenerating muscle fibers in positive anti-HMGCR patients have shown upregulation in HMGCR expression, which can prolong the autoimmune response.<sup>6</sup>

Autoimmune myopathies can occur when genetically susceptible individuals are exposed to specific environmental triggers and it was shown that those with HLA-DR11 are predisposed towards SINAM.<sup>7</sup> It has been shown that around 50% of autoimmune diseases have been precipitated by unknown factors.<sup>6</sup> Prior to disease onset, studies have shown upwards of 80% of patients who develop autoimmune symptoms experienced emotional stress.<sup>8</sup> In our patient's case, it is important to consider that the stress from the motor vehicle accident was the triggering environmental factor for SINAM, but cannot be definitively proven. The patient's HLA subtype was not tested for, but would also be an important factor to consider testing for in patients with SINAM. Although SINAM is a rare complication of statin therapy, it should be considered in patients presenting with proximal muscle weakness, elevated CK, and long term statin use.

## Acknowledgements

We acknowledge Dr. Joshua Gibson (Marshall department of radiology) for his expertise.

## Abbreviations

CK- creatinine kinase

CPK- creatinine phosphokinase

HMGCR- 3-Hydroxy-3-Methylglutaryl-CoA Reductase

STIR- Short TI inversion Recovery

## References

1. Dixit A, et al. A case of atorvastatin-associated necrotizing autoimmune myopathy, mimicking idiopathic polymyositis. *Case Rep Rheumatol*. 2018;1-3.
2. Mohassel P, et al. Anti-HMGCR myopathy. *J Neuromuscul Dis*. 2018;5(1):11–20.
3. McGrath ER, et al. Autoimmune myopathies: updates on evaluation and treatment. *Neurotherapeutics*. 2018.
4. Nichols L, et al. An unusual case of statin-induced myopathy: anti-HMGCoA necrotizing autoimmune myopathy. *J Gen Intern Med*. 2015;30(12):1879–83.
5. Selva-O'Callaghan A, et al. Statin-induced myalgia and myositis: an update on pathogenesis and clinical recommendations. *Expert Rev Clin Immunol*. 2018;14(3):215–24.
6. Mammen AL, et al. Autoantibodies against 3-Hydroxy-3-Methylglutaryl-Coenzyme A Reductase (HMGCR) in patients with statin-associated autoimmune myopathy. *Arthritis Rheum*. 2011;63(3):713–21.
7. Mammen AL, et al. Increased frequency of DRB1\*11:01 in anti-hydroxymethylglutaryl- coenzyme a reductase-associated autoimmune myopathy. *Arthritis Care Res*. 2012;64(8):1233–7.
8. Stojanovich L, et al. Stress as a trigger of autoimmune disease. *Autoimmun Rev*. 2008;7(3):209–13.