



Volume 5 | Issue 1

Article 4

2019

## Percutaneous Transluminal Balloon Venoplasty: A Less Invasive Technique for Implantation of Cardiac Leads in Patients with Limited Venous Access to the heart

Waiel Abusnina, Zachary O. Curtis, Emilia C. Leigh, Eric Y. Auyoung, Dr. Mehیار El-Hamdani, and Esam Baryun

### Author Affiliations

1. Marshall University, Huntington, West Virginia

The authors have no financial disclosures to declare and no conflicts of interest to report.

### Corresponding Author


Emilia C. Leigh MD

Marshall University

Huntington, West Virginia

Email: [leighe@marshall.edu](mailto:leighe@marshall.edu)

Follow this and additional works at: <https://mds.marshall.edu/mjm>

 Part of the [Cardiology Commons](#), and the [Internal Medicine Commons](#)

## Recommended Citation

Abusnina, Waiel; Curtis, Zachary O.; Leigh, Emilia C.; Auyoung, Eric Y.; El-Hamdani, Dr. Mehیار; and Baryun, Esam (2019) "Percutaneous Transluminal Balloon Venoplasty: A Less Invasive Technique for Implantation of Cardiac Leads in Patients with Limited Venous Access to the heart," *Marshall Journal of Medicine*: Vol. 5: Iss. 1, Article 4.

DOI: [10.33470/2379-9536.1188](https://doi.org/10.33470/2379-9536.1188)

Available at: <https://mds.marshall.edu/mjm/vol5/iss1/4>

DOI: [10.33470/2379-9536.1188](https://doi.org/10.33470/2379-9536.1188)

Open Access | 

**Percutaneous transluminal balloon venoplasty: a less invasive technique for implantation of cardiac leads in patients with limited venous access to the heart**

Wael Abusnina MD<sup>1</sup>, Zachary O. Curtis MD<sup>1</sup>, Emilia C. Leigh MD<sup>1</sup>, Eric Y. Auyoung MD<sup>1</sup>, Mehیار El-Hamdani MD, FACC, FSCAI<sup>1</sup>, Esam Baryun MD<sup>1</sup>

**Author Affiliations:**

1. Marshall University, Huntington, West Virginia

The authors have no financial disclosures to declare and no conflicts of interest to report.

**Corresponding Author:**

Emilia C. Leigh MD  
Marshall University  
Huntington, West Virginia  
Email: leighe@marshall.edu

## **Abstract**

Since its inception, cardiac pacing has made a significant advancement in cardiology. As new therapies and devices emerge, the number of implantations is steadily increasing which requires up-to-date clinical guidelines for management. Although advanced, these mechanical devices often require maintenance and revisions to achieve optimal performance. One of the most common deteriorations is lead failure.

In the case of lead failure requiring revision, new lead implant, or upgrading to a more advanced pacing system, venous stenosis resulting in partial or complete obstruction of the vessel can pose a real problem. This case series report introduces the technique of percutaneous transluminal balloon venoplasty in the setting of venous stenosis as an alternative to more invasive procedures such as lead extraction for lead revision or device upgrade.

## **Keywords**

Percutaneous transluminal balloon venoplasty; pacemaker lead deterioration; lead revision

## **Introduction**

Artificial cardiac pacemakers have come a long way since Albert S. Hyman's external cardiac pacemaker system in 1932. Major advancements in cardiac pacing occurred in the 1950s, including the first complete implantation of an epicardial pacing system and a transvenous temporary pacing lead.<sup>1</sup>

With the invention of transvenous implantable cardioverter-defibrillator (ICD) leads in the early 1980s, management of arrhythmias and heart failure improved significantly.<sup>2-4</sup> Over past several decades, novel therapies have developed and, as a result, the number of pacemaker implantations have steadily increased. Furthermore, with the improvement in technology, patients with older systems have required upgrades to ICDs and/or dual and biventricular pacing systems.<sup>5</sup> In these procedures, access to the subclavian veins is paramount to the success of the operation. However, as with any procedure requiring central venous access and insertion of leads, venous stenosis can occur.

Patients with venous stenosis rarely report significant clinical symptoms due to the development of adequate venous collateral circulation.<sup>6</sup> Young, active patients are more likely to be symptomatic. Unfortunately, if a patient requires implantation of additional leads, partial or complete venous stenosis can impede and complicate the procedure.<sup>7</sup>

There are numerous solutions to this dilemma. These solutions include: extracting one lead to gain access; implant the new lead in the opposite side then tunnel it to the same pocket; or implant epicardial lead surgically.<sup>7</sup> As an alternative to these invasive and risky procedures for new lead implant, we describe a less invasive technique in the setting of venous stenosis: percutaneous transluminal balloon venoplasty.

## Case Series

### Case I

A 74-year-old male with a history of recurrent syncope related to hypotension caused by frequent premature ventricular contractions (PVCs) and bradycardia secondary to first-degree heart block and bundle branch block underwent a dual chamber pacemaker implantation. The patient was on hemodialysis and met Class I indication for a pacemaker implant.

The venography showed a complete obstruction of the patient's left subclavian and innominate veins (Figure 1A) which challenged the left-sided access to the heart, rendering right-sided access the alternative option for the implant procedure. However, the patient had a failed arteriovenous fistula (AVF) on the left arm for hemodialysis, which resulted in a second AVF creation on the right arm, and it was not advised to implant on the same side of the fistula. The interventional cardiologist was consulted to assess the possibility of patency restoration of the left veins. Angioplasty was successfully performed using an Evercross 9/150mm balloon (Figures 1B and 1C). The transvenous pacemaker implantation was subsequently performed through the left subclavian vein, and the leads were placed without any difficulties. This resulted in a successful pacemaker implantation while reserving the right AVF function.

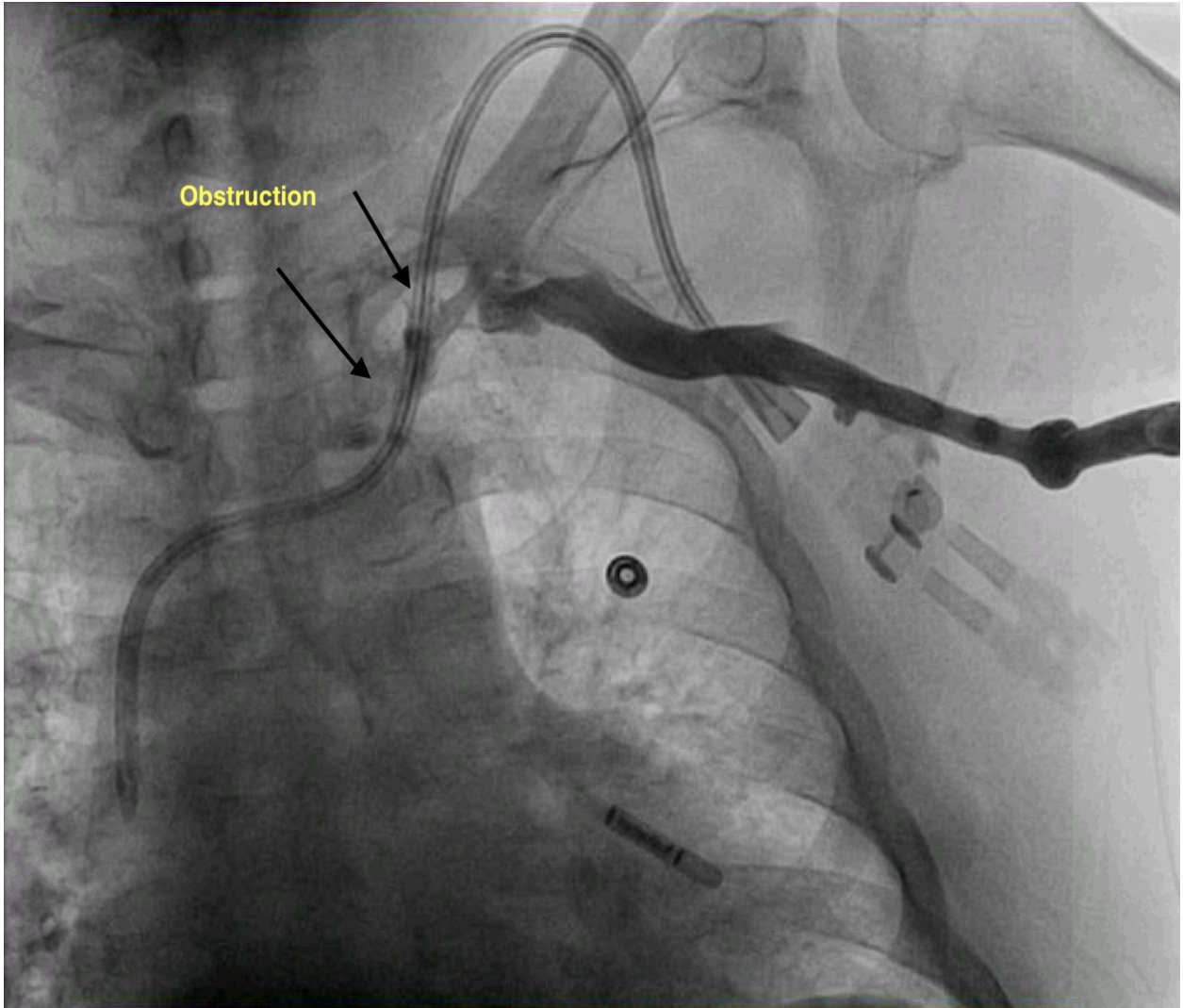


Figure 1A. Pre-venoplasty

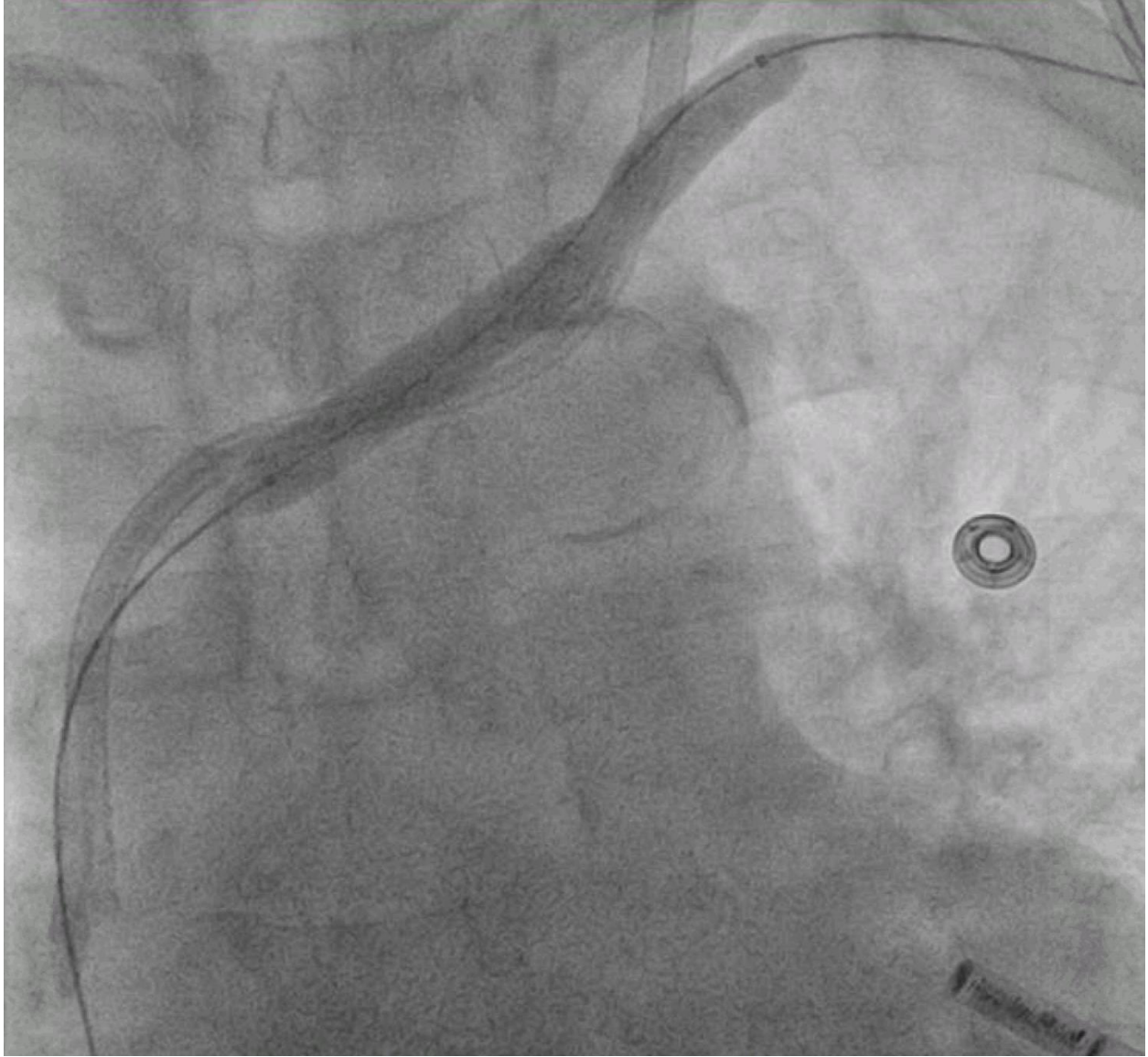

Figure 1B. Venoplasty

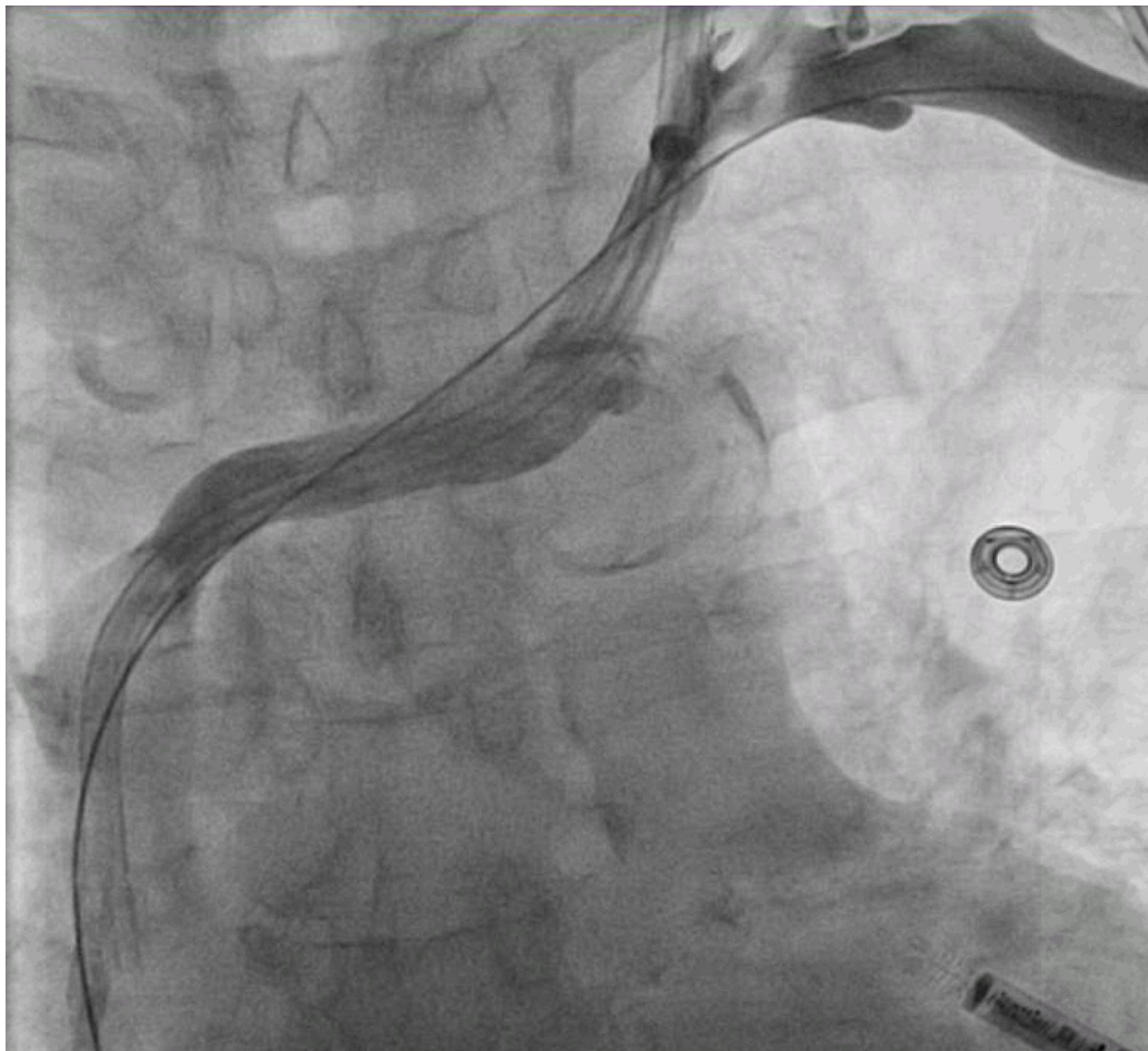


Figure 1C. Venoplasty

## Case II

A 67-year-old female with a single chamber ICD and a history of severe ischemic cardiomyopathy, atrial fibrillation, and LBBB with wide QRS and ventricular tachycardia underwent CRT-D upgrade which required the addition of an LV lead. The pre-existing generator previously implanted via left infraclavicular vein was explanted to implant the newer generator with more than one lead port.

The venous access was gained through the left subclavian vein. However, attempts to advance the wire beyond the innominate vein encountered difficulties despite the use of multiple wires,



including the Wholey wire and the Glidewire. A venogram showed a total obstruction in distal innominate vein (Figure 2A).

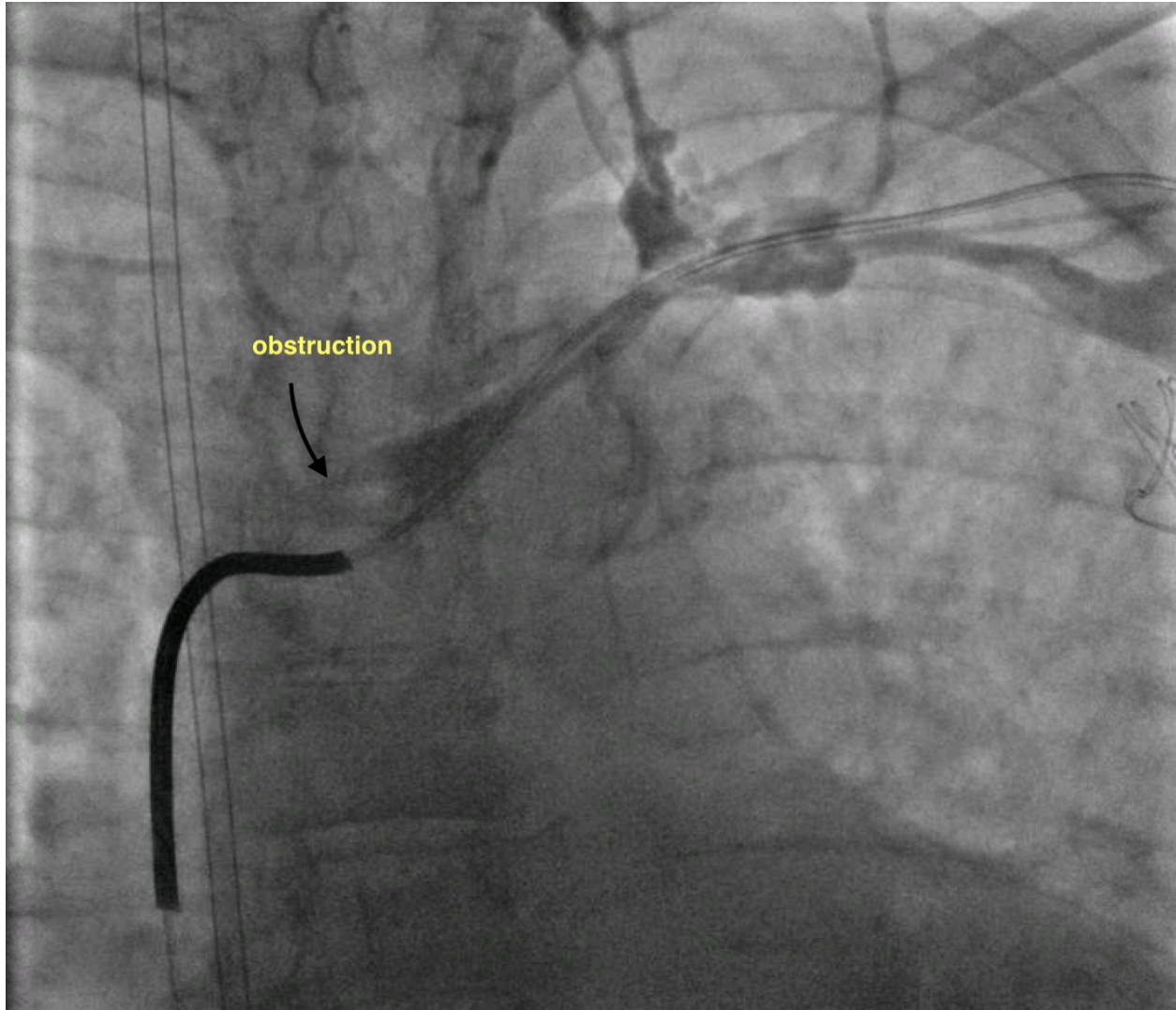


Figure 2A. Pre-venoplasty

An interventional radiologist was consulted for a balloon venoplasty, which resulted in a successful dilation of the vein (Figures 2B and 2C). Subsequently, the wire was advanced through the dilated left vein and the left ventricular lead placed. Then, the right atrial lead was placed on the right side of the heart which completed the upgrade procedure.



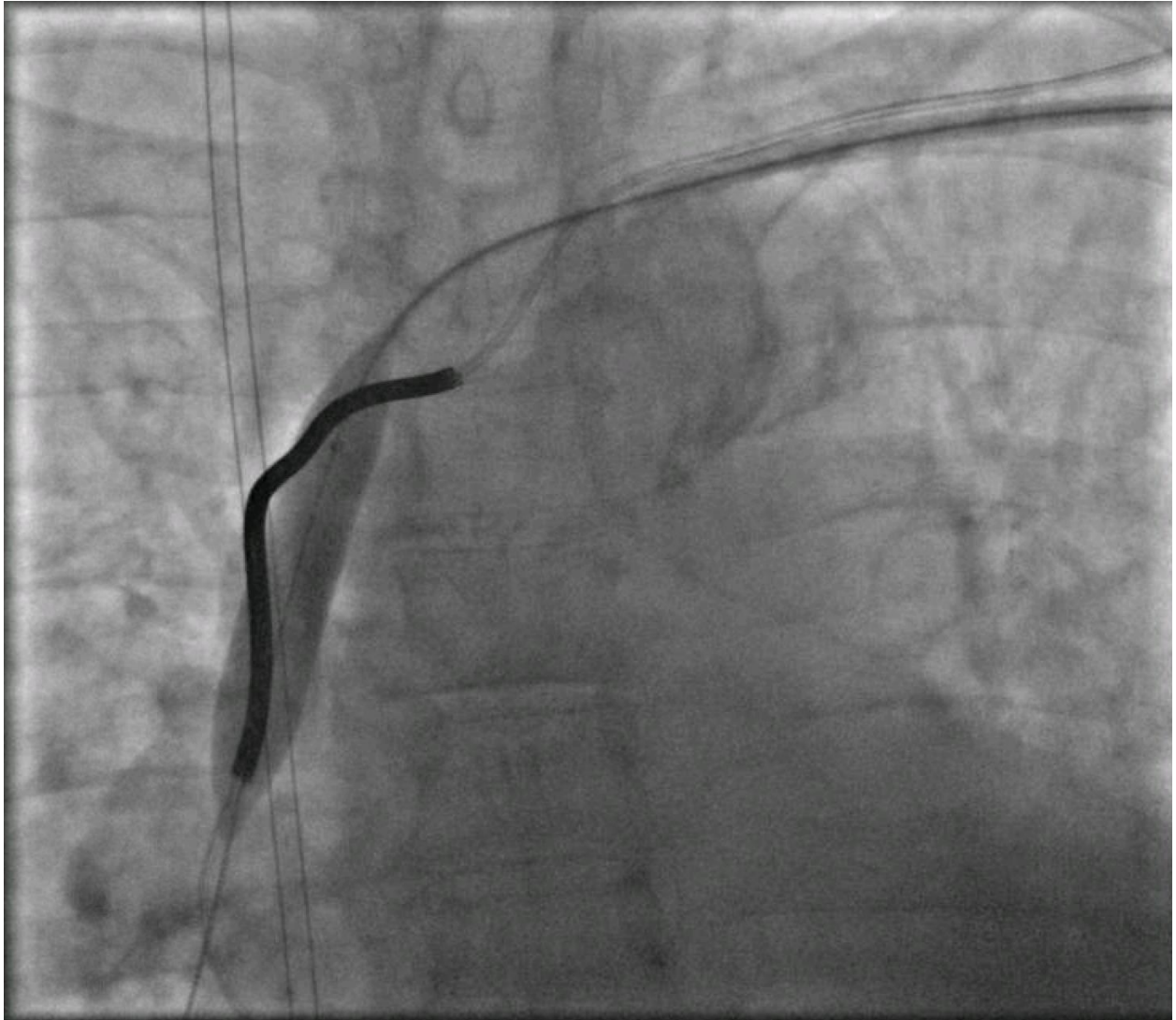


Figure 2B. Venoplasty

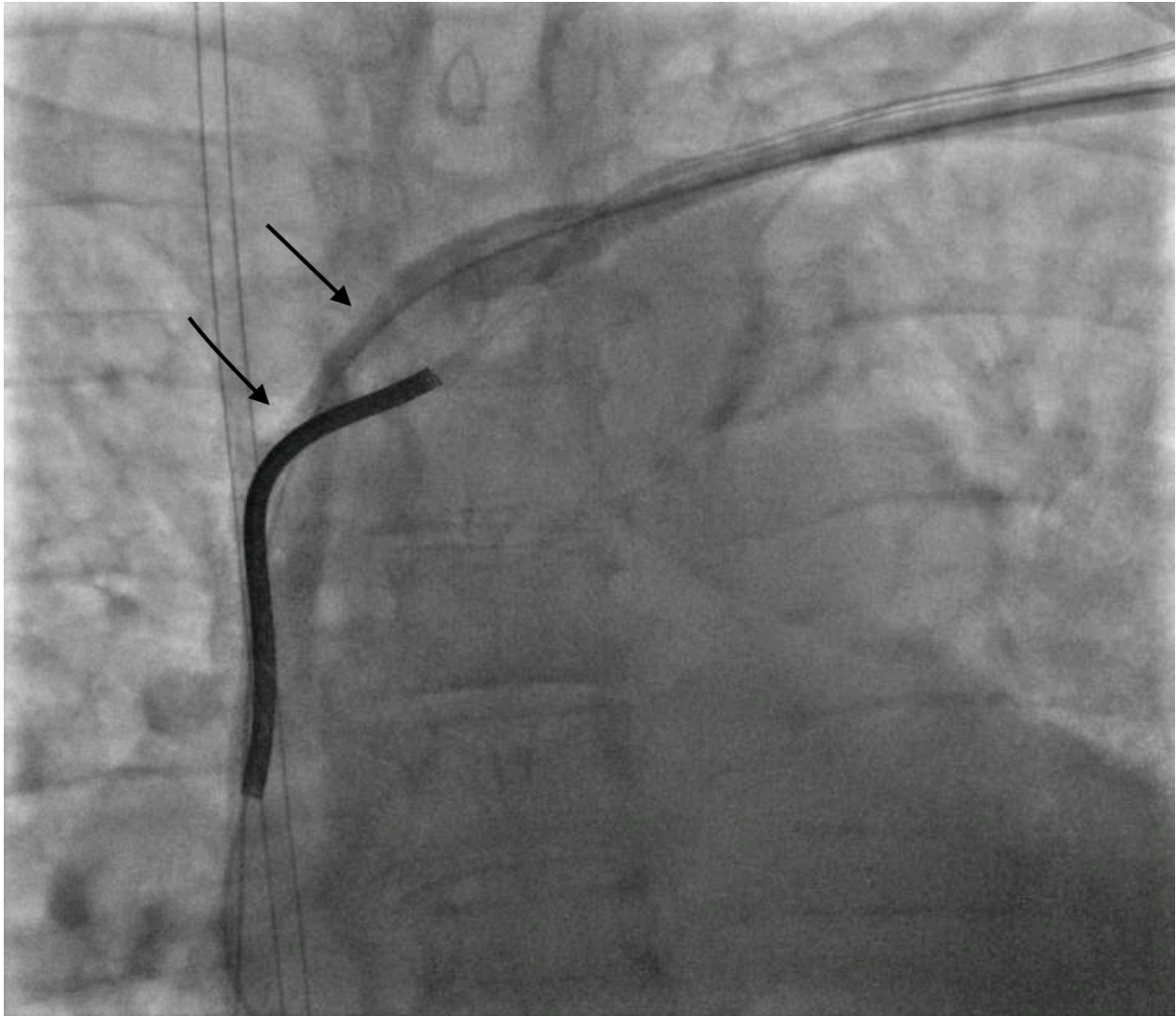


Figure 2C. Post-venoplasty

### Case III

A 77-year-old male with severe cardiomyopathy and NYHA Class 3 CHF symptoms presented with a dual chamber ICD that reached elective replacement interval. The patient was scheduled to receive CRT-D upgrade. The LV lead placement was indicated due to cardiomyopathy, prominent PR prolongation more than 300 ms, and V-pacing at 100% with QRS of almost 200 ms.

The attempt to upgrade was unsuccessful because the left subclavian vein was subtotally occluded (Figure 3A). An interventional cardiologist was consulted to dilate the occluded vessel. The right femoral vein from below and the left accessory vein from above were accessed without any difficulties, and an angiogram was obtained through the innominate vein and superior vena cava which showed a clear occlusion of the left innominate vein.

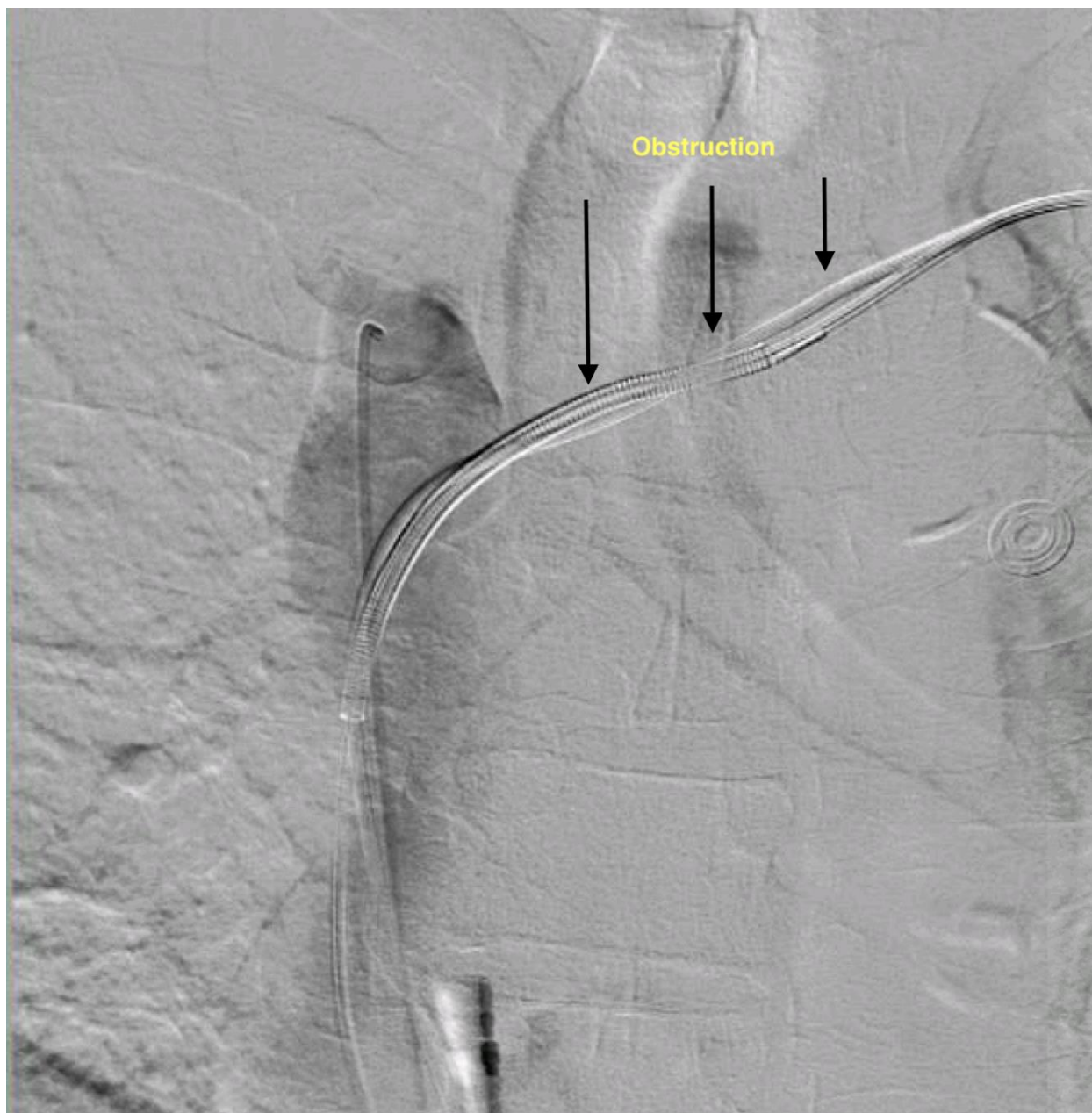

Figure 3A. Pre-venoplasty

The wire was advanced until it reached the right atrium through a slender sheath that was introduced via the left accessory vein access. A 5.0 balloon was initially used followed by a 9/80 Mustang balloon which was inflated for a total of 8 atmospheres for 2 minutes (Figure 3B).

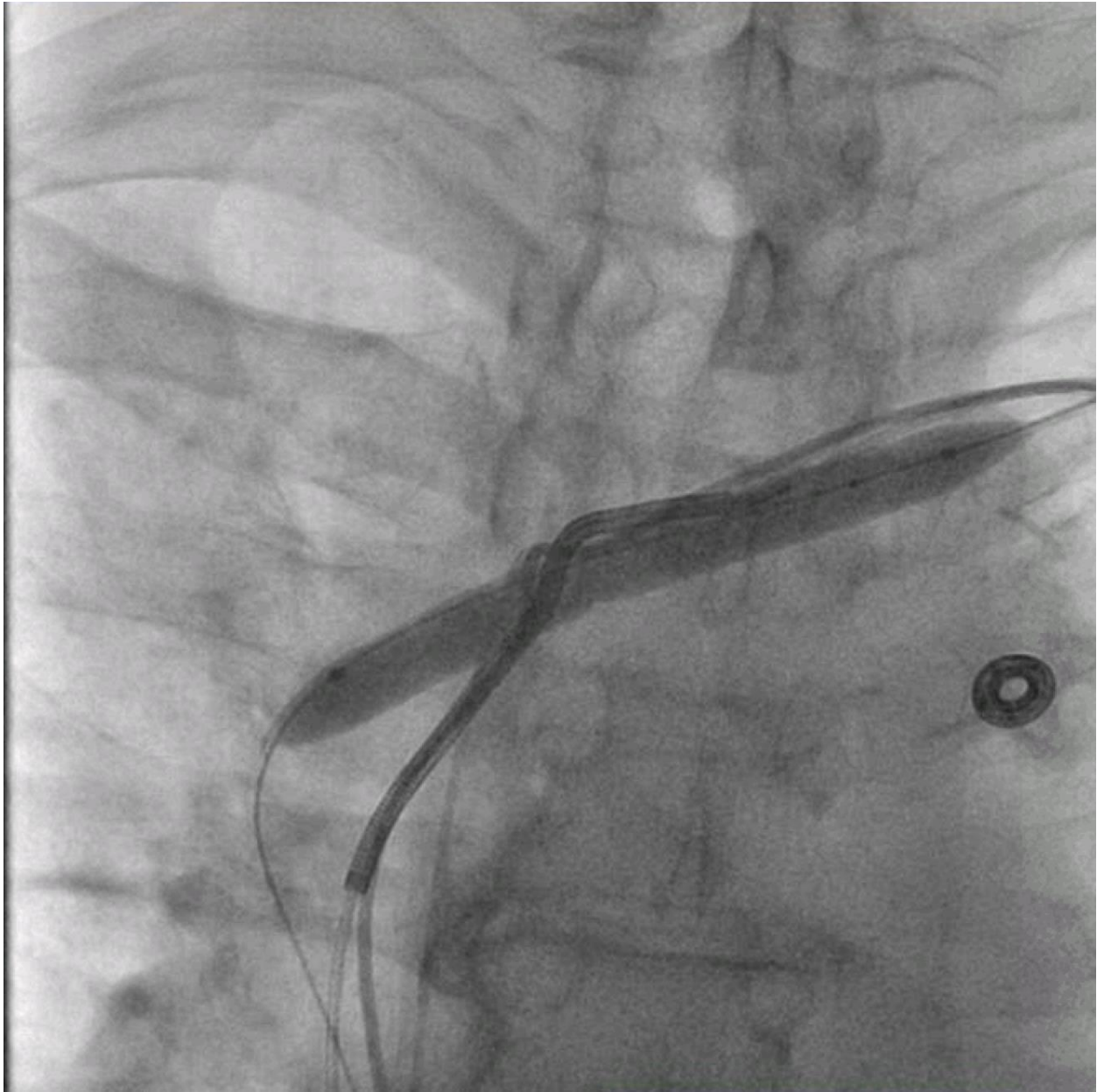


Figure 3B. Venoplasty

A post-dilation angiogram showed a complete resolution of stenosis throughout the course of the innominate vein with 10% residual and no immediate complications (Figure 3C). After the procedure, EP cardiology proceeded with the CRT-D generator change and LV lead implant on the same side of pre-existing generator.



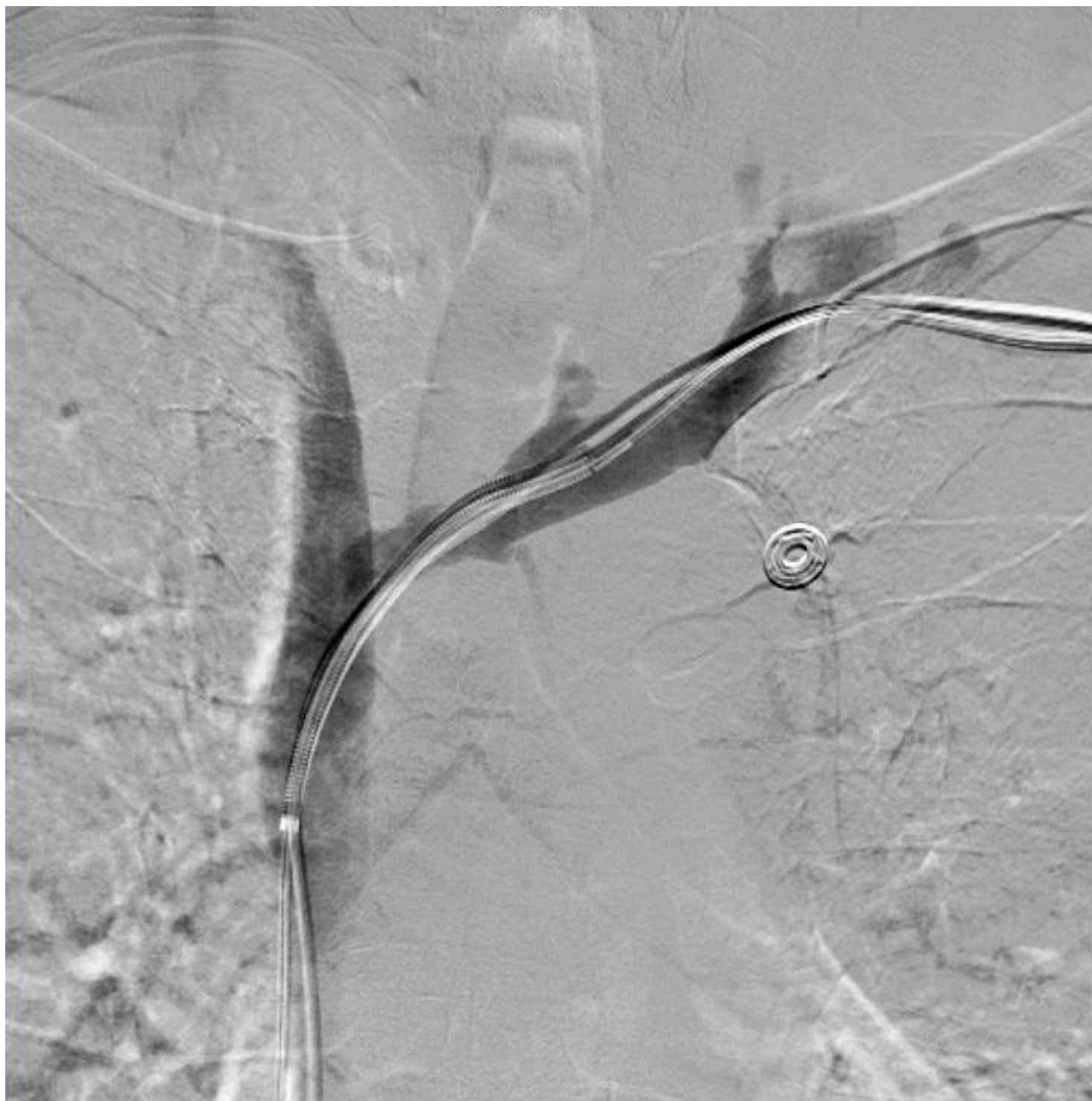

Figure 3C. Post-venoplasty

## Discussion

Transvenous introduction of the leads through the subclavian vein is the most commonly used technique for pacemaker or ICD device placement. The leads are well known to be susceptible to multiple different problems: fracture of the leads from deterioration, insulation defects, connector issues, and infections.<sup>1</sup>

In addition, the leads can cause deep venous thrombosis or irritate the vessel wall at the site of lead intersection which can result in development of venous stenosis.<sup>1,8</sup> Venous stenosis can be a

challenge for the operator if the patient requires the implantation of new leads. Therefore, patency of the accessible veins is a critical factor for procedural success.<sup>5</sup>

In association with permanent transvenous pacemaker electrodes, the incidence of partial venous obstruction varies from 31% to 50% with up to one-third of patients having total venous occlusions<sup>9,10</sup>. In a recent prospective study, about 26% of patients with pacemakers or ICD systems were found to have a total occlusion of the subclavian or innominate vein, and up to 25% of them have significant venous stenosis (>50%) with a mean time of 6.2 years since implantation.<sup>5</sup>

Venous stenosis, a well-recognized complication of pacemaker or ICD lead placement, can cause perplexing situations during the lead revision or replacement. Without doubt, total venous occlusion proves to be more challenging and leaves the operator with limited choices. In situations of total venous occlusion, there are two main options: an extraction of a functional lead in order to get access; or an implantation of the lead on the opposite side and then tunneling it to the pocket. Using the opposite side may not be an option in the presence of an AV fistula. It may be possible to get access into the vein medial to the obstruction. Epicardial implantation by a surgeon could be the last resort if a ventricular lead is needed.<sup>7</sup>

A more recent technique is to use a leadless device such as Micra for pacing the right ventricle. To bypass the downfalls of these previously described solutions to transvenous lead revision or device upgrade with venous stenosis, a new option that is gaining interest is the successful dilatation of venous stenosis. This technique avoids more invasive options. Percutaneous transluminal balloon venoplasty can be performed safely, provided the procedure is performed by personnel with adequate training and the necessary equipment is readily available. Lead implant can take place the following day while the patient remains anticoagulated with IV heparin to prevent closure of the vein.

It has been established that in symptomatic cases of venous stenosis resulting in superior vena cava syndrome (SVC syndrome), an option to relieve the symptoms is to place a stent in the area of stenosis.<sup>11,12</sup> In the cases described, these lesions are found incidentally in asymptomatic patients. Venoplasty is sufficient in dilating the vein to allow for pacemaker lead revision.<sup>13</sup> While stenting would remain a potential option for venous stenosis found when attempting pacemaker lead revision, it would require the patients to also take antiplatelet medication following the placing of the stent, which could lead to further bleeding complications.

Although there are some potential risks associated with percutaneous transluminal balloon venoplasty, its benefits may outweigh the risks. This technique can avoid proceeding with more invasive options such as surgical access or using other veins with potential future stenosis. Since veins have thinner walls and are less elastic compared to arteries, there is a possibility of rupturing the vein during the balloon venoplasty procedure. This could result in potential intrathoracic hematoma which may require further invasive procedures for it to resolve. While wiring a distal occlusion does not pose the risk of cardiac tamponade, the complications of pacemaker lead insertion are still present. The incidence of complications with percutaneous transluminal balloon venoplasty remains yet to be defined. Moreover, the routine use of preoperative venography prior to pacemaker lead revision is recommended to detect significant



occlusive venous disease and to aid in determining the optimal route of electrode placement and the type of operating room as a hybrid room would be preferred when extraction is needed.

### **Conclusion**

The adjunct use of antiplatelet agents and anticoagulants has not been adequately studied after venous stenting. Based upon the underlying pathophysiology, extrapolation of results from arterial interventions, and clinical experience, there seems to be a role for these agents. Antiplatelet agents would be most appropriate for patients with primary vein lesions while anticoagulants would have a greater role in post-thrombotic disease.<sup>14</sup> In a recent study, the current consensus is to utilize anticoagulant therapy following venous stenting while it lacks evidence with respect to the role of antiplatelet agents.<sup>15</sup> Given the lack of evidence supporting the use of both antiplatelet agents and anticoagulants, a careful assessment of the risks and benefits in the individual patients would be warranted.<sup>14</sup>

Transluminal balloon venoplasty technique is an option that can help avoid more invasive alternatives. It also spares other veins as access, hence preventing the potential for future stenosis. This option should be considered before extraction of a functional lead or attempting to get access on the contralateral side. Although the incidence of complications of venoplasty are still yet to be defined, its benefits may outweigh the risks when compared to alternative techniques for pacemaker lead revision in the setting of venous stenosis.

## Abbreviations

AF – Atrial fibrillation  
CHF – Congestive Heart Failure  
CRT – Cardiac Resynchronization Therapy  
CS – Coronary Sinus  
EF – Ejection Fraction  
EP – Electrophysiology

ICD – Implantable Cardioverter-Defibrillator  
LBBB – Left Branch Bundle Block  
LV – Left Ventricle/Ventricular  
MRI – Magnetic Resonance Imaging  
NYHA – New York Heart Association  
PVC – Premature Ventricular Contraction

## References

1. Sperzel J, Burri H, Gras D, Tjong FV, Knops RE, Hindricks G, Steinwender C, and Defaye P. State of the art of leadless pacing. *Europace*. 2015;17(10):1508-1513.
2. Lavergne T, Daubert J-C, Chauvin M, et al. Preliminary clinical experience with the first dual chamber pacemaker defibrillator. *Pacing and Clinical Electrophysiology*. 1997;20(1):182-188.
3. Frank G, Tyers O, Mills P, Clark J, Cheesman M, Yeung-Lai-Wah JA, and Brownlee RR. Bipolar leads for use with permanently implantable cardiac pacing systems: a review of limitations of traditional and coaxial configurations and the development and testing of new conductor, insulation, and electrode designs. *Journal of Investigative Surgery*. 1997;10(1-2):1-15.
4. Campeau L, Enjalbert M, Lespérance J, Bourassa MG, Kwiterovich P, Wacholder S, and Sniderman A. The relation of risk factors to the development of atherosclerosis in saphenous-vein bypass grafts and the progression of disease in the native circulation. *New England Journal of Medicine*. 1984;311(21):1329-1332.
5. Abu-El-Haija B, Bhave PD, Campbell DN, Mazur A, Hodgson-Zingman DM, Cotarlan V, and Giudici MC. Venous stenosis after transvenous lead placement: a study of outcomes and risk factors in 212 consecutive patients. *Journal of the American Heart Association*. 2015;4(8).
6. Spittell PC, Vlietstra RE, Hayes DL, Higano ST. Venous obstruction due to permanent transvenous pacemaker electrodes: treatment with percutaneous transluminal balloon venoplasty. *Pacing and Clinical Electrophysiology*. 1990;13(3):271-274.
7. Burri H. Overcoming the challenge of venous occlusion for lead implantation. *Indian Pacing and Electrophysiology Journal*. 2015;15(2):110-112.
8. Pauletti M, Pingitore R, Contini C. Superior vena cava stenosis at site of intersection of two pacing electrodes. *Heart*. 1979;42(4):487-489.
9. Stoney WS, Addlestone RB, Alford WC, Burrus GR, Frist RA, Thomas CS. The incidence of venous thrombosis following long-term transvenous pacing. *The Annals of Thoracic Surgery*. 1976;22(2):166-170.
10. Mahajan V, Strimlan V, Ordstrand HSV, Loop FD. Benign superior vena cava syndrome. *Chest*. 1975;68(1):32-35.
11. Francis CM, Starkey IR, Errington ML, Gillespie IN. Venous stenting as treatment for pacemaker-induced superior vena cava syndrome. *Am Heart J*. 1995;129(4):836-7.
12. Lindsay HS, Chennells PM, Perrins EJ. Successful treatment by balloon venoplasty and stent insertion of obstruction of the superior vena cava by an endocardial pacemaker lead. *Br Heart J*. 1994;71(4):363-5.
13. Slonim SM, Semba CP, Sze DY, Dake MD. Placement of SVC stents over pacemaker wires for the treatment of SVC Syndrome. *JVIR*. 2000;11(2):215-219.
14. Meissner MH. Indications for platelet aggregation inhibitors after venous stents. *Phlebology*. 2013;28(Suppl 1):91-8.
15. Milinis K, Thapar A, Shalhoub J, Davies AH. Antithrombotic therapy following venous stenting: International Delphi Consensus. *Eur J Vasc Endovasc Surg*. 2018;55(4):537-544.