



Volume 5 | Issue 1

Manuscript 1201

2019

Bilateral acute Ocular Ischemic Syndrome following head and neck radiation

Dipali Nemade, Paul Ferguson, Vikram Shivkumar, and Dennis Cole

Follow this and additional works at: <https://mds.marshall.edu/mjm>



Part of the [Neurology Commons](#), [Oncology Commons](#), and the [Ophthalmology Commons](#)

Recommended Citation

Nemade, Dipali; Ferguson, Paul; Shivkumar, Vikram; and Cole, Dennis (2019) "Bilateral acute Ocular Ischemic Syndrome following head and neck radiation," *Marshall Journal of Medicine*: Vol. 5: Iss. 1, Article 5.

DOI: [10.33470/2379-9536.1201](https://doi.org/10.33470/2379-9536.1201)

Available at: <https://mds.marshall.edu/mjm/vol5/iss1/5>

DOI: [10.33470/2379-9536.1201](https://doi.org/10.33470/2379-9536.1201)

Author Footnote: We acknowledge the Departments of Ophthalmology, Radiology and Radiation Oncology for providing pertinent case information.

Open Access | 

Bilateral acute ocular ischemic syndrome following head and neck radiation

Paul Ferguson MD¹, Dipali Nemade MD¹, Vikram Shivkumar MD¹, Dennis Cole MD²

Author Affiliations:

1. Marshall University, Huntington, West Virginia
2. University of Virginia, Charlottesville, Virginia

The authors have no financial disclosures to declare and no conflicts of interest to report.

Corresponding Author:

Vikram Shivkumar MD
Marshall University
Huntington, West Virginia
Email: shivkumar@marshall.edu

Abstract

Previous literature has established a clear correlation between radiation therapy (RT) to the head and neck leading to aggressive atherosclerosis of the carotid arteries and subsequent increased risk for ischemic stroke. Stenosis of carotid arteries can lead to ocular ischemic syndrome (OIS). We present a case of acute bilateral OIS following head and neck RT for left tonsillar squamous cell carcinoma (SCC) in a 64-year-old Caucasian male. Routine large vessel cerebrovascular screening following head and neck radiotherapy should be considered as a means of potentially mitigating future stroke risk through initiation of medical therapy and interventional modalities as a means of primary prevention. In addition to large vessel screening by carotid duplex ultrasound, it may also be pertinent to consider further evaluation with more detailed medium and small vessel imaging through CT angiography in select cases.

Keywords

Head and neck cancer, radiation-induced carotid stenosis (RI-CS), blindness, carotid stenosis, ocular ischemic syndrome (OIS)

Introduction

Radiation-induced carotid stenosis (RI-CS) can be a life-threatening complication due to its increased risk of stroke. Factors responsible for late effects of radiation on large and small vessels have not been extensively studied.¹ Prevalence of RI-CS ranges from 30-50% and varies according to the primary malignancy site with the highest incidence observed in carcinomas of the tongue and oral floor.² Ocular ischemic syndrome (OIS) can occur when the stenosis of the carotid artery exceeds 90%.³ OIS is bilateral in 20% of cases, while only 12% of all OIS cases present acutely. We report a patient treated with radiotherapy for left tonsillar squamous cell carcinoma who developed radiation induced bilateral carotid artery occlusion with acute bilateral total blindness.

Case

A 64-year-old Caucasian male with history of hypertension presented with abrupt onset of painless right monocular blindness and left superior altitudinal visual impairment, which quickly evolved to left total blindness, accompanied by subtle right face and arm weakness. The patient had a pertinent history of left tonsillar SCC Stage IVC (N2bM1) five years prior to presentation which was treated with radiation therapy totaling 70 Gy over a two month period. Pertinent history is that he had an unremarkable CT angiography of the head and neck four years prior to symptom onset. In the months prior to presentation the patient recalls distinct episodes of transient right sided weakness and visual “dimming”, particularly during instances of Valsalva that would resolve within a few minutes. Medical attention for these events was never pursued.

CT angiography of the head and neck at time of initial evaluation revealed occlusion of both common carotid arteries along with 40% and 60% stenosis of the right and left vertebral arteries respectively; an intact Circle of Willis was also noted (Figure 1).

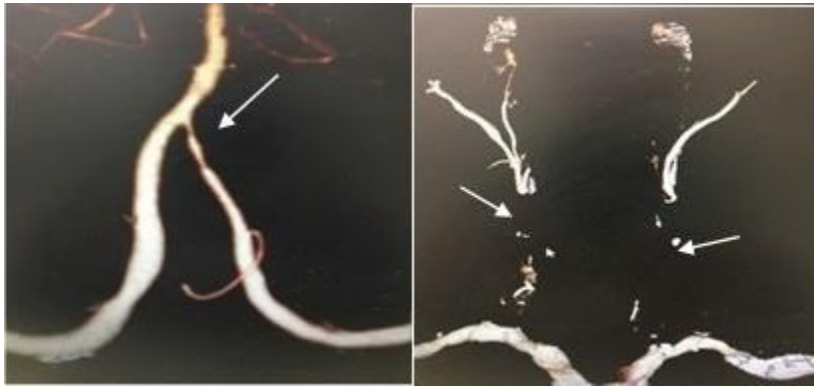

Figure 1: CT angiography showing stenosis of left vertebral artery (left) and occlusion of bilateral common carotid arteries (right)

CT perfusion scanners revealed hypoperfusion of both anterior MCA and ACA territories with completed infarct in the left anterior frontal lobe (Figure 2).

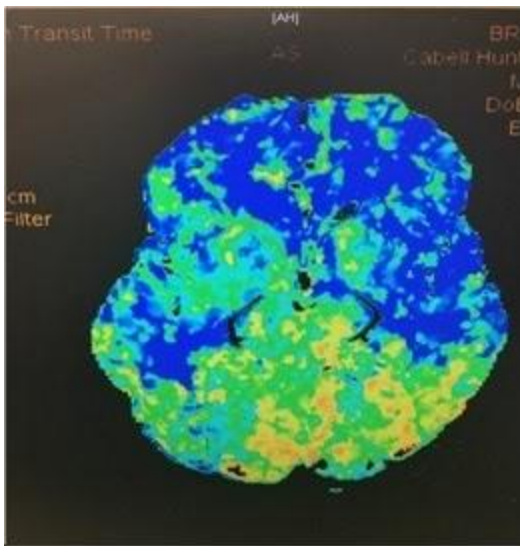


Figure 2: CT perfusion scan showing decreased perfusion (blue) in bilateral middle cerebral artery and anterior cerebral artery distributions.

He was treated with both aspirin and clopidogrel and high dose atorvastatin. During his stay, his right arm and facial strength improved back to baseline but vision was never regained.

Ophthalmologic examination detailed some intermittent light perception in the nasal field of the left eye but otherwise he was completely blind. There was no light perception in right eye. The right pupil did not react to light and the left pupil was minimally reactive. On dilated exam, optic discs were pale with marked attenuation of retinal vasculature. He was assessed by a retinal specialist who documented 4+ optic disc drusen with peripapillary atrophy without evidence of

emboli bilaterally. There were no engorged vessels or hemorrhages. Fluorescein angiography showed severe delay in choroidal filling in the left eye and a delay in retinal arterial perfusion in both eyes. These findings were suggestive of bilateral ophthalmic artery hypoperfusion. Because of his high risk for rubeosis iridis and neovascular glaucoma, he was treated with prophylactic pan-retinal photocoagulation (PRP). Months following the acute event, the patient's condition remained stable but without any visual improvement and he is currently in a blind rehabilitation center.

Discussion

Radiation therapy has become a standard treatment for all subsites of primary head and neck cancers and accounts for a dramatic improvement in patient related mortality. Radiation therapy can lead to carotid stenosis which is responsible for OIS. The mechanism is believed to be a combination of direct vessel wall damage, leading to intimal proliferation, necrosis of the media, periadventitial fibrosis, and accelerated atherosclerosis; there are indirect effects as a result of radiation-induced obliteration of the adventitial vasa vasorum.⁴

Some patients can tolerate a higher degree of stenosis due to good collateral circulation. However, stenosis of over 50% can lead to OIS in the absence of good collaterals. OIS typically results in loss of visual acuity which can be as profound as total blindness. It can also be associated with pain, particularly if there is rubeosis iridis. In most cases, OIS is unilateral but can be bilateral in 20% of cases. Reduction in acuity often occurs over weeks but in 12% of cases, it can be acute.⁵ There are case reports of OIS following radiation therapy but the deficits in these cases were not as profound or symptoms occurred gradually. A 55-year-old male with single branch retinal artery occlusion (BRAO) eight years following unilateral head and neck radiation for squamous cell carcinoma of the left tonsil has been documented.¹ A 39-year-old male who developed OIS in both eyes 14 years after RT for nasopharyngeal squamous cell carcinoma has also been published.⁶

Our patient demonstrated bilateral acute OIS with resultant total blindness. He had common carotid artery occlusion and vertebral artery stenosis with rapid progression given his normal carotid vascular imaging four years prior to his current symptoms. This accelerated atherosclerotic formation in the carotid and vertebral circulation is remarkable and is clearly linked to the prior radiotherapy.⁶ Predisposing factors for radiation-induced accelerated atherosclerosis include hypertension, hyperlipidemia, diabetes mellitus, young age, NF1, chiasmal irradiation, and concomitant or previous chemotherapy.⁷ Our patient was a smoker and had hypertension, but these alone would not cause such accelerated atherosclerosis.⁸

Routine cerebrovascular screening following head and neck radiotherapy should be considered as a means of potentially mitigating future stroke risk through initiation of medical therapy and interventional modalities as a means of primary prevention. In addition to large vessel screening by carotid duplex ultrasound, it may also be pertinent to consider further evaluation with more detailed medium and small vessel imaging through CT angiography. In addition, patients need to be educated about these symptoms and the need to seek medical attention promptly.

References

1. Jiang H, Stem MS, Finkelstein JJ. Branch retinal artery occlusion following radiation therapy to the head and neck: a case report. *BMC Ophthalmol.* 2013;13:66.
2. Lam WW, Leung SF, So NM, Wong KS, Liu KH, Ku PK, et al. Incidence of carotid stenosis in nasopharyngeal carcinoma patients after radiotherapy. *Cancer.* 2001;92(9):2357-63.
3. Jaworski A, Jaworski A, Wolffsohn JS. Ocular ischaemic syndrome. *Clin Exp Optom.* 2000;83(4):212-21.
4. Cheng SW, Wu LL, Ting AC, Lau H, Lam LK, Wei WI. Irradiation-induced extracranial carotid stenosis in patients with head and neck malignancies. *Am J Surg.* 1999;178(4):323-8.
5. Brown GC, Magargal LE. The ocular ischemic syndrome. Clinical, fluorescein angiographic and carotid angiographic features. *Int Ophthalmol.* 1988;11(4):239-51.
6. Tang Y, Luo D, Peng W, Huang F, Peng Y. Ocular ischemic syndrome secondary to carotid artery occlusion as a late complication of radiotherapy of nasopharyngeal carcinoma. *J Neuroophthalmol.* 2010;30(4):315-20.
7. Miller NR, Walsh FB, Hoyt WF. Walsh and Hoyt's clinical neuro-ophthalmology. 6th ed. Philadelphia: Lippincott Williams & Wilkins; 2005.
8. Ip JH, Fuster V, Badimon L, Badimon J, Taubman MB, Chesebro JH. Syndromes of accelerated atherosclerosis: role of vascular injury and smooth muscle cell proliferation. *J Am Coll Cardiol.* 1990;15(7):1667-87.