

Marshall University Marshall Digital Scholar

Internal Medicine

Faculty Research

1-2019

Case report: Steroid responsive mesothelioma-related pleural effusion

Mena Shehata

Marshall University, shehata@marshall.edu

Fouad Zaid

Marshall University

Peter Ottaviano

Marshall University

Yousef Shweihat

Marshall University, shweihat@marshall.edu

Nancy Munn

Marshall University, munn@marshall.edu

Follow this and additional works at: https://mds.marshall.edu/int_med



Part of the [Internal Medicine Commons](#), and the [Pulmonology Commons](#)

Recommended Citation

Shehata M, Zaid F, Ottaviano P, Shweihat Y, Munn N. Case report: Steroid responsive mesothelioma-related pleural effusion. *Respiratory medicine case reports*. 2019;26:131-5.

This Article is brought to you for free and open access by the Faculty Research at Marshall Digital Scholar. It has been accepted for inclusion in Internal Medicine by an authorized administrator of Marshall Digital Scholar. For more information, please contact zhangj@marshall.edu, beachgr@marshall.edu.



Case report

Case report: Steroid responsive mesothelioma-related pleural effusion

Mena Shehata^{a,*}, Fouad Zaid^{b,c}, Peter Ottaviano^c, Yousef Shweihat^b, Nancy Munn^{b,c}^a Department of Internal Medicine, Joan C. Edwards School of Medicine, Marshall University, Huntington, WV 25701, USA^b Department of Pulmonary Medicine, Joan C. Edwards School of Medicine, Marshall University, Huntington, WV 25701, USA^c Department of Pulmonary and Critical Care Medicine, Veterans Administration Medical Center, Huntington, WV 25701, USA

A B S T R A C T

Malignant pleural mesothelioma (MPM) is an asbestos-related tumor arising in the pleural cavity. Symptoms reflect extension of disease and include shortness of breath and chest pain. Unexplained pleural effusion and pleural pain in patients exposed to asbestos should raise the suspicion of MPM. The most common radiologic presentation is ipsilateral pleural effusion with or without pleural thickening or a mass. Thoracoscopic biopsy remains the most appropriate procedure for definitive diagnosis of mesothelioma. Despite advancement in diagnostic procedures and biomolecular research, this tumor nevertheless has poor prognosis. Mesothelioma remains a diagnostic and therapeutic challenge and is likely to remain one in the years to come.

Here we present the first reported case of steroid treatment responsive pleural effusion in a 72 year-old-male that initially was misdiagnosed as rheumatoid related effusion. However, Pleuroscopy with biopsy revealed mesothelioma.

1. Introduction

Malignant mesothelioma is a tumor arising from the mesothelial cells or sub-mesothelial cells of the pleura, peritoneum or pericardium, with more than 80% originate in the pleura [1]. The most common cause of diffuse malignant mesothelioma in the United States is inhalation of asbestos [2]. The latency from the time of exposure to the development of malignant mesothelioma is several decades [3]. Low-level exposures, as well as bystander are risk factors for the mesothelioma. No threshold of asbestos exposure has been established for the development of malignant mesothelioma [4]. Despite the fact that industrial use of asbestos was forbidden many years ago, new cases of mesothelioma continue to appear because of the long latency of the disease [5].

Here, we report a case of 72-years-old male with multiple admissions for pleuritic chest pain associated with recurrent exudative pleural effusions with dramatic response to steroids, initially misdiagnosed as connective tissue disease related pleural effusion. Yet it was found to be mesothelioma.

2. Case presentation

Herein a 72-year-old male patient with no significant past medical history apart from hyperlipidemia. He is a retired plumber and former Veteran. He quit smoking 38 years ago. He presented to the Emergency department (ED) with complain of worsening chest pain for few days that increased with deep inspiration. Pain was piercing in nature

affecting his right side, sometimes associated with cough but no concomitant shortness of breath. His vital signs at that time were within normal and his cardiopulmonary exam was unremarkable. Acute coronary syndrome was ruled out through negative troponin series and a normal EKG. Patient was diagnosed with pleurisy and was released home from ED with a NSAID along with short steroid taper.

Two weeks later the patient presented again with the same complain. Physical exam was unremarkable and initial laboratory results were significant for mild leukocytosis. Chest x-ray showed new right sided effusion with infiltrate versus consolidation (Fig. 1). Computed tomography of the chest with intravenous contrast ruled out pulmonary embolism yet it has showed a small right-sided pleural effusion as well as right lower lobe infiltration versus consolidation. Patient also had right hilar small lymphadenopathy on imaging and minimal pericardial effusion (Figs. 2–4).

Patient then was admitted to the hospital and was treated as community acquired pneumonia with intravenous ceftriaxone and Azithromycin. Patient was also started on intravenous methylprednisolone every six hours and ibuprofen as needed for pain control. The white-cell count on subsequent days has increased from 14.5×10^3 to $30.5 \times 10^3/\mu\text{L}$ on day 3. Antibiotics were escalated to intravenous vancomycin, Piperacillin and tazobactam. Pulmonary service was consulted for worsening leukocytosis in setting of pneumonia and parapneumonic pleural effusion. At that time patient symptoms had improved and there was no indication for aspiration because of minimal effusion and subjective improvement. The pulmonologist has recommended repeat chest scan in 8–12 weeks to reassess adenopathy

* Corresponding author.

E-mail address: shehata@marshall.edu (M. Shehata).

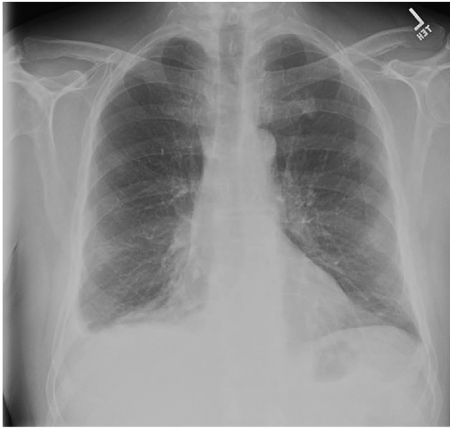

Fig. 1. Admission Plain radiograph with small pleural effusion.

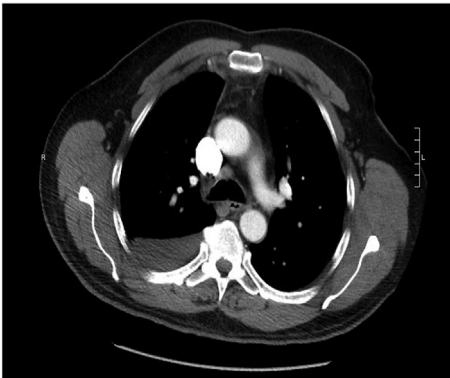

Fig. 2. CT mediastinal view of the chest with lymphadenopathy.

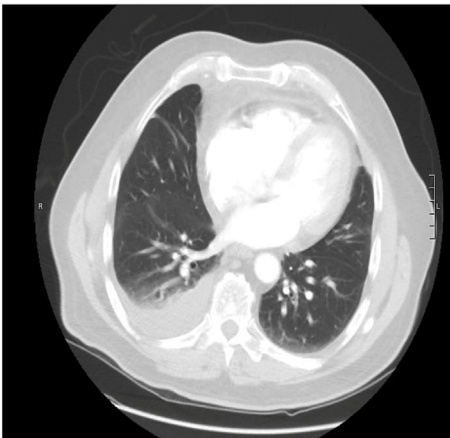

Fig. 3. Pleural effusion on the right.

and confirm resolution. His white count was attributed to steroid administration. He was discharged on oral antibiotics along with a prednisone taper upon improvement of his symptoms and labs.

Two weeks later the patient represented to ED with recurrence of his symptoms few days after he had finished his steroid course. Physical exam was significant for tachycardia 111 bpm and tachypnea, laboratory testing was significant for leukocytosis of $19.6 \times 10^3/\mu\text{L}$. EKG showed sinus tachycardia. Plain chest radiograph showed recurrence of pleural effusion in the right side (Fig. 5a). Repeat Chest CT showed worsening right pleural effusion along with progressive consolidative changes in the right lower lobe (Figs. 5b, 6 and 7). Patient was admitted and was started on intravenous vancomycin, Piperacillin, tazobactam as

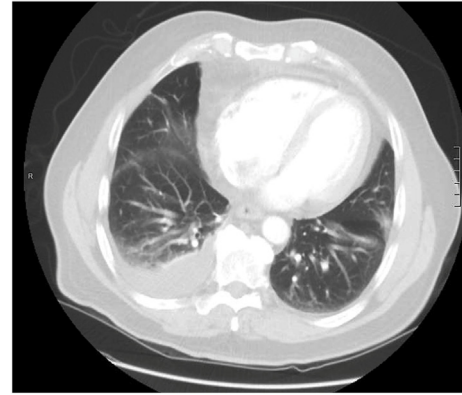


Fig. 4. Right lower lobe infiltrate.

well as methylprednisolone for presumed worsening pneumonia. Echocardiogram demonstrated normal biventricular function.

Pulmonary service was re-consulted who did bedside ultrasound on the next day showed very small right sided pleural effusion that is unsafe to tap. The dramatic improvement of pleural fluid after steroid treatment increased the suspicion of possible connective tissue disease as a cause. Connective tissue diseases work-up was done, revealed positive rheumatoid factor along with strongly positive Anti-cyclic citrullinated peptide (level > 70). Erythrocyte sedimentation rate C-reactive protein were both elevated 61 mm/hr and 260.4, respectively. ANA, ANCA profile and anti SCL-70 were negative. Before being discharged the pleural effusion as resolved (Fig. 8). He was discharged on prednisone 40 mg daily for two weeks until seen by pulmonary clinic for follow up.

Patient stopped the treatment as a repeat x-ray done in his primary care physician office after following up hospital visit showed complete resolution of his effusion (Fig. 8b).

Few days later, patient was due for his pulmonary clinic follow up and he complained of return of his pleurisy symptoms when he tapered steroid. At that time, he was restarted on a prolonged steroid taper starting at 60 mg of prednisone per day. Repeat chest scan for follow up on the hilar lymphadenopathy showed near normalization of the size of the lymph nodes and trace residual right pleural effusion (Fig. 8a and b). Also, right lower lobe infiltrate showed resolution compared to prior imaging. At that time the patient was still on steroid taper and was asymptomatic (see Fig. 9).

One month later the patient was seen in the pulmonary clinic for follow-up. Chest plain radiograph was normal and prednisone dose was further reduced to 10 mg. Yet few days later the patient developed pleuritic type chest pain and chest x ray showed re-accumulation of his pleural effusion at the emergency department (Fig. 10).

Patient refused admission and Video-Consult to pulmonary was done and patient was advised to restart on prednisone 40 mg until future appointment in the pulmonary clinic for thoracentesis. Due to the prolonged steroid course the patient was also started on Trimethoprim/Sulfamethoxazole for prophylaxis against pneumocystis. And patient returned to the pulmonary clinic one week later, and a repeat CXR showed decreased pleural effusion responding to steroid (Fig. 11). At that time, he was thought of as rheumatoid induced pleural effusion steroid responsive, yet no tapping has been done.

About one month later (4 months since initial presentation) while the patient was still taking 30 mg prednisone, his pleural effusion recurred, and first-time thoracentesis was done at the pulmonary clinic with inconclusive fluid studies. Gram stain was negative and culture later on had no growth. Patient was discharged on same treatment.

Patient developed atrial fibrillation with rapid ventricular rhythm and was admitted through another facility and chest x ray still had pleural effusion. Repeat thoracentesis results were exudative, Serum protein 6.7 g/dl, Serum LDH 149 (87-241 IU/L), Fluid LDH 851 IU/L,

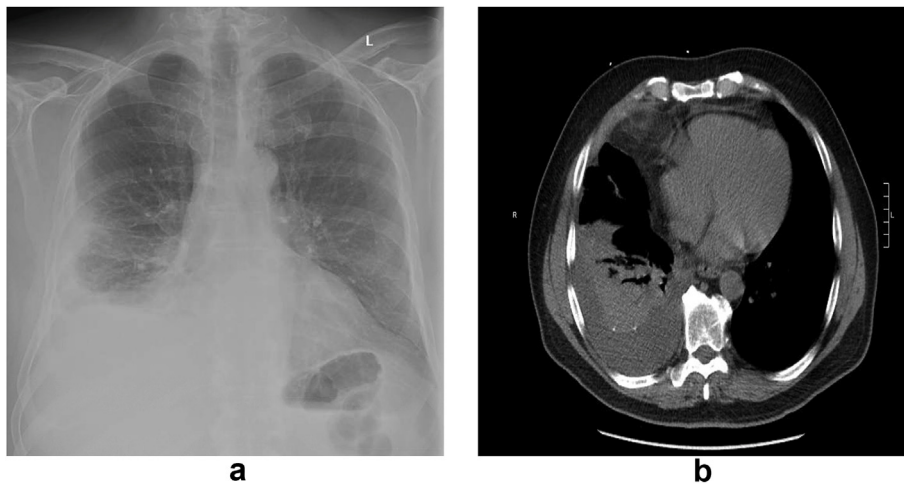


Fig. 5. Worsening pleural effusion (a and b).

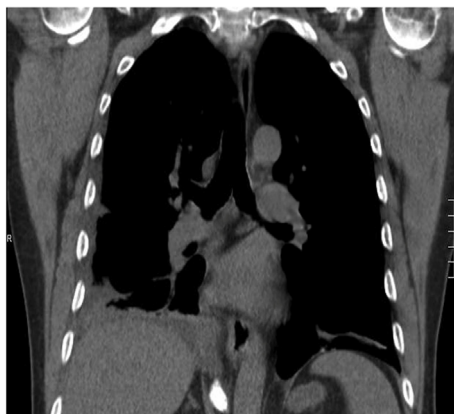

Fig. 6. Right middle lobe infiltrate.

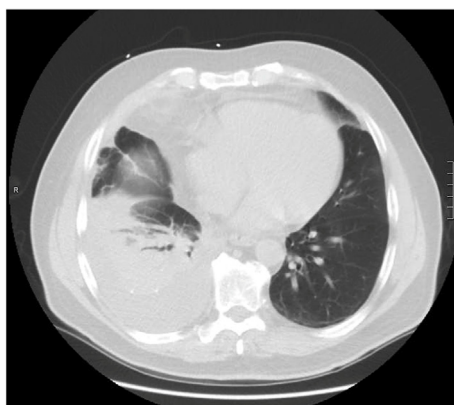

Fig. 7. Worsening right lower lobe infiltrate.

Negative microbiology, Fluid glucose 137 mg/dl, Fluid protein 3.2 g/dl, WBC $206 \times 10^3/\mu\text{L}$ (16 neutrophils, 12 monocytes, 60 lymphocytes), Cytology results came back with atypical cells present on both thoracentesis. Patient again was readmitted for therapeutic and diagnostic purposes from effusion recurrence. Third time thoracentesis done week later was same on analysis. Patient was referred for pleuroscopy with biopsy.

Pleuroscopy showed lots of loculations as well as adhesions. The parietal pleura was infiltrated with what seemed to be inflammatory tissue and had some areas of nodularity. Multiple biopsies were obtained from the parietal pleura. The entire surface of the parietal pleura

including some of the diaphragmatic pleura was involved. Visceral pleura was noted to be unaffected by gross exam. For his recurrent pleural effusion, a Pleurx catheter was left for drainage and symptomatic relief.

Pathological exam report was positive for a tumor consistent with mesothelioma (epithelioid type). Immunohistochemical stains performed. Results were of cells positive for Calretinin, CK5/6, CK7, and WT-1 but negative for Napsin-A, CK20, and TTF-1.

PET scan results revealed diffuse abnormal right pleural uptake consistent with history of mesothelioma with no evidence of disease elsewhere (Fig. 12).

Patient disease was classified as stage 1 as per the International Union Against Cancer (UICC) and the American Joint Committee on Cancer (AJCC) [6]. Patient was referred to a specialized cancer center for management.

3. Discussion

Despite the presence of some clinical and laboratory findings on review of the case, these can be as misleading if not carefully assessed. The differential diagnosis of this unexplained pleuropulmonary process includes collagen vascular disease, thromboembolic disease, and malignant tumors. The recurrent effusion that occurred in the absence of evidence of infection, as well as recurrent worsening chest pain that was reported by the patient on admissions in lieu of dramatic response to steroid on multiple occasions plus inability to do thoracentesis early made the diagnosis of the case challenging.

Pneumonia can be a cause of exudative pleural effusions especially if partially treated. Parapneumonic pleural effusion refers to pleural effusion associated with bacterial pneumonia, a pulmonary abscess or infected bronchiectasis [7]. This is less likely to be the case here since the patient symptoms didn't fit with this diagnosis. Also, his very rapid response to steroid treatment with marked regression of the effusion is less likely to happen with a parapneumonic effusion.

Patients with collagen vascular disease can initially present with recurrent pleural effusions [8]. Rheumatoid effusions are well described in the literature with pleural involvement is the most common thoracic manifestation of rheumatoid disease [9], yet the absolute incidence of rheumatoid pleural effusion is low. Especially with the presence of anti-rheumatoid factor and anti-Citrullinated peptide antibodies, rheumatoid disease is a high suspicion. Despite these suspicions the patient had no history of a rheumatoid disease. Additionally, in rheumatoid induced pleural effusion, one would see numerous polymorphonuclear leukocytes at the time of presentation and as the effusion matures a lymphocytic predominance can be appreciated [10]. Rheumatoid

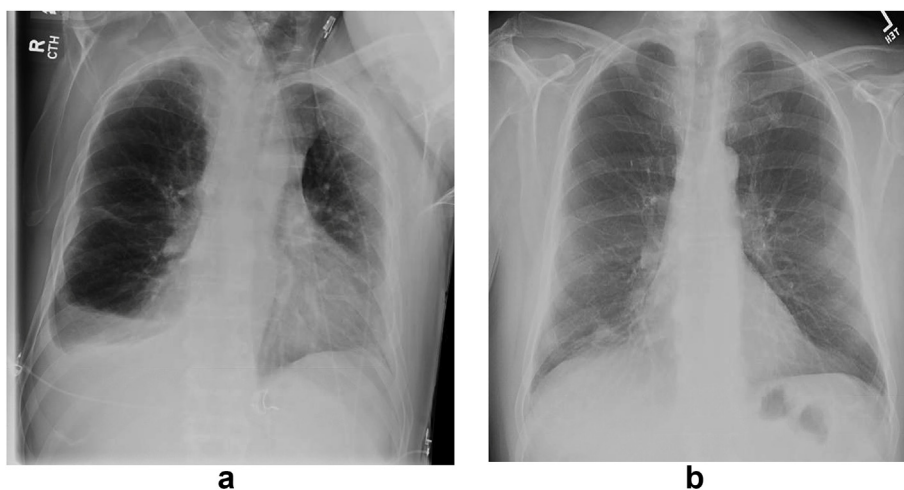


Fig. 8. Dramatic improvement of right-side pleural effusion at hospital (a) and then at the clinic (b).

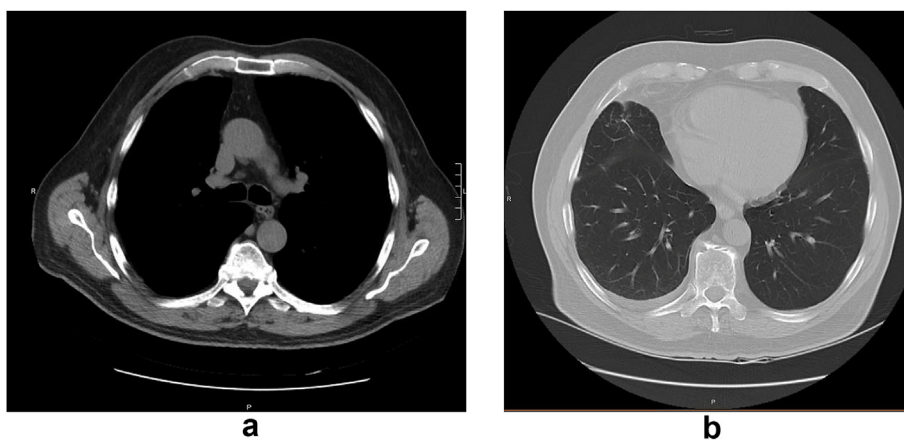


Fig. 9. CT scan showed regression of lymphadenopathy and near complete resolution of pleural effusion.

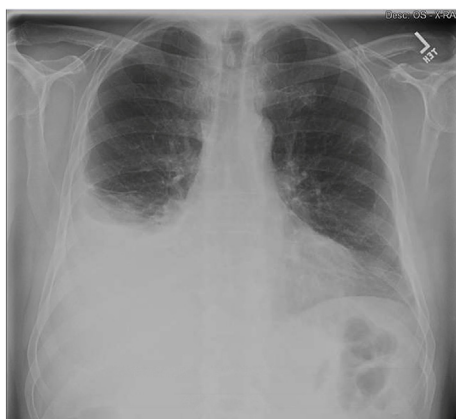

Fig. 10. Plain radiograph with recurrent moderate pleural effusion.

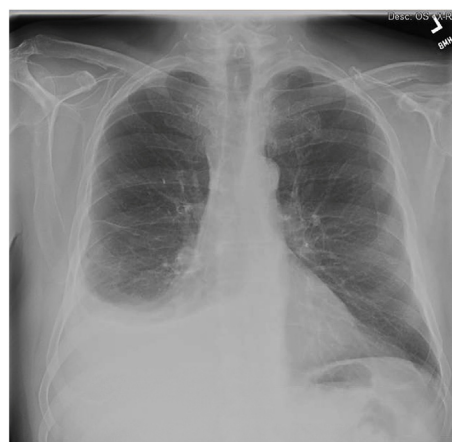

Fig. 11. Plain radiograph with decreasing right pleural effusion.

effusion is also characterized by low pleural fluid glucose level, usually less than 30 mg/dl [11]. His pleural effusion analysis was atypical of rheumatoid induced pleural effusion.

Malignant pleural effusion can result from primary malignancies of the pleura or with intrathoracic and extra-thoracic malignancies that reach the pleural space by hematogenous, lymphatic, or contiguous spread [9]. Lung carcinoma is the most common cause of chest pain and pleural effusions in this age group [8] These effusions are known as paraneoplastic or paramalignant pleural effusions [9]. Malignant

mesothelioma is a tumor arising from the mesothelial cells or sub-mesothelial cells of the pleura, peritoneum or pericardium, with more than 80% originate in the pleura [1]. The most common radiographical presentation is unilateral pleural effusion with or without ipsilateral pleural thickening or mass [12]. Only a small number of patients are asymptomatic at diagnosis, having an incidental detection of abnormality on imaging undertaken for a different reason [13]. Dyspnea is the first symptom of pleural mesothelioma cases [14,15]. Pleural

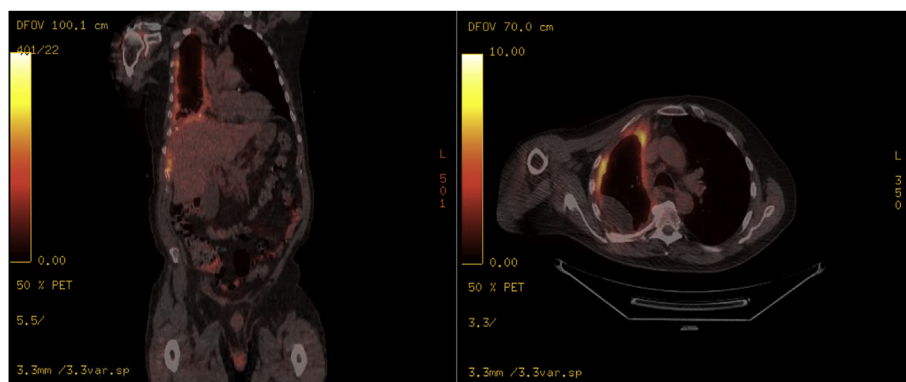


Fig. 12. Pet scan results with disease limited to pleura on the right side.

mesothelioma can cause pain by irritating intercostal nerves or by infiltrating into the chest wall. Rarer manifestations include phrenic nerve palsy, irritative cough, para-neoplastic phenomena, and spontaneous pneumothorax [16]. Malignant pleural effusion is often one of the primary manifestations of mesothelioma and can be found in about 90% of patients at diagnosis [17]. Effusion sampling obtained by thoracentesis and cytological examination is the most informative laboratory test for diagnosis. In patients who do not appear to have a history of asbestos exposure, mesothelioma should not be ruled out if other symptoms and signs of the disease are present. Unfortunately establishing the diagnosis of mesothelioma can be difficult. In malignant mesothelioma of the pleura, cytology displays a low sensitivity and is not an accurate assay in differentiating malignant cells from reactive mesothelial cells or lung cancer cells [18,19]. When nodular pleural thickening is present, a fine-needle biopsy can be performed to establish the diagnosis, but there is only a 25% chance that the biopsy will yield a diagnosis in the presence of a no diagnostic effusion. Video-assisted thoracoscopic surgery (VATS) is the diagnostic procedure of choice; it yields a diagnosis in more than 90% of cases.

Upon careful review of literature and to the best of our knowledge, we were unable to find any case report describing steroid responsive pleural effusion secondary to mesothelioma.

Declaration of conflicting interests

The author(s) declared no potential conflicts of interest with respect to the research, authorship, and/or publication of this article.

References

- [1] J. Kim, S. Bhagwandin, D.M. Labow, Malignant peritoneal mesothelioma : a review 5 (11) (2017) 1–11.
- [2] L. S. Welch, “Asbestos Exposure Causes Mesothelioma, But Not This Asbestos Exposure;,” no. 133178, pp. 318–327.
- [3] Y. Iwatsubo, J. Paireon, C.A. De Beaune, J. Bignon, P. Brochard, Pleural Mesothelioma : a Descriptive Analysis Based on a Case-Control Study and Mortality Data in Ile de 88 (1994) 77–88.
- [4] J.E. Craighead, Epidemiology of Mesothelioma and Historical Background, (2011).
- [5] V. Delgermaa, K. Takahashi, E. Park, V. Le, T. Sorahan, Global Mesothelioma Deaths Reported to the World Health Organization between 1994 and 2008,” No. January, (2011), pp. 716–724.
- [6] S. Amin MB, S.B. Edge, F.L. Greene, et al., AJCC (American Joint Committee on Cancer) Cancer Staging Manual, eighth ed., (2017).
- [7] H. Yu, Management of pleural effusion, empyema, and lung abscess 1 (212) (2011) 75–86.
- [8] R.L. Kradin, P. Fidiias, Case 17-2014 : a 64-year-old Man with Chest Pain and a Pleural Effusion, (2014).
- [9] D. Press, Pleural effusion: diagnosis, treatment, and management, (2012), pp. 31–52.
- [10] L.S. Avnon, M. Abu-Shakra, D. Flusser, D. Heimer, N. Sion-Vardy, Pleural effusion associated with rheumatoid arthritis: what cell predominance to anticipate? Rheumatol. Int. 27 (10) (2007 Aug 1) 919–925.
- [11] R. Article, Differential diagnosis of pleural effusions 49 (9) (2006) 315–319.
- [12] H.E. Fayed, V.K. Woodcock, J. Grayez, Simultaneous bilateral spontaneous hydro-pneumothorax : a rare presentation of bilateral malignant pleural mesothelioma, (2013), pp. 1–3.
- [13] A. Bianco, T. Valente, M.L. De Rimini, G. Sica, A. Fiorelli, Clinical diagnosis of malignant pleural mesothelioma 10 (7) (2018) 253–261.
- [14] A. Scherpereel, et al., Guidelines of the european respiratory society and the european society of thoracic surgeons for the management of malignant pleural mesothelioma 35 (3) (2010) 479–495.
- [15] O. Health, V. Neumann, S. Löseke, D. Nowak, F.J.F. Herth, A. Tannapfel, Malignant pleural mesothelioma 110 (2013) 18.
- [16] O. Article, Malignant Mesothelioma ± German Mesothelioma Register 1987 ± 1999, (2001), pp. 383–395.
- [17] M.C. Franceschini, et al., Mesothelin in Serum and pleural effusion in the diagnosis of malignant pleural mesothelioma with non-positive cytology 7430 (2014) 7425–7429 May 2013.
- [18] A. A. Renshaw, B. R. Dean, and K. H. Antman, “The role of cytologic evaluation of pleural fluid in the diagnosis of malignant mesothelioma *,” Chest, vol. 111, no. 1, pp. 106–109.
- [19] E.A. Rakha, et al., The sensitivity of cytologic evaluation of pleural fluid in the diagnosis of malignant mesothelioma 38 (2010) 12.