

Marshall University Marshall Digital Scholar

Internal Medicine

Faculty Research

2017

MRSA induced pulmonary-renal syndrome

Mohammed Megri

Marshall University, megri@live.marshall.edu

Majdi Al-dliw

Marshall University

Yousef Shweihat

Marshall University, shweihat@marshall.edu

Zeid Khitan

Marshall University, zkhitan@marshall.edu

Follow this and additional works at: https://mds.marshall.edu/int_med



Part of the [Internal Medicine Commons](#), [Nephrology Commons](#), and the [Pulmonology Commons](#)

Recommended Citation

Megri M, Al-dliw M, Shweihat Y, Khitan Z. MRSA induced pulmonary-renal syndrome. *Respiratory Medicine Case Reports*. 2017;20:42-44.

This Article is brought to you for free and open access by the Faculty Research at Marshall Digital Scholar. It has been accepted for inclusion in Internal Medicine by an authorized administrator of Marshall Digital Scholar. For more information, please contact zhangj@marshall.edu, beachgr@marshall.edu.



Case report

MRSA induced pulmonary-renal syndrome

Mohammed Megri^{a,*}, Majdi Al-dliw^a, Yousef Shweihat^b, Zeid Khitan^c^a Marshall University, USA^b Critical Care Medicine, Pulmonary, Interventional Pulmonary, Marshall University, USA^c Nephrology, Marshall university, USA

ARTICLE INFO

Article history:

Received 20 July 2016

Received in revised form

5 November 2016

Accepted 7 November 2016

Keywords:

ANCA

MRSA

Vasculitides

Pulmonary-renal syndrome

Diffuse alveolar hemorrhage

1. Introduction

It is no secret that the link between infection and vasculitis is well established even though the exact mechanism is still under study [1]. Infection, in addition to other factors, has been counted to trigger Vasculitis. The causal relationship has been documented only in few cases like Polyarthritus Nodosa (PNA)/Hepatitis B virus (HBV) and Cryoglobulinemia/Hepatitis C virus (HCV) cases [1]. There has also been an established link between Methicillin-Resistant-Staphylococcus aureus (MRSA) and Microscopic Polyangitis with perinuclear anti-neutrophils-cytoplasmic-antibody (P-ANCA) [2]. In addition, post MRSA infection IgA glomerulonephritis [2] is well described.

We present a rare case of pulmonary-renal syndrome secondary to recurrent MRSA spondylodiscitis. The mechanism of involvement of each organ system is unique. The organs, lung and kidneys, have been affected by different pathologic processes that were induced, we think, by the chronic MRSA infection.

2. Case report

Our patient is 37-years-old white morbid obese female. She

originally presented with MRSA spondylodiscitis at L3-L4 vertebral level and bilateral Psoas muscle abscesses. She was treated for 6 weeks with IV antibiotics with apparent resolution of symptoms. Two months after finishing her antibiotic regimen, the patient presented with worsening lower back pain for one-week duration. She has a previous history of IV drug abuse up until the episode of the initial infection but denies any recent abuse.

Her vitals were normal on ambient air. Leukocytosis of 11.9 and a chronic stable anemia with hemoglobin of 8.2 was noted on her initial blood count. Her creatinine and blood urea nitrogen were normal. Blood cultures were negative. Magnetic resonance imaging (MRI) of the spine (Fig. 1) showed persistent Spondylodiscitis at L3-4. There was persistent enhancement of the adjacent psoas muscles with associated phlegmon along the epidural space at L3-5 level. She was immediately re-started on Vancomycin. Surgical Drainage of the possible abscess was carried out in conjunction with spine stabilization. Culture of tissue obtained showed MRSA. Oral rifampin was added soon after the surgery. On the 9th day post admission patient developed gross hematuria and her renal function started to deteriorate. Urine studies suggested an intrinsic renal etiology with moderate proteinuria. The gross hematuria prevented urine microscopy from revealing casts or ruling their presence out. This was accompanied by hydronephrosis on abdominal imaging. Cystoscopy revealed clots in the ureters and bilateral ureteric bypass stents were inserted. Kidney function continued to deteriorate and she required hemodialysis. Initial work up for her hematuria and proteinuria was negative including negative P-ANCA, C-ANCA. Within 2 days of her cystoscopy she started to complain of progressive worsening dyspnea associated with oxygen desaturation. Her HGB further dropped by 2 g. Chest x-ray (Fig. 2) preformed and showed bilateral interstitial opacities suggestive of pulmonary edema. Patient continued to worsen despite repeated daily dialysis and had to be intubated for worsening respiratory distress. Lung protective ventilation was instituted immediately after intubation. Bronchoscopic alveolar lavage (BAL) was preformed and confirmed the suspicion of diffuse alveolar hemorrhage (DAH) with increasing blood content of the sequential aliquots from both right middle lobe and lingular segments. Pulmonary renal syndrome was considered and plasma exchange therapy (PLEX) with high dose steroids initiated. Vancomycin and rifampin were continued. Workup for pulmonary renal

* Corresponding author.

E-mail address: drmmegri@gmail.com (M. Megri).

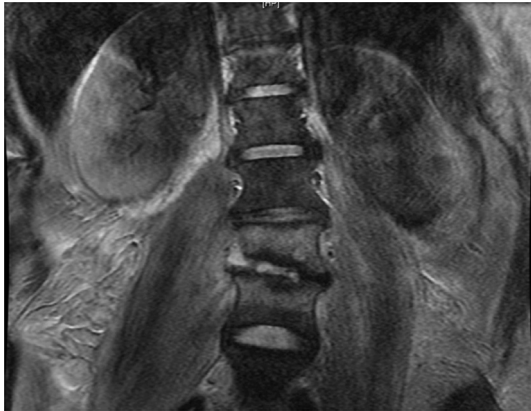


Fig. 1. MRI lumbar.

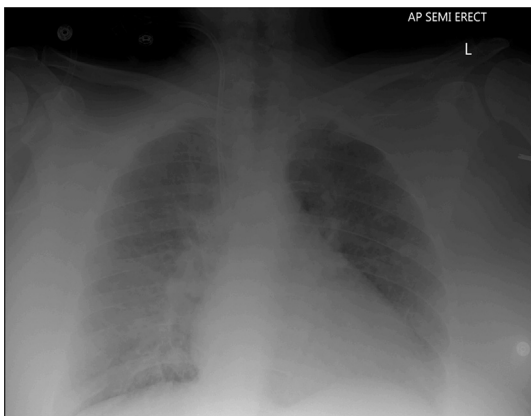


Fig. 2. Chest X ray.

syndrome revealed elevated C-ANCA levels that were previously normal. Patient showed dramatic improvement and she was weaned off the mechanical ventilation after the 4th session of PLEX (day 7 of mechanical ventilation). Renal biopsy was performed and showed features of acute tubular necrosis and immune complex deposits consistent with active staphylococcus infection-associated glomerulonephritis [11] (Figs. 3 and 4). Unfortunately her course of stay in the hospital worsened after weaning her steroids down and patient was admitted once more to intensive care unit (ICU) with

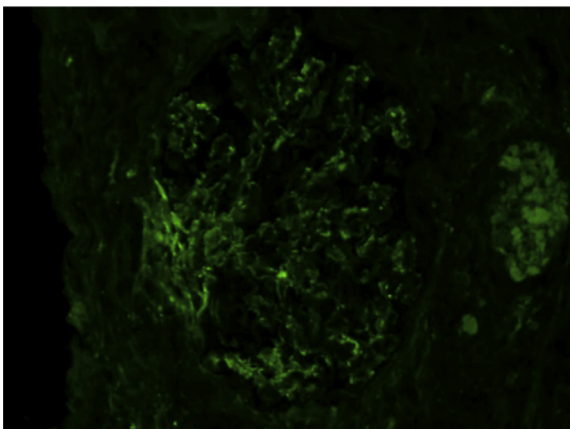


Fig. 3. Mild mesangial granular staining for C3.

worsening hypoxia and she was intubated. Repeat Bronchoscopy revealed recurrence diffuse alveolar hemorrhage. Steroids were initiated again with significant improvement. She was successfully extubated in 6 days and was eventually discharged home on oral steroids. No other immunosuppressive agents were used due to the infection status of the patient.

3. Discussion

Vasculitides are often serious and even fatal diseases that require rapid recognition [4]. They are defined by the presence of inflammatory leukocytes in vessel walls with reactive damage to mural structures. Both loss of vessel integrity leading to bleeding, and compromise of the lumen may result in downstream tissue ischemia and necrosis [3]. We can classify vasculitis according to the involved vessels location, type, size and ANCA positive or negative vasculitis [5]. Vasculitis may occur as a primary process or may be secondary to another underlying disease like infection. The exact pathogenic mechanisms underlying these diseases are unknown.

The ANCA associated vasculitis (AAV) include three groups of vasculitides; Microscopic polyangitis (MPA), granulomatosis with polyangitis (Wegener's)(GPA), and eosinophilic granulomatosis with polyangitis (Churg-Strauss) (EGPA) [5].

There are many bacterial and viral infections associated with different types of vasculitis. MRSA associated with microscopic polyangitis with P-ANCA is reported [2], as well as post MRSA infection IgA glomerulonephritis [2]. MRSA carriage or infection has been associated with cases of C-ANCA vasculitis (Wegener granulomatosis) [12–14]. We have not identified a case with the synchronous evolution of MRSA induced glomerulonephritis and DAH. Our case is unique given the development MRSA induced vasculitis and Pulmonary-renal syndrome. It makes it more unique that the occurrence of pulmonary renal syndrome was caused by 2 different mechanisms. In this case, glomerulonephritis represents post-infectious rather than pauci-immune mediated injury. This is evident by the mesangial hypercellularity as well as glomerular complement 3, and IgA deposition along with the classic sub-epithelial humps as shown in (Figs. 5 and 6) [10]. Although the DAH was not biopsy proven to be secondary to a vasculitis problem, we believe this was the case based on the rapid improvement with plasma exchange and use of steroids. The recurrence of the alveolar hemorrhage while patient was still on antibiotics and after weaning the steroids makes it more likely that the DAH was inflammation induced. The presence of C-ANCA antibodies and the response to PLEX and steroids are strong indicators of active vasculitis [7–9].

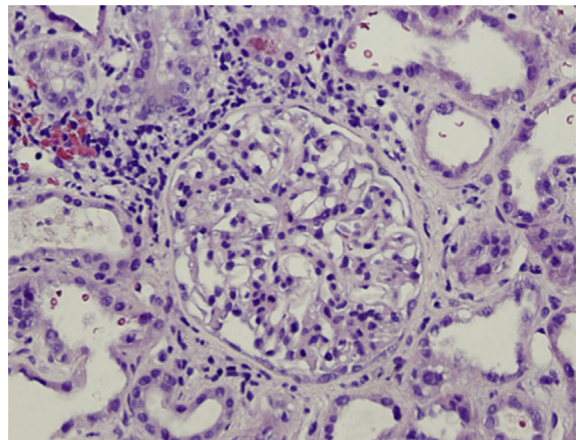


Fig. 4. Glomerulus with mesangial hypercellularity. H&E.

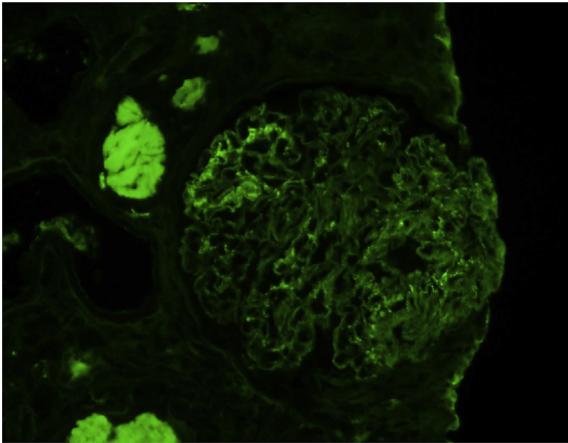


Fig. 5. Segmental granular glomerular IgA.

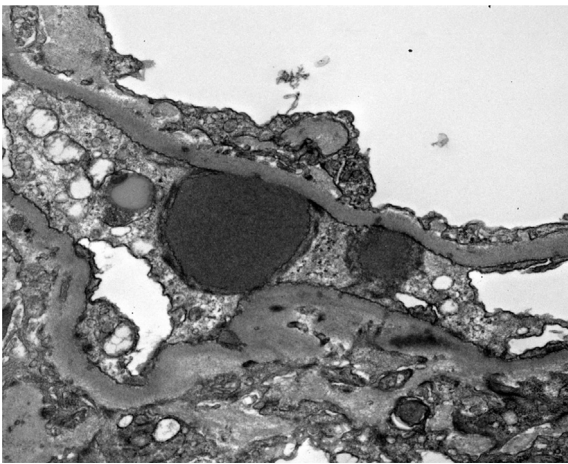


Fig. 6. Subepithelial humps.

The use of PLEX in AAV induced nephritis can lead to 24% reduction in the development of ESRD comparing to the conventional treatment with prednisone and cyclophosphamide [6–8]. The Use of PLEX in AAV associated alveolar hemorrhage and pulmonary renal syndrome can be life saving [14]. Other possible etiologies to the pulmonary-renal syndrome are possible, but very unlikely in this case. Drug induced renal injury is a well-known entity. They are unlikely the cause of the pulmonary renal syndrome based on the renal biopsy findings. In addition, none of her medications are known to induce ANCA vasculitis. The patient did not have any

other infection or known disease or drug exposure that would explain the alveolar hemorrhage. She is not known to have active rheumatologic disease and there was no sign of active heart failure to cause a bland hemorrhage. The lack of volume overload (repeated dialysis) or ARDS/diffuse alveolar damage evidenced by the rapid improvement in respiratory parameters make the diagnoses of ANCA associated DAH the only available clinical explanation. Our case has significant implications. It is the first to describe DAH related to immunologic response to MRSA infection. It also stresses the fact that multiple diseases can present due to the same etiology but with different mechanisms. Treatment of infection alone sometimes is not sufficient. Treating the deranged immunologic response to chronic infection is as important in improving patient outcomes. we hope our case will spark the interests of the readers and help spread the knowledge of the multiple effects of chronic bacterial infections.

References

- [1] <http://rheumatology.oxfordjournals.org/content/early/2009/03/03/rheumatology.kep026.full>.
- [2] A. Koyama, M. Kobayashi, N. Yamaguchi, K. Yamagata, K. Takano, M. Nakajima, F. Irie, M. Goto, M. Igarashi, T. Iitsuka, et al., Glomerulonephritis associated with MRSA infection: a possible role of bacterial superantigen, *Kidney Int.* 47 (1995) 207–216.
- [3] Vasculitis-Definition from the Merriam-Webster online dictionary.
- [4] J.C. Jennette, R.J. Falk, P.A. Bacon, et al., 2012 revised international chapel hill consensus conference nomenclature of vasculitides, *Arthritis Rheum.* 65 (2013) 1.
- [5] J.C. Jennette, R.J. Falk, K. Andrassy, et al., Nomenclature of systemic vasculitides. Proposal of an international consensus conference, *Arthritis Rheum.* 37 (1994) 187.
- [6] A.S. Bomback, G.B. Appel, ANCA-associated GN—to PLEX or not to PLEX? *Nat. Rev. Nephrol.* 9 (2013) 436–438.
- [7] H. Gallagher, J.T. Kwan, D.R. Jayne, Pulmonary renal syndrome: a 4-year, single-center experience, *Am. J. Kidney Dis.* 39 (1) (2002) 427.
- [8] A. Koyama, M. Kobayashi, N. Yamaguchi, K. Yamagata, K. Takano, M. Nakajima, F. Irie, M. Goto, M. Igarashi, T. Iitsuka, et al., Glomerulonephritis associated with MRSA infection: a possible role of bacterial superantigen, *Kidney Int.* 47 (1995) 207–216. Medline.
- [9] A. Koyama, S. Sharmin, H. Sakurai, Y. Shimizu, K. Hirayama, J. Usui, M. Nagata, K. Yoh, K. Yamagata, K. Muro, M. Kobayashi, K. Ohtani, Ta Shimizu, To Shimizu, *Staphylococcus aureus* cell envelope antigen is a new candidate for the induction of IgA nephropathy, *Kidney Int.* 66 (2004) 121–132.
- [10] Samih H. Nasr, Vivette D. D'Agati, IgA-dominant postinfectious glomerulonephritis: a new twist on an old disease, *Nephron Clin. Pract.* 119.1 (2011) c18–c26.
- [11] Samih H. Nasr, et al., Postinfectious glomerulonephritis in the elderly, *J. Am. Soc. Nephrol.* 22.1 (2011) 187–195.
- [12] Jose Cardenas-Garcia, et al., Wegener's granulomatosis in a middle-aged woman presenting with dyspnea, rash, hemoptysis and recurrent eye complaints: a case report, *J. Med. Case Rep.* 6.1 (2012) 1.
- [13] Philip J. Klemmer, et al., Plasmapheresis therapy for diffuse alveolar hemorrhage in patients with small-vessel vasculitis, *Am. J. Kidney Dis.* 42.6 (2003) 1149–1153.
- [14] K. Zycinska, et al., Co-trimoxazole and prevention of relapses of PR3-ANCA positive vasculitis with pulmonary involvement, *Eur. J. Med. Res.* 14.4 (2009) 1.