



Volume 2 | Issue 2

Manuscript 1031

2016

Management of co-existing lung cancer and endobronchal hamartomas

Mark H. Cooper, MD

Follow this and additional works at: <https://mds.marshall.edu/mjm>

 Part of the [Surgery Commons](#)

Recommended Citation

Cooper, MD, Mark H. (2016) "Management of co-existing lung cancer and endobronchal hamartomas," *Marshall Journal of Medicine*: Vol. 2: Iss. 2, Article 7.

DOI: <http://dx.doi.org/10.18590/mjm.2016.vol2.iss2.7>

Available at: <https://mds.marshall.edu/mjm/vol2/iss2/7>

DOI: <http://dx.doi.org/10.18590/mjm.2016.vol2.iss2.7>

Open Access | 

References with DOI

1. Lindner H, Willnow U. Simultaneous occurrence of Wilm's tumor and multiple lung hamartomas in a 15-year-old girl. *Z Kinderchir.* 1987. Apr;42(2):123-5. [https://doi.org/10.1016/s0022-3468\(88\)80519-0](https://doi.org/10.1016/s0022-3468(88)80519-0)
2. Mondello B, Lentini S, Buda C et al. Giant endobronchial hamartoma resected by fiberoptic bronchoscopy electrosurgical snaring. *Journal of Cardiothoracic Surgery.* 2011; 14:6:97. <https://doi.org/10.1186/1749-8090-6-97>
3. Gjerve JA, Myers JL, Prakash, UB. Pulmonary hamartomas. *Mayo Clinic Proceedings.* 1996;71: 14-20.
4. Cosio BG, Villena V, Echave-Sustaeta J et al. Endobronchial hamartoma. *Chest.* 2002;122: 202-205.
5. El-Kersh K, Perez RL, Gauhar U. A 63 year old man with a chronic cough and an endobronchial lesion. *Chest.* 2014; 145(4):919-922. <https://doi.org/10.1378/chest.13-1965>
6. Tomos P, Karaiskos T, Lahanas E. et al. Transverse bronchoplasty of the membranous wall after resection of an endobronchial hamartoma. *Annals of Thoracic surgery.* 2007;83:703-704. <https://doi.org/10.1016/j.athoracsur.2006.03.113>
7. Kang MW, Han JH, Yu JH et al. Multiple central endobronchial chondroid hamartoma. *Annals of Thoracic Surgery.* 2007;83(2):691-3. <https://doi.org/10.1016/j.athoracsur.2006.06.014>

Management of co-existing Lung Cancer and Endobronchial hamartomas

Mark H. Cooper, M.D.¹ and Brent A Grishkin, M.D.²

Author Affiliations:

1. Departments of Cardiothoracic Surgery, Marshall University, WV
2. Parkwest Hospital, Knoxville, TN.

The authors have no financial disclosures to declare and no conflicts of interest to report.

Corresponding Author:

Dr. Mark Cooper
Department of Surgery
Suite 2500, 1600 Medical Center Drive
Huntington, West Virginia
Email: cooperma@marshall.edu

Abstract:

The coexistence of lung cancer with another endobronchial malignant lesion is well known, although lung cancer with endobronchial hamartoma is infrequent, and requires accurate oncologic evaluation of the endobronchial lesion prior to potential surgical treatment of the lung cancer. These entities can lead to significant diagnostic confusion when encountered together and lead to inappropriate patient staging and treatment. We describe a patient with an undiagnosed endobronchial mass and a biopsy-proven lung cancer. She presented at another institution and was considered unresectable. She was then successfully managed by a staged approach using initial complete bronchoscopic resection of the endobronchial mass, which was found to be benign but completely obstructing the airway, and subsequent right upper lobectomy and mediastinal lymphadenectomy. The right upper lobe mass was squamous carcinoma and was ultimately stage 1A disease.

Key words: lung cancer, endobronchial hamartoma, asymptomatic

Introduction:

The survival of lung cancer patients as a group is still poor when compared to breast cancer, prostate cancer or colon cancer patients. Screening for lung cancer with low-dose computer tomography (CT) has improved survival by detection of early-stage cases. However, identification of additional abnormalities on CT scan can increase the complexity of preoperative planning. There will be a new cohort of patients who are found to have early stage lung cancer but yet have other pathology noted on the CT scan which require additional diagnostic tests and staging to ensure that patients are treated appropriately by surgical resection.

Bronchoscopy is an important tool in providing airway clearance by the surgeon prior to resection in lung cancer patients, since endobronchial abnormalities may be missed on screening CT studies.

Identification of an endobronchial mass in conjunction with a suspicious but otherwise resectable lung mass requires histopathologic diagnosis of the endobronchial lesion to ensure an oncologically adequate resection of the lung lesion. The endobronchial lesion may also cause postoperative complications due to bleeding or distal airway obstruction. Preoperative planning must adequately address these aspects of this association of endobronchial and parenchymal "mass lesions", since they may or may not be related to each other. Other cases of diagnostic dilemma have been described with other malignant lesions where the simultaneous occurrence of pulmonary hamartomas has necessitated thoracotomy and resection to obtain a final diagnosis.¹ In this case the bronchoscopy showed a lesion that was assessed, biopsied, found to be removable at the time of bronchoscopy, and resected using a snare technique, without the need for open surgical removal. This has been previously described in a case report as an isolated procedure to resect a similar giant endobronchial hamartoma causing airway obstruction by a well reputed group.² We describe a case of benign endobronchial hamartoma in conjunction with lung cancer which initially led to diagnostic confusion, but was ultimately resolved in two separate procedures to a satisfactory conclusion.

Case report:

A 63 year old Caucasian female with a reformed smoking history presented with an occasional dry cough for several months. Chest CT scan showed some minor right lower lobe atelectasis in addition to a right upper lobe pulmonary mass 1.8 x 1.4 cm, located medially in the upper lobe adjacent to the superior vena cava but with no radiographic evidence of mediastinal invasion. (Figure 1) Bronchoscopy by her pulmonologist noted a “polyp” in the bronchus intermedius. No attempt was made to biopsy the endobronchial lesion. The RUL lung lesion could not be accessed for biopsy but brushings, washings and lavage cytology were all non diagnostic. CT directed needle biopsy of the parenchymal lesion showed squamous carcinoma of the right upper lobe. Pet scan showed hypermetabolism in the right upper lobe mass and no evidence of mediastinal, endobronchial or distant hypermetabolism.

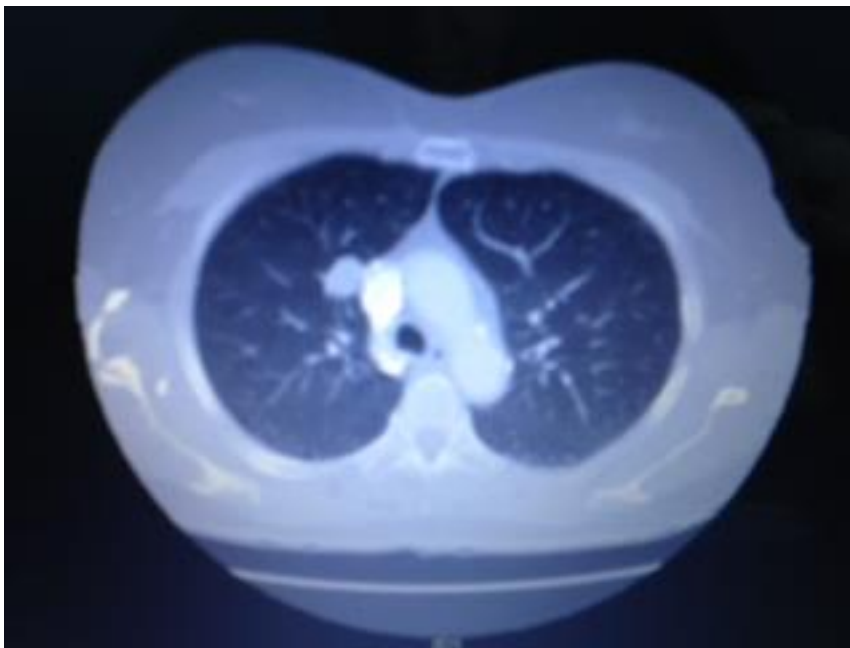

Figure 1:

Chest CT scan showing right upper lobe mass confirmed on biopsy to be non small cell carcinoma. Routine CT scanning was used and there was no evidence of endobronchial disease.

Right chest exploration was planned at another hospital; bronchoscopy following induction of general anesthesia visualized a hypervascular appearing endobronchial lesion completely obstructing the bronchus intermedius. Only a superficial biopsy was done because of concern regarding bleeding from the lesion; biopsy was non diagnostic. The operating surgeon consulted a pulmonologist to the operating room to also evaluate the bronchoscopic appearance of the lesion, and the planned thoracotomy and lobectomy were not attempted because of concerns regarding possible post operative obstruction in the bronchus intermedius due to the endobronchial lesion. The patient was then re-referred to our facility (MHC).

The patient continued to have a non productive cough, but denied fever, hemoptysis or chest discomfort. She had a 20 pack- year smoking history but had stopped smoking 20 years ago. Family history was positive for both lung cancer and breast cancer, and also for coronary artery disease. The patient had no personal history of COPD, cardiac disease, or visceral cancer. Past medical history included difficulty sleeping, restless leg syndrome and chronic low back pain for

which she received treatment at a pain clinic. She had occupational exposure to paint and also quarry work, but no asbestos exposure. Physical examination showed weight of 137 pounds and mild wheezing on the right. FEV1.0 was 2.17 and FVC was 2.61. Room air pulse oximetry declined to 95% following a six minute walk. The patient had never used oxygen at home and was able to climb a flight of stairs with relative ease. Preoperative hematocrit and blood chemistry values were normal.

At outpatient bronchoscopy the lesion in the bronchus intermedius was visualized (Figure 2A). It was noted that the lesion could be moved inside the airway and was attached to the airway by a stalk. After injection with epinephrine, the lesion was removed using hotwire cautery followed by argon plasma coagulation to the bed of the lesion (Figure 2B). There were no complications; intraoperative frozen section showed hamartoma. Final pathology showed no evidence of malignancy and confirmed the frozen section diagnosis of endobronchial hamartoma. After review of the now benign diagnosis of the endobronchial lesion and the clearance of her airway, the patient was readmitted to hospital one week later where she underwent right upper lobectomy and mediastinal lymph node dissection. She was discharged after 5 days without complications. Pathology showed a stage 1A squamous carcinoma in the resected right upper lobe, with no lymph node involvement. Oncology consultants recommended no further treatment. The patient was discharged home in five days with an uncomplicated postoperative course, and has returned to work. She remains well with an unremarkable postoperative CXR.

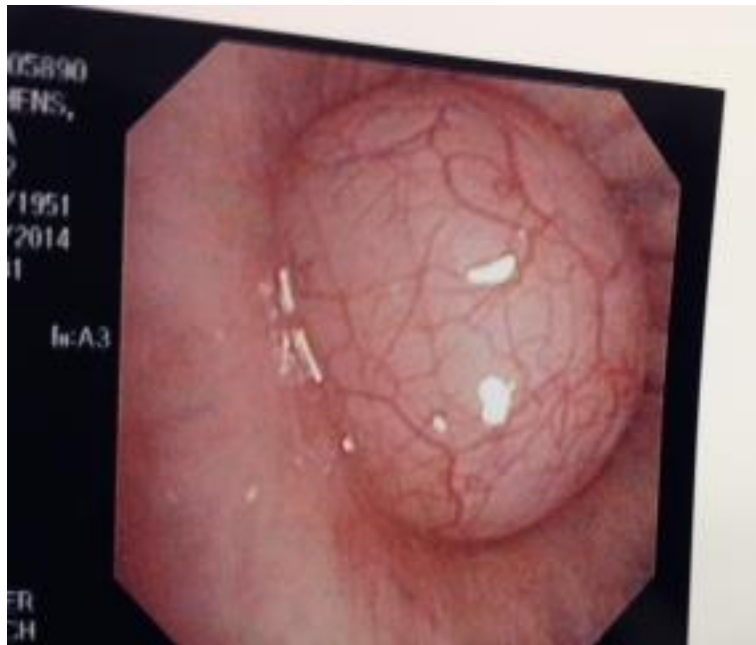

Figure 2A: Bronchoscopic view of the endobronchial lesion encountered during the bronchoscopic procedure performed at North Knoxville Medical Center. The Olympus bronchoscope is able to be passed around the lesion which is attached to the bronchial wall by a stalk.

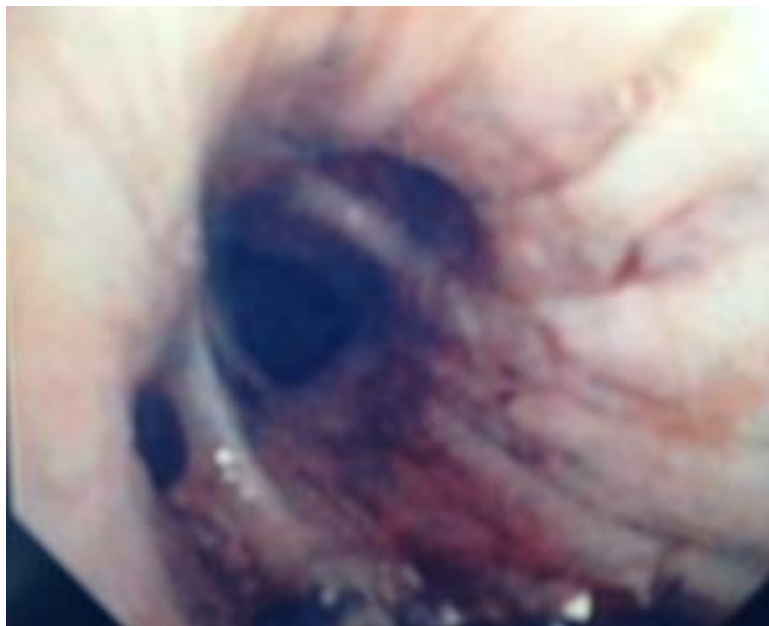


Figure 2B:

Bronchoscopic view of the airway after resection of the endobronchial hamartoma, including cauterization of the base. Olympus bronchoscope is passed into the right main stem bronchus. The airway is now free from obstruction after removal of the hamartoma. There is no evidence of inflammation in surrounding airway or distal to the lesion

Discussion:

Endobronchial hamartomas are uncommon tumors, comprising approximately 2% of all pulmonary hamartomas.³ As an isolated lesion, an endobronchial hamartoma is most often diagnosed by bronchoscopy during an evaluation of either recurrent respiratory infections, caused by airway obstruction by the hamartoma, or hemoptysis. In a series of 47 endobronchial hamartomas diagnosed by bronchial biopsy over a 23 year period at a tertiary level institution, only 7 were an incidental endoscopic finding during evaluation of a lung malignancy.⁴ Our patient had minimal symptoms despite the presence of a large lesion producing complete obstruction of the bronchus intermedius. On retrospective review of the CT scan there was nothing to suggest the presence of an endobronchial lesion; this reassures our knowledge that both fiberoptic bronchoscopy and high resolution scans are complementary in preoperative patient evaluation.

Endobronchial hamartomas have been removed using both rigid and flexible bronchoscopy, using laser resection, or resection with electrocautery snare and argon plasma coagulation of the base of the lesion,⁵ as was done in this case, or by an intrathoracic approach, using either bronchotomy and bronchoplasty⁶ or lobectomy or bilobectomy.^{4,7} With a known parenchymal malignancy requiring resection, an endobronchial mass requires diagnosis and then either preoperative or intraoperative removal to prevent post obstructive complications, and to ensure oncologic adequacy of the lung resection by verifying the benign nature of the endobronchial lesion. In this case, attempting to remove the hamartoma at the time of upper lobectomy would have necessitated at least a sleeve resection with sacrifice of the uninvolved middle lobe. At the time of bronchoscopy, we were unaware of the nature of the endobronchial lesion, but were pleasantly surprised by its non malignant nature and relative ease of removal. Thus preoperative management by bronchoscopy confirmed the benign nature of the lesion and reduced the risk of postobstructive obstruction of the remaining right lung following upper lobectomy. We will

continue to follow the patient both clinically and also bronchoscopically since recurrences of endobronchial hamartomas have been described.

Preliminary management of an endobronchial mass incidentally discovered during evaluation for a pulmonary parenchymal malignancy, using bronchoscopic techniques, prior to planned lung resection, will reduce the risk of postoperative obstructive symptoms, bleeding from the mass, or oncologic inadequacy of the resection by ensuring that the endobronchial lesion itself is benign. We believe that as CT screening is more widely adopted more instances of associated pulmonary lesions will become apparent. In this case however it was bronchoscopy that identified a lesion not noted on CT scan. The two techniques are considered complimentary to each other. Both bronchoscopy and CT scan findings will enhance the diagnostic challenges of identifying such lesions as benign or malignant. This is in a time when rapidly evolving technology has made it important to be as discerning as possible about co-existing abnormalities to save unnecessary procedures, and also to ensure that patients have appropriate procedures to enhance diagnostic accuracy. This may contribute to the progressively improving survival in lung cancer patients.

References

1. Lindner H, Willnow U. Simultaneous occurrence of Wilm's tumor and multiple lung hamartomas in a 15-year-old girl. *Z Kinderchir.* 1987. Apr;42(2):123-5.
2. Mondello B, Lentini S, Buda C et al. Giant endobronchial hamartoma resected by fiberoptic bronchoscopy electrocautery snaring. *Journal of Cardiothoracic Surgery.* 2011;14:6:97.
3. Gjerve JA, Myers JL, Prakash, UB. Pulmonary hamartomas. *Mayo Clinic Proceedings.* 1996;71:14-20.
4. Cosio BG, Villena V, Echave-Sustaeta J et al. Endobronchial hamartoma. *Chest.* 2002;122:202-205.
5. El-Kersh K, Perez RL, Gauhar U. A 63 year old man with a chronic cough and an endobronchial lesion. *Chest.* 2014;145(4):919-922.
6. Tomos P, Karaiskos T, Lahanas E. et al. Transverse bronchoplasty of the membranous wall after resection of an endobronchial hamartoma. *Annals of Thoracic surgery.* 2007;83:703-704.
7. Kang MW, Han JH, Yu JH et al. Multiple central endobronchial chondroid hamartoma. *Annals of Thoracic Surgery.* 2007;83(2):691-3.