

Marshall University Marshall Digital Scholar

Faculty Research

Marshall Institute for Interdisciplinary Research

10-1-2009

Acetaminophen Combinations Protect Against Iron-Induced Cardiac Damage in Gerbils

Ernest M. Walker Jr.
Marshall University

Ryan G. Morrison
Marshall University, morris27@marshall.edu


Lucy Dornon
Marshall University, dornon@marshall.edu

Joseph P. Laurino

Sandra M. Walker
Marshall Community and Technical College

See next page for additional authors

Follow this and additional works at: http://mds.marshall.edu/miir_faculty

 Part of the [Cardiovascular Diseases Commons](#), [Medical Biochemistry Commons](#), [Medical Microbiology Commons](#), and the [Medical Nutrition Commons](#)

Recommended Citation

Walker EM Jr., Morrison RG, Dornon L, Laurino JP, Walker SM, Studeny M, Wehner PS, Rice KM, Wu M, Blough ER (2009) Acetaminophen combinations protect against iron-induced cardiac damage in gerbils. *Ann Clin Lab Sci* 39:378–385.

This Article is brought to you for free and open access by the Marshall Institute for Interdisciplinary Research at Marshall Digital Scholar. It has been accepted for inclusion in Faculty Research by an authorized administrator of Marshall Digital Scholar. For more information, please contact zhangj@marshall.edu.

Authors

Ernest M. Walker Jr., Ryan G. Morrison, Lucy Dornon, Joseph P. Laurino, Sandra M. Walker, Mark Studeny, Paulette S. Wehner, Kevin M. Rice, Miaocong Wu, and Eric R. Blough

Acetaminophen Combinations Protect Against Iron-Induced Cardiac Damage in Gerbils

Ernest M. Walker, Jr.,^{1,2} Ryan G. Morrison,⁶ Lucy Dornon,² Joseph P. Laurino,⁹ Sandra M. Walker,⁷ Mark Studeny,^{2,10} Paulette S. Wehner,^{2,10} Kevin M. Rice,³⁻⁵ Miaozong Wu,⁵ Eric R. Blough,^{3-5,8}

¹Pathology, ²Cardiovascular Services, ³Pharmacology, Physiology, & Toxicology, ⁴Biological Sciences, ⁵Cell Differentiation & Development Center, ⁶School of Medicine, ⁷Community & Technical College, ⁸College of Education & Human Services, all at Marshall University, Huntington, WV; ⁹Chemistry Department, University of Tampa, Tampa, FL; and ¹⁰St. Mary's Medical Center, Huntington, WV

Abstract. This study tested if acetaminophen, N-methyl-D-glucamine dithiocarbamate (NMGDTC), deferoxamine, and combinations of these agents reduce excess iron content, prevent iron-induced pathology, reduce cardiac arrhythmias, and reduce mortality in iron-overloaded gerbils. Eight groups of 16 gerbils received iron dextran injections (ferric hydroxide dextran complex, 120 mg/kg, ip) or saline solution (controls) twice/wk for 8 wk. The 8 groups were treated every Monday, Wednesday, and Friday with one of the following: saline control, acetaminophen, 150 mg/kg, ip), acetaminophen (150 mg/kg, po), deferoxamine, 83 mg/kg, ip), NMGDTC (200 mg/kg, ip), or combinations of acetaminophen (75 mg/kg) with deferoxamine (42 mg/kg, each ip, separately) or acetaminophen (75 mg/kg) with NMGDTC (100 mg/kg, each ip, separately). The treatments were given 4 hr after each iron injection on days when both iron administration and treatment occurred during iron overloading (8 wk) and were continued 4 wk thereafter. Echocardiography (ECHO) was used to evaluate iron-induced cardiac changes and detect arrhythmias. Acetaminophen and NMGDTC, or combinations thereof, reduced cardiac and hepatic excess iron content as measured by inductively coupled plasma atomic emission spectrometry (ICP-AES). Acetaminophen was effective whether administered po or ip. Acetaminophen treatment had a positive inotropic effect on cardiac function. Acetaminophen-deferoxamine combination conferred equal cardioprotection as acetaminophen or deferoxamine alone, was equally able to remove hepatic iron, and was superior to either acetaminophen or deferoxamine in removing cardiac iron from iron-overloaded gerbils. Acetaminophen-NMGDTC combination was also effective in removing cardiac and hepatic iron and protecting against iron-induced cardiac damage. ECHO evaluation of iron-overloaded, untreated gerbils demonstrated a high incidence of cardiac arrhythmias, usually PVCs (10/16 = 63%), and mortality prior to completion of the experiment (4/16 = 25%). All treatments except deferoxamine, alone, reduced the incidence of cardiac arrhythmias and deaths. All treatments reduced iron-induced increases in hepatic and cardiac weights. This study demonstrates injection alternates that are equally or more effective than deferoxamine injections and shows oral acetaminophen to be effective in treatment of iron-overload and associated cardiac complications.

Keywords: iron-overload, acetaminophen, deferoxamine, N-methyl-D-glucamine dithiocarbamate

Introduction

Address correspondence to Ernest M. Walker, Jr., M.D., Ph.D., Department of Pathology, Joan C. Edwards School of Medicine, Marshall University, 1542 Spring Valley Drive, Huntington, WV 25704, USA; tel 304 654 9580; fax 304 696 6777; e-mail walkere@marshall.edu.

More than two million persons in the United States and up to one hundred million persons worldwide have some degree of iron-overload and tissue

accumulation of the metal [1]. It is estimated that nearly 40 million people worldwide have severe iron-overload. There are two major categories of conditions causing iron-overload: (a) hereditary hemochromatosis, an autosomal recessive disorder with a frequency of about 10% in individuals of European descent [2-4], and (b) various types of hemosiderosis involving RBC destruction and requiring blood transfusions [5]. In these cases, tissue iron levels progressively increase with age and may cause life-threatening complications. These include advanced liver disease and cirrhosis, diabetes mellitus due to iron accumulation in pancreatic islets with damage to beta cells, and cardiotoxicity due to iron deposits in myocytes, interstitial cells of the myocardium, and within the fibers of the conduction system. Cardiotoxic effects may be severe with cellular degeneration and fibrosis of the myocardium, disturbances of cardiac rhythm, and eventual death. Individuals with only mild to moderate elevations in tissue iron content appear to have increased risk for developing diabetes mellitus, heart disease, gastrointestinal cancers, and hematological malignancies [1].

Treatment with phlebotomy results in clinical improvement of subjects with established elevations in tissue iron burden and, if used as a preventative therapy, may lessen or ameliorate organ damage and allow normal life expectancy [1,6]. However, this treatment requires weekly removal of up to a liter of whole blood for a year or longer, followed by lifetime maintenance phlebotomy. Therapy with currently approved chelating agents is presently a poor substitute for phlebotomy and is used mainly in patients with secondary hemochromatosis or hemosiderosis. Deferoxamine (Desferal,[®] Novartis), deferiprone (L1), and deferasirox (Exjade,[®] Novartis) are the major chelating agents currently used to treat iron overload. Deferoxamine has been used for many years, but it must be administered by parenteral routes and is associated with adverse effects and low compliance [5, 7]. L1 (1, 2-dimethyl-3-hydroxypyridin-4-one), a once promising orally active iron chelator, appears to be ineffective [8] or contraindicated [9] in many patients. Deferasirox has recently been approved to treat iron-overloaded patients. It is orally effective and its long half-life enables once-daily dosing [10,11]. At present there

is a great clinical need for additional, orally active iron chelating drugs for treating iron overload.

Previous studies in our laboratory [12,13] demonstrated that injections of acetaminophen and deferoxamine are equally effective in reducing cardiac excess iron content in iron-overloaded gerbils, and preventing cardiac structural and functional changes. This paper reports concurrent studies of iron-overloaded gerbils, not published in the original paper [12], which show that injections of acetaminophen, deferoxamine, or N-methyl-D-glucamine dithiocarbamate (NMGDTC), as well as combinations of acetaminophen with deferoxamine or NMGDTC reduce the excess iron content in heart and liver and protect against iron-induced cardiotoxicity in iron-overloaded gerbils.

Materials and Methods

Chemicals. Ferric hydroxide dextran complex (Sigma Chemical Co., St Louis, MO) dissolved in NaCl solution (1%, w/v) was used for iron overloading. The treatment agents were: (a) acetaminophen (Sigma), (b) deferoxamine methanesulfonate (Sigma), and (c) NMGDTC, synthesized as described [14] and supplied by Dr. Mark M. Jones (Vanderbilt University, Nashville, TN).

Animals. Mongolian golden gerbils (Hilltop Laboratories, Scottsdale, PA; male; age 12 wk; average initial weight ~60 g) were housed on wood chip bedding in plastic tubs at 23 ± 2°C in rooms with a 12 hr light/dark cycle. Purina gerbil chow and tap water were available ad libitum. All procedures with animals were approved by the Marshall University Institutional Animal Care and Use Committee.

Treatments. The gerbils were divided into 8 groups of 16 animals: (a) saline controls (SC) received injections of 1% saline (0.15 ml/kg, ip) twice/wk for 8 wk; (b) iron-overloaded animals (IO) received similar injections of iron dextran in 1% saline (120 mg/kg, ip, twice/wk); (c) iron-overloaded treated with acetaminophen (150 mg/kg, ip, IOAi); (d) iron-overloaded treated with acetaminophen (150 mg/kg, po, IOAo); (e) iron-overloaded treated with deferoxamine (83 mg/kg, ip, IODF); (f) iron-overloaded treated with NMGDTC (200 mg/kg, ip, IONMG); (g) iron-overloaded treated with half-doses of acetaminophen (75 mg/kg) and deferoxamine (42 mg/kg) given separately as ip injections (IOA0.5NMG0.5); and (h) iron-overloaded treated with half-doses of acetaminophen (75 mg/kg) and NMGDTC (100 mg/kg) given separately as ip injections (IOA0.5DF0.5). The saline and iron dextran solutions were injected twice/wk for 8 wk. The acetaminophen, deferoxamine, NMGDTC, and combinations were administered thrice/wk (every Monday, Wednesday, and Friday). When an iron dextran injection and drug treatment fell on the same day, the treatment was administered 2 to 4 hr

after the iron dextran. The treatments followed this schedule for 8 wk and were continued for an additional 4 weeks (total of 12 wk of treatment). Echocardiograms were performed on gerbils at 12 wk after the last treatment.

Echocardiography (ECHO). ECHO studies were conducted on gerbils anesthetized by ip injection of a 2:1 (v/v) mixture of ketamine HCl (100 mg/ml) and xylazine (20 mg/ml). The ECHO studies used a Phillips Sonos 5500 echocardiogram with a S12 transducer (frequency range 8-12 MHz) as described previously [12]. Echocardiographic images were obtained including two-dimensional, pulse-wave Doppler and M-mode images. Functional and structural parameters were evaluated as described previously [12,14].

Tissue iron analysis. After completion of the echocardiograms, the gerbils were euthanized by inhalation of CO₂. The hearts and livers were removed by dissection, weighed, frozen in liquid nitrogen, and stored at -70°C until analysis. Whole hearts and liver samples (300-400 mg) were digested at 37°C for 6 or 17 hr in glass digestion tubes containing concentrated ultrapure nitric and perchloric acids (30:70, v/v, total volume 10 ml). A 1.67 mg/L iron solution was used as a digestate control. Yttrium solution (1,000 mg/L) in 2% HNO₃ was added to each tube and served as an internal standard (final concentration, 1.67 mg/L). After digestion, 5.0 ml of each digestate was transferred to a 50 ml volumetric flask and brought to volume with 2% HNO₃ (ultrapure). The solutions were filtered through 0.22 µm syringe-driven filter units (Millipore). Tissue iron concentrations were determined by inductively coupled plasma/atomic emission spectrometry (ICP-AES), using an Optima 2100 apparatus (Perkin-Elmer, Norwalk, CT; 238 and 204 nm). Standard curves (0 to 1; 0 to 10; 0 to 100 mg Fe/L) were prepared depending on the tissue iron concentrations [15-18] and the results were reported as mg Fe/entire liver or µg Fe/entire heart.

Statistics. Data were expressed as mean ± SD. Statistical analyses were performed using Sigma Stat software (Jandel Corp., San Rafael, CA). Differences among the means of the groups were assessed by two-way ANOVA, followed by Tukey's test. Values of p < 0.05 were considered significant.

Results

Effects on cardiac and liver iron. Injections ip of acetaminophen, deferoxamine, or NMGDTC, alone, and acetaminophen-deferoxamine or acetaminophen-NMGDTC combinations reduced the excess cardiac and hepatic iron contents (Fig. 1). Oral administration of acetaminophen also reduced tissue iron content and ameliorated cardiac effects. The post-treatment hepatic iron contents were: SC, 0.24 ± 0.02 mg; IO, 49.05 ± 1.46 mg; IOAi, 37.40 ± 6.78 mg; IOAo, 33.98 ± 6.34 mg; IODF, 20.20 ± 1.64 mg; IONMG, 18.31 ± 1.07 mg; IOA0.5-

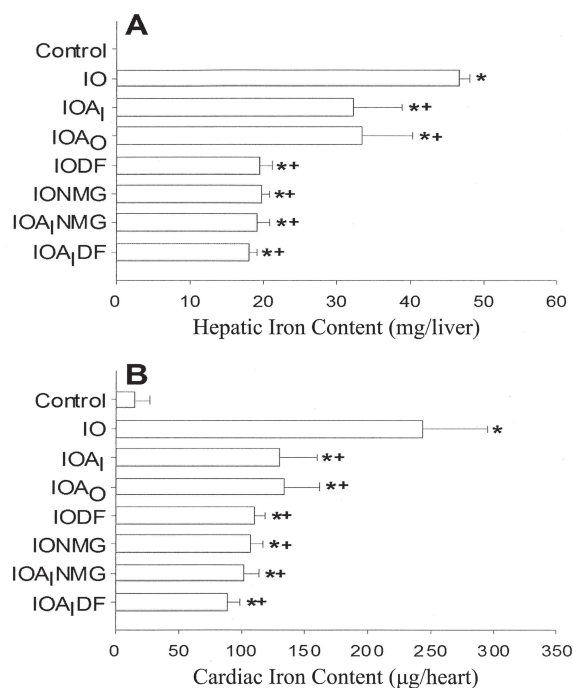


Fig. 1. The iron content of liver (mg/entire liver) (panel A) and heart (µg/entire heart) (panel B) of saline controls (n = 13), and gerbils that were iron overloaded (IO, n = 13), acetaminophen injected (IOAi, n = 9), acetaminophen administered by oral gavage (IOAo, n = 10), deferoxamine injected (IODF, n = 7), NMGDTC injected (IONMG, n = 8), acetaminophen (half-dose) plus NMGDTC (half-dose) injected (IOAiNMG, n = 8), and acetaminophen (half-dose) plus deferoxamine (half-dose) injected (IOAiDF, n = 8). The * or + indicate significant differences (p < 0.05) from the controls or iron overloaded gerbils, respectively.

NMG0.5, 18.93 ± 1.93 mg; IOA0.5DF0.5, 18.24 ± 1.04 mg. The post-treatment cardiac iron contents were: SC, 15.11 ± 11.77 µg; IO, 243.36 ± 51.08 µg; IOAi, 130.38 ± 29.58 µg; IOAo, 131.76 ± 26.62 µg; IODF, 110.50 ± 7.47 µg; IONMG, 106.34 ± 10.59 µg; IOA0.5NMG0.5, 101.39 ± 12.36 µg; IOA0.5DF0.5, 88.53 ± 9.21 µg. The average post-treatment cardiac iron concentrations per g of heart were: SC, 43.17 ± 27.81 µg; IO, 552.27 ± 58.12 µg; IOAi, 395.09 ± 88.10 µg; IOAo, 387.52 ± 66.44 µg; IODF, 324.99 ± 23.95 µg; IONMG, 304.00 ± 17.40 µg; IOA0.5NMG0.5, 316.84 ± 59.04 µg; IOA0.5DF0.5, 268.27 ± 25.38 µg.

The best results for cardiac iron removal were produced by the ip injection combination of half-doses of acetaminophen (75 mg/kg) and deferoxamine (42 mg/kg) (IOA0.5DF0.5), which removed

Table 1. Echocardiographic evaluation of cardiac structural parameters in gerbils.

Group	N	IVSd (cm)	IVSs (cm)	LVIDd (cm)	LVIDs (cm)	LVPWd (cm)	LVPWs (cm)	RV (cm)
Control	16	0.09 ± 0.01	0.15 ± 0.01	0.43 ± 0.01	0.27 ± 0.01	0.11 ± 0.01	0.14 ± 0.01	0.14 ± 0.01
IO	15	0.13 ± 0.01*	0.19 ± 0.01*	0.53 ± 0.02*	0.35 ± 0.01*	0.17 ± 0.01*	0.19 ± 0.01*	0.20 ± 0.01*
IOAi	9	0.09 ± 0.01 ⁺	0.14 ± 0.01 ⁺	0.44 ± 0.01 ⁺	0.30 ± 0.01* ^{+,+}	0.11 ± 0.01 ⁺	0.15 ± 0.01 ⁺	0.12 ± 0.01 ⁺
IOAo	10	0.09 ± 0.02 ⁺	0.15 ± 0.02 ⁺	0.48 ± 0.02 ⁺	0.31 ± 0.02* ^{+,+}	0.10 ± 0.01 ⁺	0.16 ± 0.02 ⁺	0.12 ± 0.02 ⁺
IODF	7	0.10 ± 0.01 ⁺	0.15 ± 0.01 ⁺	0.43 ± 0.02 ⁺	0.27 ± 0.01 ⁺	0.12 ± 0.01 ⁺	0.15 ± 0.01 ⁺	0.14 ± 0.01 ⁺
IONMG	8	0.11 ± 0.01 ⁺	0.16 ± 0.02 ⁺	0.44 ± 0.02 ⁺	0.30 ± 0.03 ⁺	0.12 ± 0.02 ⁺	0.16 ± 0.02 ⁺	0.15 ± 0.03 ⁺
IOAiNMG	8	0.08 ± 0.02 ⁺	0.13 ± 0.02 ⁺	0.49 ± 0.06	0.32 ± 0.04	0.12 ± 0.02 ⁺	0.16 ± 0.02 ⁺	0.11 ± 0.01 ⁺
IOAiDF	8	0.10 ± 0.01 ⁺	0.15 ± 0.01 ⁺	0.46 ± 0.05	0.32 ± 0.03	0.12 ± 0.02 ⁺	0.15 ± 0.02 ⁺	0.12 ± 0.03 ⁺

An asterisk (*) or cross (†) indicates significant difference (p < 0.05) from control and iron-overloaded (IO) gerbils, respectively. N, number of gerbils in the group; IVSd, diastolic LV septal thickness; IVSs, systolic LV septal thickness; LVIDd, diastolic LV internal thickness; LVIDs, systolic LV internal thickness; LVPWd, diastolic LV posterior wall thickness; LVPWs, systolic LV posterior wall thickness; RV, RV diastolic internal dimension.

Table 2. Echocardiographic evaluation of cardiac functional parameters in gerbils.

Group	EF (%)	FS (%)	AV Max (cm/sec)	PV Max (cm/sec)	MV Max (cm/sec)	MV Max (cm/sec)
Control	77.5 ± 1.5	40.4 ± 1.5	47.2 ± 2.5	48.9 ± 3.2	41.0 ± 3.9	40.3 ± 2.6
IO	60.6 ± 1.8*	27.9 ± 1.3*	49.8 ± 2.4	52.9 ± 4.2	38.0 ± 3.7	38.1 ± 3.1
IOAi	72.5 ± 1.7* ^{+,+}	35.0 ± 2.0* ^{+,+}	70.4 ± 4.0* ^{+,+}	66.2 ± 4.4* ^{+,+}	50.7 ± 2.9* ^{+,+}	51.0 ± 4.0* ^{+,+}
IOAo	76.4 ± 1.7 ⁺	39.3 ± 1.3 ⁺	58.6 ± 3.3* ^{+,+}	58.1 ± 4.0*	44.3 ± 3.4	37.0 ± 1.8
IODF	67.1 ± 1.1* ^{+,+}	34.1 ± 2.4* ^{+,+}	53.4 ± 3.9	47.6 ± 3.2	39.8 ± 3.2	37.6 ± 2.3
IONMG	69.6 ± 5.0* ^{+,+}	34.0 ± 3.7* ^{+,+}	54.9 ± 9.6	45.9 ± 6.1	-----	-----
IOAiNMG	70.4 ± 4.0*	34.8 ± 3.2*	60.2 ± 8.2 ⁺	57.1 ± 5.0	-----	-----
IOAiDF	64.8 ± 10.4*	29.7 ± 7.3*	48.6 ± 6.6	44.7 ± 5.0	-----	-----

An asterisk (*) or cross (†) indicates significant difference (p < 0.05) from control and iron overloaded (IO) gerbils, respectively. EF, ejection fraction; FS, left ventricular fractional shortening during systole; AV Max, maximal aortic valvular blood flow velocity; PV Max, maximal pulmonary valvular blood flow velocity; MV Max, maximal mitral valvular blood flow velocity; TV MAX, maximal tricuspid valvular blood flow velocity.

Table 3: Body weights, liver weights/body weights, and heart weights/body weights of the gerbils.

Group	Body wt. (g)	Liver wt./body wt. (%)	Heart wt./body wt. (%)
Control	83.7 ± 2.2	3.77 ± 0.46	0.41 ± 0.03
IO	66.9 ± 2.6	7.80 ± 0.86*	0.65 ± 0.12*
IOAi	85.3 ± 2.4	5.44 ± 0.36* ^{+,+}	0.43 ± 0.04 ⁺
IOAo	84.2 ± 2.3	5.14 ± 0.20* ^{+,+}	0.40 ± 0.01 ⁺
IODF	92.6 ± 5.6	4.78 ± 0.28* ^{+,+}	0.37 ± 0.01 ⁺
IONMG	85.5 ± 2.7	5.23 ± 0.22* ^{+,+}	0.39 ± 0.03 ⁺
IOAiNMG	84.4 ± 4.5	5.11 ± 0.12* ^{+,+}	0.39 ± 0.03 ⁺
IOAiDF	92.3 ± 2.3	4.25 ± 0.05* ^{+,+}	0.33 ± 0.02* ^{+,+}

Average group and organ/body weights at the end of the experiments. An asterisk (*) or cross (†) indicates significant difference (p < 0.05) from control and iron overloaded (IO) gerbils, respectively. See Materials and Methods for abbreviations.

significantly more cardiac iron ($p < 0.05$) than was removed by full-dose injections of either acetaminophen (150 mg/kg) or deferoxamine (83 mg/kg) alone. The cardiac iron removal produced by the combination of half-doses of acetaminophen and NMGDTC (100 mg/kg) (IOA0.5EY0.5) was not significantly greater than that removed by full-doses of either agent alone. Combinations of half-doses of acetaminophen and deferoxamine (IOA0.5DF0.5) removed slightly more hepatic iron than either agent alone, but the results were not significant when compared to deferoxamine alone.

Echocardiographic studies. The ECHO results for control, iron-overloaded, iron-overloaded-acetaminophen-treated and iron-overloaded-deferoxamine-treated gerbils are reported in Tables 1 and 2 and in the earlier publication [12]. Iron-overloading affected structural parameters of the heart, increased total cardiac weight, and produced cardiac hypertrophy as shown by increased septal, left ventricular, and right ventricular wall thicknesses. These changes were abrogated by treatments with acetaminophen or its combinations.

Cardiac function was evaluated by measurements of ejection fraction (EF) and left ventricular shortening during systole (FS), as well as blood flow velocities through cardiac valves. Hearts from iron-overloaded gerbils demonstrated reductions in EF and FS consistent with appreciable compromise of cardiac function. Acetaminophen, given orally or by injection, prevented these changes or restored cardiac function to values similar to untreated controls. An interesting result of acetaminophen treatment was increased blood flow rates through cardiac valves (aortic, pulmonary, mitral, tricuspid) (Table 2), which suggest a positive inotropic effect conferred by injected acetaminophen. This finding may be important and merits further study.

ECHO studies were concurrently completed for the iron-overloaded-acetaminophen (75 mg/kg) plus deferoxamine (42 mg/kg), iron-overloaded-NMGDTC (200 mg/kg), and iron-overloaded-NMGDTC (100 mg/kg) plus deferoxamine (42 mg/kg) groups. The results demonstrate cardio-protection against the iron-induced functional and structural changes similar to the protection provided by acetaminophen alone (Tables 1 & 2).

Arrhythmias and mortality. During the total period of observation of the 16 saline controls (SC), none developed cardiac arrhythmias (ECHO studies) and there were no deaths. Of 16 iron-overloaded gerbils, 10 developed significant cardiac arrhythmias, ie, chiefly premature ventricular contractions (PVCs), and 4 of the 16 gerbils died after completion of ECHOs and prior to the end of the experiment. Nine of 16 iron-overloaded gerbils treated by acetaminophen, ip (IOAi) were evaluated by ECHO and showed 0 cardiac arrhythmias (ECHO) and 1 death. Ten of 16 iron-overloaded gerbils treated orally with acetaminophen (IOAo) were evaluated by ECHO and demonstrated 1 animal with cardiac arrhythmia (PVCs) and 0 deaths. Seven of the 16 iron-overloaded gerbils treated with deferoxamine ip were evaluated by ECHO and 3 animals showed cardiac arrhythmias (PVCs), and died prior to the end of the experiment. Eight of 16 NMGDTC injected gerbils were evaluated by ECHO and there was 1 animal with cardiac arrhythmia and 1 death (same animal). Eight of 16 animals treated with half-doses of acetaminophen plus half-doses of deferoxamine were evaluated by ECHO and 1 animal demonstrated cardiac arrhythmia but 0 deaths. Eight of 16 gerbils treated with half-doses of acetaminophen plus half-doses of NMGDTC and evaluated by ECHO showed 1 animal with cardiac arrhythmia but there were 0 deaths. All treatments except deferoxamine produced appreciable reductions in the incidence of iron-induced cardiac arrhythmias and mortality.

Iron overloading was very toxic to the gerbils. Iron overloading caused a high incidence of arrhythmias (10/16), mortality (4/16), suppression of weight gain, and increased heart and liver weights as shown in Table 3. Initial body weights of the gerbils averaged about 60 g. All groups except the untreated iron-overloaded gerbils showed weight increases of 20 g or more at 12 wk. The untreated iron-overloaded group gained an average of -7 g.

Discussion

Acetaminophen is a frequently used non-steroidal anti-inflammatory analgesic agent. Deferoxamine is an established iron-removing agent with great

effectiveness when administered parenterally. NMGDTC is a substituted dithiocarbamate (LD₅₀ >2 g/kg in mice) that has been reported to combat the platinum toxicity seen in the use of cisplatin in cancer chemotherapy [19]. It has also been shown to have iron-chelating ability [20,21]. Results of this study demonstrate that it has a similar ability as deferoxamine and acetaminophen in removing cardiac and liver iron from iron-overloaded gerbils. NMGDTC was able to prevent or reverse iron-induced cardiac structural changes and improve iron-induced decline in EF and FS (Tables 1 & 2). However, NMGDTC is unstable in an acid (gastric) environment so that it has limited effectiveness when administered orally.

Injections of acetaminophen, acetaminophen-deferoxamine combination, NMGDTC, or acetaminophen-NMGDTC combination reduced the tissue iron contents without producing appreciable signs of toxicity or drug-related deaths. This is consistent with a study in rats in which daily oral (gavage) doses of acetaminophen (200 mg/kg for 200 days) failed to induce any significant changes when compared to controls [22]. In a similar study, male C57BL/6J mice received acetaminophen (30 or 300 mg/kg). The higher dose up-regulated 6 genes and down-regulated 18 genes when evaluated 24 hr after the injection of acetaminophen. The acetaminophen effects on gene expression serve as markers of mild hepatotoxicity, but no histological findings of hepatic necrosis or other hepatotoxicity were noted [23]. Results of our acetaminophen-deferoxamine or acetaminophen-NMGDTC combination studies show that the lower dose of acetaminophen is effective in combinations, thus providing a greater safety margin for the drug in treatments.

A previous study demonstrated that injections of acetaminophen and deferoxamine are equally effective in reducing cardiac excess iron content and preventing cardiac structural and functional changes as assessed by ECHO studies [12]. In the present study, the ECHO techniques demonstrated that acetaminophen-deferoxamine combination conferred equal cardioprotection as acetaminophen or deferoxamine alone. The combination demonstrated a similar ability to remove hepatic iron, and superior ability to either acetaminophen

or deferoxamine in removing cardiac iron from iron-overloaded gerbils. NMGDTC alone and acetaminophen-NMGDTC combination were as effective as deferoxamine in removing hepatic and cardiac iron (Fig. 1). NMGDTC was particularly impressive in preventing iron-induced cardiac left ventricular and right ventricular structural changes (Table 1) to a degree similar to that produced by acetaminophen. Half-dose combination of injected acetaminophen and NMGDTC reduced iron-induced alterations in right ventricular structure but were slightly less effective than NMGDTC or acetaminophen in preventing left ventricular structural changes. The finding that NMGDTC reduced or prevented iron-induced cardiac functional changes while removing excess cardiac and hepatic iron suggests that this compound is a potential agent for treating iron overload.

Congestive cardiomyopathy is the most common defect that occurs with iron overload, but pericarditis, restrictive cardiomyopathy, and angina without coronary artery disease have been reported [24-27]. Iron deposition in the bundle of His and the Purkinje system produces conduction defects and may cause fatal arrhythmias [28,29]. Physical examination may fail to disclose cardiac toxicity, but cardiac failure may occur suddenly, with rapid deterioration without medical intervention. Biventricular heart failure produces pulmonary congestion, peripheral edema, and hepatic engorgement. Vigorous iron extrication can reverse this potentially lethal complication [30].

Echocardiography in children and radionuclide ventriculography in adults are the most useful non-invasive diagnostic techniques. Exercise radionuclide ventriculograms are particularly sensitive in the detection of cardiac dysfunction in patients with iron overload [31]. These techniques can be used periodically to evaluate therapeutic responses during treatments such as chelation. In our study, echocardiography and electrocardiography were used to follow cardiac improvement induced by the acetaminophen or combination treatments. Electrocardiography was used in conjunction with echocardiography to detect the development and prevention or reversal of iron-induced cardiac arrhythmias. A strong correlation exists between the cumulative number of blood transfusions and

functional cardiac derangements in children with thalassemia [32,33], so that the echocardiographic abnormalities correlate roughly with the number of transfusions or degree of cardiac iron overload.

Effects of iron on cardiomyocyte contractility have been documented. Iron salts added to cultures of chick cardiac cells poison the cells and impede their ability to contract spontaneously. Deferoxamine restores myocyte contractility through chelation of extracellular and intracellular iron [34].

Cardiac dysfunction can occur with little tissue iron deposition. The total quantity of iron is less important than the unbound "toxic" iron subset. The concentration of unbound iron in tissues is extremely small and virtually impossible to measure. This "toxic" iron is the component bound and neutralized by iron chelators. Therefore, cardiac damage is best prevented in patients with transfusional iron overload by maintaining a constant low level of chelator in the circulation and tissues [12,35]. Early use of deferoxamine in an amount proportional to the transfusional iron load reduces the body iron burden and helps protect against diabetes mellitus, cardiac disease, and early death in patients with thalassemia major [36].

In conclusion, this study shows that NMGDTC is capable of reducing cardiac and liver iron content in iron-overloaded gerbils, combating iron-induced cardiac structural and functional changes, and reducing iron-induced hepatic weight increases. NMGDTC is effective when administered alone, or combined with acetaminophen. Acetaminophen shares with deferoxamine the abilities to remove cardiac and hepatic iron, restore contractility, and prevent iron-induced cardiac structural and functional deterioration. Acetaminophen offers a number of distinct advantages: (a) it provides a potential treatment of iron overload with an orally effective agent; (b) its iron-removing effectiveness is equal to or greater than established agents such as deferoxamine, which has to be injected; (c) acetaminophen can be used concurrently with other agents with additive or synergistic effects, allowing the use of lower doses of the agents; (d) acetaminophen protects the heart against iron-induced cardiac structural changes by preventing iron-induced increases in total heart mass and

preventing or reversing iron-induced increases in heart LV and RV thicknesses; (e) acetaminophen prevents or reverses iron-induced impairment in cardiac function, as shown by restoration of FS and EF to values similar to saline controls; (f) acetaminophen appears to decrease the incidence of life-threatening arrhythmias, a common cause of death, and may combat other iron-induced cardiac complications such as congestive cardiomyopathy; and (g) acetaminophen may have positive inotropic effects on cardiac function, a finding that should be investigated further.

Based on our previous work [12], we speculate that acetaminophen may provide cardioprotection by two different but related mechanisms: its antioxidant effects and by removal of excess cardiac iron concentrations. Deferoxamine and NMGDTC may provide cardioprotection by the same two or by different mechanisms. The iron-removing ability of acetaminophen-deferoxamine combination is superior to that of either agent alone. The antioxidant characteristics of acetaminophen might provide cardioprotection and prevent tissue or organ damage in various conditions that involve increased iron concentrations and that induce the release of free radicals and other oxidants [1]. It is interesting to speculate that combinations of acetaminophen and deferasirox, a recently approved oral agent for treating transfusional iron overload, both orally effective, might offer advantages over that of either agent. Our future studies may address this possibility.

Acknowledgements

The authors thank Romaine R. Perdue and Lisa Hunt for assistance in echocardiography and Drs. Rameez Sayyed, Imran Arif, and Shewit Weldetensae for advice and assistance. This study was supported in part by grants from McNeil Consumer and Specialty Pharmaceuticals and from the Cardiovascular Research Fund, Joan C. Edwards School of Medicine, Marshall University. Ernest M. Walker, Jr., holds US Patent #6,509,380: Method for treating iron overload with acetaminophen [13].

References

1. Walker EM Jr, Wolfe MD, Norton ML, Jones MM. Hereditary hemochromatosis. *Ann Clin Lab Sci* 1998;28:300-312.
2. Witte DL, Crosby WH, Edwards CQ, Fairbanks VF, Mitros FA. Practice guideline development task force of the College of

- American Pathologists. Hereditary hemochromatosis. *Clin Chim Acta* 1996;245:139-200.
3. Bothwell TH, MacPhail AP. Hereditary hemochromatosis: etiologic, pathologic, and clinical aspects. *Semin Hematol* 1998;35:55-71.
 4. Brandhagen DJ, Fairbanks VF, Baldus W. Recognition and management of hereditary hemochromatosis. *Am Fam Physician* 2002;65:853-860.
 5. Kontoghiorghes GJ, Pattichi K, Hadjigavriel M, Kolnagou A. Transfusional iron overload and chelation therapy with deferoxamine and deferiprone (L1). *Transfus Sci* 2000; 23:211-223.
 6. Nichols GM, Bacon BR. Hereditary hemochromatosis: pathogenesis and clinical features of a common disease. *Am J Gastroenterol* 1989;84:851-862.
 7. Cappell MS. Colonic toxicity of administered drugs and chemicals. *Am J Gastroenterol* 2004;99:1175-1190.
 8. Merson L, Olivier N. Orally active iron chelators. *Blood Rev* 2002;16:127-134.
 9. Choudhry VP, Pati HP, Saxena A, Malariva AN. Deferiprone: efficacy and safety. *Indian J Pediatr* 2004; 71:213-216.
 10. Cappellini MD, Cohen A, Piga A, Bejaoui M, Perrotta S, Agaoglu L, Aydinok Y, Kattamis A, Kilinc Y, Porter J, Capra M, Galanello R, Fattoum S, Drelichman G. A phase 3 study of deferasirox (ICL670), a once-daily oral iron chelator in patients with β -thalassemia. *Blood* 2006;107:3455-3462.
 11. Cappellini MD. Iron-chelating therapy with the new oral agent ICL 670 (Exjade®). *Best Pract Res Clin Haematol* 2005;18:289-98.
 12. Walker EM Jr, Epling CP, Parris C, Cansino S, Ghosh P, Desai DH, Morrison RG, Wright GL, Wehner P, Mangiarua EI, Walker SM, Blough ER. Acetaminophen protects against iron-induced cardiac damage in gerbils. *Ann Clin Lab Sci* 2007; 37:22-33.
 13. Walker EM Jr. Method of treating iron overload with acetaminophen. US Patent #6,509,380; 2002. Marshall University, Huntington, WV 25704.
 14. Otto CM. Principles of echocardiographic image acquisition and Doppler analysis. In: *Textbook of Clinical Echocardiography* (Otto, CM, Ed), Saunders, Philadelphia, 2000; pp 1-28.
 15. Manning TJ, Grow WR. Inductively coupled plasma-atomic emission spectrometry. In: *The Chemical Educator*, Springer-Verlag, New York, 1997;2:1-19.
 16. Ellerton S-Y, Stacey MC. Iron and 8-isoprostane levels in acute and chronic wounds. *J Invest Dermatol* 2003; 121:918-925.
 17. Schwartz KA, Zy L, Schwartz DE, Cooper TG, Braselton WE. Earliest cardiac toxicity induced by iron overload selectively inhibits electrical conduction. *J Appl Physiol* 2002;93:746-751.
 18. van de Wiel HJ. Determination of Elements by ICP-AES and ICP-MS. National Institute of Public Health and the Environment (RIVM). Bilthoven, The Netherlands. 2003; pp 1-19.
 19. Walker EM Jr, Fazekas-May MA, Heard KW, Kleve MG, Good BH, Montague D, Jones MM. Amelioration of cisplatin-induced ototoxicity and nephrotoxicity by diethylthiocarbamate (DDTC) and analogs. *Ann Clin Lab Sci* 1994;24: 121-133.
 20. Walker EM Jr, Shah D, Cannon DJ, Larsen B, Jones MM. Comparative iron mobilizing actions of selected chelating agents in iron-loaded mice. *Ann Clin Lab Sci* 1994;24:478.
 21. Lai CS. Methods for in vivo reduction of iron levels and compositions useful therefor. U.S. Patent # 5,922,761, July 13, 1999; (Medinox, Inc., San Diego, CA).
 22. Thomas BH, Nera EA, Zeitz W. Failure to observe pathology in the rat following chronic dosing with acetaminophen and acetylsalicylic acid. *Res Commun Chem Path Pharmacol* 1977;17:663-678.
 23. Jeong SY, Llim JS, Park HJ, Cho JW, Rana SV, Yoon S. Effects of acetaminophen on hepatic gene expression in mice. *Physiol Chem Phys Med NMR* 2006;38:77-83.
 24. Schellhammer P, Engle M, Hagstrom J. Histochemical studies of the myocardium and conduction system in acquired iron-storage disease. *Circulation* 1967;35:631-637.
 25. Fitchett D, Coltart D, Littler W, Leyland MJ, Trueman T, Gozzard D, Peters T. Cardiac involvement in secondary hemochromatosis. *Cardiovasc Res* 1980;14:7199-7284.
 26. Sanyal S, Johnson W, Jayalakshamma B, Green A. Fatal "iron heart" in an adolescent: biochemical and ultrastructural aspects of the heart. *Pediatrics* 1975;55:336-341.
 27. Liu P, Olivieri N. Iron overload cardiomyopathies: new insights into an old disease. *Cardiovasc Drugs Ther* 1994;8:101-110.
 28. Buja L, Roberts W. Iron in the heart. *Am J Med* 1971;51:209-221.
 29. Olson LJ, Edwards WD, McCall JT, Ilstup DM, Gersh BJ. Cardiac iron deposition in idiopathic hemochromatosis: Histologic and analytic assessment of 14 hearts from autopsy. *J Am Coll Cardiol* 1987;10:1239-1243.
 30. Rahko P, Salerni R, Uretsky B. Successful reversal by chelation therapy of congestive cardiomyopathy due to iron overload. *J Am Coll Cardiol* 1986;8:436-440.
 31. Leon M, Borer J, Bacharach S, Green M, Benz E, Griffith P, and Nienhuis A. Detection of early cardiac dysfunction in patients with severe beta-thalassemia and chronic iron overload. *NEJM* 1979;301:1143-1148.
 32. Wolfe L, Olivieri N, Sallan D, Colan, S, Rose V, Propper R, Freedman M, Nathan D. Prevention of cardiac disease by subcutaneous deferoxamine in patients with thalassemia major. *NEJM* 1985;312:1600-1603.
 33. Koren A, Garty I, Antonelli D, Katzuni E. Right ventricular cardiac dysfunction in beta-thalassemia major. *Am J Dis Child* 1987;141:93-96.
 34. Link G, Pinson A, Hershko C. Heart cells in culture: a model of myocardial iron overload and chelation. *J Lab Clin Med* 1985;106:147-153.
 35. Walker JM. The heart in thalassemia. *Eur Heart* 2002;23:102-105.
 36. Brittenham GM, Griffith PM, Nienhuis AW, Nienhuis AW, McLaren CE, Young NS, Tucker EE, Allen CJ, Farrell DE, Harris JW. Efficacy of deferoxamine in preventing complications of iron overload in patients with thalassemia major. *NEJM* 1994;331:567-573.