



University of Kentucky  
UKnowledge

Neurology Faculty Publications

Neurology

7-2-2018

# Reversible Manifestations of Extraparenchymal Neurocysticercosis

Edison M. Campos

*Hospital de Especialidades Eugenio Espejo, Ecuador*

Flavius D. Raslau

*University of Kentucky, [flavius.raslau@uky.edu](mailto:flavius.raslau@uky.edu)*

Robert Salinas

*Hospital de Especialidades Eugenio Espejo, Ecuador*

Daniela Di Capua

*Hospital de Especialidades Eugenio Espejo, Ecuador*

John T. Slevin

*University of Kentucky, [jslevin@email.uky.edu](mailto:jslevin@email.uky.edu)*

*See next page for additional authors*

**Right click to open a feedback form in a new tab to let us know how this document benefits you.**

Follow this and additional works at: [https://uknowledge.uky.edu/neurology\\_facpub](https://uknowledge.uky.edu/neurology_facpub)



Part of the [Neurology Commons](#), [Neurosciences Commons](#), and the [Parasitic Diseases Commons](#)

## Repository Citation

Campos, Edison M.; Raslau, Flavius D.; Salinas, Robert; Di Capua, Daniela; Slevin, John T.; and Villamar, Mauricio F., "Reversible Manifestations of Extraparenchymal Neurocysticercosis" (2018). *Neurology Faculty Publications*. 31.

[https://uknowledge.uky.edu/neurology\\_facpub/31](https://uknowledge.uky.edu/neurology_facpub/31)

This Article is brought to you for free and open access by the Neurology at UKnowledge. It has been accepted for inclusion in Neurology Faculty Publications by an authorized administrator of UKnowledge. For more information, please contact [UKnowledge@lsv.uky.edu](mailto:UKnowledge@lsv.uky.edu).

---

**Authors**

Edison M. Campos, Flavius D. Raslau, Robert Salinas, Daniela Di Capua, John T. Slevin, and Mauricio F. Villamar

**Reversible Manifestations of Extraparenchymal Neurocysticercosis****Notes/Citation Information**

Published in *Clinical Case Reports*, v. 6, issue 7, p. 1400-1401.


© 2018 The Authors.

This is an open access article under the terms of the [Creative Commons Attribution License](#), which permits use, distribution and reproduction in any medium, provided the original work is properly cited.

**Digital Object Identifier (DOI)**

<https://doi.org/10.1002/ccr3.1602>

# Reversible manifestations of extraparenchymal neurocysticercosis

Edison M. Campos<sup>1</sup> | Flavius D. Raslau<sup>2</sup> | Robert Salinas<sup>1</sup> | Daniela Di Capua<sup>1</sup> |  
John T. Slevin<sup>3</sup> | Mauricio F. Villamar<sup>1,3</sup> 

<sup>1</sup>Department of Neurology, Hospital de Especialidades Eugenio Espejo, Quito, Ecuador

<sup>2</sup>Department of Radiology, University of Kentucky, Lexington, KY, USA

<sup>3</sup>Department of Neurology, University of Kentucky, Lexington, KY, USA

## Correspondence

Mauricio F. Villamar, Hospital de Especialidades Eugenio Espejo, Quito, Ecuador.

Email: mauricio.f.villamar@gmail.com

## Key Clinical Message

Movement disorders are uncommon manifestations of neurocysticercosis. When present, most are secondary to parenchymal lesions in the basal ganglia. Rarely, movement disorders can occur in racemose/extraparenchymal neurocysticercosis, an aggressive variant frequently associated with cerebrospinal fluid outflow obstruction and hydrocephalus. Appropriate treatment can reverse neurological manifestations.

## KEYWORDS

hydrocephalus, movement disorders, neurocysticercosis, neuroinfectious disease, *Taenia solium*

A 21-year-old Ecuadorian woman with previous hydrocephalus due to neurocysticercosis and ventriculoperitoneal shunt placement at age 19 presented with ophthalmoparesis, cerebellar outflow tremor, and bilaterally upgoing toes (Video S1, pretreatment). CSF opening pressure was 16 cm H<sub>2</sub>O. Figure 1A shows MRI.

After 3 weeks of treatment with steroids and albendazole, there was clinical and radiological improvement (Video S1, post-treatment; Figure 1B).

Movement disorders are a rare manifestation of neurocysticercosis. Basal ganglia involvement can cause chorea and/or dystonia. Racemose/extraparenchymal neurocysticercosis, an aggressive variant that commonly causes CSF outflow obstruction and hydrocephalus, can present with parkinsonism, cerebellar outflow tremor, cranial neuropathies, and/or corticospinal signs.<sup>1,2</sup>

## ACKNOWLEDGMENT

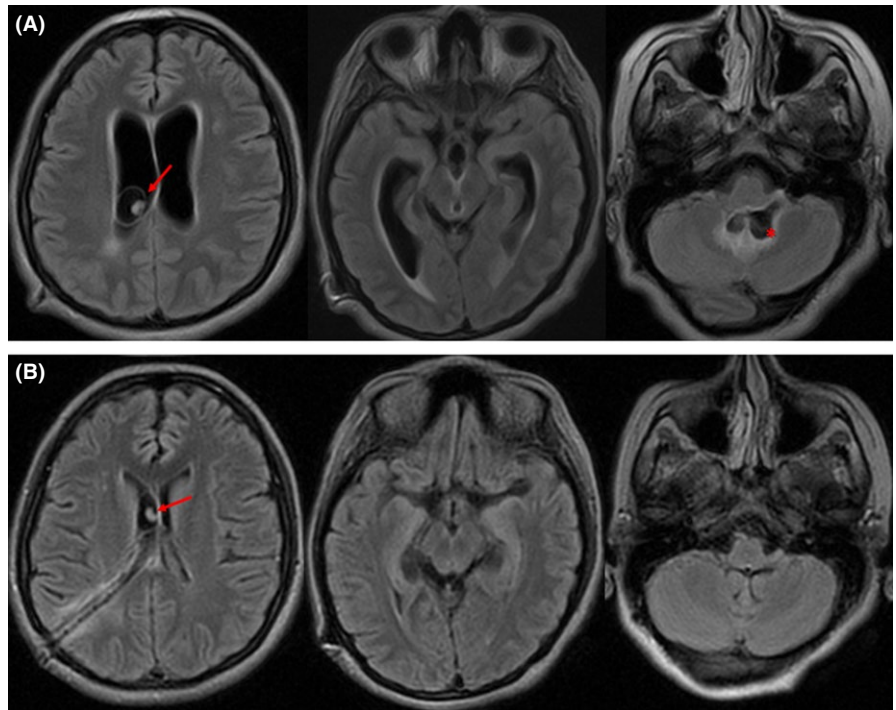
None.

## CONFLICT OF INTEREST

None declared.

## AUTHOR CONTRIBUTIONS

EMC: involved in the case concept and design, acquisition of data, interpretation of data, and manuscript writing. FDR: performed neurodiagnostic evaluation and critically revised the manuscript for intellectual content. RS: involved in the case concept and design, acquisition of data, interpretation of data, and critically revised the manuscript for intellectual content. DDC: involved in the case concept and design, acquisition of data, interpretation of data, and critically revised of the manuscript for intellectual content. JTS: interpreted the data and critically revised the manuscript for intellectual content. MFV: involved in the case concept and design, interpretation of data, manuscript writing, and critically revised the manuscript for intellectual content.



**FIGURE 1** MRI FLAIR sequence. A, Pretreatment images demonstrate communicating hydrocephalus with transependymal CSF egress. Note the intraventricular cyst with scolex (arrow) in the right lateral ventricle, and another cyst in the fourth ventricle (asterisk). B, Post-treatment images, obtained 3 weeks later, show resolution of hydrocephalus and fourth ventricle cyst

## ORCID

Mauricio F. Villamar  <http://orcid.org/0000-0003-4503-8152>

## SUPPORTING INFORMATION

Additional supporting information may be found online in the Supporting Information section at the end of the article.

## REFERENCES

1. Alarcon F, Cedeno Y, de Yebenes JG. Parkinsonism and other movement disorders in 23 cases of neurocysticercosis. *Parkinsonism Relat Disord.* 2017;42:47-53.
2. Garcia HH, Nash TE, Del Brutto OH. Clinical symptoms, diagnosis, and treatment of neurocysticercosis. *Lancet Neurol.* 2014;13:1202-1215.

**How to cite this article:** Campos EM, Raslau FD, Salinas R, Di Capua D, Slevin JT, Villamar MF. Reversible manifestations of extraparenchymal neurocysticercosis. *Clin Case Rep.* 2018;6:1400–1401. <https://doi.org/10.1002/ccr3.1602>