



*The VAD Journal: The journal of mechanical assisted circulation and heart failure*

**Peer-Reviewed Case Report**

# Temporary and Durable Mechanical Circulatory Support for Single Ventricular Failure in an Adult

**Joshua L. Hermsen<sup>1\*</sup>, Jason W. Smith<sup>1</sup>, Jay D. Pal<sup>1</sup>, Agustin Rubio<sup>2</sup>, S. Carolina Masri<sup>3</sup>, Nahush A. Mokadam<sup>1</sup>, Richard K. Cheng<sup>3</sup>, Claudius Mahr<sup>3</sup>**

<sup>1</sup>University of Washington, Department of Surgery, Div. of Cardiothoracic Surgery, Seattle, WA

<sup>2</sup>Seattle Children's Hospital, Heart Center, Div. of Interventional Cardiology, Seattle, WA

<sup>3</sup>University of Washington, Department of Medicine, Div. of Cardiology, Seattle, WA

\* Corresponding author: [hermsejl@uw.edu](mailto:hermsejl@uw.edu)

Citation: Hermsen, J. et al. (2016).  
"Temporary and Durable  
Mechanical Circulatory Support for  
Single Ventricular Failure in an  
Adult"  
*The VAD Journal*, 2. doi:  
<http://dx.doi.org/10.13023/VAD.2016.06>

Editor-in-Chief: Maya Guglin,  
University of Kentucky

Received: January 29, 2016

Accepted: March 16, 2016

Published: March 17, 2016

© 2016 The Author(s). This is an open access article published under the terms of the [Creative Commons Attribution-NonCommercial 4.0 International License](https://creativecommons.org/licenses/by-nc/4.0/) (<https://creativecommons.org/licenses/by-nc/4.0/>), which permits unrestricted non-commercial use, distribution, and reproduction in any medium, provided that the original author(s) and the publication source are credited.

Funding: Not applicable

Competing interests: Not applicable

## Abstract

Patients palliated with Fontan circulation who require mechanical circulatory support pose anatomic and physiologic challenges. We treated an acutely failed Fontan patient with sequential temporary and durable support devices. Aspects of treatment with each device required modification based on the patient's anatomy and physiology.

## Keywords

Ventricular assist device; Impella, Fontan, HVAD, Shock, Hybrid

## Patient Profile

A 32-year-old man with Damus-Kaye-Stansel reconstruction and Fontan palliation for double inlet left ventricle and L-transposition suffered cardiac arrest and gross aspiration. Bystander CPR was initiated with return of spontaneous circulation after 30 minutes. On arrival to the hospital he was intubated and found to be neurologically intact, in cardiogenic shock, anuric, and requiring multiple vasoactive infusions. Creatinine was 3.7 mg/dL, international normalized ratio was 1.6, and total bilirubin level was 3.2 mg/dL. Echocardiogram showed moderate ventricular dysfunction and mild-moderate neo-aortic insufficiency (neo-AI). Catheterization revealed unobstructed Fontan



circuit with pressures = 23mmHg (catheterization 6 months earlier = 16mmHg). INTERMACS classification was one.

An Impella 5.0 (Abiomed, Danvers, MA) ventricular assist device (VAD) was placed via right axillary cutdown. Impella passage into the left ventricle, through the native pulmonary valve resulted in severe neo-AI. Repositioning through the native aortic valve, into the rudimentary right ventricular outflow chamber, allowed full flow and stabilization. Persistent hemolysis and mucosal bleeding prompted Impella removal and HeartWare HVAD® (HeartWare, Framingham, MA) placement 10 days later as attempts at Impella weaning caused hemodynamic embarrassment. The long-term goal for the patient was HVAD as bridge to transplant.

The HVAD was placed in a hybrid OR via left anterior thoracotomy and left axillary cutdown without bypass. Epicardial ultrasound guided cannula position. Left pleural adhesions and chest-wall to pulmonary collaterals mandated subcutaneous outflow graft placement. The distal axillary artery was banded to prevent unilateral hyperemia. Endovascular semilunar valve closure was attempted with a 30mm Amplatzer ventricular septal defect occluder in an attempt to minimize neo-AI. It was thought this device would sit nicely within the sinus segment of the neo-aortic valve. Deployment of the device caused hemodynamic collapse due to coronary compression, which was relieved with re-sheathing and removal of the device.

We think the coronary compression was related to over-sizing, but a size 28mm device did not have adequate leaflet capture to ensure positional stability. Due to hemodynamic instability, it was not possible to ascertain whether the device occluded a coronary os directly or by means of distortion/torsion.

The patient made a slow recovery marked by dialysis dependence, extreme deconditioning, and nosocomial pneumonias before dying on POD 273. There were some bright spots during his prolonged hospitalization, as he remained neurologically intact and enjoyed some quality of life given his ability to eat and mobilize via a wheelchair. He was also able to take a day trip to a major league baseball game.

### **Comment**

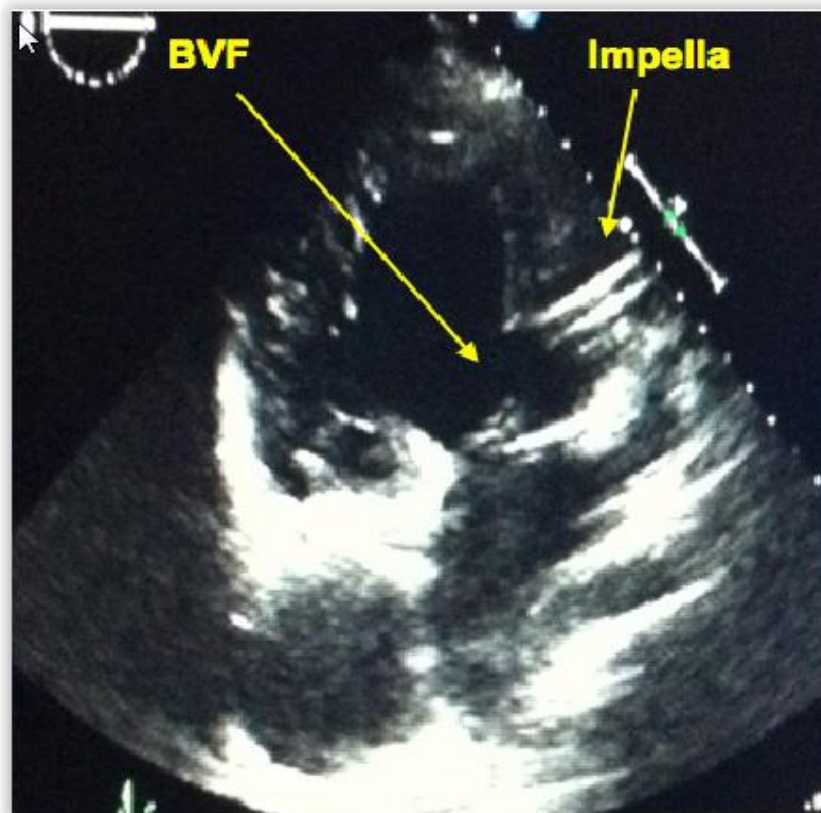
Since the Fontan circulation is susceptible to failure at multiple levels, a single approach to Fontan failure patients is unrealistic and mechanical therapies must be individualized. Impella for single ventricle support as a bridge to Berlin Heart (Berlin Heart Inc., The Woodlands, TX)<sup>1</sup> in a pediatric patient has been reported, but use in adult Fontan circulation has not.

Determining the physiologic cause of Fontan failure is imperative. Fontan obstruction or elevated pulmonary vascular resistance (PVR) are not remedied with ventricular assist therapies.<sup>2</sup> In this case, failure was caused by combined

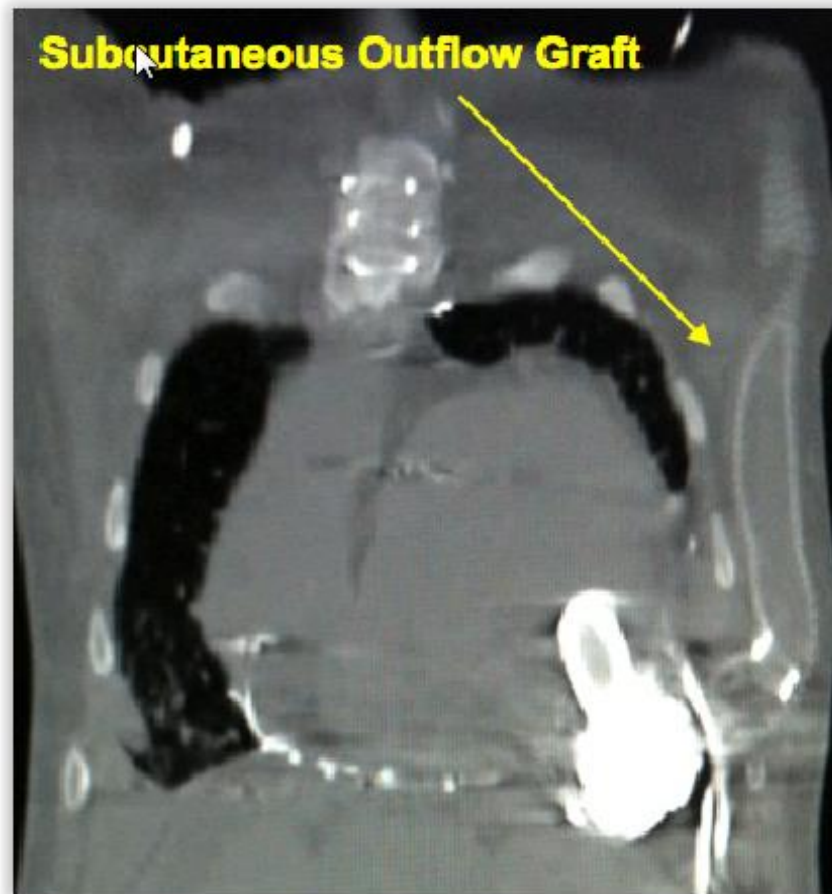


acute decline in ventricular function and aspiration causing elevated PVR. Such patients are typically supported with veno-arterial extracorporeal membrane oxygenation (VA-ECMO). This patient was not a good VA-ECMO candidate given the degree of neo-AI.

This patient presented anatomic challenges. Impella placement into the left ventricle, across the patient's neo-aortic valve resulted in unacceptable neo-AI, whereas placement into the rudimentary right ventricle (across the native aortic valve) allowed full flow and adequate support (Figure 1). We elected to place the HVAD via a non-sternotomy approach given the overall clinical situation and ongoing failure of multiple organ systems. The LV apex was accessible by left anterior thoracotomy. Epicardial and transesophageal echocardiography guided precise cannula placement.<sup>3</sup> Left pleural symphysis and chest wall to pulmonary collaterals mandated extra-thoracic outflow graft placement. Outflow graft placement inside ring reinforced polytetrafluoroethylene prevented kinking or stenosis (Figure 2). Coronary anatomy prevented minimization of neo-AI by endovascular closure device.



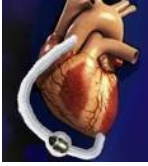**Figure 1.** Echocardiogram image shows Impella device in rudimentary right ventricular outflow chamber with tip of device near the bulboventricular foramen (BVF).



**Figure 2.** Post-operative CT scan of the chest showing VAD in cardiac apex and extra-thoracic course of outflow graft.

The optimal management of acute Fontan circulation failure is unknown. We had technical success employing a temporary, intravascular axial flow ventricular assist device as a bridge to durable VAD. Congenital anatomy presents unique challenges in caring for these patients and requires flexibility and adaptability when using devices designed for normal anatomy.

Ultimate success was not achieved in this case. However, the experience with this patient remains valuable to the still nascent literature regarding mechanical support of this disease state. Fontan circulation patients represent the fastest growing population of adults with congenital heart disease and this scenario will be confronted with increased frequency in the foreseeable future.<sup>4</sup> Some of the technical challenges related to this patient's anatomy are unique to patients with congenital disease and worth noting for treating future patients. The value of a multi-disciplinary team of surgeons, interventionalists, and cardiologists with expertise in adult congenital heart disease as well as a dedicated cardiothoracic ICU cannot be overemphasized in the care of these patients.



### **Acknowledgements, Funding and Disclosures**

Acknowledgements: none

Funding Sources: none

Disclosures: Dr. Mokadam reports consultant fees from Thoratec, Heartware, and SynCardia. Dr. Mahr reports consultant fees from Thoratec, Heartware, and Abiomed.

### **References**

1. Hoganson DM, Boston US, Gazit AZ et al. Successful bridge through transplantation with berlin heart ventricular assist device in a child with failing Fontan. *Ann.Thorac.Surg.* 2015;2:707-09.
2. Morales, DL, Adachi I, Heinle JS, et al. A new era: use of an intracorporeal systemic ventricular assist device to support a patient with a failing Fontan circulation. *J.Thorac. Cardiovasc.Surg.* 2008;3:1018-1020.
3. Jouan J, Grinda JM, Bricourt MO, et al. Non-pulsatile axial flow ventricular assist device for right systemic ventricle failure late after Senning procedure. *Int.J.Artif.Organs*, 2009;4:243-45.
4. Bowater SE, Speakman JK, Thorne SA. End-of-life care in adults with congenital heart disease: now is the time to act. *Curr Opin Support Palliat Care*, 2013;7:8-13.