



University of Kentucky
UKnowledge

Orthopaedic Surgery and Sports Medicine Faculty
Publications

Orthopaedic Surgery and Sports Medicine

12-2018

Femoroacetabular Impingement as a Complication of Acetabular Fracture Fixation

David A. Zuelzer

University of Kentucky, david.zuelzer@uky.edu

Christopher B. Hayes

University of Kentucky, christopher.hayes@uky.edu

Raymond D. Wright

University of Kentucky, raymond.wright@uky.edu

Stephen T. Duncan

University of Kentucky, stdunc2@uky.edu

Right click to open a feedback form in a new tab to let us know how this document benefits you.

Follow this and additional works at: https://uknowledge.uky.edu/orthopaedicsurgery_facpub



Part of the [Musculoskeletal System Commons](#), [Orthopedics Commons](#), [Sports Medicine Commons](#), [Sports Sciences Commons](#), [Surgery Commons](#), and the [Trauma Commons](#)

Repository Citation

Zuelzer, David A.; Hayes, Christopher B.; Wright, Raymond D.; and Duncan, Stephen T., "Femoroacetabular Impingement as a Complication of Acetabular Fracture Fixation" (2018). *Orthopaedic Surgery and Sports Medicine Faculty Publications*. 16.
https://uknowledge.uky.edu/orthopaedicsurgery_facpub/16

This Article is brought to you for free and open access by the Orthopaedic Surgery and Sports Medicine at UKnowledge. It has been accepted for inclusion in Orthopaedic Surgery and Sports Medicine Faculty Publications by an authorized administrator of UKnowledge. For more information, please contact UKnowledge@lsv.uky.edu.

Femoroacetabular Impingement as a Complication of Acetabular Fracture Fixation

Notes/Citation Information

Published in *Trauma Case Reports*, v. 18, p. 56-59.

© 2018 The Authors. Published by Elsevier Ltd.

This is an open access article under the CC BY-NC-ND license (<http://creativecommons.org/licenses/by-nc-nd/4.0/>).

Digital Object Identifier (DOI)

<https://doi.org/10.1016/j.tcr.2018.07.003>



Case Report

Femoroacetabular impingement as a complication of acetabular fracture fixation

David A. Zuelzer*, Christopher B. Hayes, Raymond D. Wright, Stephen T. Duncan

Department of Orthopaedics and Sports Medicine, University of Kentucky, 740 S. Limestone Rd, K403, Lexington, KY 40536-0284, USA

ARTICLE INFO

Keywords:

Acetabular fracture
Femoroacetabular impingement
Hip arthroscopy
Complication

ABSTRACT

Case: We present the case of a thirteen-year-old female who sustained a posterior wall acetabular fracture dislocation. She underwent urgent closed reduction and subsequent uncomplicated open reduction and internal fixation. Post reduction computed tomography demonstrated a concentrically reduced hip joint with no evidence of femoroacetabular impingement (FAI). She subsequently healed her fracture and returned to running activities; however, one year later presented with aching pain in her thigh. Radiographs demonstrated the development of a large osseous prominence on her anterolateral femoral neck consistent with femoroacetabular impingement. Based on these findings she was evaluated by a hip preservation specialist. She subsequently underwent successful hip arthroscopy for labral repair and femoral osteochondroplasty. She was eventually able to return to running sports with little pain.

Summary: We present a case of FAI presenting as a complication of acetabular fracture fixation. This should be discussed with patients presenting with traumatic hip dislocations as a possible complication of surgical fixation or possibly of the injury itself.

Introduction

Numerous factors influence outcomes following open treatment of acetabular fractures including fracture pattern, age, associated chondral damage, neurovascular injury, and associated dislocation. Traumatic hip dislocations often times have associated injuries including chondral damage, labral tears, and ligamentum teres tears [1]. Interestingly, the current published literature has not described the development of femoroacetabular impingement (FAI) following either traumatic hip dislocation or acetabular fracture. Here we present FAI development as a late complication following operative treatment of a posterior wall acetabular fracture dislocation. The authors have obtained the patient's informed written consent for print and electronic publication of the case report.

Case report

A thirteen-year-old female presented to the emergency department as the restrained passenger in a motor vehicle collision at highway speed. She experienced loss of consciousness during the accident and complained of right hip pain on arrival. She was diagnosed with a right posterior wall acetabular fracture dislocation without marginal impaction or neurovascular deficit. She underwent procedural sedation for closed reduction in the emergency department and was placed into distal femoral traction to maintain reduction and provide patient comfort. She was taken for open reduction and internal fixation on hospital day one.

She was positioned prone on a radiolucent flat-top table. A Kocher-Langenbeck exposure was performed. A very peripheral

* Corresponding author.

E-mail address: david.zuelzer@uky.edu (D.A. Zuelzer).<https://doi.org/10.1016/j.tcr.2018.07.003>

Accepted 16 July 2018

Available online 13 October 2018

2352-6440/© 2018 The Authors. Published by Elsevier Ltd. This is an open access article under the CC BY-NC-ND license (<http://creativecommons.org/licenses/by-nc-nd/4.0/>).

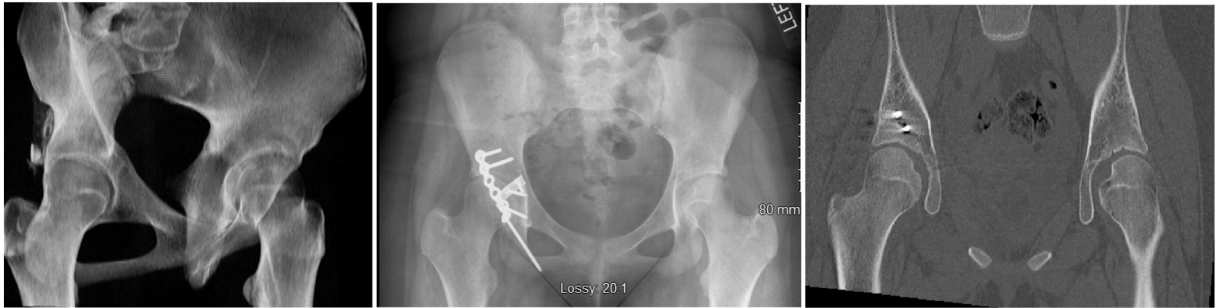

Fig. 1. A–C. A). 3D Recon image of a right posterior wall acetabulum fracture. B). Immediate postoperative radiographs and C) immediate postoperative CT scan showing interval hardware placement and no preexisting CAM lesion.

acetabular fracture with substantial capsular attachments was identified. The fracture fragment was reduced, wired provisionally, and then secured with a spring plate pelvic reconstruction plate used in buttress fashion (Fig. 1). The obturator internus and piriformis tendons were approximated to the posterior aspect of the greater trochanter. Post-operative imaging demonstrated an anatomic reduction and no evidence of intra articular screw placement. She was discharged on hospital day 8 and remained weight of leg weight bearing for six weeks. She maintained weight of leg weight bearing and was ambulatory with the use of a walker the following day. She subsequently healed her acetabular fracture and advanced to weight bearing as tolerated at 3 months. At six months post-op she could run without pain. At one year she had complaints of right anterior thigh pain and occasional pain with rotation of the hip and was prescribed Ibuprofen. Radiography showed no evidence of osteoarthritis or degenerative changes. She then presented to clinic a month later outside of normal follow up for continued right hip pain and subjective instability after running in gym class. At this point she was referred to a hip preservation specialist for evaluation of femoroacetabular impingement that had advanced radiographically (Fig. 2).

Upon presentation to the hip preservation consultant, she had complaints of pain and mechanical symptoms. Examination demonstrated positive impingement signs including a positive Patrick test with significantly reduced hip flexion and internal rotation. Radiographically, she had reduced femoral head neck offset, most pronounced anterior and lateral, with alpha angle of $\sim 90^\circ$, mild inferior joint space narrowing, and retained implants that would preclude adequate soft tissue visualization with MR. A CT scan was obtained to better clarify the extent of the FAI lesion for operative planning. Hip arthroscopy was performed utilizing mid anterior, anterolateral, and distal anterolateral portals. She was found to have a degenerative and detached labrum from 12:00 to 3:00 position as described by Philippon et al. [2], grade 1 changes of the posterolateral acetabular cartilage and delamination of the anterior acetabular cartilage from 10:00 to 2:00 position. There was a loose chondral flap in the central portion of the femoral head with grade 3 changes present in the acetabular fossa. She had a loose chondral piece of bone within the acetabular fossa. She had reduced head neck offset seen extending from the anterior portion of the femoral head to the very lateral and posterior portion with adhesion and osteophyte formation within the joint itself. She underwent labral repair, capsular plication, and anterior femoral osteochondroplasty. Her pain and feelings of instability improved post operatively and her pain decreased to approximately 3 out of 10. At one year following her arthroscopic procedure, she returned to athletic competition and has minimal complaints of hip pain despite a persistent posterior cam lesion (Fig. 3).

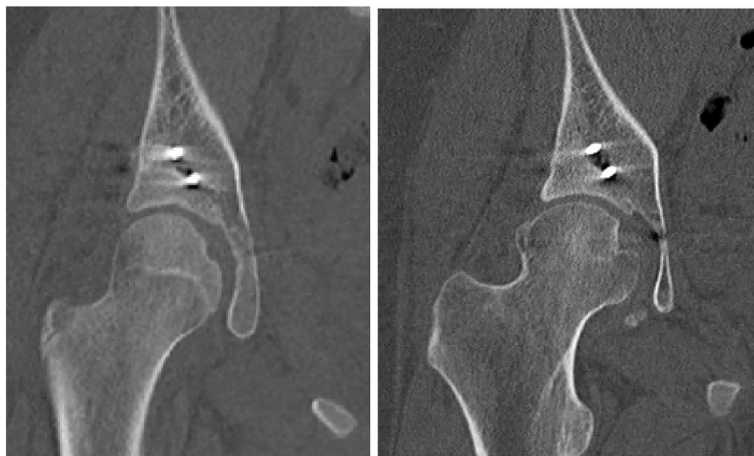

Fig. 2. A and B. Representative slices of CT scans at the same depth taken 2 years apart demonstrate the interval development of CAM lesion of femoral head. A). Immediate postoperative CT scan. B). 14 months postoperatively the posterior wall fracture has healed with no degenerative changes seen. There has been interval development of a CAM lesion.

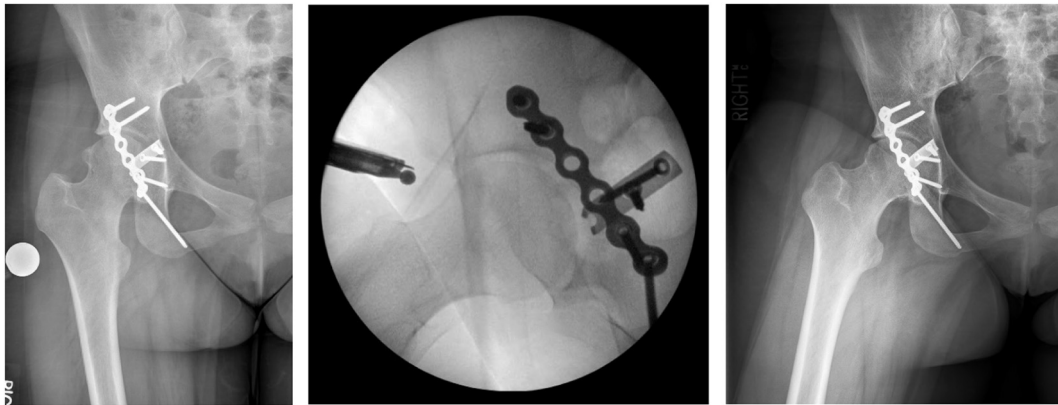


Fig. 3. A–C. A). Preoperative radiograph taken before hip arthroscopy and femoral osteochondroplasty. B). Dunn view taken with fluoroscopy intraoperatively and C). Follow-up radiographs taken 1 year after hip arthroscopy and femoral osteochondroplasty. Note that there is no evidence of recurrence at 1 year following osteochondroplasty.

Discussion

Femoroacetabular impingement has garnered abundant clinical and academic attention recently. The exact etiology of FAI is unclear however is thought to involve abnormal torsion of the acetabulum and femoral neck. Acetabular retroversion and decreased femoral anteversion have been implicated in pincer and cam impingement mechanisms, respectively [3]. The subsequent impact of the acetabulum and femoral neck lead to progressive labral and articular cartilage damage leading to abnormal bony growth and development of FAI.

There are no current reports of FAI development following acetabular fracture fixation. We have presented a case of FAI that appears to have developed after a dislocation associated with a posterior wall acetabular fracture. Cam impingement is characterized by bony deformity that develops on the femoral neck and typically spans the 1:00 to 3:00 position on the clock face [4]. Our patient developed a lesion that was somewhat atypical in that it started more laterally at about 12:00 position and ending at about 2:00 position. There was no associated pincer lesion of the acetabulum but a labral tear with associated grade III chondral changes were identified adjacent to the cam lesion. It is unclear whether the labral tear or the chondral changes were consequences of the dislocation, fracture fixation, or from development of FAI.

Early reports demonstrated excellent outcomes for patients following acetabular fractures with posterior dislocation and were not thought to predispose to the development of osteoarthritis [5]. Follow up studies have shown poor functional outcomes following posterior wall acetabular fractures in 10–30% of patients [6–8]. Even worse outcomes were found with those that sustained femoral head cartilage damage with an elevated risk for post traumatic osteoarthritis [7]. This patient had a posterior wall fracture dislocation requiring a reduction maneuver in the ER and was subsequently found to have chondral damage upon arthroscopic evaluation. These findings placed her at an elevated risk for poor outcome.

The exact etiology of FAI is not well understood. Prior hypotheses have involved the production of reactive bone due to abnormal impingement and subsequent development of the cam lesion as well as labral tears and underlying chondral damage [9]. Despite her timely anatomic fixation she developed a large anterolateral cam lesion with reduced head neck offset of the femoral neck. There was no surgical treatment performed on the femoral side. She was also noted to have grade III chondral damage which likely occurred during her dislocation and subsequent reduction. This may point to underlying cartilage damage as the etiology of the pathologic deformity seen in cam type impingement. Likely, the bony cam lesion occurs immediately adjacent to the cartilage damage, analogous to osteophyte formation during osteoarthritic changes. Alternatively, it has been suggested that cam deformity occurs as a consequence of abnormal growth plate modulation. It is possible that remaining growth potential combined with maintenance of slight hip flexion for prolonged period may have resulted in abnormal growth and development of an accelerated cam deformity.

Late complications of acetabular fractures that predispose to poor outcome have previously been elucidated. Poor postoperative reduction increases risk of avascular necrosis, heterotopic ossification, and post-traumatic arthritis [5, 10]. Here we have presented a previously unreported complication following a posterior wall acetabular fracture that represents a poor clinical outcome that was salvaged with hip arthroscopy and femoral osteochondroplasty. This represents the first known case of femoroacetabular impingement occurring as a complication of posterior wall acetabular fracture fixation. Additionally, this may implicate chondral damage as the underlying cause of the hallmark cam type impingement lesion. Finally, this case highlights the importance of prolonged follow up and scrutinizing x-rays of patients with new onset pain and poor satisfaction following posterior wall acetabular fracture fixation for possible reversible causes of hip pain including femoroacetabular impingement.

Disclosure statement

The authors have nothing to disclose.

References

- [1] M.J. Philippon, et al., Arthroscopic findings following traumatic hip dislocation in 14 professional athletes, *Arthroscopy* 25 (2) (2009) 169–174.
- [2] M.J. Philippon, et al., Arthroscopic management of femoroacetabular impingement: osteoplasty technique and literature review, *Am. J. Sports Med.* 35 (9) (2007) 1571–1580.
- [3] D. Tonnis, A. Heinecke, Acetabular and femoral anteversion: relationship with osteoarthritis of the hip, *J. Bone Joint Surg. Am.* 81 (12) (1999) 1747–1770.
- [4] A.B. Yanke, et al., Sex differences in patients with CAM deformities with femoroacetabular impingement: 3-dimensional computed tomographic quantification, *Arthroscopy* 31 (12) (2015) 2301–2306.
- [5] J.M. Matta, Fractures of the acetabulum: accuracy of reduction and clinical results in patients managed operatively within three weeks after the injury, *J. Bone Joint Surg. Am.* 78 (11) (1996) 1632–1645.
- [6] B.R. Moed, S.E. WillsonCarr, J.T. Watson, Results of operative treatment of fractures of the posterior wall of the acetabulum, *J. Bone Joint Surg. Am.* 84-A (5) (2002) 752–758.
- [7] B.R. Moed, P.H. Yu, K.I. Gruson, Functional outcomes of acetabular fractures, *J. Bone Joint Surg. Am.* 85-A (10) (2003) 1879–1883.
- [8] A.M. Saterbak, et al., Clinical failure after posterior wall acetabular fractures: the influence of initial fracture patterns, *J. Orthop. Trauma* 14 (4) (2000) 230–237.
- [9] J.W.T. Byrd, *Operative Hip Arthroscopy*, Third edition, Springer, New York, 2013 (xxi, 553 pages).
- [10] P.V. Giannoudis, et al., Operative treatment of displaced fractures of the acetabulum. A meta-analysis, *J. Bone Joint Surg. (Br.)* 87 (1) (2005) 2–9.