



[The VAD Journal: The journal of mechanical assisted circulation and heart failure](#)

Peer-Reviewed Case Series

A Modified Access Technique of Impella 5.0 Axillary Artery Insertion

Abdallah K Alameddine^{1*}, Brian Binnall¹, Eric DiBiasio-White¹, and Khaled O Alameddine²

*Corresponding author: akalameddine@gmail.com

¹ Division of Cardiac Surgery, Baystate Medical Center, Springfield, MA

² University of Massachusetts Medical School-Baystate, Swedish Covenant Hospital, Chicago, IL

Abstract

The conventional method for the axillary artery insertion of Impella 5.0 is a non-tunneling route of the side-graft. We present an alternative technique in order to facilitate device insertion and to ensure protection from potential wound contamination. The technique consists of exiting the graft separately and away from the main incision with an intact skin and subcutaneous fat between the two sites. By proper isolation of the main wound, the risk of infection can thus be largely mitigated. Furthermore, this technique allows a better landing entry angle of graft insertion; the resulting smoother curve trajectory leads to facile device insertion, while the risk of kinking after resumption of flow is readily avoided. A further possible advantage would be a less likely to produce thrombosis at the anastomosis. Differences of this technique have already been reported for insertions of extracorporeal membrane oxygenation (ECMO), and for aortic dissections and aneurysms. Our experience in 8 cases suggests the applicability of our method to access the axillary artery for Impella 5.0 insertion.

Keywords: arterial cannulation, axillary artery, mechanical circulatory support, axial flow left ventricular-aortic pump (Impella 5.0).

Introduction

Utilization of temporary (< 6 days) mechanical circulatory left ventricular (LV) assist devices has allowed circulatory support and recovery of the LV in the treatment of cardiogenic shock, or in the setting of acute left heart failure. In that regard, the use of Impella 5.0 ventricular support system (Abiomed Inc., Danvers, MA) is rapidly expanding; however, on occasion the LV recovery requires the device to be in place for longer-time period where wound infection may be a problem.^{1,2}

Citation: Alameddine A. et al. (2018) "A modified access technique of Impella 5.0 axillary artery insertion".

The VAD Journal, 4. doi: <https://doi.org/10.13023/vad.2018.10>

Editor-in-Chief: Maya Guglin, University of Kentucky

Received: July 26, 2018

Accepted: September 7, 2018

Published: September 8, 2018

© 2018 The Author(s). This is an open access article published under the terms of the Creative Commons Attribution-NonCommercial 4.0 International License (<https://creativecommons.org/licenses/by-nc/4.0/>), which permits unrestricted non-commercial use, distribution, and reproduction in any medium, provided that the original author(s) and the publication source are credited.

Funding: Not applicable

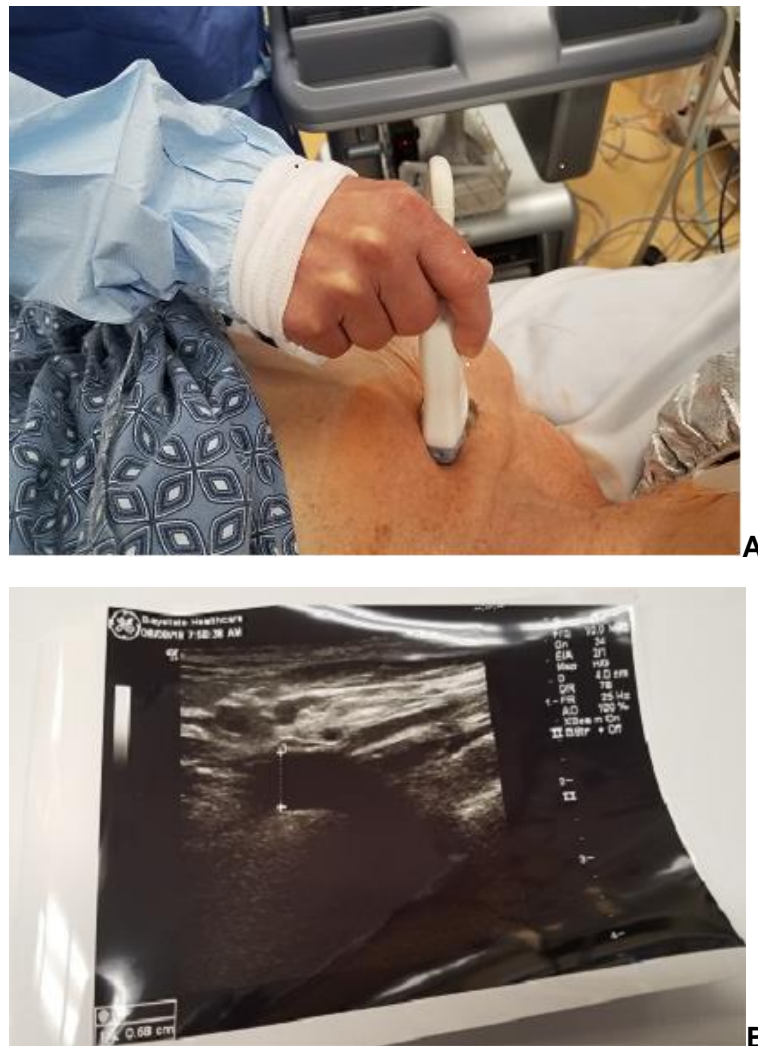Competing interests: Not applicable



Relevant technical steps

After confirmation of a suitable candidate, anesthesia is induced, a transesophageal echo probe positioned, and a pulmonary central catheter is introduced into the pulmonary artery. We prefer to perform the implantation in the hybrid operating room.

Prior to procedure, ultrasound imaging is a key investigation of the axillary artery that allows safe feasibility of a peripheral access, Figures 1A, B. This artery should have a minimum caliber of 6.20 mm which is needed for the Impella device's implantation to proceed. The operative field should include both infraclavicular and groin regions exposed in case additional access is needed.





The infraclavicular exposure of the axillary artery (AA) starts with locating the coracoid process which can be felt easily under the skin. The coracoid process marks the most lateral border of an approximately two inch skin incision inferior and parallel to the clavicle. After opening the deep clavipectoral fascia, the tendon of the pectoralis minor muscle is divided (partially or totally) near its insertion on the coracoid process.

Blunt blades Adson Cerebellum (V Mueller, Franklin Lakes, NJ) Retractor are cranked up for retraction of pectoralis major muscle, and a Karmody Vascular Spring Retractor (V Mueller) is used for deeper axillary fat retraction.

Except for the sub-adventitial AA isolation, no sharp dissection is used once the AA has been visualized to avoid any trauma to this delicate vessel and to the brachial cords. Instead, a Kittner dissector (peanut) is used to gently tease-off the local connective tissue surrounding the vessel. Most of the time, the AA is pulseless in such patients who may be managed with extracorporeal LV support. The nerves to the pectoralis major muscle are preserved to avoid subsequent atrophy of this muscle. The thoracoacromial arterial branch (TA) of the AA marks the medial border of the anastomosis. As is done in the femoral artery exposure, small vessel tributaries are not cauterized but rather are ligated in continuity with fine silk (4.0) ties or hemoclipped. These tributaries are often accompanied by lymphatic channels which will not coagulate with the electric current and thus might lead to the postoperative lymphatic leaks. At this point, the lateral and medial brachial plexus cords are particularly vulnerable, and care should be taken not to cut or injure them through excessive diathermy heat. The AA is freed subadventitially and 2 retraction tapes are used to facilitate its exposure. A double-looped tape can be placed so as to straddle the TA branch³. This not only controls the branch but also prevents slippage. The other tape is placed distally to accommodate a distance of at least 1.2 cm so that a 10 mm Hemashield Platinum woven double velour vascular graft (MAQUET Cardiovascular LLC Wayne, NJ) can be anastomosed in an end to side fashion. The access point is usually medial to the origin of the lateral thoracic artery.

After administering intravenously 5 to 10,000 units of heparin, a small Cooley-Derra clamp (V Mueller) tangential occlusion clamp or two straight or profunda vascular clamps are applied across the artery between the snares. Then the AA is incised longitudinally, and the end to side anastomosis is completed with 5.0 prolene suture. After completion of the anastomosis, meticulous hemostasis is imperative especially since these devices require postoperative heparinization.

The graft is tunneled out of the infraclavicular pocket by subcutaneous passage and a small incision is carried out at the shoulder exit wound site about 2" away from the main incision, Figures 2 A, B, C.

Keeping the side graft straight and aligned as it enters the shoulder area, depending on the AA anatomic depth dictates, should result in a trajectory without kink. The 23 Fr (6 cm long) peel-away introducer with hemostatic valve is inserted over the catheter shaft into the graft, and secured with the graft lock.

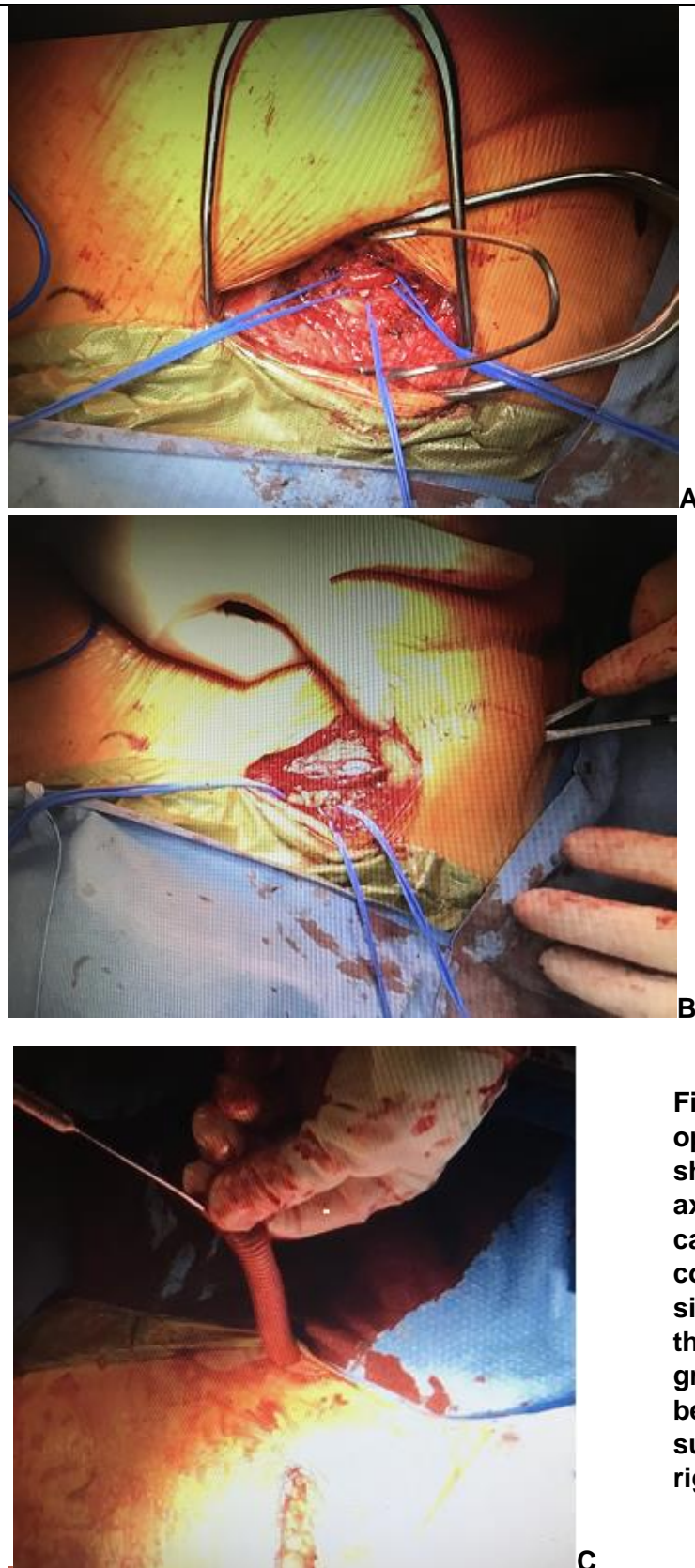


Figure 2 A, B, C. Intraoperative photographs showing the right axillary artery cannulation after completion of an end-to-side anastomosis through a 10-mm side graft. The exit wound is being prepared, with the surgeon standing on the right side of the patient.



The device catheter is then carefully advanced into the left ventricle. At this stage, the ACT is maintained around 200 seconds. The device is advanced into the left ventricle loaded on a 0.035 inch guidewire with the use of both transesophageal echocardiography and fluoroscopy guidance. When both a correct Impella catheter position across the aortic valve and a pulsatile placement signal are documented, the device is activated after removing the wire and the peel away introducer. Thereafter, the repositioning sheath is advanced to the arteriotomy site.

The flow rate is ramped up to a maximum P-9 level. All the flows were satisfactory, and the patients became hemodynamically stable. The trimmed graft flush *under* the skin is then secured around the catheter using a heavy silk tie (#5). The 2 incisions are closed in layers and the skin is stapled. Antibiotic wound irrigation is optional.

Explantation technique

Under general anesthesia the surgical areas included the entire chest, right deltoid region and the right groin. The surgical areas are draped separately as a preemptive way to avoid contamination at the time when the assistant surgeon pulls out the device from under the sheaths. Systemic antibiotic was administered. The old staples and anchoring skin sutures of the repositioning device were removed and the incision was reopened using only blunt dissection to avoid new tissue trauma. At this point the old Hemashield graft was exposed and vessel looped for potential bleeding control. The old surgical fragments were removed, and deep wound culture was taken. The area was copiously irrigated with Bacitracin solution. The main wound was draped separately from the outer area where the device has been anchored.

Under trans-esophageal echocardiography and keeping the pump running at ramp 2, the device was withdrawn so the tip of the sheath was just above the aortic valve. After this step, the pump was shot off and the device was withdrawn afterward the vessel loop was snugged around the graft for bleeding control. A vascular TA 30 stapler was used to sever the graft just 1 cm above the axillary anastomosis and it was hemostatic. Thrombotic morcels were retrieved from the stump of the graft to avoid potential distal arm embolization. A representative thrombus material was sent for pathology examination. The wound was again irrigated with Bacitracin solution and closed in layers.

We have employed this technique for cardiogenic heart failure in 8 cases with good success. Two cases were due to viral myocarditis, and two cases due to postcardiotomy cardiogenic shock. The remaining cases were due to idiopathic cardiomyopathy. In those patients who survived, the graft was excised between 4 and 30 days post LV assistance with a mean of 11 days. Despite perioperative heparinization, there have been no bleeding or hematoma formation, therefore no transfusions were required due to perioperative blood loss. Furthermore, there were no wound infections, kinking, cannulation issues, or device malposition. The mean age was 66 years (SD \pm 14; range: 48-76, 2 females) with 2 deaths: 1 due to septicemia related to sacral ulcers, and 1 to pneumonia. The mean pump flow was



4.5 ± 0.4 L/min. The remaining characteristics and patient outcomes are outlined in the table 1.

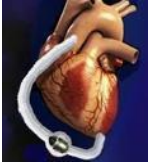Table 1. Patient characteristics and postoperative outcomes

Case	Age	Sex	Diagnosis	Ana-stomotic bleeding	Wound Infection	Flouro time (min)	Pump Flows L/min	Days on Impella	Follow up	Death <30 days
1	76	M	Cardiogenic shock, STEMI	No	No	13.9	4.9	2	Right heart failure, Died after Impella RP placed	Y (2d)
2 Right axillary	76	M	Cardiogenic shock, STEMI	No	No	8.8	4.4	12	Removed, pump thrombosis	N
3 Left axillary	76	M	Cardiogenic shock, STEMI	No	No Enterobacter bacteremia (pneumonia)	6.8	4.5	12	Mitraclip placed for mitral regurgitation	Y (23 d)
4	48	F	Viral myocarditis	No	No	7.5	3.6	15	D/C to quaternary care, D/C LTACH	N
5	74	M	Cardiogenic shock s/p CABGx3	No	No	17	4.5	9	D/C Rehab	N
6	52	F	Decompensated systolic HF	No	No	7.9	5.0	4	Heart transplant	N
7	75	M	Decompensated systolic HF s/p CABGx4, MVR, TV repair	No	No Impella removed for bacteremia, source:sacral wound	3.8	4.5	30	Alive at 30 days	N
8	48	M	Cardiogenic shock, myocarditis	No	No	4.4	4.9	8	D/C home	N

CABG= coronary artery bypass , D/C = Discharged, HF= heart failure, LTACH= Long term acute care hospital, MVR= mitral valve replacement, STEMI= ST elevation myocardial infarction, TV=tricuspid valve

Discussion

The conventional placement of the axillary artery cannulation is a non-tunneling technique. It was originally described by Sabick et al with a side graft and was associated with low morbidity compared with cannulating the artery directly^{4,5}. However, in that report the cannulation was only used temporarily during the operation as inflow for cardiopulmonary bypass.



The main advantages to the tunneling technique compared to conventional placement are the prevention of wound contamination, either in the immediate postoperative period, or in the case of requiring longer-term circulatory support.

A report by Mastroianniet et al. indicates a wound infection rate of 7%, one case (Methicillin resistant *Staphylococcus aureus*) in 14 patients using the conventional technique.⁶ The incidence of bleeding from the arterial outflow graft as reported by others was 17.3 % (14 patients) using an arterial inflow by a side graft sewn to the axillary artery for extracorporeal membrane oxygenation support in a cohort of 308 patients.⁷

Furthermore, it is well known that patients in heart failure are prone to systemic infection due to their compromised immune defense system.⁸ Based on that notion, it is our belief that wound infection rates after mechanical circulatory support device implantation is underreported.

The second advantage of this technique is a potential decrease in clot formation at the anastomotic site between the graft and the recipient axillary artery. This is based on a smoother landing site due to the tunneling, with less formation of eddy current. This assertion should be verified in further studies.

The AA is chosen as the first choice implantation as opposed to other peripheral access because it allows ambulation, and often times one or both groin vessels may have already been used either for extracorporeal membrane oxygenation, or for a temporary right or left ventricular support (Impella 2.5 or Impella CP) before upgrading to Impella 5.0 implantation. Finally, the axillary artery is rarely calcified or is involved in arteriosclerosis.

The graft length must be carefully judged following passage under the shoulder subcutaneous tissue. Redundant graft, which leads to kinking, as well as overstretching which leads to tension on suture line, must both be avoided.

Tunneling the graft into the operative field prior to performing the anastomosis may limit the hand movement of the operating surgeon.

The mean axillary artery diameter in the adult human is 6.38 mm (median 6.2, SD: 1.57 mm), and this size is sufficient for a 21 Fr microaxial pump motor to be introduced without difficulty in the majority of cases.¹⁰ An endovascular dilator (Cook Medical, Bloomington, Indiana), or a Garret dilator 5-6 mm tip flexible shaft (Piling surgical instruments, Morrisville, NC) may be used to predilate the vessel if necessary, Figure 3 A, B. If one AA is small, some patients have asymmetrically sized vessels; therefore, the other side can be checked. If still unable to insert then convert to venoarterial extracorporeal membrane oxygenation.

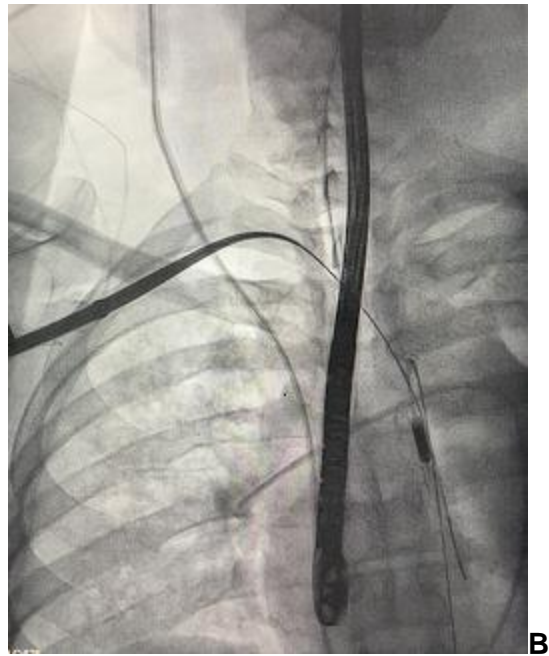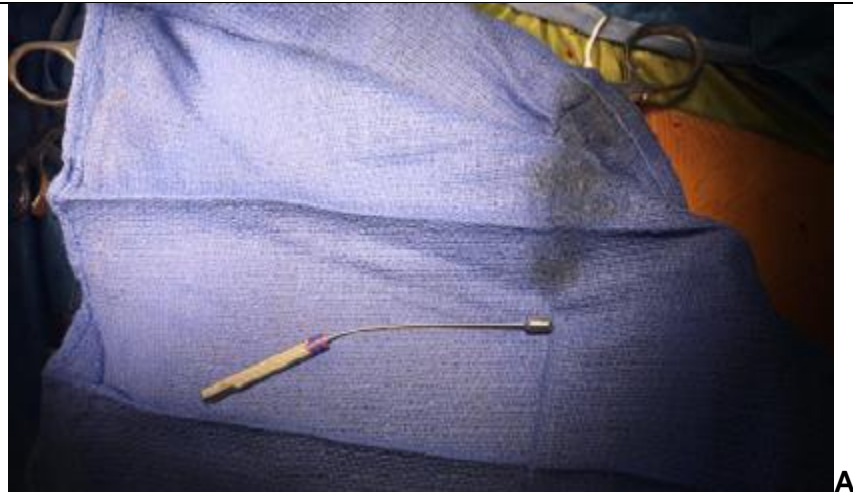


Figure 3 A, B. Photographs of Garret vascular dilator and the endovascular dilator.



References

- 1- Shishehbor MH, Moazami N, Tong MZ, Unai S, Tang WH, Soltesz EG. Cardiogenic shock: From ECMO to Impella and beyond. *Cleveland Clinic Journal of Medicine*. 2017; 84:287-295.
- 2- Ando M, Garan AR, Takayama H, Topkara V, et al. A continuous-flow external ventricular assist device for cardiogenic shock: Evolution over 10 years. *J Thorac Cardiovasc Surg*. 2018; 156:157-65.
- 3- Rutherford RB, editor. *Atlas of vascular surgery-basic techniques and exposures*. Philadelphia, PA: WB Saunders Co, 1993: section 1, page 17.
- 4- Sabik JF, Lytle BW, McCarthy PM, Cosgrove DM. Axillary artery: an alternative site of arterial cannulation for patients with extensive aortic and peripheral vascular disease. *J Thorac Cardiovasc Surg* 1995; 109:885–91.
- 5- Sabik JF, Neme H, Lytle BW, Blackstone EH, Gillinov AM, Rajeswaran J, Cosgrove DM. Cannulation of the axillary artery with a side graft reduces morbidity. *Ann Thorac Surg* 2004; 77:1315–20.
- 6- Mastroianni C, Bouabdallaoui N, Leprince P, Lebreton G. Short-term mechanical circulatory support with the Impella 5.0 device for cardiogenic shock at La Pite-Salpetriere. *Eur Heart J Acute Cardiovasc Care*. 2017; 6:87-92.
- 7- Chamogeorgakis T, Lima B, Shafii AE, Nagpal D, et al. Outcomes of axillary artery side graft cannulation for extracorporeal membrane oxygenation. *J Thorac Cardiovasc Surg*. 2013; 145:1088-92.
- 8- Bansal A, Bhamra JK, Patel R, MD, Desai S, et al. Using the Minimally Invasive Impella 5.0 via the Right Subclavian Artery Cutdown for Acute on Chronic Decompensated Heart Failure as a Bridge to Decision. *Ochsner J*. 2016; 16: 210–216.
- 9- Alon D, Stein GY, Korenfeld R, Fuchs S. Predictors and Outcomes of Infection-Related Hospital Admissions of Heart Failure Patients. *PLoS One*. 2013; 8(8): e72476
- 10- Tayal R, Iftikhar H, LeSar B, Patel R, Tyagi N, Cohen M, Wasty N. CT Angiography Analysis of Axillary Artery Diameter versus Common Femoral Artery Diameter: Implications for Axillary Approach for Transcatheter Aortic Valve Replacement in Patients with Hostile Aortoiliac Segment and Advanced Lung Disease. *Int J Vasc Med*. 2016; 2016:3610705.