



University of Kentucky
UKnowledge

Otolaryngology--Head & Neck Surgery Faculty
Publications

Otolaryngology--Head & Neck Surgery

1-12-2017

Correlation of Positron Emission Tomography/ Computed Tomography Scan with Smoking, Tumor Size, Stage and Differentiation in Head and Neck Cancer Patients

Jordan L. Pleitz
University of Kentucky

Partha Sinha
University of Kentucky

Emily V. Dressler
University of Kentucky

Rony K. Aouad
University of Kentucky, rony.aouad@uky.edu

Right click to open a feedback form in a new tab to let us know how this document benefits you.

Follow this and additional works at: https://uknowledge.uky.edu/otolaryngology_facpub

 Part of the [Biostatistics Commons](#), [Otolaryngology Commons](#), and the [Radiology Commons](#)

Repository Citation

Pleitz, Jordan L.; Sinha, Partha; Dressler, Emily V.; and Aouad, Rony K., "Correlation of Positron Emission Tomography/Computed Tomography Scan with Smoking, Tumor Size, Stage and Differentiation in Head and Neck Cancer Patients" (2017). *Otolaryngology--Head & Neck Surgery Faculty Publications*. 6.

https://uknowledge.uky.edu/otolaryngology_facpub/6

This Article is brought to you for free and open access by the Otolaryngology--Head & Neck Surgery at UKnowledge. It has been accepted for inclusion in Otolaryngology--Head & Neck Surgery Faculty Publications by an authorized administrator of UKnowledge. For more information, please contact UKnowledge@lsv.uky.edu.

Correlation of Positron Emission Tomography/Computed Tomography Scan with Smoking, Tumor Size, Stage and Differentiation in Head and Neck Cancer Patients

Notes/Citation Information

Published in *World Journal of Nuclear Medicine*, v. 16, issue 1, p. 51-55.

© 2016 World Journal of Nuclear Medicine

This is an open access article distributed under the terms of the [Creative Commons Attribution - NonCommercial - ShareAlike 3.0 License](#), which allows others to remix, tweak, and build upon the work non-commercially, as long as the author is credited and the new creations are licensed under the identical terms.

Digital Object Identifier (DOI)

<https://doi.org/10.4103/1450-1147.181156>

Original article

Correlation of Positron Emission Tomography/Computed Tomography Scan with Smoking, Tumor Size, Stage and Differentiation in Head and Neck Cancer Patients

Jordan L. Pleitz, Partha Sinha¹, Emily V. Dressler², Rony K. Aouad

Departments of Otolaryngology - Head and Neck Surgery, ¹Nuclear Medicine and ²Biostatistics, University of Kentucky, Lexington, KY 40536, USA

Abstract

The goal of this study was to identify associations between positron emission tomography/computed tomography (PET/CT) maximum standardized uptake value (SUVmax) in patients presenting with head and neck squamous cell carcinoma (SCC) with tumor site, size, histologic differentiation, smoking, and diabetes. Charts of patients with oropharyngeal and laryngeal SCC who underwent ¹⁸F-fluorodeoxyglucose PET/CT scans were reviewed between May 2007 and August 2013. Statistical analyses included modeling log-transformed SUVmax values by tumor site, size, histologic differentiation, smoking status, and diabetes using unadjusted linear regressions. Differences were considered statistically significant for $P < 0.05$. A total of 111 patients (54 with oropharynx and 57 with larynx cancers) were included, 83 men and 28 women with an average age of 57.5 years old. There was a significantly higher pack-year smoking history ($P = 0.005$) in the larynx cancer group. While tumor T-stage was found to be significantly different ($P < 0.0001$), there was no difference in tumor size between the two groups: 3.16 cm and 3.58 cm in the oropharynx and larynx, respectively ($P = 0.55$). In the oropharynx cohort, SUVmax was associated with both tumor size ($P = 0.0001$) and stage ($P < 0.0002$). Interestingly, SUVmax differed by tumor differentiation in the larynx ($P = 0.04$) but not the oropharynx ($P = 0.71$). Finally, there was no significant difference in SUVmax relative to diabetes and smoking status. PET/CT SUVmax correlated with both tumor size and stage in oropharyngeal cancer patients, and it correlated only with tumor differentiation but not the size or stage in the larynx. There were no significant differences in SUVmax by diabetes or smoking status.

Keywords: Larynx cancer, maximum standardized uptake value, oropharynx cancer, positron emission tomography/computed tomography, smoking, tumor differentiation

Introduction

Positron emission tomography (PET) has gained acceptance as a useful tool in the evaluation and management of head and neck squamous cell

carcinoma (HNSCC).^[1] It relies on radiolabeled ¹⁸F-fluorodeoxyglucose (¹⁸F-FDG), a glucose analog that is transported into, but not metabolized by, actively dividing cells. Increased mitotic activity, and thus increased ¹⁸F-FDG uptake, underlies the ability of PET to detect tissues proliferating at an increased rate. ¹⁸F-FDG uptake within a region of interest is reported as standardized uptake value (SUV), which accounts

Address for correspondence:

Dr. Rony K. Aouad, Department of Otolaryngology - Head and Neck Surgery, University of Kentucky, 800 Rose Street, C-240, Lexington, KY 40536, USA.
E-mail: rony.aouad@uky.edu

This is an open access article distributed under the terms of the Creative Commons Attribution-NonCommercial-ShareAlike 3.0 License, which allows others to remix, tweak, and build upon the work non-commercially, as long as the author is credited and the new creations are licensed under the identical terms.

For reprints contact: reprints@medknow.com

Access this article online

Quick Response Code:



Website:
www.wjnm.org

DOI:
10.4103/1450-1147.181156

How to cite this article: Pleitz JL, Sinha P, Dressler EV, Aouad RK. Correlation of positron emission tomography/computed tomography scan with smoking, tumor size, stage and differentiation in head and neck cancer patients. *World J Nucl Med* 2017;16:51-5.

for injected activity level, incubation time, and patient height and weight. PET/computed tomography (CT) scans combine PET with low-dose CT images, thus providing both physiologic and anatomic information within the head and neck.

The use of ^{18}F -FDG PET/CT for initial HNSCC staging, assessment of tumor response to therapy, and posttreatment surveillance has become increasingly common in clinical practice.^[1] Yoon *et al.* demonstrated the superiority of ^{18}F -FDG PET/CT over CT, magnetic resonance imaging, and ultrasonography in evaluating pretreatment locoregional tumor spread in HNSCC.^[2] The usefulness of whole-body ^{18}F -FDG PET/CT in detecting distant metastatic disease has also been shown.^[3] In a recent meta-analysis of 2335 patients, Gupta *et al.* demonstrated the ability of ^{18}F -FDG PET/CT to determine posttreatment tumor response, especially with studies performed more than 12 weeks following completion of therapy.^[4] Paes *et al.* described the ability of ^{18}F -FDG PET/CT to detect the perineural spread of HNSCC.^[5] In his study of 63 consecutive HNSCC, Schwartz *et al.* found an association between baseline primary tumor FDG SUV and HNSCC outcomes.^[6] Furthermore, Higgins *et al.* demonstrated a negative correlation between pretreatment primary tumor SUV and 2-year disease-free survival.^[7]

The association of ^{18}F -FDG PET/CT findings with specific HNSCC tumor characteristics is a recent topic of interest.^[8] The primary goal of this study was to correlate PET/CT maximum SUV (SUVmax) of index lesions in patients presenting with HNSCC with tumor site, size, and histologic differentiation. The relationship of SUVmax with patient smoking status and diabetes was also investigated.

Materials and Methods

Collection of study data occurred following approval by the Institutional Review Board. The principle investigator retrospectively reviewed the charts of all patients initially diagnosed with HNSCC at our institution between May 2007 and August 2013. Exclusion criteria consisted of prior head and neck cancer treatment, incomplete patient records, and inadequate quality of the CT or PET/CT scans. Patients were divided based on tumor location, including oropharynx primary tumors and larynx primary tumors.

Gathered chart information included patient gender, age, pack-year smoking history, smoking status at the time of PET/CT, and the presence of diabetes. Tumor-specific variables, including location, T-stage, tumor size, differentiation, and locoregional spread were analyzed using pretreatment diagnostic CTs performed nearest the

time of PET/CT. The tumor size was defined as the greatest tumor dimension (cm) measured in one of the three planes (axial, sagittal, or coronal). Histopathologic analyses were performed on specimens obtained using pretreatment biopsies and primary surgical excisions, when available. All pathologic specimens were formalin-fixed and stained using hematoxylin and eosin. Tumor differentiation was classified as well, moderate, or poor. The CT scans were excluded if they were low quality, thicker than 3 mm and the measurements were difficult to be made.

All patients scanned at our institution underwent pretreatment ^{18}F -FDG PET/CT with a Biograph TruPoint 6 scanner (Siemens Healthcare, Germany) using lutetium oxyorthosilicate crystals. Scans were performed in two-dimensional mode. Before scanning, patients fasted at least 6 h (with the exception of water). Blood glucose levels were determined before injection of ^{18}F -FDG. Scans were not performed on patients with glucose levels >200 mg/dL. Patients were weighed immediately before tracer injection. Following tracer injection, patients were given 10 mL gastrografin oral contrast per institutional guidelines. No intravenous contrast was used.

After voiding, patients underwent low-dose head and neck CT (256 × 256 matrix, 1.5 mm slice thickness). PET imaging of the head and neck (256 × 256 matrix, 1.5 mm slice thickness) was performed immediately thereafter. Two-bed positions were used, with an emission time of 5 min per position. Following this, “eyes-to-thigh” supine imaging was performed using low-dose, nonbreath holding CT (256 × 256 matrix, 3 mm slice thickness) followed by PET (256 × 256 matrix, 1.5 mm slice thickness). Seven bed positions were used, with an emission time of 3 min per position.

Somaris 5 software (Siemens Healthcare, Germany) with two iterative passes was used for image reconstruction. Images were interpreted by board-certified nuclear medicine physicians using a Syngo MMWP VE36A Workstation (Siemens Healthcare, Germany). Primary tumors were assessed with zoomed head and neck images. Images were reviewed in axial, coronal, and sagittal planes. SUVmax of lesions were calculated in three-dimensional by manually placing a region of interest in one plane to encompass the entire lesion [Figure 1]. Automated computer generated planes in the other two planes were then reviewed and adjusted if necessary to ensure that the entire tumor volume was included in all three planes and no physiologic structure with increased uptake (e.g., salivary glands) was included. SUV calculations were based on body volume (derived from patient weight), injected activity, and incubation time. Corrections for lean body mass were not made.

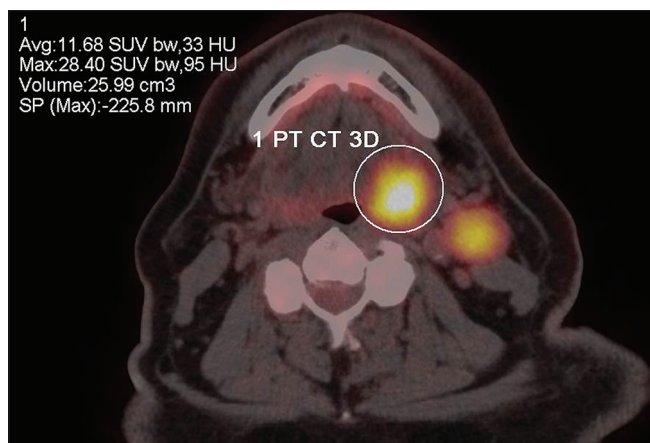


Figure 1: An example of maximum standardized uptake value of a left oropharynx tumor

All histopathologic and radiographic findings were reviewed at multidisciplinary tumor board and approved by our neuroradiologists and head and neck pathologists before their respective reports signed.

Statistical analysis correlating SUVmax with current smoking status, serum glucose level, T-stage, tumor size, and tumor differentiation was performed. The primary endpoint of SUVmax was log transformed to allow for parametric comparisons between cancer types using Fisher's exact tests and 2-sample *t*-tests for categorical and continuous outcomes, respectively. Differences in log mean SUVmax between various demographic and clinical variables were considered in subsets of larynx or oropharynx cancer types. Strategies included linear regression models and Pearson correlations stratified by cancer type. Mean least square regression estimates with standard deviation (SD) of log SUVmax by categories are presented with corresponding *P* values. Differences were considered statistically significant for *P* < 0.05.

Results

A total of 111 patients were included in the study, and characteristics are presented in Table 1. 57 patients (41 males, 16 females) were included in the larynx cancer cohort whereas 54 patients (42 males, 12 females) were included in the oropharynx cohort. Mean age was 57.46 years (SD 8.35) and 60.06 (SD 8.74) in the larynx and oropharynx groups, respectively (*P* = 0.11). Mean smoking history was 33.13 pack-years (SD 38.61) in the oropharynx cohort and 53.47 pack-years (SD 34.65) in the larynx cohort (*P* = 0.005). In the oropharynx group, 18 patients (34%) were current smokers whereas 20 patients (37.7%) had previously quit and 15 patients (28.3%) never smoked. In the larynx group, 37 patients (66.1%) were current smokers

Table 1: Patients characteristics

	Oropharynx (n=54)		Larynx (n=57)		Difference between groups (P)
Gender					
Men	42	77.78%	41	71.93%	
Women	12	22.22%	16	28.07%	
Age (years)	60.06	SD: 8.74	57.46	SD: 8.35	0.11
Smoking					
Current	18	33.33%	37	64.91%	0.002
Previous	21	38.88%	14	24.56%	
Never	15	27.77%	5	8.77%	
Pack/year	33		53.5		0.005
T-stage					
T1	8		2		
T2	21		8		
T3	3		25		
T4	22		22		
Staging					
I-II	2	3.70%	5	8.77%	
III-IV	52	96.30%	52	91.23%	
Size (cm)	3.16	SD: 1.14	3.58	SD: 1.39	0.09
Glucose	100.1	SD: 16.61	102.2	SD: 20.41	0.55
SUVmax (log transformed)	2.52	SD: 0.40	2.50	SD: 0.40	0.87

SD: Standard deviation; SUVmax: Maximum standardized uptake value

whereas 14 patients (25%) had previously quit and 5 patients (8.9%) never smoked. Smoking status was unknown in one patient for both the oropharynx cancer and larynx cancer cohorts. There was a significant difference in smoking status between the two groups (*P* = 0.002).

Oropharynx T-staging was as follows: T1-tumors (*n* = 8, 14.8%), T2-tumors (*n* = 21, 38.9%), T3-tumors (*n* = 3, 5.6%), and T4-tumors (*n* = 22, 40.7%). Larynx T-staging was as follows: T1-tumors (*n* = 2, 3.5%), T2-tumors (*n* = 8, 14%), T3-tumors (*n* = 25, 43.9%), and T4-tumors (*n* = 22, 38.6%). Tumor T-staging between the two groups was significantly different (*P* < 0.0001). Mean oropharynx tumor size was 3.16 cm (SD 1.14) whereas mean larynx tumor size was 3.58 cm (SD 1.39). There was no significant difference in tumor size between the two groups (*P* = 0.09).

Overall log transformed mean SUVmax was 2.52 (SD 0.40) in the oropharynx cohort and 2.50 (SD 0.40) in the larynx cancer cohort (*P* = 0.87). Scatter plots with the linear regression estimate plotted for the log transformed SUVmax by type are shown in Figures 2 and 3. In the oropharynx group, SUVmax is significantly associated with both tumor size (*P* < 0.0001) and stage (*P* = 0.0002). In the larynx group, there was no significant difference in SUVmax based on tumor size (*P* = 0.38) or stage (*P* = 0.25). Interestingly, SUVmax significantly is associated with larynx tumor differentiation (*P* = 0.04) but

not the oropharynx ($P = 0.71$). Furthermore, there was no significant difference between SUVmax, diabetes ($P = 0.21$ and $P = 0.86$) and smoking status ($P = 0.99$ and $P = 0.56$) in both groups, respectively. Model estimates for SUVmax are shown in Table 2.

Discussion

The use of ^{18}F -FDG PET/CT for initial HNSCC staging, assessment of tumor response to therapy, and posttreatment surveillance has become increasingly common in clinical practice.^[1] Numerous studies have

shown the superiority of the PET/CT in determining pretreatment locoregional spread,^[2] distant metastasis,^[3] and posttreatment response in SCC of the head and neck of the head and neck.^[4]

The primary goal of this study was to correlate PET/CT SUVmax with HNSCC tumor site, size, and histologic differentiation. Interestingly, this study showed that SUVmax correlated with tumor size ($P < 0.0001$) and stage ($P < 0.0002$) in the oropharynx only. It is important to note that the T-stage in the larynx does not

Table 2: Associations with log transformed maximum standardized uptake value for larynx and oropharynx cancer

	Oropharynx			Larynx		
	SUVmax estimate	SD	P	SUVmax estimate	SD	P
Tumor size (cm)	0.23	0.04	0.0001*	0.03	0.04	0.38
Stage						
T1	2.08	0.13	0.0002*	2.58	0.28	0.25
T2	2.44	0.07		2.42	0.14	
T3	3.03	0.19		2.41	0.08	
T4	2.66	0.07		2.63	0.09	
Differentiation						
Poor	2.54	0.07	0.71	2.52	0.08	0.04*
Moderate	2.46	0.09		2.53	0.07	
Well	2.67	0.4		1.94	0.22	
Smoking						
Current	2.52	0.1	0.99	2.5	0.07	0.56
Former	2.51	0.09		2.56	0.11	
Never	2.51	0.11		2.33	0.18	
Diabetes						
Yes	2.66	0.13	0.21	2.47	0.17	0.86
No	2.48	0.06		2.51	0.06	

*Unadjusted linear regression model estimates. SD: Standard deviation; SUVmax: Maximum standardized uptake value

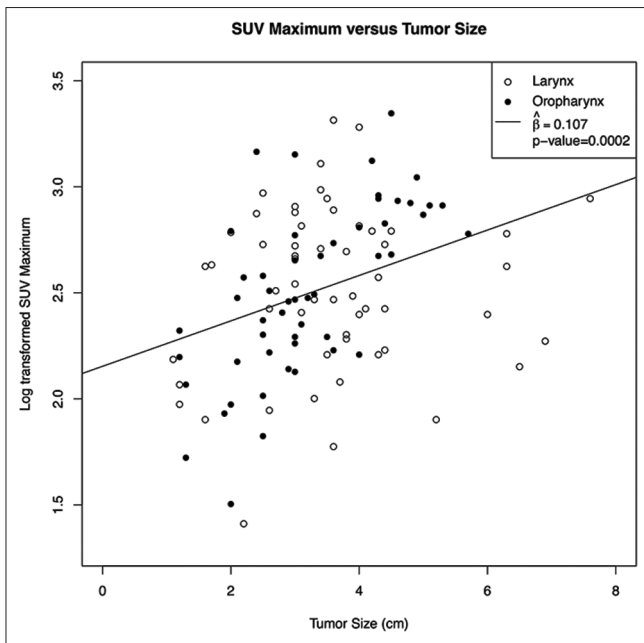


Figure 2: Scatter plot with the linear regression estimate plotted for the log transformed maximum standardized uptake value by type

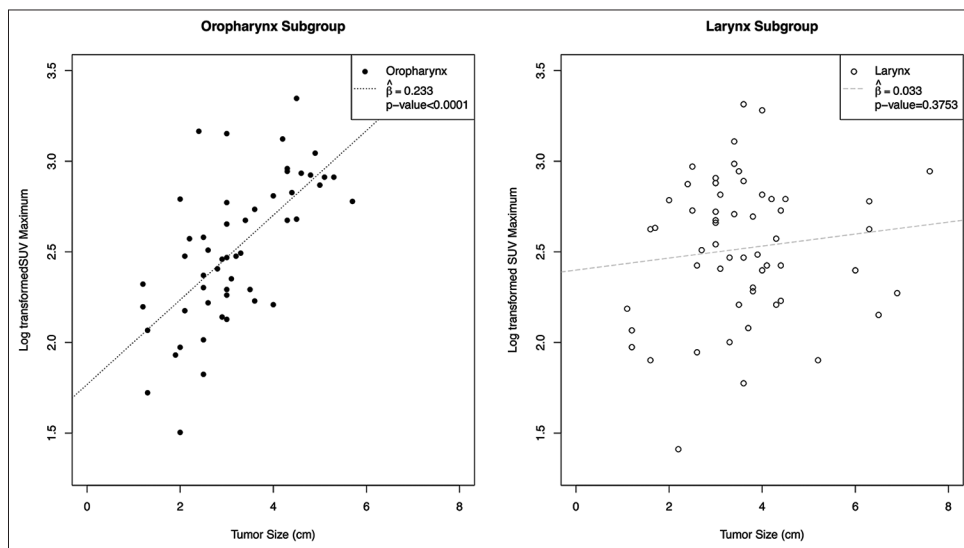


Figure 3: Scatter plot with the linear regression estimate plotted for the log transformed maximum standardized uptake value by type for the whole-group

follow the size of the tumor but the subsites involved by the tumor and the mobility of the vocal cord: A 1 cm tumor of the base of the tongue is staged a T1 of the oropharynx, but it could be staged a T3 of the larynx if the vocal cord is immobile. Similar results were found by Haerle *et al.*^[8] in their study of newly diagnosed HNSCC patients where a positive association of SUVmax was found with T-classification. However, unlike Haerle's study, we also observed a correlation between SUVmax and tumor histologic differentiation in the larynx: The higher the SUV, the higher tumor differentiation.

The secondary endpoint of this study was to examine the association between SUVmax and smoking history of the head and neck cancer patients. The relationship of SUVmax and tobacco usage is poorly reported in the literature. Na *et al.*^[9] studied the association between smoking history, SUV, and nodal disease in nonsmall-cell lung cancer and he found the SUV of nonsmokers was less than the SUV of smokers ($P < 0.001$). Our results did not demonstrate a significant correlation between SUVmax and smoking status in either oropharynx or larynx cancer patients. To the best of our knowledge, this is the first study correlating SUVmax and smoking status in HNSCC.

Despite those interesting findings, our study has some limitations. The study is retrospective by design. In addition, pack-year, which is considered to be the standard way of measuring the smoking history, was determined based on patient responses recorded during their initial presentation to the clinic. This measure may have been flawed given its subjectivity and reliance on "rounded" numbers. Future studies may potentially overcome this by analyzing objective measures of tobacco use (e.g., serum cotinine levels). In addition, it is challenging to compare oropharynx and larynx cancers SUVmax with regards to T-size given the differences in TNM staging between the two subsites. A large tumor in the oropharynx may only be considered a T1-T2 (<4 cm without deep muscle invasion) while a small tumor of the larynx with immobility of the vocal fold is a T3. Furthermore, this study did include several tumors <1.5 cm, in which accuracy of SUVmax decreases.^[1] The effect of these inaccuracies was likely small, as these tumors only accounted for five patients in the oropharynx cohort and three patients in the larynx cohort. Finally, the method we used to measure the size of the tumor may be another source of weakness despite all our efforts to minimize this human error.

Conclusion

Our study showed that SUVmax correlated with both tumor size and stage in oropharyngeal cancers, but not histologic differentiation unlike in the larynx where SUVmax correlated with tumor differentiation but not with size and stage of the tumor. We did not find any correlation between SUVmax and diabetes or smoking status. These findings are sure interesting, however future research is needed to help determine the clinical significance of PET/CT's SUVmax in head and neck cancer, especially in counseling patients before their treatment.

Financial support and sponsorship

Nil.

Conflicts of interest

There are no conflicts of interest.

References

1. Escott EJ. Role of positron emission tomography/computed tomography (PET/CT) in head and neck cancer. *Radiol Clin North Am* 2013;51:881-93.
2. Yoon DY, Hwang HS, Chang SK, Rho YS, Ahn HY, Kim JH, *et al.* CT, MR, US, 18F-FDG PET/CT, and their combined use for the assessment of cervical lymph node metastases in squamous cell carcinoma of the head and neck. *Eur Radiol* 2009;19:634-42.
3. Xu GZ, Zhu XD, Li MY. Accuracy of whole-body PET and PET-CT in initial M staging of head and neck cancer: A meta-analysis. *Head Neck* 2011;33:87-94.
4. Gupta T, Master Z, Kannan S, Agarwal JP, Ghosh-Laskar S, Rangarajan V, *et al.* Diagnostic performance of post-treatment FDG PET or FDG PET/CT imaging in head and neck cancer: A systematic review and meta-analysis. *Eur J Nucl Med Mol Imaging* 2011;38:2083-95.
5. Paes FM, Singer AD, Checkver AN, Palmquist RA, De La Vega G, Sidani C. Perineural spread in head and neck malignancies: Clinical significance and evaluation with 18F-FDG PET/CT. *Radiographics* 2013;33:1717-36.
6. Schwartz DL, Rajendran J, Yueh B, Coltrera MD, Leblanc M, Eary J, *et al.* FDG-PET prediction of head and neck squamous cell cancer outcomes. *Arch Otolaryngol Head Neck Surg* 2004;130:1361-7.
7. Higgins KA, Hoang JK, Roach MC, Chino J, Yoo DS, Turkington TG, *et al.* Analysis of pretreatment FDG-PET SUV parameters in head-and-neck cancer: Tumor SUVmean has superior prognostic value. *Int J Radiat Oncol Biol Phys* 2012;82:548-53.
8. Haerle SK, Huber GF, Hany TF, Ahmad N, Schmid DT. Is there a correlation between ¹⁸F-FDG PET SUVmax, T-classification, histological grading, and the anatomic subsite in newly diagnosed squamous cell carcinoma of the head and neck? *Eur Arch Otorhinolaryngol* 2010;267:1635-40.
9. Na II, Park JY, Kim KM, Cheon GJ, Choe DH, Koh JS, *et al.* Significance of smoking history and FDG uptake for pathological N2 staging in clinical N2-negative non-small-cell lung cancer. *Ann Oncol* 2011;22:2068-72.