



University of Kentucky
UKnowledge

Gluck Equine Research Center Faculty Publications

Gluck Equine Research Center

9-2015

Recurrent *Streptococcus equi* subsp. *zooepidemicus* Bacteremia in an Infant

Joshua R. Watson
Ohio State University

Amy Leber
Ohio State University

Sridhar Velineni
University of Kentucky, sridharvelineni@uky.edu

John F. Timoney
University of Kentucky, jtimoney@uky.edu

Monica I. Ardura
Ohio State University

Right click to open a feedback form in a new tab to let us know how this document benefits you.

Follow this and additional works at: https://uknowledge.uky.edu/gerc_facpub

 Part of the [Large or Food Animal and Equine Medicine Commons](#)

Repository Citation

Watson, Joshua R.; Leber, Amy; Velineni, Sridhar; Timoney, John F.; and Ardura, Monica I., "Recurrent *Streptococcus equi* subsp. *zooepidemicus* Bacteremia in an Infant" (2015). *Gluck Equine Research Center Faculty Publications*. 9.
https://uknowledge.uky.edu/gerc_facpub/9

This Article is brought to you for free and open access by the Gluck Equine Research Center at UKnowledge. It has been accepted for inclusion in Gluck Equine Research Center Faculty Publications by an authorized administrator of UKnowledge. For more information, please contact UKnowledge@sv.uky.edu.

Recurrent *Streptococcus equi* subsp. *zooepidemicus* Bacteremia in an Infant

Notes/Citation Information

Published in *Journal of Clinical Microbiology*, v. 53, no. 9, p. 3096-3099.

Copyright © 2015, American Society for Microbiology. All Rights Reserved.

The copyright holders have granted the permission for posting the article here.

Digital Object Identifier (DOI)

<http://dx.doi.org/10.1128/JCM.01306-15>

Recurrent *Streptococcus equi* subsp. *zooepidemicus* Bacteremia in an Infant

Joshua R. Watson,^a Amy Leber,^{a,b} Sridhar Velineni,^c John F. Timoney,^c Monica I. Ardura^a

Department of Pediatrics, Infectious Diseases and Immunology, Nationwide Children's Hospital, and The Ohio State University, Columbus, Ohio, USA^a; Departments of Pathology and Laboratory Medicine, Nationwide Children's Hospital, Columbus, Ohio, USA^b; Gluck Equine Research Center, University of Kentucky, Lexington, Kentucky, USA^c

We describe a case of an infant with recurrent bacteremia caused by *Streptococcus equi* subsp. *zooepidemicus*, likely transmitted from mother to infant. Our case highlights the importance of an epidemiological history and molecular diagnostics in ascertaining insights into transmission, pathogenesis, and optimal management.

CASE REPORT

A male infant was born via spontaneous vaginal delivery to a gravida 1, para 1 female at 32 weeks and 6 days of gestation because of preterm labor with Apgar scores of 7 at 1 min and 8 at 5 min. The mother's group B streptococcal colonization status was unknown, and she received 2 doses of ampicillin prior to delivery. Artificial rupture of membranes occurred approximately 1 h prior to delivery. Placental pathology was normal. The infant required continuous positive airway pressure for respiratory distress and received 1 dose of surfactant. He was admitted to the neonatal intensive care unit at the delivery hospital and received ampicillin and gentamicin until a blood culture was negative at 48 h. On day of life (DOL) 12, the infant developed apnea, bradycardia, and hypoxemia. Physical examination revealed poor perfusion, poor tone, and skin erythema on the right side of his neck, chest, and abdomen. Neck ultrasound demonstrated parotitis and cellulitis, and blood culture yielded Gram-positive cocci identified by the outside hospital as group C streptococcus (GCS). He received intravenous ampicillin for 10 days with clinical improvement and clearance of bacteremia. He was discharged home on DOL 23.

The infant did well until DOL 28, when his parents noted nasal congestion, poor feeding of expressed human milk and infant formula, and decreased activity. On DOL 29, he developed altered breathing and central cyanosis after a feeding. Transient skin erythema on the right side of the neck was also noted. Review of systems was negative for fever, cough, emesis, and seizures. At the Nationwide Children's Hospital emergency department, he developed apnea, bradycardia, and hypoxemia requiring intubation and mechanical ventilation. Laboratory studies and cultures were obtained, and empirical ampicillin and cefotaxime administration was initiated. In the pediatric intensive care unit, he required intravenous fluid resuscitation, vasopressors, and stress dose corticosteroids for hypotension and poor perfusion. A complete blood count, hepatic panel, and cerebrospinal fluid analysis were unremarkable. Chest X-ray, echocardiogram, and computed tomography of the head and neck were normal. Rhinovirus was detected in a nasopharyngeal sample by PCR (1). Peripheral blood cultures were obtained, and the aerobic blood culture was positive for Gram-positive cocci in pairs and chains at 14 h of incubation (BacT/Alert FN; bioMérieux, Durham, NC). Initial subculture revealed colonies that were 1 to 2 mm in diameter with a large zone of beta-hemolysis on sheep blood agar (Fig. 1) and were identified

as GCS based on a negative catalase test and a latex agglutination result positive for group C antigen (Streptex; Remel, Lenexa, KS). The initial blood isolate from the outside hospital was also obtained, and the identification of GCS was confirmed by the aforementioned methods. Results of antimicrobial susceptibility testing (2) of both isolates were as follows: susceptible to penicillin (MIC, 0.03 µg/ml, Etest; bioMérieux, Durham, NC), resistant to clindamycin (disk diffusion), and a rifampin MIC of 0.023 µg/ml (Etest). Culture from the endotracheal tube aspirate also yielded rare GCS; urine and cerebrospinal fluid cultures were negative. The infant was extubated on hospital day 6 and demonstrated continued clinical improvement. He had documented clearance of bacteremia within 24 h and received 18 days of intravenous ampicillin. Evaluation for primary immunodeficiency was negative.

Additional history revealed that 48 h prior to the patient's first episode of GCS sepsis, his mother had developed fever and malaise requiring hospitalization. Her blood and urine cultures were negative, and her symptoms resolved. Days before the patient's second episode of GCS sepsis, the mother developed pharyngitis. A throat culture yielded GCS, for which she was prescribed azithromycin. Epidemiological history revealed that the family lived on a farm in Ohio where the father cared for approximately 100 horses, none of which were ill.

Throat cultures obtained from both parents during the second hospitalization were negative for GCS carriage. The infant and his parents were treated with a 2-day course of rifampin prior to hospital discharge. At a 6-week follow-up appointment, the infant was clinically well. Throat cultures from the infant and father at

Received 19 May 2015 Returned for modification 15 June 2015
Accepted 10 July 2015

Accepted manuscript posted online 15 July 2015

Citation Watson JR, Leber A, Velineni S, Timoney JF, Ardura MI. 2015. Recurrent *Streptococcus equi* subsp. *zooepidemicus* bacteremia in an infant. *J Clin Microbiol* 53:3096–3099. doi:10.1128/JCM.01306-15.

Editor: A. B. Onderdonk

Address correspondence to Monica I. Ardura, monica.ardura@nationwidechildrens.org.

Copyright © 2015, American Society for Microbiology. All Rights Reserved.
doi:10.1128/JCM.01306-15

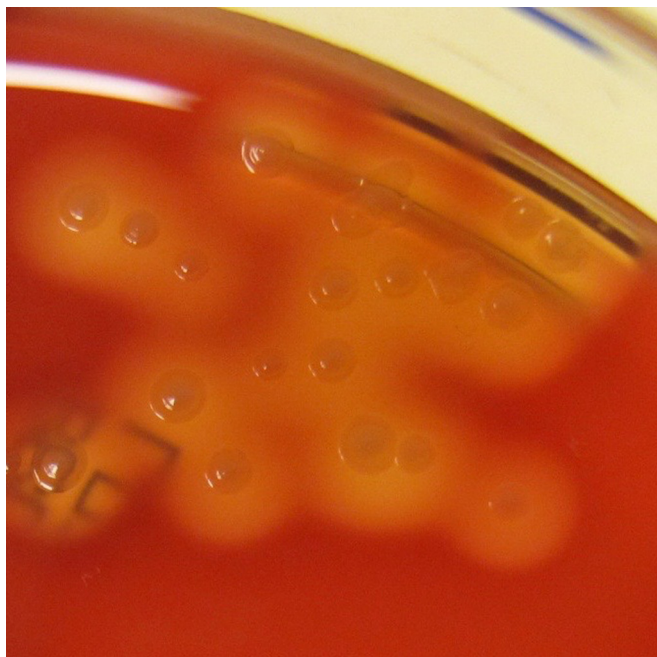


FIG 1 Subculture of the infant's blood isolate on sheep blood agar after 24 h of incubation at 35°C in 5% CO₂. Colonies were 1 to 2 mm in diameter, slightly umbonate, shiny, and gray to clear with entire edges and a large zone of beta-hemolysis. The final identification was *S. equi* subsp. *zooepidemicus*.

that time were negative. The mother's throat culture yielded an isolate that was identified as described above as GCS susceptible to penicillin (MIC, 0.03 µg/ml), resistant to clindamycin (disk diffusion), and with a rifampin MIC of 0.023 µg/ml. Concern that maternal GCS pharyngeal colonization could serve as a source of re-exposure of the infant to GCS prompted treatment of the mother with oral penicillin for 10 days combined with rifampin during the final 4 days. At an appointment 3 months following the second hospitalization, the infant continued to do well and had negative throat and rectal cultures. Maternal throat culture was also negative at that time. At 16 months of age, the infant has had no further recurrences of GCS bacteremia or sepsis.

Further phenotypic characterization was performed with the two blood isolates from the infant and the throat isolate from the mother (from the 6-week follow-up appointment). The isolates were identified as *Streptococcus equi* subsp. *zooepidemicus* by Vitek 2 (bioMérieux, Durham, NC) by using the Gram-positive identification card with 99% probability and excellent identification

confidence. The isolates fermented lactose and sorbitol but not trehalose, consistent with *S. equi* subsp. *zooepidemicus* (3). Matrix-assisted laser desorption/ionization–time of flight mass spectrometry (Vitek MS; bioMérieux, Durham, NC) was performed and identified all of the isolates as *S. equi* subsp. *zooepidemicus* with a confidence value of 99.9 (Vitek MS IVD version 2.0, unclaimed identification).

Sequencing of the 16S rRNA genes (MicroSEQ 500 16S rDNA Bacterial Identification System; Life Technologies, Grand Island, NY) of the three isolates revealed identical 499-bp consensus sequences. Comparison to sequences available in databases at the National Center for Biotechnology Information, MicroSEQ v2.1, and SmartGene (Lausanne, Switzerland) showed that our isolates clustered closely with *S. equi* subsp. *equi* and *zooepidemicus*, but the sequence length was not sufficient to reliably distinguish between the two subspecies.

Analysis of the isolates by pulse-field gel electrophoresis (PFGE) with SmaI revealed that the two blood isolates from the infant were indistinguishable from one another. The PFGE pattern of the isolate from the mother's throat culture had two bands different from the infant's blood isolates, a difference that may be explained by a single genetic event (4). The PFGE results indicate that the mother's isolate was closely related to the infant's isolates and was probably the same strain.

Additional molecular characterization of the isolates is shown in Table 1. The *S. equi* subsp. *zooepidemicus* *szm* and *szp* genes were detected and sequenced (5) and were identical in the three isolates. Molecular detection of *S. equi* subsp. *equi* genes *eqbN* and *se18.9* was also attempted (6, 7). Absence of *eqbN* and *se18.9* (as found in *S. equi* subsp. *equi*), together with the presence of identical *szm* and *szp* sequences typical of *S. equi* subsp. *zooepidemicus*, in all three isolates confirmed the identification and supported the conclusion that the isolates from the infant and the mother were the same strain of *S. equi* subsp. *zooepidemicus*. Multilocus sequence typing (MLST) (5) revealed that all three isolates had the same novel sequence type, 190 (ST190) (<http://pubmlst.org/szooepidemicus/>). As may be seen in *S. equi* subsp. *zooepidemicus*, superantigen genes *szn* and *szp*, but not *szf*, were detected by PCR (8).

This report describes, to our knowledge, the first case of recurrent *S. equi* subsp. *zooepidemicus* infection in a young infant. Epidemiological history prompted a detailed molecular characterization that identified the bacterial isolates as *S. equi* subsp.

TABLE 1 Molecular characterization of *S. equi* subsp. *zooepidemicus* clinical isolates from infant and mother^a

Source of bacterial isolate	MLST result	<i>S. equi</i> subsp. <i>zooepidemicus</i>					<i>S. equi</i> subsp. <i>equi</i>	
		SzP protein ^b	SzM protein ^c	<i>szf</i>	<i>szn</i>	<i>szp</i>	<i>eqbN</i>	<i>se18.9</i>
Infant's blood								
Initial episode	ST190	N2HV5, 5PEPK	A3(b), B2 tandem repeats	Absent	Present	Present	Absent	Absent
Recurrent episode	ST190	N2HV5, 5PEPK	A3(b), B2 tandem repeats	Absent	Present	Present	Absent	Absent
Mother's throat at 6-wk follow-up								
	ST190	N2HV5, 5PEPK	A3(b), B2 tandem repeats	Absent	Present	Present	Absent	Absent

^a SzP, protective protein; SzM, M-like protein; *szf*, *szn*, and *szp*, superantigen genes; *eqbN*, equibactin gene of *S. equi* subsp. *equi*; *se18.9*, gene for factor H binding protein of *S. equi* subsp. *equi*; N2HV5, N-terminal N2 and hypervariable 5 sequence motifs; 5PEPK, five carboxy-terminal PEPK repeats.

^b The N, HV, and PEPK regions of SzP are variable among isolates of *S. equi* subsp. *zooepidemicus*. The genes were completely sequenced and were identical in all three isolates (18).

^c The A and B regions of SzM are variable among isolates of *S. equi* subsp. *zooepidemicus*. The genes were completely sequenced and were identical in all three isolates (19).

zoepidemicus (ST190) and elucidated the mother as the potential source. This result provided a risk factor that could be modified to prevent future disease.

S. equi subsp. *zoepidemicus* and its clonal derivative *S. equi* subsp. *equi* share high DNA homology but differ in their pathogenicity (9). *S. equi* subsp. *equi* is the causative agent of a highly contagious respiratory tract infection of horses called strangles. *S. equi* subsp. *zoepidemicus*, in contrast, is a commensal organism of equine mucosal surfaces that may cause invasive infections in horses during times of viral infection, heat stress, or tissue injury (8, 9).

The production of superantigens may be important in the pathogenesis of *S. equi* subsp. *zoepidemicus* infections. Similar to *Streptococcus pyogenes*, three genes encoding superantigens (*szf*, *szn*, and *szp*) have been described in the *S. equi* subsp. *zoepidemicus* genome (8). Of 165 *S. equi* subsp. *zoepidemicus* isolates examined by Paillot et al. (8), one or more superantigens were detected in 49%. The three superantigens possess a characteristic amino acid sequence signature, and their amino acid sequences are 34 to 59% identical to those of superantigens produced by *S. pyogenes*. The presence of *szn* and *szp* was associated with mitogenic activity, but the presence of *szf* was not. In our case, both *szn* and *szp*, but not *szf*, were detected.

Cases of *S. equi* subsp. *zoepidemicus* infections in adults with close and continuous contact with horses and dogs have been described previously (10, 11). A search of the MEDLINE database for English-language publications of infections in infants ≤ 3 months of age with the key words “Group C Strep*,” “*Streptococcus equi*,” and “*Streptococcus zoepidemicus*” yielded three prior reports that identified *S. equi* subsp. *zoepidemicus* causing meningitis and sepsis (12–14). Two of the cases occurred during outbreaks related to the consumption of unpasteurized cow’s milk but without confirmation of infection in family members of the infants (12, 13). Another report of *S. equi* subsp. *zoepidemicus* infection described a 14-week-old infant whose family owned a horse (15). In that case, the mother had a lower respiratory tract infection 3 weeks before the infant’s illness, but she was not tested for *S. equi* subsp. *zoepidemicus* colonization. In the case of our infant, results of molecular analysis supported mother-to-infant transmission. Although we questioned the possibility of an equine reservoir, we were unable to test the horses to confirm a zoonosis. No cases of recurrent *S. equi* subsp. *zoepidemicus* infection during the first 3 months of life were found in the published literature.

Because of concern that the patient’s mother was a chronic pharyngeal carrier of *S. equi* subsp. *zoepidemicus*, she was treated with penicillin and rifampin according to guidelines for chronic *S. pyogenes* carriage (16, 17). We believed this was a necessary intervention given the infant’s recurrent episodes of sepsis, prematurity, and immature immune system. This strategy appeared to be successful at least temporarily, as evidenced by a negative maternal throat culture at the 3-month follow-up visit and lack of disease recurrence in the infant.

In conclusion, this report describes the first case of recurrent bacteremia in a young infant caused by *S. equi* subsp. *zoepidemicus*, likely transmitted from mother to infant. Molecular characterization of bacterial isolates was essential to determine the precise identity of the pathogen and to identify modifiable risk factors for recurrent infection. Additionally, molecular techniques detected superantigen genes that may explain the organism’s pathogenicity. Clinicians should be aware that *S. equi*

subsp. *zoepidemicus* may cause invasive infections in young infants and that recurrence is possible.

Nucleotide sequence accession numbers. The nucleotide sequences of the *S. equi* subsp. *zoepidemicus* *szm* and *szp* genes have been deposited in the GenBank database and assigned accession numbers [KP735516](#) (*szm*) and [KP735515](#) (*szp*).

ACKNOWLEDGMENT

We thank Susi Miller, medical librarian at Nationwide Children’s Hospital, for her assistance with the literature search.

REFERENCES

- Lu X, Holloway B, Dare RK, Kuypers J, Yagi S, Williams JV, Hall CB, Erdman DD. 2008. Real-time reverse transcription-PCR assay for comprehensive detection of human rhinoviruses. *J Clin Microbiol* 46:533–539. <http://dx.doi.org/10.1128/JCM.01739-07>.
- Clinical and Laboratory Standards Institute. 2014. Performance standards for antimicrobial susceptibility testing; 23rd informational supplement. CLSI M100-S24. Clinical and Laboratory Standards Institute, Wayne, PA.
- Edwards PR. 1933. Further studies on the differentiation of human and animal strains of hemolytic streptococci. *J Bacteriol* 25:527–536.
- Tenover FC, Arbeit RD, Goering RV, Mickelsen PA, Murray BE, Persing DH, Swaminathan B. 1995. Interpreting chromosomal DNA restriction patterns produced by pulsed-field gel electrophoresis: criteria for bacterial strain typing. *J Clin Microbiol* 33:2233–2239.
- Velineni S, Timoney JF, Russell K, Hamlen HJ, Pesavento P, Fortney WD, Crawford PC. 2014. Clones of *Streptococcus zoepidemicus* from outbreaks of hemorrhagic canine pneumonia and associated immune responses. *Clin Vaccine Immunol* 21:1246–1252. <http://dx.doi.org/10.1128/CVI.00222-14>.
- Heather Z, Holden MT, Steward KF, Parkhill J, Song L, Challis GL, Robinson C, Davis-Poynter N, Waller AS. 2008. A novel streptococcal integrative conjugative element involved in iron acquisition. *Mol Microbiol* 70:1274–1292. <http://dx.doi.org/10.1111/j.1365-2958.2008.06481.x>.
- Ijaz M, Velineni S, Timoney JF. 2011. Selective pressure for allelic diversity in SeM of *Streptococcus equi* does not affect immunoreactive proteins SzPse or SeI8.9. *Infect Genet Evol* 11:1159–1163. <http://dx.doi.org/10.1016/j.meegid.2011.01.011>.
- Paillot R, Darby AC, Robinson C, Wright NL, Steward KF, Anderson E, Webb K, Holden MT, Efstratiou A, Broughton K, Jolley KA, Priestnall SL, Marotti Campi MC, Hughes MA, Radford A, Erles K, Waller AS. 2010. Identification of three novel superantigen-encoding genes in *Streptococcus equi* subsp. *zoepidemicus*, *szf*, *szn*, and *szp*. *Infect Immun* 78:4817–4827. <http://dx.doi.org/10.1128/IAI.00751-10>.
- Timoney JF. 2004. The pathogenic equine streptococci. *Vet Res* 35:397–409. <http://dx.doi.org/10.1051/vetres:2004025>.
- Pelkonen S, Lindahl SB, Suomala P, Karhukorpi J, Vuorinen S, Koivula I, Vaisanen T, Penttinen J, Autio T, Tuuminen T. 2013. Transmission of *Streptococcus equi* subspecies *zoepidemicus* infection from horses to humans. *Emerg Infect Dis* 19:1041–1048. <http://dx.doi.org/10.3201/eid1907.121365>.
- Abbott Y, Acke E, Khan S, Muldoon EG, Markey BK, Pinilla M, Leonard FC, Steward K, Waller A. 2010. Zoonotic transmission of *Streptococcus equi* subsp. *zoepidemicus* from a dog to a handler. *J Med Microbiol* 59:120–123. <http://dx.doi.org/10.1099/jmm.0.012930-0>.
- Barrett NJ. 1986. Communicable disease associated with milk and dairy products in England and Wales: 1983–1984. *J Infect* 12:265–272. [http://dx.doi.org/10.1016/S0163-4453\(86\)94320-3](http://dx.doi.org/10.1016/S0163-4453(86)94320-3).
- Edwards AT, Roulson M, Ironside MJ. 1988. A milk-borne outbreak of serious infection due to *Streptococcus zoepidemicus* (Lancefield group C). *Epidemiol Infect* 101:43–51. <http://dx.doi.org/10.1017/S0950268800029204>.
- Mulder CJ, Zanen HC. 1984. A study of 280 cases of neonatal meningitis in The Netherlands. *J Infect* 9:177–184. [http://dx.doi.org/10.1016/S0163-4453\(84\)91351-3](http://dx.doi.org/10.1016/S0163-4453(84)91351-3).
- Jenkins EL, McGuire W. 2000. Group C streptococcal meningitis in infancy. *Acta Paediatr* 89:1141.
- Shulman ST, Bisno AL, Clegg HW, Gerber MA, Kaplan EL, Lee G, Martin JM, Van Beneden C. 2012. Clinical practice guideline for the

- diagnosis and management of group A streptococcal pharyngitis: 2012 update by the Infectious Diseases Society of America. *Clin Infect Dis* 55: 1279–1282. <http://dx.doi.org/10.1093/cid/cis847>.
17. American Academy of Pediatrics. 2012. Group A streptococcal infections, p 668–680. *In* Pickering LK, Baker CJ, Kimberlin DW, Long SS (ed), Red book: 2012 report of the Committee on Infectious Diseases. American Academy of Pediatrics, Elk Grove Village, IL.
 18. Walker JA, Timoney JF. 1998. Molecular basis of variation in protective SzP proteins of *Streptococcus zooepidemicus*. *Am J Vet Res* 59:1129–1133.
 19. Velineni S, Timoney JF. 2013. Characterization and protective immunogenicity of the SzM protein of *Streptococcus zooepidemicus* NC78 from a clonal outbreak of equine respiratory disease. *Clin Vaccine Immunol* 20: 1181–1188. <http://dx.doi.org/10.1128/CVI.00069-13>.