



2016

HISTOLOGICAL AND BEHAVIORAL CONSEQUENCES OF REPEATED MILD TRAUMATIC BRAIN INJURY IN MICE

Amanda Nicholle Bolton Hall

University of Kentucky, amanda.bolton22@gmail.com

Digital Object Identifier: <http://dx.doi.org/10.13023/ETD.2016.165>

[Right click to open a feedback form in a new tab to let us know how this document benefits you.](#)

Recommended Citation

Bolton Hall, Amanda Nicholle, "HISTOLOGICAL AND BEHAVIORAL CONSEQUENCES OF REPEATED MILD TRAUMATIC BRAIN INJURY IN MICE" (2016). *Theses and Dissertations--Physiology*. 26.

https://uknowledge.uky.edu/physiology_etds/26

This Doctoral Dissertation is brought to you for free and open access by the Physiology at UKnowledge. It has been accepted for inclusion in Theses and Dissertations--Physiology by an authorized administrator of UKnowledge. For more information, please contact UKnowledge@lsv.uky.edu.

STUDENT AGREEMENT:

I represent that my thesis or dissertation and abstract are my original work. Proper attribution has been given to all outside sources. I understand that I am solely responsible for obtaining any needed copyright permissions. I have obtained needed written permission statement(s) from the owner(s) of each third-party copyrighted matter to be included in my work, allowing electronic distribution (if such use is not permitted by the fair use doctrine) which will be submitted to UKnowledge as Additional File.

I hereby grant to The University of Kentucky and its agents the irrevocable, non-exclusive, and royalty-free license to archive and make accessible my work in whole or in part in all forms of media, now or hereafter known. I agree that the document mentioned above may be made available immediately for worldwide access unless an embargo applies.

I retain all other ownership rights to the copyright of my work. I also retain the right to use in future works (such as articles or books) all or part of my work. I understand that I am free to register the copyright to my work.

REVIEW, APPROVAL AND ACCEPTANCE

The document mentioned above has been reviewed and accepted by the student's advisor, on behalf of the advisory committee, and by the Director of Graduate Studies (DGS), on behalf of the program; we verify that this is the final, approved version of the student's thesis including all changes required by the advisory committee. The undersigned agree to abide by the statements above.

Amanda Nicholle Bolton Hall, Student

Dr. Kathryn E. Saatman, Major Professor

Dr. Bret N. Smith, Director of Graduate Studies

HISTOLOGICAL AND BEHAVIORAL CONSEQUENCES OF
REPEATED MILD TRAUMATIC BRAIN INJURY IN MICE

DISSERTATION

A dissertation submitted in partial fulfillment of the
requirements for the degree of Doctor of Philosophy in the
College of Medicine
at the University of Kentucky

By
Amanda Nicholle Bolton Hall

Lexington, Kentucky

Director: Dr. Kathryn E. Saatman, Professor of Physiology

Lexington, Kentucky

2016

Copyright © Amanda Nicholle Bolton Hall 2016

ABSTRACT OF DISSERTATION

HISTOLOGICAL AND BEHAVIORAL CONSEQUENCES OF REPEATED MILD TRAUMATIC BRAIN INJURY IN MICE

The majority of the estimated three million traumatic brain injuries that occur each year are classified as “mild” and do not require surgical intervention. However, debilitating symptoms such as difficulties focusing on tasks, anxiety, depression, and visual deficits can persist chronically after a mild traumatic brain injury (TBI) even if an individual appears “fine”. These symptoms have been observed to worsen or be prolonged when an individual has suffered multiple mild TBIs. To test the hypothesis that increasing the amount of time between head injuries can reduce the histopathological and behavioral consequences of repeated mild TBI, a mouse model of closed head injury (CHI) was developed. A pneumatically controlled device with a silicone tip was used to deliver a diffuse, midline impact directly onto the mouse skull. A 2.0mm intended depth of injury caused a brief period of apnea and increased righting reflex response with minimal astrogliosis and axonal injury bilaterally in the entorhinal cortex, optic tract, and cerebellum.

When five CHIs were repeated at 24h inter-injury intervals, astrogliosis was exacerbated acutely in the hippocampus and entorhinal cortex compared to a single mild TBI. Additionally, in the entorhinal cortex, hemorrhagic lesions developed along with increased neurodegeneration and microgliosis. Axonal injury was observed bilaterally in the white matter tracts of the cerebellum and brainstem. When the inter-injury interval was extended to 48h, the extent of inflammation and cell death was similar to that caused by a single CHI suggesting that, in our mouse model, extending the inter-injury interval from 24h to 48h reduced the acute effects of repeated head injuries.

The behavioral consequences of repeated CHI at 24h or 48h inter-injury intervals were evaluated in a ten week longitudinal study followed by histological analyses. Five CHI repeated at 24h inter-injury intervals produced motor and cognitive deficits that persisted throughout the ten week study period. Based upon histological analyses, the acute inflammation, axonal injury, and cell death observed acutely in the entorhinal cortex had resolved by ten weeks after injury. However, axonal degeneration and gliosis were present in the optic tract, optic nerve, and corticospinal tract. Extending the inter-injury interval to 48h did not significantly reduce motor and cognitive deficits, nor did it

protect against chronic microgliosis and neurodegeneration in the visual pathway. Together these data suggested that some white matter areas may be more susceptible to our model of repeated mild TBI causing persistent neuropathology and behavioral deficits which were not substantially reduced with a 48h inter-injury interval.

In many forms of TBI, microgliosis persists chronically and is believed to contribute to the cascade of neurodegeneration. To test the hypothesis that post-traumatic microgliosis contributes to mild TBI-related neuropathology, mice deficient in the growth factor progranulin ($Grn^{-/-}$) received repeated CHI and were compared to wildtype, C57BL/6 mice. Penetrating head injury was previously reported to amplify the acute microglial response in $Grn^{-/-}$ mice. In our studies, repeated CHI induced an increased microglial response in $Grn^{-/-}$ mice compared to C57BL/6 mice at 48h, 7d, and 7mo after injury. However, no differences were observed between $Grn^{-/-}$ and WT mice with respect to their behavioral responses or amount of axonal injury or ongoing neurodegeneration at 7 months despite the robust differences in microgliosis. Dietary administration of ibuprofen initiated after the first injury reduced microglial activation within the optic tract of WT mice 7d after repeated mild TBI. However, a two week ibuprofen treatment regimen failed to affect the extent of behavioral dysfunction over 7mo or decrease chronic neurodegeneration, axon loss, or microgliosis in brain-injured $Grn^{-/-}$ mice when compared to standard diet.

Together these studies underscore that mild TBIs, when repeated, can result in long lasting behavioral deficits accompanied by neurodegeneration within vulnerable brain regions. Our studies on the time interval between repeated head injuries suggest that a 48h inter-injury interval is within the window of mouse brain vulnerability to chronic motor and cognitive dysfunction and white matter injury. Data from our microglia modulation studies suggest that a chronically heightened microglial response following repeated mild TBI in progranulin deficient mice does not worsen chronic behavioral dysfunction or neurodegeneration. In addition, a two week ibuprofen treatment is not effective in reducing the microglial response, chronic behavioral dysfunction, or chronic neurodegeneration in progranulin deficient mice. Our data suggests that microglia are not a favorable target for the treatment of TBI.

KEYWORDS: Microglia, Neurodegeneration, Traumatic Brain Injury, Progranulin, Ibuprofen

Amanda Nicholle Bolton Hall
Student's Signature

April 20, 2016
Date

HISTOLOGICAL AND BEHAVIORAL CONSEQUENCES OF
REPEATED MILD TRAUMATIC BRAIN INJURY IN MICE

By

Amanda Nicholle Bolton Hall

Kathryn E. Saatman, Ph.D.

Director of Dissertation

Bret N. Smith, Ph.D.

Director of Graduate Studies

April 20, 2016

For my parents, whose never ending love and support
encouraged me to reach for the stars.

For my husband, whose love, strength, and laughter
helped me to get there.

ACKNOWLEDGEMENTS

I have been blessed to have had so many people in my life that have supported, guided, taught, strengthened, mentored, and motivated me to successful completion of my dissertation work. I am extremely grateful to Dr. Kathryn Saatman for her support and dedication as my mentor at the University of Kentucky. Over the past six years, I have become a successful scientist, mentor, and teacher because of her guidance and constant motivation which inspired me to be and do better. To my amazing committee members, whom I dubbed “Team Awesome” at our first meeting: Drs. Joe Springer, Peter Nelson, Bret Smith, and John Gensel. I thank you all for challenging me when I needed to be challenged, supporting me when I needed support, and making me laugh when what I needed most was laughter. To my outside examiner, Dr. Brian MacPherson, thank you for your time and commitment to the education of graduate students. To the entire Department of Physiology and the Spinal Cord and Brain Injury Research Center, thank you for all of the food and fun that you provided over the years, not to mention the countless resources that were provided to help me grow as a person and aid in conducting my research. Specifically, I would like to thank Mrs. Zelneva Madison, without whom I would have surely lost my head a long time ago. I am indebted to many former and current Saatman Lab members for their wealth of knowledge in the field of Neurotrauma and the technical training that they willingly provided. Specifically I would like to thank the following: Dr. Brantley Graham for her impeccable ability to serenade mice into breeding; Dr. Binoy Joseph for his love of optic nerves and willingness to always help when needed; Jen Brelsfoard, for her amazing mouse whispering skills in behavioral testing, morning coffee talks, and lunch-time runs (I promise we work hard!); and Erica

Littlejohn for all of the late nights in the lab, your willingness to talk through data with me, and for reminding me there is more to life than whether my data looks 'good'. To the Drs. Carolyn Meyer, Danielle Lyons, Paulina Davis, and Future Dr. Brittany Carpenter, thank you for your never-ending encouragement and friendship over the past six years and the many years to come. I would especially like to thank my parents, Jeff and Mary Bolton, my brother, Jarron, and my sister, Dacie. We may be physically separated by many miles, but your love has always been present. I must also thank my amazingly wonderful husband, Mike Hall, for his encouragement throughout this crazy journey. I am also so grateful for the love and support from the new additions to my family, my parents-in-law, Michael and Mary Jo Hall, and the rest of the Hall Family. I am incredibly blessed, and I know without a doubt that I would not be the person I am today without all of the amazing people in my life.

TABLE OF CONTENTS

ACKNOWLEDGEMENTS iii

List of Tables ix

List of Figures x

CHAPTER 1: Introduction 1

 Traumatic Brain Injury 1

 Etiology and Epidemiology 1

 Clinical Presentation 2

 Pathophysiology..... 4

 Primary Injury 6

 Secondary Injury Cascades 7

 Repeated Traumatic Brain Injury..... 11

 Experimental TBI Models..... 13

 Chronic Traumatic Encephalopathy 36

 Epidemiology of Neurodegenerative Diseases 36

 Traumatic Brain Injury is a Risk Factor for Neurodegenerative Diseases 37

 History and Epidemiology 37

 Clinical Presentation 38

 Histopathology 39

 Progranulin..... 42

 Structure 42

 Physiological Function..... 42

 Role in Pathological Conditions 45

 Progranulin Deficient Mouse Model 46

 Ibuprofen..... 49

 Biochemical Structure and Physiological Function 49

 Therapeutic Potential for TBI 50

 Summary 52

CHAPTER 2: Regional Neurodegeneration and Gliosis are Amplified by Mild Traumatic Brain Injury at 24h Intervals 54

 Preface..... 54

 Introduction..... 55

 Materials and Methods..... 57

 Animals: 57

Closed Head Injury:	58
Euthanasia and Tissue Processing:	63
Histology:.....	63
Immunohistochemistry:	64
Quantification of Histology/Immunohistochemistry:	65
Results.....	68
Impact Depth Characterization	68
Acute Physiological Responses Decrease with Repeated CHI.....	71
Mild TBI Repeated at 24h but not 48h Intervals Exacerbates Acute Neuron Death in the Entorhinal Cortex.....	74
Mild TBIs Produce Axonal Injury	76
Astrocytosis is Exacerbated by Repeated CHI at 24h but not 48h Intervals	80
Microglia are Activated by CHI Repeated at 24h but not 48h Intervals	85
Repeated CHI does not Induce Acute Tau Hyper-Phosphorylation	87
Discussion.....	88
Acknowledgements.....	96
CHAPTER 3: Repeated Closed Head Injury in Mice Results in Sustained Motor and Memory Deficits and Chronic Cellular Changes.....	97
Preface.....	97
Introduction.....	98
Materials and Methods.....	102
Animals	102
Repeated Closed Head Injury	102
Behavioral Analysis	104
Tissue Processing.....	106
Histopathological Analysis	106
Statistics	111
Results.....	112
Apnea and Righting Reflex.....	112
rCHI Induces Persistent Memory Dysfunction.....	114
rCHI Induces Deficits in Motor Coordination with Beam Walking but not Gait Analysis.....	116
Chronic Neurodegeneration after Mild TBI Irrespective of Inter-injury Interval	119
Persistent Inflammation after Mild TBI in Optic Tract and Pyramidal Tract but not Entorhinal Cortex and Hippocampus.....	124

Absence of Pathological Tau	132
Discussion	134
Motor Pathway Damage	134
Memory Circuit Damage	136
Visual System Damage	138
Conclusion	140
CHAPTER 4: Progranulin Deficiency Exacerbates Microgliosis but not Behavioral Dysfunction or Chronic Neurodegeneration after Repeated Mild Traumatic Brain Injury in Mice	141
Preface.....	141
Introduction.....	142
Materials and Methods.....	144
Animals.....	144
Experimental Design.....	145
Closed Head Injury	145
Behavioral Testing.....	147
Histopathology.....	150
Statistics	155
Results.....	156
Apnea and Righting Reflex.....	156
Microgliosis is Exacerbated Acutely in Progranulin-Deficient Mice after Repeated Mild TBI	160
Effects of Progranulin deficiency on Acute Axonal Injury after Repeated Mild TBI	169
Progranulin Deficiency did not Affect Recovery of Motor Function Chronically after Repeated Mild TBI.....	174
Cognitive Dysfunction Sustained Chronically after Repeated Mild TBI.....	176
Vision is not Grossly Impaired Chronically after Repeated Mild TBI.....	178
Age-Related Microgliosis in Grn ^{-/-} Mice is Amplified in the Optic Tract and Optic Nerve by Repeated Mild TBI.....	180
Progranulin Deficiency Does not Worsen Neurodegeneration after Repeated Mild TBI	185
Absence of Pathological Tau and pTDP43.....	189
Discussion.....	190
CHAPTER 5: Acute Ibuprofen Treatment following Repeated Mild Traumatic Brain Injury Does Not Reduce Chronic Neurodegeneration or Neurobehavioral Dysfunction	196

Preface.....	196
Introduction.....	197
Materials and Methods.....	200
Animals.....	200
Closed Head Injury.....	200
Experimental Design.....	201
Ibuprofen Treatment.....	202
Behavioral Testing.....	202
Histopathology.....	202
Statistics.....	203
Results.....	204
Apnea and Righting Reflex.....	204
Microgliosis is Attenuated by Ibuprofen in the Optic Tract 7d after Repeated Mild TBI.....	207
Effects of Ibuprofen Treatment on Acute Axonal Injury after Repeated Mild TBI.....	214
Ibuprofen did not Protect against Motor Dysfunction Following Repeated Mild TBI in Progranulin-deficient Mice.....	218
Ibuprofen did not Alter Cognitive Function Following Repeated Mild TBI in Progranulin-deficient Mice.....	220
Vision is Mildly Affected after Repeated Mild TBI.....	222
Acute Ibuprofen Treatment does not Attenuate Chronic Microgliosis in Grn ^{-/-} Mice after Repeated Mild TBI.....	224
Ibuprofen Reduces Axon Loss in Grn ^{-/-} Mice.....	228
Discussion.....	232
CHAPTER 6: Discussion and Conclusions.....	238
Review of Major Findings.....	238
Implications for Time Interval between Repeated Mild TBIs.....	240
Implications for Microgliosis after Repeated Mild TBIs.....	244
Discussion of Limitations and Alternative Approaches.....	245
Future Directions.....	249
APPENDIX 1: Permission for Article Reprint for Chapter 2.....	251
REFERENCES.....	253
VITA.....	273

List of Tables

Table 1.1: Experimental Models Evaluating only Single Mild TBI	19
Table 1.2: Experimental Models of Repeated versus Single Mild TBI	22
Table 1.2 Continued: Experimental Models of Repeated versus Single Mild TBI.....	23
Table 1.3: Experimental Models of Repeated Mild TBI Comparing Number of Injuries	26
Table 1.4: Experimental Models of Repeated Mild TBI Comparing Inter-Injury Intervals	29
Table 1.4 Continued: Experimental Models of Repeated Mild TBI Comparing Inter-Injury Intervals	30
Table 1.5: Experimental Models of Mild TBI in Juvenile Animals.....	33
Table 3.1: Antibody List	108
Table 3.2. Apnea and Righting Reflex	113
Table 3.3. Digigait Analysis.....	118
Table 4.1: Apnea mild TBI in Grn ^{-/-} and C57Bl/6 mice decreases with subsequent injuries.	158
Table 4.2: Righting Reflex in Grn ^{-/-} and C57Bl/6 mice decreases with subsequent injuries.	159
Table 5.1: Apnea following mild TBI in Grn ^{-/-} and C57Bl/6 decreases with subsequent injuries.	205
Table 5.2: Righting Reflex following mild in Grn ^{-/-} and C57Bl/6 mice decreases with subsequent injuries.	206

List of Figures

Figure 2.1: Repeated closed head injury (CHI) experimental design.....	61
Figure 2.2: Comparison of neuroinflammation after repeated anesthesia.	62
Figure 2.3: Acute physiological and histopathological consequences of single impact as a function of depth.	70
Figure 2.4: Righting reflex (A) and apnea (B) after sham injury, repeated closed head injury at 24h intervals (rCHI-24h), and repeated closed head injury at 48h intervals (rCHI-48h).	73
Figure 2.5: Neuronal degeneration in the entorhinal cortex after single and repeated closed head injury (CHI).....	75
Figure 2.6: Neuronal degeneration in the cerebellum and brainstem after a single and repeated closed head injury (CHI).	77
Figure 2.7: Axonal injury after repeated closed head injury (CHI).	79
Figure 2.8: Astrocytosis in the entorhinal cortex and hippocampus after sham and repeated closed head injuries (CHI).	82
Figure 2.9: Astrocytosis in the cerebellum and brainstem after repeated closed head injury (CHI).	84
Figure 2.10: Microgliosis after repeated closed head injuries (CHI).....	86
Figure 3.1: Repeated closed head injury (CHI) induced motor and memory deficits over ten weeks post-injury.	115
Figure 3.2: Hematoxylin and Eosin stain following repeated closed head injury (rCHI) or repeated sham injury (rSHAM).	120
Figure 3.3: Repeated closed head injury (CHI) induced chronic axonal degeneration in the pyramidal tract and cerebellar cruciform.	121
Figure 3.4: Repeated closed head injury (CHI) induced chronic axonal degeneration in the optic tract and optic nerve.	123
Figure 3.5: Inflammation did not persist in the entorhinal cortex or hippocampus ten weeks after repeated closed head injury (CHI).	125
Figure 3.6: Repeated closed head injury (CHI) caused chronic activation of microglia and reactive astrocytes in the cerebellum and brainstem.....	127
Figure 3.7: Repeated closed head injury (CHI) caused chronic microgliosis in the optic tract and optic nerve.	129
Figure 3.8: Acute microgliosis in the optic tract after single and repeated closed head injuries (CHI).	131
Figure 3.9: PHF-1 after repeated closed head injury (CHI) compared to positive control tissue.	133

Figure 4.1: Microgliosis was exacerbated in the optic nerve of Grn ^{-/-} mice 48h after repeated mild TBI.	162
Figure 4.2: Microgliosis was significantly increased in the optic tract and superior colliculus of Grn ^{-/-} mice 48h after repeated mild TBI.	163
Figure 4.3: Microgliosis was significantly increased in the entorhinal cortex 48h after repeated mild TBI.	164
Figure 4.4: Microgliosis was significantly increased in the optic nerves of Grn ^{-/-} mice 7d after repeated mild TBI.	166
Figure 4.5: Microgliosis was significantly increased in the optic tract and superior colliculus. 7d after repeated mild TBI	167
Figure 4.6: Microgliosis was not significantly increased in the entorhinal cortex, hippocampus, or thalamus 7d after repeated mild TBI.	168
Figure 4.7: Axonal swellings in the optic nerve were observed acutely following repeated mild TBI.	171
Figure 4.8: Acute neurodegeneration of visual pathway was observed 7d following repeated mild TBI.	172
Figure 4.9: Fluorograde C positive axonal injury in the optic tract and cell death in the entorhinal cortex following repeated mild TBI.	173
Figure 4.10: Transient motor deficits observed after repeated mild TBI are not worsened in Grn ^{-/-} mice.	175
Figure 4.11: Repeated mild TBI induces persistent cognitive dysfunction that is equivalent in C57BL/6 and Grn ^{-/-} mice.	177
Figure 4.12: Repeated mild TBI did not induce overt deficits in vision.	179
Figure 4.13: Repeated mild TBI in Grn ^{-/-} mice induced chronically elevated microgliosis in the optic nerve.	182
Figure 4.14: Repeated mild TBI in Grn ^{-/-} mice induced chronically elevated microgliosis in the optic tract.	183
Figure 4.15: Progranulin deficiency results in age-related microgliosis in entorhinal cortex, hippocampus, and thalamus that is not altered by repeated mild TBI.	184
Figure 4.16: Chronic neurodegeneration after repeated mild TBI is not worsened in Grn ^{-/-} mice.	187
Figure 4.17: Axon loss after repeated mild TBI is not affected by progranulin deficiency.	188
Figure 5.1: Ibuprofen did not reduce optic nerve microglial reactivity in C57BL/6 mice 48h after repeated mild TBI.	208
Figure 5.2: Ibuprofen did not significantly reduce microgliosis in optic tract or superior colliculus of C57BL/6 mice 48h after repeated mild TBI.	209
Figure 5.3: Microgliosis was not increased in the entorhinal cortex, hippocampus, or thalamus 48h after repeated mild TBI.	210

Figure 5.4: Ibuprofen treatment significantly attenuated microgliosis in the optic tract 7d after repeated mild TBI.	212
Figure 5.5: Microgliosis was not significantly increased by injury in the entorhinal cortex, hippocampus, or thalamus 7d after repeated mild TBI.	213
Figure 5.6: Ibuprofen treatment did not significantly reduce the amount of axonal injury following repeated mild TBI.	216
Figure 5.7: Acute silver stain labeling was increased in the optic tract and superior colliculus 7d after repeated mild TBI.	217
Figure 5.8: Transient motor deficits observed after repeated mild TBI are not affected by ibuprofen.	219
Figure 5.9: Repeated mild TBI induces persistent cognitive dysfunction that is not affected by ibuprofen.	221
Figure 5.10: Repeated mild TBI did not induce chronic deficits in vision.	223
Figure 5.11: Acute ibuprofen treatment following repeated mild TBI in Grn ^{-/-} mice did not alter chronic microglial reactivity in the optic nerve.	225
Figure 5.12: Acute ibuprofen treatment following repeated mild TBI in Grn ^{-/-} mice did not alter chronic microgliosis in the optic tract or superior colliculus.	226
Figure 5.13: Ibuprofen treatment in Grn ^{-/-} mice did not reduce age-related chronic microgliosis in entorhinal cortex, hippocampus, and thalamus.	227
Figure 5.14: Acute ibuprofen treatment did not reduce chronic neurodegeneration in the optic tract of Grn ^{-/-} mice after repeated mild TBI.	230
Figure 5.15: Acute ibuprofen treatment reduces the amount of axon loss in Grn ^{-/-} mice.	231

CHAPTER 1: Introduction

Traumatic Brain Injury

Etiology and Epidemiology

Traumatic brain injury (TBI) occurs after a direct or indirect insult to the head resulting in damage to the brain that interrupts normal brain function (CDC 2015). Based on estimates from emergency department visits in the United States from 2002 to 2010, the Center for Disease Control (CDC) reports falls as the leading cause of all reported TBIs. However, the percentage of TBIs that are due to falls varies among age groups. In patients under the age of 4 and over the age of 65 years, falls account for approximately 75% of TBIs, with the second leading cause of reported TBIs occurring when the individual is struck by or against an object. The incidence of TBIs due to falls and being struck by or against each account for approximately 35% of TBIs in youth, ages 5 to 14 years. In young adults (ages 15-24 years) and adults between the ages of 25-44 years, falls and being struck by or against an object account for a similar proportion of reported TBIs as motor vehicle accidents and assault. In adults aged 45-64 years, TBI incidence due to falls is increased in respect to young adults and adults aged 25-44yrs. (CDC 2015)

According to a 1996 report, approximately 57 million people living in the world at that time had been hospitalized with a TBI making TBI a global health problem (Murray and Lopez 1996). More recently, 5.3 million people in the United States alone are estimated to be living with a disability due to TBI (CDC 2015). Between 1.9 and 3.8 million TBIs are estimated to occur every year (Langlois, Rutland-Brown et al. 2006), resulting in upwards of 300,000 hospitalizations (CDC 2015) and \$60 billion in direct

healthcare costs (Finkelstein, Corso et al. 2006). Three to 6% of individuals who sustain a TBI require hospitalization due to bleeding in the brain requiring neurosurgical intervention. The vast majority of TBIs fall within the mild category of TBI (Kraus and Nourjah 1988) and do not require hospitalization. However, a classification of “mild” does not mean the injury is insignificant as long-term disabilities such as deficits in working memory can still occur (Alves, Macciocchi et al. 1993; McAllister, Sparling et al. 2001). Approximately 2% of the United States population is living with long-term or lifelong disabilities caused by TBIs making it one of the most disabling injuries (Thurman, Branche et al. 1998).

Clinical Presentation

After TBI one sign that brain function is altered is loss of consciousness (Menon, Schwab et al. 2010). Additionally, amnesia for events either immediately prior to or immediately following the injury, difficulties with motor control such as muscle weakness or balance, changes in vision or speech, confusion, disorientation, or problems with concentration are all clinical signs that brain function has been altered (Menon, Schwab et al. 2010).

Further medical evaluation is used to determine the extent of a patient’s TBI. The Glasgow Coma Scale (GCS) measures a patient’s eye, verbal, and motor responses to auditory and painful stimuli in order to measure consciousness. Scores range from 3 to 15, where 3 is deep unconsciousness and 15 is normal consciousness. In general, a patient with a GCS score of 3-8 falls under the categorization of severe TBI, while a GCS score of 9-12 is considered a moderate TBI, and a GCS score of 13-15 is classified as a mild TBI. The original GCS was published in 1974 by Graham Teasdale and Bryan Jennett of

the University of Glasgow (Teasdale and Jennett 1974). After its publication, the GCS was quickly adopted by hospitals around the world as its reproducibility and objective evaluation of neurological status after head injury was established (Jennett, Teasdale et al. 1976; Teasdale, Knill-Jones et al. 1978).

However, the GCS was not intended to stand alone in its assessment of unconsciousness nor was it intended by Teasdale and Jennett to be used to predict outcome (Teasdale, Knill-Jones et al. 1978). Supplemental evaluations have been developed over the years to measure unconsciousness and provide a tool for predicting outcome for TBI. The most recently validated assessment, full outline of unresponsiveness (FOUR), compliments the GCS in testing eye and motor reflexes, but also examines brainstem reflexes and respiration (McNett, Amato et al. 2014). FOUR is a more complicated evaluation than the GCS, making its incorporation into clinical settings a slow transition.

For individuals with mild TBI there are several other evaluations that have been specifically tailored to detect milder symptoms. The post-concussion symptom (PCS) scale has patients rate 15-30 physical, cognitive, emotional, and sleep-related symptoms on a scale of 0-7, where 0 represents no symptoms and 7 represents severe. For athletes suspected of a concussion during a game or practice, the standardized assessment of concussion (SAC) is used for sideline evaluation. The test examines the individual's ability to orient with time, their immediate and delayed memory recall, and ability to concentrate. Prior to the start of the season, athletes are tested with the SAC to determine a baseline score. Following any suspected head injuries, athletes are tested again. If their

score is below their baseline, the athlete should not be allowed to return to play until further evaluated and cleared.

Symptoms of TBI can last a lifetime or resolve quickly depending on the severity of the injury. For the majority of individuals with mild TBI, symptoms will resolve within a week after injury. However, studies have shown symptoms of mild TBI can last months (Rimel, Giordani et al. 1981) and up to a year after the injury (McMahon, Hricik et al. 2014). TBI also increases an individual's risk of additional health concerns such as binge-drinking (Horner, Ferguson et al. 2005), depression (Holsinger, Steffens et al. 2002), neurodegenerative diseases (Plassman, Havlik et al. 2000) and post-traumatic epilepsy (Agrawal, Timothy et al. 2006). The long-lasting effects of TBI in addition to TBI-associated health concerns place a burden on the patients' families leading to emotional and financial distress.

Pathophysiology

Each GCS category encompasses a large heterogeneity of potential pathological findings. For example, individuals A, B, and C could present at the hospital with the same GCS score, but that does not mean that individuals A, B, and C have similar pathology. TBIs are heterogeneous and can take the form of contusion, hemorrhage, diffuse axonal injury, and/or diffuse swelling. Different mechanisms of injury may require different neurosurgical interventions, and ultimately different therapeutic treatments. Computed-Tomography (CT) scans and/or Magnetic Resonance Imaging (MRI) are used to create a picture of the macroscopic pathology occurring in the brain after injury. CT scans use x-ray technology to quickly capture the contrast between bone and brain tissue. Skull fractures are easily identifiable, as are substantial hemorrhage and

edema in the brain tissue. However, the pathology observed with CT has been described as the ‘tip of the ice-berg’ in regards to the total amount of injury in the brain. MRI is a more sensitive imaging technique than CT and can evaluate more specific pathology such as arteriovenous malformation (Harmon, Drezner et al. 2013). In a study of 135 mild TBI patients, MRI detected positive findings in 27% of patients with negative CT findings (Yuh, Mukherjee et al. 2013) providing evidence of pathological consequences of mild TBI even in cases of a normal GCS score. The study further supports the need for more advanced neuroimaging techniques to be validated for the study of mild TBI cases.

As there are no therapeutics as of yet for the treatment of TBI, neuroimaging is currently used to assess whether neurosurgical intervention is required for cases such as skull fracture or subdural hematoma. Five percent of patients with a GCS of 15 and 30% of patients with a GCS of 13 are reported to present with positive CT and/or MRI findings (Borg, Holm et al. 2004). As a small percentage of mild TBIs have observable damage to the brain, three separate consensus forums on management of concussion have reported that CT and MRI should be used judiciously in order to prevent unnecessary radiation (Giza, Kutcher et al. 2013; Harmon, Drezner et al. 2013; McCrory, Meeuwisse et al. 2013). Additional criteria have been developed and validated in an effort to decrease the number of normal CT results following mild TBI (Bouida, Marghli et al. 2013). The Canadian CT Head Injury/Trauma Rule (CCHR) is one such guideline used to aid clinical decisions. For cases of mild TBI where the patient has a GCS score of less than 15 two hours after injury, is suspected of having an open or depressed skull fracture, has any sign of basal fracture (such as ‘raccoon’ eyes), has more than one vomiting episode, or is 65 years of age or older the CCHR suggests further evaluation of the head

injury with a CT scan (Stiell, Wells et al. 2001). These signs are high risk indicators of significant brain injury that may require neurosurgical intervention. Mild TBIs where structural damage is observed are often referred to as “complicated” mild TBI.

Primary Injury

The initial damage caused by direct impact to the head, rapid acceleration/deceleration, penetrating injury and/or blast injury is termed the primary injury. The mechanisms of primary injury often manifest as membrane damage causing axonal injury and blood brain barrier (BBB) breakdown. Diffuse axonal injury is one of the most common pathologies of closed head injuries often inducing coma (Smith, Nonaka et al. 2000; Povlishock and Katz 2005). Primary axotomy refers to the severing of the axon directly by the TBI resulting in distortion of the cytoskeleton (Povlishock and Christman 1995). In addition, micropores in the cell membrane occur allowing sodium and calcium to enter the cell resulting in a depolarization of the membrane potential (Pettus, Christman et al. 1994; Farkas and Povlishock 2007; Krishnamurthy and Laskowitz 2016).

The BBB refers to separation of the brain parenchyma from blood. Micro vessels made up of endothelial cells linked together by tight junctions form a physical barrier. These cells also allow the influx of nutrients and ions into the brain parenchyma and allow an efflux of toxins, and restrict the influx of large or highly charged molecules. The CNS is thereby able to regulate homeostasis and create an immunologically privileged environment. A TBI compromises the BBB by damaging endothelial cells, disrupting tight junctions, and allowing atypical transport of molecules (Campbell, Hanrahan et al.

2012). The result is disruption of normal neuronal function and the initiation of an additional secondary injury cascade that further damages the brain.

Secondary Injury Cascades

Secondary injury refers to the pathological events that occur in response to the primary injury. The main mechanism of secondary injury is excitotoxicity (Krishnamurthy and Laskowitz 2016). Excitotoxicity is due to a surplus of excitatory neurotransmitter signaling that initiates an overload of calcium inside the post-synaptic cell. Several excitatory neurotransmitters work within the CNS, but glutamate is believed to be the primary contributor to excitotoxicity. Depolarization of the pre-synaptic neuron opens calcium channels that signal the release of glutamate from the pre-synaptic cell. Extracellular glutamate has been shown to increase proportionally to the severity of injury (Faden, Demediuk et al. 1989; Palmer, Marion et al. 1994), as much as 50 fold compared to normal (Bullock 1995). As in normal physiological conditions, glutamate released from the pre-synaptic neuron into the synaptic cleft acts upon the ligand-gated ion receptors N-methyl-D-aspartate receptor (NMDAR) and α -amino-3-hydroxy-5-methyl-4-isoxazolepropionic acid receptor (AMPA) on the post-synaptic cell membrane to allow for an influx of sodium and calcium. However, in injury states, excess glutamate is released from the pre-synaptic cell, and glutamate transporters in neighboring astrocytes become dysfunctional. The consequence is activation of more AMPA and NMDA receptors, causing large amounts of sodium and calcium to enter the cell.

Increased intracellular calcium can lead to further neuronal damage and even death by several means, one of which is mitochondrial dysfunction (Boya, Gonzalez-Polo et al. 2003). Mitochondria have been described as “calcium sinks” as they will sequester

large amounts of calcium from the cytosol in an effort to maintain calcium homeostasis (Ichas and Mazat 1998). Under injury conditions where calcium is overloaded in the cell, the large quantities of calcium taken up by the mitochondria lead to increases in mitochondrial production of reactive oxygen species (ROS) (Sullivan, Thompson et al. 1999; Chen, Yang et al. 2007), loss of ATP production (Jacobus, Tiozzo et al. 1975; Vercesi, Reynafarje et al. 1978), and opening of the mitochondrial permeability transition pore (Bernardi 1996). The consequence of these events is the release of cytochrome c and other pro-apoptotic factors which trigger the formation of the caspase-3 cleaving apoptosome. Cleavage of caspase-3 induces apoptosis of the cell, resulting in cell death. Another feature of calcium overload after TBI is activation of cytoskeletal-cleaving calpains (Araujo, Carreira et al. 2010). Breakdown of filaments and microtubules can cause damage to the structural integrity of the neuron (Liu, Liu et al. 2008) and dysfunction of the transported networks within the neuron (Saatman, Abai et al. 2003). Immunohistochemical labeling of transport proteins after TBI, such as amyloid precursor protein (APP), have been used to identify damaged axons within hours (Roberts, Gentleman et al. 1991; Roberts, Gentleman et al. 1994). However, not all axons within a region appear damaged by the primary injury, likely due to the heterogeneity among axons in their size and myelination. In contrast, some dysfunctional axons can also appear normal depending on the marker used to detect injury (Tomei, Spagnoli et al. 1990). Calpains are also responsible for cleaving the mGluR1 receptor blocking the neuroprotective PI3K-AKT pathway (Liu, Liu et al. 2008). These events are spread via positive feedback, as the initial glutamate release in injured neurons induces further neurotransmitter release from the post-synaptic cell (Werner and Engelhard 2007).

Disruption of the BBB initiates additional secondary injury cascades by allowing an influx of thrombin, fibrinogen and albumin into the parenchyma initiating a coagulation cascade (Price, Wilson et al. 2016). Decreased cerebral blood flow causes ischemia at the site of impact. A lack of oxygen and nutrients in the impact area limits the production of ATP needed for cell function (del Zoppo and Mabuchi 2003; Schwarzmaier, Kim et al. 2010). Alongside coagulation factors, neutrophils and peripheral immune cells, such as macrophages, also infiltrate brain tissue (Chodobski, Zink et al. 2011). Because the brain is considered immunologically privileged, the infiltrating immune cells are believed to become active, secreting cytokines (Kumar and Loane 2012). Secretion of these cytokines then initiates the activation of microglia and astrocytes.

Microglia and astrocytes express pattern recognition receptors on their cell surface called Toll-like receptors (TLR) that allow them to recognize foreign or damaged cells (Gorina, Font-Nieves et al. 2011). Recognition by TLRs of trigger molecules induces the production and release of inflammatory chemokine and cytokines initiating the inflammatory cascade.

Under normal conditions, astrocytes play an important role in maintaining homeostasis of neurons by the uptake of glutamate from synapses (Chen and Swanson 2003). Under injury conditions in which excessive amounts of neurotransmitters are released into the synaptic cleft, astrocytes downregulate production of glutamate transporters (Beschoner, Simon et al. 2007). This down-regulation is believed to perpetuate the excessive amounts of glutamate in the synaptic cleft resulting in cell death. Astrocytes are also responsible for maintaining the integrity of the BBB (Risau and

Wolburg 1990). Following TBI, astrocytes secrete inflammatory molecules that modulate reactivity and suppression of astrocyte function (Gorina, Font-Nieves et al. 2011). Secretion of the cytokine IL-6 by astrocytes has been reported to increase the permeability of the BBB (Schwaninger, Sallmann et al. 1999), further damaging the already delicate BBB allowing for greater infiltration of peripheral cells (Jin, Liu et al. 2012). In addition, astrocytes increase expression of glial fibrillary acidic protein (GFAP) and vimentin, two intermediate filament proteins (Pekny, Eliasson et al. 1999) and increase self-proliferation in areas of injury (Bardehle, Kruger et al. 2013). Within a week following injury in rodent models, reactive astrocytes have been shown to form a glial scar which effectively surrounds the injured tissue separating it from nearby healthier tissue (Villapol, Byrnes et al. 2014). The glial scar is beneficial in stopping the influx of peripheral immune cells that contribute to a continued inflammatory response (Dardiotis, Hadjigeorgiou et al. 2008), but creates a barrier for the regeneration of damaged axons.

Microglia are the immune cells of the brain. Under normal conditions, microglia continuously interact with the neuro-environment, searching for signs of damage or infection. In this state they are considered “resting”. Following injury, microglia respond to the damage by expressing pro-inflammatory cytokines to increase microglial reactivity and phagocytose the debris. While the removal of debris is beneficial there is growing literature that microglia can remain activated long after injury and may contribute to continued neurodegeneration (Holmin and Mathiesen 1999; Block and Hong 2005; Chen, Johnson et al. 2009). Like astrocytes, microglia are heterogeneous. It is believed that activated microglia can be categorized into three different states: classically activated, alternatively activated, and acquired deactivation. Classically activated (also known as

stage M1) microglia are believed to release pro-inflammatory cytokines and reactive oxygen species that contribute to white matter injury and cell death (Karve, Taylor et al. 2016). Conversely, alternatively activated microglia (also known as stage M2b) are believed to be involved in wound healing and repair by producing scavenger receptors. Microglia in acquired deactivation states (also known as stage M2c) promote inflammation resolution (Cao, Thomas et al. 2012; Karve, Taylor et al. 2016). Several studies have reported a transient increase in M2 microglial responses following injury that is followed by a delayed increase in M1 microglia (Hu, Li et al. 2012; Jin, Liu et al. 2012; Wang, Zhang et al. 2013) suggesting the activated microglia observed chronically after injury are deleterious.

Repeated Traumatic Brain Injury

A history of TBI is associated with 2 to 5 times higher risk of sustaining another head injury (Guskiewicz, Marshall et al. 2007; Emery, Kang et al. 2011). Individuals involved in activities such as military training and athletics are at risk to sustain multiple head injuries (Guskiewicz, Weaver et al. 2000; Marar, McIlvain et al. 2012). However, the incidence of TBIs occurring during these activities is difficult to estimate for two primary reasons. The first reason is that a large proportion of head injuries go unreported (McCrea, Hammeke et al. 2004), and the second reason is that current data systems place TBIs occurring during sports or recreational activities under “falls” or “struck by/against” categories (CDC 2015).

It is widely presumed that if the brain is not allowed an adequate amount of time to recover, a subsequent head injury will result in more severe pathological and behavioral consequences. Multiple head injuries are associated with worsened and

prolonged behavioral symptoms. Individuals who have suffered more than one mild TBI are reported to perform worse on information processing tasks compared to individuals who sustained a single mild TBI (Gronwall and Wrightson 1975). A more severe consequence of multiple head injuries is observed in the rare case of second impact syndrome (SIS). SIS occurs when an individual receives a second head injury before symptoms from the first head injury have subsided resulting in an increase in intracranial pressure (McCrory and Berkovic 1998). The rapidity with which the pressure rises most commonly results in very severe morbidity or mortality. For a large portion of individual suffering from mild TBI, symptoms are reported to subside within a week (McCrea, Barr et al. 2005; McCrory, Johnston et al. 2005; Marar, McIlvain et al. 2012). However, there is increasing evidence that repeated head injuries are associated with worsened emotional, cognitive, and motor dysfunction over time and may induce the development of the neurodegenerative disease Chronic Traumatic Encephalopathy (CTE), as discussed later in this chapter. It is difficult to determine the amount of time required for recovery due to (1) lack of accurate patient histories in regards to head injuries, (2) the heterogeneity of head injuries, and (3) the lack of diagnostic imaging or biomarkers for milder, cellular responses to injury. Therefore, much work studying repeated head injuries has been performed using animal models of TBI.

Experimental TBI Models

Experimental Models of Moderate/Severe TBI

As described above, humans with moderate or severe TBI present with GCS scores between 3 and 12 caused by a variety of different types of injury that may cause similar or dramatically different symptomatology. Well established animal models of TBI include fluid percussion injury (FPI) (Dixon, Lyeth et al. 1987; McIntosh, Noble et al. 1987), controlled cortical impact (CCI) (Lighthall 1988), weight drop (WD) (Shapira, Shohami et al. 1988; Chen, Constantini et al. 1996), impact acceleration (IA) (Foda and Marmarou 1994; Marmarou, Foda et al. 1994) and blast injury (Cernak, Savic et al. 1996; Leung, VandeVord et al. 2008). Each model was created to ensure a precise and replicable injury in order to characterize the physiological, behavioral, and histopathological consequences of TBI. Models of midline FPI, IA, and blast injury were developed to create models of human diffuse axonal injury whereas CCI, WD, and lateral FPI were developed as models of contusion brain injury via penetration or hemorrhage, respectively. The observed behavioral consequences of TBI in animals include loss of consciousness, deficits in learning and memory, difficulties with motor coordination, anxiety, and depression. Histopathologically, animal models are able to replicate axonal injury and BBB disruption as well as secondary mechanisms of injury such as excitotoxicity, cell death, and inflammation. The cellular responses can involve many regions of the brain. With the use of animal models investigators have been able to more thoroughly study the time course of secondary injury mechanisms. This knowledge has been invaluable in evaluating therapeutic strategies to limit or reduce the injury caused by BBB breakdown, gliosis, axonal injury, and/or neuron death after TBI

Experimental Models of Mild TBI

Human mild TBI is designated as mild because it typically causes fewer and less severe behavioral consequences and induces minimal if any pathological findings with standard neuroimaging techniques. In experimental models, the definition of mild TBI has progressed over time and is more recently represented as minimal axonal injury, gliosis, and cell death in the brain that produce transient and/or mild behavioral deficits such as difficulties with memory or motor coordination. In order to produce these pathological and behavioral changes many of the above-mentioned models have been modified to reduce the severity of injury. Some laboratories have minimized the injury by decreasing the depth or speed of impact (Chen, Mao et al. 2014), the weight dropped (DeFord, Wilson et al. 2002; Fujita, Wei et al. 2012), or the blast or pulse pressure (Cao, Thomas et al. 2012). In many other laboratories the CCI model has been adapted by performing a closed-skull/head injury (CHI) instead of performing a craniotomy and directly impacting the dura. For laboratories using a CHI model, some continue to use the traditional metal impact tip whereas others have created tips made of silicone or rubber to reduce the incidence of skull fracture. Stereotaxic frames may be used to fix the head in order to create a more reproducible injury or animals may be placed on a foam pad or similar cushion as in the original IA model to allow for some movement as can occur in the human condition. Similar modifications to restrict or allow mobility have also been studied in models of blast injury. Impact acceleration models have been modified to produce mild TBI by placing mice onto aluminum foil or kim wipes so that a mild impact to the head will push the animal through the lining causing a rotational acceleration of the brain. Several tables are discussed throughout this section. In the column labeled “Injury

Model” is information regarding the species of animals used the type of mode (e.g. CHI), the location of injury (e.g. Midline), whether the head was fixed or unfixed, and information regarding the object used to impact the skull/brain.

Despite the numerous ways in which to induce a mild TBI in animal models, there are many major pathological and behavioral features in common as discussed below. Because the vast majority of human mild TBIs do not result in skull fracture or contusion, mild TBI models often have been developed to avoid substantial BBB disruption. BBB breakdown in more severe injury models can be observed by labeling IgG extravasation from the vasculature into the parenchyma (Saatman, Feeko et al. 2006), but is not typically found in models of mild TBI (Laurer, Bareyre et al. 2001). Blood pressure does not appear to change in response to mild TBI (Laurer, Bareyre et al. 2001; DeFord, Wilson et al. 2002) nor is there a decrease in the cerebrovascular response to the neurotransmitter, acetylcholine (Fujita, Wei et al. 2012). In addition, mild TBI models present with limited cell death leading to little change in traditional cellular stains such as Nissl or Hematoxylin and Eosin. Rather, Fluorojade (FJ) (Longhi, Saatman et al. 2005; Huh, Widing et al. 2008; Creed, DiLeonardi et al. 2011) or silver stain (Shitaka, Tran et al. 2011) have been used to detect and label sparsely distributed degenerating neurons. Other mild TBI studies have reported an absence of cell death (Meehan, Zhang et al. 2012; Weil, Gaier et al. 2014) which supports the notion that mild TBI does not induce overt cell death, but rather more subtle pathological problems.

Axonal injury is a major feature of mild TBI models and is commonly distributed in white matter tracts, particularly the subcortical white matter (Creed, DiLeonardi et al. 2011; Mouzon, Chaytow et al. 2012), but has also been observed in gray matter regions

such as the cortex or thalamus (Khuman, Meehan et al. 2011; Shitaka, Tran et al. 2011). Many studies utilize markers for amyloid precursor protein (APP) to evaluate axonal injury. APP is made in the cell body and transported down the axon to the axon terminal where it is believed to be involved in synaptic formation. Upon injury, microtubules along the axon can become disconnected which disrupts axonal transport of molecules, such as APP, to the axon terminal. APP accumulates at the sites of microtubule disruption where the axon swells, forming bulbs. APP positive bulbs have been shown to increase in size over time (Wilkinson, Bridges et al. 1999). However, following mild TBI, Creed and colleagues reported a transient wave of axonal injury such that large amounts of axonal injury were observed using APP immunohistochemistry one day after injury but progressively decreased across seven days. In contrast, FJ was observed from 24h out to 14d following injury, suggesting that APP accumulation is useful as a marker of early axonal injury, but that other markers are necessary to assess chronic axonal injury. However, mild APP accumulations have been reported as late as 12mo after injury in a CHI model (Mouzon, Bachmeier et al. 2014). A number of studies report negative findings with APP following a single mild TBI (Laurer, Bareyre et al. 2001; Shitaka, Tran et al. 2011; Meehan, Zhang et al. 2012). Shitaka and colleagues reported no APP accumulations in the subcortical white matter tract 24h, 72h, and 7d following CHI, but were able to detect some abnormalities with silver stain (Shitaka, Tran et al. 2011) suggesting that APP labeling and silver stain may detect axons in two different stages of injury.

Inflammation occurs in response to the consequences of axonal injury such as membrane damage, increases in reactive oxygen species, excitotoxicity, and the release

of other toxic byproducts from damaged cells. Astrocytosis is most commonly observed by labeling for glial fibrillary acidic protein (GFAP) which is upregulated following injury. Increases in GFAP labeling have been observed acutely following injury (Uryu, Laurer et al. 2002; Khuman, Meehan et al. 2011; Chen, Leung et al. 2012) and can progressively increase over the first two weeks (Mouzon, Chaytow et al. 2012) before resolving (Mouzon, Bachmeier et al. 2014). Microgliosis can also occur quickly after a mild TBI (Khuman, Meehan et al. 2011; Mouzon, Chaytow et al. 2012), but appears to remain at a constant level of activity (Mouzon, Chaytow et al. 2012) and is sustained long after injury (Mouzon, Bachmeier et al. 2014). Ionized calcium-binding adaptor molecule-1 (Iba-1) is expressed in all microglia. Upon activation, microglia cell bodies swell and the processes thicken. This morphological change increases the amount of Iba-1 expression in the tissue area and can be quantified. Other markers such as ED1 for rats and cluster of differentiation-68 (CD68) for mouse tissue can selectively detect activated microglia allowing for clearer differentiation of reactive microglia. However, as mentioned in the section above on secondary injury mechanisms, reactive astrocytes and microglia can be heterogeneously activated and different states may be responsible for the continued progression of axonal injury and subsequent cell death.

Several symptoms of mild TBI such as headache or nausea are not replicable in rodent models. However, problems with memory or learning, attention deficits, and difficulties with motor coordination can be examined in animal models of mild TBI. Motor dysfunction can be evaluated using a number of tests such as rotarod, beam walking, neurological severity score, and digigait. Using these various tasks, motor dysfunction has been observed acutely after injury (Chen, Leung et al. 2012; Petraglia,

Plog et al. 2014; Mychasiuk, Hehar et al. 2016) and appears to resolve within a week in several studies (Khuman, Meehan et al. 2011; Mouzon, Chaytow et al. 2012; Petraglia, Plog et al. 2014). Additional studies have evaluated motor dysfunction at 2mo or later and did not report any deficits (Uryu, Laurer et al. 2002; Mouzon, Bachmeier et al. 2014) further supporting the transient nature of motor dysfunction after mild TBI. Cognitive dysfunction can also be evaluated using a number of tasks, but the Morris Water Maze (MWM) and the novel object recognition task (NOR) are the most commonly reported. The MWM can test both learning and spatial memory capabilities whereas the NOR is a test of non-spatial memory. A significant deficit in cognition does not occur in all studies of mild TBI (Laurer, Bareyre et al. 2001; Uryu, Laurer et al. 2002; Shitaka, Tran et al. 2011; Chen, Leung et al. 2012), but when it does develop it can be long-lasting (Zohar, Rubovitch et al. 2011; Cheng, Craft et al. 2014; Mouzon, Bachmeier et al. 2014). It is difficult to ascertain why some models show deficits, but it may, in part, be due to modifications in the tasks from laboratory to laboratory. Tests which were developed to detect more stark deficits in models of moderate and severe TBI or even repeated mild TBI as discussed later, may mask more subtle cognitive deficits of a single mild TBI.

Table 1.1: Experimental Models Evaluating only Single Mild TBI

Ref	Injury Model		Axonal Injury	Cell Death	Inflammation	Behavioral Deficits
(Creed, DiLeonardi et al. 2011)	Mice	CHI Midline Fixed 5mm Metal	Transient wave of white matter injury (1d to 7d)	FJ: present 24h-14d in white matter and cortex	--	Memory: deficit at 3d not at 6d
(Zohar, Rubovitch et al. 2011)	Mice	WD Lateral Unfixed	--	--	--	Memory: deficit out to 90d
(Khuman, Meehan et al. 2011)	Mice	IA-kinwipe Midline Unfixed 53g metal	APP: cortex	None	GFAP and Iba-1: increased at 2-3d	Motor: transient Memory: deficit at 24h
(Chen, Leung et al. 2012)	Mice	PCI Midline Unfixed Dry ice CO ₂	--	--	GFAP: increased at 24h	Motor: gait deficit at 1h Memory: no deficit at 1h
(Fujita, Wei et al. 2012)	Rats	IA-foam Midline Unfixed Weight Helmet	APP minimal	--	--	--
(Mychasiuk, Hehar et al. 2015)	Rats	IA-foil Midline Unfixed 150g weight	--	--	--	Motor: deficit at 1mo Attention deficits Increased Impulsivity
(Mychasiuk, Hehar et al. 2016)	Rats IA Unfixed	Midline	--	--	No increase in GFAP mRNA expression	Motor: deficit at 24h Memory: deficit at 8d
		Lateral	--	--	GFAP mRNA expression increased	Motor: deficit at 24h Memory: deficit at 8d in males, not females

-- indicates that the pathology or behavioral dysfunction was not evaluated. CHI = closed head injury. WD = weight drop. IA = impact acceleration. PCI = projectile concussion injury. FJ = fluorojade. APP = amyloid precursor protein. GFAP = glial fibrillary acidic protein. Iba-1 = ionized calcium-binding adaptor molecule-1.

Experimental Models of Repeated Mild TBI

Individuals who suffer a head injury are at a higher risk of receiving subsequent head injuries. While the symptoms of a single mild head injury often resolve within a few days to a week after injury, multiple head injuries have been shown to cause worsened and prolonged symptoms. Similarly, studies of experimental repeated mild TBI demonstrated worsened cellular pathology and behavioral dysfunction as compared to a single mild TBI.

In models of a single mild TBI where no axonal injury or BBB disruption was observed, repeated mild TBIs within a short time frame are able to induce these pathologies (Laurer, Bareyre et al. 2001; Shitaka, Tran et al. 2011). Surprisingly, Mouzon and colleagues reported a decrease in corpus callosum axonal injury with repeated mild TBI compared to single injury (Mouzon, Chaytow et al. 2012). However, in a follow up study, axonal injury was observed 12mo after injury and was increased in the corpus callosum of animals which received repeated mild TBI compared to that in animals which received a single mild TBI (Mouzon, Bachmeier et al. 2014). In the same study, the thickness of the corpus callosum was also significantly decreased suggesting a loss of myelin and or axons in the region. Similar to changes with axonal injury, studies of repeated mild TBI have shown increased and/or prolonged astrocytosis and microgliosis in regions of injury compared to that in animals with a single injury (Uryu, Laurer et al. 2002; Shitaka, Tran et al. 2011; Mouzon, Chaytow et al. 2012; Aungst, Kabadi et al. 2014; Mouzon, Bachmeier et al. 2014). In a number of studies multiple mild TBIs were able to induce motor or memory dysfunction that was not observed with a single mild TBI (Shitaka, Tran et al. 2011; Cheng, Craft et al. 2014). In other studies,

motor or cognitive dysfunction was worsened or prolonged compared to a single mild TBI (Laurer, Bareyre et al. 2001; Aungst, Kabadi et al. 2014; Petraglia, Plog et al. 2014).

Table 1.2: Experimental Models of Repeated versus Single Mild TBI

Ref	Injury Model	# of Injuries	Inter-injury Interval	Axonal Injury	Cell Death	Inflammation	Behavioral Deficits
(Petraglia, Plog et al. 2014)	Mice CHI Lateral Unfixed 6mm rubber helmet	1	--	--	--	--	Motor: deficit at 1h, 4h, 24h, 72h, but resolved by 7d Memory: deficit acutely and at 1mo, but not 6mo Anxiety: 2wks
		42	6 at 2h/daily for 7d	--	--	--	Motor: greater deficit persisted out to 1mo Memory: greater deficit acutely, but 1mo deficit same as single Anxiety: 2wks, 1mo and 6mo
(Laurer, Bareyre et al. 2001)	Mice CHI Lateral 6mm Rubber	1	--	APP: none	Nissl: no overt damage	--	Motor: transient Memory: none at 1 or 8wks
		2	24h	APP: increased in white matter	Nissl: no overt cell loss	--	Motor: longer lasting than single Memory: none at 1 or 8wks
(Uryu, Laurer et al. 2002)	9mo Mice CHI Lateral Fixed 6mm Rubber	1	--	--	Nissl: no overt damage	GFAP: mild increase at 2d	Motor: none at 16wk Memory: none at 16wk
		3	24h	--	Increased cortical iron deposits at 16wks	GFAP increased out to 9wks; resolved by 16wk	Motor: none at 16wk Memory: none at 16wk
(Shitaka, Tran et al. 2011)	Mice CHI Lateral Fixed 9mm Rubber	1	--	APP: none at 7d SS: minimal white matter	Nissl: no overt damage	Iba-1: none at 7d	Memory: no deficit at 2-5d
		2	24h	APP and SS: cortex and white matter SS: hippocampus and thalamus	Nissl: No overt damage	Iba-1: increased at 7d	Memory: deficit at 2-5d

Table 1.2 Continued: Experimental Models of Repeated versus Single Mild TBI

Ref	Injury Model	# of Injuries	Inter-injury Interval	Axonal Injury	Cell Death	Inflammation	Behavioral Deficits
(Cheng, Craft et al. 2014)	Mice	1	--	--	--	--	Memory: no deficit at 1mo
	Frontal Fixed 56g Metal Ball	2	48h	--	--	GFAP and Iba-1: similar to sham at 12mo	Memory: Deficit at 1 month
(Nichols, Deshane et al. 2016)	Mice IA-foam	1	--	--	--	--	Memory: memory deficit at 3wks
	Unfixed WD Steel helmet	3	24h	--	--	--	Memory: learning deficit at 1, 2, and 3wks; memory deficit at 3wks
(Mouzon, Chaytow et al. 2012)	Mice CHI	1	--	APP: increased in white matter	Nissl: No overt damage at 1d, but cerebellar damage at 10d	GFAP: increased from 24h to 10d; Iba-1 increased at 24h and 10d	Motor: deficit out to 7d Memory: deficit at 7d
	Midline Fixed 5mm Metal	5	48h	APP: CC decreased from single, brainstem increased from single	Nissl: cerebellum not different from single 10d after injury	GFAP and Iba-1: increased compared to single at 10d	Motor: not different from single Memory: trend, but not different from single
(Mouzon, Bachmeier et al. 2014)	Mice CHI	1	--	APP: mild at 12mo	LFB/CV: 10% decrease in CC thickness	GFAP: similar to sham at 12mo; Iba-1 increased in white matter	Motor: none at 6mo Memory: learning deficit at 12 mo and 18mo; no spatial deficit
	Midline Fixed 5mm Metal	5	48h	APP: increased at 12mo	LFB/CV: 15% decrease in CC thickness compared to single	GFAP and Iba-1: increased in white matter; GFAP increased in hippocampus	Motor: none at 6mo Memory: learning deficit at 6mo and 18mo; spatial deficit at 6mo and 12mo

-- indicates that the pathology or behavioral dysfunction was not evaluated. CHI = closed head injury. WD = weight drop. IA = impact acceleration. APP = amyloid precursor protein. GFAP = glial fibrillary acidic protein. Iba-1 = ionized calcium-binding adaptor molecule-1. CC = corpus callosum. SS = silver stain. LFB/CV = luxol fast blue/cresyl violet.

Increasing Number of Injuries

As discussed in the section above, repeated mild TBIs can induce pathology and behavioral dysfunction not observed with a single mild TBI or exacerbate the effects. A small number of studies have examined how the number of repeated insults can alter pathological and/or behavioral outcomes (Table 1.3). Shultz and colleagues were able to show graded increases in cortical damage when comparing 1, 3, and 5 mild FPI at a 5d inter-injury interval in rats (Shultz, Bao et al. 2012). Increased cortical damage corresponded with persistent activation of microglia. Behavioral evaluation showed that three repeated mild FPI induced a deficit in memory that was prolonged compared to that after a single FPI. Five repeated mild FPI also induced anxiety. Meehan and colleagues reported memory deficits that were not significantly different from sham following 1 IA injury but appeared to be progressively worsened by increasing the number of injuries (Meehan, Zhang et al. 2012). However, behavioral dysfunction was not statistically compared between injury groups. Increasing the number of impacts from 1 to 3, 5, or 10 IA did not induce axonal injury, cell loss, or cell death 24h after the final injury in any group. In a study, of repeated FPI, rats were evaluated for motor and memory deficits prior to injury and following 1, 2 and 3 repeated injuries (DeRoss, Adams et al. 2002). No motor dysfunction was observed after any injury. However, the study reported a decrease in the number of trials needed to reach baseline scores in MWM following each injury, from an average of 14 trials after the first injury to 2 trials after the third injury. It is not clear whether the baseline was re-set following each injury, but the study suggests that familiarization with a task may enable the injured person or animal to perform better after injury than if they were unfamiliar with the task. Further evaluation of animals with

several weeks of pre-injury training would be informative in better understanding the results. Regardless, the study addresses a potential caveat to repeated evaluation of some behavioral testing on the same cohort of mice across time.

Table 1.3: Experimental Models of Repeated Mild TBI Comparing Number of Injuries

Ref	Injury Model	# of Injuries	Inter-injury Interval	Axonal Injury	Cell Death	Inflammation	Behavioral Deficits
(Shultz, Bao et al. 2012)	Rats FPI Lateral	1	--	--	Similar to sham with very little cortical damage	ED1: mild, not significant from sham at 24h or 8wks	Memory: deficit at 24h but not 8wks Anxiety: no deficit at 24h or 8wks
		3	5d	--	Most had moderate cortical damage	ED1: increased at 24h but not 8wks	Memory: deficit at 24h and 8wks Anxiety: no deficit at 24h or 8wks
		5		--	Larger percentage with cortical damage	ED1: increased at 24h and 8wks	Memory: deficit at 24h and 8wks Anxiety: deficit at 24h and 8wks
(Kane, Angoa-Perez et al. 2012)	Mice IA-foil Midline Unfixed 95g weight	1	--	--	--	GFAP: not reported ILβ4: None at 30d	--
		5	24h	--	--	GFAP: not reported ILβ4: None at 30d	Motor: none at 7d
		10	24h (with 48h break btwn 5 & 6)	--	--	GFAP: increased compared to sham ILβ4: none at 30d	Motor: none at 7d
(Meehan, Zhang et al. 2012)	Mice IA- kimwipe Midline Unfixed 53g metal	1	--	APP: none	H&E: no cell loss FJ: None TUNEL:None	--	Memory: no deficit at 24h
		3	24h	APP: none	H&E: no cell loss FJ: none TUNEL: none	--	Memory: deficit compared to sham at 24h
		5					
		10					
(DeRosas, Adams et al. 2002)	Rats FPI Lateral	1	--	--	--	--	Motor: none Memory: 14 trials needed to reach baseline
		2*	10d-14d	--	--	--	Motor: none Memory: 7 trials needed to reach baseline
		3*	10d-14d	--	--	--	Motor: none Memory: 2 trials needed to return to baseline

* indicates that the same mice were evaluated after 1, 2, and 3 injuries and were not different cohorts of mice as in other studies. -- indicates that the pathology or behavioral dysfunction was not evaluated. FPI = fluid percussion injury. IA = impact acceleration. H&E = hematoxylin and eosin. APP = amyloid precursor protein. GFAP = glial fibrillary acidic protein. ED-1 = rat homologue of cluster of differentiation 68. ILβ4 = isolectin B4.

Inter-Injury Interval

Due to the transient nature of many symptoms of mild TBI in humans, it has long been presumed that by allowing enough time between injuries, the consequences of repeated injuries can be reduced to that of a single mild TBI. We can begin to understand how the inter-injury interval influences the pathological and behavioral outcomes by examining the studies of repeated mild TBI that have been previously described. Repeated TBI at inter-injury intervals of 24h or less appear to increase axonal injury (Laurer, Bareyre et al. 2001; Shitaka, Tran et al. 2011) and worsen motor dysfunction (Laurer, Bareyre et al. 2001; Petraglia, Plog et al. 2014) compared to a single CHI. However, even TBI repeated at longer intervals such as 48h and 5d induces greater and/or longer lasting cognitive dysfunction compared to a single CHI (Aungst, Kabadi et al. 2014; Cheng, Craft et al. 2014).

TBI severity exists on a spectrum. Comparison of data across studies with varying inter-injury intervals is instructive. However, more informative are studies which compare differing inter-injury intervals within the study and are therefore using the same injury model in comparison. The shortest inter-injury interval study compared two IA injuries at 3h, 5h, or 10h and evaluated changes in axonal injury and vascular reactivity to acetylcholine (Fujita, Wei et al. 2012). The amount of axonal injury progressively decreased with longer inter-injury intervals, but even at 10h interval repeated IA exacerbated axonal injury compared to a single IA. Similarly, two IA at 3h intervals caused a decrease in vascular reactivity to acetylcholine, but vascular reactivity was closer to normal with a 5h inter-injury interval and back to sham levels with at 10h inter-

injury interval. Two separate studies report increased axonal injury with a 3d inter-injury interval. In one study a 20d interval reduced axonal injury down to sham level, but did not mitigate the inflammatory response (Weil, Gaier et al. 2014).

Only one study has evaluated motor dysfunction in relation to inter-injury interval. Longhi and colleagues reported worsened motor function acutely following TBI repeated at an interval of 3d, whereas motor function following repeated TBI at intervals of 5d and 7d was equivalent to that after a single injury (Longhi, Saatman et al. 2005). In relation to cognitive dysfunction, the shorter the inter-injury interval, the more persistent the deficits in memory appear to be. For example, mild TBIs at a 24h inter-injury interval were reported to induce a cognitive deficit persisting 1yr following injury, whereas cognitive dysfunction resolved by 1yr with an inter-injury interval of 1wk (Meehan, Zhang et al. 2012). A subsequent study by the same group extended these findings to show that lengthening the inter-injury interval to 2wk lead to normalization of cognitive function by 6mo (Mannix, Meehan et al. 2013), while a 1mo inter-injury interval resulted in no additional deficit by 1mo after the final injury (Meehan, Zhang et al. 2012). Using a slightly different model, Longhi and colleagues reported that an inter-injury interval of 3d or 5d, but not 7d induced memory deficits acutely after injury (Longhi, Saatman et al. 2005). Together these data further support the hypothesis that unfavorable outcomes following repeated head injuries can be lessened if the head injuries occur far enough apart. However, the influence of inter-injury intervals on histopathological outcomes is vastly understudied.

Table 1.4: Experimental Models of Repeated Mild TBI Comparing Inter-Injury Intervals

Ref	Injury Model	# of Injuries	Inter-injury Interval	Axonal Injury	Cell Death	Inflammation	Behavioral Deficits
(Longhi, Saatman et al. 2005)	Mice CHI Lateral Fixed 9mm silicone	1	--	APP: white matter	FJ: positive in ipsi cortex	--	Motor: transient Memory: none at 3d
		2	3d	APP: increased compared to single	FJ: not different from single	--	Motor: worse than single at 24h, similar at 3d and 7d Memory: deficit at 3d
			5d	--	--	--	Motor: same as single Memory: deficit at 3d
			1wk	--	--	--	Motor: same as single Memory: none at 3d
(Fujita, Wei et al. 2012)	Rats IA-foam Midline Unfixed Metal weight w/helmet	1	--	APP: minimal	--	--	--
		2	3h	APP: increased swellings in corticospinal tract at 4h compared to single	--	--	--
			5h	APP: decreased swellings from 3h cohort; increased from single	--	--	--
(Meehan, Zhang et al. 2012)	Mice IA- kimwipe Midline Unfixed 53g metal	5	24h	APP: none	H&E: no cell loss FJ: none TUNEL: none	--	Memory: deficit at 24h, 1mo and 1yr
			1wk				Memory: deficit at 24h and 1mo, resolved by 1yr
			1mo				Memory: deficit at 24h resolved by 1mo

Table 1.4 Continued: Experimental Models of Repeated Mild TBI Comparing Inter-Injury Intervals

Ref	Injury Model	# of Injuries	Inter-injury Interval	Axonal Injury	Cell Death	Inflammation	Behavioral Deficits	
(Mannix, Meehan et al. 2013)	Mice IA- kimwipe Midline Unfixed 53g metal	5	24h	--	--	Iba-1: none GFAP: increased in several regions at 6mo	Memory: deficit at 3d and 6mo	
			1wk	--	--	--	Memory: deficit at 6mo	
			2wk	--	--	--	Memory: None at 6mo	
			1mo	--	--	--	Memory: none at 6mo	
(Weil, Gaier et al. 2014)	Rats IA Lateral Unfixed 36g weight onto plastic plunger	1		--	FJ: none SS: similar to sham	Iba-1: increased from sham GFAP: similar to to sham	Learning deficit at ~1mo	
			2	3d	--	FJ: none SS: increased compared to sham and single	Iba-1 and GFAP: increased from sham	Memory and Learning deficit at ~1mo from first injury
				20d	--	FJ: none SS: similar to sham	Iba-1 and GFAP: increased from sham	Learning deficit at ~1mo from first injury

-- indicates that the pathology or behavioral dysfunction was not evaluated. CHI = closed head injury. IA = impact acceleration. APP = amyloid precursor protein. FJ = fluorojade. GFAP = glial fibrillary acidic protein. Iba-1 = ionized calcium-binding adaptor molecule-1. SS = silver stain.

Pediatric head injury

As reported earlier, a large number of head injuries occur in children and young adults. It is well understood that children's brains are not miniature adult brains but undergo age-related changes in hormone expression, myelination, and brain glucose metabolism. These differences have led to the development of juvenile animal models of repeated mild TBI. Raghupathi and colleagues induced mild TBI in post-natal day (PND) 11 or 17 rats and evaluated axonal injury, cortical thinning, and memory dysfunction (Raghupathi and Huh 2007). Three days following injury brains from both injured groups presented similarly with axonal injury to the white matter tracts, no lesion development or gross pathological changes. However, by 14d injured PND11 rats presented with enlarged ventricles, cortical thinning and increased astrogliosis that progressively worsened and led to memory dysfunction 4wks after injury. However, injured PND17 rats lacked cortical cell loss or memory dysfunction suggesting that the younger population is more susceptible to brain damage following head injury. A subsequent study provided evidence of learning and memory deficits in injured PND17 animals at more acute time points (Huh, Widing et al. 2007). Taken together, these two studies suggest that the deficit caused by the mild TBI is prolonged in PND11 rats versus that in PND17 rats.

When the impact was reduced to eliminate skull fractures, repeated head injuries in PND11 rats exacerbated axonal injury and astrogliosis compared to a single injury (Huh, Widing et al. 2007). Additionally, ventricular swelling and cortical thinning were observed earlier with repeated head injuries, but did not induce deficits in learning 2wks following the injury. However, the data discussed in the paragraph above would suggest that the injury may induce acute deficits in learning and memory, but that in juvenile rats

more modest head injuries do not accumulate to induce a more severe outcome to that of a single harder impact.

In slightly older rats (PND35), mild TBI can induce transient memory dysfunction that is prolonged with repeated injuries similar to that of studies evaluating young adult rodents (Prins, Alexander et al. 2013). In the same study, cerebral glucose metabolism decreased following mild TBI. If the injury was repeated while glucose metabolism was depressed (24h inter-injury interval), the depression of glucose was exacerbated and persisted for a longer amount of time. However, by waiting until glucose metabolism recovered before repeating the insult (5d inter-injury interval) the injury only depressed glucose metabolism to levels observed with a single injury. Memory dysfunction was not examined on the 5d inter-injury interval group, but the study suggests that normalization of cerebral glucose metabolism may be an indicator of decreased vulnerability to repeated impacts.

Table 1.5: Experimental Models of Mild TBI in Juvenile Animals

Ref	Injury Model	Animal Model	# of Injuries	Inter-injury Interval	Axonal Injury	Cell Death	Inflammation	Behavioral Deficits
(Huh, Widing et al. 2007)	CHI Lateral Fixed 5mm Silicone	Rat pups PND11	1	--	APP: white matter bulbs and swellings		Mild astrocytosis at 1d	Memory: no deficit at 2wk
			2	5-10 min	APP: white matter bulbs	White matter thinning and enlarged ventricles by 7d	GFAP increased	Memory: no deficit at 2wk
			3		APP: less white matter bulbs	White matter thinning and enlarged ventricles by 3d	GFAP further increased	--
(Raghupathi and Huh 2007)	CHI Lateral Fixed 5mm Silicone	Rat pups PND11 v PND17	1	--	APP: white matter	PND11 injured: ventricular swelling and cortical thinning at 14 and 28d	PND11 injured: increased astrocytosis	Memory: PND11 injured-deficit at 4wk
(Huh, Widing et al. 2008)	CHI Lateral Fixed 5mm Metal	Rat pups PND17	1	--	APP: white matter & thalamus	FJ: thalamus and cortex	GFAP: Increased cortex and hippocampus	Memory: deficit at 7d and 17d
(Friess, Ichord et al. 2009)	RA	Piglets PND 3-5	1	--	APP	--	--	Memory: none at 1d or 8d
(Prins, Hales et al. 2010)	IA-wood Lateral Unfixed 5mm metal	Rats PND35	1	--	APP: white matter		No increase at 1d	Memory: deficit at 2d
(Prins, Alexander et al. 2013)	IA-wood Lateral Unfixed 5mm metal	Rats PND35	1	--	--	--	--	Memory: deficit at 1d but resolved by 3d
			2	24h	--	--	--	Memory: deficit at 1d and 3d
				5d	--	--	--	--

-- indicates that the pathology or behavioral dysfunction was not evaluated. CHI = closed head injury. IA = impact acceleration. RA = rotational acceleration. APP = amyloid precursor protein. GFAP = glial fibrillary acidic protein. PND = post-natal day.

Neuroimaging of Mild Traumatic Brain Injury

The immediate clinical concern when a patient presents with a head injury is whether or not they need neurosurgical intervention to save their life, due to hemorrhage or a penetrating head injury. These pathological abnormalities are easily observed with standard CT or MRI techniques. However, CT and MRI are not specific enough to detect more subtle levels of injury that appear to occur with mild TBI. Pathological outcomes of mild TBI may not require immediate life-saving procedures, but the long-term consequences that can occur with mild TBI have motivated further evaluation of mild TBI with more specific neuroimaging techniques.

Small animal MRI machines allow for researchers to image brain tissue following injury and compare the imaging outcomes to traditional histopathology. An increasingly common technique is diffusion tensor imaging (DTI) which measures water diffusion as it relates to the integrity of the axon. Uninjured axon fibers restrict the flow of water to run in parallel with the fiber tracts, but under injury conditions where axons are damaged, the flow of water is altered. In a study of rotational acceleration, DTI was capable of detecting white matter changes in the amygdala that varied with the magnitude and duration of acceleration of the injury (Stemper, Shah et al. 2015). In animal models of repeated mild TBI, damage detected by DTI has been shown to correlate with the amount of silver stain in white matter tracts even in the absence of APP accumulation (Bennett, Mac Donald et al. 2012). Inflammation and protein aggregation may influence DTI measurements, but were not correlated in the study. However, because inflammation occurs quickly after injury and can persist chronically, being able to visualize

microgliosis and astrogliosis could further unfold the role of inflammation in chronic neurodegeneration.

Summary of Experimental Models of Mild TBI

In short, much of what we know about the pathological consequences of mild TBI is from studies of experimental mild TBI in small animals such as mice and rats. Mild TBI causes axonal injury more so than BBB disruption. Location of injury is predominantly in white matter regions, but has been observed in gray matter areas below the impact site in models involving impact. Concomitantly, transient astrogliosis, chronic microgliosis, transient motor dysfunction and deficits in learning and memory are also features of experimental mild TBI. Amplification of these pathologies can occur with repeated mild TBI, and may be reduced by extending the amount of time between injuries.

Chronic Traumatic Encephalopathy

Epidemiology of Neurodegenerative Diseases

A neurodegenerative disease (NDD) is a condition associated with the progressive loss of neurons or dysfunction of neurons through degenerative processes. NDDs manifest in a number of different ways symptomatically and pathologically but, in general, NDDs affect the individual's day to day life, ultimately leading to death as the disease progresses. There are a large number of types and subtypes of NDDs that are used to clinically diagnose an individual. The most well-known and most common type of NDD is Alzheimer's disease (AD) (Morris 1994). The first case of AD was described by Alois Alzheimer, a German psychiatrist in 1901. In 2010, nearly 5 million people over the age of 65 years were living with AD in the United States (Hebert, Weuve et al. 2013). While the percentage of the population with AD is not expected to rise dramatically, the number of people living with AD in the U.S. is estimated to almost triple by the year 2050 due to increases in our aged population.

The second most common type of NDD in adults over the age of 65 years is vascular dementia (VaD). Accounting for 15-20% of NDD, VaD is often preceded by cardiovascular problems in which blood supply to the brain is compromised such as after stroke (Duthie and Glatt 1988; Chapman, Williams et al. 2006). Frontotemporal Dementia (FTD) is another prevalent NDD. In adults between the ages of 45 to 64, the prevalence of FTD is 15-22 people per 100,000 (United States), making it the second most common type of NDD in people under the age of 65years, behind only AD.

Traumatic Brain Injury is a Risk Factor for Neurodegenerative Diseases

A TBI can cause rapid onset of many similar symptoms of neurodegenerative diseases depending on the severity and location of injury. TBI has also been reported as a risk factor for a number of NDDs including AD (Plassman, Havlik et al. 2000), FTD (Kalkonde, Jawaid et al. 2012; Deutsch, Mendez et al. 2015), and ALS (Riggs 1993; Chio, Benzi et al. 2005), suggesting that a TBI may weaken or over-tax the normal functioning system leading to cytotoxic accumulations of proteins and development of disease. However, because TBI is a risk factor for so many NDDs, it suggests that other factors must also be involved and that a TBI may accelerate the development of the disease. In animal models of AD, hallmark pathologies such as Amyloid Beta plaques and tau accumulation can be increased or induced with TBI (Ojo, Mouzon et al. 2013).

History and Epidemiology

Chronic Traumatic Encephalopathy (CTE) is a neurodegenerative disease associated specifically with repeated TBI. CTE was first diagnosed in boxers by Harrison Martland in the 1920s (Martland 1928). Martland termed the diagnosis “punch drunk” as the symptomatology observed was similar to that of an intoxicated person: slurred speech and gait abnormalities. For approximately 75 years after the initial diagnosis by Martland, the disease was primarily associated with boxing. In 1990 an estimated 17% of boxers were reported to develop CTE (Roberts, Whitwell et al. 1990). In 2005, the first report of CTE in a National Football League (NFL) player was published by Bennett Omalu, et al. (Omalu, DeKosky et al. 2005). Since 2005, CTE has been observed in additional NFL players (Omalu, DeKosky et al. 2006; McKee, Daneshvar et al. 2014), athletes from other sports (Geddes, Vowles et al. 1999; McKee, Daneshvar et al. 2014), and military

personnel with a history of repeated head injuries (Goldstein, Fisher et al. 2012; McKee and Robinson 2014).

As referenced previously, the majority of individuals with mild TBIs recover quickly. In these cases individuals often return to normal activities shortly after injury. Individuals involved in high risk activities, such as athletics, are more likely to receive additional head injuries. Yet, not everyone with repeated head injuries has CTE, suggesting that other factors may be at play in the disease. Additionally, the severity, number, or time between injuries necessary to induce CTE is unknown.

Clinical Presentation

Clinically, symptoms of CTE present years after the traumatic insult (Gavett, Stern et al. 2011; Stern, Daneshvar et al. 2013; McKee, Daneshvar et al. 2014) and can be diverse. A 1950s study of 69 boxers with CTE described the common features of CTE as slowness of thought and speech, memory problems, dementia, tremor, and the motor-speech disorder dysarthria (Critchley 1957). More recently, the core clinical features of CTE have been described as difficulties in cognition, emotional or physical violence, and changes in mood such as depression or feeling overly sad (Montenigro, Baugh et al. 2014). Clinical features further supporting a diagnosis of CTE are described as impulsivity, anxiety, apathy, paranoia, suicidality, headache, motor deficits, and progressive decline of normal function and delayed onset of symptoms from the traumatic event (Montenigro, Baugh et al. 2014).

Histopathology

In 1973, Corsellis and colleagues published a detailed description of CTE in 15 retired boxers. They noted cerebral atrophy, enlarged lateral and third ventricles and a thinned corpus callosum, cavum septum pellucidum with fenestrations and cerebellar scarring (Corsellis, Bruton et al. 1973). Microscopically, neuronal loss was observed in several regions including the cerebrum and cerebellum, in addition to beta-amyloid plaque deposition in a majority of the cases (Corsellis, Bruton et al. 1973; Tokuda, Ikeda et al. 1991). More recent pathological descriptions include that of Corsellis et al., but note that gross anatomical changes are not typically present in mild cases of CTE, thereby citing the severity of atrophy as an indicator of the disease progression (McKee, Stein et al. 2015).

Like other neurodegenerative diseases, CTE is a progressive disease. Thus pathological stages of the disease have been characterized by examination of the localization and spread of aggregated proteins. In the first stage of CTE development, microscopic evidence of hyper-phosphorylated tau aggregations in neurons are found primarily deep within the sulci (Stern, Daneshvar et al. 2013; McKee, Stein et al. 2015). Tau is a microtubule associated protein present within the axon of neurons that stabilizes microtubules in order to form networks for axonal transport. In disease states tau becomes hyper-phosphorylated reducing binding-affinity for microtubules and promoting aggregation within the neuron. In the second stage tau pathology spreads from the focal sulci areas to the superficial cortical layers. By stage three, the phospho-tau pathology is widespread through the cortices and includes the hippocampus, entorhinal cortex, and amygdala. In the final stage, stage four, phospho-tau pathology is severe and widespread.

In addition to phosphorylated-tau depositions, accumulations of the transactive response DNA binding protein-43kDa (TDP43) have also been observed in the majority of cases of CTE (McKee, Stein et al. 2015). TDP43 is an RNA binding protein that regulates the splicing of transcripts (Buratti and Baralle 2001; Mercado, Ayala et al. 2005) and mRNA turnover (Strong, Volkening et al. 2007; Ayala, Misteli et al. 2008; Godena, Romano et al. 2011). Similar to tau, in disease states TDP43 becomes dysfunctional and its phosphorylated form aggregates in the cytosol. TDP43 has been observed in all stages of CTE, but is most closely associated with stage four of the disease (McKee, Stein et al. 2015). TDP43 pathology has been shown to co-localize partially with phospho-tau and can also present in glia and neurites (McKee, Gavett et al. 2010). As with other neurodegenerative diseases, neuroinflammation also occurs alongside CTE neuropathology (Soares, Hicks et al. 1995), but work has primarily focused on the role that tau and TDP43 play in the disease.

As discussed above, animal models of TBI have shown behavioral and histopathological changes after even mild injuries. However, phospho-tau pathology has only been reported in a small number of brain injury studies in wildtype mice (Goldstein, Fisher et al. 2012; Luo, Nguyen et al. 2014). The limited support for TBI-induced tauopathy from animal models advocates the use of genetically modified mice in experimental design. For example, in transgenic mice expressing the human form of tau, repeated mild TBI increases tau pathology in the cortex and hippocampus (Ojo, Mouzon et al. 2013).

While there is much overlap between the symptoms and pathological markers of CTE and other neurodegenerative diseases, CTE is a distinct neurodegenerative disease.

Currently, CTE can only be definitively diagnosed post-mortem, but work continues to further distinguish CTE through the use of imaging and biomarkers (Zhang, Puvenna et al. 2016). This can be complicated in cases of co-morbidity in which an individual has CTE and an additional neurodegenerative disease. Comorbidity has been reported to occur in almost 40% of CTE cases (Kiernan, Montenigro et al. 2015). The co-occurrence of other NDDs with CTE suggests similar pathophysiological mechanisms may occur between diseases. Additionally, similar therapeutic strategies may be able to lessen the progression of the diseases or even abolish the behavioral consequences of the diseases.

Progranulin

Structure

Progranulin is a secreted growth factor (Bateman, Belcourt et al. 1990) that was discovered independently by several labs in the early 1990s and named epithelial transforming growth factor (Parnell, Wunderlich et al. 1992), acrogranin (Baba, Hoff et al. 1993), PC-cell-derived growth factor (Zhou, Gao et al. 1993), and granulin-epithelin precursor protein (Bhandari, Daniel et al. 1996). For simplicity, the name progranulin will be used throughout the remainder of this chapter and in following chapters when referring to the full-length protein.

Progranulin is a biologically active precursor-protein containing 7.5 cysteine-rich granulin repeats (Bhandari, Palfree et al. 1992). Cleavage of progranulin by serine proteases can generate seven granulin peptides, three of which have been shown to be biologically active (Tolkatchev, Malik et al. 2008). The granulin sequence results in unique beta-hairpin folds that are held in parallel via disulfide bridges (Hrabal, Chen et al. 1996). Homologues to progranulin have also been discovered in plants (Chen, Huang et al. 2006), slime mold (Eichinger, Pachebat et al. 2005), and fish (Cadieux, Chitramuthu et al. 2005) in addition to mammals, suggesting that it evolved about 1.5 billion years ago and has been evolutionarily conserved (Bateman and Bennett 2009).

Physiological Function

Progranulin expression has been observed in epithelia, fibroblasts, endothelia, neurons, and microglia. In epithelia, fibroblasts, and endothelia, progranulin acts as a somatic growth factor signaling the extracellular regulated kinase and

phosphatidylinositol 3-kinase pathways (Lu and Serrero 2001; He, Ismail et al. 2002) that stimulate proliferation and survival of cells. The phosphorylation of focal adhesion kinase which signals the clustering of integrins is also promoted by progranulin to initiate cell motility. In a mouse model of injury to the skin, progranulin expression was shown to increase and was associated with an increase in proliferation and migration of epithelial cells (He and Bateman 2003). Using an *in vitro* model of injury, increased progranulin expression also promoted angiogenesis in an effort to repair the wound (He and Bateman 2003). The cleaved granulin peptides are reported to have several progranulin-related functions. For example, two granulin peptides are thought to mediate epithelia and tumor cell proliferation via a yin-yang effect (Plowman, Green et al. 1992; Tolkatchev, Malik et al. 2008). One granulin peptide induces proliferation while the other acts to diminish proliferation.

In the central nervous system, neurons and microglia also express progranulin. During development progranulin has been shown to regulate male sex differentiation of the mouse brain (Suzuki, Yoshida et al. 1998; Suzuki, Bannai et al. 2000). In the adult brain, progranulin is heavily involved in neuro-inflammation. A substantial upregulation in progranulin expression has been observed in activated microglia in several conditions including a mouse model of axotomy (Moisse, Volkening et al. 2009), mouse models of Alzheimer's disease (Pereson, Wils et al. 2009), and in both humans with Amyotrophic Lateral Sclerosis (ALS) and ALS mouse models (Malaspina, Kaushik et al. 2001; Lobsiger, Boillee et al. 2007; Irwin, Lipka et al. 2009). Full length progranulin is believed to protect against over-inflammation by binding and blocking the receptor for tumor necrosis factor-alpha (TNF- α) (Tang, Lu et al. 2011), thereby reducing

downstream signal transduction such as downregulation of the anti-inflammatory molecule interleukin-10 (Zhu, Stevenson et al. 2002). Conflicting reports suggested that progranulin did not mediate inflammation in this way (Chen, Chang et al. 2013; Etemadi, Webb et al. 2013), but in a review titled “New discovery rarely runs smooth: an update on progranulin/TNFR interactions”, Wang and colleagues succinctly sum the numerous studies in support of the progranulin/TNFR relationship and provide probable causes for previously conflicting reports (Wang, Liu et al. 2015). Progranulin has also been reported to facilitate the interaction of CpG oligonucleotide with Toll-Like Receptor-9 signaling the production of pro-inflammatory TNF- α and IL-6 (Park, Buti et al. 2011), but increased inflammation in progranulin deficient mice suggests that this is not progranulin’s only function (Ahmed, Sheng et al. 2010; Yin, Dumont et al. 2010). Cleaved granulins have also been implicated as pro-inflammatory molecules as they increase secretion of interleukin-8, a pro-inflammatory cytokine (Zhu, Stevenson et al. 2002). In neurons, progranulin has been shown to promote motor neuron cell survival and mediate neurite growth (Van Damme, Van Hoecke et al. 2008; Ryan, Baranowski et al. 2009; Gao, Joselin et al. 2010). However, the mechanism by which progranulin elicits these effects on neurons is understudied in comparison to microglia and other inflammatory mediator cells.

Role in Pathological Conditions

“Why then can one desire too much of a good thing?”

As You Like It, Act 4, Scene 1, Line 124

William Shakespeare

Much of what is known about progranulin is due to studies examining the consequences of its overexpression or deficiency as both increased and depressed levels of progranulin are pathological. Overexpression of progranulin has been implicated in several forms of cancer. As previously mentioned, progranulin is important to initiate mechanisms for wound repair such as proliferation and motility of immune cells, and angiogenesis. In cancerous states, these same mechanisms are overactive, increasing proliferation of tumor cells (He and Bateman 1999; Lu and Serrero 2001) and decreasing apoptosis (He, Ismail et al. 2002). Conversely, tumor formation has been reduced by mitigating the expression of progranulin mRNA in breast cancer (Lu and Serrero 2001), liver cancer (Cheung, Wong et al. 2004) and esophageal cancer (Chen, Li et al. 2008). This data has led to much work studying progranulin blocking agents as promising cancer therapeutics. However, it is necessary to tightly regulate the progranulin expression so as not to cause an insufficiency in progranulin.

The most well-known pathological condition due to insufficient progranulin is the development of the neurodegenerative disease frontotemporal lobar degeneration (FTLD). FTLD refers to neuronal loss, primarily in the frontal and temporal lobes of the brain, causing changes in personality and inappropriate language use. Genome-Wide Association Studies (GWAS) have implicated loss of function mutations in three genes in the development of FTLD, one of which is progranulin. As of 2013, 69 pathological

mutations causing an autosomal dominant haploinsufficiency in progranulin have been connected to the generation of the disease. FTLD due to progranulin mutations was called FTD with ubiquitin inclusions (FTD-U) until 2006 when the ubiquitinated protein was found to be TDP43 (Arai, Hasegawa et al. 2006; Neumann, Sampathu et al. 2006). Progranulin insufficiency also induces inflammation, loss of myelin in white matter, and dystrophic neurites. A complete loss of progranulin due to autosomal recessive progranulin mutations causes neuronal ceroid lipofuscinosis-11 (CLN11). CLN11 causes early onset vision loss due to retinal dystrophy, seizures, and cerebellar ataxia and atrophy (Smith, Damiano et al. 2012).

Progranulin Deficient Mouse Model

The mouse homolog to GRN (Grn) is located on chromosome 11 (Bhandari, Giaid et al. 1993) and its amino acid sequence is 75% identical to the human GRN gene (Bhandari, Palfree et al. 1992). Several transgenic mouse models for progranulin deficiency (Grn^{-/-}) have been independently generated (Kayasuga, Chiba et al. 2007; Yin, Dumont et al. 2010; Kao, Eisenhut et al. 2011; Petkau, Neal et al. 2012; Wils, Kleinberger et al. 2012) Each of these lines results in a complete knockout of progranulin and consequentially the granulin peptides. Using these mice, the behavioral and pathological consequences of progranulin deficiency have been further characterized.

Several of the Grn^{-/-} lines exhibit similar deficits in social interactions such that they are passive and disinterested in intruder mice (Yin, Dumont et al. 2010; Ghoshal, Dearborn et al. 2012; Petkau, Neal et al. 2012). An increase in biting attacks has been observed in one of the Grn^{-/-} mouse lines, suggesting increased aggression (Kayasuga, Chiba et al. 2007). Subtle impairments in spatial memory were observed using the

Morris Water Maze, primarily in $\text{Grn}^{-/-}$ mice aged 15mo or older (Yin, Dumont et al. 2010; Ghoshal, Dearborn et al. 2012; Wils, Kleinberger et al. 2012). Slower swim speeds have been reported in $\text{Grn}^{-/-}$ mice (Ghoshal, Dearborn et al. 2012; Wils, Kleinberger et al. 2012), but no deficits in motor function were observed using the rotarod task (Yin, Dumont et al. 2010).

While varying degrees of behavioral impairments were reported among the $\text{Grn}^{-/-}$ mouse lines, the pathological consequences were more consistent. All lines show increased microgliosis and astrogliosis with age compared to age-matched C57BL/6 mice in several brain regions including the cortex, hippocampus, thalamus, and brainstem (Ahmed, Sheng et al. 2010; Yin, Banerjee et al. 2010; Wils, Kleinberger et al. 2012).

$\text{Grn}^{-/-}$ mice aged 23mo show signs of focal neuronal loss in the CA2-3 (Ahmed, Sheng et al. 2010) and $\text{Grn}^{-/-}$ mice aged 10-12 months have reduced hippocampal synaptic transmission (Petkau, Neal et al. 2012). More prominent in most $\text{Grn}^{-/-}$ lines was the accumulation of ubiquitinated proteins (Ahmed, Sheng et al. 2010; Yin, Banerjee et al. 2010; Yin, Dumont et al. 2010; Ghoshal, Dearborn et al. 2012; Petkau, Neal et al. 2012; Wils, Kleinberger et al. 2012), occurring as early as 7months of age (Ahmed, Sheng et al. 2010; Wils, Kleinberger et al. 2012). In humans with progranulin-related FTL, the ubiquitinated protein was discovered to be phosphorylated TDP43. One $\text{Grn}^{-/-}$ mouse line has shown age-related cytoplasmic pTDP43 immunoreactivity in the hippocampus and thalamus (Yin, Banerjee et al. 2010; Yin, Dumont et al. 2010), and another has reported increased insoluble fragments of pTDP43 using western blot analysis (Wils, Kleinberger et al. 2012). However, several other lines have reported negative findings of increased cytoplasmic and/or aggregates of TDP43 (Ahmed, Sheng

et al. 2010; Ghoshal, Dearborn et al. 2012; Petkau, Neal et al. 2012; Wils, Kleinberger et al. 2012) or pTDP43 (Ahmed, Sheng et al. 2010; Ghoshal, Dearborn et al. 2012; Petkau, Neal et al. 2012). The lack of TDP43 pathology in $Grn^{-/-}$ mice raises the possibility that TDP43 pathology is a late stage phenomenon. The positive findings of ubiquitin accumulations in addition to increased lipofuscin accumulation (Ahmed, Sheng et al. 2010; Petkau, Neal et al. 2012; Wils, Kleinberger et al. 2012) support progranulin's role in ubiquitin-proteasomal and lysosomal degradation.

$Grn^{-/-}$ mice have been an invaluable tool for the study of progranulin and its role in cancer and neurodegeneration. While progranulin deficiency alone is enough to induce inflammation and some neuronal loss, as described in the $Grn^{-/-}$ mice above, trauma in $Grn^{-/-}$ mice has been shown to exacerbate these pathological consequences. In a model of a brain-stab wound, microgliosis and the amount of Fluorojade B positive cells were increased compared to that in injured C57BL/6 mice (Tanaka, Matsuwaki et al. 2013a; Tanaka, Matsuwaki et al. 2013b) . Similar results were also found after injection of the neurotoxin 1-methyl-4-(2'-methylphenyl)-1,2,3,6-tetrahydropyridine (MPTP) (Martens, Zhang et al. 2012), further supporting the need for adequate amounts of progranulin in order to regulate the inflammatory response and protect against cell death after injury.

Ibuprofen

Biochemical Structure and Physiological Function

Ibuprofen is a non-steroidal anti-inflammatory drug (NSAID) that was first developed in 1960s as a treatment for rheumatism (Adams, Cliffe et al. 1967). Ibuprofen's chemical name is (\pm) -(*R,S*)-2-(4-isobutylphenyl)-propionic acid. Biochemically, the *S*-(+) enantiomer of ibuprofen has been proven to be 160 times more biologically active than that of the *R*-(-) enantiomer (Adams, Bresloff et al. 1976) and is responsible for its therapeutic potential (Boneberg, 1996). Ibuprofen is effective in abolishing pain and fever, reducing inflammation in joints and soft tissue, and inhibiting the migration of leukocytes into the injury site (Adams, McCullough et al. 1969; Bertelli and Soldani 1979; Romer 1980; Goldlust and Rich 1981). Ibuprofen can be administered orally, and its effects are most commonly observed within an hour and peak around three hours after administration (Davies 1998)

To induce these effects, ibuprofen non-selectively inhibits cyclooxygenase (COX-1 and COX-2) (Kaufmann, Andreasson et al. 1997). COX-1 is responsible for maintaining a normal level of prostaglandins by converting arachidonic acid into the inflammatory prostaglandins (Sales and Jabbour 2003). Upon injury, COX-2 becomes upregulated which causes an increase in prostaglandin production (Girgis, Palmier et al. 2013). Through inhibition of COX-1 and COX-2, ibuprofen can decrease prostaglandin production (Moncada and Vane 1979) and thereby reduce the inflammatory response.

Therapeutic Potential for TBI

Ibuprofen is capable of crossing the BBB where it similarly reduces the brain's inflammatory response to injury or disease. Inflammation has been observed concomitantly with aggregated proteins in neurodegenerative diseases such as Alzheimer's disease and Parkinson's disease. In the 1990s, several reports indicated that individuals who reported regular use of non-steroidal anti-inflammatory drugs (NSAIDs) had a lower risk of developing AD (Andersen, Launer et al. 1995; Stewart, Kawas et al. 1997; Anthony, Breitner et al. 2000). Ibuprofen was the most frequently used NSAID (Stewart, Kawas et al. 1997). A number of experimental studies as well as clinical trials were set up to evaluate the claims that Ibuprofen or other NSAID use could reduce the risk for AD. Chronic ibuprofen administration reduced Amyloid Beta production and inflammation in mouse models of Alzheimer's disease (Lim, Yang et al. 2000; Yan, Zhang et al. 2003; Heneka, Sastre et al. 2005), but clinical trials with NSAIDs as a therapeutic treatment for Alzheimer's disease were unsuccessful (Scharf, Mander et al. 1999; Reines, Block et al. 2004).

However, because ibuprofen and other NSAIDs were effective in reducing reactive microglia, a number of studies have evaluated their use as a therapeutic treatment for TBI and stroke. Following injury there is a rapid increase in proinflammatory cytokines (Frugier, Morganti-Kossmann et al. 2010). Chronically, activated microglia and increased cytokines have been observed as long as 1 year after injury (Kumar and Loane 2012; Faden and Loane 2015) in association with neurodegeneration (Soares, Hicks et al. 1995; Nonaka, Chen et al. 1999). One thought is that persistent microgliosis following TBI may contribute to ongoing neurodegeneration and cause many post-

traumatic symptoms including epilepsy, depression, substance abuse and CTE (Ojo, Mouzon et al. 2013; Bramlett and Dietrich 2015). Thus, limiting the microglial response to injury may be beneficial in reducing these unfavorable outcomes.

Ibuprofen has been proven effective in reducing neuronal injury and improving neurological outcome following experimental global and focal ischemia (Kuhn, Steimle et al. 1986; Grice, Chappell et al. 1987; Cole, Patel et al. 1993; Patel, Drummond et al. 1993; Antezana, Clatterbuck et al. 2003). In a study of ischemia-induced neuronal injury, ibuprofen-treated animals were shown to have an increase in IL-1 receptor antagonist (IL-1ra). IL-1ra is an endogenous competitive antagonist of IL-1 receptors and can counteract the pro-inflammatory cytokine IL-1 β that is upregulated acutely after injury (Rowe, Harrison et al. 2014).

In studies of TBI, ibuprofen and other COX inhibitors have been able to improve neurological dysfunction and attenuate neuronal death acutely after injury compared to untreated injured animals (Cernak, Savic et al. 1996; Gopez, Yue et al. 2005; Hakan, Toklu et al. 2010; Ng, Semple et al. 2012; Thau-Zuchman, Shohami et al. 2012). However, administration of ibuprofen for four months following FPI significantly worsened cognitive deficits and did not attenuate hippocampal or cortical tissue loss (Browne, Iwata et al. 2006). Additional studies of other COX inhibitors have shown no effect on neuronal death (Kunz, Marklund et al. 2006), lesion volume or cognitive deficits (Hickey, Adelson et al. 2007). In a study evaluating one dose of ibuprofen following injury, ibuprofen did not help or harm behavioral outcome 24h after injury (Harrison, Rowe et al. 2014). Together these studies suggest that acute administration of

ibuprofen to reduce the immediate inflammatory response may be a good tool to study the role of microgliosis in chronic neurodegeneration.

Summary

TBI affects millions of people in the United States every year, and even mild head injuries can affect the quality of life for many individuals, especially for individuals who sustain multiple head injuries. Experimental models of mild TBI have substantially contributed to our understanding of the pathological consequences induced. Mild TBI is often associated with axonal injury in predominantly white matter tracts with concomitant neuro-inflammation and transient behavioral dysfunction. Repeated injuries exacerbated axonal injury, induced chronic microgliosis, and prolonged behavioral impairments. Chronic microgliosis is believed to contribute to ongoing neurodegeneration and pathology associated with neurodegenerative diseases. However, few experimental studies have been able to induce CTE-like pathology in wildtype mice.

The dissertation herein describes the comprehensive histopathological and behavioral characterization for a mouse model of repeated mild TBI and the effects of inter-injury interval on those outcomes. Furthermore, the dissertation describes studies investigating the relationship between neurodegeneration and microgliosis using this model of repeated mild TBI. To begin, the model was modified from the existing CCI model by replacing the tip with one made of silicone and impacting directly onto the skull to create a diffuse bilateral head injury with minimal gliosis, axonal injury, and cell death (Chapter 2). Using this model, repeated mild TBI at 24h inter-injury intervals increased inflammation and cell death, but when mild TBI were repeated at 48h inter-injury intervals these outcomes were similar to that of a single mild TBI. These results

spurred a ten week longitudinal study to evaluate the behavioral and chronic histopathological effects of repeated mild TBI at 24h and 48h inter-injury intervals (Chapter 3). To evaluate the role of microgliosis in chronic neurodegeneration microgliosis was either increased or mitigated following repeated mild TBI. To exacerbate microgliosis (Chapter 4) we utilized progranulin-deficient mice ($Grn^{-/-}$) that have significantly increased age-related and injury-induced microgliosis compared to wildtype mice (Yin, Dumont et al. 2010; Tanaka, Matsuwaki et al. 2013a). Ibuprofen was used to mitigate microgliosis following repeated mild TBI (Chapter 5). In both studies an acute histological evaluation was performed and a 7mo longitudinal assessment of behavioral dysfunction was followed by histological evaluation. Collectively, our analysis of repeated mild TBI with varying inter-injury intervals highlights the persistent behavioral consequences that can occur with seemingly little acute cell loss in animal models of mild TBI requiring a thorough discussion of our findings and the implications of inter-injury interval in the study of mild TBI (Chapter 6). Furthermore, our analysis of modulating microgliosis and its effect on axonal injury and chronic neurodegeneration were contrary to our hypothesis requiring a thorough discussion of microgliosis following repeated mild TBIs and the implications for targeting inflammation in future therapeutics.

CHAPTER 2: Regional Neurodegeneration and Gliosis are Amplified by Mild
Traumatic Brain Injury at 24h Intervals

Preface

Chapter 2 has been reprinted, with alterations, from *Journal of Neuropathology and Experimental Neurology*, Amanda N. Bolton (Hall) and Kathryn E. Saatman, “Regional neurodegeneration and gliosis are amplified by mild TBI repeated at 24h intervals”. Copyright 2014, with permission from Oxford University Press. Figures have been renumbered to the format dictated by the University of Kentucky Graduate School, and Supplementary Figure 1 has been inserted into the text of Chapter 2 as Figure 2.2.

Introduction

In the United States approximately 1.7 to 3.8 million people sustain a traumatic brain injury (TBI) every year (Langlois, Rutland-Brown et al. 2006; Faul M 2010), with the vast majority categorized as "mild" (Kraus and Nourjah 1988) and occurring during sports-related activities (Langlois, Rutland-Brown et al. 2006). A mild TBI is caused by a traumatic or biomechanical force that results in altered brain function, without neuropathological complications as can be observed with standard imaging techniques (Giza, Kutcher et al. 2013; Harmon, Drezner et al. 2013; McCrory, Meeuwisse et al. 2013). Mild TBI presents with a wide variety of signs and symptoms. These may include symptoms such as dizziness, headache, and/or nausea and signs such as loss of consciousness, memory loss, agitation, and/or motor deficits (Giza, Kutcher et al. 2013; Harmon, Drezner et al. 2013; McCrory, Meeuwisse et al. 2013). For many patients, rest over time will help alleviate symptoms of mild head injury within hours to a few days, but in 10-15% of individuals, symptoms will remain for much longer (McCrory, Meeuwisse et al. 2013).

Emphasis, specifically in sports-related TBI, has been put on alleviating symptoms before an athlete should return to play. Yet it is unclear whether cellular responses in the brain subside during that time, or if the brain remains in a state of heightened vulnerability to subsequent trauma. Individuals then return to play with a higher risk of sustaining another mild TBI, especially in high contact sports such as boxing and football (Giza, Kutcher et al. 2013; Harmon, Drezner et al. 2013; McCrory, Meeuwisse et al. 2013). Furthermore, the neurologic and pathophysiologic sequelae of additional TBIs may be more severe than that initiated by the first TBI if the brain has not

fully recovered. Animal models are an important tool in elucidating the molecular events triggered by mild TBI, investigating the cellular basis for continued vulnerability, and correlating brain pathology with neurobehavioral dysfunction. Models allow for a controlled, reproducible impact and enable the systematic variation of experimental parameters to explore the effects of repeated mild TBI.

The study of TBI is informed by a variety of well-established animal models: weight drop (Shapira, Shohami et al. 1988; Chen, Constantini et al. 1996), fluid percussion injury (Dixon, Lyeth et al. 1987; McIntosh, Noble et al. 1987), impact acceleration (Foda and Marmarou 1994; Marmarou, Foda et al. 1994), and controlled cortical impact (Lighthall 1988). These models have been used to describe patterns of gliosis, axonal injury, and/or neuron death as well as deficits in memory and motor coordination after a single “moderate to severe” injury. Many of these models have been modified to examine mild TBI and the effects of repeated injuries (Laurer, Bareyre et al. 2001; Creeley, Wozniak et al. 2004; Bennett, Mac Donald et al. 2012; Fujita, Wei et al. 2012; Shultz, Bao et al. 2012; Dewitt, Perez-Polo et al. 2013; Redell, Moore et al. 2013). To establish a model of mild TBI suitable for the study of repeated head injury, we selected a closed skull model, as have many laboratories (Creeley, Wozniak et al. 2004; Dikranian, Cohen et al. 2008; Huh, Widing et al. 2008; Bennett, Mac Donald et al. 2012; Kane, Angoa-Perez et al. 2012; Meehan, Zhang et al. 2012; Mouzon, Chaytow et al. 2012; Luo, Nguyen et al. 2014), in order to increase the ease with which repeated injuries can be applied and create a more diffuse pattern of injury by transferring the force of the insult across a large portion of the brain. We employed head fixation to minimize variability due to head movement. Impact was performed with a pliant tip to minimize

skull fracture, as described in previous publications (Laurer, Bareyre et al. 2001; Longhi, Saatman et al. 2005; Bennett, Mac Donald et al. 2012). However, while many repetitive mild TBI studies have employed a lateral impact (Huh, Widing et al. 2007; Dikranian, Cohen et al. 2008; Prins, Hales et al. 2010; Shitaka, Tran et al. 2011; Shultz, Bao et al. 2012; Luo, Nguyen et al. 2014), we chose a midline impact (Creeley, Wozniak et al. 2004; Fujita, Wei et al. 2012; Mouzon, Chaytow et al. 2012) with the goal of producing bilateral injury to enhance the distributed nature of the pathology. We then characterized histological and physiological responses to a single mild TBI as a function of injury severity and compared the response of single mild TBI to mild TBI repeated at either a 24h or 48h interval. We provide corroboration that axonal injury and astrogliosis are features of single mild closed head injury (CHI), but demonstrate an enhanced vulnerability of the brain to mild TBI repeated at a 24h interval, resulting in more extensive neurodegeneration and neuroinflammation, including pathology within the entorhinal cortex, cerebellum and brainstem.

Materials and Methods

Animals:

2-3 month old male, C57BL/6 mice were purchased from Jackson Laboratories (Bar Harbor, ME) for all experiments. Upon arrival, mice were group housed under a controlled 14:10 light: dark cycle and provided food and water *ad libitum*. Animal husbandry and all surgical procedures were approved by the University of Kentucky Institutional Animal Care and Use Committee and followed the federal guidelines set by the Institute of Laboratory Animal Resources (U.S.) and Committee on the Care and Use of Laboratories Animals.

Closed Head Injury:

Following induction of anesthesia in a chamber using 3% isoflurane/3% oxygen for 1-2 minutes mice were transferred into a stereotaxic frame with non-rupture Zygomatic ear cups (Kopf, Instruments, Tujunga, CA) where anesthesia was maintained using 2.5% isoflurane/2.5% oxygen delivered via a nose cone. The surgical area of the scalp was cleaned with a betadine solution. Following injection of 0.2ml 1:200,000 epinephrine and 0.5% bupivacaine (Henry Schein Animal Health, Dublin, OH) in sterile, normal saline for local analgesia, the scalp was resected. Mice then received a mild closed head injury (CHI) using a pneumatically controlled cortical impact device (TBI-0310 Impactor, Precision Systems and Instrumentation, Fairfax Station, VA) with a custom made, 5mm diameter, pliant, silicone tip with a hardness of 55 Shore A. The tip was aligned along the midline suture between the bregma and lambda sutures. The device was programmed to impact at an intended depth (0.5mm-3.0mm) at a 3.5m/sec velocity with a 500msec dwell time. Sham-injured mice received anesthesia and underwent the same surgical procedure without receiving an impact. The total duration of anesthesia was controlled for all animals to be 10 minutes.

In order to most accurately assess for loss of consciousness due to injury versus anesthesia, mice were immediately removed from the stereotaxic device after impact and placed onto a heating pad on their backs. Apnea duration and time to right spontaneously to a prone position (righting reflex) were assessed. After righting, mice were briefly re-anesthetized to suture their scalps and returned to the heating pad to fully recover. Mice were subcutaneously injected with 1mL of sterile, normal saline to increase hydration encouraging a normal eating response post-injury and maintenance of healthy weight.

For repeated sham and CHI injuries, sutures were removed, the scalp was resected, and then the above injury and assessment procedures were performed.

For initial characterization of the impact depth on histological and physiological responses, a single impact was delivered with a prescribed depth of 0.5mm, 1.0mm, 1.5mm, 2.0mm, 2.5mm or 3.0mm (n=2-3/impact depth). Apnea and righting reflex data were analyzed separately by 1-way ANOVA followed by post-hoc Neuman-Keuls tests using Graph Pad Prism 6 software (La Jolla, CA). Mice from these groups were euthanized 48h post-injury for analysis of astrocytosis and neuron degeneration.

For repeated CHI experiments mice were randomized into three major groups: 2.0mm repeated CHI, 2.0mm single CHI, and sham CHI (Figure 2.1). The repeated CHI group received five impacts at either a 24h interval between injuries (rCHI-24h; n=9) or a 48h interval (rCHI-48h; n=8). These intervals were selected based on multiple studies that suggest the interval of vulnerability for repeated mild TBI in rodents may be 24-48h (Laurer, Bareyre et al. 2001; Prins, Hales et al. 2010; Shitaka, Tran et al. 2011; Meehan, Zhang et al. 2012; Mouzon, Chaytow et al. 2012; Luo, Nguyen et al. 2014). Five impacts were utilized based on previous studies of repeated mild TBI (Kane, Angoa-Perez et al. 2012; Meehan, Zhang et al. 2012; Mouzon, Chaytow et al. 2012). rCHI mice were euthanized 24h after their final impact in order to assess the acute consequences of repeated CHI at varying inter-injury intervals. The single CHI group was divided into three subgroups to parallel the survival times of the rCHI groups relative to the first and last injuries: 24h (single 24h; n=6), 5days (single 5d; n=5), and 9days (single 9d; n=5). Sham control mice for the rCHI-24h (n=4) and rCHI-48h groups (n=3) were pooled for analysis (n=7), except in Figure 2.2. One mouse assigned to the rCHI-24h group and one

assigned to the rCHI-48h group died to receiving five CHI. Therefore the final group sizes were 8 for rCHI-24h and 7 for rCHI-48h. Apnea and righting reflex data were analyzed by repeated measures 1-way ANOVA (injury group x number of CHI) followed by post-hoc Neuman-Keuls tests using Graph Pad Prism 6 software.

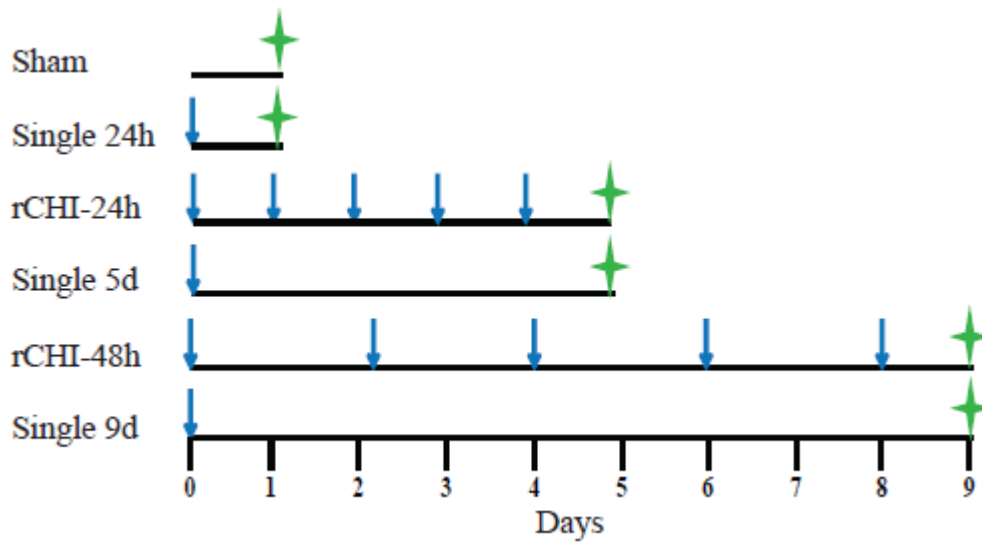


Figure 2.1: Repeated closed head injury (CHI) experimental design.
 Blue arrows indicate day of CHI. Green crosses indicate euthanasia.

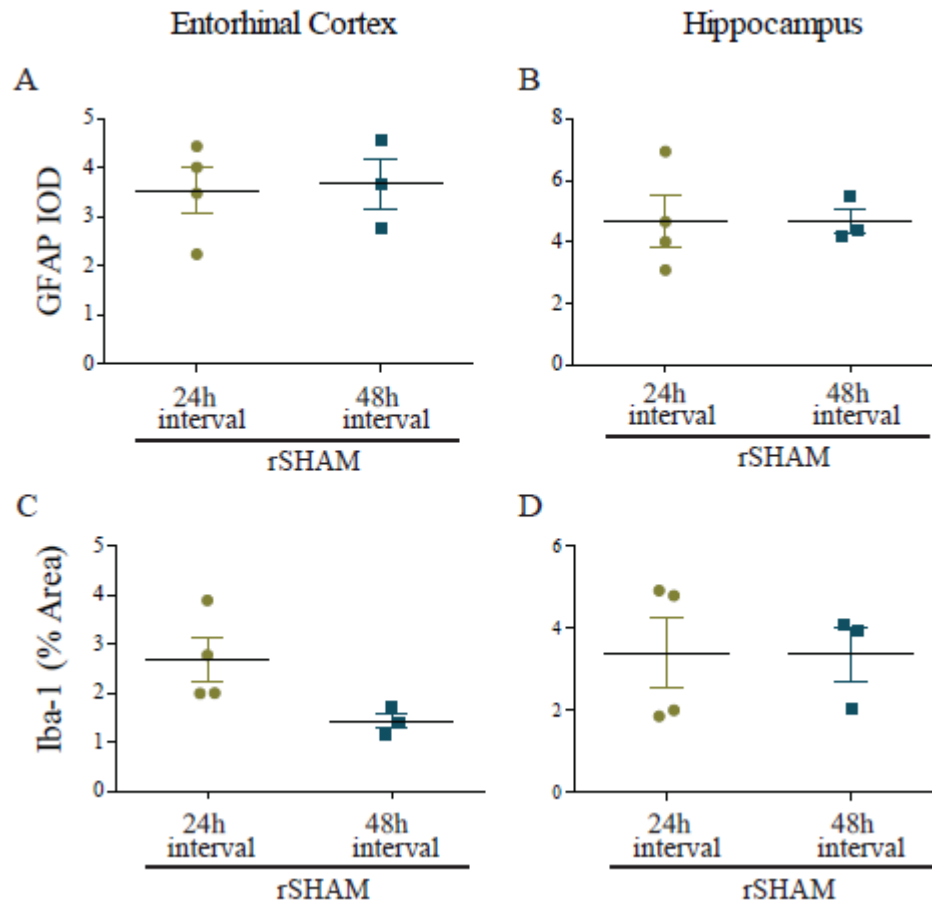


Figure 2.2: Comparison of neuroinflammation after repeated anesthesia.

Immunohistochemical labeling of glial fibrillary acidic protein (GFAP) and ionized calcium-binding adaptor molecule 1 (Iba-1) after five sham injuries repeated at 24h or 48h intervals. The mean Integrated Optical Density of GFAP per astrocyte (A, B) and the percent area of Iba-1 immunolabeling (C, D) were quantified within the entorhinal cortex (A, C) and the hippocampus (B, D). Bars represent mean \pm SEM. Groups were not significantly different for any measure (T-test; $p > 0.05$).

Euthanasia and Tissue Processing:

Mice were euthanized by intraperitoneal injection of Fatal Plus (130mg/kg, Henry-Schein Animal Health, Dublin, OH) before transcardial perfusion with cold heparinized sterile saline followed with 10% neutral buffered formalin (Fisher Scientific, Atlanta, GA). Mice were decapitated and heads placed into formalin for 24h. Brains were then removed from the skull and allowed to post-fix for an additional 24h. Following this period, the brains were placed into 30% sucrose in 1X TBS for 24-48h to cryoprotect the tissue. The tissue was frozen in -25 to -35°C isopentane before being cut into 40µm thick coronal sections using a sliding microtome (Dolby-Jamison, Pottstown, PA). Tissue sections were stored at -20°C in cryoprotectant (30% glycerol, 30% ethylene glycol in 1X TBS).

Histology:

For initial assessment of cell loss, a series of 9 sections spaced at 400µm intervals were Nissl stained with 2.5% Cresyl Violet (Redell, Moore et al. 2013).

Degenerating neurons were examined with Fluorojade-C (FJC) using previously described methodology (Dewitt, Perez-Polo et al. 2013). For each animal, 4 sections at 400µm intervals within the caudal hippocampus and entorhinal cortex (from -2.2 to -3.4mm Bregma), and 6-8 sections at 200µm intervals within the cerebellum and the brainstem were selected. Sections were initially treated with diaminobenzidine (DAB, Vector Laboratories, Burlingame, CA) for five minutes, washed in ddH₂O, and mounted onto slides. The DAB treatment was used to quench endogenous peroxidases, eliminating any non-specific fluorescence that may occur with hemorrhage. The tissue was dehydrated by placing slides on a warmer (45°C) for 30 minutes and then leaving them at

room temperature overnight. On the following day, slides were immersed sequentially in 1% NaOH in 80% ethanol, 70% ethanol, and ddH₂O before being placed into 0.06% potassium permanganate solution for ten minutes. The tissue was washed with ddH₂O before incubating in 0.0001% FJC solution (Millipore, Temecula, CA) in 0.1% acetic acid for ten minutes. The tissue was rinsed with ddH₂O, air dried, coverslipped with Cytoseal 60 (Thermo Scientific, Hanover Park, IL) and protected from light.

Immunohistochemistry:

Free-floating tissue sections were used for immunohistochemical analysis. In order to label tissue for accumulation of amyloid precursor protein (cAPP) and hyperphosphorylated tau (PHF-1), antigen retrieval was performed using 10mM citric acid in 65°C water bath for 15 minutes. Tissue was then allowed to cool at room temperature for 20 minutes before being washed with 1XTBS. For all tissues, to quench endogenous peroxides, tissue was treated with 3% H₂O₂ in 50/50 methanol/ddH₂O for 30 minutes, rocking at room temperature. Tissue was subsequently washed and blocked for 1h with 5% Normal Horse Serum in 1XTBS/0.1% Triton X-100 before incubation in primary antibody overnight at 4°C. The following antibodies were used: anti-amyloid precursor protein (cAPP, rabbit polyclonal, 1:2000; Invitrogen/Life Technologies, Carlsbad, CA), anti-tau pSer396/404 (PHF-1, mouse monoclonal, 1:500, Peter Davies, The Feinstein Institute for Medical Research, Great Neck, NY), anti-glial fibrillary acidic protein (GFAP, mouse monoclonal, 1:3000; Sigma-Aldrich, St. Louis, MO), anti-ionized calcium-binding adaptor molecule-1 (Iba-1, rabbit polyclonal, 1:1000; Wako, Richmond, VA), and anti-MHC II (I-A/I-E, rat monoclonal, 1:1000; eBiosciences, San Diego, CA). On the following day GFAP, cAPP, and PHF-1 labeled tissue were incubated in

appropriate biotin-conjugated secondary for 1h. The tissue was washed before incubating in Avidin-Biotin complex (Vector Laboratories, Burlingame, CA) for 1h and then treating with DAB as directed by the manufacturer. Iba-1 and I-A/I-E labeled tissues were incubated in appropriate secondary antibodies conjugated with Alexa-488 and Cy-3, respectively.

Quantification of Histology/Immunohistochemistry:

FJC stained sections were viewed at 40x magnification using an Olympus AX80 microscope with a TRITC filter. FJC positive cells in bilateral entorhinal cortices were counted by an individual blinded to the injury conditions. Counts were summed for each animal for statistical analysis. Cerebellum and brainstem sections labeled with FJC were examined qualitatively.

cAPP positive axons in 4 sections/animal spaced at 200 μ m intervals (~bregma level -2.2 to -3.4) were viewed under bright field using an Olympus AX80 microscope with a 40x lens. Axonal swellings and bulbs were counted by a blinded examiner. Counts were summed for each animal for statistical analysis.

GFAP immunoreactivity was viewed using an Olympus BX51 microscope (20x) with an ASI XY automated stage. 24bit RGB images of the entorhinal cortices and hippocampi were captured using a 12bit Q Imaging camera. The calibrated Stage-Pro module of Image Pro Plus (Media Cybernetics, MD) was used to assemble the images into a montage. The entorhinal cortex was analyzed in 4 sections/animal taken at 200 μ m intervals (Bregma -2.8 to -3.4mm). Astrocytosis in the hippocampus was analyzed in 3 sections/animal taken at 200 μ m intervals (Bregma -2.8 to -3.2mm). To quantify GFAP

immunoreactivity the area of interest (AOI) was outlined using the anatomical features as described in “The Mouse Brain in Stereotaxic Coordinates”, 4th Edition (Paxinos & Franklin). The hippocampus was outlined along the dorsal edge by following the alveus of hippocampus, and then above the thalamus on the ventral side of the hippocampus. To outline the entorhinal cortex, the rhinal fissure (rf) was used as a starting point. A line was drawn ventrally along the periphery of the entorhinal cortex, approximately 1.5mm from rf. From there, the line was extended horizontally to the lateral ventricle before continuing dorsally along the edge of the lateral ventricle until horizontal to rf. The line was continued horizontally to the rf to connect to the point of origin. The range was set at 0-210 for each color, and the minimum area set at 5 pixels to capture GFAP labeled astrocytes and eliminate background noise. The number of GFAP immunoreactive astrocytes was quantified, and the mean Integrated Optical Density (IOD) was determined by dividing the total IOD by the number of astrocytes within a given AOI. Higher IOD corresponded to greater GFAP immunoreactivity. Data collected was averaged for each region (entorhinal cortex, hippocampus) for each animal for statistical analysis. In the cerebellum and brainstem, GFAP immunoreactivity was qualitatively assessed in a series of 6-8 sections selected at 200 μ m intervals.

Iba-1 immunoreactivity was viewed using a FITC filter on an Olympus BX51 microscope (20x) with an ASI XY automated stage. 8 bit greyscale images were taken and montaged as previously described. The percentage of Iba-1 immunoreactivity in the entorhinal cortex and hippocampus were analyzed by first setting the display range at 0-255 in order to outline the hippocampus or entorhinal cortex as previously described. A blinded examiner then chose the range that selected immunoreactive microglia for each

tiled image. The percent of the total area which contained Iba-1 labeled microglia was measured and averaged for the entorhinal cortex across 8 montages/animal and for the hippocampus across 6 montages/animal. Tissue labeled with Iba-1 was co-labeled with I-A/I-E (MHC Class II). I-A/I-E immunolabeling was evaluated qualitatively.

A 1-way ANOVA followed by post-hoc Neuman-Keuls tests where appropriate was performed using the Graph Pad Prism 6 software to determine statistical significance among groups for each marker within each region.

Results

Impact Depth Characterization

An initial cohort of mice was subjected to CHI of differing impact depths in order to characterize the CHI model and to determine the injury parameters that resulted in a mild TBI as evaluated by neuronal degeneration, gliosis, and acute post-concussive physiological responses. Prescribed impact depths on the midline suture of the mouse skull of 0.5mm, 1.0mm and 1.5mm did not prolong suppression of the righting reflex after impact (Figure 2.3A) but produced a graded increase in apnea with increased injury severity (Figure 2.3B) when compared to anesthesia alone in sham control animals. Mice injured with a prescribed depth of 2.0mm had a significantly increased righting reflex suppression ($p < 0.05$) and apnea duration ($p < 0.05$) compared to sham control mice and mice receiving CHI at all other smaller impact depths. Impact depths of 2.0mm did not result in skull fracture. In contrast, impact depths of 2.5mm and 3.0mm produced skull fractures or prolonged apnea that resulted in death in 6 of 10 animals tested.

At 48h after CHI, FJC-positive cells were observed in only the 3.0mm impact group in the dentate gyrus (Figure 2.3O) suggesting a single CHI of less than 3.0mm depth did not produce notable neurodegeneration in the cerebrum at 48h after impact. GFAP immunohistochemistry was used to visualize astroglial changes throughout the cerebrum. Impact depths of 0.5mm (data not shown), 1.0mm (Figure 2.3H-J), 1.5mm (data not shown), and 2.0mm (Figure 2.3L-N) caused only slight increases in GFAP immunoreactivity in the hippocampus and entorhinal cortex. In contrast, hippocampal and cortical gliosis was more evident after CHI at a 2.5mm (data not shown) or 3.0mm impact depth (Figure 2.3P-R) particularly in the dentate gyrus and hilus where neuronal

degeneration was also occurring. Based on the initial characterization of impact depths in the range of 0.5-3.0mm, a prescribed depth of 2.0mm was selected for subsequent experiments evaluating repeated CHI based on the presence of acute physiological responses (increased righting reflex and apnea times) and mild gliosis indicative of tissue responses in the absence of notable neuronal death. The cerebella and brainstems of this cohort of animals were not available for assessment.

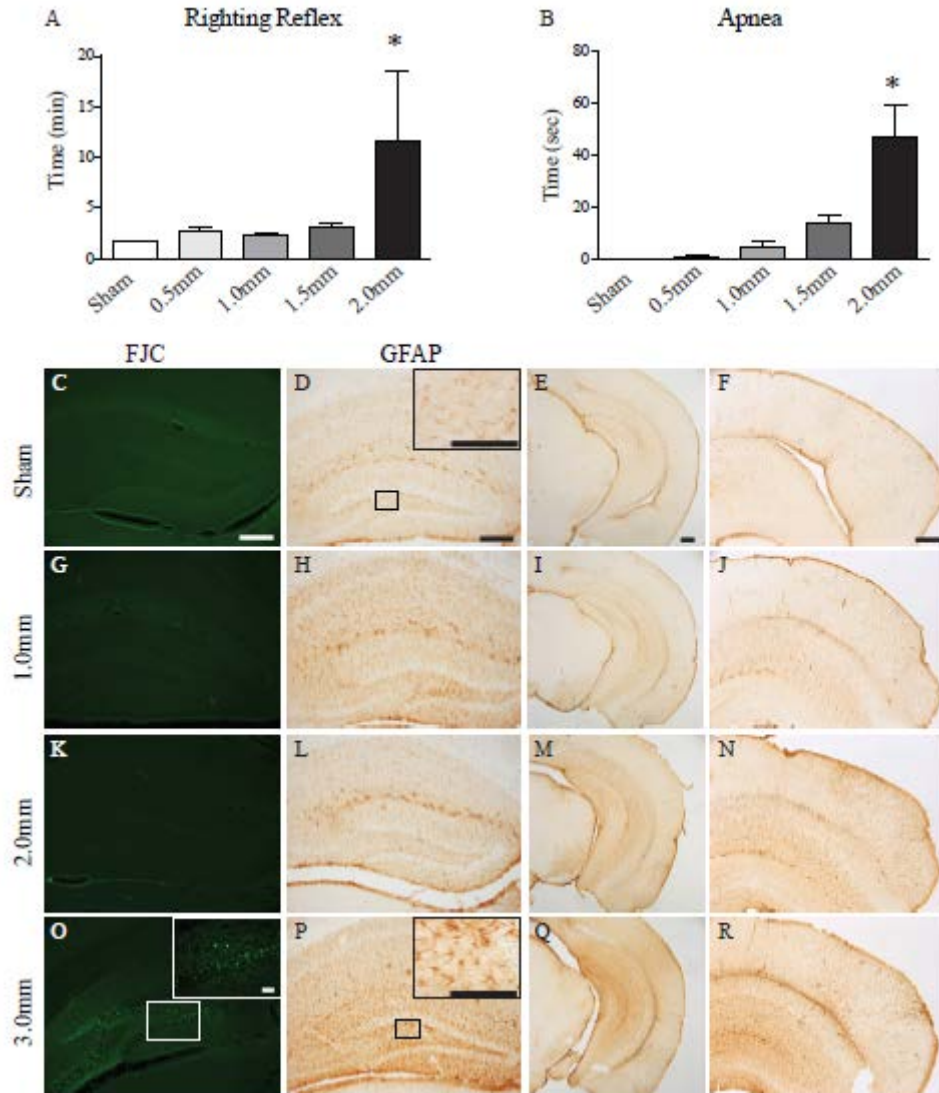


Figure 2.3: Acute physiological and histopathological consequences of single impact as a function of depth.

Righting reflex (A) and apnea (B) following closed head injury (CHI). * indicates $p < 0.05$ compared to all other groups. Bars represent mean + SEM. $n = 2-3$ /group. Fluoro-jade C (FJC) staining after sham (C), 1.0mm (G), 2.0mm (K), and 3.0mm (O) impact depths. FJC positive cells were evident in the dentate gyrus 48h after a 3.0mm impact depth. Glial Fibrillary Acidic Protein (GFAP) labeled astrocytes in the hippocampus and entorhinal cortex after sham (D, E, F), 1.0mm (H, I, J), 2.0mm (L, M, N), and 3.0mm (P, Q, R) impact depths. Mild astrocytosis was evident in the caudal hippocampus and entorhinal cortex after a 2.0mm impact. A 3.0mm impact increased astrocytosis in the entire hippocampus and motor cortex. Scale bars = 500 μ m in C, D, G, H, K, L, O, P; 100 μ m in D, O, P inserts; 1mm in E, F, I, J, M, N, Q, R.

Acute Physiological Responses Decrease with Repeated CHI

To evaluate the effects of repeated CHI on acute physiological responses and determine if apnea and righting reflex depend on the inter-injury interval, responses were compared among mice from sham, rCHI-24h and rCHI-48h groups.

The amount of time to elicit a righting reflex response (Figure 2.4A) was dependent upon both the injury group ($p < 0.0005$) and the number of CHI ($p < 0.0001$) with a significant interaction between these factors ($p < 0.05$). Suppression of the righting reflex in both rCHI groups was significantly longer than in the sham group ($p < 0.001$ for rCHI-24h; $p < 0.005$ for rCHI-48h). Across time, return of the righting reflex response in the rCHI-24h group was significantly more delayed compared to the rCHI-48h group ($p < 0.05$). However, post-hoc testing did not reveal a significant difference in righting reflex between the two rCHI groups for any specific CHI (first through fifth). Within the rCHI-24h group, righting reflex suppression was prolonged significantly after the first and second CHI ($p < 0.05$ compared to sham). Reflex suppression was significantly reduced after the fourth and fifth impact compared to the rCHI-24h group's response to the initial impact. The rCHI-48h group also exhibited a significant increase in the time to restore righting reflex after the first CHI but not after subsequent CHI.

Apnea duration (Figure 2.4B) varied as a function of injury ($p < 0.0001$) and the number of CHI ($p < 0.005$) with a significant interaction between these factors ($p < 0.05$). Both the rCHI-24h and rCHI-48h groups had significant apnea after the first impact as compared to the sham group ($p < 0.0001$ and $p < 0.001$, respectively), but apnea duration decreased significantly when the second impact was imparted 48h as opposed to 24h after the first ($p < 0.05$). Both repeated mild TBI groups showed a trend toward shorter apnea

with successive impacts. As compared to apnea following the first impact, apnea was significantly reduced following the third, fourth, and fifth impacts for the rCHI-24h group and the second, fourth and fifth impacts for the rCHI-48h group, suggestive of a compensatory mechanism at play with multiple mild TBIs.

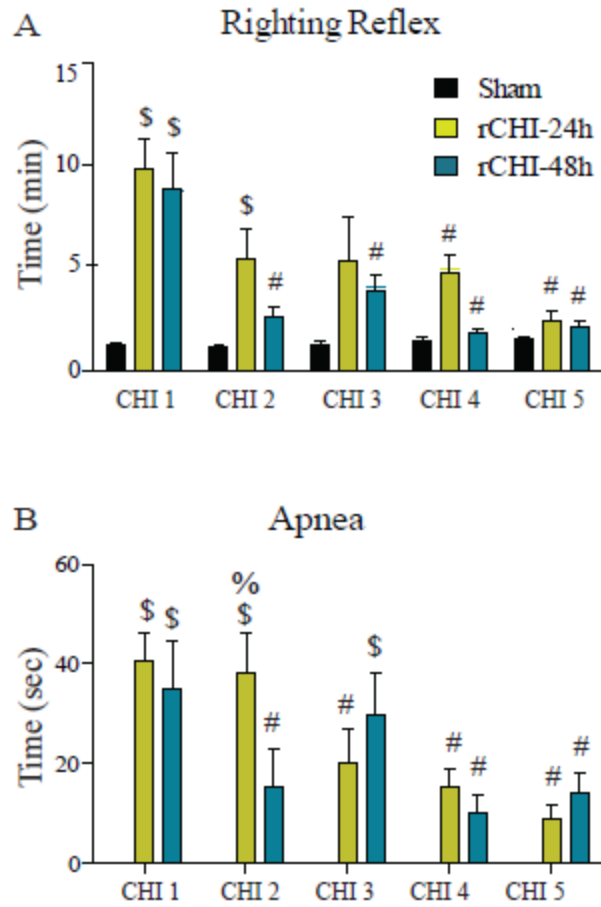


Figure 2.4: Righting reflex (A) and apnea (B) after sham injury, repeated closed head injury at 24h intervals (rCHI-24h), and repeated closed head injury at 48h intervals (rCHI-48h). \$ indicates $p < 0.05$ compared to sham. % indicates $p < 0.05$ compared to rCHI-48h. # indicates $p < 0.05$ compared to CHI 1 of same group. Bars represent mean + SEM. $n = 7-8$ /group.

Mild TBI Repeated at 24h but not 48h Intervals Exacerbates Acute Neuron Death in the Entorhinal Cortex

Several histological assessments were used to evaluate the effects of repeated CHI on the brain and whether the time interval between impacts influenced these responses. Nissl staining did not reveal any overt pathological changes at 1, 5, or 9d after a single CHI (Figure 2.5A). However, 5 of 8 mice in the rCHI-24h group exhibited hemorrhagic lesions in the entorhinal cortex at 24h after the fifth concussion (Figure 2.5C). The incidence of hemorrhagic lesions decreased to 1 of 7 in the rCHI-48h group (Figure 2.5E), and the lesion was smaller in size compared to those observed in mice injured at a 24h interval.

In the entorhinal cortex, a single impact of 2.0mm resulted in a small number of FJC-positive cells 24h after the injury (Figure 2.5B) indicating neuronal degeneration; however, the number of degenerating neurons was not significantly different from sham (Figure 2.5G). In the rCHI-24h group, FJC-positive cells were located around the region of hemorrhage (Figure 2.5C) as well as in the entorhinal cortex in tissue sections that did not contain a lesion. Mild TBI repeated at a 24h interval, but not a 48h interval, resulted in a significant increase in numbers of FJC-positive cells within the entorhinal cortex as compared to sham injury ($p < 0.05$; Figure 2.5G). Neither single nor repeated CHI at a 2.0mm impact depth resulted in FJC staining in the hippocampus.

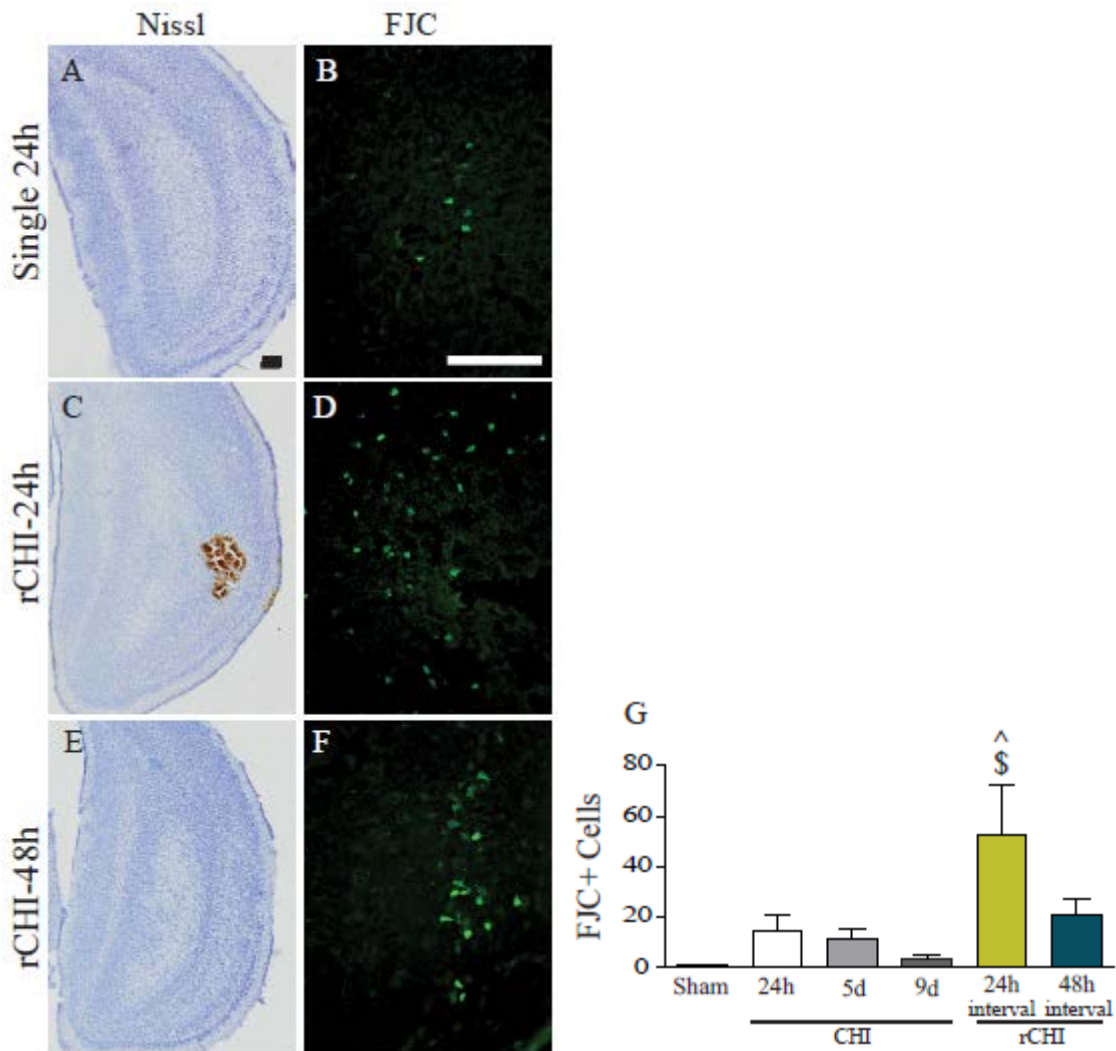


Figure 2.5: Neuronal degeneration in the entorhinal cortex after single and repeated closed head injury (CHI).

Nissl staining of mice receiving single CHI with 24h euthanasia (Single 24h; A), five CHI repeated with a 24h inter-injury interval (rCHI-24h; E), and five CHI repeated with a 48h inter-injury interval (rCHI-48h; D). Nissl staining showed evidence of hemorrhagic lesions in the entorhinal cortex of the rCHI-24h group. FJC staining in the entorhinal cortex of mice in the Single 24h group (B), rCHI-24h (D), and rCHI-48h (F). Scale bars = 500 μ m in A, C, E; 250 μ m in B, D, F. The number of FJC-positive cells was increased in the entorhinal cortex of the rCHI-24h group compared to sham (G). Bars represent mean + SEM. \$ indicates $p < 0.05$ compared to sham. ^ indicates $p < 0.05$ compared to Single 9d. $n = 5-6$ for single CHI groups, $n = 7-8$ for rCHI groups, and $n = 7$ for sham-injured group.

In the cerebellum, qualitative assessment of FJC staining revealed a small amount of bilateral neuronal degeneration within the Purkinje cell and molecular layers of the most distal aspect of the lateral cerebellar folia 24h after a single CHI (Figure 2.6A) that was primarily restricted to neuronal process staining in the molecular layer by 9d after a single CHI (not shown). In contrast, somas of degenerating neurons were rarely labeled in mice that received rCHI at 24h intervals. With an inter-injury interval of 48h, some rCHI mice exhibited FJC labeling of a small number of neurons and processes within the lateral cerebellar folia, similar to that observed in the single CHI groups.

Mild TBIs Produce Axonal Injury

While FJC staining did not reveal notable axonal injury in the cortex, cerebral white matter or hippocampus, it provided clear evidence of axon damage within the cerebellum and brainstem at 24h after repeated mild TBI. Mild axonal injury was observed in the lateral cerebellar white matter tracts (Figure 2.6A) but not in the brainstem (Figure 2.6B) with single CHI. Axonal injury was more extensive and more diffusely distributed in the rCHI-24h group, with axonal injury in lateral (Figure 2.6C) and central white matter tracts within the cerebellum, and scattered throughout the brainstem, with most concentrated ventrolaterally (Figure 2.6D). Repeated CHI at a 48h interval resulted in a similar distribution of axonal injury as with the 24h interval, but the amount of axonal injury appeared to be less (Figure 2.6E, F).

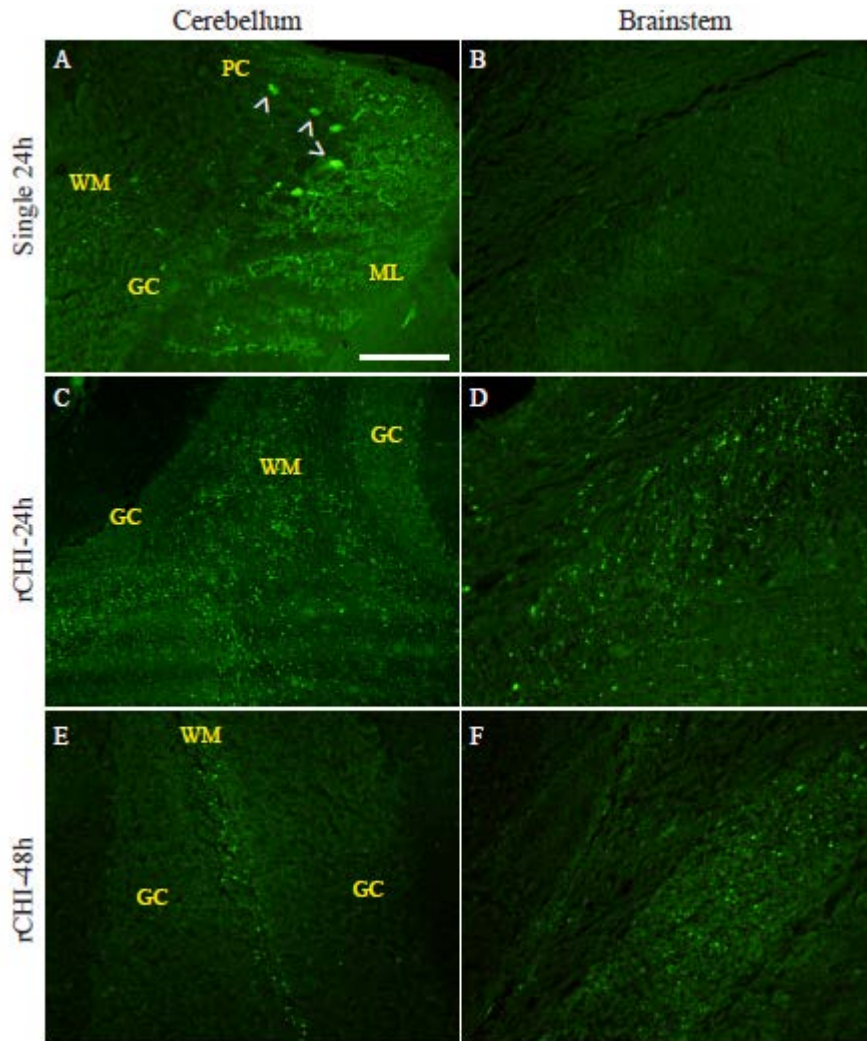


Figure 2.6: Neuronal degeneration in the cerebellum and brainstem after a single and repeated closed head injury (CHI).

Fluorochrome C (FJC) staining in mice euthanized 24h after a single CHI (Single 24h) indicated degenerating neurons within the purkinje cell (PC) layer and some axonal injury in the white matter (WM) tract of the cerebellum (A) with very little injury to the brainstem (B). Five CHI repeated at a 24h inter-injury interval (rCHI-24h) exacerbated axonal degeneration throughout the WM of the cerebellum (C) and in the ventrolateral aspects of the brainstem (D). When the interval between repeated CHI was lengthened to 48h (rCHI-48h) a decrease in axonal degeneration was observed in the cerebellum (E) and brainstem (F) compared to the rCHI-24h group. ^ indicates degenerating neurons; ML = molecular layer; GC = granular cell layer; scale bar = 100 μ m. n=5-6 for single CHI groups, n=7-8 for rCHI groups, and n=7 for sham-injured group.

Within the cerebrum, axonal injury was detected by the accumulation of cAPP in axonal swellings and small bulbs in the entorhinal cortex 24h after a single CHI (Figure 2.7A, D). The number of cAPP-positive axons/bulbs diminished with longer survival durations (5d, 9d; Figure 2.7G) indicating an acute but not protracted wave of axonal injury. When CHI were repeated at 24h intervals, the number of labeled axons increased compared to a single CHI, but this was not statistically significant (Figure 2.7G). The incidence of axonal injury was also similar between the rCHI-24h group (5 of 8 with >1 swelling/section) and the single 24h group (3 of 6). Despite these similarities, cAPP-labeled bulbs appeared much larger in the rCHI-24h group (Figure 2.7B, E) than in single CHI groups (Figure 2.7A, D). Additionally, in the rCHI-24h group, the clusters of bulbs were located adjacent to the external capsule (Figure 2.7B, E) whereas axonal injury in the single 24h group was more centrally located within the entorhinal cortex. When CHI was repeated at 48h intervals few mice exhibited axonal injury (2 of 7). Although the mean number of cAPP labeled axons was similar to the single 24h group, this was due to one animal with an unusually high number of swellings.

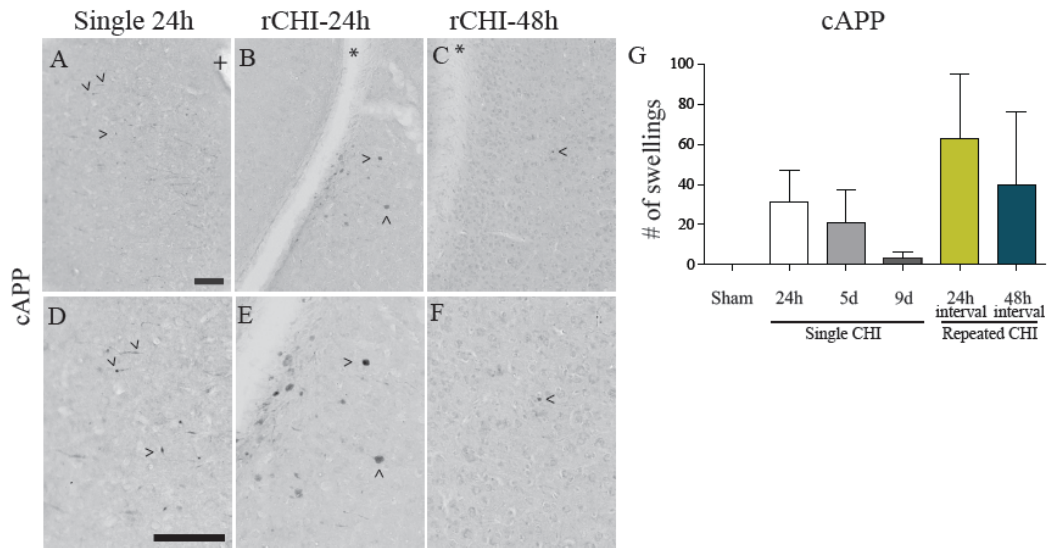


Figure 2.7: Axonal injury after repeated closed head injury (CHI).

Immunohistochemical labeling of amyloid precursor protein (cAPP) 24h after a single CHI (Single 24h; A, D), five CHI repeated at 24h intervals (rCHI-24h; B, E), and five CHI repeated at 48h intervals (rCHI-48h; C, F). ^ indicates cAPP labeled axons; * indicates the external capsule; + indicates the rhinal fissure; scale bars = 250 μ m. The number of immunolabeled axonal swellings was counted. There was no significant difference across groups (G). Bars represent mean + SEM. n=5-6 for single CHI groups, n=7-8 for rCHI groups, and n=7 for sham-injured group.

Astrocytosis is Exacerbated by Repeated CHI at 24h but not 48h Intervals

GFAP-positive astrocytes were present in the entorhinal cortex in sham-injured animals, but their cell bodies and processes did not appear swollen (Figure 2.8A, D). Acutely after a single CHI, some astrocytes in a small area of the entorhinal cortex appeared more swollen compared to those in sham mice. While the number of GFAP-positive astrocytes at 24h was not increased compared to sham injury, numbers increased progressively over 9d following a single mild TBI ($p < 0.05$ compared to CHI 24h; Figure 2.8G). A single mild TBI also resulted in a delayed increase in the intensity of GFAP immunoreactivity per astrocyte at 9d following injury ($p < 0.05$ compared to sham; Figure 2.8G). When CHI was repeated at 24h intervals, astrocytes across the entire entorhinal cortex region appeared reactive with swollen cell bodies and processes (Figure 2.8B, E). The number of GFAP-positive astrocytes in the entorhinal cortex was significantly increased in rCHI-24h mice compared to mice evaluated 24h after a single CHI ($p < 0.05$; Figure 2.8G) and appeared to be increased compared to the single CHI 5d survival group, although this did not reach statistical significance. The intensity of GFAP immunoreactivity per astrocyte was also increased in the entorhinal cortex of the rCHI-24h group compared to the single CHI groups and sham injury ($p < 0.05$; Figure 2.8G). When the inter-injury interval was lengthened to 48h, the regional extent of reactive astrocytosis was similar to that observed 9d after a single CHI, but some cell bodies and processes appeared swollen as in the rCHI-24h group (Figure 2.8C, F). Numbers of GFAP-positive astrocytes in the entorhinal cortex of the rCHI-48h group increased compared to 24h after a single CHI, but were not different from 9d after a single CHI (Figure 2.8G). GFAP immunoreactivity for a given astrocyte in the rCHI-48h group did

not change compared to sham and single CHI suggesting that a longer interval between injuries may protect against cumulative impacts (Figure 2.8G). These data point to an additive effect of CHI repeated at a 24h but not a 48h interval on astrogliosis in the entorhinal cortex.

In the hippocampus, both the number and GFAP immunoreactivity per astrocyte were higher at 24h after a single CHI than at 5d and 9d, consistent with acute transient gliosis (Figure 2.8H). However, the response 24h after a single CHI was equivalent to sham suggesting a possible anesthesia-induced gliosis in sham-injured mice which received five anesthesia exposures. Increased hippocampal astrocytosis has been previously reported with repeated anesthesia (Mouzon, Chaytow et al. 2012). However, the degree of anesthesia-induced astrocytosis was not influenced by the interval between anesthesia bouts (Figure 2.2). Mild TBI repeated at a 24h interval did not result in a greater number of GFAP-positive astrocytes compared to sham or single CHI (Figure 2.8H). GFAP immunoreactivity per astrocyte was significantly increased in the rCHI-24h group compared to sham, but not the single 24h group (Figure 2.8H). When CHI was repeated at 48h inter-injury intervals astrocytes appeared less swollen than in the rCHI-24h group, and neither the number of GFAP-positive astrocytes nor GFAP expression per astrocyte were significantly different compared to sham or the single 24h group (Figure 2.8H).

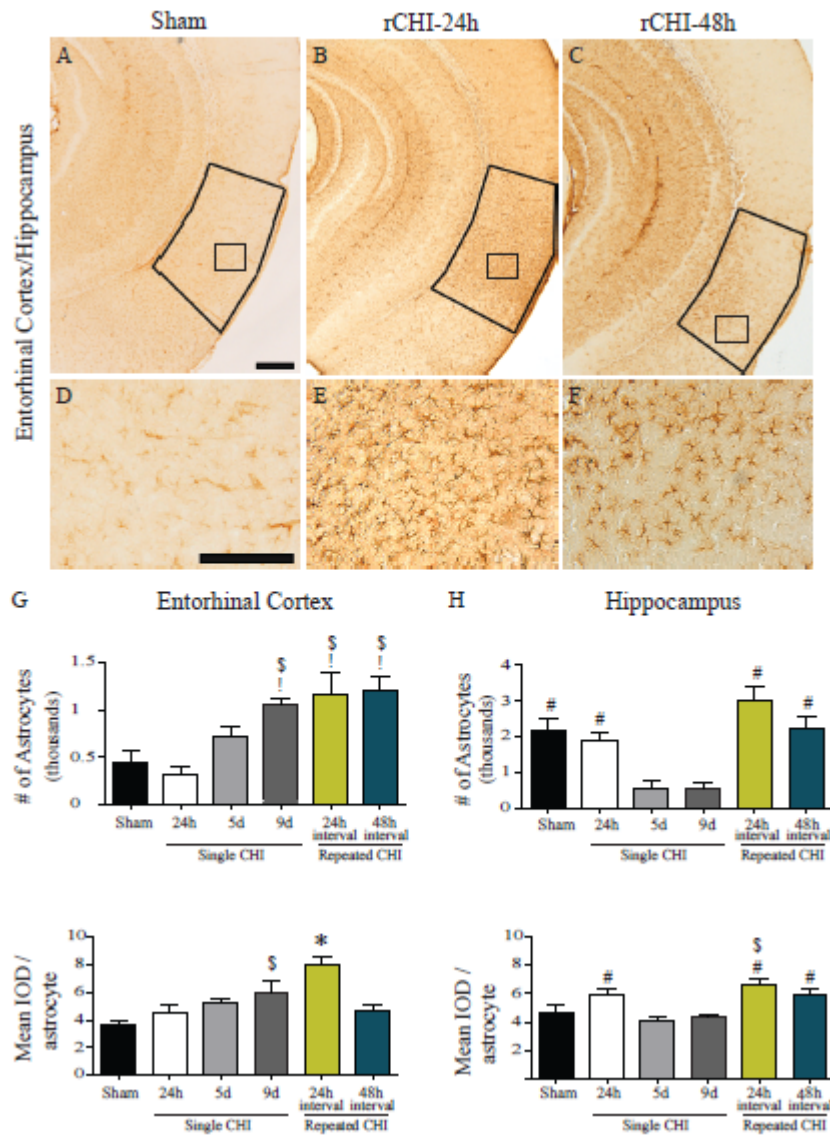


Figure 2.8: Astrocytosis in the entorhinal cortex and hippocampus after sham and repeated closed head injuries (CHI).

Immunohistochemical labeling of glial fibrillary acidic protein (GFAP) after sham (A, D) five CHI repeated at 24h intervals (rCHI-24h; B, E) or 48h intervals (rCHI-48h, C, F). Scale bars = 500 μ m in A-C; 250 μ m in D-F. Immunoreactive astrocytes were counted in the entorhinal cortex (representative area of interest outlined in black; G) and hippocampus (H). The mean Integrated Optical Density of GFAP per astrocyte was quantified in the entorhinal cortex (G) and hippocampus (H). Bars represent mean + SEM. * indicates $p < 0.05$ compared to all other groups. \$ indicates $p < 0.05$ compared to sham. ! indicates $p < 0.05$ compared to Single 24h. # indicates $p < 0.05$ compared to single 5d and single 9d. $n = 5-6$ for single CHI groups, $n = 7-8$ for rCHI groups, and $n = 7$ for sham-injured group.

Qualitative analysis of astrocytosis within the cerebellum and brainstem revealed patterns among injury groups similar to those described for the entorhinal cortex. A single CHI induced a mild gliosis in the molecular layer of the most distal aspect of the lateral cerebellar folia, in regions similar to those exhibiting neuron degeneration with FJC. Very little astrocyte reactivity was noted in the brainstem. When repeated at 24h intervals, five CHI caused an increased response of astrocytes bilaterally within cerebellum, most notably in the lateral folia (Figure 2.9B). Astrocyte processes extending across the molecular layer became thickened and cell bodies within the granular cell layer hypertrophied (Figure 2.9E). Repeated CHI at 24h intervals also resulted in increased GFAP immunostaining in the gray and white matter of the brainstem (Figure 2.9H, K). When the interval was extended to 48h, five CHI induced a milder astrocytic response within the lateral cerebellum (Figure 2.9C, F) and brainstem (Figure 2.9I, L) compared to the rCHI-24h group.

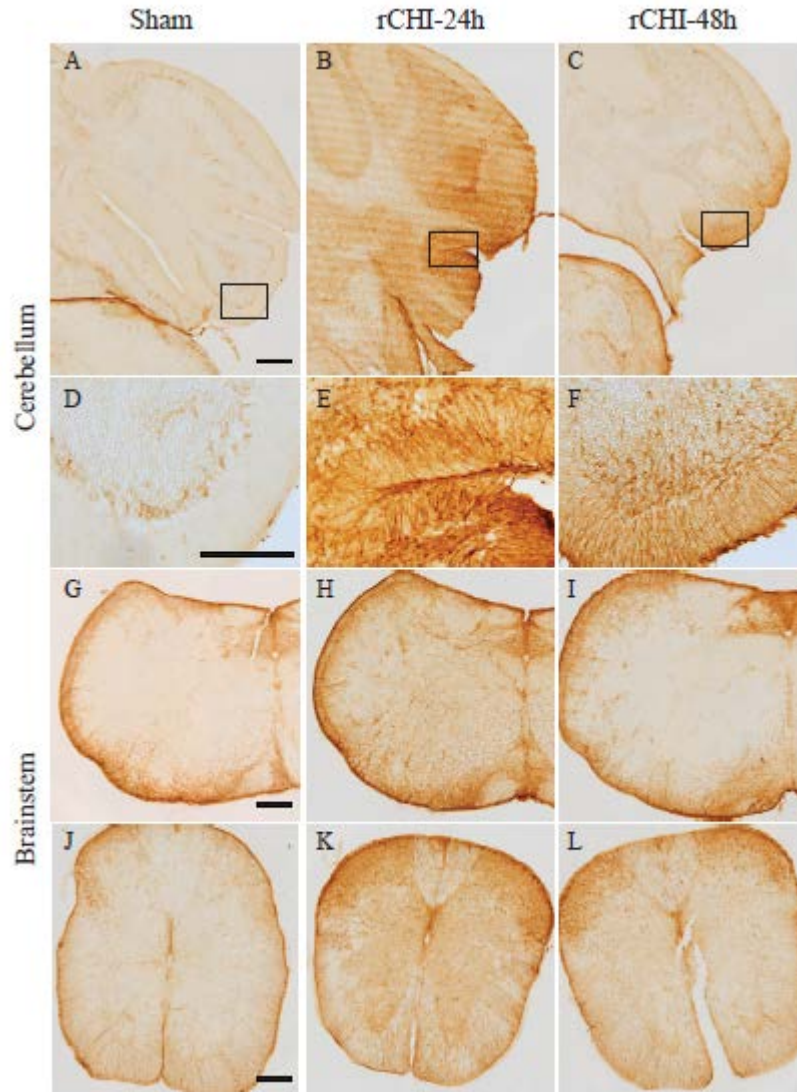


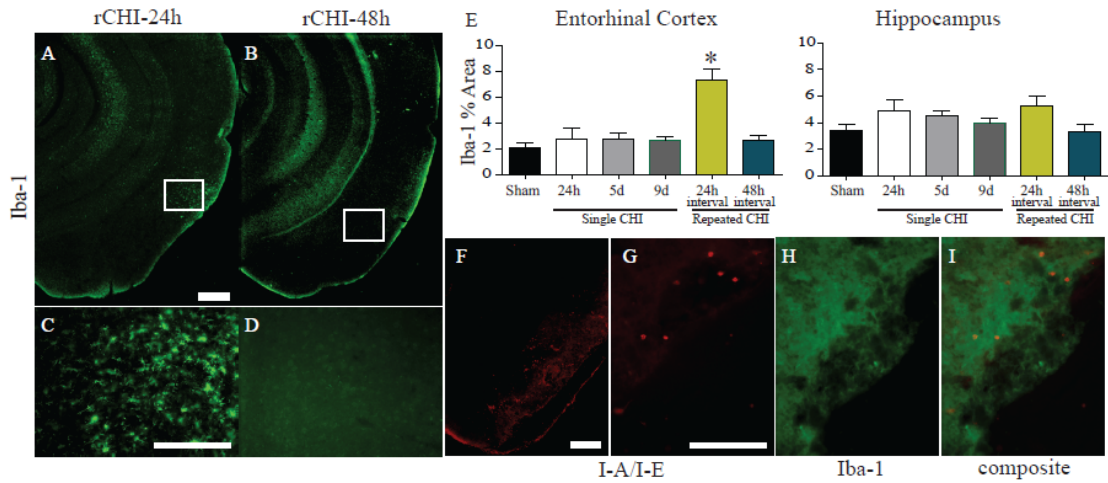
Figure 2.9: Astrocytosis in the cerebellum and brainstem after repeated closed head injury (CHI).

Immunohistochemical labeling of glial fibrillary acidic protein (GFAP) after sham CHI indicated a baseline level of immunostaining in the Purkinje cell layer of the cerebellum (A, D) and in the brainstem (G, J). When five CHI were repeated at 24h intervals (rCHI-24h) reactive astrocytosis was observed throughout the cerebellum, with the greatest hypertrophy occurring in the molecular and granular layers of the lateral cerebellar folia (B, E). Following five CHI repeated at 48h intervals (rCHI-48h) reactive astrocytosis was not as robust and was focused in the lateral cerebellar folia (C, F). Astrogliosis was more pronounced in the brainstem after rCHI at 24h intervals (H, K) than at 48h intervals (I, L). Scale bars =500 μ m in A-C, G-I, J-L; 250 μ m in D-F. n=5-6 for single CHI groups, n=7-8 for rCHI groups, and n=7 for sham-injured group.

Microglia are Activated by CHI Repeated at 24h but not 48h Intervals

In an uninjured mouse, Iba-1 mostly labeled small, uniform microglia cell bodies and very thin processes. Microgliosis was observed as morphological changes to Iba-1 labeled cells such as swelling of the cell bodies and enlarged Iba-1-positive processes. Microgliosis, measured via the percent area occupied by Iba-1 immunolabeling, was not increased at 24h, 5d, or 9d after single CHI compared to sham injury in either the entorhinal cortex or the hippocampus (Figure 2.10E). However, following rCHI at 24h intervals, microglial cell bodies and processes in the entorhinal cortex appeared swollen (Figure 2.10A, C). The percent area of Iba-1 labeled microglia was increased in the entorhinal cortex ($p < 0.0001$ compared to all other groups; Figure 2.10E) but not in the hippocampus ($p > 0.05$). rCHI repeated at 48h intervals did not induce significant microgliosis (Figure 2.10B, D) in the entorhinal cortex or hippocampus when compared to sham injury or single CHI ($p > 0.05$; Figure 2.10E).

I-A/I-E (MHC II) has been used as a marker for activated microglia (de Hoz, Gallego et al. 2013), but mild CHI did not induce microglial expression of MHC II after injury as evidenced by the lack of co-expression with Iba-1 (Figure 2.10I). Instead, in areas of hemorrhage, I-A/I-E appeared to label macrophages that had infiltrated the brain due to blood-brain barrier breakdown (Figure 2.10F, G). I/A-I/E labeled cells also lined the ventricles in all groups (data not shown).



Repeated CHI does not Induce Acute Tau Hyper-Phosphorylation

Immunohistochemistry with PHF-1 did not reveal qualitative increases in hyper-phosphorylated tau in the cortex or hippocampus in any injury group as compared to sham controls (data not shown).

Discussion

Many mild TBIs that occur every year can be attributed to recreational activities such as boxing and football where the risks of repeated concussions are increased. In this study we developed a mouse model of mild TBI by utilizing a cushioned midline impact to the closed skull. This model induced injury primarily to the entorhinal cortex and cerebellum with additional pathology in the brainstem with repeated impacts. By varying the programmed depth of impact, a 2.0mm depth of impact was selected as an optimal injury severity, inducing acute physiological consequences and mild gliosis without skull fracture or overt cortical or hippocampal cell death. This is representative of the human condition in which loss of consciousness may occur after impact, but imaging analysis of the brain is typically unremarkable. We then demonstrated that five mild TBIs, at either a 24h or 48h inter-injury interval, resulted in apnea and righting reflex suppression that diminished with successive impacts. Despite the diminishing response, five CHI repeated at a 24h inter-injury interval amplified gliosis and increased neuronal degeneration and axonal injury compared to a single CHI. When the inter-injury interval between multiple head injuries was increased from 24h to 48h, the resultant histopathological consequences were similar to a single CHI.

Transient loss of consciousness of up to 30 minutes in duration occurs in human cases of mild TBI (CDC 2003). In mice, the righting reflex has been utilized for over fifty years to indicate loss of consciousness (Frank and Sanders 1963). While smaller impact depths did not significantly alter the righting reflex response, a 2.0mm depth single CHI produced a loss of consciousness of approximately 10 minutes, within the range representing mild TBI in rodent models (Dewitt, Perez-Polo et al. 2013). While

this reflex suppression is of longer duration than in some previous reports (2 to 5 minutes), most of these studies employed a toe/tail pinch response or other painful stimulus to assess consciousness (Longhi, Saatman et al. 2005; Prins, Hales et al. 2010; Shultz, Bao et al. 2012) which may result in more rapid return of responsiveness (Kubo, Nishikawa et al. 2009). Although anesthesia suppresses the righting reflex, we maintained a consistent duration of inhalant anesthesia throughout each surgery.

Apnea duration increased in a graded fashion as a function of impact depth. While apnea is not a typically noted feature of mild TBI in humans, apneic responses are common in rodent mild TBI models utilizing midline impact to the skull (Marmarou, Foda et al. 1994; Creed, DiLeonardi et al. 2011; Mouzon, Chaytow et al. 2012), and are substantially longer than apneic responses reported with lateral injury (Prins, Hales et al. 2010; Shultz, Bao et al. 2012). Whereas lateral impact may direct tissue deformation across midline as well as downward through deeper brain structures, midline impact likely directs tissue deformation towards the brainstem, transiently affecting neurons involved in respiration (Thibault, Meaney et al. 1992). In midline models of more severe TBI, animals require intubation to aid in respiratory efforts (Marmarou, Foda et al. 1994). While it is difficult to separate the potential effects of apnea from those of the mechanical insult, brief apnea in our model is unlikely to contribute significantly to pathology. Repeated apnea during obstructive sleep apnea has been implicated in memory dysfunction in humans and animal models, but only in severe cases involving upwards of 100 episodes of apnea every night, with each episode lasting seconds to minutes (Veasey 2012).

During a series of five concussions, loss of consciousness and apnea diminished with subsequent CHI to near sham control levels. Diminution of the righting reflex response and apnea occurred at a faster rate when the inter-injury interval was lengthened from 24h to 48h, suggesting an adaptive or protective mechanism was initiated by 48h but not 24h after CHI. Our findings corroborate a study by Mouzon and colleagues (Mouzon, Chaytow et al. 2012) in which apnea duration diminished with repeated midline mild TBI in mice. However, they are in contrast with other studies demonstrating increased or sustained apnea duration or righting reflex responses across repeated mild TBIs (DeFord, Wilson et al. 2002; Creeley, Wozniak et al. 2004; Prins, Hales et al. 2010; Mouzon, Chaytow et al. 2012; Shultz, Bao et al. 2012). Differences in the impact device, impact tip characteristics, severity of injury, location of injury, or anesthesia may contribute to these disparate observations. Further investigation is needed to understand the evolution and underlying mechanisms of righting reflex suppression and apnea responses with repeated mild TBI. However, our data raise an interesting question as to whether people adapt to repeated concussions in terms of their acute physiological responses. That is, in response to an equivalent concussive insult would athletes such as boxers who receive many blows to the head over the course of their careers exhibit different symptoms from individuals with no prior concussions? If symptomatology decreases with multiple concussions, the severity and potential consequences of any given head injury could be underappreciated.

Historically, models of mild TBI produced some degree of neuron degeneration (for review, see (Dewitt, Perez-Polo et al. 2013)) which was observed early after injury, suggesting a transient wave of cell death (Creed, DiLeonardi et al. 2011). With the

growing interest in repeated concussions, injury parameters have been modified to greatly reduce or eliminate cell death as a feature of a single (Huh, Widing et al. 2007; Meehan, Zhang et al. 2012) or repeated mild TBI (DeFord, Wilson et al. 2002; Shitaka, Tran et al. 2011; Meehan, Zhang et al. 2012). However, many of these studies used relatively insensitive measures such as Nissl staining to assess cell death. In our model, following a single 2.0mm, midline CHI, no overt cell loss was observable with Nissl staining, but a small amount of acute neuron degeneration in the entorhinal cortex and Purkinje cell layer of the cerebellum was detectable with FJC. When CHI was repeated at a 24h inter-injury interval, the number of FJC labeled neuron cell bodies increased and a hemorrhagic lesion developed in the entorhinal cortex. Worsening of cell loss, cortical thinning or the development of a lesion with repeated as compared to single TBI has been reported (Huh, Widing et al. 2007; Mouzon, Chaytow et al. 2012; Shultz, Bao et al. 2012), but these observations were qualitative or semi-quantitative and did not use neuron-specific markers for acute degeneration. Longhi et al. (Longhi, Saatman et al. 2005) noted that acute cortical neurodegeneration was qualitatively equivalent following one and two CHI at a 3d interval. We examined shorter intervals and provide quantitative data to demonstrate that lengthening the inter-injury interval from 24h to 48h prevents exacerbation of neuronal death in the entorhinal cortex, indicating that the initial cellular dysfunction was reversible within 48h after injury. To our knowledge, this is the first report quantifying the effects of repeated mild TBI and time interval variations on the accumulation of degenerating neurons. Hence, we provide a model in which multiple injuries may convert sub lethal neuronal damage to neuronal degeneration, an important platform for investigating both neuronal and axonal vulnerability to mild TBI.

Interestingly, increased acute cell death was not observed in the cerebellum, which may point to unique damage mechanisms or to accelerated degeneration that was not captured using FJC staining. Further evaluation of long-term neuron damage, including stereological cell counts, is necessary to more fully understand the degree of neuron death in the entorhinal cortex and cerebellum.

Axonal injury is a common feature of mild diffuse TBI which is typically exacerbated with repeated injuries (Laurer, Bareyre et al. 2001; Huh, Widing et al. 2007; Friess, Ichord et al. 2009; Prins, Hales et al. 2010; Fujita, Wei et al. 2012). In the present study, single CHI produced mild axonal injury in the entorhinal cortex and the cerebellum, a distribution unique from other mild TBI models which most commonly report subcortical white matter tract damage (Laurer, Bareyre et al. 2001; Longhi, Saatman et al. 2005; Huh, Widing et al. 2007; Prins, Hales et al. 2010; Creed, DiLeonardi et al. 2011). It is not clear why midline impact did not result in subcortical white matter axonal injury as detected by APP immunostaining or FJC staining, but future studies will utilize alternative detection techniques such as silver staining that may be more sensitive or detect alternative phenotypes of axonal injury (Shitaka, Tran et al. 2011). TBI repeated at a 24h interval did not significantly increase the number of APP-positive axons in the entorhinal cortex, but axonal swellings appeared larger, which may point to a functional distinction. While the size of axonal swellings has been reported to correlate with survival time (Wilkinson, Bridges et al. 1999), larger swellings in the rCHI-24h group cannot be solely attributed to longer survival, because equivalent swellings were not observed in single CHI groups with matched survival times. In contrast, rCHI at a 24h interval resulted in a marked enhancement of cerebellar axonal injury and the

appearance of diffuse axonal damage in the brainstem. The development of axonal injury after repeated but not after single mild TBI has been reported in the brainstem (Fujita, Wei et al. 2012; Mouzon, Chaytow et al. 2012) and the thalamus (Huh, Widing et al. 2007) in other midline CHI models and could indicate that one mild TBI triggers axonal dysfunction that only evolves into APP-positive pathology with repeated injury. When mild TBI were repeated at 48h inter-injury intervals, axonal injury in the entorhinal cortex was similar to that in mice examined 9 days after a single CHI and degenerating axons in the cerebellum and brainstem were observed less frequently than in the rCHI-24h group. These data suggest that longer intervals between mild TBI protect against exacerbation of axonal injury, as has been shown by Povlishock and colleagues (Fujita, Wei et al. 2012). Combined, our data supports the hypothesis that repeated mild TBIs, within a certain time frame, can induce and/or accelerate axonal injury.

While the cellular mechanisms for transient neuronal vulnerability to repeated mild TBI are not well understood, dynamic changes in cell membrane permeability, glutamate release, calcium regulation and mitochondrial function may play roles. Decreased cerebral glucose metabolism has also been proposed as the underlying cause of vulnerability to a second TBI (Prins, Alexander et al. 2013). The interplay between neurons and reactive glia after trauma further complicates identification of causative cellular mechanisms.

Upon a traumatic event, astrocytes become reactive and initiate protective repair mechanisms in order to restrict tissue damage by repairing any blood-brain-barrier breakdown (Bush, Puvanachandra et al. 1999) and aid in synaptogenesis (Diniz, Almeida et al. 2012). A single CHI of 2.0mm or less resulted in very mild, progressive

astrogliosis, as in other rodent models of single CHI (Hellewell, Yan et al. 2010; Mouzon, Chaytow et al. 2012). When mild TBIs were repeated at 24h inter-injury intervals astrocytosis was enhanced in the entorhinal cortex, cerebellum, and brainstem, corroborating previous reports of increased astrogliosis with repeated compared to single mild TBI (Mouzon, Chaytow et al. 2012; Luo, Nguyen et al. 2014). What remains unclear, however, is whether exacerbated astrocytosis is neuroprotective or detrimental to the surrounding neurons. Astrocytes are responsible for the reuptake of glutamate from the synaptic cleft but, after a contusion injury, glutamate transporters are downregulated enhancing excitotoxicity within the synaptic cleft (Rao, Baskaya et al. 1998). Future studies will examine the persistence of the glial response following repeated CHI and its relationship to initial and ongoing neuronal damage.

Similar to astrocytosis, microglial reactivity has been noted in rodents after single and repeated mild TBI, primarily in the cortex below the site of impact, corpus callosum, and hippocampus acutely after injury (Shitaka, Tran et al. 2011; Mouzon, Chaytow et al. 2012; Shultz, Bao et al. 2012) and as long as two (Shultz, Bao et al. 2012) and 12 months (Mouzon, Bachmeier et al. 2014) after injury. In this study, microglial reactivity was not evident over a 9d period after a single CHI or acutely after rCHI at a 48h interval. However, rCHI at a 24h interval significantly increased entorhinal cortex microgliosis. In contrast, Mouzon et al. (Mouzon, Chaytow et al. 2012) demonstrated that five mild TBIs at 48h intervals increased microgliosis in the cortex and corpus callosum within 24h after the final injury. However, the injury paradigm used by Mouzon et al. induced microgliosis after a single mild TBI, while our model produced microgliosis only with repeated concussions, suggesting that our single CHI may represent a milder initial

injury. Microglia activation was observed in the entorhinal cortex in concert with axonal injury and neuronal degeneration. Upon activation, microglia release many cytokines and chemokines that signal the onset of an inflammatory cascade. Depending upon the levels of these various signaling molecules after trauma, microglia can develop phenotypes promoting either cell death or tissue repair (Ziebell and Morganti-Kossmann 2010). Further investigation into microglial cytokine/chemokine expression between repeated insults and chronically after repeated mild TBI is needed to better understand whether microglia aid or antagonize neuronal repair after repeated traumatic insults.

The combination of neuroglial responses in the hippocampus, entorhinal cortex, cerebellum and brainstem in our CHI model is distinctive, as most mild TBI models create cellular damage in the sensory and motor cortices near the impact site, the corpus callosum and/or the hippocampus. The entorhinal cortex, in conjunction with the hippocampus, is involved in the memory circuit. Bilateral electrolytic lesions of the entorhinal cortex have been shown to induce deficits in memory and learning (Hardman, Evans et al. 1997). Thus, in our model of repeated mild TBI, bilateral entorhinal cortex neurodegeneration coupled with hippocampal gliosis may facilitate the investigation of posttraumatic memory deficits. Bilateral damage of the cerebellum and brainstem axonal injury may have functional implications for complex motor coordination and balance. Thus, future work should determine whether repeated CHI with this model results in behavioral dysfunction. The present study was limited to the evaluation of acute physiological and histopathological changes. Because repeated mild TBI is believed to be a risk factor for or cause of neurodegenerative diseases such as Alzheimer's disease or

chronic traumatic encephalopathy (McKee and Robinson 2014), it will be important to examine long-term histological consequences of repeated mild TBI in this model.

In conclusion, as compared to a single mild TBI, mild TBIs repeated at a 24h interval resulted in greater neuron degeneration, axonal injury, astrogliosis and microgliosis throughout caudal regions of the mouse brain. These increased tissue responses were not simply due to the greater number of impacts, as five concussions induced at 48h intervals did not increase neuron death or gliosis as compared to a single injury. Additional studies are needed to identify cellular and molecular factors contributing to the transient vulnerability to repeated mild TBI. Enhanced neuropathological changes associated with repeated head injuries were evident despite diminishing acute physiological responses to successive impacts. These data support the need to supplement symptomatic analysis of mild TBI with assessment of brain pathology through the use of imaging, biomarkers or other technologies.

Acknowledgements

PHF-1 was a generous gift from Dr. Peter Davies.

CHAPTER 3: Repeated Closed Head Injury in Mice Results in Sustained Motor
and Memory Deficits and Chronic Cellular Changes

Preface

For the following chapter, study design and interpretation of results were conducted by Amanda Bolton Hall and Kathryn Saatman. Surgery procedures, tissue processing, immunohistochemistry of cerebrum tissue, histological analyses of all cerebrum tissue, analysis of behavioral data, and statistics were performed by Amanda Bolton Hall. Behavioral testing and silver staining of cerebrum tissue was conducted by Jennifer Brelsfoard. Optic nerves were processed, labeled using immunohistochemistry and analyzed by Binoy Joseph.

Introduction

An estimated 3.8 million people in the United States sustain a traumatic brain injury (TBI) every year, resulting in 60 billion dollars in annual healthcare costs (Langlois, Rutland-Brown et al. 2006; Faul M 2010). Approximately 80% of TBIs are classified as “mild” head injuries (Kraus and Nourjah 1988; Tellier, Della Malva et al. 1999; Harmon, Drezner et al. 2013), and often result in one or more symptoms such as nausea, dizziness, and/or headaches (Makdissi, Darby et al. 2010; Meehan, d'Hemecourt et al. 2010; Marar, McIlvain et al. 2012; Harmon, Drezner et al. 2013). Memory loss, motor coordination deficits, vision impairment, anxiety, and/or irritability have also been observed after mild TBI (Harmon, Drezner et al. 2013; McCrory, Meeuwisse et al. 2013). Most mild TBI patients are discharged within 48h after their head injury (Rimel, Giordani et al. 1981; Syed, Lone et al. 2007), encouraged to rest and removed from activities that are a high risk for subsequent TBI until any and all symptoms have ceased (Giza, Kutcher et al. 2013). However, the time necessary for all symptoms of mild TBI to subside can range from 1 week (McCrea, Barr et al. 2005; McCrory, Makdissi et al. 2005; Meehan, d'Hemecourt et al. 2010; Marar, McIlvain et al. 2012) to months (Rimel, Giordani et al. 1981) or even a year (McMahon, Hricik et al. 2014). Varied responses to mild TBI and insufficient evidence correlating symptom presentation to cellular injury make it difficult to determine the brain's period of vulnerability after a head injury. A repeated head injury occurring before the brain fully recovers can induce a phenomenon known as second impact syndrome causing hyperemia, intracranial hypertension and even death (Laurer, Bareyre et al. 2001). In less severe cases, individuals who have suffered two mild head injuries have been reported to perform worse on information processing tasks compared

to individuals who sustained a single mild head injury (Gronwall and Wrightson 1975). Increasing evidence suggests that repeated mild TBI may be associated with changes in mood, cognition, and motor coordination over months to years and may develop into a condition now known as Chronic Traumatic Encephalopathy (CTE) (Martland 1928; McKee, Cantu et al. 2009). However, the mechanism of injury and the role that repeated insults play in the development of pathology and behavioral consequences that associate with CTE is limited by (a) the sample size of confirmed human cases, (b) the accuracy of injury assessment and acquired behavioral histories from the patients and/or their families, and (c) the snapshot of disease progression at death.

Numerous studies have shown that multiple injuries in close succession result in worsened behavioral function and/or histopathology compared to a single mild TBI (Laurer, Bareyre et al. 2001; DeFord, Wilson et al. 2002; Longhi, Saatman et al. 2005; Huh, Widing et al. 2007; Shitaka, Tran et al. 2011; Bennett, Mac Donald et al. 2012; Fujita, Wei et al. 2012; Kane, Angoa-Perez et al. 2012; Meehan, Zhang et al. 2012; Shultz, MacFabe et al. 2012; Prins, Alexander et al. 2013; Bolton and Saatman 2014; Cheng, Craft et al. 2014; Mouzon, Bachmeier et al. 2014; Petraglia, Plog et al. 2014; Weil, Gaier et al. 2014; Nichols, Deshane et al. 2016). Lengthening the inter-injury interval, or period of rest between injuries, typically limits brain damage and or dysfunction following repeated mild TBI (Longhi, Saatman et al. 2005; Friess, Ichord et al. 2009; Fujita, Wei et al. 2012; Meehan, Zhang et al. 2012; Mannix, Meehan et al. 2013; Prins, Alexander et al. 2013; Bolton and Saatman 2014; Weil, Gaier et al. 2014; Semple, Lee et al. 2015). In our mouse model of mild TBI which impacts directly onto the intact skull, closed head injuries (CHI) repeated at 24h intervals produced increased

neuronal death and axonal injury, enhanced astrogliosis, and induced microgliosis in several brain regions including the hippocampus, entorhinal cortex and cerebellum compared to single CHI or sham injury (Chapter 2). These data are consistent with other studies of repeated mild TBI at 24h inter-injury intervals which report axonal injury (Laurer, Bareyre et al. 2001; Shitaka, Tran et al. 2011), astrocytosis (Uryu, Laurer et al. 2002; Kane, Angoa-Perez et al. 2012; Mannix, Meehan et al. 2013; Luo, Nguyen et al. 2014; Zhang, Teng et al. 2015), and microgliosis (Shitaka, Tran et al. 2011; Shultz, Bao et al. 2012; Mannix, Meehan et al. 2013) in the brain. Although similar pathological consequences have been described with repeated mild TBI at 48h inter-injury intervals (Mouzon, Chaytow et al. 2012; Ojo, Mouzon et al. 2013; Mouzon, Bachmeier et al. 2014; Tzekov, Quezada et al. 2014), 24h and 48h inter-injury intervals have not been previously compared within a single study, with the exception of our acute histopathology study (Chapter 2). In our model, extending the inter-injury interval between CHI from 24h to 48h significantly reduced the amount of acute cell death and inflammation (Chapter 2), supporting the hypothesis that a longer period of rest between head injuries allows the brain to recover and reduces the potential for exacerbation of the secondary injury cascade.

Both 24h and 48h inter-injury intervals have been separately reported to induce transient motor impairment (Laurer, Bareyre et al. 2001; Mouzon, Chaytow et al. 2012; Zhang, Teng et al. 2015) and persistent cognitive deficits for as long as a year after injury compared to sham injured mice (Meehan, Zhang et al. 2012; Mouzon, Bachmeier et al. 2014), but have not been compared within in the same study. We hypothesized that five repeated mild TBI at 24h inter-injury intervals would induce behavioral deficits and

result in persistent inflammation and secondary injury out to ten weeks. In addition, we anticipated that lengthening the inter-injury interval to 48h would lessen long-term behavioral deficits and neuropathology.

Materials and Methods

Animals

Two- to 3-month old male C57BL/6 mice were purchased from Jackson Laboratories (Bar Harbor, ME). Upon arrival, mice were group housed under a controlled 14:10h light: dark cycle and provided mouse chow and water *ad libitum*. Animal husbandry and all surgical procedures were approved by the University of Kentucky Institutional Animal Care and Use Committee and followed the federal guidelines set by the Institute of Laboratory Animal Resources (U.S.) and Committee on the Care and Use of Laboratory Animals.

Repeated Closed Head Injury

Experimental CHI was induced following a previously described procedure (Chapter 2). Mice were anesthetized with 2.5% isoflurane delivered via a nose cone, and the head of each mouse was fixed between two zygomatic bars stabilized in a stereotaxic frame. The incision site was cleaned with 70% ethanol and betadine and local analgesia was achieved by subcutaneous injection of 0.2ml 1:200,000 epinephrine and 0.5% bupivacaine (Henry Schein Animal Health, Dublin, OH) in sterile, normal saline prior to scalp reflection. A pneumatically controlled cortical impact device (TBI-0310 Impactor, Precision Systems and Instrumentation, Fairfax Station, VA) with a 5mm diameter, cushioned tip of 55 Shore A hardness was programmed to deliver a 2.0mm impact at 3.5m/s with a 500ms dwell time. The impactor was aligned to the skull directly over the midline suture. The posterior edge of the tip was aligned at the lambda suture (approximately Bregma level -5mm). The diameter of the tip (5mm) is such that the anterior edge of the tip meets the bregma suture (0mm Bregma level). Subsequent

injuries were induced at the same location. This impact was previously characterized such that a single injury would result in minimal gliosis and cell death without resulting in skull fracture (Chapter 2). Immediately after impact, mice were removed from the stereotaxic device and placed onto their backs on a heating pad. Apnea duration and the time to spontaneously right to a prone position (righting reflex) were assessed. Upon righting, mice were briefly re-anesthetized to suture the scalp using vicryl sutures containing antibiotics (Ethicon, Cincinnati, OH). After suturing, 1ml of sterile saline was delivered subcutaneously to increase hydration after the injury. Sham-injured animals underwent identical anesthesia and surgical procedures without receiving an impact.

All mice were monitored on a heating pad until they became ambulatory. Additionally, mice were evaluated to 1-3h and 24h after each injury, followed by weekly inspections. Mice were rated to have no (0), mild (1), moderate (2), or severe (3) pain as indicated by locomotion in their home cage, pain on palpation of surgery site, behavioral abnormalities, and the appearance of the incision. Examples of pain responses included hunched posture, tenderness at the site of the incision, audible vocalizations, stumbling and/or hugging the cage. Humane endpoints were in place for mice scoring moderate or severe in at least one category, or mild in more than one category. In addition, all mice were required to maintain 85% of their starting weight in order to receive each subsequent head injury. However, no mice in the current study met either criteria for being removed from the study.

For all experiments, mice were randomized into three groups. The first injury group received five CHI, one every 24h (rCHI-24h; n=10), whereas the second injury group received five CHI, one every 48h (rCHI-48h; n=10). A third group consisted of

sham CHI repeated every 24h for five days (sham; n=10). We showed previously that sham-injured animals with anesthesia repeated at either 24h or 48h intervals were not significantly different based on histology (Chapter 2); therefore, only one sham control group was utilized. One mouse assigned to the rCHI-24h group and one mouse assigned to the rCHI-48h group did not recover from their apneic episode after an injury, resulting in an n of 9 for each of these groups.

Behavioral Analysis

Beam Walking

The beam walking test has been modified from our previously described protocol with the controlled cortical impact (CCI) model (Schoch, Evans et al. 2012; Madathil, Carlson et al. 2013), which utilized four beams of varying widths to examine motor coordination after injury. Only the narrowest beam and rod were utilized in this study to enhance sensitivity as a milder deficit was anticipated. Prior to injury, mice were acclimated to beam walking using a 3cm width Plexiglas beam. Twenty-four hours after the final injury or sham procedure, mice were scored on their ability to walk across a 0.5cm width, Plexiglas beam and a 0.5cm diameter, wooden dowel rod. Mice received 3pts for walking across the beam without having a foot slip or inverting on the beam. One point was deducted if one or more foot slips occurred, an additional point was deducted if the animal inverted under the beam, and a score of zero was given if the mouse fell off the beam or could not cross. On the rod, a maximum score of 2pts was given for walking across the rod; a point was deducted if mice inverted more than two times while crossing, and a score of zero was given if the mouse fell off the rod or could not cross. These tasks

were repeated on the following testing days: 3d, 10d, 17d, 24d, 6wk, 8wk, and 10wk. For correlations with histological quantifications, the average beam walking score across the ten week period was used.

Novel Object Recognition

The novel object recognition (NOR) test has been previously established in our lab and others to test cognition after TBI in rodents (Prins, Hales et al. 2010; Schoch, Evans et al. 2012; Madathil, Carlson et al. 2013). Prior to injury, mice were acclimated to a 10.5" x 19" x 8" plastic box for one hour. Eight days after the final injury or sham procedure, mice were placed back into their individual testing box and allowed to explore two identical objects placed in opposite corners for five minutes. Four hours later, mice were placed back into their testing cage for five minutes with one of the previously explored objects and a novel object. The amount of time spent exploring each object was recorded. Additional time in the testing box was allowed to ensure a total object exploration time of at least ten seconds. Three mice (two rCHI-48h, one rSHAM) required an extra 1-3 minutes on the first testing day. Recognition Index was calculated as the time spent exploring the novel object divided by the combined familiar and novel object exploration times, and was expressed as a percentage. For each additional testing day at 2wk, 4wk, 8wk, and 10wk post-injury, mice were returned to their testing cage for five minutes to explore a distinct novel object and the same familiar object.

Gait Analysis

On the third day following the final injury, mice were placed in a Digigait box with a clear treadmill belt (Mouse Specifics, Inc., Framingham, MA). A camera positioned underneath the belt recorded the ventral aspect of the mouse. The belt was set

to 15cm/s, a speed which required the animals to continuously walk. Five consecutive seconds of video in which the mouse moved within the same frame were utilized for analysis. This task was repeated at 1mo after injury. The videos were then analyzed with the Mouse Specifics software using established protocols to measure gait and paw placement (Amende, Kale et al. 2005; Springer, Rao et al. 2010).

Tissue Processing

Following the final behavioral test, mice were euthanized by intraperitoneal injection of Fatal Plus (130mg/kg, Henry-Schein Animal Health, Dublin, OH) before transcardial perfusion with cold, heparinized sterile saline followed by cold, 4% paraformaldehyde (PFA) for ten minutes. After perfusion, mice were decapitated and the heads placed into vials of 4% PFA for 24h. The brains and optic nerves were then removed from the skull and post-fixed in 4% PFA for an additional 24h. Following post-fixation, tissue was placed into 30% sucrose in 1X-Tris-buffered saline (TBS) for 48h for cryoprotection. The brain tissue was frozen in -25 to -35°C isopentane before being cut into 40µm thick coronal sections using a sliding microtome (Dolby-Jamison, Pottstown, PA). For optic nerves, tissue was frozen in optimal cutting temperature compound (OCT) on the sliding microtome and cut into 10µm thick longitudinal sections. Tissue sections were stored at -20°C in 30% glycerol, 30% ethylene glycol in 1X TBS.

Histopathological Analysis

Histology

Silver staining was performed on a series of brain tissue which included 12 sections spaced at 400µm for the cerebrum and 200µm for the cerebellum/brainstem. The

FD NeuroSilver kit (FD NeuroTechnologies, Ellicott City, MD) was used with the following two modifications from the manufacturer's instructions: (1) for the step involving the mixture of solution C and F, tissue was placed into the solution 2x 2.5 minutes; (2) tissue was dehydrated sequentially in 70%, 80%, 95%, and 100% ETOH, and cleared in Xylenes prior to coverslipping.

Immunohistochemistry

A series of free-floating tissue sections spaced at 400µm apart were used for immunohistochemistry. For procedures utilizing 3,3'-diaminobenzidine, tissue sections were treated with 3% H₂O₂ in 50/50 methanol/ddH₂O for 30 minutes in order to quench endogenous peroxides. For all immunohistochemical protocols, tissues were blocked with 5% normal horse serum in 0.1% Triton X-100/1XTBS before incubation in primary antibody (Table 3.1) overnight at 4°C. On the following day tissue sections were rinsed and incubated in the appropriate secondary antibody (Table 3.1) for 1 hour. For Iba-1 labeled tissue, the tissue was washed after incubation in Alexa 488-conjugated secondary antibody, mounted onto gelatin-coated slides, and coverslipped using Fluoromount mounting media (Southern Biotech, Birmingham, AL). For all other protocols using biotinylated secondary antibodies, the tissue was washed before incubating in Avidin-Biotin complex (Vector Laboratories, Burlingame, CA) for 1 hour and then treating with 3,3'-diaminobenzidine as directed by the manufacturer (Vector Laboratories).

Table 3.1: Antibody List

Antibody Name	Public Identifier	Supplier	Cat # Log #	Clone & Host	Immunogen	Concentration	Validation study
Anti-ionized calcium-binding adaptor molecule 1	Iba-1	Wako Richmond, VA	019-19741 CTR-6026	Poly Rabbit	Synthetic peptide corresponding to C-terminus of Iba-1	1:1000	(Imai, Ibata et al. 1996)
Anti-gial fibrillary acidic protein	GFAP	Sigma-Aldrich St. Louis, MO	G9269 127K4807	Poly Rabbit	GFAP from human brain	1:1000	(Piccin and Morshead 2011)
Anti-cluster of differentiation-68	CD68	Bio-Rad Herclues, CA	MCA1957 0114	Mono FA-11 Rat	Purified concanavalin A acceptor glycoprotein from P815 cell line.	1:1000 (cerebrum); 1:500 (optic nerve)	(Ramprasad, Terpstra et al. 1996)
Anti-neurofilament protein-200	NF200	Sigma-Aldrich St. Louis, MO	N0142 017K4802	Mono Mouse	C-terminal segment of enzymatically dephosphorylated pig neurofilament 200	1:100	(Balaratna singam, Morgan et al. 2010)
Anit-paired helical filament-1	PHF-1	The Feinstein Institute Great Neck, NY	n/a	Mono Mouse	Soluble PHF	1:500	(Greenberg, Davies et al. 1992)
Donkey anti-rabbit IgG, Biotin-SP conjugate	Dk anti Rb IgG Biotin	Jackson Immuno West Grove, PA	711-065-152 11372	Mono Mouse	Whole IgG	1:1000	--
Donkey anti-rat IgG, Biotin-SP conjugate	Dk anti Rt IgG Biotin	Jackson Immuno West Grove, PA	712-065-153 106342	Polyl Donkey	Whole IgG	1:1000	--
Donkey anti-mouse IgG, Biotin-SP conjugate	Dk anti Ms IgG biotin	Jackson Immuno West Grove, PA	715-065-151 107570	Poly Donkey	Whole IgG	1:1000 (cerebrum); 1:500 (optic nerve)	--
Donkey anti-rabbit IgG, Alexa Fluor 488, conjugate	Dk anti Rb Alexa 488	Life Technologies Carlsbad, CA	A21206 1275888	Poly Donkey	Gamma immunoglobins heavy and light chains	1:2000	--

Quantification of Histology

All analyses were performed by an examiner blinded to the injury conditions of each animal.

In our previous study, inflammation was increased 24h following repeated mild TBI at 24h inter-injury intervals in the entorhinal cortex and hippocampus (Chapter 2). Therefore, GFAP immunoreactivity was analyzed at 10wks post-injury in the entorhinal cortices and hippocampi (4 sections/animal) and Iba-1 immunoreactivity was analyzed in the entorhinal cortices (4 sections/animal) as previously described [23]. In brief, GFAP and Iba-1 images were taken using an Olympus BX51 microscope with an ASI XY automated stage, and a montage of the images were created using Image Pro Plus software. For GFAP immunolabeling, the mean integrated optical density (IOD) of was measured and averaged across sections for statistical analyses. For Iba-1 labeling, an examiner chose the display range (between 0 and 255) that selected immunoreactive microglia for each tiled image. The percent area of Iba-1 immunoreactivity was measured and averaged for statistical analyses.

Silver-stained sections were viewed at 10x magnification using an Olympus BX51 microscope with an ASI XY automated stage. Images of the tissue were captured with the calibrated Stage-Pro module of Image Pro Plus (Media Cybernetics, MD) and assembled into a montage. Based on initial light microscopic evaluation of the cerebrum and brainstem, regions with notable positive staining were selected for quantitative analysis. In the cerebrum, the optic tract and peduncle were analyzed bilaterally in 2-3 sections/animal. In the brainstem, the pyramidal tract and adjacent grey matter were analyzed in two sections/animal. Each area of interest (AOI) was outlined using the

anatomical markers found in “The Mouse Brain in Stereotaxic Coordinates”, 4th Edition (Paxinos & Franklin). Utilizing the entire range of pixel densities (0-255), the mean density of each AOI was recorded. For each animal, the mean density was averaged across sections for each anatomical area for statistical analyses. Silver staining in the cerebellar lobes was evaluated qualitatively.

Following the observations in the optic and pyramidal tracts with silver stain, inflammation was also evaluated in these regions using immunohistochemical labeling of CD68 and GFAP for activated microglia or astrocytosis, respectively. For analysis, tissue sections were imaged using the Olympus BX51 microscope (10x) with a Q Imaging camera. Each AOI was outlined as described above. An examiner then chose the density range that selected immunoreactive microglia or astrocytes for each image. The percent of the total area which contained CD68 labeled microglia or GFAP labeled astrocytes were measured and averaged bilaterally for the optic tract across 2-3 sections/animal and for the pyramidal tract in 1 section/animal.

Neurodegeneration observed in the visual pathway prompted an evaluation of the optic nerves for axon loss and ongoing microgliosis. NF200 immunolabeling was used to visualize intact axons and CD68 immunolabeling was used to examine activated microglia. For quantitative analysis, each nerve was imaged using an Olympus AX80 microscope (10x) and a DP-70 camera. Several overlapping images were obtained to encompass the length of the optic nerve from the retina to the optic chiasm. These images were used to create a montage of the whole nerve in Adobe Illustrator CS6. The intensity threshold that detected labeled neurofilament protein or activated microglia was selected. The area of positive labeling was normalized to the AOI for statistical analyses.

PHF-1 labeled tissue was evaluated qualitatively. Brain tissue from a 3.5mo old rTg4510 tau mouse was used as a positive control for PHF-1 labeling (Spires, Orne et al. 2006).

Statistics

Analyses were completed using Graph Pad Prism 5 or Statistica 5.0 software. For apnea, righting reflex, and behavioral tests, a repeated measures 1-way ANOVA (time x injury group) was performed followed by post-hoc Newman-Keuls tests where appropriate. For each histological marker within each region, a 1-way ANOVA followed by post-hoc Newman-Keuls tests where appropriate was performed. For correlations between histological and behavioral outcomes, Spearman's correlation was performed, and Spearman's rho and corresponding p values are reported. All data are presented as means with standard error.

Results

Apnea and Righting Reflex

As in our previous report using this model of mild TBI (Chapter 2), both apnea duration and time to right increased in length after CHI and were maximal after the first injury, decreasing in duration with subsequent impacts (Table 3.2). For apnea duration there was a significant main effect of injury group ($p < 0.05$) and CHI number ($p < 0.05$) but the interaction between the two was not statistically significant ($p = 0.07$). Post-hoc comparisons among groups indicated that rCHI at either 24h or 48h increased apnea compared to sham injury (\$ indicates $p < 0.05$ compared to sham). In addition, post-hoc analysis for the main effect of CHI number demonstrated that apnea duration was highest after CHI 1 and CHI 2 (# indicates $p < 0.05$ compared to CHI 3, 4, and 5). Time to right after injury was significantly dependent on the injury group ($p < 0.05$) and the CHI number ($p < 0.05$; interaction $p < 0.05$). Post-hoc analyses revealed a significant increase in the time to right after the first CHI ($p < 0.05$ when compared to sham injury) and a trend toward an increase after the second impact in the rCHI-24h group ($p = 0.08$). Apnea duration and righting reflex were not significantly different between animals in the rCHI-24h and rCHI-48h groups. At this impact depth, CHI did not produce skull fractures in any mice.

Table 3.2. Apnea and Righting Reflex

		CHI 1	CHI 2	CHI 3	CHI 4	CHI 5
Apnea (sec)	rSHAM	# 0	# 0	0	0	0
	rCHI-24h	26 ± 7	21 ± 7	15 ± 6	8 ± 4	10 ± 2
	rCHI-48h	22 ± 4	21 ± 5	8 ± 3	11 ± 3	5 ± 2
Righting Reflex (min)	rSHAM	1:15 ± 0:04	1:11 ± 0:06	1:13 ± 0:05	1:21 ± 0:06	1:26 ± 0:05
	rCHI-24h	9:13 ± 2:46	\$ 6:03 ± 2:04	2:33 ± 0:29	1:49 ± 0:15	2:15 ± 0:15
	rCHI-48h	10:40 ± 2:28	\$ 5:35 ± 1:50	2:08 ± 0:28	2:05 ± 0:15	1:46 ± 0:11

Apnea and the time to flip to prone position (righting reflex) were recorded after each of five closed head injuries (CHI 1-5). \$ indicates p<0.05 compared to sham. # indicates p<0.05 compared to CHI 3, 4, and 5. n= 9-10/group.

rCHI Induces Persistent Memory Dysfunction

The novel object recognition (NOR) task was used to compare memory function among the rSHAM, rCHI-24h, and rCHI-48h groups at several time points across ten weeks (Figure 3.1A). In our hands, naïve and sham-injured mice spend about 70-75% of total exploration time on the novel object (Madathil, Carlson et al. 2013). Mice receiving repeated sham injury exhibited this same behavior with a recognition index of approximately 70%. Memory ability was dependent upon injury status ($p < 0.05$) but not time after injury ($p > 0.05$; Interaction, $p > 0.05$). CHI repeated at either 24h intervals or 48h intervals induced a persistent deficit in cognition across the testing period ($p < 0.05$ compared to rSHAM). Lengthening the inter-injury interval from 24h to 48h appeared to result in a milder initial cognitive deficit, but this difference was not sustained across the 10wk period ($p = 0.1$).

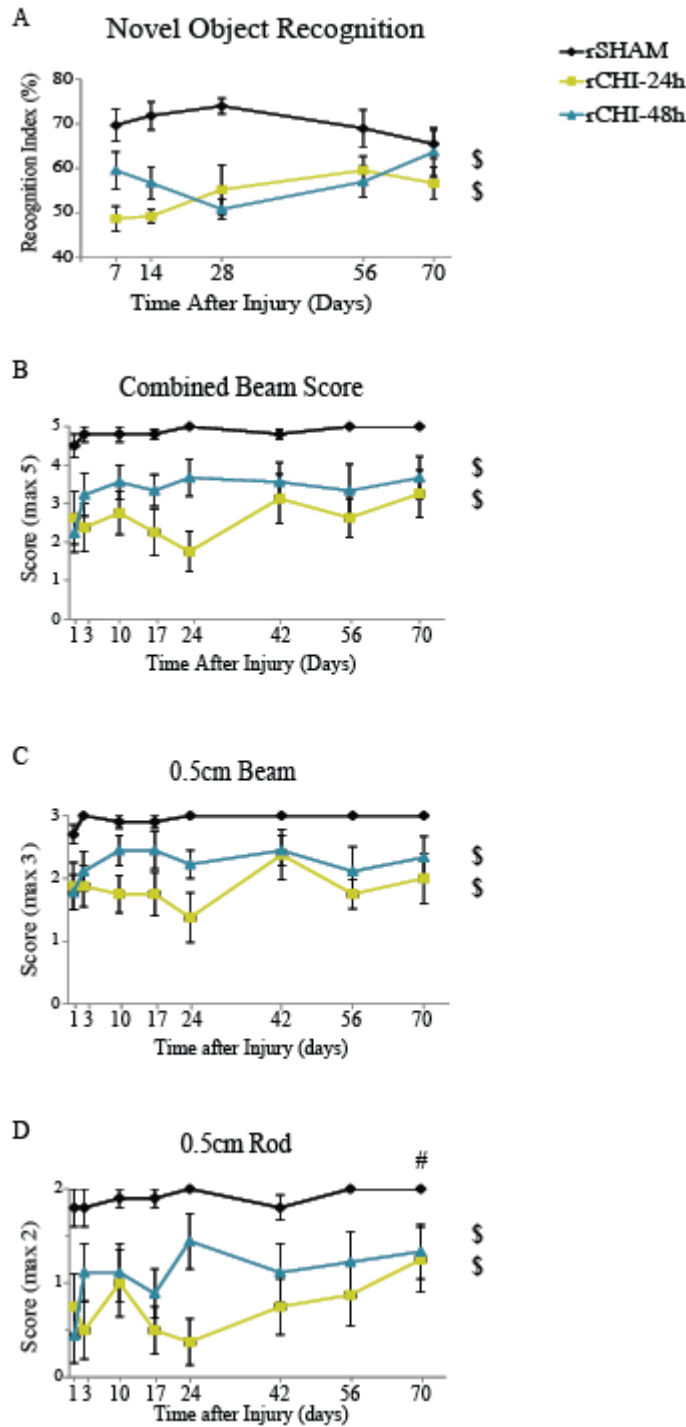


Fig 3.1: Repeated closed head injury (CHI) induced motor and memory deficits over ten weeks post-injury.

Behavioral testing was conducted following repeated sham (rSHAM), repeated CHI at a 24h interval (rCHI-24h), and repeated CHI at a 48h interval (rCHI-48h). (A) Memory scores in the novel object recognition task were calculated by dividing the time spent exploring the novel object by the total exploration time (recognition index). (B) The beam walking task was used to identify deficits in motor coordination. A score of 5 indicated perfect performance on the task, with lower scores indicating poorer motor skills. Component analysis for the beam walking task of (C) the 0.5cm Plexiglas beam and (D) the 0.5cm wooden dowel rod. \$ indicates significant difference from rSHAM ($p < 0.05$ post-hoc testing for main effect of injury). # indicates that performance across all groups was better at ten weeks compared to 24h ($p < 0.05$). $n = 9-10$ /group.

rCHI Induces Deficits in Motor Coordination with Beam Walking but not Gait Analysis

Following the final day of injury, mice were assessed on a beam walking task at several time points to examine deficits in motor coordination after rCHI (Figure 3.1B). Beam walking scores were dependent upon the injury group ($p < 0.05$) but not the amount of time after injury ($p > 0.05$; Interaction $p > 0.05$). Post-hoc testing among injury groups revealed that CHI repeated at either 24h intervals ($p < 0.05$) or 48h intervals ($p < 0.05$) produced significant motor deficits compared to sham injury. Although rCHI-24h appeared to result in a larger beam walking deficit than rCHI-48h across 10wks, this did not reach statistical significance ($p = 0.1$). To determine whether combining the beam and rod portions of the test masked subtle deficits better detected by one task, scores were analyzed separately (Figure 3.1 C, D). Individual analyses of the beam and rod corroborated the combined beam test, with rCHI at 24h and 48h intervals inducing significant motor deficits compared with sham injury. However, performance on the rod varied as a function of time, with significant recovery at 10wks compared with 24h post-injury (Figure 3.1D). To determine whether the motor deficit observed in rCHI animals might have been a result of the first impact and not a cumulative effect, we analyzed beam walking data from our previous acute CHI study (Chapter 2) in which mice were evaluated 2h and 24h after each impact. Two hours after a single CHI, mice ($n = 15$) scored an average of 1.8 ± 0.2 on the 0.5cm beam (maximum score of 3) and 1.8 ± 0.1 on the rod (maximum score of 2). By 24h after a single CHI, beam walking scores (2.8 ± 0.1 on the beam and 2.0 ± 0.0 on the rod) were comparable to those of sham mice,

suggesting a single CHI resulted in only mild transient motor dysfunction which resolved by 24h.

Gait coordination was assessed using a treadmill test (Digigait). Mice were tested three days after the final injury, as well as at 1 month after injury. A large number of parameters can be examined using the Digigait software. Results from analyses of gait symmetry, hindlimb shared stance, and paw area at peak stance are provided in Table 3.3. No significant differences were observed among groups in any parameter at either of the time points after injury.

Table 3.3. Digigait Analysis

Timepoint:	rSHAM		rCHI-24h		rCHI-48h		
	3d	1mo	3d	1mo	3d	1mo	
Gait Symmetry	0.90 ± 0.05	0.95 ± 0.07	0.97 ± 0.06	0.94 ± 0.05	0.97 ± 0.06	0.92 ± 0.05	
Hindlimb Shared Stance (sec)	0.13 ± 0.02	0.14 ± 0.02	0.13 ± 0.02	0.15 ± 0.03	0.12 ± 0.02	0.13 ± 0.03	
Paw Area at Peak Stance (cm ²)	Fore:	0.31 ± 0.02	0.28 ± 0.03	0.28 ± 0.03	0.26 ± 0.02	0.29 ± 0.03	0.26 ± 0.04
	Hind:	0.56 ± 0.07	0.52 ± 0.08	0.55 ± 0.07	0.47 ± 0.08	0.56 ± 0.08	0.52 ± 0.12

Gait symmetry, hindlimb shared stance, and paw area at peak stance 3d and 1mo following repeated sham (rSHAM), repeated CHI at a 24h interval (rCHI-24h), and repeated CHI at a 48h interval (rCHI-48h). n= 9-10/group.

Chronic Neurodegeneration after Mild TBI Irrespective of Inter-injury Interval

Conventional Hematoxylin and Eosin stain did not reveal contusion, hemorrhage or overt neuron death or atrophy (Figure 3.2). Silver stain was used to label neurons undergoing degeneration (de Olmos, Beltramino et al. 1994) and has been used previously to demonstrate axonal injury after closed head injury (Shitaka, Tran et al. 2011; Bennett, Mac Donald et al. 2012; Brody, Benetatos et al. 2015). In our hands, the staining yielded a copper-toned background with black particulates in the degenerating regions. No evidence of neurodegeneration in the neocortex, hippocampus, or corpus callosum was observed after repeated CHI or sham injury. However, repeated CHI induced bilateral degeneration in the pyramidal tract of the brainstem (Figure 3.3 B, C, E, F) and in the white matter regions of the cerebellar cruciform (Figure 3.3 J, K, M, N). The mean density of silver stain in the pyramidal tract (Figure 3.3A, solid outline) was normalized to the adjacent inferior olive (Figure 3.3A, dotted outline). While some animals (7 of 9 in rCHI-24h and 4 of 9 in rCHI-48h) exhibited pyramidal tract degeneration after repeated CHI, this effect did not reach statistical significance (ANOVA $p=0.052$; Figure 3.3G). As the pyramidal tract contains corticospinal axons involved in motor control, we postulated that persistent motor deficits might be related to the degree of pyramidal tract degeneration. However, the density of pyramidal tract silver staining in injured animals did not significantly correlate with their average beam walking score ($p>0.05$; $r= 0.12$; Figure 3.3H).

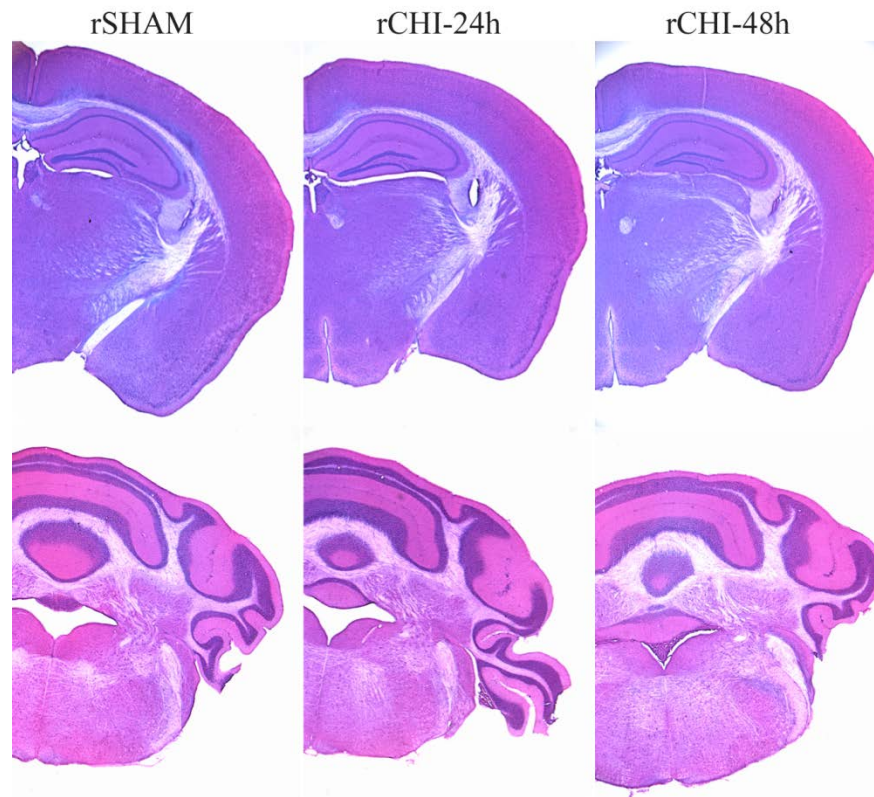


Figure 3.2: Hematoxylin and Eosin stain following repeated closed head injury (rCHI) or repeated sham injury (rSHAM). No overt cell loss was observed in the cerebrum (top panel) or cerebellum (bottom panel) of mice after rCHI at 24h or 48h inter-injury intervals compared to mice that received rSHAM injury. n= 9-10/group.

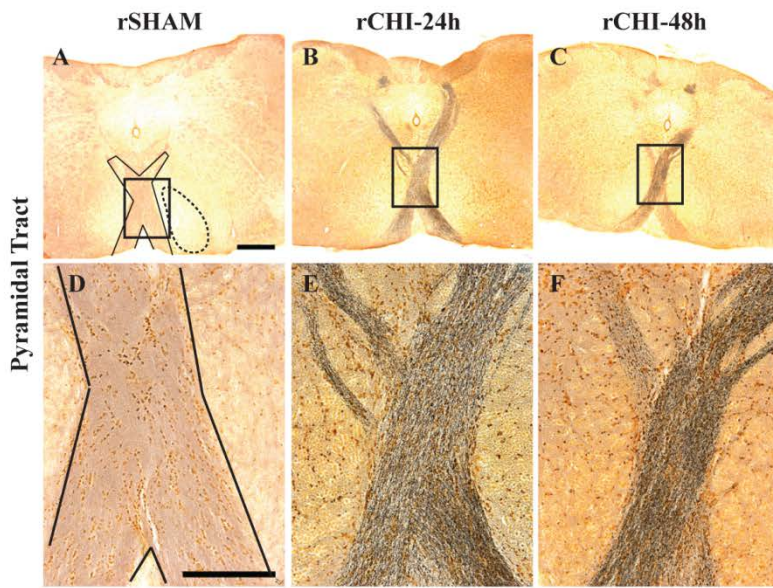
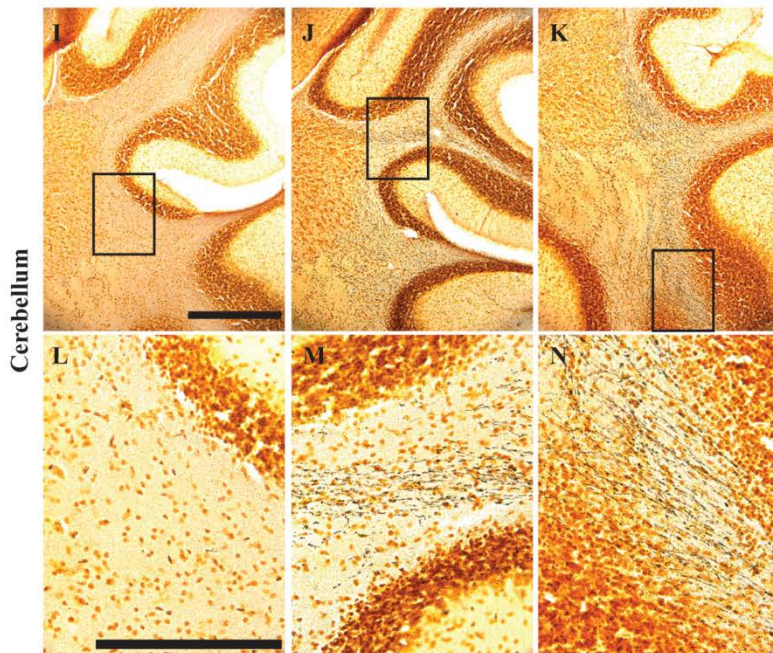
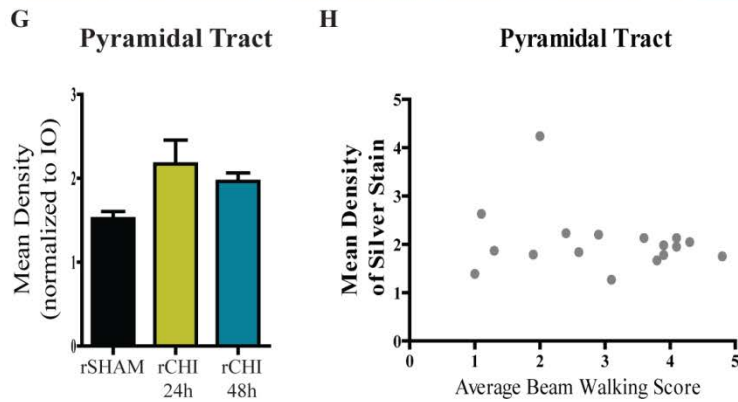


Figure 3.3: Repeated closed head injury (CHI) induced chronic axonal degeneration in the pyramidal tract and cerebellar cruciform.

Argyrophilic axons in the pyramidal tract (A-F) and cerebellar cruciform (I-N) were labeled using silver stain. Scale bars: 500 μ m A-C, I-K; 250 μ m D-F, L-N). The mean density of silver staining in the pyramidal tract (G) was normalized to background using adjacent stained areas. Correlation between pyramidal tract silver stain after repeated CHI and average beam walking score across ten weeks (H). n= 9-10/group.



In the cerebrum, axons within the optic tract were positively labeled with silver stain in repeated CHI (Figure 3.4 B, C, E, F) but not sham-injured (Figure 3.4 A, D) mice. The mean density of silver stain within the optic tract (Figure 3.4A, solid outline) was normalized to the thalamic peduncle adjacent to the optic tract (Figure 3.4A, dotted outline) to control for variation in background intensity across animals. Silver stain mean density in the optic tract of the rCHI-24h group ($p < 0.05$) and rCHI-48h group ($p < 0.05$) was significantly increased compared to rSHAM (Figure 3.4G). Optic tract silver staining was greater in the rCHI-48h group than the rCHI-24h group ($p < 0.05$). Neurodegeneration within the optic tracts as well as a recent study published by Tzekov and colleagues (Tzekov, Quezada et al. 2014) prompted us to evaluate the optic nerves of brain-injured animals for additional damage. In an uninjured or sham animal, axons stained positively for NF200, the heavy chain component of neurofilaments (Figure 3.4H). Damaged optic nerves, in contrast, exhibited loss of NF200 labeling (Figure 3.4 I, J), which was statistically significant for CHI repeated at either 24h or 48h intervals ($p < 0.05$ compared to sham; Figure 3.4K). The interval for induction of CHI did not significantly influence the loss of NF200 immunolabeling ($p > 0.05$).

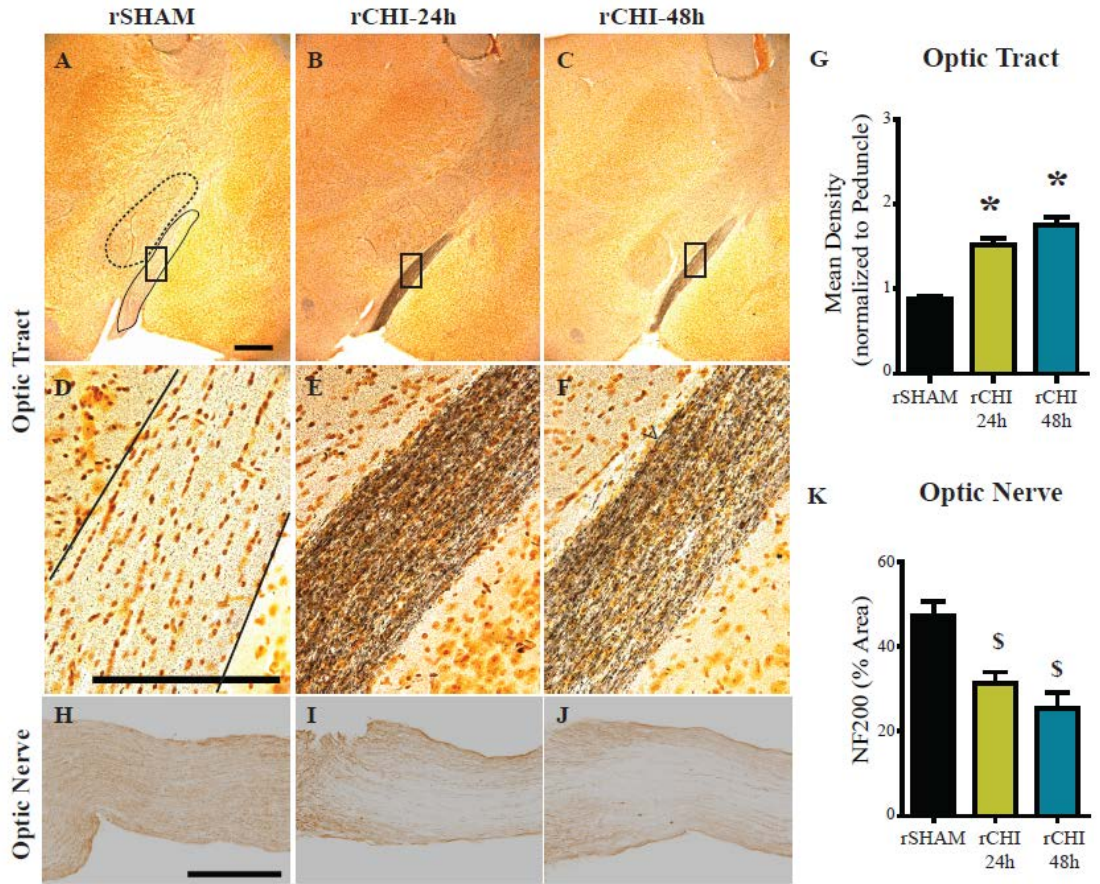


Figure 3.4: Repeated closed head injury (CHI) induced chronic axonal degeneration in the optic tract and optic nerve.

Argyrophilic axons in the optic tract (A-F) were labeled using silver stain. Scale bars: 500 μ m A-C; 250 μ m D-F. The mean density of silver staining in the optic nerve was normalized to background using adjacent stained areas (G). * indicates $p < 0.05$ compared to all other groups. Optic nerves (H-J) were labeled for neurofilament heavy chain (NF200) and the percent area of staining was quantified (K). Scale bars: 250 μ m H-J. \$ indicates $p < 0.05$ compared to sham. $n = 9-10$ /group.

Persistent Inflammation after Mild TBI in Optic Tract and Pyramidal Tract but not Entorhinal Cortex and Hippocampus

Microglia and astrocyte reactivity were measured in several brain regions by Iba-1/CD68 immunoreactivity and GFAP immunoreactivity, respectively. Iba-1 labels all microglia. However, morphological features were used to delineate ‘activated’ microglia from ‘inactivated’ or resting microglia. In contrast, CD68 selectively labels activated microglia which appeared with swollen cell bodies and thick processes.

Due to acute microgliosis and astrocyte activation previously noted in the entorhinal cortex and hippocampus 24h following repeated CHI (Chapter 2), these regions were analyzed at ten weeks post-injury. In the entorhinal cortex, only a few hypertrophic microglia were observed at 10wks post-injury. The vast majority of Iba-1 labeled microglia had a resting morphology with small cell bodies and thin processes (Figure 3.5 A-C). The area of Iba-1 labeled microglia relative to a defined area of interest was comparable across all groups ($p>0.05$; Figure 3.5J). Iba-1 labeled microglia in the hippocampi were observed qualitatively and no differences were observed among groups. GFAP-positive astrocyte cell bodies and processes in the entorhinal cortex and hippocampus of rCHI animals did not appear swollen or increased in number compared to those in rSHAM animals (Figure 3.5 D-I). When quantified, the mean GFAP IOD/astrocyte in the entorhinal cortex was comparable across all groups ($p>0.05$; Figure 3.5K). In the hippocampus, one animal in the rCHI-24h group had the highest mean IOD/astrocyte of 5.9. However, on average the groups were comparable to each other ($p>0.05$; Figure 3.5L).

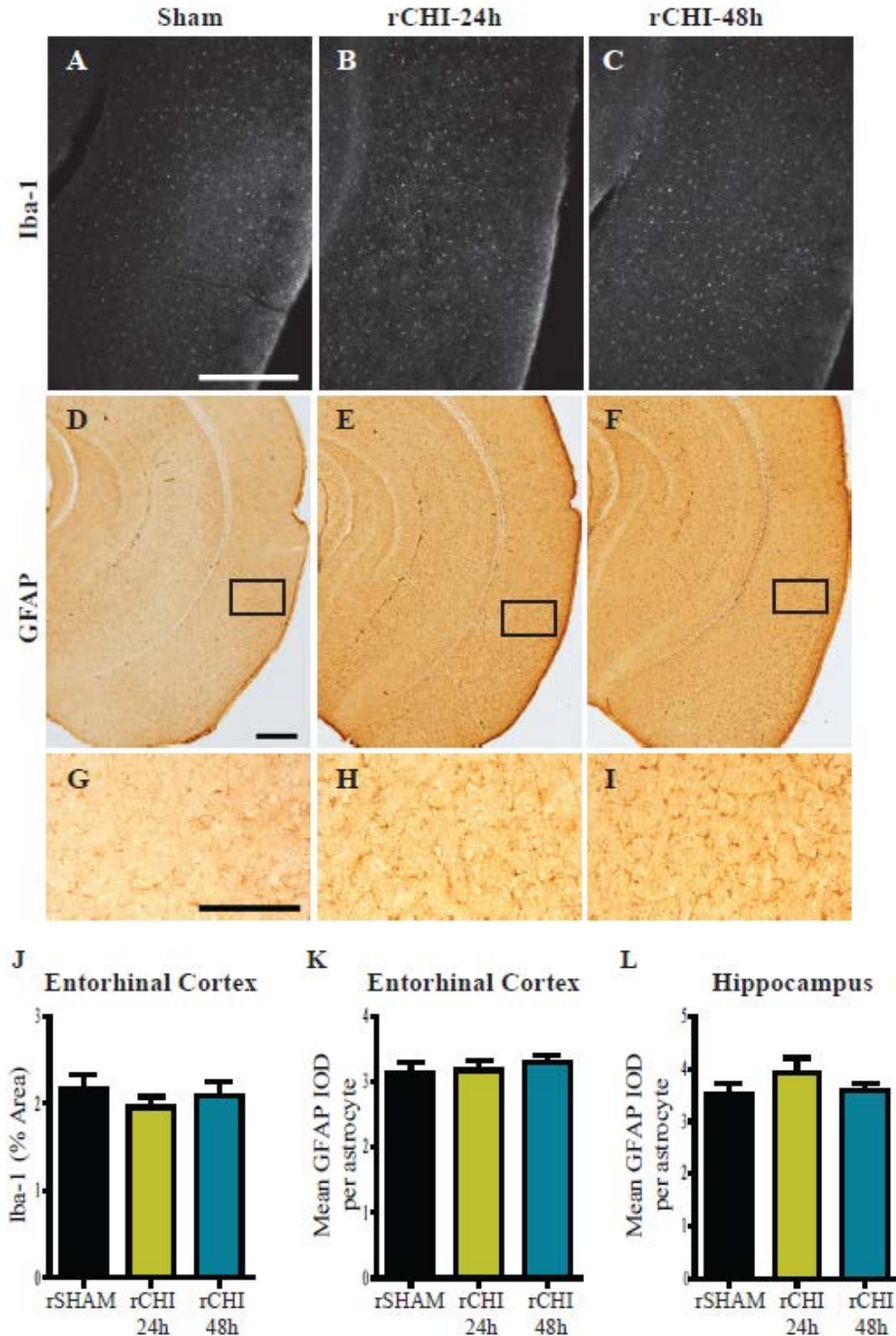


Figure 3.5: Inflammation did not persist in the entorhinal cortex or hippocampus ten weeks after repeated closed head injury (CHI).

Immunohistochemical labeling of ionized calcium-binding adaptor protein-1 (Iba-1; A-C) and glial fibrillary acidic protein (GFAP; D-I) in the entorhinal cortex and hippocampus after repeated sham (rSHAM), repeated CHI at 24h intervals (rCHI-24h), and repeated CHI at 48h intervals (rCHI-48h). Scale bars: 500 μ m A-F; 250 μ m G-I. The percent area of Iba-1 labeling was quantified for analysis in the entorhinal cortex (J). The mean integrated optical density (IOD) of GFAP/astrocyte was analyzed for the entorhinal cortex (K) and the hippocampus (L). n= 9-10/group.

In the pyramidal tract (Figure 3.6A) and cerebellar cruciform (Fig 3.6G) of rSHAM animals very few, if any, CD68-positive microglia were observed. Repeated CHI resulted in an appreciable increase in activated microglia in the pyramidal tract (Figure 3.6 B, C) and cerebellum (Figure 3.6 H, I), in a subset of animals injured at 24h (5 of 9) or 48h (3 of 9) intervals. However, across the entire group, the percent area of CD68 was not significantly increased within the pyramidal tract of rCHI animals compared to rSHAM animals (ANOVA $p>0.05$, Figure 3.6M). A mild astrocytic response was observed within the pyramidal tract (Figure 3.6 E, F) and cerebellar cruciform (Figure 3.6 K, L) of injured animals. While a few animals from each injury group had a higher percent area of GFAP labeling in the pyramidal tract compared to sham animals, groups were not significantly different from each other ($p>0.05$; Figure 3.6N). Because neuroinflammation is often concomitant with neurodegeneration (Chapter 2 and (Bolton and Saatman 2014; Luo, Nguyen et al. 2014)) we asked whether pyramidal tract degeneration predicted the extent of gliosis. Neither microgliosis nor astrocytosis correlated with increases in silver stain ($p>0.05$; $r=0.33$ for silver stain v. CD68; $r=-0.37$ for silver stain v. GFAP; Figure 3.6O). Surprisingly, GFAP immunoreactivity in the pyramidal tract correlated with better average beam walking scores in injured animals ($p<0.05$; $r=0.67$; Figure 3.6O), while, CD68 immunolabeling appeared to be inversely correlated with beam walking scores, although the correlation did not reach statistical significance ($p=0.056$; $r=-0.47$; Figure 3.6O).

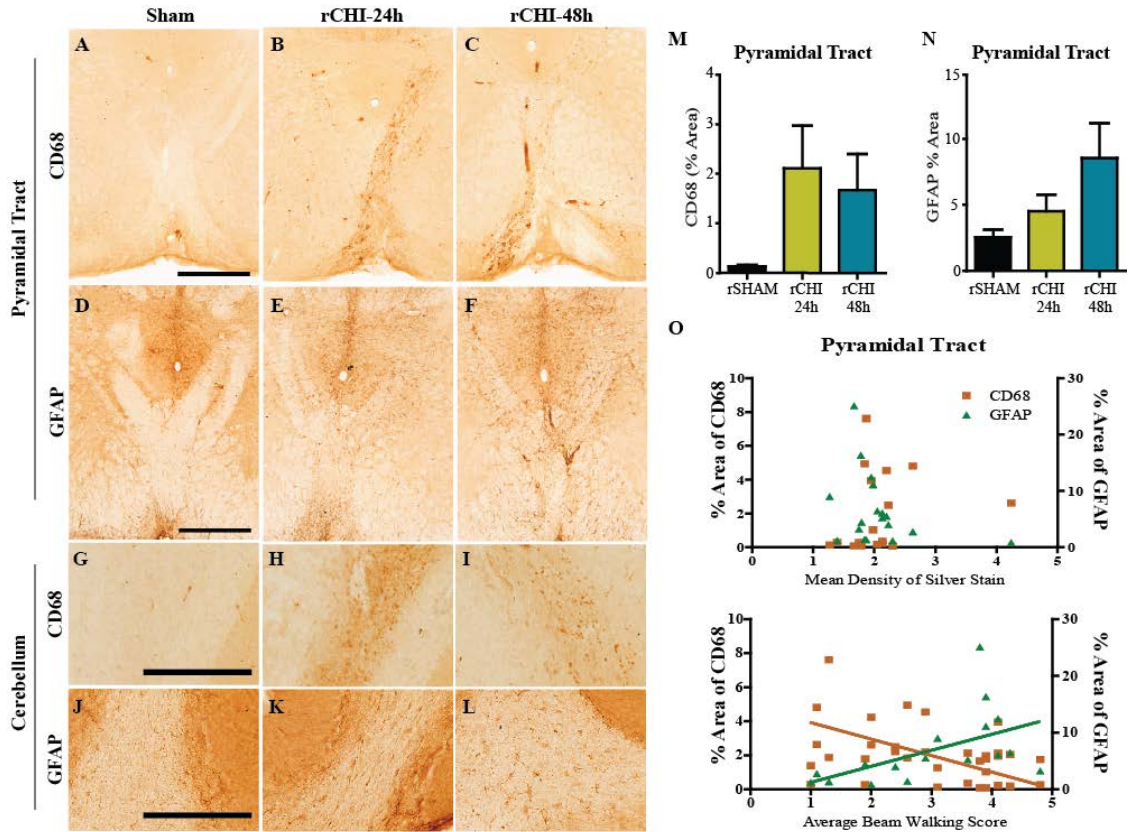


Figure 3.6: Repeated closed head injury (CHI) caused chronic activation of microglia and reactive astrocytes in the cerebellum and brainstem.

Immunohistochemical labeling of cluster of differentiation 68 (CD68) and of glial fibrillary acidic protein (GFAP) in the pyramidal tract (A-C and D-F, respectively) and white matter tracts of cerebellar cruciform (G-I and J-L, respectively) after repeated sham (rSHAM), repeated CHI at 24h intervals (rCHI-24h), and repeated CHI at 48h intervals (rCHI-48h). Scale bars: 500 μ m A-F; 250 μ m G-L. The percent area of CD68 and GFAP labeling was quantified for analysis in the pyramidal tract (M and N respectively). The percent area of CD68 (orange squares) and GFAP (green triangles) labeling in the pyramidal tract did not correlate with the mean density of silver stain in the pyramidal tract (O top panel). The percent area of CD68 or GFAP labeling after repeated CHI compared to the average beam walking score across ten weeks (O bottom panel). Lines represent linear regression for visualization purposes. n= 9-10/group.

In the optic tract of injured animals, CD68-positive microglia were diffusely distributed (Figure 3.7 B, C). In addition, GFAP-labeled astrocytes appeared to increase in number and were enlarged throughout the region (Figure 3.7 E, F). The percent area of CD68 labeling (Figure 3.7J) and of GFAP-labeled astrocytes (Figure 3.7K) were significantly increased ten weeks after repeated CHI at either 24h or 48h inter-injury intervals ($p < 0.05$ compared to sham). CD68-positive microglia were also observed throughout the optic nerves of injured animals (Figure 3.7 H, I), congregated most heavily in the areas where NF200 labeling was diminished. The percent area of CD68 labeling was significantly increased ten weeks after repeated CHI at either 24h or 48h inter-injury intervals compared to sham injury ($p < 0.05$; Figure 3.7L). Increasing the inter-injury interval from 24h to 48h did not significantly reduce gliosis in the optic tract or optic nerve ten weeks after injury ($p > 0.05$).

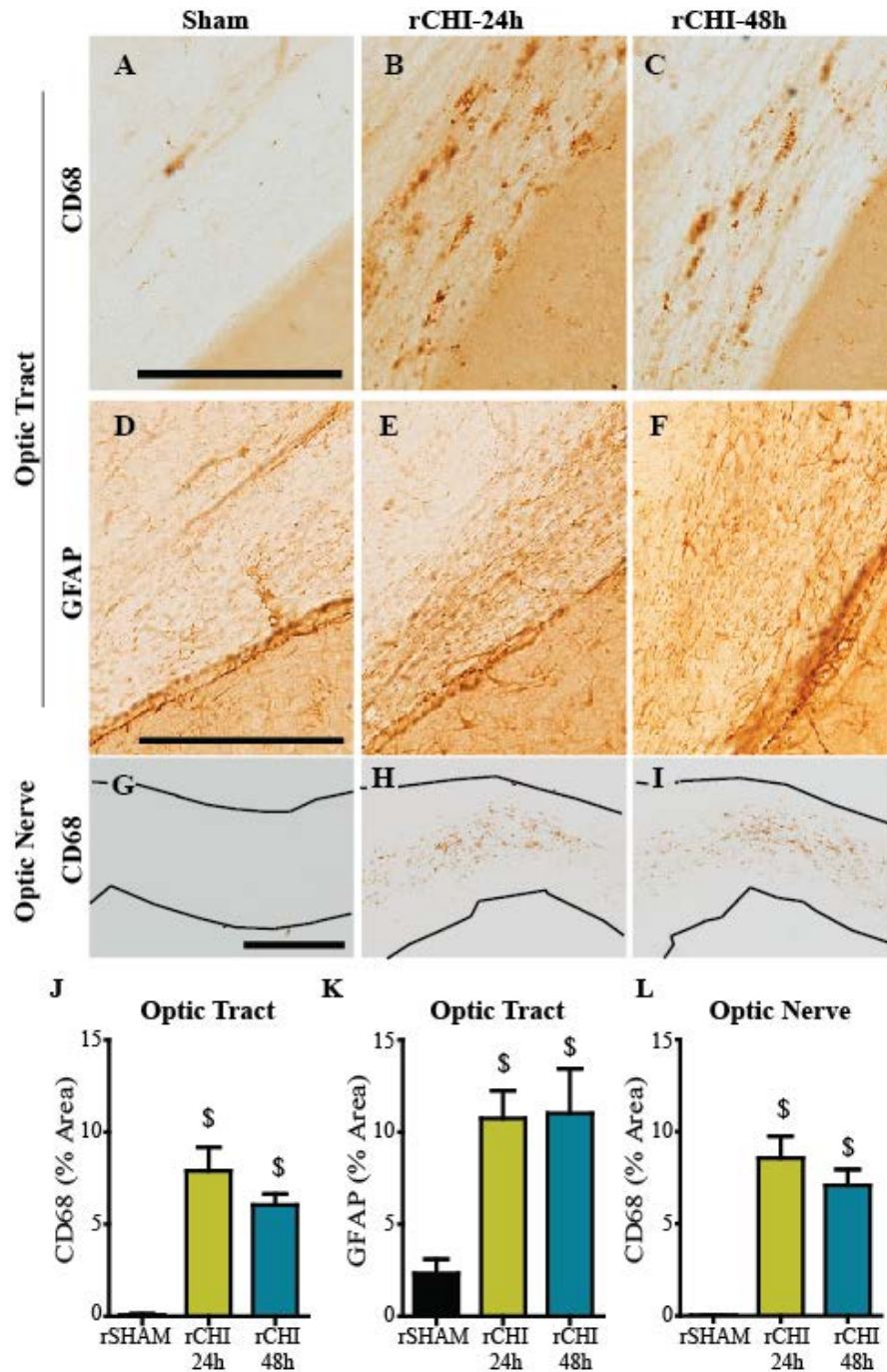


Figure 3.7: Repeated closed head injury (CHI) caused chronic microgliosis in the optic tract and optic nerve.

Immunohistochemical labeling of cluster of differentiation 68 (CD68; A-C, G-I) and glial fibrillary acidic protein (GFAP; D-F) after repeated sham (rSHAM), repeated CHI at 24h intervals (rCHI-24h), and repeated CHI at 48h intervals (rCHI-48h). Scale bars: 250 μ m. The percent area of CD68 labeling was quantified for analysis in the optic tract (J), and optic nerves (L). The percent area of GFAP labeling was quantified for analysis in the optic tract (K). \$ indicates $p < 0.05$ compared to sham. $n = 9-10$ /group.

To determine whether microgliosis in the optic tract was initiated early after rCHI or represented a delayed response to ongoing neurodegeneration, we evaluated archival tissue from our previous study with this model (Chapter 2). Groups included repeated CHI (rCHI-24h (n=7) and rCHI-48h (n=8)) euthanized 24h after the final injury, single CHI (euthanized at 24h (n=8), 5d (n=5), or 9d (n=5) post-injury) and repeated sham (n=8). CD68 immunolabeling in the optic tract 24h after a single CHI was similar to labeling in rSHAM animals ($p>0.05$; Figure 3.8). However, by five days after a single CHI, CD68 immunolabeling in the optic tract was significantly increased ($p<0.05$ compared to rSHAM). Microglial reactivity decreased significantly by nine days after a single CHI compared to five days after a single CHI ($p<0.05$) but remained elevated compared to rSHAM ($p<0.05$). When CHI were repeated at a 24h or 48h inter-injury interval, the percent area of CD68 labeling was significantly increased compared to that in rSHAM animals ($p<0.05$), but the response was similar to the peak microglial response seen five days after a single CHI.

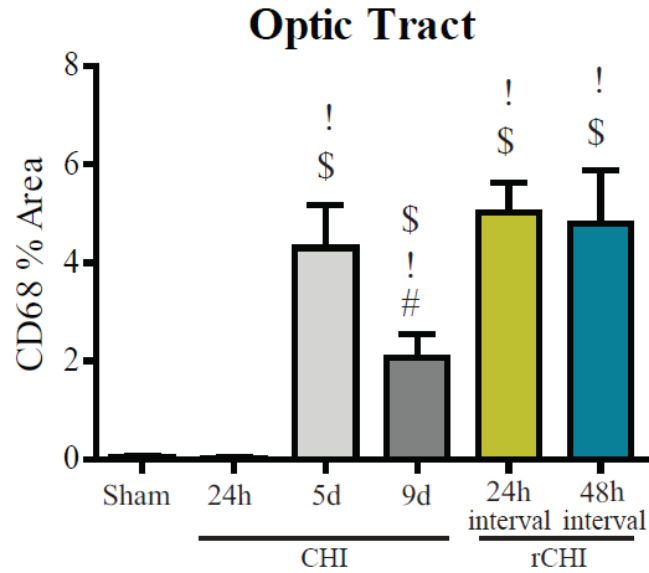


Figure 3.8: Acute microgliosis in the optic tract after single and repeated closed head injuries (CHI).

The percent area of immunohistochemical labeling of cluster of differentiation 68 (CD68) was quantified in the optic tract of mice receiving repeated sham injury (rSHAM), single CHI (euthanized at 24h, 5d, and 9d after injury) and five repeated CHI at 24h or 48h inter-injury intervals (euthanized 24h after the final injury) for comparative analysis. \$ indicates $p < 0.05$ compared to sham. ! indicates $p < 0.05$ compared to (single) CHI 24h. # indicates $p < 0.05$ compared to CHI 5d.

Absence of Pathological Tau

Neuronal inclusions of hyper-phosphorylated tau is a hallmark for CTE in humans, a condition associated with repeated TBI. In the current study mice with repeated CHI did not exhibit hyper-phosphorylated tau when immunolabeled with PHF-1 antibody ten weeks after injury (Figure 3.9). Transgenic mice modified to express human tau (rTg4510) exhibit age-related tau phosphorylation (Spires, Orne et al. 2006). PHF-1 accumulation was detected in brain sections from a 3.5 month old rTG4510 mouse, serving as a positive control for the protocol.

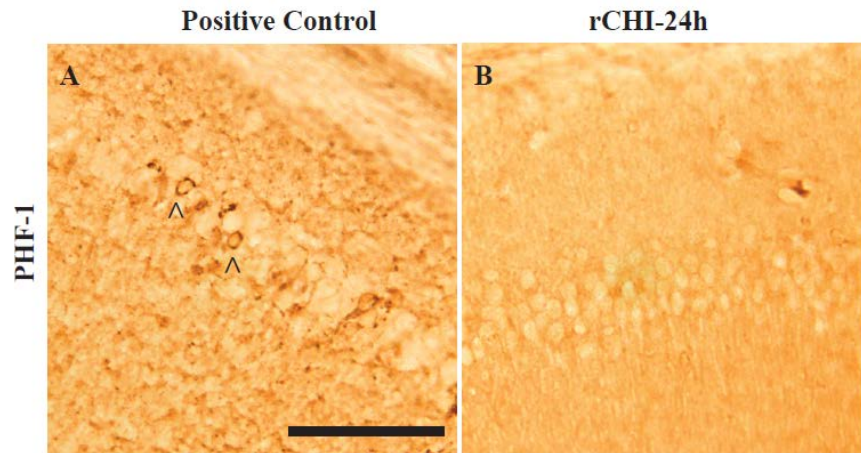


Figure 3.9: PHF-1 after repeated closed head injury (CHI) compared to positive control tissue. Hippocampal image from 3.5mo old rTg4510 tau mouse immunohistochemically labeled with Paired Helical Filament 1 (PHF-1; A). Black arrowheads indicate positive tau inclusions. Repeated CHI did not induce PHF-1 positive tau inclusions by ten weeks after injury (B). Scale bar: 125 μ m. n = 2 positive controls; n = 8 rCHI-24h.

Discussion

We previously established a model of mild TBI in which the extent of acute histopathology was dependent on injury severity and was amplified by repeated impacts if the inter-injury interval was 24h but not 48h (Chapter 2). Using this same model, five CHI resulted in persistent cognitive and motor dysfunction over a 10wk period as well as neurodegeneration and neuroinflammation in the visual pathway, the corticospinal tract and the cerebellum. Counter to our original hypothesis, these injury-induced changes were not effectively mitigated by extending the inter-injury interval from 24h to 48h.

Motor Pathway Damage

Motor dysfunction is not a prominent feature of mild TBI, but difficulties in motor coordination are a common symptom associated with CTE. A number of repeated mild TBI models result in tissue damage in the motor cortex without concomitant motor impairment as assessed by beam crossing (Shultz, Bao et al. 2012), rotarod (Longhi, Saatman et al. 2005; Kane, Angoa-Perez et al. 2012; Mouzon, Chaytow et al. 2012; Bachstetter, Rowe et al. 2013; Luo, Nguyen et al. 2014; Mouzon, Bachmeier et al. 2014; Febinger, Thomasy et al. 2015; Selwyn, Cooney et al. 2015), or gait analysis (Luo, Nguyen et al. 2014). Others have described transient motor impairment that resolves within a week after injury (Laurer, Bareyre et al. 2001; Selwyn, Cooney et al. 2015; Zhang, Teng et al. 2015) or somewhere between 1wk and 6mo (Mouzon, Chaytow et al. 2012; Mouzon, Bachmeier et al. 2014). Our study is unique in documenting early motor deficits in beam walking, which persisted out to ten weeks after injury. Increasing the interval between injuries from 24h to 48h did not significantly reduce impairment in beam walking despite decreasing acute pathology (Chapter 2), suggesting motor

dysfunction after repeated CHI is not directly dependent on acute regional neuron loss or inflammation. Without a parallel group of mice with a single CHI it is not possible to completely rule out that the motor deficit were a consequence of *repeated* versus *single* mild TBI. However, assessments of beam walking 2h and 24h after the initial CHI from our previous study (not previously reported) show that one impact produces only a very slight and transient impairment which resolves by 24h, suggesting the long-lasting motor dysfunction observed in the current study is primarily due to repeated mild TBIs. Detection of longer lasting motor deficits in our model of repeated mild TBI as compared to others may be due, in part, to differences in the location, number or severity of our impacts, or to greater sensitivity of our motor task. We adapted our beam walking test to focus on its most difficult aspects and reduce the potential of masking small motor deficits.

In addition to mild deficits in beam walking ability, mice with repeated mild TBI exhibited chronic neurodegeneration within the pyramidal tract and cerebellum. Although the pyramidal tract contains the upper motor neurons of the corticospinal tract that control voluntary movements, the amount of persistent neurodegeneration in the pyramidal tract ten weeks after injury did not correlate with beam walking deficits. It is possible that the peak of neurodegeneration in this region occurred much earlier, given that other studies of TBI have noted maximal silver staining at 48h after a severe, focal TBI (Kupina, Detloff et al. 2003) or 72h after a milder impact acceleration injury (Hall, Gibson et al. 2005). Therefore, further temporal studies are necessary to elucidate whether acute neurodegeneration in the pyramidal tract correlates with beam walking deficits.

Neurodegeneration in the pyramidal tract and cerebellum was coupled with astrocytosis and microgliosis at 10 weeks post-injury. The relationship between ongoing neurodegeneration and chronic inflammation is still debated (Bennett and Brody 2014; Faden and Loane 2015). However, in the current study, quantification of reactive astrocytes and activated microglia in the pyramidal tract failed to reveal a correlation with silver stain accumulation. Interestingly, increased astrocytosis correlated with improved beam walking ability, suggesting that the long-term astrocyte response may be involved in promoting recovery after injury as has been reported in experiments of spinal cord injury (Okada, Nakamura et al. 2006; Herrmann, Imura et al. 2008). Reactive microgliosis, in contrast, appeared to be higher in mice with greater motor dysfunction. Such an inverse relationship between the activation of astrocytes and of microglia has been reported in mouse models of Alzheimer's disease (Kraft, Hu et al. 2013) and Batten disease (Macauley, Pekny et al. 2011). When reactive astrocytosis was inhibited in either of these models, microgliosis was upregulated. Future studies are needed to better understand the factors that modulate the relative astrocyte and microglial responses to brain trauma.

Memory Circuit Damage

Difficulties with memory, such as amnesia to the traumatic event or trouble with memory retention can occur following mild TBI. Based on our previous observation of damage in the entorhinal cortex and hippocampus, regions involved in the memory circuit, we postulated that repeated CHI may result in cognitive deficits. Indeed, mice with repeated CHI had significantly lower memory scores in an NOR task across a 10wk period compared sham mice, adding to the growing literature documenting memory

impairment after repeated mild TBI that persists longer with increased number of injuries (Prins, Hales et al. 2010; Meehan, Zhang et al. 2012; Shultz, Bao et al. 2012; Cheng, Craft et al. 2014) or shorter time intervals (Longhi, Saatman et al. 2005; Meehan, Zhang et al. 2012; Mannix, Meehan et al. 2013; Weil, Gaier et al. 2014). Extending the inter-injury interval between two head injuries to greater than 1wk has been shown to improve cognitive deficits compared to shorter inter-injury intervals (Longhi, Saatman et al. 2005; Meehan, Zhang et al. 2012; Mannix, Meehan et al. 2013; Weil, Gaier et al. 2014). Differences in the rate of improvement for a 1wk inter-injury interval between studies may be attributed to differences in the number of injures, 2 versus 5, respectively. We found no significant attenuation of memory dysfunction by extending the inter-injury interval from 24h to 48h, with little evidence of ongoing neurodegeneration, astrogliosis or microgliosis in the entorhinal cortex or hippocampus further demonstrating that 48h is within the period of vulnerability for cognitive dysfunction. It remains to be determined whether an acute transient wave of neuron death and/or inflammation in these regions contributes to persistent memory dysfunction, but it seems unlikely to be the major determinant since the rCHI-48h group, which had less neuron loss and microglial activation than the rCHI-24h group early after injury (Chapter 2) exhibited comparable cognitive deficits. An alternative explanation for persistent neurobehavioral impairment may be ongoing dysfunction of surviving neurons. Future studies with this repeated mild TBI model could evaluate impairment in axonal conduction velocity or long-term potentiation, neuronal changes found after a single blast injury which resulted in deficits in hippocampal-dependent learning and memory without macroscopic tissue damage (Goldstein, Fisher et al. 2012). Alternatively, metabolic measures gleaned through

imaging approaches or autoradiography could reveal areas of sub lethal neuron injury. The duration of depressed glucose metabolism within the hippocampus has been suggested to predict the window of vulnerability for cognitive dysfunction with repeated mild TBI in rats (Prins, Alexander et al. 2013).

Visual System Damage

Humans with mild TBIs often complain of disruptions in normal vision which can manifest in the form of saccades and difficulties with pursuit, convergence, accommodation and the vestibular-ocular reflex (Ventura, Balcer et al. 2014). These changes can result in difficulties with reading, light sensitivity, and headaches leading to poor quality of life. Despite the high occurrence, visual dysfunction after TBI is an underrepresented area of study. Evidence is growing that models of midline, diffuse head injury are a valuable tool for exploring the visual pathway damage after mild TBI. In 2004, Creeley and colleagues reported argyrophilic fibers and bodies in the optic tract and superior colliculi 24h after three repeated weight drop impacts at 24h intervals (Creeley, Wozniak et al. 2004). More recently, Tzekov and colleagues documented demyelination of optic nerve axons, inflammation within the optic nerve and loss of retinal ganglion cells 10 and 13 weeks after five repeated CHI at 48h intervals (Tzekov, Quezada et al. 2014). Xu and colleagues also observed retinal ganglion cell loss in addition to inflammation and neurodegeneration within the optic tract and optic nerve after four repeated impact acceleration injuries within one week (Xu, Nguyen et al. 2014). The optic tract neurodegeneration was significantly increased compared to that in animals with a single injury, but was not significantly different from that in mice receiving 12 injuries within one week (Xu, Nguyen et al. 2014).

Our study is the first to examine visual pathway pathology with respect to inter-injury interval. We show ongoing axonal injury in the optic nerve and optic tract ten weeks after repeated CHI. Analysis of CD68 in the optic tract of archival tissue taken at 24h post-injury in our previous study demonstrates that a single CHI initiates a delayed transient microglial activation in the optic tract while repeated CHI leads to optic tract microgliosis sustained up to 10wks post-injury. Inflammation in the optic tract was not diminished acutely or chronically by extending the inter-injury interval from 24h to 48h suggesting that the visual pathway is more susceptible to CHI than is the entorhinal cortex and hippocampus. Increased susceptibility for damage in the visual system may be due to the optic nerve's location beneath and its separation from the cerebrum as has been described following fluid percussion injury (Wang, Fox et al. 2013). Visual system damage raises the possibility that repeated mild TBI induces visual dysfunction. Although retinal ganglion cell loss was not observed after a single mild fluid percussion injury (Wang, Fox et al. 2013), it has been reported after repeated closed head impact (Tzekov, Quezada et al. 2014) and repeated impact acceleration (Xu, Nguyen et al. 2014). Electroretinography traces in mice after repeated CHI showed decreased photopic negative response (PhNR) compared to that in sham animals (Tzekov, Quezada et al. 2014). Decreases in PhNR suggest dysfunction of retinal ganglion cells (Viswanathan, Frishman et al. 1999) which could influence performance in vision-based tasks such as the NOR task. However, mice with visual pathway neurodegeneration following repeated impact acceleration did not perform poorly in a visible platform trial suggesting the damage may not induce substantial vision impairment (Creeley, Wozniak et al. 2004). The NOR task used in this study incorporates large objects with marked differences in

their shapes and sizes. Rodents rely heavily on their whisker sensation and olfaction more so than their vision when exploring their surroundings. Therefore, potential visual dysfunction may not impede their ability to explore and sense differences in the objects during the NOR task, lessening the possible confound of diminished vision. However, further vision function tests are warranted to better understand potential consequences of visual pathway damage after mTBI.

Conclusion

Several reports have concluded that post-concussive symptoms in humans do not correlate with the presence or absence of positive neuroimaging findings acutely after injury (Hanlon, Demery et al. 1999; Huynh, Jacobs et al. 2006; Kurca, Sivak et al. 2006). In conjunction with our previous work we provide evidence for a similar phenomenon in mice. Despite significant differences in acute histopathology following five mild TBIs repeated at 24h or 48h intervals, in the current study repeated CHI resulted in persistent deficits in beam walking and novel object recognition in mice up to ten weeks after injury that were not significantly reduced by extending the inter-injury interval. Neuronal degeneration and gliosis observed acutely in the entorhinal cortex and hippocampus did not persist out to ten weeks after injury. However, axonal degeneration and inflammation in the optic tract, optic nerve, pyramidal tract and cerebellum were observed even ten weeks after the final injury. Additional work with long periods of rest between injuries, as well as with single head injuries would help determine if further increasing the interval between injuries can reduce the chronic consequences of mild TBI.

CHAPTER 4: Progranulin Deficiency Exacerbates Microgliosis but not
Behavioral Dysfunction or Chronic Neurodegeneration after Repeated Mild Traumatic
Brain Injury in Mice

Preface

For the following chapter, study design and interpretation of results were conducted by Amanda Bolton Hall and Kathryn Saatman. Surgery procedures, tissue processing, immunohistochemistry of cerebrum tissue, histological analyses of all cerebrum tissue, analysis of behavioral data, and statistics were performed by Amanda Bolton Hall. Behavioral testing and silver staining of cerebrum tissue was conducted by Jennifer Brelsfoard. Optic nerves were processed, labeled using immunohistochemistry and analyzed by Binoy Joseph.

Introduction

Mild traumatic brain injuries (TBI) account for approximately 75% of TBIs that occur every year in the United States (Kraus and Nourjah 1988). A very small percentage of individuals who suffer from a mild TBI require surgical intervention. More commonly, symptoms of headache, dizziness, and amnesia resolve within days of the event (McCrea, Barr et al. 2005; McCrory, Makdissi et al. 2005; Meehan, d'Hemecourt et al. 2010; Marar, McIlvain et al. 2012). Individuals are allowed to return to their normal daily activities upon recovery from their symptoms (Giza, Kutcher et al. 2013). For some people their normal daily activities include participation in events where the risk of subsequent injuries is high. Multiple head injuries can result in worsened or prolonged symptomatology and are associated with the development of the neurodegenerative disease chronic traumatic encephalopathy (CTE) years after the events.

The symptoms of CTE are diverse, but most commonly include cognitive deficits, emotional or physical outbursts, depression, and motor deficits (Critchley 1957). Symptoms are delayed from the time of the traumatic event and worsen over time (Montenigro, Baugh et al. 2014). Pathologically, the brains of individuals with CTE present with cerebral atrophy, enlarged lateral and third ventricles and thinned corpus callosum. CTE also presents with neuronal inclusions of the microtubule associated protein-tau deep within the sulci of several cortical lobes, a hallmark described by McKee and colleagues that is currently undergoing independent validation as a distinguishing feature of CTE (McKee, Stein et al. 2015). As the disease progresses, the tau pathology spreads from the sulci areas to the cortical layers and to additional non-cortical regions such as the hippocampus and amygdala until it is widespread in the most severe cases of

the disease (McKee, Stein et al. 2015). Eighty percent of cases also include the phosphorylation and accumulation of the transactive response DNA binding protein-43kDa (TDP43) (McKee, Stein et al. 2015).

TDP43 is also a pathological marker in the majority of frontotemporal dementia (FTD) cases (Neumann, Sampathu et al. 2006). Many cases of FTD with TDP43 have been linked to mutations causing a haplo-insufficiency in the growth factor progranulin (Leverenz, Yu et al. 2007). In the central nervous system, progranulin is expressed in neurons and microglia where it acts as a modulator of inflammation having both anti- and pro-inflammatory characteristics. Several lines of progranulin deficient ($Grn^{-/-}$) mice have been generated, and one line is reported to have age-related cytosolic accumulation of phosphorylated TDP43 (Yin, Dumont et al. 2010). All $Grn^{-/-}$ mice have reported age-related increases in microgliosis (Yin, Dumont et al. 2010; Ghoshal, Dearborn et al. 2012; Petkau, Neal et al. 2012; Wils, Kleinberger et al. 2012) that occurs prior to the accumulation of TDP43 pathology and in conjunction with accumulation of ubiquitinated proteins and lipofuscin (Yin, Dumont et al. 2010). In response to the intracellular pathogen *Listeria monocytogenes* (Yin, Banerjee et al. 2010) or to the neurotoxin precursor 1-methyl-4-(2'-methylphenyl)-1,2,3,6-tetrahydrophine (MPTP) (Martens, Zhang et al. 2012), $Grn^{-/-}$ mice show increased microgliosis and release of pro-inflammatory cytokines. More recently, a stab brain injury was shown to induce increased acute microgliosis in $Grn^{-/-}$ mice associated with increased neuronal loss 4d after injury (Tanaka, Matsuwaki et al. 2013a; Tanaka, Matsuwaki et al. 2013b). Chronic neuroinflammation is associated with a number of neurodegenerative diseases and is thought to be influential in the development of chronic neurodegeneration. We previously

reported increased acute neuroinflammation in response to repeated mild TBI that was long-lasting in the visual pathway and associated with chronic neurodegeneration (Chapter 3). To test the hypothesis that injury-induced chronic microgliosis effects chronic neurodegeneration we first confirmed that repeated mild TBI would induce an exacerbated microglial response in $Grn^{-/-}$ mice. We then examined the chronic effects of an increased microglial response on cognition and motor coordination across 7 months followed by histological evaluation of microgliosis and neurodegeneration 7 months after injury.

Materials and Methods

Animals

A total of 118 mice were used for the following studies. Two breeder trios (2F:1M) of progranulin knockout mice (B6(Cg)- $Grn^{tm1.1Aidi}/J$) were also purchased from Jackson Laboratories (Bar Harbor, ME) to establish an in-house colony. Progranulin knock out ($Grn^{-/-}$) mice were developed using C57BL/6 blastocysts and mice were backcrossed for at least five generations (Yin, Banerjee et al. 2010) prior to arrival at The Jackson Laboratory, where they were bred to C57BL/6J inbred mice for at least one generation according to The Jackson Laboratory, making purchased C57BL/6 mice a suitable wildtype control for $Grn^{-/-}$ mice. Two month old male and female, C57BL/6 mice were purchased from Jackson Laboratories (Bar Harbor, ME). Upon arrival, mice were group housed under a controlled 14:10 light: dark cycle and provided food and water *ad libitum* and allowed to acclimate for one week before injury or breeding. Animal husbandry and all surgical procedures were approved by the University of Kentucky Institutional Animal Care and Use Committee and followed the federal guidelines set by

the Institute of Laboratory Animal Resources (U.S.) and Committee on the Care and Use of Laboratory Animals.

Experimental Design

For the following studies, C57BL/6 and Grn^{-/-} mice received repeated CHI or sham-injury as described below. Histological analyses were performed in an acute cohort at 48h and 7d following the final CHI (n=10/genotype) or sham injury (n=5/genotype). A larger cohort of C57BL/6 and Grn^{-/-} mice received repeated CHI (n=15-18/genotype) or sham injury (n=9-10/genotype) and were assessed for behavioral deficits for 7months, after which they were euthanized for histological analyses. Due to the length of time required for some of the behavioral testing, mice were assigned to several groups which were injured on successive weeks to limit the number of mice tested in a day. Each group contained mice of each genotype designated for repeated CHI and sham injury but were either all female or all male to further reduce compromising behavioral testing.

Closed Head Injury

CHI was performed as previously described (Chapters 2 and 3). In brief, mice were placed into a chamber and 3% isoflurane/3% oxygen was conducted for 1-2 minutes to induce anesthesia. Mice were then transferred into a stereotaxic frame with non-rupture Zygomar ear cups (Kopf, Instruments, Tujunga, CA) where anesthesia was maintained using 2.5% isoflurane/2.5% oxygen delivered via a nose cone. An injection of 0.2ml of 1:200,000 epinephrine and 0.5% bupivacaine (Henry Schein Animal Health, Dublin, OH) in sterile, normal saline under the scalp induced local analgesia prior to resecting the scalp. CHI was induced using a pneumatically controlled cortical impact device (TBI-0310 Impactor, Precision Systems and Instrumentation, Fairfax Station, VA)

with a 5mm diameter, pliant, silicone tip with a hardness of 55 Shore A. The tip was aligned along the midline suture between the bregma and lambda sutures. The device was programmed to impact at an intended depth of 2.0mm at a 3.5m/sec velocity with a 500msec dwell time. Immediately after injury, mice were removed from the stereotaxic frame and placed in supine position on a heating pad. Apnea duration and righting reflex were assessed. After righting, mice were re-anesthetized briefly in order to suture their scalps. Mice additionally received a subcutaneous injection of 1mL of sterile, normal saline prior to returning to the heating pad to fully recover. Sham-injured mice received anesthesia and underwent the same surgical procedure without receiving an impact. The total duration of anesthesia was controlled for all animals to be 10 minutes. Sham and CHI injuries were repeated five times at twenty-four hour intervals. During these subsequent procedures, sutures were removed, the scalp was resected, and injury was induced in the same location followed by the same assessment protocol.

Four mice in the study did not recover from their apneic episode following one of the five injuries, resulting in death: one mouse from the 48h Grn^{-/-} rCHI cohort, two mice from the 7mo Grn^{-/-} rCHI cohort, and two mice from the 7mo C57BL/6 rCHI cohort. One mouse in the study (7mo Grn^{-/-} rCHI) lost more than 15% of its initial body weight before completion of all five injuries and was removed from the study as described by a priori guidelines for animal welfare. Three Grn^{-/-} mice only had one eye at the time of surgery. As they aged, their one eye became cloudy. These mice were behaviorally assessed to evaluate deficits in vision but were not included in the final study cohort.

Behavioral Testing

Beam Walking

Prior to injury, mice were trained to walk across a 3cm beam. After injury, mice were observed as they traversed across three beams of varying widths: 1cm width Plexiglas beam, 0.5cm width Plexiglas beam, and a 0.5cm diameter wooden dowel rod. For both the Plexiglas beams, 1 point was deducted if a foot slip occurred while traversing the beam. An additional point was deducted if mice fell upside down while traversing the beam. Zero points were awarded if mice fell off the beam or could not traverse the beam. For the dowel rod, 1 point was deducted if mice fell upside down on the beam more than two times. Zero points were awarded if mice fell off the beam or could not traverse the beam. Points for each beam were combined to give a maximum score of 8 points per animal (3pts for each Plexiglas beam, 2pts for the dowel rod). This protocol was repeated on each of the following days after injury: 1, 7, 14, 28, 56, 112, 168. One group out of six inadvertently missed their testing on day 14. They were therefore removed from the analyses for the beam walking test resulting in a final n's of 13 C57BL/6 rCHI, 8 C57BL/6 rSHAM, 11 Grn^{-/-} rCHI, and 6 Grn^{-/-} rSHAM.

Novel Object Recognition

Seven days after the final CHI or sham injury, mice were acclimated for one hour to individual, empty Plexiglas cages of 10.5" x 19" x 8" dimensions, termed the "testing cage". For behavioral assessment, mice were then placed into their testing cage with two identical objects and explored for five minutes. Four hours later, mice were placed into their testing cage with one of the previously explored objects and a new object. They were again allowed to explore the two objects for five minutes. The amount of time spent

with each object was recorded. The percent recognition index was determined by dividing the amount of time spent with the novel object by the total exploration time. This protocol was repeated on the following testing days: 14, 28, 56, 112, 168. The familiar objects remained the same throughout the study. However, on each testing day, a new, unfamiliar object was used as the novel object.

Visible Platform

The visible platform trial was based on the established Morris Water Maze task (Schenk and Morris 1985). A 1m diameter circular tank was filled with 18-20°C water mixed with white paint powder and a 6cm diameter platform was placed just below the water line. The platform's location was identified by a 5cm tall, 1cm diameter cylinder object placed on top of it. For each trial mice were individually placed into one of four quadrants labeled north, south, east, and west. The starting position was alternated between the quadrants, for a total of five trials. The amount of time it took for each mouse to reach the platform was recorded. If a mouse took longer than 60seconds to reach the platform, it was placed on the platform by the experimenter. Upon reaching, or being placed on, the platform mice were allowed to remain there for 15 seconds. The average of the best two trials was used for statistical analysis. This protocol was performed on the following testing days after completion of the NOR task: 14, 28, 56, 112, 168.

Novel Mouse Recognition Task

The Familiar Mouse Recognition (NMR) task was modified from the three chamber social task (Landauer and Balster 1982). This task resembles the NOR, but uses mice rather than inanimate objects. The day before testing (approximately 7mo after CHI

or sham injury), mice were acclimated for one hour to the Plexiglas cage of 10.5” x 19” x 8” dimensions containing two identical, inverted wire pencil cups placed in opposite quadrants of the cage. The following day, two naïve mice from the same litter, housing cage, and matching the sex of the test mouse were placed individually under the cups. The test mouse was then introduced to the test cage and allowed to explore the two contained mice. The time the test mouse spent with their nose within approximately a centimeter of the wire cups containing each naïve mouse was recorded as exploration. Two sets of naïve mice were alternated between test subjects to reduce the potential for stress.

Twenty-four hours later one of the now ‘familiar’ mice was returned to the test cage and placed under one pencil cup. A new ‘mouse, also naïve to injury and of the same sex as the test mouse, but selected from a different housing cage from the ‘familiar’ mice, was placed under the other cup. The test mouse was then introduced to the cage and allowed to explore the two mice for five minutes. The change in the recognition index of the familiar mouse from the first testing day to the second was calculated. ‘Stranger’ mice were alternated between test subjects to reduce the potential for stress.

Visual Cliff

The apparatus for this test was created based on previously published reports (Gibson and Walk 1960; Fox 1965). A 1 inch wide, 1 ½ inch tall beam traversed the middle of a white, Plexiglas box. Below the beam was a thin sheet of glass. On one side of the beam was a black and white checkerboard print, immediately under the glass, and on the other side, the checkerboard print surface was placed along the side and 2ft below the glass at the bottom of the box. These sides were dubbed the “safe side” and the “cliff

side” respectively. Prior to testing, mice were briefly anesthetized in order to shave off their whiskers in order to prevent the tactile detection of the glass floor. After fully recovering from the brief anesthesia, mice were placed onto a beam inside of the testing apparatus and allowed 3 minutes to make a decision on which side of the beam to step off. If mice did not make a choice after three minutes they were removed and placed back into their home cage. Six trials were recorded for each mouse, alternating the direction of travel along the beam, and the percent of ‘safe’ side selections was normalized to the total times the mice left the beam.. This task was the last task and was performed the day prior to euthanasia.

Histopathology

Tissue Processing

Mice were euthanized at either 48h or 7d (acute cohort) or 7mo (chronic cohort) following their final sham or injury procedure by intraperitoneal injection of Fatal Plus (130mg/kg, Henry-Schein Animal Health, Dublin, OH) before transcardial perfusion with cold, heparinized sterile saline followed by cold, 4% paraformaldehyde (PFA) for five minutes. After perfusion, mice were decapitated and the heads placed into vials of 4% PFA for 24h. Following this period, the brains and optic nerves were removed from the skull and post-fixed in 4% PFA for an additional 24h. Following post-fixation, tissue was placed into 20% sucrose in 1X-Tris-buffered saline (TBS) for 48h for cryoprotection. The brain tissue was frozen in -25 to -35°C isopentane before being cut into 40µm thick coronal sections using a sliding microtome (Dolby-Jamison, Pottstown, PA). For optic nerves, tissue was frozen in optimal cutting temperature compound (OCT) on the sliding

microtome and cut into 10 μ m thick longitudinal sections. Tissue sections were stored at -20°C in 30% glycerol, 30% ethylene glycol in 1X TBS.

Histology

Degenerating neurons were examined with Fluorojade-C (FJC) in a subset of the mice surviving 48h (n=5-6 injured and 2-3 sham/ genotype) using previously described methodology (Dewitt, Perez-Polo et al. 2013). For each animal, 2 sections at approximately -1.4 and -1.8mm Bregma levels and 2 sections at approximately -3.5 and -3.9mm Bregma levels were selected to evaluate the optic tract and posterior entorhinal cortex, respectively. Staining was performed on free-floating tissue sections using transfer wells and 12-well trays. Sections were initially treated with diaminobenzidine (DAB, Vector Laboratories, Burlingame, CA) for five minutes to quench endogenous peroxidases, eliminating any non-specific fluorescence that may occur with hemorrhage. The tissue was washed with ddH₂O 2x prior to being immersed sequentially in 1% NaOH in 80% ethanol, 70% ethanol, ddH₂O, and 0.06% potassium permanganate solution. The tissue was washed with ddH₂O before incubating in 0.0001% FJC solution (Millipore, Temecula, CA) in 0.1% acetic acid. The tissue was rinsed with ddH₂O, mounted onto gelatin-coated slides, protected from light while air dried, and coverslipped with Cytoseal 60 (Thermo Scientific, Hanover Park, IL).

Silver staining was performed on 12 sections (0.4 to -4.4 mm Bregma level, spaced 400 μ m apart) for 7d and 7mo tissue as previously described in Chapter 3 using the FD NeuroSilver kit (FD NeuroTechnologies, Ellicott City, MD). The following two modifications from the manufacturer's instructions were performed: (1) for the step involving the mixture of solution C and F, tissue was placed into the solution 2x 2.5

minutes; (2) tissue was dehydrated sequentially in 70%, 80%, 95%, and 100% ETOH, and cleared in Xylenes prior to coverslipping.

Immunohistochemistry

Free-floating tissue sections were used for immunohistochemistry. For mice surviving 48h or 7d, 6 sections of cerebral tissue spaced 400 μ m apart between -2.5mm and -4.5mm Bregma levels were used for immunohistochemical analyses. For mice surviving 7mo, 12 sections of cerebral tissue spaced 400 μ m apart between 0.5mm and -4.5mm Bregma levels were used for immunohistochemical analyses. Tissue sections were treated with 3% H₂O₂ in methanol for 30 minutes in order to quench endogenous peroxides. For all immunohistochemical protocols, tissues were blocked with 5% normal horse serum in 0.1% Triton X-100/1XTBS before incubation in primary antibody overnight at 4°C. Primary antibodies included rat anti-mouse cluster of differentiation-68 (CD68, Bio-Rad, Hercules, CA; 1:1000 for cerebrum, 1:500 for nerves), anti-neurofilament protein-200 (NF200, Sigma-Aldrich, St. Louis, MO; 1:100), anti-dephosphorylated neurofilament (SMI-32, Covance, Greenfield, IN; 1:1000), anti-paired helical filament-1 (PHF-1, The Feinstein Institute, Great Neck, NY; 1:500), and anti-phosphorylated TAR DNA binding protein-43 (pTDP43, Cosmo-Bio, Carlsbad, CA; 1:2000 and Millipore, Billerica, MA). On the following day tissue sections were rinsed and incubated in the appropriate biotin-conjugated secondary antibodies for 1 hour. Tissue was washed before incubating in Avidin-Biotin complex (Vector Laboratories, Burlingame, CA) for 30minutes. The substrate 3,3'-diaminobenzidine was applied as directed by the manufacturer (Vector Laboratories).

Histological and Immunohistochemical Analyses

All analyses were performed by an examiner blinded to the injury condition of the tissue. Fluorochrome C labeling and PHF-1 and pTDP43 immunolabeling were assessed qualitatively. Brain tissue from a 17mo old *Grn*^{-/-} mouse was used as a positive control for pTDP43 labeling (Yin, Dumont et al. 2010). Brain tissue from a 3.5mo old rTg4510 tau mouse was used as a positive control for PHF-1 labeling (Spires, Orne et al. 2006). For all other stains/immunohistochemistry quantitative analyses were performed.

For CD68 and silver stain labeling in the cerebrum quantitative analyses were performed using the Aperio ScanScope XT slidescanner (Leica Biosystems Inc., Buffalo Grove, IL) and Aperio ImageScope software. The slidescanner imaged the entire slide (5-6 sections/slide) at 20x magnification and specific regions of interest were manually outlined. Each area of interest (AOI) was outlined using the anatomical markers found in “The Mouse Brain in Stereotaxic Coordinates”, 4th Edition (Paxinos & Franklin).

Tissue from the cerebrum was immunolabeled with CD68 to mark activated microglia. Regions of interest were selected based on our previous works in Chapters 2 and 3: optic tract, superior colliculus, entorhinal cortex, and hippocampus. Because *Grn*^{-/-} mice, are reported to have increased microgliosis in the thalamus with age, the thalamus was also included as a region of interest. The Aperio algorithm for positive pixel count (version 9) was used to discriminate between positively labeled activated microglia and background stain. The total number of positive pixels for each region of interest was divided by the total area (mm²) of the region of interest. The number of positive pixels/mm² was used for statistical analyses among groups for each region of interest.

Silver staining resulted in a yellow/light brown background with black degenerative staining. Similar regions of interest as CD68 quantification were evaluated for silver stain labeling using the Aperio algorithm for color deconvolution. This algorithm was used to discriminate between the darker, black positive labeling and the light-brown negative background labeling. A percent of positive labeling in the outlined regions of interest was calculated and used for statistical analyses among groups.

Optic nerves were immunolabeled for CD68 to detect activated microglia, SMI-32 to detect dephosphorylated neurofilament that accumulates to form bulbs in the injured axon (Trapp, Hauer et al. 1988), and NF200 to detect loss of neurofilament protein as a marker of axonal injury or axon loss (Serbest, Burkhardt et al. 2007). For quantitative analysis of each marker, nerves were imaged using an AX80 microscope (Olympus, Melville, NY) (10x) and a DP-70 camera (Olympus). Several overlapping images were obtained to encompass the length of the optic nerve from the retina to the optic chiasm. These images were used to create a montage of the whole nerve in Adobe Illustrator CS6. For CD68 labeling, the intensity threshold that detected activated microglia was selected using Image Pro Plus software (Version 7.0, Media Cybernetics, Rockville, MD). The area of activated microglia was measured and normalized to the AOI. Similarly, the intensity threshold that detected NF200 labeled neurofilaments were selected, and the percent of the total area which contained labeled neurofilament protein was calculated. For SMI-32 labeling, three orthogonal grids comprised of 20 x20 40 μ m squares was overlaid on the montaged nerve images as previously described (Saatman, Abai et al. 2003). The number of grids which contained positive SMI-32 labeling was counted and normalized to the total number of grids within the AOI.

Statistics

For behavioral testing over several time points, as occurred with NOR, beam walking, and visible platform, a repeated measures 2-way ANOVA was performed (genotype x injury x time). For behavioral testing at one time point, as occurred with NMR and visual cliff, and histological analyses a 2-way ANOVA was performed (genotype x injury). When appropriate, Neuman-Keuls post-hoc analyses were performed. All data are presented as means with standard error.

Results

Apnea and Righting Reflex

Sham injury did not induce apnea in either genotype in any cohort. The righting reflex response in sham animals averaged (across time points) between 1 and 1.5 minutes.

After repeated CHI, apnea (Table 4.1) was induced as in our previous studies (Chapter 2). In the 48h cohort, the apneic response was dependent on the number of CHI ($p < 0.05$) but not genotype ($p > 0.05$; interaction $p > 0.05$), such that apnea was increased after the first CHI compared to that after CHI 2-5. In the 7d cohort, the apneic response was dependent on number of CHI ($p < 0.05$) and genotype ($p < 0.05$; interaction $p < 0.05$), such that the apneic response in $Grn^{-/-}$ mice after the first and second CHI was significantly increased compared to that in C57BL/6 mice after any CHI and $Grn^{-/-}$ mice after CHI 3-5. In the 7mo cohort, apnea was dependent on the number of CHI ($p < 0.05$) but not genotype ($p > 0.05$; interaction $p > 0.05$). The apneic responses after the first three injuries were each statistically longer than that after the final two injuries. Note that while there are differences between the duration of apneic episodes after injury among cohorts, all but two animals receiving CHI (1 in the 48h C57BL/6 cohort and one in the 7mo $Grn^{-/-}$ cohort) had at least 4 out of 5 apneic episodes greater than 5 seconds in length. It takes less than five seconds to quickly remove the animals from the head holders and place onto their backs. Thus apnea equal to or greater than five seconds can be reasonably assessed as positive apneic response to injury. The two animals noted as exceptions had 3 out of 5 apneic episodes greater than 5 seconds in length.

In comparison to sham-injured mice, injury resulted in a longer average righting reflex response by at least 1.5min in all genotypes in all cohorts (Tables 4.2). More specifically, in the 48h cohort, righting reflex duration was dependent upon injury ($p < 0.05$) and number of CHI ($p < 0.05$; interaction between injury and number of CHI $p < 0.05$), but not genotype ($p > 0.05$). The righting reflex response after the first CHI was significantly longer than the righting reflex in sham-injured animals and the righting reflex response after CHIs 2-5. In the 7d cohort, righting reflex duration was dependent upon injury ($p < 0.05$), number of CHI ($p < 0.05$), and genotype ($p < 0.05$) with a significant interaction between all three dependent variables ($p < 0.05$). Post-hoc analysis deduced that the righting reflex response after the first CHI in the $Grn^{-/-}$ mice was longer than that of sham-injured mice, C57BL/6 injured mice, and the response after CHIs 2-5. In the 7mo cohort, righting reflex was dependent upon injury ($p < 0.05$) and number of CHI ($p < 0.05$; interaction between injury and number of CHI $p < 0.05$), but not genotype ($p > 0.05$). Based on post-hoc analyses, the righting reflex response of injured mice was significantly higher after the first CHI than the response in sham-injured mice and the response after CHIs 2-5. The response after CHI 2 was significantly increased compared to sham and CHIs 4-5, whereas the response after CHI 4 and CHI 5 were also statistically increased compared to sham-injured mice on injury day 4 and 5.

Table 4.1: Apnea mild TBI in Grn^{-/-} and C57Bl/6 mice decreases with subsequent injuries.

			CHI 1	CHI 2	CHI 3	CHI 4	CHI 5
48h cohort	rCHI	C57BL/6	*				
		Grn ^{-/-}	30 ± 6	23 ± 5	14 ± 3	14 ± 4	10 ± 2
7d cohort	rCHI	C57BL/6	32 ± 10	22 ± 4	14 ± 3	16 ± 3	14 ± 2
		Grn ^{-/-}	14 ± 2	15 ± 2	12 ± 5	7 ± 1	8 ± 1
7mo Cohort	rCHI	C57BL/6	39 ± 5 *	27 ± 6 *	17 ± 4	13 ± 3	10 ± 4
		Grn ^{-/-}	#	#	#		
7mo Cohort	rCHI	C57BL/6	29 ± 4	22 ± 5	19 ± 4	12 ± 2	13 ± 3
		Grn ^{-/-}	20 ± 4	21 ± 4	14 ± 5	9 ± 2	7 ± 1

In the 48h cohort, the duration of apnea was significantly increased after the first closed head injury (CHI 1) (* indicates p<0.05 compared to CHI 1-5). n=10/genotype. In the 7d cohort, the duration of apnea was significantly increased in Grn^{-/-} mice after CHI 1 and CHI 2 (* indicates p<0.05 compared to C57BL/6 mice). n= 9/genotype. In the 7mo cohort, CHI 1-3 resulted in significantly lengthened apnea duration (# indicates p<0.05 compared to CHI 4 and 5). n=15-18/genotype.

Table 4.2: Righting Reflex in Grn^{-/-} and C57Bl/6 mice decreases with subsequent injuries.

			CHI 1	CHI 2	CHI 3	CHI 4	CHI 5
48h cohort	rSHAM	C57BL/6	1:02 ± 0:03	1:23 ± 0:12	1:26 ± 0:09	1:15 ± 0:06	1:23 ± 0:06
		Grn ^{-/-}	1:11 ± 0:13	1:33 ± 0:15	1:32 ± 0:12	1:36 ± 0:24	1:28 ± 0:09
	rCHI	C57BL/6	7:05 ± 1:29	2:46 ± 0:27	2:24 ± 0:10	1:56 ± 0:11	2:10 ± 0:09
		Grn ^{-/-}	7:11 ± 1:38	3:20 ± 1:03	2:38 ± 0:38	2:42 ± 0:20	2:43 ± 0:11
7d cohort	rSHAM	C57BL/6	1:15 ± 0:08	1:11 ± 0:02	1:15 ± 0:05	1:35 ± 0:05	1:26 ± 0:05
		Grn ^{-/-}	1:03 ± 0:16	1:22 ± 0:10	1:28 ± 0:08	1:13 ± 0:07	1:22 ± 0:07
	rCHI	C57BL/6	2:54 ± 0:32	3:35 ± 0:43	1:57 ± 0:13	1:29 ± 0:06	1:43 ± 0:08
		Grn ^{-/-}	9:51 ± 1:38 *	4:38 ± 1:15	2:34 ± 0:22	2:04 ± 0:11	2:02 ± 0:09
7mo Cohort	rSHAM	C57BL/6	1:22 ± 0:06	1:28 ± 0:07	1:25 ± 0:08	1:21 ± 0:07	1:34 ± 0:09
		Grn ^{-/-}	1:20 ± 0:07	1:26 ± 0:06	1:23 ± 0:06	1:24 ± 0:04	1:25 ± 0:06
	rCHI	C57BL/6	* \$ 7:00 ± 1:03	# \$ 4:05 ± 0:44	3:36 ± 0:31	\$ 2:58 ± 0:20	\$ 3:04 ± 0:26
		Grn ^{-/-}	6:11 ± 0:50	4:01 ± 0:37	2:55 ± 0:44	2:18 ± 0:11	1:56 ± 0:13

In the 48h cohort, repeated closed head injury (rCHI) groups had a significant increase in time to right (* indicates p<0.05 compared to rSHAM group). n=5 sham/genotype; n=10 injured/genotype. In the 7d cohort, Grn^{-/-} mice had a significant increase in time to right after the first CHI (\$ indicates p<0.05 compared to Grn^{-/-} sham mice). n=5 sham/genotype; n=9 injured/genotype. In the 7mo cohort, rCHI groups had a significant increase in time to right following the first CHI and second CHI (\$ indicates p<0.05 compared to that in rSHAM groups; * indicates p<0.05 compared to CHI 2-5; # indicates p<0.05 compared to CHI 4 and 5). n=9-10 sham/genotype; n=15-18 injured/genotype.

Microgliosis is Exacerbated Acutely in Progranulin-Deficient Mice after Repeated Mild TBI

Microgliosis was examined by using a marker for cluster of differentiation-68 (CD68) 48h and 7d after the final surgery. Sporadic positive labeling was observed in sham-injured mice from both genotypes, but was very minimal (not shown).

In C57BL/6 mice receiving rCHI, positively labeled microglia were observed 48h after the final injury in the optic nerve (Figure 4.1), optic tract (Figure 4.2), superior colliculus (Figure 4.2), and entorhinal cortex (Figure 4.3). $Grn^{-/-}$ mice receiving rCHI exhibited a more robust and widespread microglial response to injury compared to the microglial response in injured C57BL/6 mice, apparent by the swollen microglial cell bodies and processes in several brain regions: the optic nerve (Figure 4.1 D, E, F), optic tract (Figure 4.2 D), superior colliculus (Figure 4.2 E, F), entorhinal cortex (Figure 4.3 A, B), hippocampus (Figure 4.3 D-G), and thalamus (Figure 4.3 I, J). Quantification of CD68 was performed across these regions. Microgliosis in the optic nerve (Figure 4.1G), optic tract (Figure 4.2G) and superior colliculus (Figure 4.2H) was dependent upon injury and genotype (interaction $p < 0.05$). Post-hoc analyses revealed a significant increase in microglial reactivity within the optic nerve of injured C57BL/6 mice compared to sham-injured mice ($p < 0.05$). However, microgliosis in injured $Grn^{-/-}$ mice was significantly increased in the optic nerve, optic tract and superior colliculus compared to injured C57BL/6 mice and sham-injured mice ($p < 0.05$). Microgliosis in the entorhinal cortex (Figure 4.3C) was dependent upon injury ($p < 0.05$), but was not statistically different between $Grn^{-/-}$ and C57BL/6 mice. While mild microglial activity was evident in injured

animals, no significant differences were found in analyses of the hippocampus (Figure 4.3H) and thalamus (Figure 4.3K).

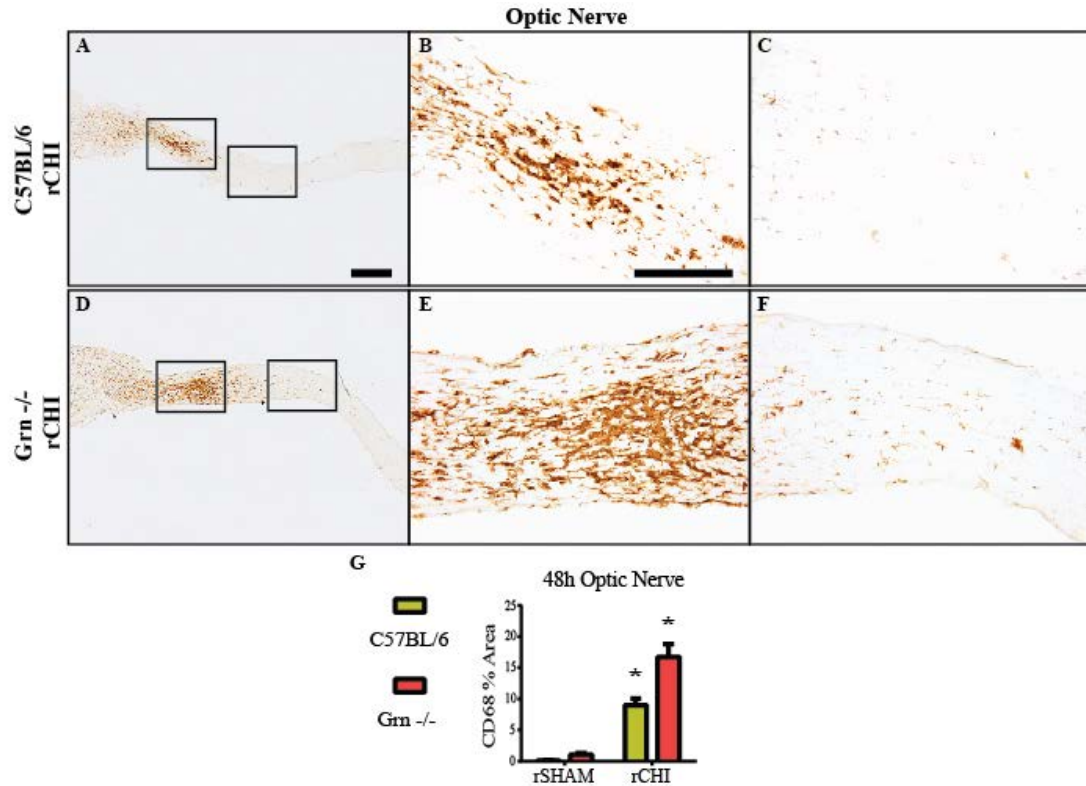


Figure 4.1: Microgliosis was exacerbated in the optic nerve of Grn^{-/-} mice 48h after repeated mild TBI.

Immunohistochemical labeling for cluster of differentiation-68 (CD68) in the optic nerve 48h after repeated closed head injury (rCHI) in Grn^{-/-} and C57BL/6 mice. The percent area of CD68 labeling was quantified for analyses. CD68 labeling was significantly increased after rCHI (G) compared to repeated sham injury (rSHAM) animals. CD68 labeling in injured Grn^{-/-} mice was also significantly increased compared to injured C57BL/6 mice (* indicates p<0.05 compared to all other groups). Scale bars represent 1mm: A, D; 500μm: B, C, E, F. n=4-5 sham/genotype; n=9-10 injured/genotype.

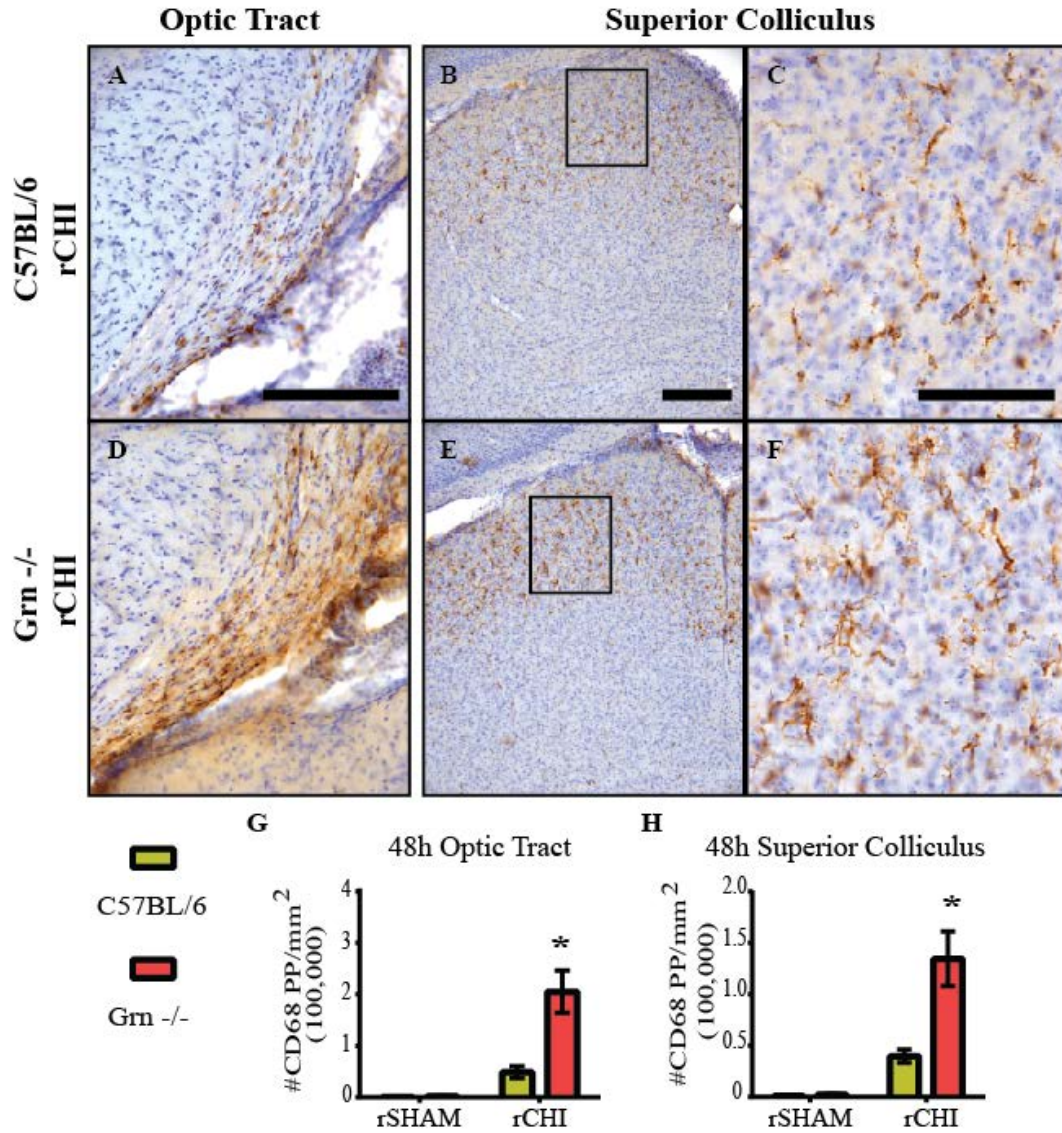


Figure 4.2: Microgliosis was significantly increased in the optic tract and superior colliculus of Grn^{-/-} mice 48h after repeated mild TBI.

Immunohistochemical labeling for cluster of differentiation-68 (CD68) in the optic tract (A, D) and superior colliculus (B, C, E, F) 48h after repeated closed head injury (rCHI) in Grn^{-/-} and C57BL/6 mice. The number of CD68 positive pixels were counted and normalized to the area of interest (mm²). CD68 was significantly increased in the optic tract (G) and superior colliculus (H) of injured Grn^{-/-} mice compared to all other groups (* indicates p < 0.05). rSHAM represents mice with repeated sham injury. Scale bars represent 500μm: A, B; 250μm D-G. n=4-5 sham/genotype; n=9-10 injured/genotype.

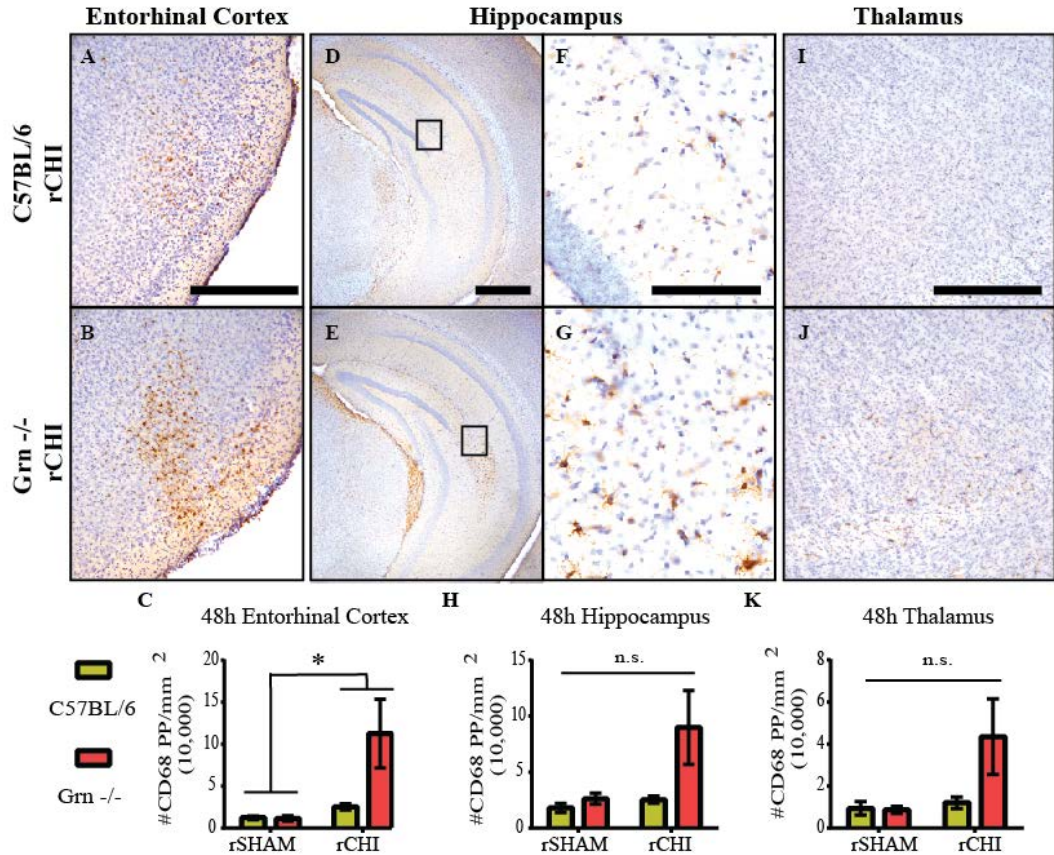


Figure 4.3: Microgliosis was significantly increased in the entorhinal cortex 48h after repeated mild TBI.

Immunohistochemical labeling for cluster of differentiation-68 (CD68) in the entorhinal cortex (A, B), hippocampus (D-G), and thalamus (I, J) 48h after repeated closed head injury (rCHI) in Grn^{-/-} and C57BL/6 mice. The number of CD68 positive pixels were counted and normalized to the area of interest (mm²). CD68 was significantly increased in the entorhinal cortex of mice receiving rCHI compared to that in mice receiving repeated sham injury (rSHAM; C; * indicates p<0.05). CD68 in the hippocampus (H) and thalamus (K) was not significantly increased among groups. Scale bars represent 500µm: A, B, D, E, I, J; 250µm: F, G. n=4-5 sham/genotype; n=9-10 injured/genotype.

By 7d after injury, activated microglia did not appear as bushy or swollen compared to 48h after injury. In the optic nerve, activated microglia were still observed in injured C57BL/6 (Figure 4.4 A-C) and injured Grn^{-/-} mice (Figure 4.4 D-F). Quantification revealed a significant increase in injured C57BL/6 mice compared to rSHAM groups (interaction $p < 0.05$; post-hoc $p < 0.05$; Figure 4.4G). In the optic nerves of injured Grn^{-/-} mice, microgliosis was further increased compared to all other groups (post-hoc $p < 0.05$).

In the optic tract of injured C57BL/6 mice (Figure 4.5A) the amount of reactive microglia appeared increased compared to 48h after injury, while the response in the superior colliculus (Figure 4.5 D, F) had diminished. For injured Grn^{-/-} mice, the microglial response in the optic tract (Figure 4.5B) and superior colliculus (Figure 4.5 E,G) appeared to persist at an increased level compared to injured C57BL/6. Although microgliosis appeared increased in the optic tract of injured Grn^{-/-} mice compared to injured C57BL/6 mice, quantification of CD68 labeling revealed that 7d after injury microgliosis in the optic tract (Figure 4.5C) was dependent upon injury ($p < 0.05$) but not genotype ($p > 0.05$), such that microgliosis was significantly increased when both injured groups were compared to both sham groups. In the superior colliculus (Figure 4.5H), microgliosis was significantly increased due to injury ($p < 0.05$) and genotype ($p < 0.05$; interaction $p < 0.05$), such that microgliosis was significantly increased in injured Grn^{-/-} mice compared to all other groups. Analyses of CD68 in the entorhinal cortex did not show any significant differences among groups likely due to the variability in this region following injury (Figure 4.6A-C), hippocampus (Figure 4.6D-H), or thalamus (Figure 4.6I-K).

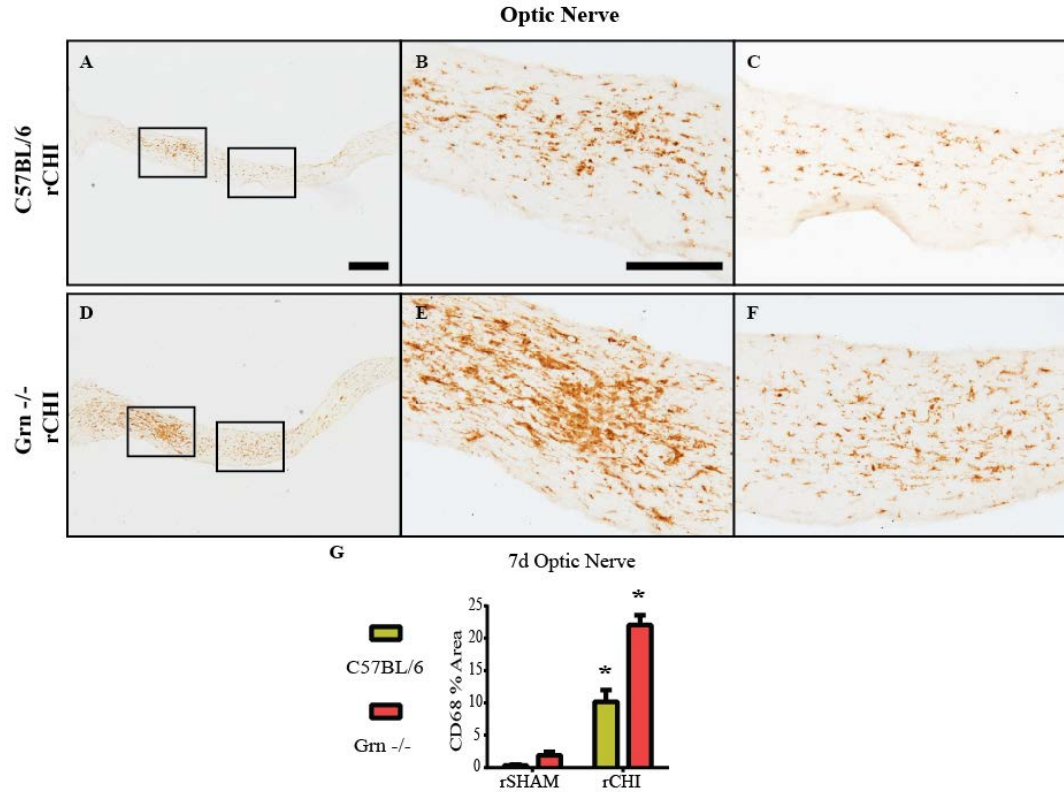


Figure 4.4: Microgliosis was significantly increased in the optic nerves of Grn^{-/-} mice 7d after repeated mild TBI.

Immunohistochemical labeling for cluster of differentiation-68 (CD68) in the optic nerve 48h after repeated closed head injury (rCHI) Grn^{-/-} and C57BL/6 mice. The percent area of CD68 labeling was quantified for analyses. CD68 labeling in injured C57BL/6 mice was significantly increased compared to mice with repeated sham injury (rSHAM). Injured Grn^{-/-} mice were further increased compared to injured C57BL/6 mice. (* indicates p<0.05 compared to all other groups). Scale bars represent 1mm: A, D; 500μm: B, C, E, F. n=4-5 sham/genotype; n=9-10 injured/genotype.

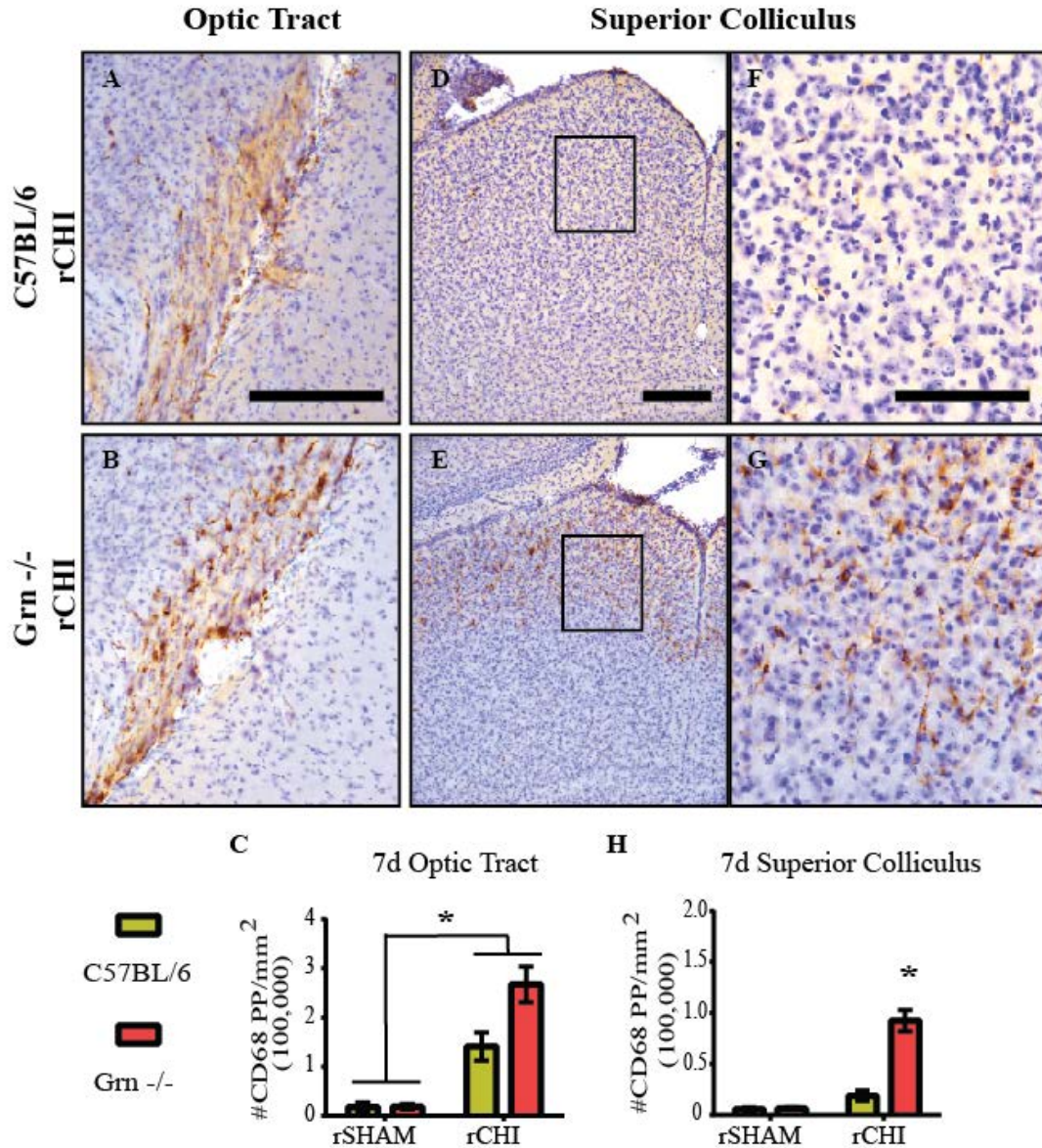


Figure 4.5: Microgliosis was significantly increased in the optic tract and superior colliculus. 7d after repeated mild TBI

Immunohistochemical labeling for cluster of differentiation-68 (CD68) in the optic tract (A, D) and superior colliculus (B, C, E, F) 48h after repeated closed head injury (rCHI) in Grn^{-/-} and C57BL/6 mice. The number of CD68 positive pixels were counted and normalized to the area of interest (mm²). CD68 was significantly increased in the optic tract (C) of injured mice compared to mice receiving repeated sham injury (rSHAM). In the superior colliculus (H), CD68 was significantly increased in injured Grn^{-/-} mice compared to all other groups (* indicates p<0.05). rSHAM represents mice with repeated sham injury. Scale bars represent 500µm: A, B; 250µm D-G. n=4-5 sham/genotype; n=9-10 injured/genotype.

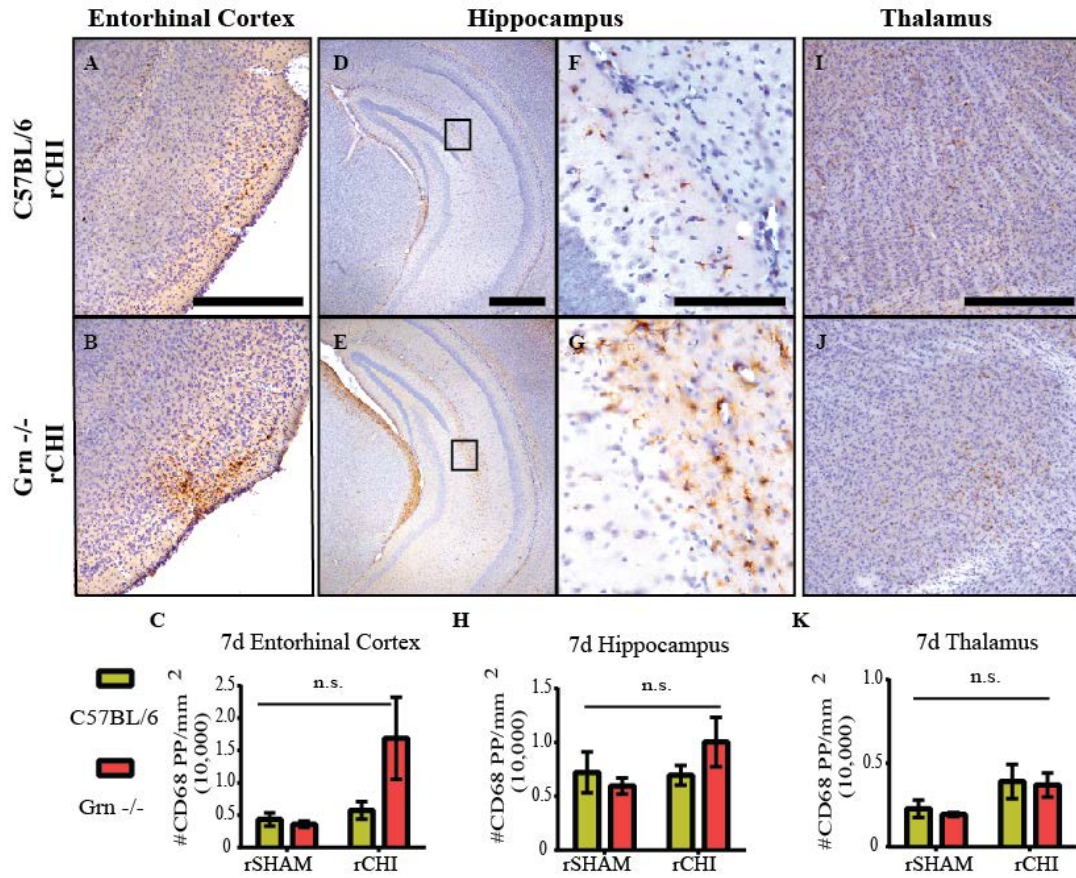


Figure 4.6: Microgliosis was not significantly increased in the entorhinal cortex, hippocampus, or thalamus 7d after repeated mild TBI.

Immunohistochemical labeling for cluster of differentiation-68 (CD68) in the entorhinal cortex (A, B), Hippocampus (D-G), and Thalamus (I, J) 7d after repeated closed head injury (rCHI) in Grn^{-/-} and C57BL/6 mice. The number of CD68 positive pixels were counted and normalized to the area of interest (mm²). CD68 was not significantly increased in the entorhinal cortex (C), hippocampus (H), and thalamus (K) 7d after repeated CHI compared to repeated sham. Scale bars represent 500µm: A, B, D, E, I, J; 250µm: F, G. n=4-5 sham/genotype; n=9-10 injured/genotype.

Effects of Progranulin deficiency on Acute Axonal Injury after Repeated Mild TBI

Optic nerves were examined for axonal injury using SMI-32, a marker for dephosphorylated neurofilament (Trapp, Hauer et al. 1988). In the majority of sham-injured animals, very little positive labeling was observed. However, in cases of injury, neurofilaments are dephosphorylated, disassemble, and accumulate in axonal swellings (Trapp, Hauer et al. 1988). Forty-eight hours and 7d following repeated CHI, SMI-32 positive swellings were observed in C57BL/6 and Grn^{-/-} mice (Figure 4.7 A-L). The percent of overlaid grid squares containing SMI-32 labeling 48h after injury revealed a similar degree of injury between C57BL/6 (40.6 ± 3.7%) and Grn^{-/-} mice (37.7 ± 4.3%) (Figure 4.7M). By 7d, the extent of SMI-32 labeling in Grn^{-/-} mice remained at about the same level (41.1 ± 4.3%), whereas labeling in C57BL/6 injured mice was reduced to 26.2 ± 5.2% (Figure 4.7N). Statistically, SMI-32 labeling was increased with injury (p<0.05) but did not vary with genotype (p>0.05) at both 48h and 7d after the final injury.

Cerebral tissue was labeled with silver stain to detect ongoing neurodegeneration. The staining results in a yellow and copper background stain with argyrophilic neurons and axons staining black (Figure 4.8). Degenerating axons were prevalent in the optic tract of injured C57BL/6 (Figure 4.8 E, F) and Grn^{-/-} (Figure 4.8 M, N) mice, but very little degeneration was observed in the superior colliculus (Figure 4.8 G, H and O, P, respectively). Sham-injured Grn^{-/-} mice also presented with degenerating axons in the optic tract (Figure 4.8 I, J). A few positively labeled cell bodies were present in the entorhinal cortex of a small number of injured animals (not shown), but the majority appeared similar to sham-injured animals. The thalamus and hippocampus were also evaluated qualitatively, and no silver staining was present.

Using an algorithm for color deconvolution we were able to separate the positive stain from the background labeling. Analyses revealed that the percent of silver stain labeling in the optic tract was significantly increased in mice that received rCHI compared to those that received rSHAM (main injury effect $p < 0.05$). $Grn^{-/-}$ mice trended toward an increase in optic tract silver stain ($p = 0.053$), but there was not an interaction between injury and genotype ($p = 0.70$). Silver staining in the superior colliculus was not significantly different among groups ($p > 0.05$).

A subset of animals from the 48h injury cohort was labeled with FJC and examined qualitatively (Figure 4.9). No positive labeling was observed in C57BL/6 sham animals. One of 4 $Grn^{-/-}$ sham animals showed a few positively labeled axons in the optic tract (not shown). All injured animals exhibited FJC-positive axons in the optic tract (Figure 4.9 A, B, D, E) regardless of genotype. Positive swellings and small bulbs were also noted, similar to silver stain labeling in injured animals. In the entorhinal cortex of injured mice, a few positively labeled neurons were also observed (Figure 4.9 C, F).

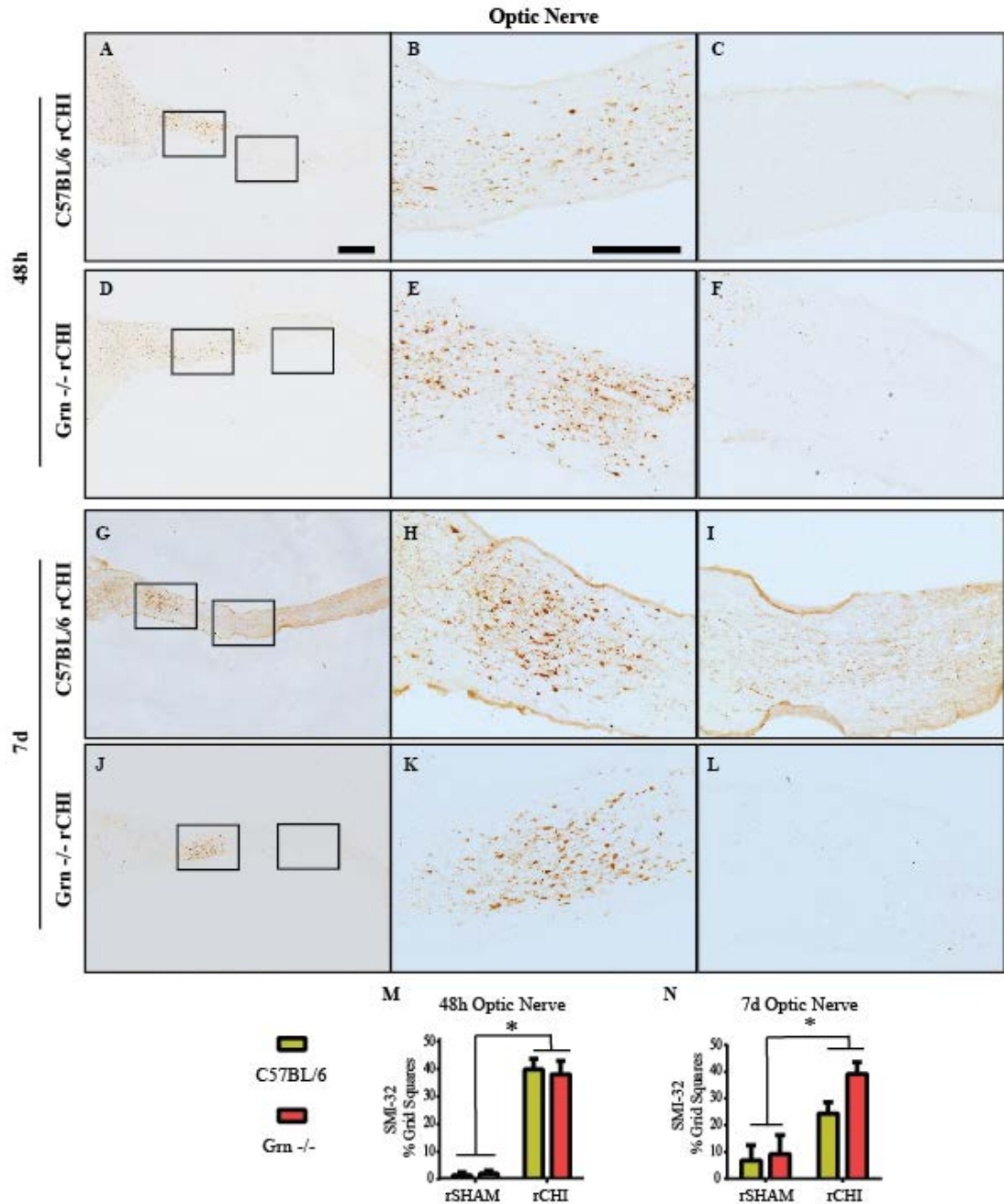


Figure 4.7: Axonal swellings in the optic nerve were observed acutely following repeated mild TBI.

Immunohistochemical labeling for non-phosphorylated neurofilament (SMI-32) 48h (A-F) and 7d (G-L) after repeated closed head injury (rCHI) in Grn^{-/-} and C57BL/6 mice. The percent of SMI-32 positive grid squares was measured in the optic nerve 48h (M) and 7d (N) after rCHI or repeated sham-injury (rSHAM). A significant increase was observed in rCHI groups compared to that in rSHAM (* indicates $p < 0.05$). Scale bars represent 1mm for images in column 1; 500 μ m for images in columns 2 and 3. $n = 4-5$ sham/genotype; $n = 9-10$ injured/genotype.

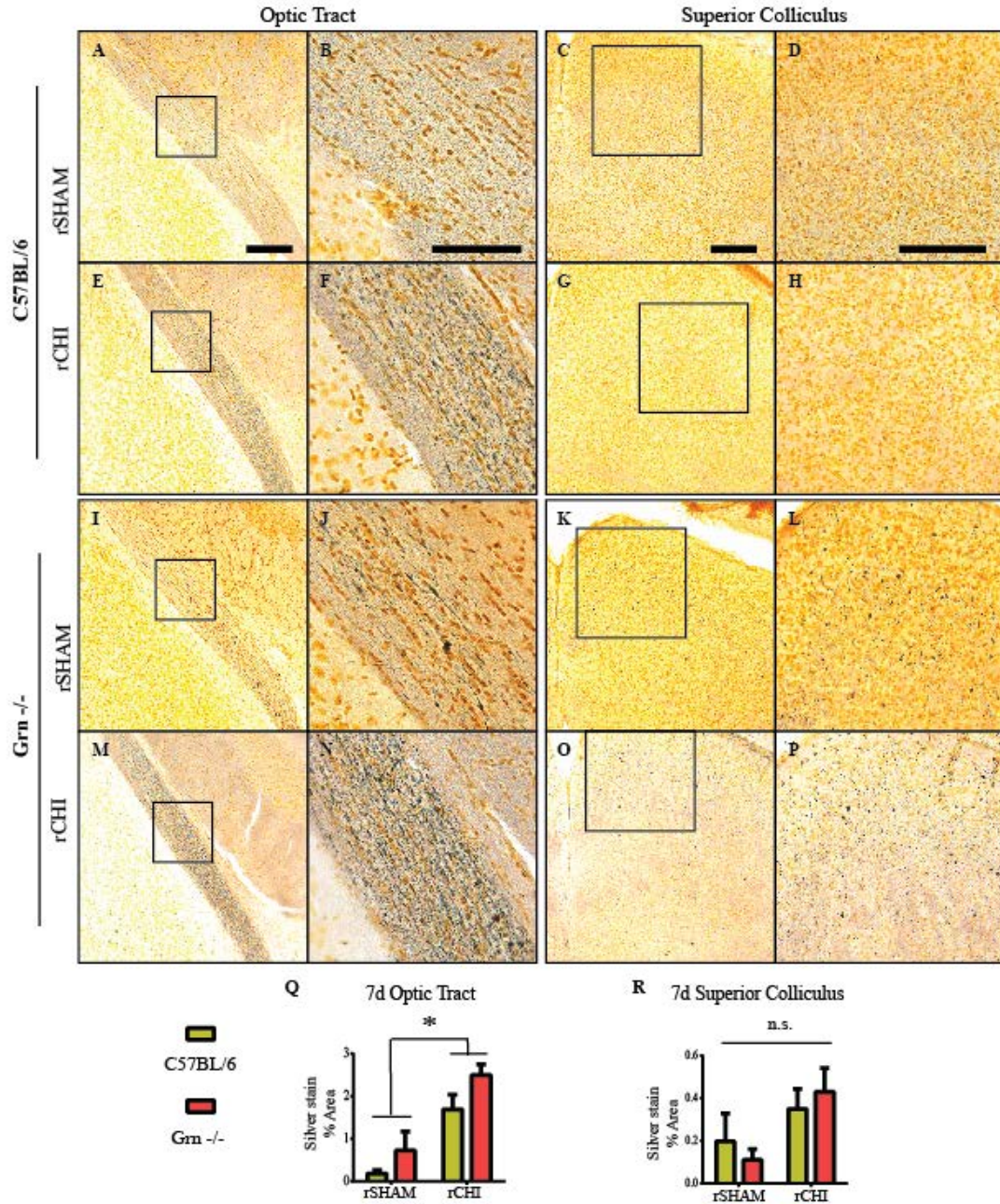


Figure 4.8: Acute neurodegeneration of visual pathway was observed 7d following repeated mild TBI.

Argyrophilic neurons (silver stain) were labeled 7d after repeated closed head injury (rCHI) or repeated sham-injury (rSHAM) in Grn^{-/-} and C57BL/6 mice. The percent of positive silver stain labeling was measured in the optic tract 7d (Q) and superior colliculus (R) of rCHI and rSHAM animals. A significant increase was observed in the rCHI groups compared to that in the rSHAM groups (* indicates p<0.05). Scale bars represent 500µm for images in columns 1, 3, and 4; 250µm for images in column 2. n=4-5 sham/genotype; n=9-10 injured/genotype.

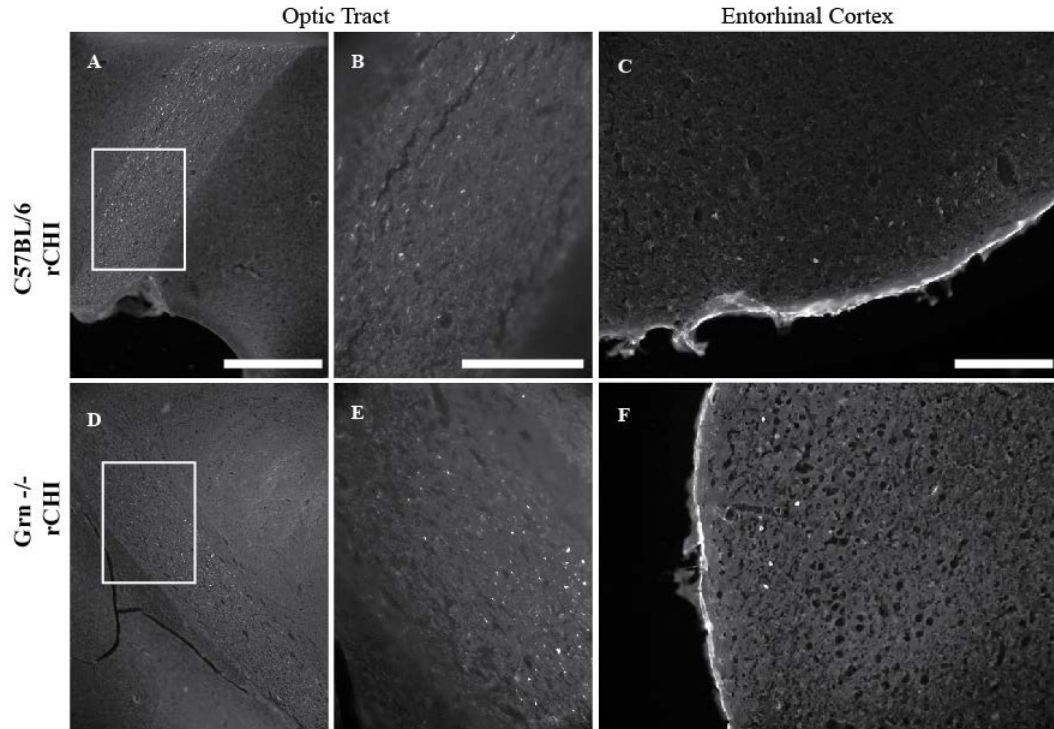


Figure 4.9: Fluor Jade C positive axonal injury in the optic tract and cell death in the entorhinal cortex following repeated mild TBI.

Degenerating neurons were labeled using Fluor Jade C 48h after repeated closed head injury (rCHI) in *Grn*^{-/-} and C57BL/6 mice. Positively labeled axons were observed after rCHI in the optic tract of C57BL/6 mice (A,B) and *Grn*^{-/-} (D,E). FJC-positive neuron cell bodies were identified 48h after rCHI in the entorhinal cortex of C57BL/6 (C) and *Grn*^{-/-} (F) mice. n=2-3 sham/genotype; n= 5-6 injured/genotype.

Progranulin Deficiency did not Affect Recovery of Motor Function Chronically after Repeated Mild TBI

Motor dysfunction was assessed at several time points following injury in sham and CHI animals using a beam walking task for which a score of an eight indicates normal function (Figure 4.10). Repeated CHI resulted in a significant deficit in beam walking performance over the 6 month evaluation period (injury effect $p < 0.05$). Overall, Grn^{-/-} tended to perform worse than C57BL/6 mice on this motor task, but the effect of genotype did not reach statistical significance ($p = 0.06$). Surprisingly this trend was likely driven by poor early performance of the sham Grn^{-/-} mice rather than by greater impairment of the injured Grn^{-/-} mice. Motor function also varied as a function of time after injury ($p < 0.05$) with significantly higher scores on days 56, 112, and 168 as compared to days 1 and 7, consistent with spontaneous recovery of motor function after mild TBI.

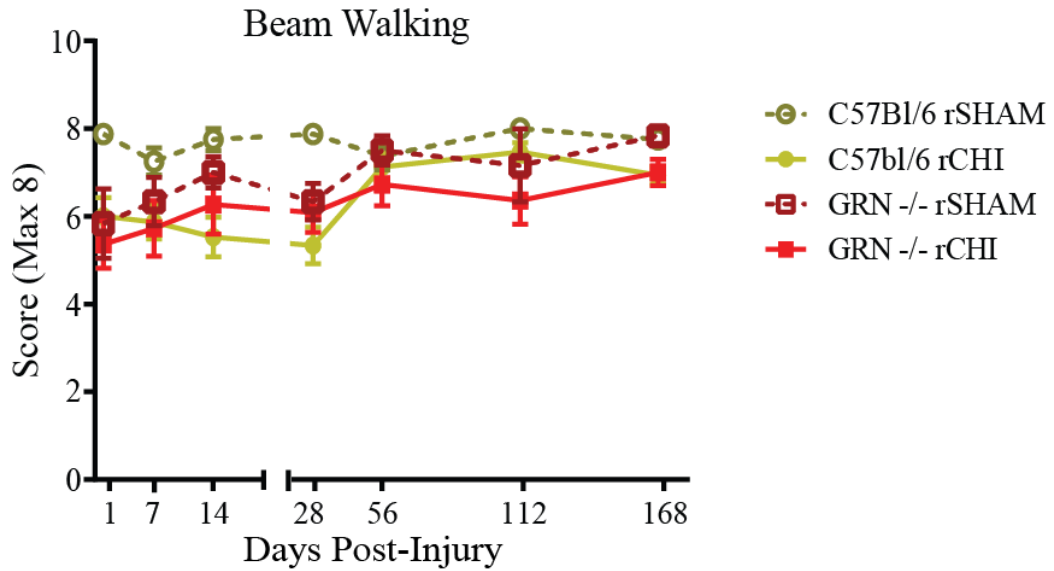


Figure 4.10: Transient motor deficits observed after repeated mild TBI are not worsened in Grn^{-/-} mice.

Behavioral deficits were examined across 6mo in Grn^{-/-} and C57BL/6 mice after repeated closed head injury (rCHI) and repeated sham (rSHAM). (B) The beam walking task was used to identify deficits in motor coordination. A score of 8 indicated perfect performance on the task, with lower scores indicating poorer motor skills. Repeated CHI induced a significant deficit in motor function following injury. Beam walking scores were significantly higher at 56, 112, and 168d compared to scores during the first week. n=6-8 sham/genotype; n=11-15 injured/genotype.

Cognitive Dysfunction Sustained Chronically after Repeated Mild TBI

Cognitive dysfunction was assessed using the NOR task at several time points over the course of the study (Figure 4.11A). Repeated CHI resulted in a significant memory deficit across 7 months post-injury (injury effect $p < 0.05$), and the injury effect was dependent on genotype (interaction $p < 0.05$). Post-hoc analyses revealed that C57BL/6 injured mice and Grn^{-/-} injured mice performed significantly worse than their sham counterparts across time. However, across time, Grn^{-/-} sham mice performed significantly worse than C57BL/6 sham mice. Because NOR scores were not dependent on time ($p > 0.05$), comparisons at specific testing times could not be performed. However, Grn^{-/-} sham mice performed poorly in their initial assessment and during the final two testing periods.

We developed the Novel Mouse Recognition test (NMR) as a means of examining cognition in a context less dependent than NOR on visual cues. Rather, contextual cues such as smell and vocalizations could be used by the test mouse to identify mice. The test was conducted once, 7 mo after injury (Figure 4.11B). On average, sham-injured mice spent a smaller percent of their total exploration time with the familiar mouse on the second testing day compared to the first. A similar change in percent time spent with the familiar mouse was observed in injured C57BL/6 mice. However, injured Grn^{-/-} mice, on average, spent the same percentage of total exploration time with the familiar mouse in both trials suggesting they had less memory recall of the familiar mouse. However, differences among groups did not reach statistical significance (interaction $p = 0.09$).

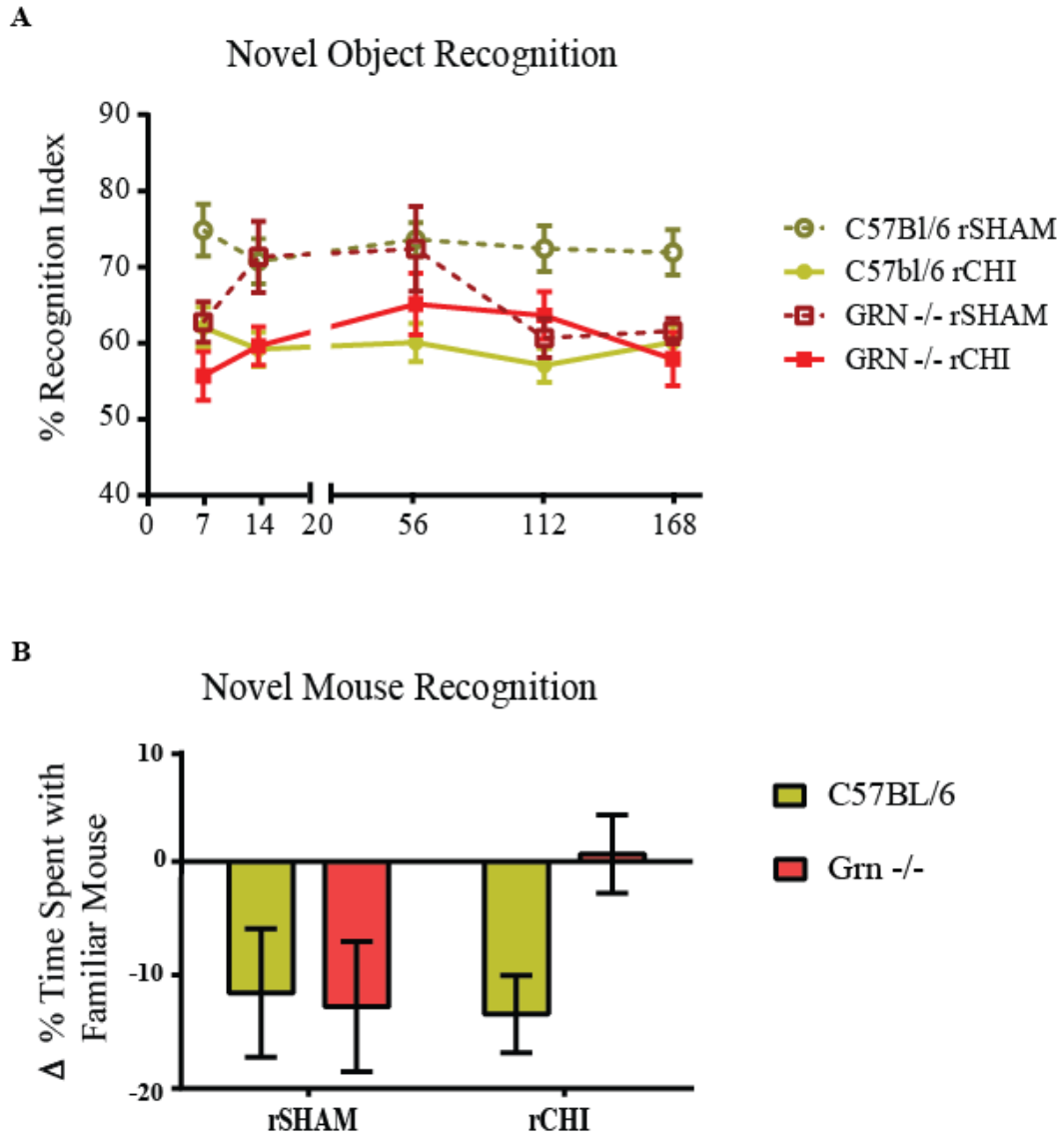


Figure 4.11: Repeated mild TBI induces persistent cognitive dysfunction that is equivalent in C57BL/6 and Grn^{-/-} mice.

Cognitive deficits were examined across 7mo in Grn^{-/-} and C57BL/6 mice after repeated closed head injury (rCHI) and repeated sham (rSHAM). (A) Memory scores in the novel object recognition task were calculated by dividing the time spent exploring the novel object by the total exploration time (recognition index=RI). Grn^{-/-} sham mice performed significantly worse compared to C57BL/6 mice across time. Repeated CHI induced persistent deficits in C57BL/6 and Grn^{-/-} mice relative to their sham counterparts. (B) For the familiar mouse recognition task, memory scores were calculated by subtracting the RI for the familiar mouse during trial 2 from the RI for the familiar mouse during trial 1. Performance was equivalent across groups. n=8-10 sham/genotype; n=15-18 injured/genotype.

Vision is not Grossly Impaired Chronically after Repeated Mild TBI

Mice were tested for visual dysfunction using the visible platform test in the Morris water maze following each day of NOR testing (Figure 4.12A). Based on the average of the best 2 out of 5 trials, mice took ten seconds or less to find the platform. No significant differences were observed among groups ($p > 0.05$). Figure 4.12B shows the results for the average of all five trials for Grn^{-/-} sham mice and two Grn^{-/-} sham mice that were found to only have one eye at time of surgery (Mouse A and Mouse B). The other eye became cloudy over time. These mice served as positive controls for visual dysfunction. Mice were also examined for visual dysfunction using the visual cliff test at 7mo after injury (Figure 4.12C). On average, mice from each group chose the 'safe' side of the box more than the 'cliff' side. No significant differences were observed among groups (injury, genotype, and interaction: $p > 0.05$).

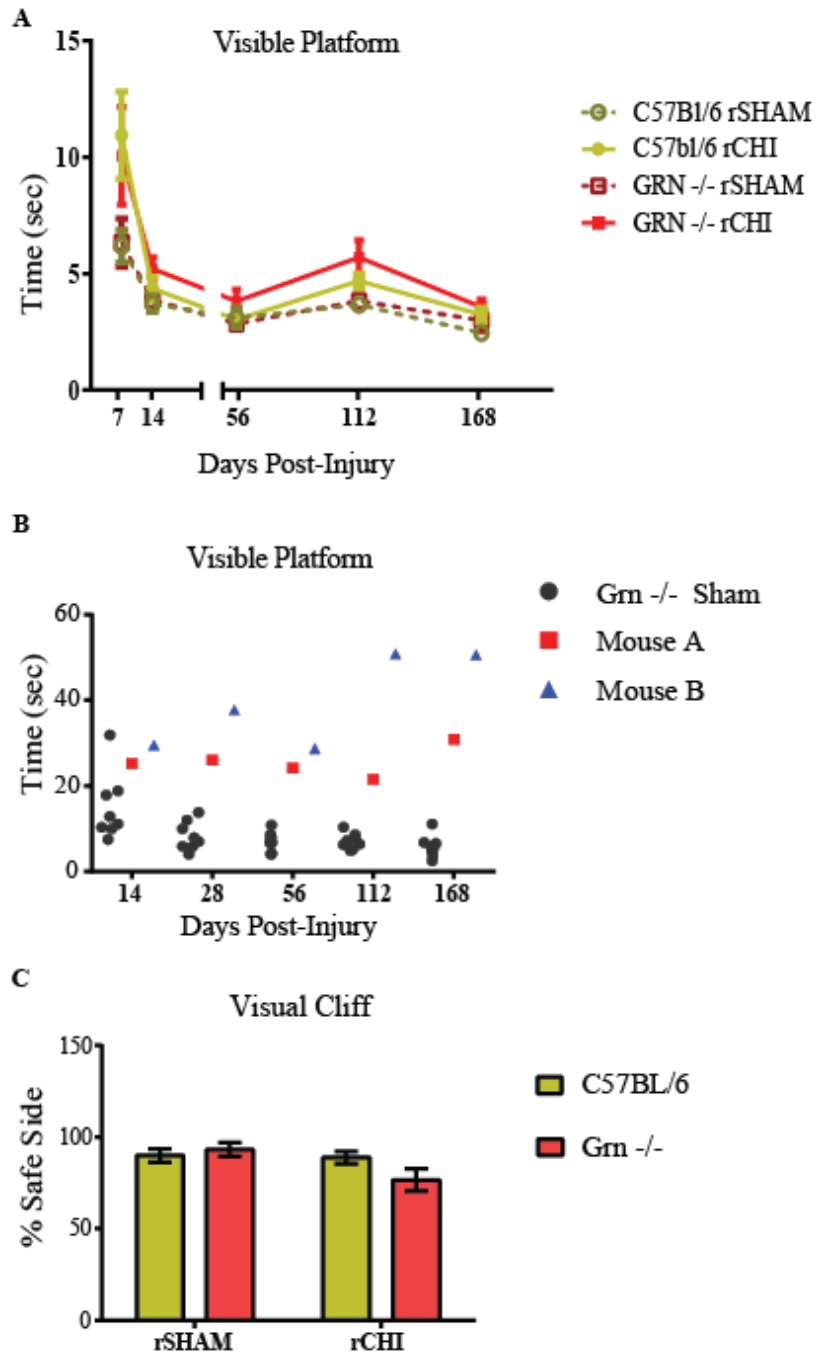


Figure 4.12: Repeated mild TBI did not induce overt deficits in vision.

Deficits in vision were assessed across the 7mo study in Grn^{-/-} and C57BL/6 mice after repeated closed head injury (rCHI) and repeated sham (rSHAM). The amount of time to reach the visible platform in a Morris water maze apparatus was measured (A). There was not a significant increase in the amount of time to reach the platform in any group across time. n=8=10 sham/genotype; n=15-18 injured/genotype. One-eyed Grn^{-/-} mice (Mouse A and B) have increased difficulty finding the platform compared to normal Grn^{-/-} mice (B). In the visual cliff task the percentage of trials the mouse selected the ‘safe’ side of the apparatus was used for analysis (C). There was not a significant difference among groups.

Age-Related Microgliosis in Grn^{-/-} Mice is Amplified in the Optic Tract and Optic Nerve by Repeated Mild TBI

To determine whether rCHI was associated with long-term microgliosis, CD68 was used to label activated microglia in the optic nerve and cerebrum at 7 months after injury. Microgliosis was not observed in sham-injured C57BL/6 mice (Figure 4.13A,B; Figure 4.14 A, F). Seven months after repeated CHI in C57BL/6 mice, a small number of phagocytic microglia were present in a similar region to the acute SMI-32 labeling, close to the chiasm (Figure 4.13 C, D). A small number of reactive microglia were observed in the optic tract (Figure 4.14B) and superior colliculus (Figure 4.14G), but were not observed in the entorhinal cortex (Figure 4.15B), hippocampus (Figure 4.15G) or thalamus (Figure 4.15L).

Unlike the younger cohorts, activated microglia were present in sham-injured Grn^{-/-} mice. Age-related increases in the hippocampus and thalamus of Grn^{-/-} mice have been previously reported (Yin, Dumont et al. 2010). In the optic nerve, the microglia of sham-injured Grn^{-/-} animals (9-10 months of age) appeared reactive with thickened processes and swollen cell bodies throughout the nerve (Figure 4.13 E, F). Similar observations were also observed in the optic tract (Figure 4.14 C) superior colliculus (Figure 4.14 H), entorhinal cortex (Figure 4.15 C), hippocampus (Figure 4.15 H) and thalamus (Figure 4.15 M). A large amount of phagocytic microglia were observed in the optic nerves of injured Grn^{-/-} mice in the same region as acute SMI-32 labeling close to the chiasm, but had also progressed towards the retina (Figure 4.13 G, H). Quantitative analyses indicated optic nerve microgliosis was dependent upon both genotype and injury (interaction $p < 0.05$; Figure 4.13 I). At 7mo after injury, optic nerve microgliosis was not

significantly increased in injured C57BL/6 mice compared to sham. The age-related microgliosis in sham-injured Grn^{-/-} mice was significantly increased compared to C57BL/6 mice (p<0.05). However, repeated CHI in Grn^{-/-} mice further intensified the microglial response in the optic nerve (p<0.05 compared to sham-injured Grn^{-/-} mice). In the optic tract, CD68 labeling was dependent upon genotype and injury (interaction p<0.05; Figure 4.14 E), where repeated CHI induced a chronic upregulation of microglial reactivity selectively in Grn^{-/-} mice (p<0.05 compared to all other groups). In the superior colliculus (Figure 4.14 J), entorhinal cortex (Figure 4.15 E), hippocampus (Figure 4.15 J) and thalamus (Figure 4.15 O), microglial reactivity was dependent on genotype (p<0.05) but not injury (p>0.05) indicating an age-related increase in microgliosis that was not exacerbated 7mo after repeated CHI.

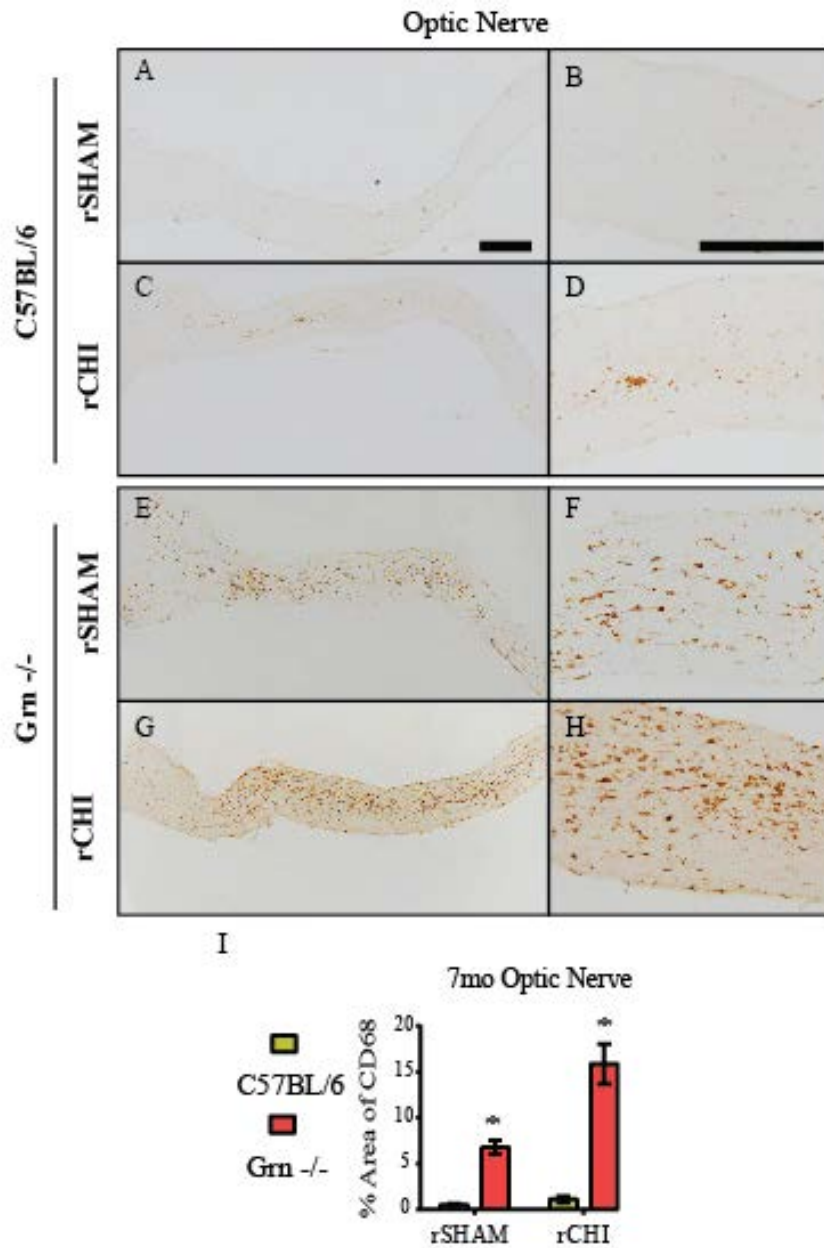
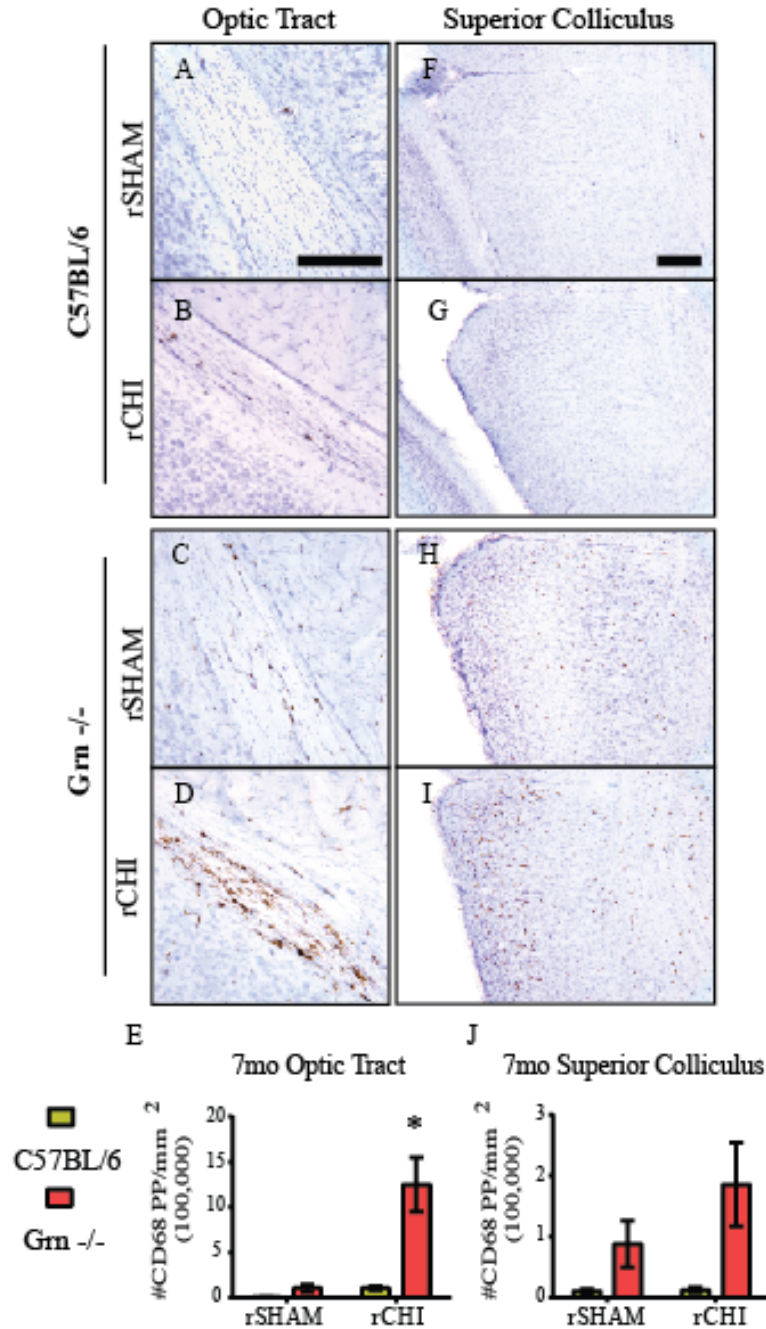


Figure 4.13: Repeated mild TBI in *Grn*^{-/-} mice induced chronically elevated microgliosis in the optic nerve.

Immunohistochemical labeling for cluster of differentiation-68 (CD68) in the optic nerve (A-H) 7mo after repeated closed head injury (rCHI) or repeated sham-injury (rSHAM) in *Grn*^{-/-} and C57BL/6 mice. The number of CD68 positive pixels were counted and normalized to the area of interest (mm²). CD68 labeling was significantly increased in the optic nerve (I) of *Grn*^{-/-} sham animals compared to that in C57BL/6 sham and C57BL/6 rCHI. CD68 was exacerbated after rCHI in *Grn*^{-/-} compared to *Grn*^{-/-} sham mice. (* indicates p<0.05 compared to all other groups). 1mm: A, C, E, D; 500µm: B, D, F, H. n=5 sham/genotype; n=8-9 injured/genotype.



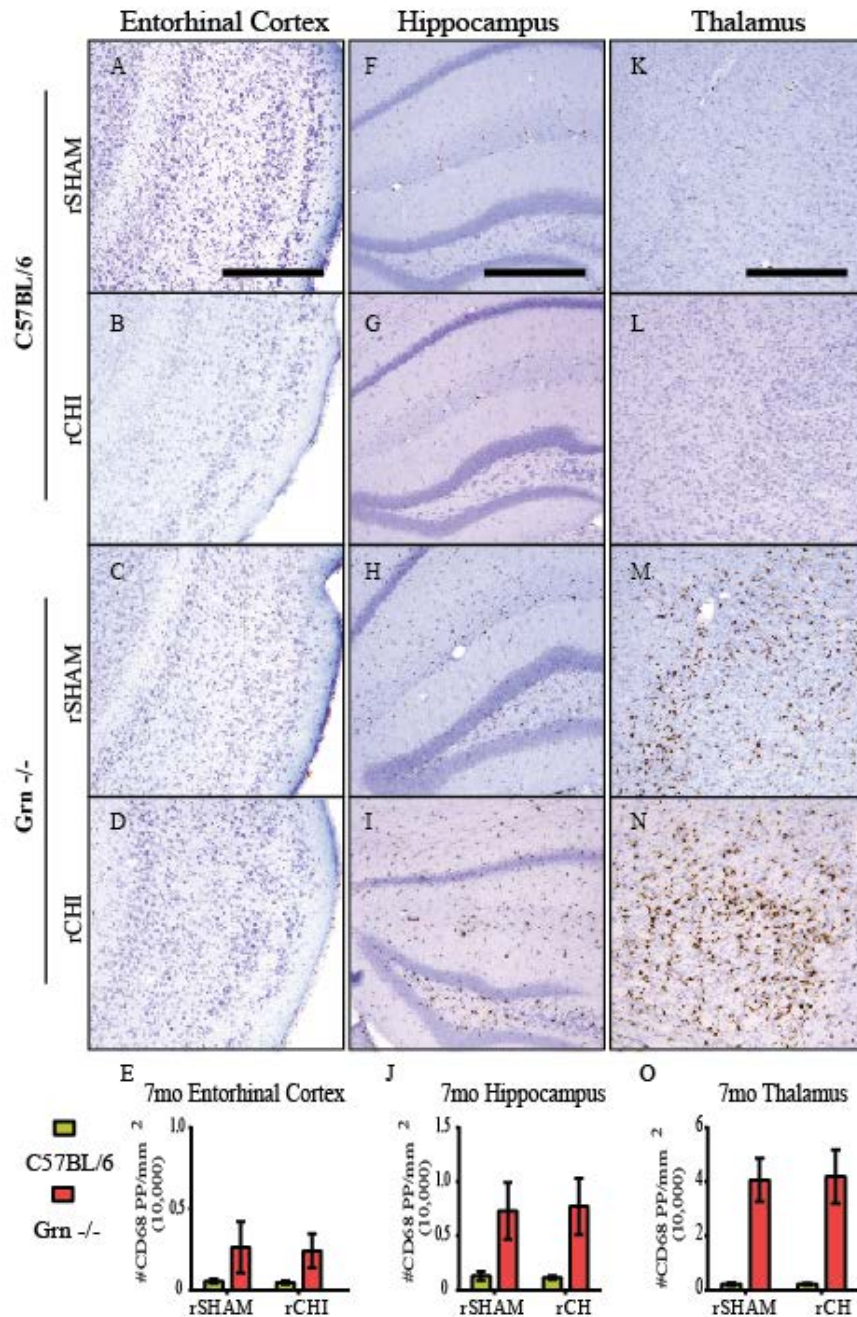


Figure 4.15: Progranulin deficiency results in age-related microgliosis in entorhinal cortex, hippocampus, and thalamus that is not altered by repeated mild TBI.

Immunohistochemical labeling for cluster of differentiation-68 (CD68) in the entorhinal cortex (A-D), hippocampus (F-I), and thalamus (K-N) 7mo after repeated closed head injury (rCHI) in C57BL/6 and Grn^{-/-} mice. The number of CD68 positive pixels were counted and normalized to the area of interest (mm²). CD68 was significantly increased in Grn^{-/-} mice in the entorhinal cortex (E), hippocampus (J), and thalamus (O) but was not significantly influenced by rCHI 7mo after injury. Scale bars represent 500µm. n=5 sham/genotype. n=8-10 injured/genotype.

Progranulin Deficiency Does not Worsen Neurodegeneration after Repeated Mild TBI

To determine whether rCHI initiates neurodegenerative cascades that persist for months after injury, cerebral tissue from the 7mo cohort was labeled with silver stain to detect ongoing neurodegeneration. Sham-injured C57BL/6 animals exhibited only sporadic silver-stained particles in the optic tract (Figure 4.16 A, B). Several axons were labeled in the optic tracts of sham-injured Grn^{-/-} animals (Figure 4.16 I, J). In contrast, injured C57BL/6 and Grn^{-/-} mice exhibited more abundantly stained axons in the optic tract (Figure 4.16 E, F and M, N, respectively) compared to sham animals. No overt differences were noted in injured Grn^{-/-} mice versus injured C57BL/6 mice. Quantitative analyses confirmed increased silver stain accumulation in the optic tract of injured animals ($p < 0.05$ compared to sham) (Figure 4.16 Q) but did not reveal significant differences between Grn^{-/-} mice and C57BL/6 mice (genotype, $p > 0.05$). Axonal staining was also observed in the superior colliculus of Grn^{-/-} mice but not C57BL/6 mice (Figure 4.16). In the superior colliculi of both Grn^{-/-} sham (Figure 4.16 K, L) and Grn^{-/-} injured (Figure 4.16 O, P) mice, large accumulations of silver stain were observed. Similar auto fluorescent labeling was observed in separate tissue sections with both the FITC and TRITC filter (not shown) indicating lipofuscin accumulation in this area as has been previously observed in the hippocampus of 23mo old Grn^{-/-} mice (Ahmed, Sheng et al. 2010).

Neurofilament 200 antibody labels neurofilament heavy chain (Serbest, Burkhardt et al. 2007). In the current study, NF200 was used to detect intact axons. In sham-injured animals, approximately 70% of the region of interest was labeled positively with anti-NF200 (Figure 4.17 I). Repeated CHI significantly reduced the amount of NF200

labeling ($p < 0.05$ compared to sham). Injured C57BL/6 mice showed a reduction in NF200 ($47.8 \pm 3.9\%$) 7mo after injury (Figure 4.17 I). NF200 labeling was further reduced in injured $\text{Grn}^{-/-}$ ($35.7 \pm 4.2\%$) but this was not significantly different from NF200 labeling in C57BL/6 injured mice (Figure 4.17 I).

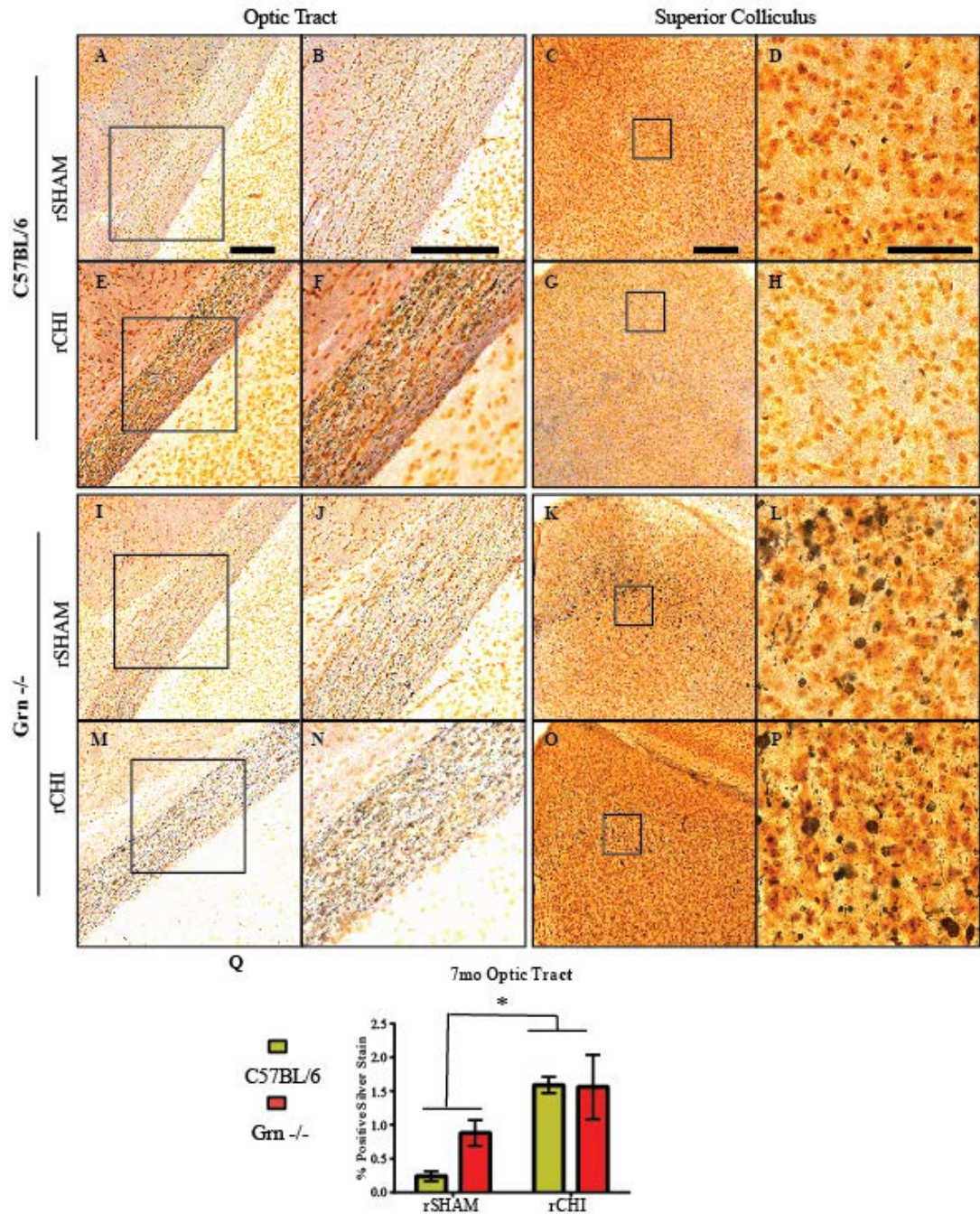


Figure 4.16: Chronic neurodegeneration after repeated mild TBI is not worsened in Grn^{-/-} mice.

Argyrophilic neurons were labeled using silver stain in the optic tract (left two columns) and superior colliculus (right two columns) 7mo after repeated closed head injury (rCHI) in C57BL/6 and Grn^{-/-} mice. The percent of positive silver stain labeling was measured for the optic tract (Q) 7mo after sham or rCHI injury. Scale bars represent 500 μ m. n=5 sham/genotype. n=8-10 injured/genotype.

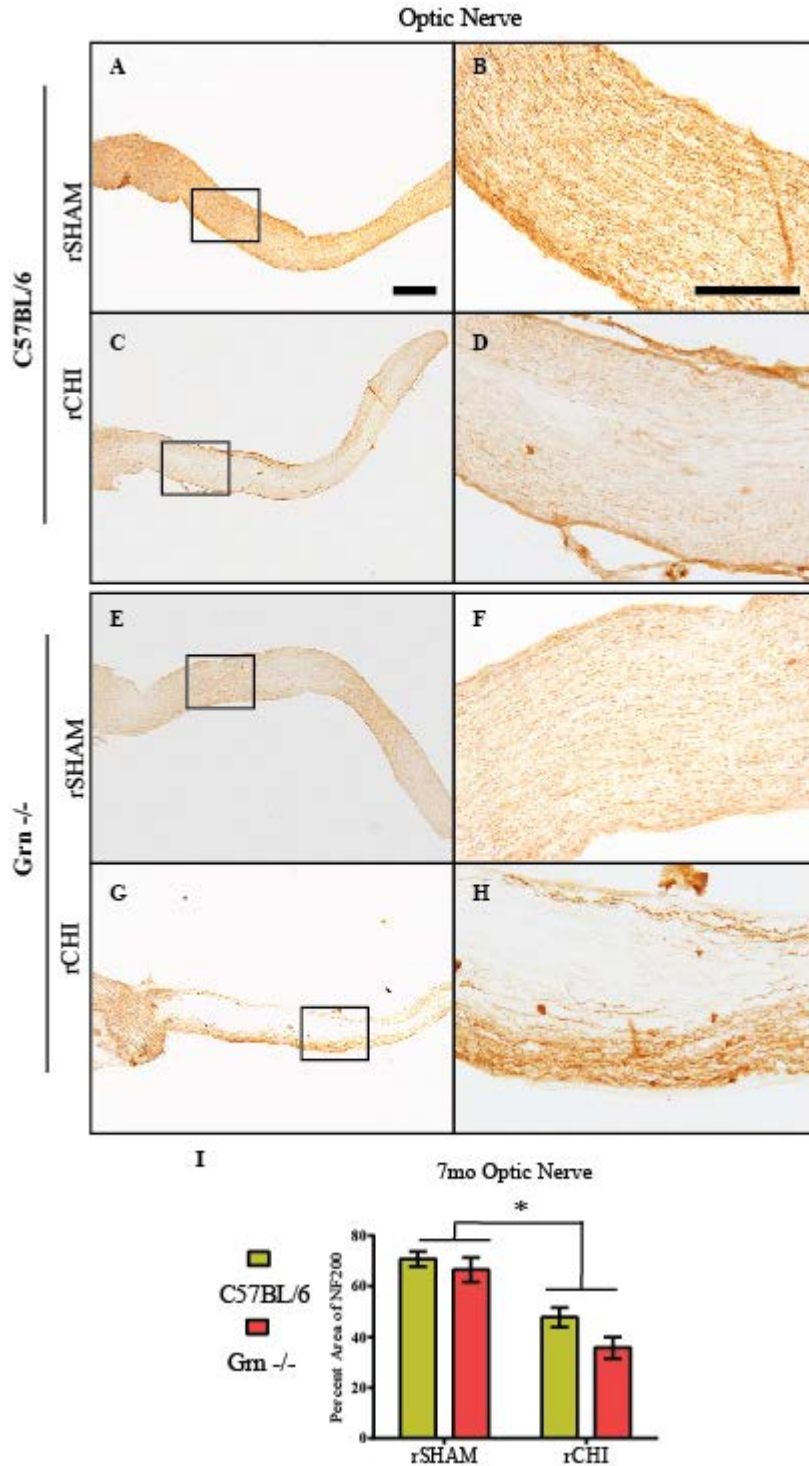


Figure 4.17: Axon loss after repeated mild TBI is not affected by progranulin deficiency. Optic nerves were labeled with neurofilament heavy chain (NF200) antibody to detect axon loss 7mo after repeated closed head injury (rCHI) in C57BL/6 and Grn^{-/-} mice (A-H). The percent area of staining was quantified (I). Scale bars represent 1mm for images in column 1; 500 μ m for images in columns 2. n=5 sham/genotype. n=8-10 injured/genotype.

Absence of Pathological Tau and pTDP43

The line of Grn^{-/-} mice used for the current studies have been previously shown to have age-related accumulations of cytosolic phosphorylated TDP-43 in hippocampal and thalamic neurons by 12 months of age (Yin, Dumont et al. 2010). A subset of mice from our 7mo study (mice at 10mo of age) were immunolabeled to determine whether rCHI resulted in earlier onset of pathology than has been previously reported with naïve mice. However, no positive pathology was observed (data not shown). Two 17mo old Grn^{-/-} mice served as positive controls for immunohistochemical labeling, but positive labeling was not observed using the same antibody described in previous reports (Yin, Banerjee et al. 2010; Yin, Dumont et al. 2010) or a similar antibody generated independently (Neumann, Sampathu et al. 2006). See methods section on immunohistochemistry for details. Pathological tau was observed in our positive control brain tissue from a 3.5mo old rTg4510 tau mouse, but was not observed in Grn^{-/-} or C57BL/6 mice following repeated mild TBI (data not shown).

Discussion

In the present study we support our previous findings that repeated mild TBI in C57BL/6 mice induces acute microgliosis in the visual pathway (Chapter 3) and entorhinal cortex (Chapter 2) and prolonged motor and cognitive dysfunction (Chapter 3). We provide evidence of an acute exaggeration of microgliosis following repeated CHI in Grn^{-/-} mice in the visual pathway, entorhinal cortex, and hippocampus that was not accompanied by worsened axonal injury or neurodegeneration compared to C57BL/6 mice. A seven month longitudinal examination of neurobehavioral consequences of repeated CHI in C57BL/6 mice and Grn^{-/-} mice was conducted. Despite significant increases in microgliosis acutely after injury, Grn^{-/-} mice with rCHI did not perform significantly worse or have prolonged impairment in motor, cognitive, or visual tasks compared to injured C57BL/6 mice. Histopathological analyses 7mo after injury revealed a continued microglial response in the visual pathway that was significantly higher than that in Grn^{-/-} rSHAM or C57BL/6 rCHI and rSHAM mice. While axon loss appeared to be increased in injured Grn^{-/-} mice compared to injured C57BL/6 mice, loss was not significantly different between groups. In addition, silver stain labeled neurodegeneration in the optic tract was similar between injured groups. Thus, increased chronic activation of microglia following repeated mild TBI in Grn^{-/-} mice did not exacerbate axonal injury or neurodegeneration nor did it contribute to worsened behavioral consequences.

In response to TBI, microglia can become quickly activated by debris from damaged axons, release of ATP, or increased glutamate and/or can be activated by peripheral immune cells that infiltrate the brain following BBB breakdown (see review (Hanisch and Kettenmann 2007)). Progranulin is a somatic growth factor that is

expressed in a number of cell types including neurons and microglia (Ahmed, Mackenzie et al. 2007), and is substantially increased following trauma or in cases of neurodegenerative disease (Wang, Wilfred et al. 2010). Because progranulin is a competitive antagonist to TNFR-1, thereby limiting the action of the pro-inflammatory molecule TNF- α (Liu and Bosch 2012), mice lacking progranulin are reported to have an increased microglial response to several types of CNS insults (Yin, Banerjee et al. 2010; Martens, Zhang et al. 2012; Tanaka, Matsuwaki et al. 2013a; Tanaka, Matsuwaki et al. 2013b). For example, the neurotoxin precursor 1-methyl-4-(2'-methylphenyl)-1,2,3,6-tetrahydrophine (MPTP) elicits an increased microglial response in Grn^{-/-} mice compared to Grn^{+/+} mice 24h after 2days of treatment (Martens, Zhang et al. 2012). In the present study, exacerbated microgliosis was also induced acutely following repeated mild TBI in Grn^{-/-} mice compared to that in C57BL/6 control mice. Increased microgliosis in Grn^{-/-} mice due to MPTP treatment (Martens, Zhang et al. 2012) or stab brain injury (Tanaka, Matsuwaki et al. 2013b) is accompanied by a significant loss of neurons within 4d compared to Grn^{+/+} mice. In the current study, increased microgliosis did not correspond with significantly worsened axonal injury or neurodegeneration within a week after injury. Differences in outcome between trauma studies may be due to differences in the mechanisms of primary injury, blood brain barrier disruption versus axonal injury. The phenotype of microglia is influenced by the stimulus activating it (Lucin and Wyss-Coray 2009). Inflammation was strikingly increased in Grn^{-/-} mice following repeated mild TBI. However, substantial blood brain barrier disruption as occurs following a penetrating head injury would allow infiltration of peripheral immune cells that could exacerbate cell death, compared to the inflammatory response due to axonal injury

following a diffuse head injury. Evaluation of cytokine expression after focal versus diffuse injury in progranulin deficient mice are needed to evaluate differences in the functional phenotype of microglia that are independent of histological abnormalities. Furthermore, electrophysiological studies, could determine whether increased microgliosis in $Grn^{-/-}$ mice contributes to an increase in neuronal dysfunction.

In humans, TBI-induced neurodegeneration is typically found in association with chronic inflammation (Soares, Hicks et al. 1995), and microglial release of reactive oxygen species is thought to perpetuate neurodegeneration in a positive feedback manner (Block and Hong 2005). Age-related increases in microglial reactivity have been well characterized in $Grn^{-/-}$ mice (Ahmed, Sheng et al. 2010; Yin, Dumont et al. 2010; Wils, Kleinberger et al. 2012) and were also observed in the present study. However, chronic effects of progranulin deficiency following CNS trauma have not been evaluated until now. We showed increased microglial reactivity out to 7mo after repeated CHI that was significantly elevated compared to that in age-matched $Grn^{-/-}$ sham mice. Evaluation of chronic neurodegeneration revealed a similar amount of silver staining in the optic tract and no significant difference in optic nerve axon loss between C57BL/6 and $Grn^{-/-}$ mice 7mo after rCHI, suggesting that increased microgliosis induced by repeated CHI in progranulin deficient mice does not worsen chronic neurodegeneration.

Persistent memory dysfunction and transient motor dysfunction have been previously observed following repeated mild TBI (Meehan, Zhang et al. 2012; Mannix, Meehan et al. 2013; Aungst, Kabadi et al. 2014; Mouzon, Bachmeier et al. 2014). We anticipated that an increase in neurodegeneration following rCHI in $Grn^{-/-}$ mice that would induce worsened behavioral function due to the inability for signal transduction.

The behavioral testing paradigm was modified from our previous mild TBI studies (Chapter 3) to create slightly easier tasks. As a result, five CHI repeated at 24h inter-injury intervals in C57BL/6 mice showed a resolved motor dysfunction by 8wks following injury. However, memory dysfunction continued to persist throughout the 7month testing period. Repeated CHI in Grn^{-/-} mice did not induce worsened behavioral consequences compared to deficits in injured C57BL/6 mice. While inflammation was strikingly different between injured Grn^{-/-} and C57BL/6 mice, chronic neurodegeneration and behavioral dysfunction were similar supporting the relationship between neurodegeneration and cognitive dysfunction that is independent of microgliosis.

Cognitive dysfunction has been previously reported to occur in naive Grn^{-/-} mice as early as 9mo of age (Ghoshal, Dearborn et al. 2012) simultaneous to significant accumulations of ubiquitin or lipofuscin (Ahmed, Sheng et al. 2010), but no deficits in motor skills has been previously reported (Yin, Dumont et al. 2010; Wils, Kleinberger et al. 2012). The deficits observed in Grn^{-/-} mice during our first NOR testing and acute motor testing may be due, in part, to an increase in anxiety as has been reported to occur as early as 2-3mo of age (Kayasuga, Chiba et al. 2007; Yin, Dumont et al. 2010). Whereas, the deficits in NOR testing 5 and 6mo after injury may be due to age-related cognitive dysfunction. Future studies with these mice may include longer periods of acclimation prior to injury than were conducted in the present study in an effort to minimize the influence of anxiety on the test. The lack of deficits in the visible platform trial and visual cliff task after rCHI in either group suggests that the deficits in motor and cognitive tests may not be overtly influenced by the degeneration of the optic nerve and visual pathway. The authors recognize that these testing paradigms are not sufficient to

completely rule out visual dysfunction as changes in visual acuity have been detected following a mild blast injury that induces increased microgliosis in the visual pathway using a virtual reality Optometry System (Reiner, Heldt et al. 2015). For the purposes of the present study, vision does not appear to affect other behavioral consequences of injury.

In humans, cytosolic inclusions of pTDP43 are used as a marker for frontotemporal lobar degeneration in individuals with progranulin mutations (Arai, Hasegawa et al. 2006; Neumann, Sampathu et al. 2006). While several other independently generated $Grn^{-/-}$ mouse strains do not report TDP43 pathology (Ahmed, Sheng et al. 2010; Ghoshal, Dearborn et al. 2012; Petkau, Neal et al. 2012), the strain utilized in the current study has been previously reported to have age-related pathology consisting of cytosolic pTDP43 accumulation (Yin, Banerjee et al. 2010; Yin, Dumont et al. 2010). In our hands, we were unable to detect any pTDP43 accumulations with the same antibody used by Yin and colleagues or another pTDP43 antibody in 17mo old mice or mice receiving rCHI prohibiting us from evaluating the effects of rCHI on pTDP43 accumulation. Tau pathology in FTLD occurs separately from FTLD with TDP43 and does not occur with age in $Grn^{-/-}$ mice (Ghoshal, Dearborn et al. 2012; Wils, Kleinberger et al. 2012). However, tau and TDP43 pathology occurs in cases of the TBI-induced neurodegenerative disease Chronic Traumatic Encephalopathy (CTE) (McKee, Stein et al. 2015). In mice, tau pathology following mild TBI has been reported, although it is observed primarily in studies of blast injury (see review (Ojo, Mouzon et al. 2016)). Tau pathology has not been observed in our previous studies (Chapter 2 and 3) nor in

other mouse models of closed head injury in which the head is fixed (Ojo, Mouzon et al. 2013; Mouzon, Bachmeier et al. 2014).

In conclusion, we have provided evidence of increased microgliosis acutely after repeated mild TBI in $\text{Grn}^{-/-}$ mice that remains elevated up to 7mo after injury compared to aged $\text{Grn}^{-/-}$ sham mice or C57BL/6 injured mice. Microgliosis was increased in injured $\text{Grn}^{-/-}$ mice. However, repeated mild TBI in $\text{Grn}^{-/-}$ mice did not cause increases in axonal injury or neuronal degeneration, nor was there an association with worsened behavioral deficits compared to injured C57BL/6 mice. Our study does not support the hypothesis that increased inflammation following TBI contributes to chronic neurodegeneration.

CHAPTER 5: Acute Ibuprofen Treatment following Repeated Mild Traumatic
Brain Injury Does Not Reduce Chronic Neurodegeneration or Neurobehavioral
Dysfunction

Preface

For the following chapter, study design and interpretation of results were conducted by Amanda Bolton Hall and Kathryn Saatman. Surgery procedures, tissue processing, immunohistochemistry of cerebrum tissue, histological analyses of all cerebrum tissue, analysis of behavioral data, and statistics were performed by Amanda Bolton Hall. Behavioral testing and silver staining of cerebrum tissue was conducted by Jennifer Brelsfoard. Optic nerves were processed, labeled using immunohistochemistry and analyzed by Binoy Joseph.

Introduction

Traumatic brain injuries (TBI) cause neurodegeneration that is typically found in association with chronic inflammation (Soares, Hicks et al. 1995). Microglia are the immune cells of the brain that react quickly (Frugier, Morganti-Kossmann et al. 2010) in response to axonal injury and blood brain barrier disruption and can persist years after injury (Papadopoulos and Lecanu 2009; Smith, Gentleman et al. 2013; Faden and Loane 2015). Persistent neuroinflammation has been implicated in a number of chronic symptoms associated with TBI including epilepsy, depression and cognitive impairment (Ramlackhansingh, Brooks et al. 2011; Bramlett and Dietrich 2015). Little has been reported on neuroinflammation in cases of the TBI-induced neurodegenerative disease Chronic Traumatic Encephalopathy (CTE) (Saing, Dick et al. 2012; Faden and Loane 2015). However, mouse models of repeated mild TBI have reported microgliosis up to 12 months after injury (Mouzon, Bachmeier et al. 2014). In addition, repeated mild TBI in tau-transgenic mice causes an increase in tau pathology associated with increased inflammation (Ojo, Mouzon et al. 2013) suggesting a role for microglia in CTE-like pathology.

Repeated mild TBI in progranulin-deficient ($Grn^{-/-}$) mice resulted in exacerbated microgliosis in the visual pathway persistent out to 7mo after injury (Chapter 4). Progranulin has both anti- and pro-inflammatory characteristics and acts as a modulator of inflammation in the CNS. Other studies have also shown that insults to the CNS in $Grn^{-/-}$ mice via bacterial (Yin, 2010) or chemical toxin (Martens, Zhang et al. 2012) and stab brain injury (Tanaka, Matsuwaki et al. 2013a) can cause an exacerbation of acute microgliosis. However, in our previous study, exacerbation of microgliosis in $Grn^{-/-}$ mice

following repeated mild TBI did not induce significant increases in neuronal degeneration or axon loss compared to that in injured C57BL/6 wildtype mice (Chapter 4). Our data suggests that the continued degeneration of neurons after injury may not be propagated by chronically activated microglia.

To further examine the role of microgliosis in chronic neurodegeneration following repeated mild TBI we utilized the well-known over-the-counter drug ibuprofen. Ibuprofen is a non-steroidal anti-inflammatory drug (NSAID) that non-selectively inhibits cyclooxygenases (COX-1 and COX-2) and acts as an agonist to PPAR γ ((Kaufmann, Andreasson et al. 1997; Lehmann, Lenhard et al. 1997; Kojo, Fukagawa et al. 2003). Some debate surrounds the mechanism of ibuprofen's therapeutic effect. Nevertheless, a 7d ibuprofen treatment has been shown to reduce cytokine expression following diffuse TBI (Cao, Thomas et al. 2012). Gopez and colleagues have also reported reduced prostaglandin production by using COX inhibitors in an animal model of stroke (Gopez, Yue et al. 2005). Animal models of global and focal ischemic stroke have also shown a reduction in neuronal injury and improved neurobehavioral outcomes following treatment with ibuprofen (Kuhn, Steimle et al. 1986; Cole, Patel et al. 1993; Patel, Drummond et al. 1993; Antezana, Clatterbuck et al. 2003) and other COX inhibitors (Gopez, Yue et al. 2005; Thau-Zuchman, Shohami et al. 2012; Shang, Cheng et al. 2014). Chronic administration (several months) of ibuprofen has shown therapeutic efficacy in mouse models of Alzheimer's disease (Ogawa, Umegaki et al. 2000; Jantzen, Connor et al. 2002), but following TBI chronic administration of ibuprofen worsened cognitive outcomes in mice (Browne, Iwata et al. 2006). Therefore the current study examined the acute and chronic effects of a short-term ibuprofen treatment following

repeated mild TBI on activated microglia, axonal injury, and neurobehavioral function. We hypothesized that ibuprofen administration would reduce the acute microglial response following repeated mild TBI leading to a decrease in neuronal injury. In our long-term behavioral study, we hypothesized an early 2wk administration of ibuprofen would limit the injury-induced chronic microgliosis observed previously in $Gm^{-/-}$ mice (Chapter 4) leading to a reduction in neuronal injury and better motor and cognitive outcomes.

Materials and Methods

Animals

A total of 117 mice were used for the following studies. Two breeder trios (2F:1M) of progranulin knockout mice (B6(Cg)-*Grn*^{tm1.1Aidi}/J) were also purchased from Jackson Laboratories (Bar Harbor, ME) to establish an in-house colony. Progranulin knockout (*Grn*^{-/-}) mice were developed using C57BL/6 blastocysts and mice were backcrossed for at least five generations (Yin, Banerjee et al. 2010) prior to arrival at The Jackson Laboratory, where they were bred to C57BL/6J inbred mice for at least one generation according to The Jackson Laboratory. Purchased C57BL/6 mice were used as a suitable wildtype control for *Grn*^{-/-} mice. Two month old male and female, C57BL/6 mice were purchased from Jackson Laboratories (Bar Harbor, ME). Upon arrival, mice were group housed under a controlled 14:10 light: dark cycle and provided food and water *ad libitum* and allowed to acclimate for one week before breeding or use for experiments. Animal husbandry and all surgical procedures were approved by the University of Kentucky Institutional Animal Care and Use Committee and followed the federal guidelines set by the Institute of Laboratory Animal Resources (U.S.) and Committee on the Care and Use of Laboratory Animals.

Closed Head Injury

Closed head injuries (CHI) were performed as previously described in Chapter 2. In brief, anesthesia was induced by placing mice into a chamber of 3% isoflurane/3% oxygen for 1-2 minutes before being transferred into a stereotaxic frame with non-rupture Zygomar ear cups (Kopf, Instruments, Tujunga, CA) where anesthesia was maintained using 2.5% isoflurane/2.5% oxygen delivered via a nose cone. An injection of 0.2ml of

1:200,000 epinephrine and 0.5% bupivacaine (Henry Schein Animal Health, Dublin, OH) in sterile, normal saline was placed under the scalp for local analgesia, and the scalp was resected. CHI was induced using a pneumatically controlled cortical impact device (TBI-0310 Impactor, Precision Systems and Instrumentation, Fairfax Station, VA) with a 5mm diameter, pliant, silicone tip with a hardness of 55 Shore A. The tip was aligned along the midline suture between the bregma and lambda sutures. The device was programmed to impact at an intended depth of 2.0mm at a 3.5m/sec velocity with a 500msec dwell time. Immediately after injury, mice were removed from the stereotaxic frame and placed in supine position on a heating pad. Apnea duration and righting reflex were assessed. After righting, mice were re-anesthetized briefly in order to suture their scalps. 1mL of sterile, normal saline was injected subcutaneously to promote hydration and recovery prior to returning to the heating pad. Sham-injured mice received anesthesia and underwent the same surgical procedure without receiving an impact. The total duration of anesthesia before CHI or sham injury was controlled to be 10 minutes. Sham and CHI injuries were repeated five times at twenty-four hour intervals. During these subsequent procedures, sutures were removed, the scalp was resected, and then the above injury and assessment procedures were performed.

Experimental Design

C57Bl/6 mice with and without ibuprofen treatment received repeated CHI or sham injury and a histological assessment was conducted 48h and 7d following the final injury. Grn^{-/-} mice with and without ibuprofen treatment received repeated CHI or sham injury and behavioral assessment was conducted across 7mo followed by histological examination. These studies were performed in parallel with the studies reported in

Chapter 4. Thus, data collected acutely in C57Bl/6 mice and chronically in Grn^{-/-} mice that did not receive ibuprofen treatment are re-evaluated here in comparison to mice receiving ibuprofen treatment.

Ibuprofen Treatment

Ibuprofen was supplemented into the mouse chow at 375ppm. This dose is identical to studies on TBI and Alzheimer's disease where it was effective at reducing microglial reactivity and cytokine expression (Lim, Yang et al. 2000; Jantzen, Connor et al. 2002; Cao, Thomas et al. 2012). The ibuprofen supplemented chow replaced the normal chow immediately following the first injury. For the acute studies, ibuprofen supplemented chow was provided until euthanasia at 48h or 7d. For chronic studies, ibuprofen supplemented chow was provided for a total of two weeks. Mice and food were weighed every day during the first two weeks of the study for all groups. Mice remained group housed following injury. Therefore, food weights were divided by the number of mice within each cage to estimate the amount of food consumed.

Behavioral Testing

Behavioral testing was conducted in parallel with behavioral testing discussed in Chapter 4. Therefore, the methods pertaining to behavioral testing are identical to those in Chapter 4.

Histopathology

Histopathological assessment was conducted in parallel with histology discussed in Chapter 4. Therefore, the methods pertaining to histopathology including

staining/labeling of tissue and quantification were taken from Chapter 4 and are provided below for convenience.

Statistics

For behavioral testing over several time points, as occurred with NOR, beam walking, and visible platform, a repeated measures 3-way ANOVA was performed (treatment x injury x time). For behavioral testing at one time point, as occurred with NMR and visual cliff, and histological analysis a 2-way ANOVA was performed (treatment x injury). When appropriate, Neuman-Keuls post-hoc analyses were performed. All data are presented as means with standard error.

Results

Apnea and Righting Reflex

Sham injury did not induce apnea in either genotype in any cohort. The righting reflex response in sham animals averaged (across surgery days) between 1 and 1.5 minutes.

In all cohorts, apnea following CHI varied with the number of CHI ($p < 0.05$) but was not dependent on treatment ($p > 0.05$; interaction $p > 0.05$). Post-hoc analysis revealed the apnea responses were increased following CHI 1 and CHI 2 compared to that after CHI 3-5 ($p \leq 0.05$) indicating a decrease in apneic episode with repeated CHI.

In all cohorts, the righting reflex response varied as a function of injury ($p < 0.05$) and number of CHI ($p < 0.05$; interaction $p < 0.05$), but not treatment ($p > 0.05$). Post-hoc analyses of the 48h cohort revealed a significant increase in the time to right following the first CHI compared to that following sham injury or CHI 2-5. In the 7d cohort, the times to right were significantly increased following the first and second CHI compared to that following sham injury or CHI 3-5, but were not significantly different from each other. And in the 7mo cohort, the righting reflex response was significantly lengthened after all CHI compared to the response in sham-injured animals. The time to right following the first CHI was significantly increased compared to the righting reflex response following subsequent injuries, and the response following the second CHI was significantly increased compared to that after CHI 3-5. Together these responses show a diminishing righting reflex response with repeated CHI as has been reported previously (Chapters 2-4).

Table 5.1: Apnea following mild TBI in Grn ^{-/-} and C57Bl/6 decreases with subsequent injuries.

			CHI 1	CHI 2	CHI 3	CHI 4	CHI 5
48h cohort	rCHI	C57BL/6	# 30 ± 6	# 23 ± 5	14 ± 3	14 ± 4	10 ± 2
		C57BL/6 + Ibup.	30 ± 5	26 ± 6	10 ± 1	10 ± 1	10 ± 3
7d cohort	rCHI	C57BL/6	# 14 ± 2	# 15 ± 2	12 ± 5	7 ± 1	8 ± 1
		C57BL/6 + Ibup.	27 ± 7	21 ± 6	10 ± 1	5 ± 2	8 ± 2
7mo Cohort	rCHI	Grn ^{-/-}	# 20 ± 4	# 22 ± 4	14 ± 5	9 ± 2	7 ± 1
		Grn ^{-/+} Ibup.	24 ± 5	24 ± 6	14 ± 3	17 ± 6	13 ± 4

For 48h, 7d, and 7mo cohorts, the duration of apnea was significantly increased after the first and second closed head injury (CHI 1 and CHI 2) (# indicates p<0.05 compared to CHI 3-5). n=10/genotype for 48h and 7d cohorts; n=15-16/genotype for the 7mo cohort.

Table 5.2: Righting Reflex following mild in Grn ^{-/-} and C57BL/6 mice decreases with subsequent injuries.

			CHI 1	CHI 2	CHI 3	CHI 4	CHI 5
48h cohort	rSHAM	C57BL/6	1:02 ± 0:03	1:23 ± 0:12	1:26 ± 0:09	1:15 ± 0:06	1:23 ± 0:06
		C57BL/6 + Ibup.	1:12 ± 0:12	1:25 ± 0:08	1:22 ± 0:05	1:29 ± 0:07	1:23 ± 0:08
	rCHI	C57BL/6	*				
		C57BL/6 + Ibup.	7:05 ± 1:29	2:46 ± 0:27	2:24 ± 0:10	1:56 ± 0:11	2:10 ± 0:09
7d cohort	rSHAM	C57BL/6	1:15 ± 0:08	1:11 ± 0:02	1:15 ± 0:05	1:35 ± 0:05	1:26 ± 0:05
		C57BL/6 + Ibup.	1:30 ± 0:12	1:42 ± 0:07	1:16 ± 0:05	1:15 ± 0:10	1:25 ± 0:06
	rCHI	C57BL/6	\$ #	\$ #			
		C57BL/6 + Ibup.	2:54 ± 0:32	3:35 ± 0:43	1:57 ± 0:13	1:29 ± 0:06	1:43 ± 0:08
7mo Cohort	rSHAM	Grn ^{-/-}	1:20 ± 0:07	1:26 ± 0:06	1:23 ± 0:06	1:24 ± 0:04	1:25 ± 0:06
		Grn ^{-/-} + Ibup.	1:15 ± 0:06	1:37 ± 0:07	1:35 ± 0:05	1:31 ± 0:09	1:32 ± 0:08
	rCHI	Grn ^{-/-}	*	*	\$	\$	\$
		Grn ^{-/-} + Ibup.	6:11 ± 0:50	4:01 ± 0:37	2:55 ± 0:44	2:18 ± 0:11	1:56 ± 0:13
			8:17 ± 1:16	6:43 ± 1:11	3:22 ± 0:28	3:16 ± 0:45	2:06 ± 0:26

In the 48h cohort, repeated closed head injury (rCHI) groups had a significant increase in time to right (* indicates p<0.05 compared to rSHAM group). n=5 sham/genotype; n=10 injured/genotype. In the 7d cohort, Grn ^{-/-} mice had a significant increase in time to right after the first and second CHI (\$ indicates p<0.05 compared to Grn ^{-/-} sham mice; # indicates p<0.05 compared to CHI 3-5). n=5 sham/genotype; n=9 injured/genotype. In the 7mo cohort, rCHI groups had a significant increase in time to right following the first CHI and second CHI (* indicates p<0.05 compared to CHI 2-5; \$ indicates p<0.05 compared to rSHAM). n=9-10 sham/genotype; n=15-16 injured/genotype.

Microgliosis is Attenuated by Ibuprofen in the Optic Tract 7d after Repeated Mild TBI

Microgliosis was examined by using a marker for cluster of differentiation-68 (CD68). 48h and 7d after the final surgery, minimal positive labeling was observed in sham-injured mice with and without ibuprofen treatment (not shown).

In C57BL/6 mice receiving rCHI, positively labeled microglia were observed 48h after the final injury in the optic nerve (Figure 5.1 A-C), optic tract (Figure 5.2 A), superior colliculus (Figure 5.2 B, C), and entorhinal cortex (Figure 5.3 A). C57BL/6 mice receiving ibuprofen supplemented chow had a similar amount of CD68 positive microglia in the optic nerve (Figure 5.1 D-F), optic tract (Figure 5.2 D), and entorhinal cortex (Figure 5.3 E) but a reduced amount in the superior colliculus (Figure 5.2 E, F). Microgliosis in the hippocampus (Figure 5.3 B, C, F, G), and thalamus (Figure 5.3 D, H) of injured animals with and without ibuprofen treatment were minimally increased in comparison to sham animals (not shown). Quantification of CD68 was performed across these regions. Microgliosis in the optic nerve (Figure 5.1 G), optic tract (Figure 5.2 G) and superior colliculus (Figure 5.2 H) was significantly increased with injury ($p < 0.05$) but was not altered by ibuprofen treatment. Microgliosis in the entorhinal cortex (Figure 5.3 I) and thalamus (Figure 5.3 K) were not significantly different from sham animals. In the hippocampus (Figure 5.3 J), microgliosis was significantly dependent upon treatment ($p < 0.05$) but not injury ($p > 0.05$) such that ibuprofen treatment increased the number of CD68 positive pixels compared to that in C57BL/6 mice without treatment.

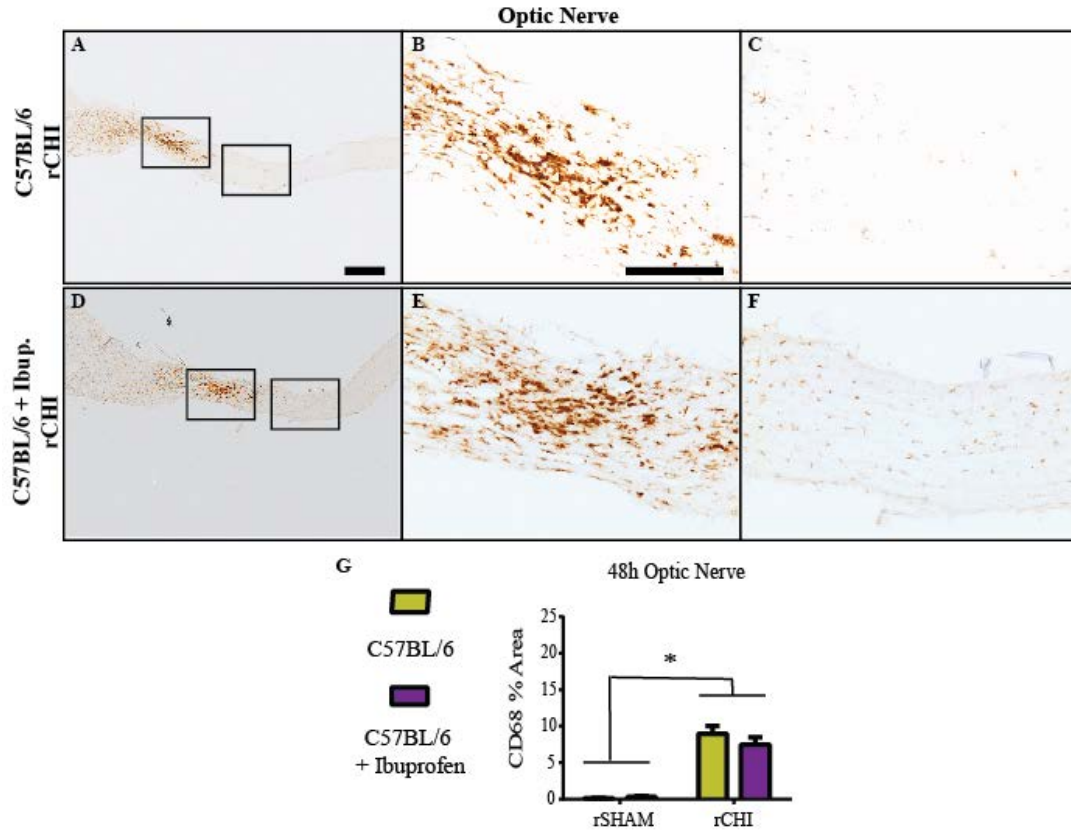


Figure 5.1: Ibuprofen did not reduce optic nerve microglial reactivity in C57BL/6 mice 48h after repeated mild TBI.

Immunohistochemical labeling for cluster of differentiation-68 (CD68) in the optic nerve 48h after repeated closed head injury (rCHI) in C57BL/6 mice with (D-F) and without (A-C) ibuprofen treatment. The percent area of CD68 labeling was quantified for analyses. CD68 labeling was significantly increased after rCHI (G) compared to repeated sham injury (rSHAM) animals (* indicates $p < 0.05$). Scale bars represent 1mm: A, D; 500 μ m: B, C, E, F. n=4-5 sham/treatment; n=8-9 injured/treatment.

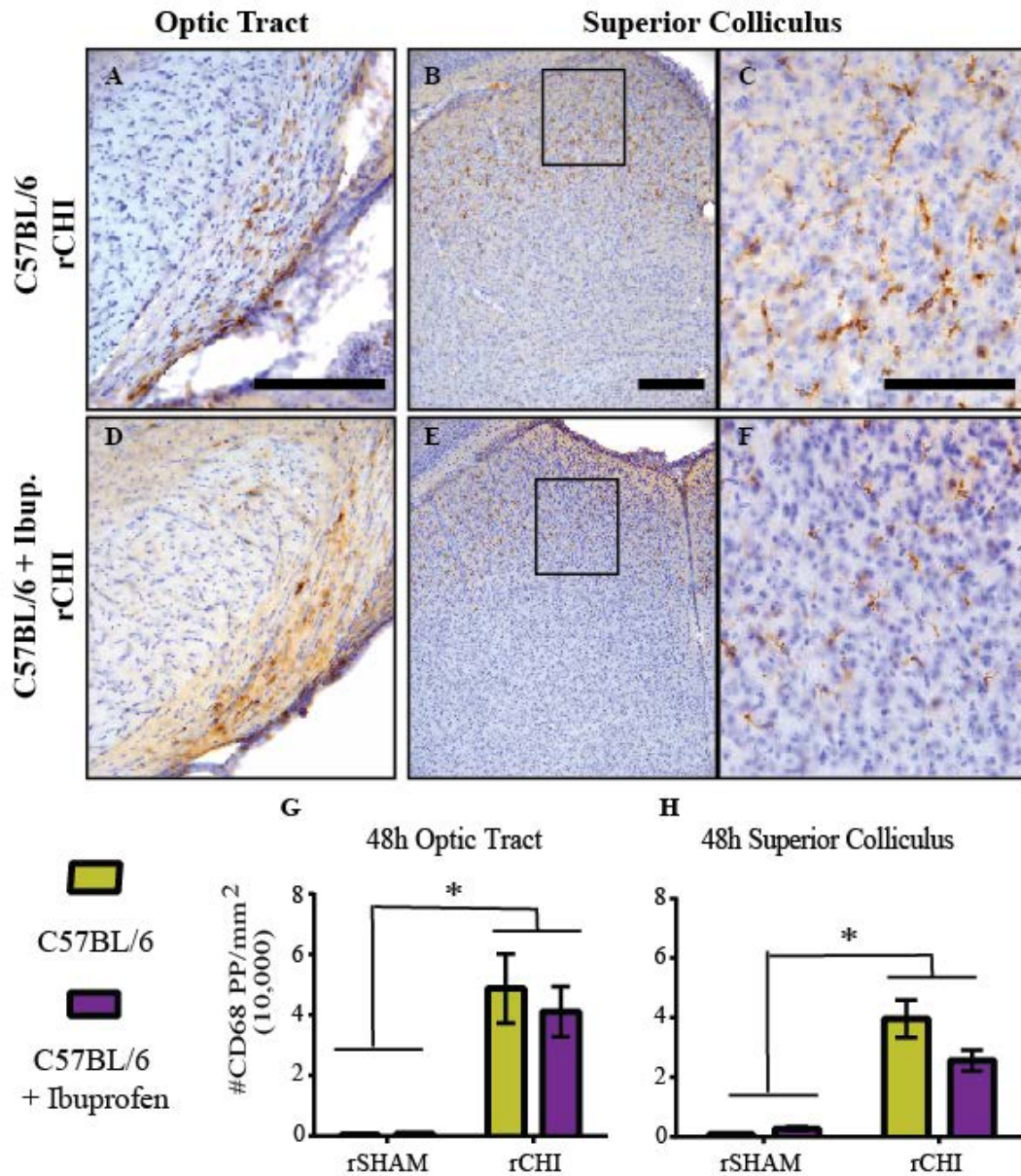


Figure 5.2: Ibuprofen did not significantly reduce microgliosis in optic tract or superior colliculus of C57BL/6 mice 48h after repeated mild TBI.

Immunohistochemical labeling for cluster of differentiation-68 (CD68) in the optic tract (A, D) and Superior Colliculus (B, C, E, F) 48h after repeated closed head injury (rCHI) in C57BL/6 mice with and without ibuprofen treatment. The number of CD68 positive pixels were counted and normalized to the area of interest (mm²). CD68 labeling was significantly increased in the optic tract (C) and superior colliculus (H) of injured mice compared to repeated sham injury (rSHAM) groups (* indicates p<0.05), but was not significantly reduced by ibuprofen treatment. Scale bars represent 500µm: A, B; 250µm D-G. n=4-5 sham/treatment; n=8-9 injured/treatment.

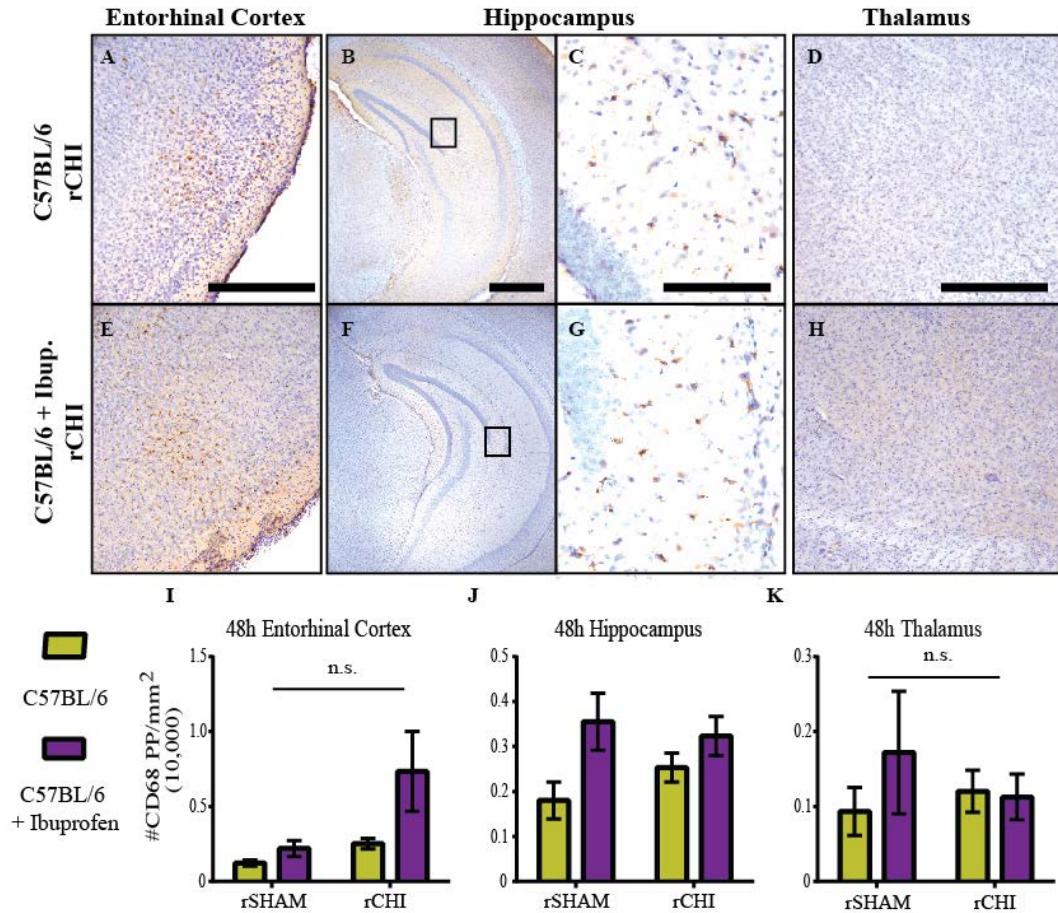


Figure 5.3: Microgliosis was not increased in the entorhinal cortex, hippocampus, or thalamus 48h after repeated mild TBI.

Immunohistochemical labeling for cluster of differentiation-68 (CD68) in the entorhinal cortex (A, E) hippocampus (B, C, F, G) and thalamus (D, H) 48h after repeated closed head injury (rCHI) in C57BL/6 mice with and without ibuprofen treatment. The number of CD68 positive pixels were counted and normalized to the area of interest (mm²). No significant differences were observed with injury or treatment in the entorhinal cortex (I) or thalamus (K). The number of CD68 positive pixels in the hippocampus (H) was significantly increased following rCHI, but was significantly increased due to ibuprofen treatment (J). Scale bars represent 500µm:A, B, D, E, I, J; 250µm: F, G. n=4-5 sham/treatment; n=8-9 injured/treatment.

By 7d after injury, reactive microglia were still observed in the optic nerve (not shown), optic tract (Figure 5.4 A) and entorhinal cortex (Figure 5.5 A) of injured animals. Quantification of CD68 labeling revealed regional differences in the amount of microglial reactivity due to rCHI and the effects of ibuprofen treatment. In the optic tract, microglial reactivity was increased with injury ($p < 0.05$) and varied with ibuprofen treatment ($p < 0.05$; interaction $p < 0.05$). Untreated, brain-injured C57BL/6 mice exhibited increased microglial reactivity, and ibuprofen treatment significantly attenuated posttraumatic microgliosis in the optic tract ($p < 0.05$; Figure 5.4 G) reducing it to a level comparable to that in sham mice. In the entorhinal cortex the regional spread of activated microglia appeared confined primarily to cortical layers II and III, and analysis of the entire entorhinal cortex did not reveal a significant difference among groups ($p > 0.05$ for injury and treatment; Figure 5.4 C). Similarly, the microglial response in the superior colliculus appeared reduced 7d compared to 48h after rCHI and was not significantly different from that in mice receiving repeated sham injury (Figure 5.3 H). As observed 48h after rCHI, no significant differences were observed in the hippocampus (Figure 5.4 H) or thalamus (Figure 5.4 K) of injured mice.

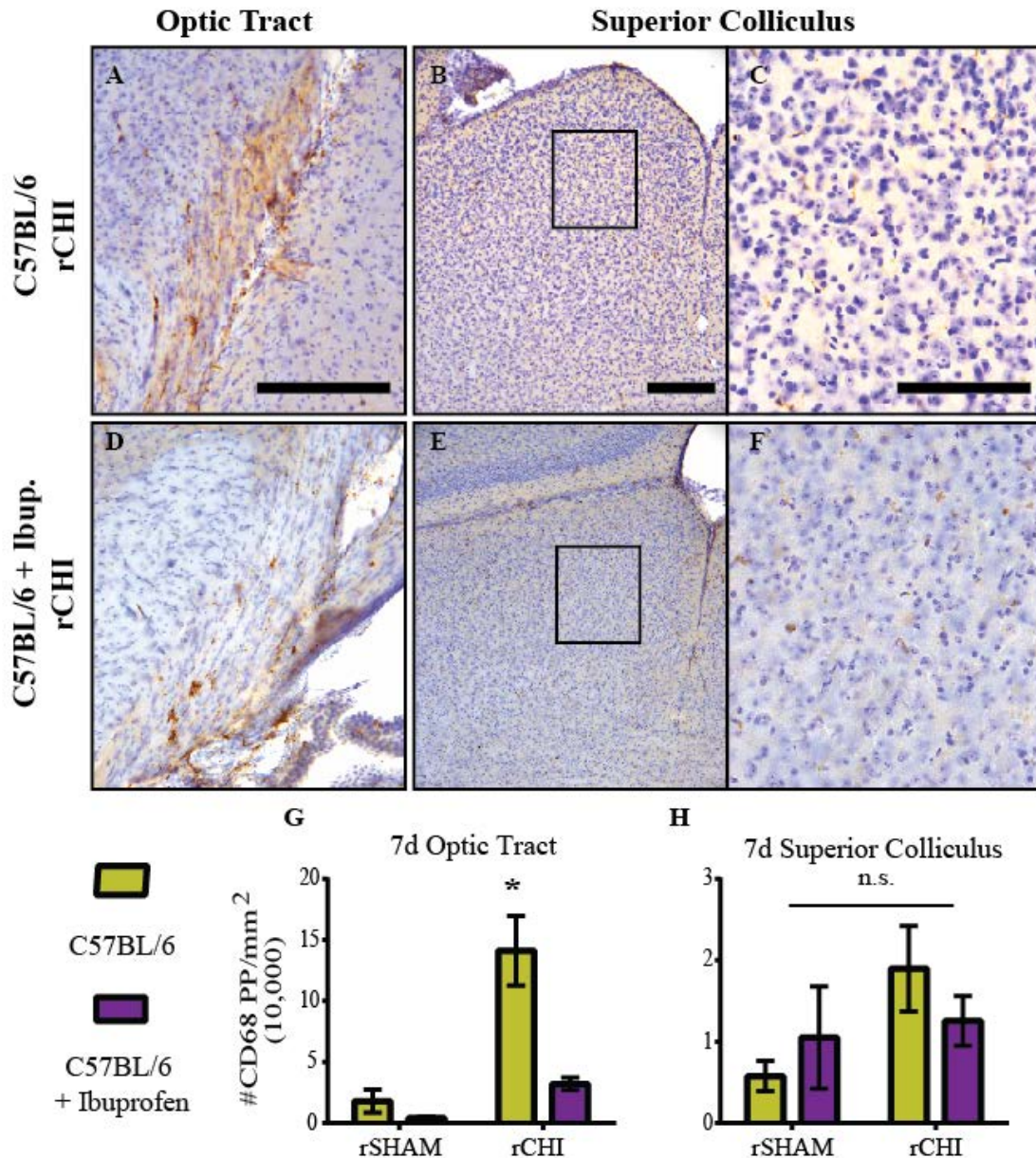


Figure 5.4: Ibuprofen treatment significantly attenuated microgliosis in the optic tract 7d after repeated mild TBI.

Immunohistochemical labeling for cluster of differentiation-68 (CD68) in the optic tract (A, D) and superior colliculus (B, C, E, F) 7d after repeated closed head injury (rCHI) in C57BL/6 mice with and without ibuprofen treatment. The number of CD68 positive pixels were counted and normalized to the area of interest (mm²). In the optic tract, CD68 labeling was significantly increased in C57BL/6 mice without treatment compared to injured C57BL/6 mice with ibuprofen treatment and repeated sham injury (rSHAM) groups (G; *indicates p<0.05). CD68 labeling in the superior colliculus (H) was not significantly different among groups. Scale bars represent 500µm: A, B; 250µm D-G. n=5 sham/treatment; n=10 injured/treatment.

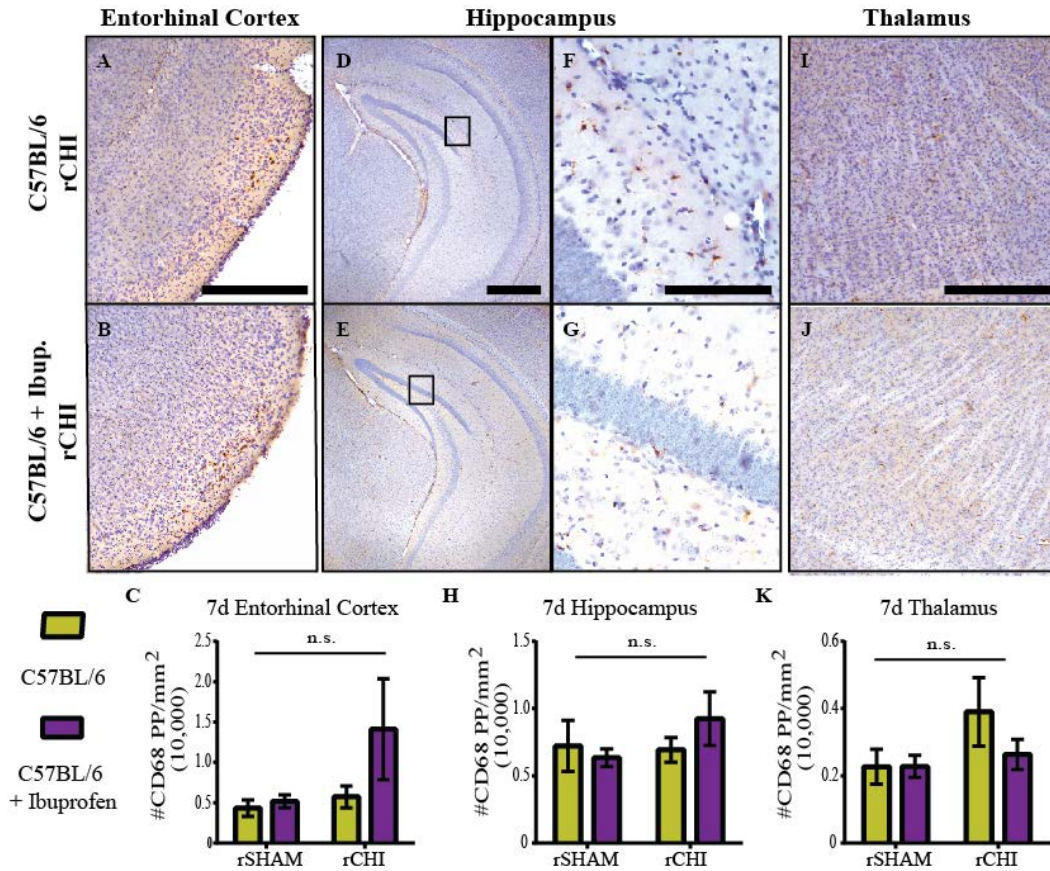


Figure 5.5: Microgliosis was not significantly increased by injury in the entorhinal cortex, hippocampus, or thalamus 7d after repeated mild TBI.

Immunohistochemical labeling for cluster of differentiation-68 (CD68) in the entorhinal cortex (A, B) hippocampus (D-G) and thalamus (I, J) 7d after repeated closed head injury (rCHI) in C57BL/6 mice with and without ibuprofen treatment. The number of CD68 positive pixels were counted and normalized to the area of interest (mm²). CD68 was not significantly increased in the entorhinal cortex (C), hippocampus (H), and thalamus (K) 7d after repeated CHI compared to repeated sham. Scale bars represent 500µm: A, B, D, E, I, J; 250µm: F, G. n=5 sham/treatment; n=10 injured/treatment.

Effects of Ibuprofen Treatment on Acute Axonal Injury after Repeated Mild TBI

The optic nerves were examined for axonal injury using SMI-32, a marker for dephosphorylated neurofilament. In the majority of sham-injured animals, very little positive labeling is typically observed, but following injury neurofilaments are cleaved or dephosphorylated and can accumulate in axonal swellings (Trapp, Hauer et al. 1988). Forty-eight hours and 7d following repeated CHI, SMI-32 positive swellings were observed in C57BL/6 mice with and without ibuprofen treatment. At 48h after injury, semi-quantitative analysis using a grid overlay revealed that, on average, 40% of grid squares contained SMI-32 labeled axonal bulbs or swellings in C57BL/6 mice without treatment, whereas 27% of grid squares were positive, on average, in C57BL/6 mice treated with ibuprofen (Figure 5.6 M). By 7d, the percent of SMI-32 labeling in injured mice without treatment was reduced to 26%, whereas labeling in injured mice with ibuprofen treatment was similar, at 24% (Figure 5.6 N). While ibuprofen treatment appeared to reduce axonal injury 48h after the final injury, statistical analysis revealed that SMI-32 labeling was dependent upon injury ($p < 0.05$) but not treatment ($p > 0.05$) at both 48h and 7d after the final injury.

As previously reported (Chapter 4) cerebral tissue was labeled with silver stain to detect ongoing neurodegeneration. The staining results in a yellow and copper background stain with argyrophilic neurons and axons staining black (Figure 5.7 F, N). Similar amounts of degenerating axons were present in the optic tract of injured mice from both groups (Figure 5.7 E, F, M, N), but little axonal labeling was observed in the superior colliculus (Figure 5.7 G, H, O, P). Positively labeled neuron bodies were observed in the entorhinal cortex of some animals, but most injured animals were without

positive entorhinal cortex labeling. Using an algorithm for color deconvolution to separate the positive stain from the background stain the optic tract and superior colliculus were analyzed for increases in neurodegeneration following rCHI. Analyses revealed that the percent of silver stain accumulation in the regions increased as a function of injury ($p < 0.05$) but was not dependent upon treatment ($p > 0.05$).

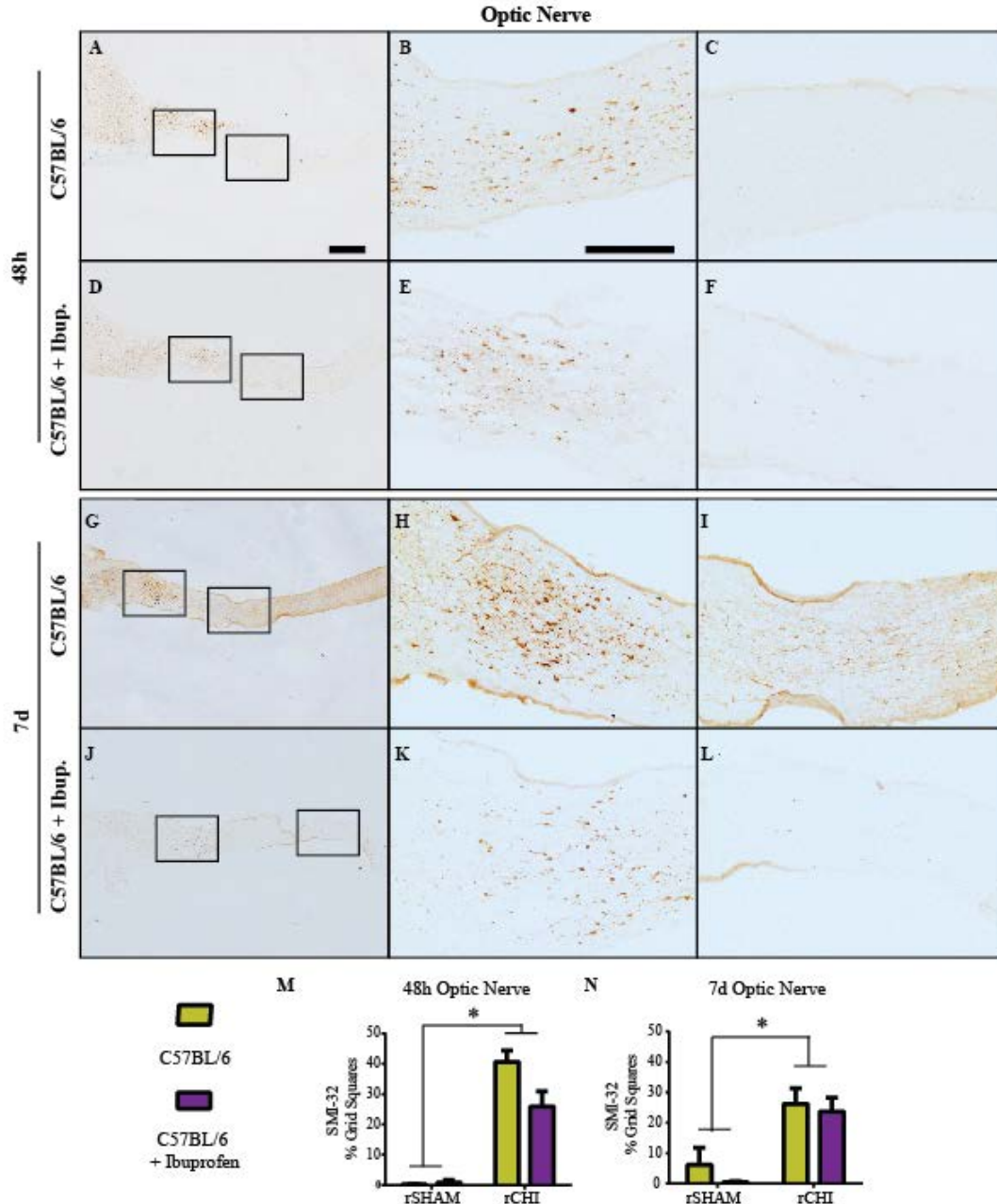


Figure 5.6: Ibuprofen treatment did not significantly reduce the amount of axonal injury following repeated mild TBI.

Immunohistochemical labeling for non-phosphorylated neurofilament (SMI-32) 48h (A-F) and 7d (G-L) after repeated closed head injury (rCHI) in C57BL/6 mice with and without ibuprofen treatment. The percent of SMI-32 positive grid squares was measured in the optic nerve 48h (M) and 7d (N) after rCHI or rSHAM. A significant increase was observed in rCHI groups compared to that in repeated sham-injured (rSHAM) groups (* indicates $p < 0.05$). Scale bars represent 1mm for images in column 1; 500 μ m for images in columns 2 and 3. $n = 5$ sham/treatment; $n = 8-9$ injured/treatment.

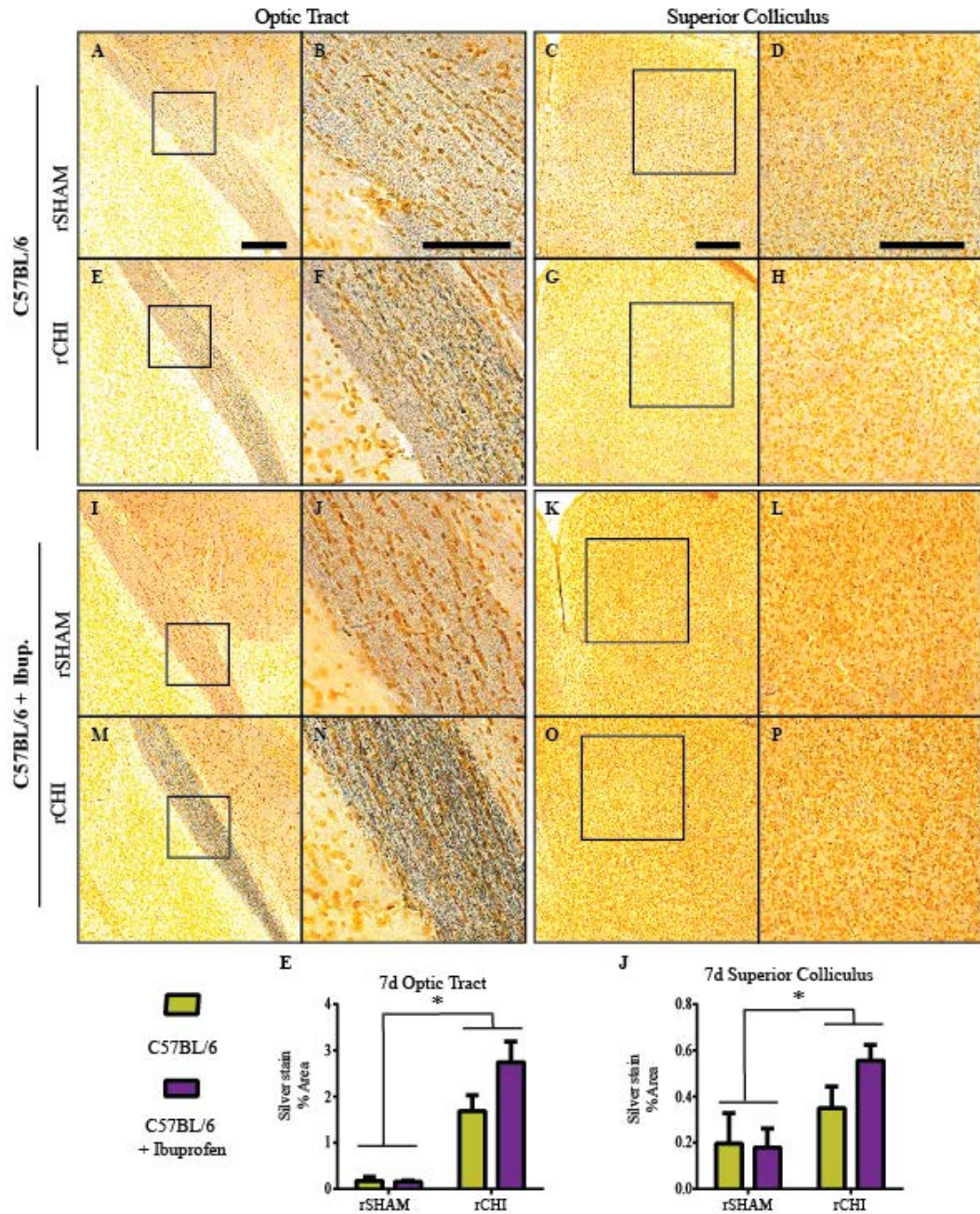


Figure 5.7: Acute silver stain labeling was increased in the optic tract and superior colliculus 7d after repeated mild TBI.

Argyrophilic neurons (silver stain; A-P) were labeled 7d after repeated closed head injury (rCHI) or repeated sham injury (rSHAM) in C57BL/6 mice with and without ibuprofen treatment. The percent of positive silver stain labeling was measured in the optic tract (E) and superior colliculus (J) after rCHI or rSHAM. In both regions, the percent area of silver stain labeling was significantly increased following rCHI but was not dependent on treatment. Scale bars represent 500 μ m for images in columns 1, 3, and 4; 250 μ m for images in column 2. n=5 sham/treatment; n=8-9 injured/treatment.

Ibuprofen did not Protect against Motor Dysfunction Following Repeated Mild TBI in Progranulin-deficient Mice

In a separate cohort of Grn^{-/-} mice, receiving ibuprofen-supplemented or normal mouse chow, motor dysfunction was assessed at several time points following injury in sham and rCHI animals using a beam walking task (Figure 5.8). A score of an eight indicates a perfect score. Neither Grn^{-/-} sham group performed up to normal sham standards. However, mice receiving rCHI performed worse. Motor function was impaired following rCHI ($p < 0.05$ compared to sham) but improved over time following injury ($p < 0.05$). Post-hoc analysis revealed that beam walking scores on day 1 were significantly worse than on days 14, 28, 56, 112, and 168 and beam walking scores on day 7 were significantly worse than on days 56, 112, and 168, indicating recovery of motor function over time. Acute ibuprofen treatment for two weeks appeared to result in slightly lower beam walking scores in the early assessments, but the interaction between treatment and injury did not reach statistical significance ($p = 0.09$) so no post-hoc testing was performed.

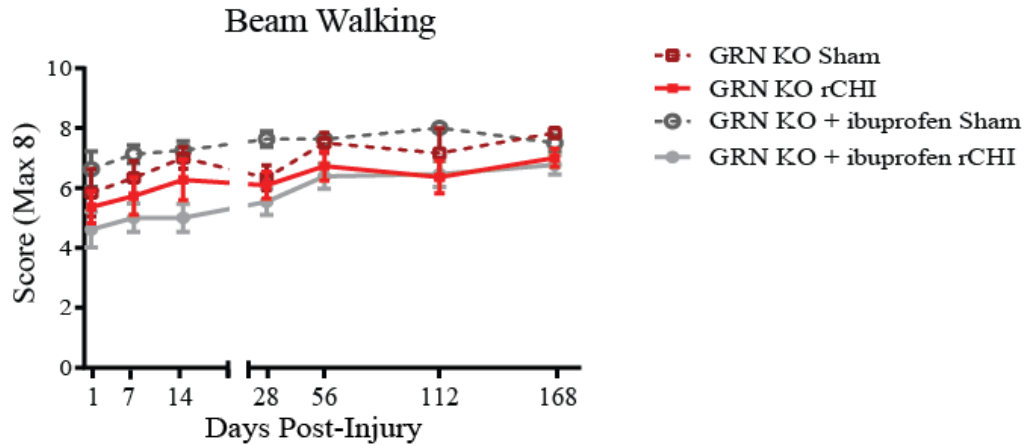


Figure 5.8: Transient motor deficits observed after repeated mild TBI are not affected by ibuprofen.

Behavioral deficits were examined for 7mo after repeated closed head injury (rCHI) and repeated sham (rSHAM) in Grn^{-/-} mice with and without ibuprofen. The beam walking task was used to identify deficits in motor coordination. A score of 8 indicated perfect performance on the task, with lower scores indicating poorer motor skills. Repeated CHI induced a significant deficit in motor function of Grn^{-/-} mice that was not altered by a 2wk ibuprofen treatment in Grn^{-/-} mice. Beam walking scores on day 1 were significantly worse than on days 14 through 168 and beam walking scores on day 7 were significantly worse than on days 56 through 168. n=6-8 sham/treatment; n=11-13 injured/treatment.

Ibuprofen did not Alter Cognitive Function Following Repeated Mild TBI in Progranulin-deficient Mice

Cognitive dysfunction was assessed using the NOR task at several time points over the course of the study (Figure 5.9A). Memory ability in the NOR task was worsened following injury ($p < 0.05$), and varied with time after injury ($p < 0.05$; no interaction, $p > 0.05$). Post-hoc analysis of the main time effect revealed NOR scores to be higher on the third trial (on day 56) compared to NOR scores on days 7, 112 and 168. Ibuprofen treatment appeared to improve NOR scores in Grn^{-/-} rSHAM animals and reduce NOR scores in Grn^{-/-} mice which received rCHI, but treatment was not a statistically significant factor ($p > 0.05$; interaction between treatment and injury $p = 0.06$).

The Novel Mouse Recognition (NMR) task was developed as a means of examining cognition in a context less dependent than NOR on visual cues. Rather, contextual cues such as smell and vocalizations could be used by the test mouse to identify familiar versus stranger mice. The test was conducted once at 7mo after injury (Figure 5.9B). For sham-injured mice their total exploration with the familiar mouse during the second trial was over 10% less than in the first trial. Injured Grn^{-/-} mice with and without ibuprofen treatment spent, on average, 1% more and 5% less of their total exploration with the familiar mouse, respectively, during the second trial compared to the first trial. However, these data were not significantly different between groups (interaction between injury and treatment $p = 0.06$).

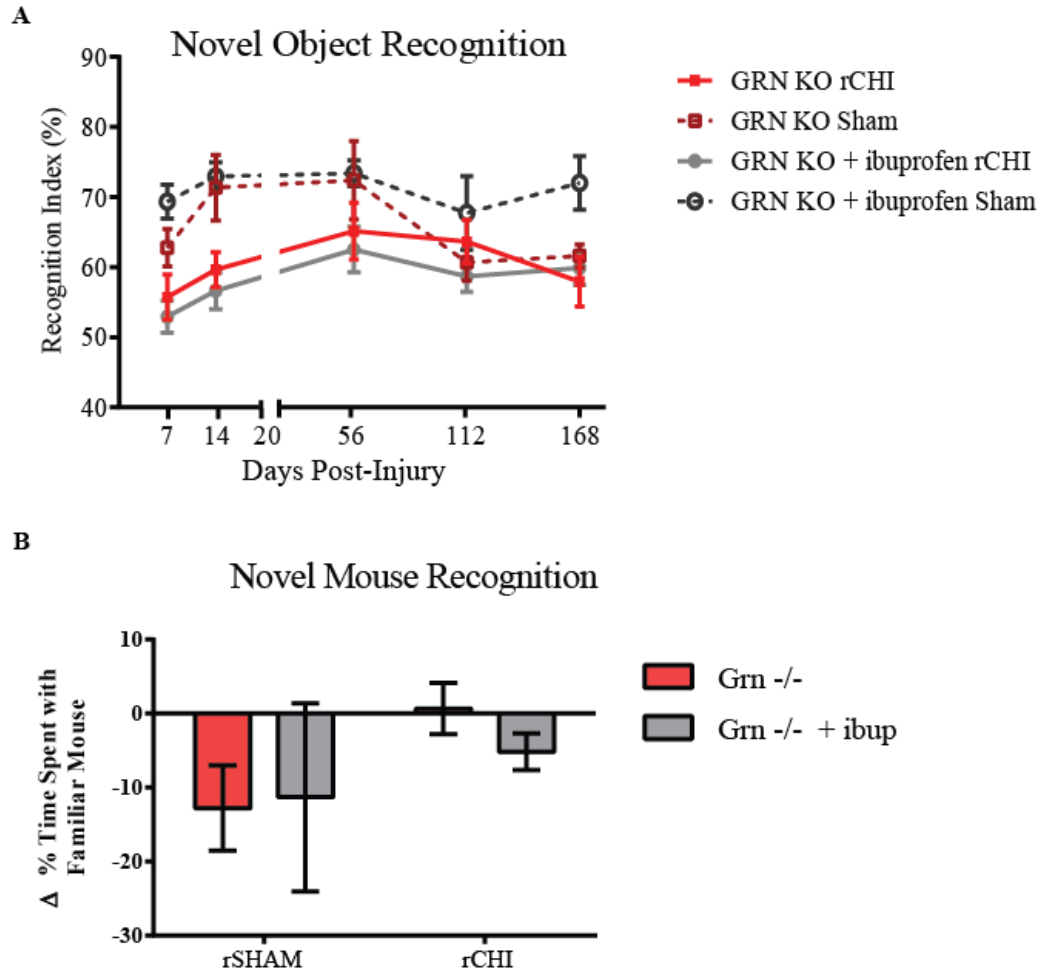


Figure 5.9: Repeated mild TBI induces persistent cognitive dysfunction that is not affected by ibuprofen.

Cognitive deficits were examined over 7mo after repeated closed head injury (rCHI) and repeated sham (rSHAM) in *Grn*^{-/-} mice with and without ibuprofen. (A) Memory scores in the novel object recognition task were calculated by dividing the time spent exploring the novel object by the total exploration time (recognition index=RI). Repeated CHI induced persistent deficits in *Grn*^{-/-} mice compared to that in their sham counterparts. (B) For the familiar mouse recognition task, memory scores were calculated by subtracting the RI for the familiar mouse during trial 2 from the RI for the familiar mouse during trial 1. There was not a significant difference using this test across groups. n=8-9 sham/treatment; n=15 injured/ treatment.

Vision is Mildly Affected after Repeated Mild TBI

Mice were tested for visual dysfunction using the visible platform test (Figure 5.10A). Based on the average of the best 2 out of 5 trials, mice took ten seconds or less to find the platform. Performance in the task was dependent upon injury ($p < 0.05$) and time ($p < 0.05$; interaction $p > 0.05$). 7d after injury, injured mice averaged between 10 and 15 seconds to reach the platform whereas sham mice averaged between 5 and 10 seconds. On each subsequent testing day, injured mice performed at or slightly above (within 2 seconds) sham mice. Across groups, scores from testing on day 7 following injury was significantly worse than scores on each subsequent day. No significant difference was observed with treatment ($p > 0.05$). Mice were also examined for visual dysfunction using the visual cliff 7mo after injury (Figure 5.10B). On average, mice from each group chose the 'safe' side of the box more than the 'cliff' side. No significant differences were observed among groups (injury, treatment, and interaction: $p > 0.05$).

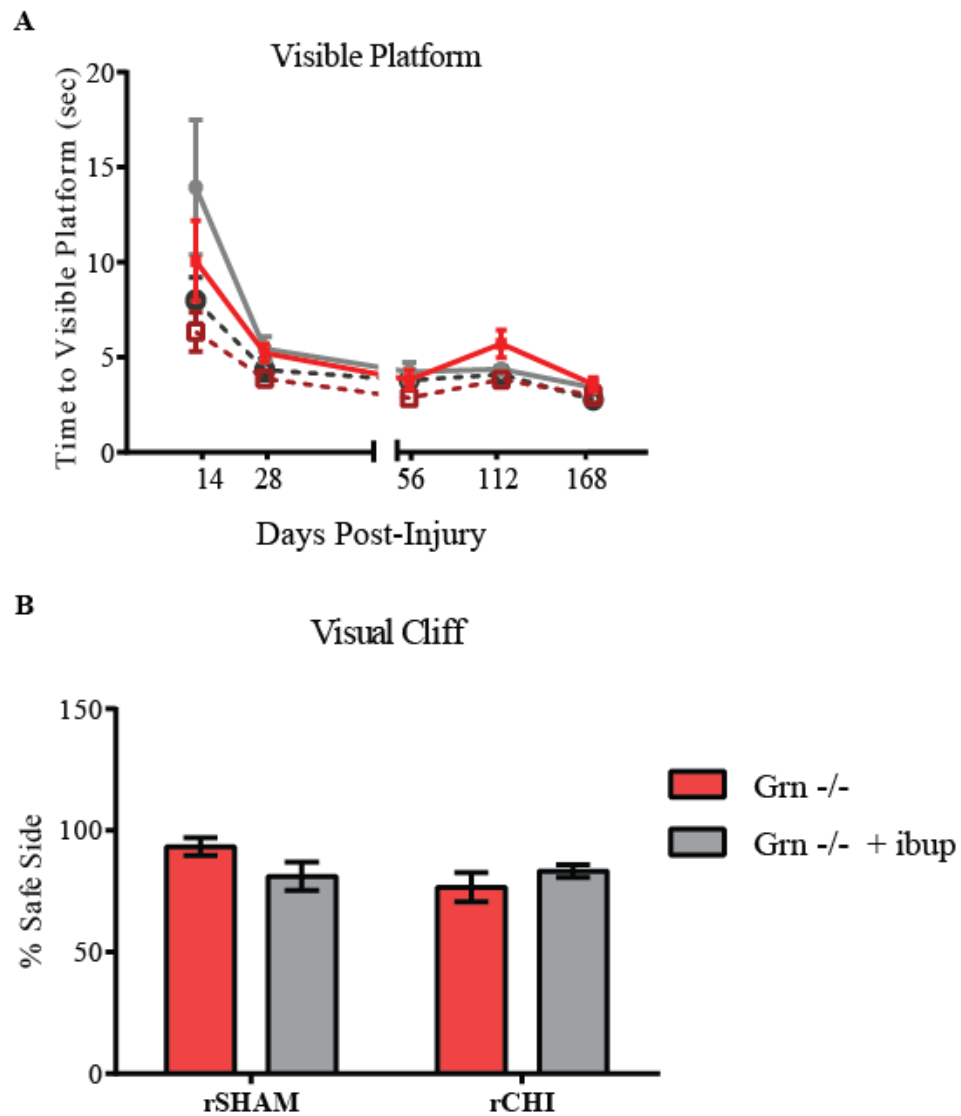


Figure 5.10: Repeated mild TBI did not induce chronic deficits in vision.

Deficits in vision were assessed for 7mo after repeated closed head injury (rCHI) and repeated sham (rSHAM) in Grn^{-/-} mice with and without ibuprofen. (A) The amount of time to reach the visible platform in a Morris water maze apparatus was measured. The time to reach the platform was significantly dependent on injury and time after injury. Time to the platform was significantly increased across groups on the first day of testing compared to all other testing days. (B) In the visual cliff task the percentage of trials the mouse selected the 'safe' side of the apparatus was used for analysis. There was not a significant difference among groups. n=8-9 sham/treatment; n=15 injured/ treatment.

Acute Ibuprofen Treatment does not Attenuate Chronic Microgliosis in Grn^{-/-} Mice after Repeated Mild TBI

As previously mentioned (Chapter 4) the microglia of Grn^{-/-} sham animals appeared reactive with thickened processes and swollen cell bodies throughout the optic nerve, (Figure 5.11 A, E), optic tract (Figure 5.11 A, C), superior colliculus (Figure 5.11 F, H), entorhinal cortex (Figure 5.12 A, C) and as previously reported, also in the hippocampus (Figure 5.12 F, H) and thalamus (Figure 5.12 K, M). In the optic nerves of injured Grn^{-/-} mice, a large amount of amoeboid shaped microglia were observed close to the chiasm where the majority of axonal injury was observed acutely (Figure 5.11 C, D, G, H). Further away from the optic chiasm, the number of microglia appeared lessened in ibuprofen-treated injured animals. However, acute ibuprofen treatment did not significantly reduce chronic microgliosis following repeated mild TBI (Figure 5.11 I). Increased CD68 labeling was also observed following rCHI in the optic tract (Figure 5.12 B, D) and superior colliculus (Figure 5.12 G, I). Quantitative analysis did not reveal differences in the amount of CD68 labeling between Grn^{-/-} mice with and without ibuprofen treatment in the optic tract (Figure 5.12 E) or superior colliculus (Figure 5.12 J). Microgliosis observed in the entorhinal cortex (Figure 5.13 E), hippocampus (Figure 5.13 J), and thalamus (Figure 5.14 O) was not significantly different following rCHI or ibuprofen treatment.

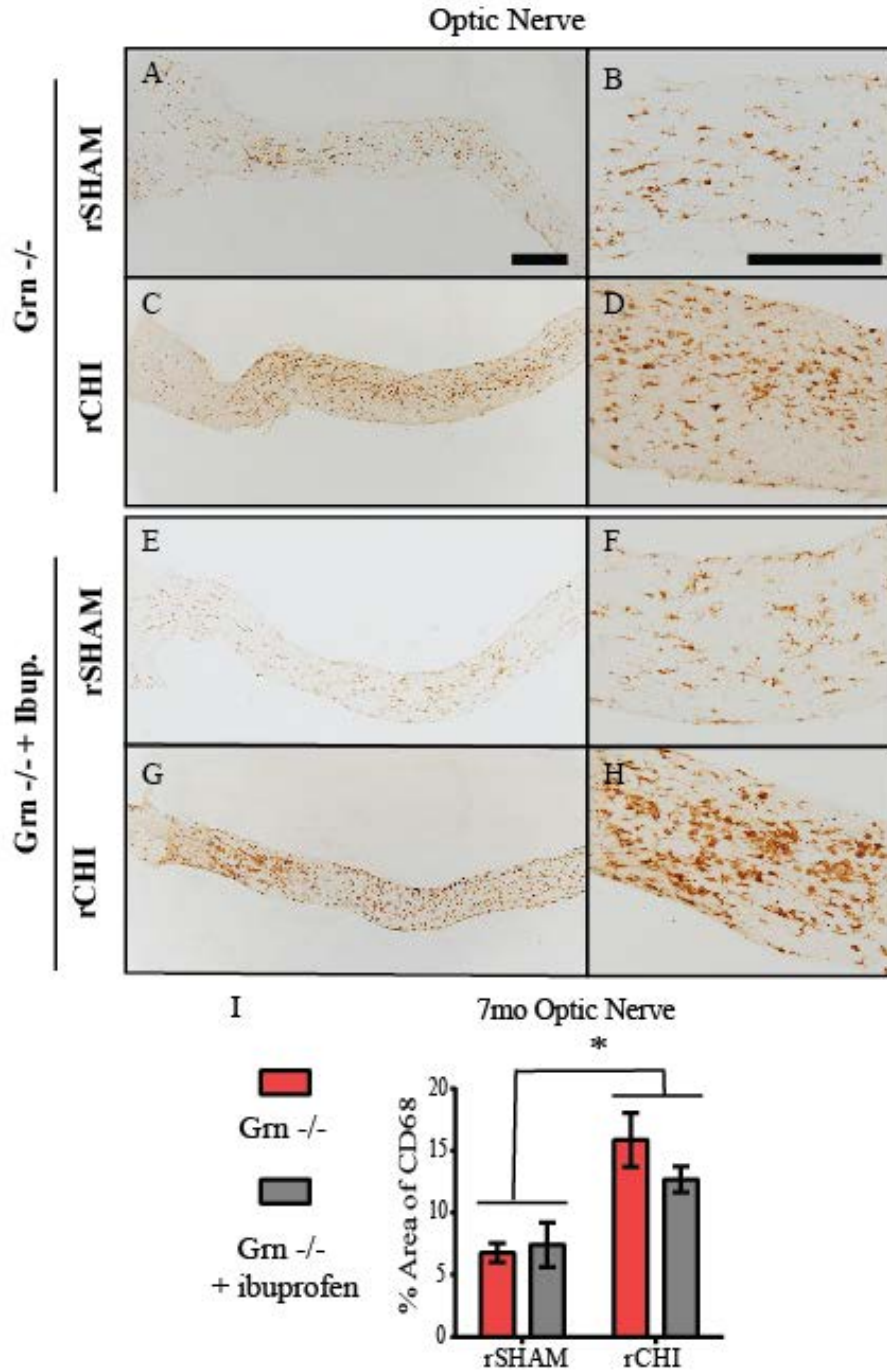


Figure 5.11: Acute ibuprofen treatment following repeated mild TBI in Grn^{-/-} mice did not alter chronic microglial reactivity in the optic nerve.

Immunohistochemical labeling for cluster of differentiation-68 (CD68) in the optic nerve (A-H) 7mo after repeated closed head injury (rCHI) or repeated sham-injury (rSHAM) in Grn^{-/-} mice with and without ibuprofen. The percent area of CD68 labeling was quantified for analyses. CD68 labeling was significantly increased after rCHI (I) compared to repeated sham injury (rSHAM) animals (* indicates p < 0.05). Two weeks of ibuprofen treatment acutely after injury did not significantly reduce microgliosis chronically in Grn^{-/-} mice. Scale bars represent 1mm: A, D; 500µm: B, C, E, F. n=5 sham/treatment; n=8-9 injured/treatment.

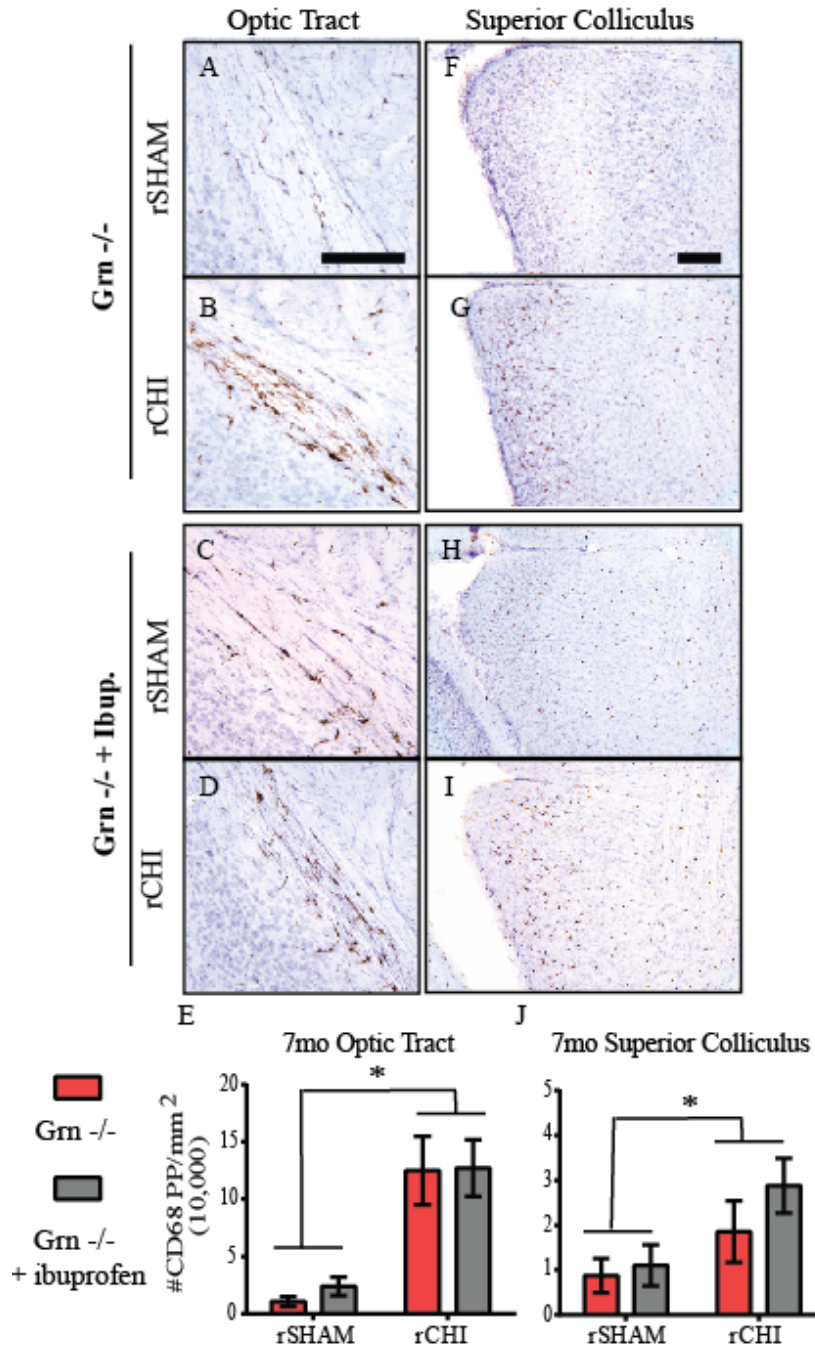
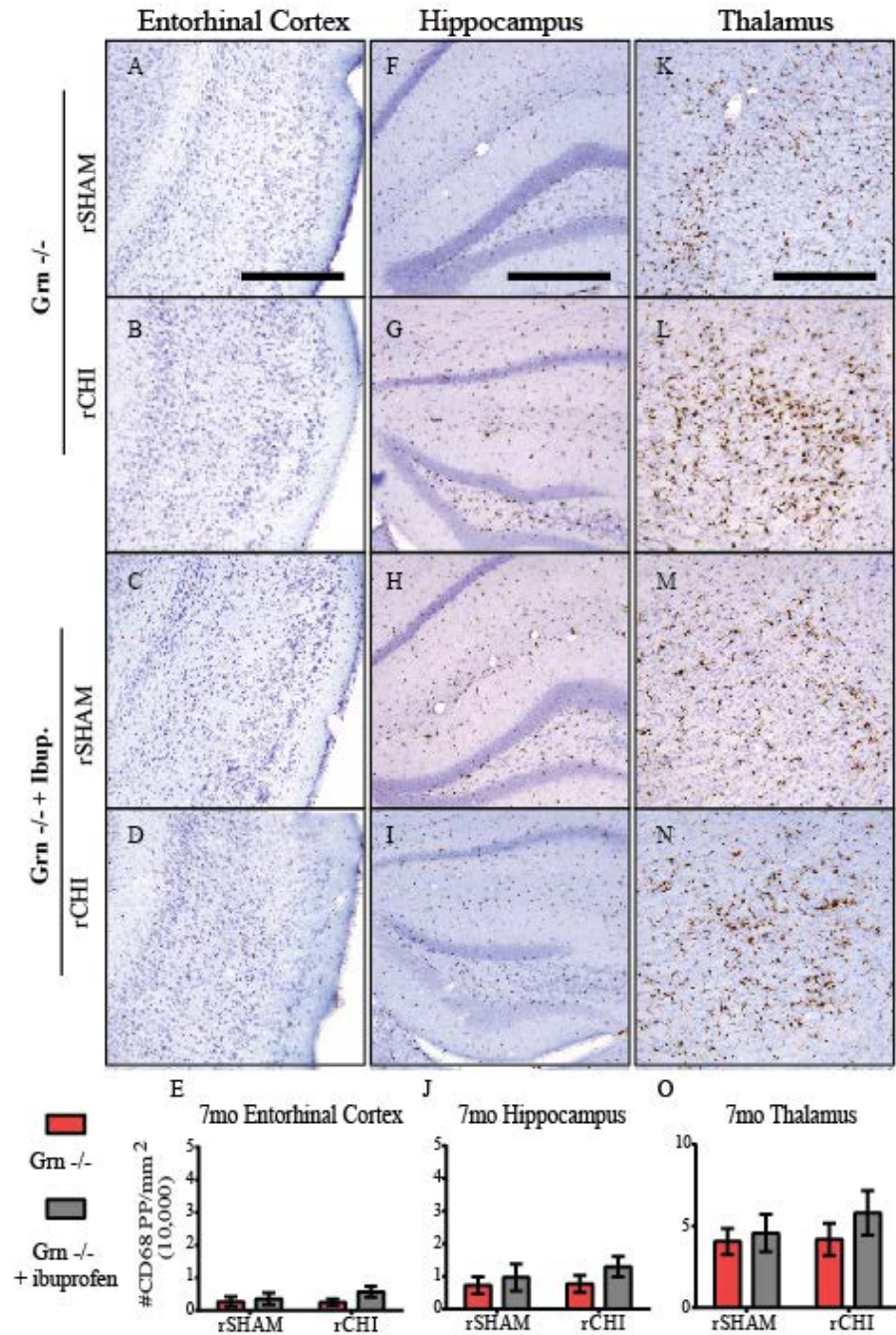


Figure 5.12: Acute ibuprofen treatment following repeated mild TBI in Grn^{-/-} mice did not alter chronic microgliosis in the optic tract or superior colliculus.

Immunohistochemical labeling for cluster of differentiation-68 (CD68) in the optic tract (A-D) and superior colliculus (F-I), 7mo after repeated closed head injury (rCHI) or repeated sham injury (rSHAM) in Grn^{-/-} mice with and without ibuprofen. The number of CD68 positive pixels were counted and normalized to the area of interest (mm²). CD68 labeling was significantly increased in the optic tract (E) and superior colliculus (J) after rCHI (* indicates p<0.05). Two weeks of ibuprofen treatment acutely after injury did not significant reduce microgliosis chronically in Grn^{-/-} mice. Scale bars represent 500µm: A, B; 250µm D-G. n=5 sham/treatment; n=8-9 injured/treatment.



Ibuprofen Reduces Axon Loss in Grn^{-/-} Mice

As in tissue from the 7d cohort, cerebral tissue from the 7mo cohort was labeled with silver stain to detect ongoing neurodegeneration. As reported previously in Chapter 4, several axons were labeled in the optic tracts of Grn^{-/-} sham animals (Figure 5.14 A, B). However, silver stained axons were more abundant in the optic tract of injured mice (Figure 5.14 E, F) compared to that in sham animals. Compared to the 7d cohort, silver stain 7mo after rCHI appeared less dense. However, these two groups were not compared to each other quantitatively. The average percent of silver stain was slightly higher at 2.5% in injured ibuprofen-treated Grn^{-/-} animals compared to that in injured Grn^{-/-} mice without ibuprofen which averaged at 1.5% percent. Quantitative analyses of silver stain accumulation in the optic tract (Figure 5.14Q) indicated a significant increase due to injury ($p < 0.05$) but not treatment ($p > 0.05$). In the superior colliculi of all Grn^{-/-} animals (Figure 5.14 columns 3 and 4) large accumulations of silver stain were also observed. Staining densities varied among animals, but qualitative analysis did not indicate differences due to injury or treatment.

Neurofilament (NF200) immunolabeling was used to detect intact axons. In sham-injured animals, approximately 70% of the region of interest was labeled positively with NF200 (Figure 5.15 I). Repeated CHI in Grn^{-/-} mice (Figure 5.15 C, D) caused a reduction in NF200 to approximately 40% 7mo after injury (Figure 5.15 I). NF200 labeling in injured Grn^{-/-} mice receiving ibuprofen treatment (Figure 5.15 G, H) averaged a higher percent of positively labeling at approximately 55%, (Figure 5.15 I). Statistical analysis indicated that the percent of NF200 labeling was decreased 7mo after rCHI

($p < 0.05$) and was increased due to ibuprofen treatment ($p < 0.05$). However, there was not an interaction between injury and treatment ($p > 0.05$).

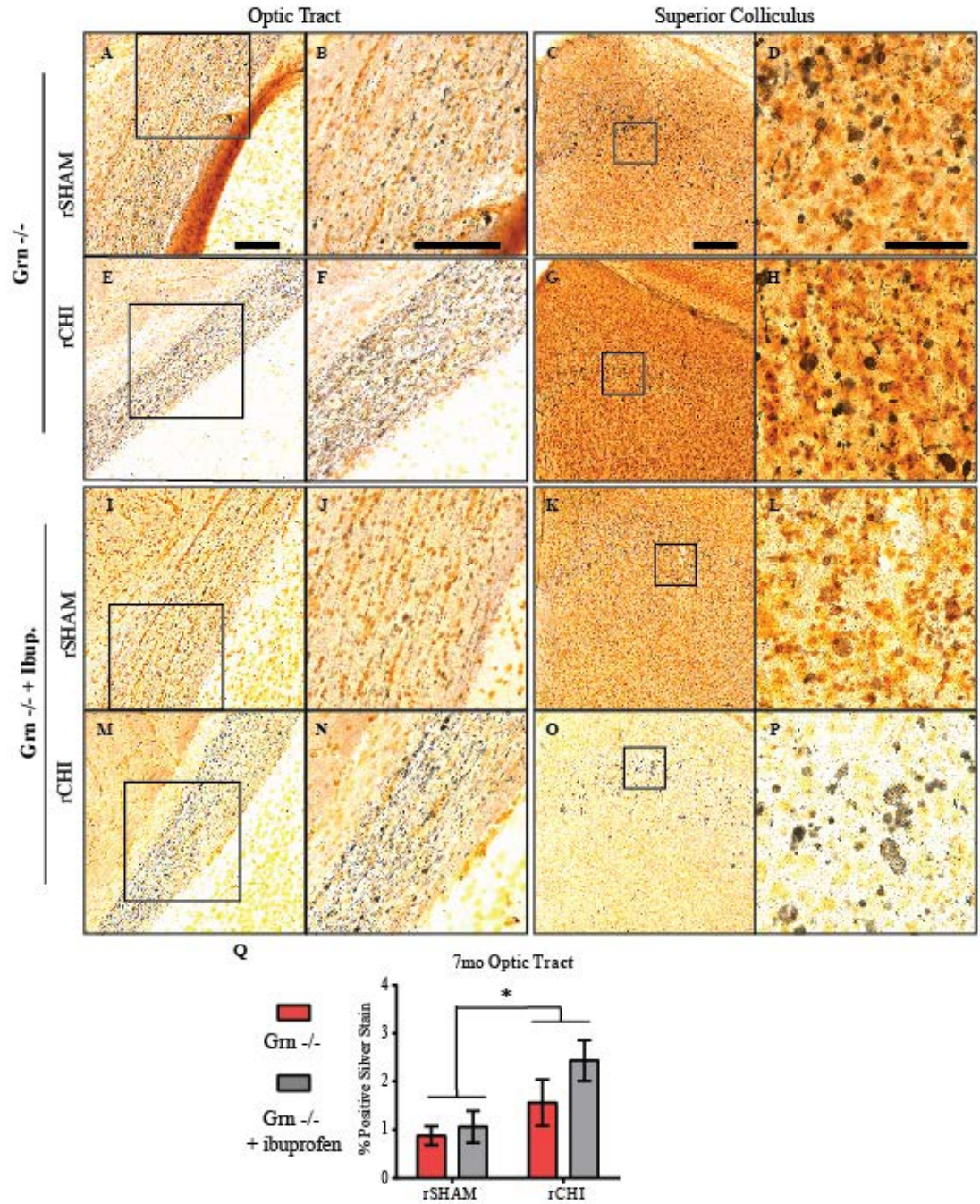


Figure 5.14: Acute ibuprofen treatment did not reduce chronic neurodegeneration in the optic tract of $Grn^{-/-}$ mice after repeated mild TBI.

Argyrophilic neurons were labeled using silver stain in the optic tract (columns 1 and 2) and superior colliculus (columns 3 and 4) 7mo after repeated closed head injury (rCHI) or repeated sham injury (rSHAM) in $Grn^{-/-}$ mice with and without ibuprofen treatment. The percent of positive silver stain labeling was measured for the optic tract (Q) 7mo after rCHI or sham injury. The amount of chronic silver stain was dependent upon injury but was not affected by acute ibuprofen administration in $Grn^{-/-}$ mice. Scale bars represent 500 μ m for images in columns 1, 3, and 4. For Column 2 scale bar represents 250 μ m for images B and J and 500 μ m for F and N. n=5 sham/treatment; n=8-9 injured/treatment.

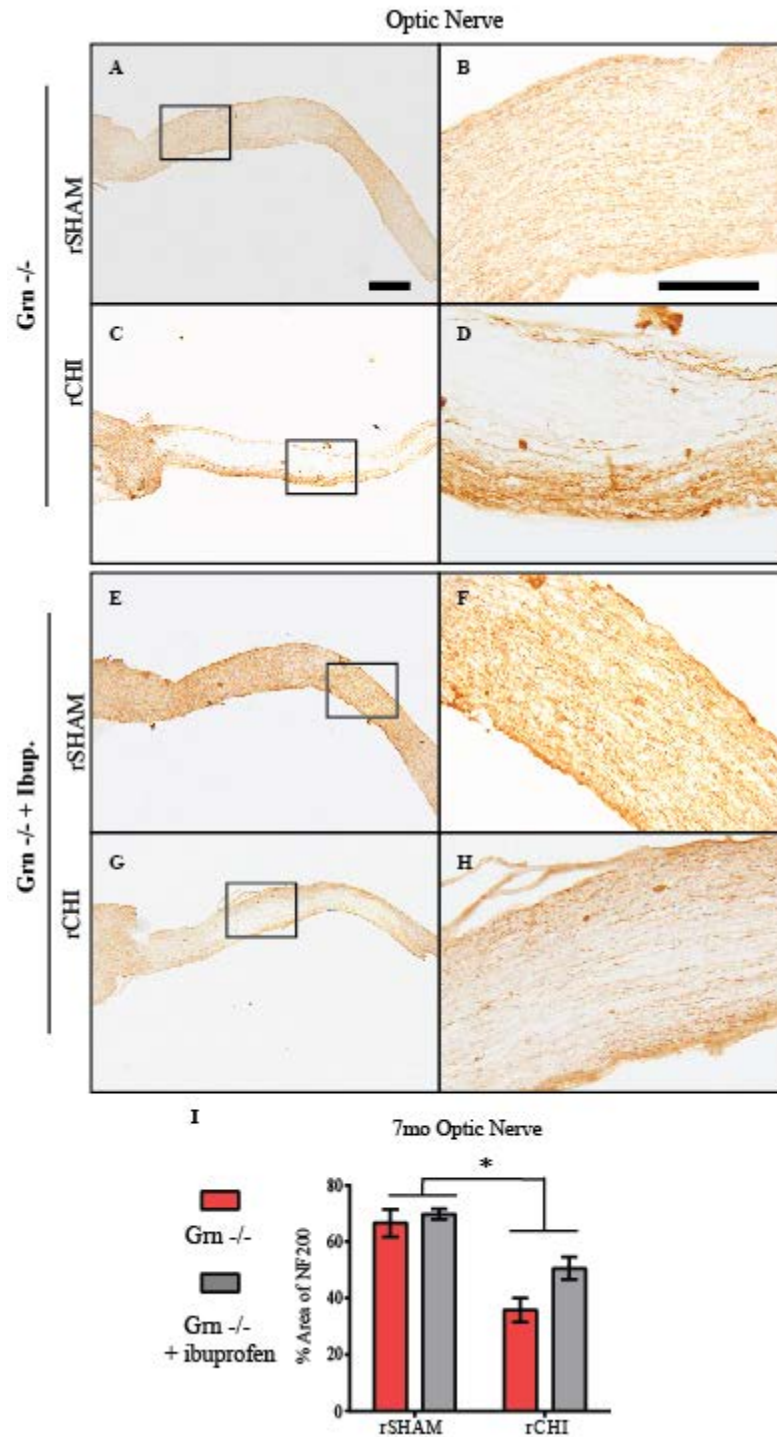


Figure 5.15: Acute ibuprofen treatment reduces the amount of axon loss in *Grn*^{-/-} mice. Optic nerves were labeled with neurofilament heavy chain (NF200) antibody to detect axon loss 7mo after repeated closed head injury (rCHI) or repeated sham injury (rSHAM) in *Grn*^{-/-} mice with and without ibuprofen treatment (A-H). The percent area of staining was quantified (I). Chronic axon loss was dependent upon injury and was dependent upon ibuprofen treatment, but there was not a significant interaction between the two dependent variables. Scale bars represent 1mm for images in column 1; 500 μ m for images in column 2. n=5 sham/treatment; n=8-9 injured/treatment.

Discussion

Mild TBI accounts for majority of the millions of TBIs that occur annually in the United States (CDC 2015). While a single mild TBI does not often result in long-lasting symptoms, the risk of receiving additional TBIs increases substantially (Guskiewicz, Marshall et al. 2007; Emery, Kang et al. 2011). Individuals with multiple mild TBIs perform worse on information processing tasks compared to those with a single mild TBI (Gronwall and Wrightson 1975). Using animal models of repeated mild TBI, we (Chapter 2) and others have shown that repeated mild TBI can induce neuronal damage that is more severe than a single mild TBI and can cause a greater microglial response (Shultz, Bao et al. 2012; Mouzon, Bachmeier et al. 2014). In the current study we utilized the non-steroidal anti-inflammatory drug (NSAID) ibuprofen to reduce the microglial response to repeated mild TBI. Ibuprofen was given via the chow following the first treatment and continued until euthanasia for the 48h and 7d cohorts or 2wks for the 7mo cohorts.

We chose to deliver the ibuprofen treatment following the first injury in order to mimic the real world scenarios where an individual may receive a mild TBI and self-treat their symptoms with a NSAID instead of going to see a doctor. Thus, in our acute studies using C57BL/6 mice, ibuprofen was on board for a total of seven days in the 48h group and twelve days in the 7d group. In the 48h group, ibuprofen-treated mice did not show a reduction in CD68 positive microglia in the visual pathway following injury, and there were no significant injury induced microgliosis in the entorhinal cortex, hippocampus, or thalamus. Axonal injury was observed by 48h after repeated CHI. In ibuprofen-treated rCHI mice, the amount of axonal injury in the optic nerve appeared to be reduced

compared to that in non-treated, injured animals, although this was not statistically significant. By 7d after injury, microglial reactivity appeared to increase from 48h in the optic tract of untreated, injured mice but remain at similar levels in the optic tract of ibuprofen-treated animals. Although, comparison of different euthanasia time points is limited by a lack of randomization in immunohistochemical analyses between groups (48h, 7d and 7mo euthanasia time points). However, qualitatively, the similar amounts of activated microglia at 48h and 7d after injury in the ibuprofen group may be attributed to ibuprofen-induced cell-cycle arrest of activated microglia as has been reported by others (Elsisi, Darling-Reed et al. 2005; Varvel, Bhaskar et al. 2009) limiting the proliferation of microglia. Optic tract neurodegeneration and axonal injury were also observed 7d after injury, but were similar between injury groups. Together these data suggest the efficacy of ibuprofen to mitigate microgliosis following TBI is time dependent. However, additional time points with longer ibuprofen treatment are needed to support this observation.

For every study of ibuprofen or another cyclooxygenase inhibitor that reports improvement in histopathology or behavior (Cernak, Savic et al. 1996; Hakan, Toklu et al. 2010; Cao, Thomas et al. 2012; Shang, Cheng et al. 2014) there is a study reporting no improvement (Kunz, Marklund et al. 2006; Hickey, Adelson et al. 2007) or worsened (Dash, Mach et al. 2000; Browne, Iwata et al. 2006) functional deficits with ibuprofen treatment. However, the purpose of the current study was not to examine whether ibuprofen was therapeutic for the treatment of repeated mild TBI. Rather the purpose was to evaluate the efficacy of ibuprofen to reduce microgliosis following injury in order to study whether reduced microgliosis acutely after injury could mitigate chronic

neurodegeneration and the associated neurobehavioral consequences. In the current study, ibuprofen treatment following repeated mild TBI did not attenuate cognitive or motor deficits as has been previously reported in several models of single TBI (Gopez, Yue et al. 2005; Thau-Zuchman, Shohami et al. 2012). Instead, $Grn^{-/-}$ injured mice treated with ibuprofen appeared to perform worse than $Grn^{-/-}$ injured mice without ibuprofen in several tasks, although this was not statistically significant. Histological evaluation seven months after injury indicated a persistent increase in microgliosis and chronic neurodegeneration following repeated mild TBI that was not significantly reduced with acute ibuprofen treatment. In a study of chronic intracerebroventricular infusion of lipopolysaccharide, ibuprofen was able to reduce the behavioral deficits induced by the LPS (Richardson, Kim et al. 2005). However, when Richardson and colleagues withdrew the ibuprofen treatment, an increase in microgliosis occurred by 15d suggesting that ibuprofen can stall the microglial response, but once removed, microglia will respond to pathological triggers. Without an acute $Grn^{-/-}$ group with ibuprofen treatment it is difficult to confirm whether microgliosis was ever mitigated in $Grn^{-/-}$ mice. However, we have previously shown optic tract neurodegeneration ten weeks following repeated mild TBI (Chapter 3). Thus there is a high probability that once ibuprofen treatment was removed, the ongoing axonal injury in the optic nerve and optic tract caused microglia to quickly respond and persist chronically.

Microgliosis has been observed in human cases of Frontotemporal Lobar Degeneration (FTD) (Arnold, Han et al. 2000) in addition to several other neurodegenerative diseases: Alzheimer's disease (AD) (Arends, Duyckaerts et al. 2000), Parkinson's disease (McGeer and McGeer 1998), Amyotrophic Lateral Sclerosis (ALS)

(Kawamata, Akiyama et al. 1992) and Multiple Sclerosis (Boyle and McGeer 1990). In the late 1990s, studies reported that the use of non-steroidal anti-inflammatory drugs (NSAIDs) resulted in a 50% reduction in the risk of Alzheimer's disease (Stewart, Kawas et al. 1997; McGeer and McGeer 1998), and ibuprofen was reported as the most frequently used NSAID (Stewart, Kawas et al. 1997). These reports set in motion many studies examining the role of microgliosis in the progression of neurodegenerative diseases, and the mechanism by which ibuprofen is therapeutic. Studies in animal models of AD were able to show suppression of amyloid beta plaques and inflammation following ibuprofen treatment (Lim, Yang et al. 2000; Jantzen, Connor et al. 2002; Yan, Zhang et al. 2003). Ibuprofen was also shown to decrease nitric oxide and inducible nitric oxide synthase (Ogawa, Umegaki et al. 2000) and reduce cytokine-induced amyloid beta production (Blasko, Apochal et al. 2001) in cell culture models of AD. In addition to animal models of AD, ibuprofen has been examined in models of Parkinson's disease (Carrasco, Casper et al. 2005) and lipopolysaccharide infection (Richardson, Kim et al. 2005), but cyclooxygenase inhibitors have not been examined in models of FTD until the current study. Interestingly, $Grn^{-/-}$ sham animals treated with ibuprofen appeared to perform better in neurobehavioral tasks compared to $Grn^{-/-}$ sham animals that did not receive ibuprofen, both acutely and at chronic time points. Additional studies are needed to fully understand the effect of ibuprofen on $Grn^{-/-}$ sham animals in reducing age-related behavioral dysfunction such as a time course of treatment study and investigation into additional pathological consequences of progranulin deficiency such as lipofuscin accumulation.

In the present study we have combined both genetically-induced microgliosis and injury-induced microgliosis and attempted to mitigate it with an over-the-counter anti-inflammatory that may be used by many people following a mild TBI. We reported previously (Chapter 4) that CD68 positive microglia in aged $\text{Grn}^{-/-}$ mice are morphologically different from CD68 positive microglia following rCHI. Activated microglia in aged $\text{Grn}^{-/-}$ mice have small cell bodies and thin processes, whereas chronically activated microglia following injury are swollen and many appear macrophage-like. All ‘activated’ microglia are not the same, and morphological differences between groups suggest physiological differences. Microglia can be separated based on cytokine and chemokine expression into “classically activated”, “alternatively activated” and “acquired deactivation” states (Cao, Thomas et al. 2012). Classically activated microglia phagocytose dead and dying cells due to axonal injury and/or blood brain barrier disruption as a part of the immune response (Ransohoff and Cardona 2010). In contrast, microglia in an acquired deactivation state are believed to down-regulate the inflammatory response (Mantovani, Locati et al. 2004; Cullheim and Thams 2007). Alternatively activated microglia are reported to promote neuronal plasticity and axonal regeneration (Chen and Guilarte 2006), and are most beneficial in chronic stages of recovery. Following diffuse brain injury, Cao and colleagues reported an increase in microglia with classically activated gene expression ($\text{TNF-}\alpha$) and acquired deactivation gene expression ($\text{TGF}\beta$ -1 and $\text{TGF}\beta$ -IIR), but no increase in alternatively activated gene expression (arginase I) was observed out to 28days (Cao, Thomas et al. 2012). In a CNS injury study utilizing a stab brain wound in $\text{Grn}^{-/-}$ mice, Tanaka and colleagues reported an increase in $\text{TGF}\beta$ -1 in CD68 positive cells by 4d after injury compared to $\text{Grn}^{+/+}$ mice

(Tanaka, Matsuwaki et al. 2013a) suggesting an increase in microglia with an acquired deactivation state. Therefore we acknowledge that future studies should evaluate the temporal profile of cytokine levels following repeated mild TBI in wildtype and progranulin-deficient mice in order to better understand the phenotypic role being investigated.

In our previous studies amplifying posttraumatic microgliosis by means of progranulin deficiency failed to increase neuronal degeneration or worsen neurobehavioral deficits (Chapter 4). Here, use of an anti-inflammatory drug which reduced the extent of microglial activation in the optic tract after repeated mild TBI did not mitigate neuronal degeneration or reduce neurobehavioral deficits. Together the data refute a role for chronic microgliosis in contributing to neurodegeneration and neurobehavioral dysfunction following repeated mild TBI.

CHAPTER 6: Discussion and Conclusions

Review of Major Findings

The stretching or shearing of white matter tracts causing axonal injury has been observed in human cases and with experimental models of TBI (Creed, DiLeonardi et al. 2011; Smith, Gentleman et al. 2013). In experimental models axonal injury often presents with inflammation, and both can be exacerbated with repeated injuries (Laurer, Bareyre et al. 2001; Shitaka, Tran et al. 2011). Activated microglia persist chronically following injury (Smith, Gentleman et al. 2013; Mouzon, Bachmeier et al. 2014), and their presence in a number of neurodegenerative diseases lends support for a microglia-mediated mechanism in the development of neurodegenerative diseases. Chronic microgliosis following TBI raises the possibility of microglia as the link between TBI and neurodegenerative diseases, specifically CTE. To begin to address the role of chronic microgliosis in neurodegeneration triggered by trauma, we first developed a model of mild TBI characterized by transient loss of consciousness and small amounts of axonal injury, reactive glia, or cell death acutely after injury. We hypothesized that repeated closed head injury at 24h inter-injury intervals (rCHI-24h) would exacerbate acute histopathology compared to single mild TBI, and that extending the interval from 24h to 48h (rCHI-48h) would reduce the outcomes. Indeed, mice from the rCHI-24h group exhibited increased inflammation, cell death, and axonal injury in several regions including the entorhinal cortex, visual pathway (optic nerve, optic tract, and superior colliculus), cerebellum, and brainstem. Mice in the rCHI-48h group appeared similar to mice that received a single injury. Based on these results, we hypothesized that rCHI-24h would induce behavioral deficits, and that by extending the inter-injury interval to 48h

the deficits would be reduced. A ten week longitudinal evaluation of motor and cognitive dysfunction was performed in mice with rCHI-24h or rCHI-48h or with repeated sham injuries (rSHAM). Across the ten week study, mice with rCHI-24h performed significantly worse than rSHAM mice in beam walking and the NOR task (motor and cognitive tests, respectively). Surprisingly, mice with rCHI-48h did not show lessened behavioral dysfunction in either motor or memory tasks. Upon histopathological evaluation, both cohorts of injured mice showed similar levels of ongoing neurodegeneration and inflammation in the visual pathway. Repeated CHI also induced a significant amount of axon loss in the optic nerve which was not significantly affected by inter-injury interval duration. Persistent degeneration of axons within the visual pathway raised the possibility of a deficit in vision potentially altering the interpretation of cognitive tests that rely on vision such as the NOR. Therefore in our 7mo study we evaluated mice with the visible platform test, a specific part of the Morris Water Maze trial that tests for visual dysfunction. Injured wildtype mice had equivalent performance across time when compared to sham mice, suggesting that even with a significant amount of optic nerve axon loss, mice should still be capable of detecting an object.

The rCHI-24h paradigm was used for all following experiments evaluating the relationship between microgliosis and chronic neurodegeneration. We hypothesized that chronic microgliosis contributed to chronic neurodegeneration, and thereby increasing or mitigating microgliosis following injury would lead, respectively, to worsened or reduced neurodegeneration and corresponding behavioral deficits. To test the hypothesis that increased microgliosis worsens neurodegeneration and behavioral impairment, we utilized progranulin-deficient ($Grn^{-/-}$) mice that have been previously shown to have an

exacerbated microglial response to stab brain injury (Tanaka, Matsuwaki et al. 2013a). $Grn^{-/-}$ mice with rCHI showed significantly worsened microgliosis acutely that persisted out to 7mo after injury. However, increased microgliosis failed to significantly worsen chronic neurodegeneration or behavioral dysfunction. To test the hypothesis that reducing the microglial response following injury would reduce neurodegeneration and behavioral deficits we provided a group of mice with ibuprofen, an NSAID that has been previously shown to effectively reduce activated microglia and their cytokine expression following TBI (Cao, Thomas et al. 2012). In the acute evaluation, ibuprofen was able to mitigate the microglial response in the optic tract, but it did not correspond with decreased neurodegeneration. In our 7mo study, $Grn^{-/-}$ mice treated with ibuprofen for two weeks following the first injury did not show a chronic reduction in microgliosis. Acute ibuprofen treatment did not alleviate behavioral dysfunction or the amount of neurodegeneration or axon loss. Contrary to our hypothesis, modulating microgliosis after repeated mild TBI did not significantly influence the extent of chronic neurodegeneration or behavioral impairment, suggesting that microgliosis is not a favorable target for the treatment of mild TBI.

Implications for Time Interval between Repeated Mild TBIs

Individuals with a mild TBI are at an increased risk of sustaining subsequent head injuries. In part, the increased risk is associated with the lifestyle of the individual and activities that they are involved. Athletic activities such as boxing and football are two sports commonly associated with head injuries. After sustaining any kind of injury in a sport, one of the most often asked questions by players, parents, and coaches alike is “How long until they can play again?”. It has been suggested that individuals with a head

injury wait until all symptoms have subsided before returning to their normal daily activities. However, because of limited diagnostic techniques the relationship between symptomatology and cellular consequences of TBI in humans is not well understood.

Experimental models of mild TBI have assisted in filling the gaps as they allow for replication of injuries in multiple test subjects to define the significant pathological consequences. For mild TBI, the most common pathologies are white matter axonal injury and inflammation. Studies of repeated mild TBI have reported an increase in axonal injury and inflammation and/or worsening of behavioral deficits. While every study of repeated mild TBI specifies an inter-injury interval, few studies have compared repeated mild TBIs with different intervals in the same study (Longhi, Saatman et al. 2005; Fujita, Wei et al. 2012; Meehan, Zhang et al. 2012; Mannix, Meehan et al. 2013; Weil, Gaier et al. 2014). To test the hypothesis that varying inter-injury intervals between repeated CHI would significantly alter the pathological consequences we first characterized a single CHI that induced minimal axonal injury and inflammation in the entorhinal cortex, cerebellum, and brainstem. Repeated CHI at 24h inter-injury intervals increased cell death in the entorhinal cortex, but did not increase the number of axonal bulbs. However, the bulbs did appear larger which also suggested a worsened injury. Increased astrogliosis and microgliosis occurred in similar regions of injury. When the inter-injury interval was lengthened axonal injury and inflammation in these regions appeared similar to a single injury suggesting that a 48h window was outside the window of vulnerability for repeated head injuries in a mouse. Only two studies have evaluated axonal injury as it relates to the time interval between injuries (Fujita, Wei et al. 2012; Meehan, Zhang et al. 2012). In one study two injuries repeated 3hr apart caused an

increase in axonal injury 4h after injury compared to a sham injury. Axonal injury was progressively lessened when repeated at 5h and 10h apart but was still increased compared to a single injury. In the second study, five injuries spaced at 24h, 1wk, and 1mo were evaluated for axonal injury using the same marker as the previously mentioned study, but did not report any axonal injury 24h after the final repeated injury or a single injury. Silver stain has been reported as a better marker for axonal injury than APP following mild TBI (Shitaka, Tran et al. 2011). Therefore studies of mild TBI reporting a lack of axonal injury with APP may be missing a population of degenerating axons. Nevertheless, because APP has been used to detect axonal injury 24h or later following mild TBI, these two interval studies in conjunction with our study suggests the magnitude of injury may be critical for the development of axonal injury and subsequent secondary injury. Thus, the window of vulnerability would be much shorter for smaller magnitude impacts. Consequentially these differences between studies make their comparison difficult and challenge our ability to determine if there is a transient period of vulnerability following a TBI.

In the evaluation of behavioral consequences of repeated mild TBI, the presence or absence of axonal injury does not appear to correspond with motor or cognitive dysfunction. Memory deficits have been observed to worsen with increased number of injuries without resulting in accumulation of APP in axons (Meehan, Zhang et al. 2012). In the same study, varying the interval between injuries had no effect on axonal injury, but behavioral deficits were observed to persist longer with shorter intervals between injuries. A lack of axonal injury (and cell death) suggests that more subtle consequences such as synaptic dysregulation occur after injury to induce behavioral deficits. In our ten

week behavioral study, mice with injuries repeated at 24h inter-injury intervals developed persistent deficits in motor and memory dysfunction compared to those in sham animals. Despite the acute pathological differences observed in the brains of animals receiving repeated CHI at 24h versus 48h inter-injury intervals, mice with CHI repeated at 48h inter-injury intervals exhibited behavioral impairment that was not different from that in mice with CHI repeated at 24h intervals. Evaluation of axonal injury with silver stain did not reveal ongoing degeneration in regions involved in the memory circuit, but ongoing neurodegeneration was detected in the visual pathway, cerebellum, and brainstem, the extent of which was similar between mice receiving repeated CHI at 24h or 48h inter-injury intervals. Our study suggests that a significant reduction in acute pathology due to inter-injury interval is not necessarily indicative of significant reduction in chronic pathology or behavioral outcomes. However, data from Mannix and colleagues would suggest that a much longer evaluation of behavioral dysfunction may be necessary to delineate the consequences of CHI repeated at 24h versus 48h. In their studies, an inter-injury interval of 1wk had persistent memory dysfunction out to 6mo after injury (Mannix, Meehan et al. 2013). However, Longhi and colleagues reported that repeated mild TBI with a 1wk inter-injury interval did not induce memory deficits 3d after injury (Longhi, Saatman et al. 2005).

In an early report of repeated mild TBI, DeFord and colleagues varied the weight of the object dropped onto the skull to evaluate how the severity of repeated injuries alters memory dysfunction (DeFord, Wilson et al. 2002). They reported that reducing the weight of impact, lessened the cognitive consequences of repeated head injuries. Taken together with the literature on varying the inter-injury interval, the magnitude of impact

may be a key regulator in the period of vulnerability. That does not make studies of inter-injury interval unwarranted, but rather imperative. By understanding the period of vulnerability within an injury model, we can effectively study the cumulative consequences of repeated mild head injuries versus that of a single mild head injury.

Implications for Microgliosis after Repeated Mild TBIs

Experimental models of mild TBI have reported inflammatory responses that can be increased with subsequent head injuries. In our first two studies, both astrocytosis and microgliosis was increased acutely in several regions of the brain following repeated mild TBI and persisted out to ten weeks. The amount of microgliosis in the pyramidal tract following repeated mild TBI correlated with a worsened beam walking score and suggested that increased microgliosis chronically after injury may worsen behavioral deficits. In our 7mo study, reactive microglia were still present in the visual pathway of wildtype mice, but quantitative analyses did not show significant differences between wildtype injured and sham animals. Other experimental studies have shown microglia to persist up to a year after injury (Mouzon, Bachmeier et al. 2014), and chronic microgliosis is associated with pathological accumulations in neurodegenerative disease (Lim, Yang et al. 2000; Yan, Zhang et al. 2003) implicating a role for chronic microgliosis in the development of neurodegenerative disease following head injury.

A number of studies have evaluated the effect that reducing microgliosis has on injury, but the effect that exacerbating microgliosis has on neurodegeneration is not well understood. In our studies progranulin-deficient mice were used to increase microgliosis following injury and a short-term ibuprofen treatment was used to mitigate microgliosis following injury. We showed an exacerbated microglial response to injury in Grn^{-/-} mice

acutely following injury that was persistent out to 7mo after injury. However, the exacerbated microglial response did not affect the amount of chronic neurodegeneration nor did it significantly increase the amount of axon loss. In our evaluation of mitigating microgliosis, ibuprofen reduced microgliosis in the optic tract at 7d after injury. However, when the short-term treatment was evaluated chronically, microgliosis was similar between $Grn^{-/-}$ mice with and without ibuprofen. No significant difference in ongoing neurodegeneration or axon loss was observed between injured groups. Richardson and colleagues have shown that withdrawal of ibuprofen treatment following lipopolysaccharide infusion resulted in an increase of reactive microglia (Richardson, Kim et al. 2005). Therefore, if similar levels of substrates for microglial activation, such as dying neurons, were still present at the time of ibuprofen withdrawal in our studies, then the study by Richardson and colleagues would suggest that microglia would respond at the same magnitude as untreated $Grn^{-/-}$ mice thereby resulting in similar levels of chronically activated microglia. Thus, our data does not implicate microgliosis as the culprit for chronic neurodegeneration and suggests alternative targets for therapeutic treatments of repeated mild TBI.

Discussion of Limitations and Alternative Approaches

Our behavioral evaluation of varying the interval between repeated CHI is limited by the lack of behavioral evaluation of a single mild TBI. The similarities in acute pathology between a single CHI and repeated CHI at 48h inter-injury intervals suggests that a single mild TBI may be capable of inducing similar behavioral outcomes. Motor testing following the first CHI of a repeated CHI cohort indicated normal motor function 24h after injury, but cognitive dysfunction was not evaluated. In our 7mo study, we

showed that motor function following repeated CHI at 24h inter-injury intervals can recover, but that cognitive dysfunction persists out to 7mo. Alternative to our ten week behavioral evaluation, we could have compared motor and cognitive dysfunction between repeated CHI at 24h or 48h inter-injury intervals across a much longer time period. A longer period of evaluation may have revealed chronic behavioral differences with varied inter-injury intervals as has been observed in other studies (Meehan, Zhang et al. 2012; Mannix, Meehan et al. 2013). Alternatively, evaluation of a third inter-injury interval longer than 48h may have shown a shorter duration of behavioral dysfunction within the ten week study period.

We provided a comprehensive histological evaluation of axonal injury, cell death, and inflammation in our studies. However, in restricting our evaluation to histology, we limited the ability to measure the expression levels of cytokines and chemokines, tau protein, and synaptic proteins which would enable us to better understand the sub-cellular events contributing to behavioral outcomes. For our studies evaluating microgliosis, we assumed that the microglial response to injury in $Grn^{-/-}$ mice is an exacerbation of that which occurs at a lower level in wildtype mice. However, $Grn^{-/-}$ mice are reported to have increased levels of TGF β 1 following injury compared to C57BL/6 mice (Tanaka, Matsuwaki et al. 2013b), a cytokine which has been described as a marker for the acquired deactivation state of microglia (Cao, Thomas et al. 2012). Thus, the lack of a panel of cytokine and chemokine expression levels limits our interpretation of microglia's involvement in chronic neurodegeneration. It is possible that a small amount of phagocytic microglia in wild type mice causes similar expression levels of pro-

inflammatory cytokines as the activated microglia in Grn^{-/-} mice. If so, this could implicate a role for microglia in neurodegeneration following brain injury.

Instead of using a transgenic mouse, alternative approaches to exacerbating microgliosis following injury could be to induce a more severe injury or to supplement the head injury with a toxin to increase microgliosis. However, increased microgliosis following a more severe head injury would be attributed to increased axonal injury and therefore not comparable to an exacerbated microglial response due to a similar primary head injury. The use of a substrate, such as lipopolysaccharide, to exacerbate microgliosis following injury may induce different inflammatory reactions than a head injury and would not be better than the Grn^{-/-} mice in that matter. The benefit to using progranulin-deficient mice is that we were able to observe how a model of neurodegenerative disease is influenced by head injury mimicking a real world scenario of genetic and environmental risk factors in the development of disease.

The Grn^{-/-} line used in these studies has been previously reported to have age-related accumulation of cytosolic pTDP43 by 12 months of age. In a small cohort of animals we did not observe accumulations by 10mo of age in injured or uninjured animals. Neither were we able to detect pathological TDP43 in naïve Grn^{-/-} mice at 17mo of age, despite numerous attempts. Grn^{-/-} mice have also been reported to have an increased accumulation of lipofuscin with age, a byproduct of the oxidation of unsaturated fatty acid. Because it is not degradable, lipofuscin has been called a marker of aging. Lipofuscin is auto fluorescent between 500 and 695nm. However, in our studies with Grn^{-/-} mice we injected cholera toxin beta (CTB) into the retina 24h prior to euthanasia to evaluate the amount of anterograde transport from the retina to the superior

colliculus. The CTB was tagged with Alexa-488 causing a co-fluorescence of both lipofuscin and CTB limiting our evaluation of CTB transport and lipofuscin accumulation. Large accumulations of silver stain were observed in the superior colliculus where lipofuscin accumulation occurred. However, other areas of lipofuscin accumulation, such as the hippocampus, did not exhibit silver stain labeling making it an unreliable alternative to analyzing lipofuscin.

In our studies of mitigating microgliosis following injury we delivered a dosage of ibuprofen that has previously been shown effective in reducing microgliosis (Cao, 2012). We were able to detect reduced acute microgliosis in the optic tract of mice treated with ibuprofen. However, because our animals remained group housed after injury, we do not have individual measures of ibuprofen dosage to perform correlative evaluation of ibuprofen treatment and axonal injury in acute studies. However, because the ibuprofen treated chow was dyed green, we were able to confirm by fecal samples that all ibuprofen treated mice had eaten the ibuprofen supplemented chow between the first and second injury. In order to reduce the risk of worsening behavioral outcomes with chronic ibuprofen administration as has been previously reported following TBI (Browne, Iwata et al. 2006) we provided ibuprofen supplemented chow to $Grn^{-/-}$ mice for only two weeks following the first injury. Without an acute evaluation of $Grn^{-/-}$ mice treated with ibuprofen it is impossible to prove that ibuprofen was effective in reducing the microglial response while on board. However, data from wildtype treated animals is supportive. Alternatively to ibuprofen, a more specific target of microglia might limit the consequences of chronic neurodegeneration. The p38a microtubule associated protein kinase (MAPK) has been implicated as an important regulator of microglial activation

and can limit the acute phase of cytokine expression following TBI (Bachstetter, Rowe et al. 2013). However studies using an inducible model of macrophage depletion following head injury were unable to effectively reduce acute white matter axonal injury despite reducing the microglial expression of pro-inflammatory cytokines and chemokines (Bennett, 2014). Taken together, these studies suggest that a better alternative would be to reduce the secondary injury mechanisms that lead to axonal degeneration and thereby reducing the microglial response.

Future Directions

Collectively, our studies provide evidence for increased axonal injury and neurodegeneration following repeated mild TBI that is not influenced chronically by the amount of microgliosis following injury. Entorhinal cortex pathology is observed acutely after injury, and while cell death and inflammation are resolved shortly after injury, the injury may have induced more subtle, but longer lasting cellular consequences that are not readily observed by our approach. Future studies should evaluate expression of synaptic markers to determine if a loss of synapses has occurred following injury, or electrophysiology could be incorporated to evaluate the health of intact neurons and their ability to signal post-synaptic neurons. Neurogenesis has been implicated in the formation of new memories, and TBI can cause death of newborn neurons. In our study, we did not observe cell death in the dentate gyrus. However, a decrease in the amount of newborn neurons or inability for the neurons to integrate may effectively inhibit memory dysfunction. The ability for many studies to show transient behavioral deficits suggests that the consequences of mild TBI are reversible if given enough time. Any of these

evaluations should also be evaluated in animals with a single head injury in order to evaluate if the effects are exacerbated with repeated injuries.

While we were unable to reproduce TDP43 pathology in progranulin-deficient mice and thereby develop a model of CTE-like pathology, future studies could explore other pathological features of progranulin-deficient mice such as the accumulation of ubiquitinated proteins and lipofuscin. An increase in these markers following repeated head injury would suggest that cellular mechanisms of degradation are worsened by mild TBI. Impaired lysosomal mechanisms due to injury could contribute to an earlier buildup of proteins and may lead to a younger age at death. Thus future studies could also evaluate the rate of mortality following a single and repeated mild TBI compared to naïve animals.

APPENDIX 1: Permission for Article Reprint for Chapter 2.

**OXFORD UNIVERSITY PRESS LICENSE
TERMS AND CONDITIONS**

Apr 03, 2016

This is a License Agreement between Amanda N Bolton Hall ("You") and Oxford University Press ("Oxford University Press") provided by Copyright Clearance Center ("CCC"). The license consists of your order details, the terms and conditions provided by Oxford University Press, and the payment terms and conditions.

All payments must be made in full to CCC. For payment instructions, please see information listed at the bottom of this form.

License Number	3841381242586
License date	Apr 03, 2016
Licensed content publisher	Oxford University Press
Licensed content publication	Journal of Neuropathology and Experimental Neurology
Licensed content title	Regional Neurodegeneration and Gliosis Are Amplified by Mild Traumatic Brain Injury Repeated at 24-Hour Intervals
Licensed content author	Amanda N. Bolton, Kathryn E. Saatman
Licensed content date	2014-10-01
Type of Use	Thesis/Dissertation
Institution name	None
Title of your work	HISTOLOGICAL AND BEHAVIORAL CONSEQUENCES OF REPEATED MILD TRAUMATIC BRAIN INJURY IN MICE
Publisher of your work	n/a
Expected publication date	Apr 2016
Permissions cost	0.00 USD
Value added tax	0.00 USD
Total	0.00 USD
Total	0.00 USD
Terms and Conditions	

STANDARD TERMS AND CONDITIONS FOR REPRODUCTION OF MATERIAL FROM AN OXFORD UNIVERSITY PRESS JOURNAL

1. Use of the material is restricted to the type of use specified in your order details.
2. This permission covers the use of the material in the English language in the following territory: world. If you have requested additional permission to translate this material, the terms and conditions of this reuse will be set out in clause 12.
3. This permission is limited to the particular use authorized in (1) above and does not allow you to sanction its use elsewhere in any other format other than specified above, nor does it apply to quotations, images, artistic works etc that have been reproduced from other sources which may be part of the material to be used.
4. No alteration, omission or addition is made to the material without our written consent. Permission must be re-cleared with Oxford University Press if/when you decide to reprint.
5. The following credit line appears wherever the material is used: author, title, journal, year, volume, issue number, pagination, by permission of Oxford University Press or the sponsoring society if the journal is a society journal. Where a journal is being published on behalf of a learned society, the details of that society must be included in the credit line.
6. For the reproduction of a full article from an Oxford University Press journal for whatever purpose, the corresponding author of the material concerned should be informed of the proposed use. Contact details for the corresponding authors of all Oxford University Press journal contact can be found alongside either the abstract or full text of the article concerned, accessible from www.oxfordjournals.org Should there be a problem clearing these rights, please contact journals.permissions@oup.com
7. If the credit line or acknowledgement in our publication indicates that any of the figures, images or photos was reproduced, drawn or modified from an earlier source it will be necessary for you to clear this permission with the original publisher as well. If this permission has not been obtained, please note that this material cannot be included in your publication/photocopies.
8. While you may exercise the rights licensed immediately upon issuance of the license at the end of the licensing process for the transaction, provided that you have disclosed complete and accurate details of your proposed use, no license is finally effective unless and until full payment is received from you (either by Oxford University Press or by Copyright Clearance Center (CCC)) as provided in CCC's Billing and Payment terms and conditions. If full payment is not received on a timely basis, then any license preliminarily granted shall be deemed automatically revoked and shall be void as if never granted. Further, in the event that you breach any of these terms and conditions or any of CCC's Billing and Payment terms and conditions, the license is automatically revoked and shall be void as if never granted. Use of materials as described in a revoked license, as well as any use of the materials beyond the scope of an unrevoked license, may constitute copyright infringement and Oxford University Press reserves the right to take any and all action to protect its copyright in the materials.
9. This license is personal to you and may not be sublicensed, assigned or transferred by you to any other person without Oxford University Press's written permission.
10. Oxford University Press reserves all rights not specifically granted in the combination of (i) the license details provided by you and accepted in the course of this licensing transaction, (ii) these terms and conditions and (iii) CCC's Billing and Payment terms and conditions.
11. You hereby indemnify and agree to hold harmless Oxford University Press and CCC, and their respective officers, directors, employs and agents, from and against any and all claims arising out of your use of the licensed material other than as specifically authorized pursuant to this license.
12. Other Terms and Conditions:

v1.4

REFERENCES

- Adams, S. S., P. Bresloff, et al. (1976). "Pharmacological differences between the optical isomers of ibuprofen: evidence for metabolic inversion of the (-)-isomer." J Pharm Pharmacol **28**(3): 256-257.
- Adams, S. S., E. E. Cliffe, et al. (1967). "Some biological properties of 2-(4-isoburylphenyl)-propionic acid." J Pharm Sci **56**(12): 1686.
- Adams, S. S., K. F. McCullough, et al. (1969). "The pharmacological properties of ibuprofen, an anti-inflammatory, analgesic and antipyretic agent." Arch Int Pharmacodyn Ther **178**(1): 115-129.
- Agrawal, A., J. Timothy, et al. (2006). "Post-traumatic epilepsy: an overview." Clin Neurol Neurosurg **108**(5): 433-439.
- Ahmed, Z., I. R. Mackenzie, et al. (2007). "Progranulin in frontotemporal lobar degeneration and neuroinflammation." J Neuroinflammation **4**: 7.
- Ahmed, Z., H. Sheng, et al. (2010). "Accelerated lipofuscinosis and ubiquitination in granulin knockout mice suggest a role for progranulin in successful aging." Am J Pathol **177**(1): 311-324.
- Alves, W., S. Macciocchi, et al. (1993). "Postconcussive symptoms after uncomplicated mild head injury." J Head Trauma Rehabil **8**(3).
- Amende, I., A. Kale, et al. (2005). "Gait dynamics in mouse models of Parkinson's disease and Huntington's disease." J Neuroeng Rehabil **2**: 20.
- Andersen, K., L. J. Launer, et al. (1995). "Do nonsteroidal anti-inflammatory drugs decrease the risk for Alzheimer's disease? The Rotterdam Study." Neurology **45**(8): 1441-1445.
- Antezana, D. F., R. E. Clatterbuck, et al. (2003). "High-dose ibuprofen for reduction of striatal infarcts during middle cerebral artery occlusion in rats." J Neurosurg **98**(4): 860-866.
- Anthony, J. C., J. C. Breitner, et al. (2000). "Reduced prevalence of AD in users of NSAIDs and H2 receptor antagonists: the Cache County study." Neurology **54**(11): 2066-2071.
- Arai, T., M. Hasegawa, et al. (2006). "TDP-43 is a component of ubiquitin-positive tau-negative inclusions in frontotemporal lobar degeneration and amyotrophic lateral sclerosis." Biochem Biophys Res Commun **351**(3): 602-611.
- Araujo, I. M., B. P. Carreira, et al. (2010). "Calpains and delayed calcium deregulation in excitotoxicity." Neurochem Res **35**(12): 1966-1969.
- Arends, Y. M., C. Duyckaerts, et al. (2000). "Microglia, amyloid and dementia in alzheimer disease. A correlative study." Neurobiol Aging **21**(1): 39-47.
- Arnold, S. E., L. Y. Han, et al. (2000). "Quantitative neurohistological features of frontotemporal degeneration." Neurobiol Aging **21**(6): 913-919.
- Aungst, S. L., S. V. Kabadi, et al. (2014). "Repeated mild traumatic brain injury causes chronic neuroinflammation, changes in hippocampal synaptic plasticity, and associated cognitive deficits." J Cereb Blood Flow Metab **34**(7): 1223-1232.
- Ayala, Y. M., T. Misteli, et al. (2008). "TDP-43 regulates retinoblastoma protein phosphorylation through the repression of cyclin-dependent kinase 6 expression." Proc Natl Acad Sci U S A **105**(10): 3785-3789.

- Baba, T., H. B. Hoff, 3rd, et al. (1993). "Acrogranin, an acrosomal cysteine-rich glycoprotein, is the precursor of the growth-modulating peptides, granulins, and epithelins, and is expressed in somatic as well as male germ cells." Mol Reprod Dev **34**(3): 233-243.
- Bachstetter, A. D., R. K. Rowe, et al. (2013). "The p38alpha MAPK regulates microglial responsiveness to diffuse traumatic brain injury." J Neurosci **33**(14): 6143-6153.
- Balaratnasingam, C., W. H. Morgan, et al. (2010). "Time-dependent effects of focal retinal ischemia on axonal cytoskeleton proteins." Invest Ophthalmol Vis Sci **51**(6): 3019-3028.
- Bardehle, S., M. Kruger, et al. (2013). "Live imaging of astrocyte responses to acute injury reveals selective juxtavascular proliferation." Nat Neurosci **16**(5): 580-586.
- Bateman, A., D. Belcourt, et al. (1990). "Granulins, a novel class of peptide from leukocytes." Biochem Biophys Res Commun **173**(3): 1161-1168.
- Bateman, A. and H. P. Bennett (2009). "The granulin gene family: from cancer to dementia." Bioessays **31**(11): 1245-1254.
- Bennett, R. E. and D. L. Brody (2014). "Acute reduction of microglia does not alter axonal injury in a mouse model of repetitive concussive traumatic brain injury." J Neurotrauma **31**(19): 1647-1663.
- Bennett, R. E., C. L. Mac Donald, et al. (2012). "Diffusion tensor imaging detects axonal injury in a mouse model of repetitive closed-skull traumatic brain injury." Neurosci Lett **513**(2): 160-165.
- Bernardi, P. (1996). "The permeability transition pore. Control points of a cyclosporin A-sensitive mitochondrial channel involved in cell death." Biochim Biophys Acta **1275**(1-2): 5-9.
- Bertelli, A. and G. Soldani (1979). "Polymyxin B-induced oedema in hind paw of the rat as an assay for antiinflammatory drugs." Arzneimittelforschung **29**(5): 777-778.
- Beschorner, R., P. Simon, et al. (2007). "Reactive astrocytes and activated microglial cells express EAAT1, but not EAAT2, reflecting a neuroprotective potential following ischaemia." Histopathology **50**(7): 897-910.
- Bhandari, V., R. Daniel, et al. (1996). "Structural and functional analysis of a promoter of the human granulin/epithelin gene." Biochem J **319** (Pt 2): 441-447.
- Bhandari, V., A. Giaid, et al. (1993). "The complementary deoxyribonucleic acid sequence, tissue distribution, and cellular localization of the rat granulin precursor." Endocrinology **133**(6): 2682-2689.
- Bhandari, V., R. G. Palfree, et al. (1992). "Isolation and sequence of the granulin precursor cDNA from human bone marrow reveals tandem cysteine-rich granulin domains." Proc Natl Acad Sci U S A **89**(5): 1715-1719.
- Blasko, I., A. Apochal, et al. (2001). "Ibuprofen decreases cytokine-induced amyloid beta production in neuronal cells." Neurobiol Dis **8**(6): 1094-1101.
- Block, M. L. and J. S. Hong (2005). "Microglia and inflammation-mediated neurodegeneration: multiple triggers with a common mechanism." Prog Neurobiol **76**(2): 77-98.
- Bolton, A. N. and K. E. Saatman (2014). "Regional neurodegeneration and gliosis are amplified by mild traumatic brain injury repeated at 24-hour intervals." J Neuropathol Exp Neurol **73**(10): 933-947.

- Borg, J., L. Holm, et al. (2004). "Diagnostic procedures in mild traumatic brain injury: results of the WHO Collaborating Centre Task Force on Mild Traumatic Brain Injury." J Rehabil Med(43 Suppl): 61-75.
- Bouida, W., S. Marghli, et al. (2013). "Prediction value of the Canadian CT head rule and the New Orleans criteria for positive head CT scan and acute neurosurgical procedures in minor head trauma: a multicenter external validation study." Ann Emerg Med **61**(5): 521-527.
- Boya, P., R. A. Gonzalez-Polo, et al. (2003). "Mitochondrial membrane permeabilization is a critical step of lysosome-initiated apoptosis induced by hydroxychloroquine." Oncogene **22**(25): 3927-3936.
- Boyle, E. A. and P. L. McGeer (1990). "Cellular immune response in multiple sclerosis plaques." Am J Pathol **137**(3): 575-584.
- Bramlett, H. M. and W. D. Dietrich (2015). "Long-Term Consequences of Traumatic Brain Injury: Current Status of Potential Mechanisms of Injury and Neurological Outcomes." J Neurotrauma **32**(23): 1834-1848.
- Brody, D. L., J. Benetatos, et al. (2015). "The pathophysiology of repetitive concussive traumatic brain injury in experimental models; new developments and open questions." Mol Cell Neurosci **66**(Pt B): 91-98.
- Browne, K. D., A. Iwata, et al. (2006). "Chronic ibuprofen administration worsens cognitive outcome following traumatic brain injury in rats." Exp Neurol **201**(2): 301-307.
- Bullock, R. (1995). "Strategies for neuroprotection with glutamate antagonists. Extrapolating from evidence taken from the first stroke and head injury studies." Ann N Y Acad Sci **765**: 272-278; discussion 298.
- Buratti, E. and F. E. Baralle (2001). "Characterization and functional implications of the RNA binding properties of nuclear factor TDP-43, a novel splicing regulator of CFTR exon 9." J Biol Chem **276**(39): 36337-36343.
- Bush, T. G., N. Puvanachandra, et al. (1999). "Leukocyte infiltration, neuronal degeneration, and neurite outgrowth after ablation of scar-forming, reactive astrocytes in adult transgenic mice." Neuron **23**(2): 297-308.
- Cadieux, B., B. P. Chitramuthu, et al. (2005). "The zebrafish progranulin gene family and antisense transcripts." BMC Genomics **6**: 156.
- Campbell, M., F. Hanrahan, et al. (2012). "Targeted suppression of claudin-5 decreases cerebral oedema and improves cognitive outcome following traumatic brain injury." Nat Commun **3**: 849.
- Cao, T., T. C. Thomas, et al. (2012). "Morphological and genetic activation of microglia after diffuse traumatic brain injury in the rat." Neuroscience **225**: 65-75.
- Carrasco, E., D. Casper, et al. (2005). "Dopaminergic neurotoxicity by 6-OHDA and MPP+: differential requirement for neuronal cyclooxygenase activity." J Neurosci Res **81**(1): 121-131.
- CDC (2003). "Report to Congress on Mild Traumatic Brain Injury in the United States: Steps to Prevent a Serious Public Health Problem." Prevention CfDCA (ed). Centers for Disease Control and Prevention, Atlanta, GA: 1-47.
- CDC (2015). "Traumatic Brain Injury in the United States: Epidemiology and Rehabilitation." Prevention CfDCA (ed). Centers for Disease Control and Prevention, Atlanta, GA.

- Cernak, I., J. Savic, et al. (1996). "Involvement of the central nervous system in the general response to pulmonary blast injury." J Trauma **40**(3 Suppl): S100-104.
- Chapman, D. P., S. M. Williams, et al. (2006). "Dementia and its implications for public health." Prev Chronic Dis **3**(2): A34.
- Chen, H. J., D. J. Huang, et al. (2006). "Molecular cloning and characterization of a granulin-containing cysteine protease SPCP3 from sweet potato (*Ipomoea batatas*) senescent leaves." J Plant Physiol **163**(8): 863-876.
- Chen, M. K. and T. R. Guilarte (2006). "Imaging the peripheral benzodiazepine receptor response in central nervous system demyelination and remyelination." Toxicol Sci **91**(2): 532-539.
- Chen, R., L. Yang, et al. (2007). "Cytotoxic phospholipid oxidation products. Cell death from mitochondrial damage and the intrinsic caspase cascade." J Biol Chem **282**(34): 24842-24850.
- Chen, X., J. Chang, et al. (2013). "Progranulin does not bind tumor necrosis factor (TNF) receptors and is not a direct regulator of TNF-dependent signaling or bioactivity in immune or neuronal cells." J Neurosci **33**(21): 9202-9213.
- Chen, X. H., V. E. Johnson, et al. (2009). "A lack of amyloid beta plaques despite persistent accumulation of amyloid beta in axons of long-term survivors of traumatic brain injury." Brain Pathol **19**(2): 214-223.
- Chen, X. Y., J. S. Li, et al. (2008). "Expression of PC cell-derived growth factor and vascular endothelial growth factor in esophageal squamous cell carcinoma and their clinicopathologic significance." Chin Med J (Engl) **121**(10): 881-886.
- Chen, Y., S. Constantini, et al. (1996). "An experimental model of closed head injury in mice: pathophysiology, histopathology, and cognitive deficits." J Neurotrauma **13**(10): 557-568.
- Chen, Y., H. Mao, et al. (2014). "A modified controlled cortical impact technique to model mild traumatic brain injury mechanics in mice." Front Neurol **5**: 100.
- Chen, Y. and R. A. Swanson (2003). "Astrocytes and brain injury." J Cereb Blood Flow Metab **23**(2): 137-149.
- Chen, Z., L. Y. Leung, et al. (2012). "A novel animal model of closed-head concussive-induced mild traumatic brain injury: development, implementation, and characterization." J Neurotrauma **29**(2): 268-280.
- Cheng, J. S., R. Craft, et al. (2014). "Tau reduction diminishes spatial learning and memory deficits after mild repetitive traumatic brain injury in mice." PLoS One **9**(12): e115765.
- Cheung, S. T., S. Y. Wong, et al. (2004). "Granulin-epithelin precursor overexpression promotes growth and invasion of hepatocellular carcinoma." Clin Cancer Res **10**(22): 7629-7636.
- Chio, A., G. Benzi, et al. (2005). "Severely increased risk of amyotrophic lateral sclerosis among Italian professional football players." Brain **128**(Pt 3): 472-476.
- Chodobski, A., B. J. Zink, et al. (2011). "Blood-brain barrier pathophysiology in traumatic brain injury." Transl Stroke Res **2**(4): 492-516.
- Cole, D. J., P. M. Patel, et al. (1993). "Temporary focal cerebral ischemia in spontaneously hypertensive rats: the effect of ibuprofen on infarct volume." J Pharmacol Exp Ther **266**(3): 1713-1717.

- Corsellis, J. A., C. J. Bruton, et al. (1973). "The aftermath of boxing." Psychol Med **3**(3): 270-303.
- Creed, J. A., A. M. DiLeonardi, et al. (2011). "Concussive brain trauma in the mouse results in acute cognitive deficits and sustained impairment of axonal function." J Neurotrauma **28**(4): 547-563.
- Creeley, C. E., D. F. Wozniak, et al. (2004). "Multiple episodes of mild traumatic brain injury result in impaired cognitive performance in mice." Acad Emerg Med **11**(8): 809-819.
- Critchley, M. (1957). "Medical aspects of boxing, particularly from a neurological standpoint." Br Med J **1**(5015): 357-362.
- Cullheim, S. and S. Thams (2007). "The microglial networks of the brain and their role in neuronal network plasticity after lesion." Brain Res Rev **55**(1): 89-96.
- Dardiotis, E., G. M. Hadjigeorgiou, et al. (2008). "Alpha-1 antichymotrypsin gene signal peptide a/t polymorphism and primary intracerebral hemorrhage." Eur Neurol **59**(6): 307-314.
- Dash, P. K., S. A. Mach, et al. (2000). "Regional expression and role of cyclooxygenase-2 following experimental traumatic brain injury." J Neurotrauma **17**(1): 69-81.
- Davies, N. M. (1998). "Clinical pharmacokinetics of ibuprofen. The first 30 years." Clin Pharmacokinet **34**(2): 101-154.
- de Hoz, R., B. I. Gallego, et al. (2013). "Rod-like microglia are restricted to eyes with laser-induced ocular hypertension but absent from the microglial changes in the contralateral untreated eye." PLoS One **8**(12): e83733.
- de Olmos, J. S., C. A. Beltramino, et al. (1994). "Use of an amino-cupric-silver technique for the detection of early and semiacute neuronal degeneration caused by neurotoxicants, hypoxia, and physical trauma." Neurotoxicol Teratol **16**(6): 545-561.
- DeFord, S. M., M. S. Wilson, et al. (2002). "Repeated mild brain injuries result in cognitive impairment in B6C3F1 mice." J Neurotrauma **19**(4): 427-438.
- del Zoppo, G. J. and T. Mabuchi (2003). "Cerebral microvessel responses to focal ischemia." J Cereb Blood Flow Metab **23**(8): 879-894.
- DeRoss, A. L., J. E. Adams, et al. (2002). "Multiple head injuries in rats: effects on behavior." J Trauma **52**(4): 708-714.
- Deutsch, M. B., M. F. Mendez, et al. (2015). "Interactions between traumatic brain injury and frontotemporal degeneration." Dement Geriatr Cogn Disord **39**(3-4): 143-153.
- Dewitt, D. S., R. Perez-Polo, et al. (2013). "Challenges in the development of rodent models of mild traumatic brain injury." J Neurotrauma **30**(9): 688-701.
- Dikranian, K., R. Cohen, et al. (2008). "Mild traumatic brain injury to the infant mouse causes robust white matter axonal degeneration which precedes apoptotic death of cortical and thalamic neurons." Exp Neurol **211**(2): 551-560.
- Diniz, L. P., J. C. Almeida, et al. (2012). "Astrocyte-induced synaptogenesis is mediated by transforming growth factor beta signaling through modulation of D-serine levels in cerebral cortex neurons." J Biol Chem **287**(49): 41432-41445.
- Dixon, C. E., B. G. Lyeth, et al. (1987). "A fluid percussion model of experimental brain injury in the rat." J Neurosurg **67**(1): 110-119.

- Duthie, E. H., Jr. and S. L. Glatt (1988). "Understanding and treating multi-infarct dementia." Clin Geriatr Med **4**(4): 749-766.
- Eichinger, L., J. A. Pachebat, et al. (2005). "The genome of the social amoeba *Dictyostelium discoideum*." Nature **435**(7038): 43-57.
- Elsisi, N. S., S. Darling-Reed, et al. (2005). "Ibuprofen and apigenin induce apoptosis and cell cycle arrest in activated microglia." Neurosci Lett **375**(2): 91-96.
- Emery, C., J. Kang, et al. (2011). "Risk of injury associated with bodychecking experience among youth hockey players." CMAJ **183**(11): 1249-1256.
- Etemadi, N., A. Webb, et al. (2013). "Progranulin does not inhibit TNF and lymphotoxin-alpha signalling through TNF receptor 1." Immunol Cell Biol **91**(10): 661-664.
- Faden, A. I., P. Demediuk, et al. (1989). "The role of excitatory amino acids and NMDA receptors in traumatic brain injury." Science **244**(4906): 798-800.
- Faden, A. I. and D. J. Loane (2015). "Chronic neurodegeneration after traumatic brain injury: Alzheimer disease, chronic traumatic encephalopathy, or persistent neuroinflammation?" Neurotherapeutics **12**(1): 143-150.
- Farkas, O. and J. T. Povlishock (2007). "Cellular and subcellular change evoked by diffuse traumatic brain injury: a complex web of change extending far beyond focal damage." Prog Brain Res **161**: 43-59.
- Faul M, X. L., Wald MM, Coronado VG (2010). Traumatic Brain Injury in the United States: Emergency Department Visits, Hospitalizations, and Deaths 2002-2006. C. f. D. C. a. Prevention. Atlanta, National Center for Injury Prevention and Control.
- Febinger, H. Y., H. E. Thomasy, et al. (2015). "Time-dependent effects of CX3CR1 in a mouse model of mild traumatic brain injury." J Neuroinflammation **12**: 154.
- Finkelstein, E., P. Corso, et al. (2006). The Incidence and Economic Burden of Injuries in the United States., New York: Oxford University Press.
- Foda, M. A. and A. Marmarou (1994). "A new model of diffuse brain injury in rats. Part II: Morphological characterization." J Neurosurg **80**(2): 301-313.
- Fox, M. W. (1965). "The visual cliff test for the study of visual depth perception in the mouse." Anim Behav **13**(2): 232-233.
- Frank, G. B. and H. D. Sanders (1963). "A Proposed Common Mechanism of Action for General and Local Anaesthetics in the Central Nervous System." Br J Pharmacol Chemother **21**: 1-9.
- Friess, S. H., R. N. Ichord, et al. (2009). "Repeated traumatic brain injury affects composite cognitive function in piglets." J Neurotrauma **26**(7): 1111-1121.
- Frugier, T., M. C. Morganti-Kossmann, et al. (2010). "In situ detection of inflammatory mediators in post mortem human brain tissue after traumatic injury." J Neurotrauma **27**(3): 497-507.
- Fujita, M., E. P. Wei, et al. (2012). "Intensity- and interval-specific repetitive traumatic brain injury can evoke both axonal and microvascular damage." J Neurotrauma **29**(12): 2172-2180.
- Gao, X., A. P. Joselin, et al. (2010). "Progranulin promotes neurite outgrowth and neuronal differentiation by regulating GSK-3beta." Protein Cell **1**(6): 552-562.
- Gavett, B. E., R. A. Stern, et al. (2011). "Chronic traumatic encephalopathy: a potential late effect of sport-related concussive and subconcussive head trauma." Clin Sports Med **30**(1): 179-188, xi.

- Geddes, J. F., G. H. Vowles, et al. (1999). "Neuronal cytoskeletal changes are an early consequence of repetitive head injury." Acta Neuropathol **98**(2): 171-178.
- Ghoshal, N., J. T. Dearborn, et al. (2012). "Core features of frontotemporal dementia recapitulated in progranulin knockout mice." Neurobiol Dis **45**(1): 395-408.
- Gibson, E. J. and R. D. Walk (1960). "The "visual cliff"." Sci Am **202**: 64-71.
- Girgis, H., B. Palmier, et al. (2013). "Effects of selective and non-selective cyclooxygenase inhibition against neurological deficit and brain oedema following closed head injury in mice." Brain Res **1491**: 78-87.
- Giza, C. C., J. S. Kutcher, et al. (2013). "Summary of evidence-based guideline update: evaluation and management of concussion in sports: report of the Guideline Development Subcommittee of the American Academy of Neurology." Neurology **80**(24): 2250-2257.
- Godena, V. K., G. Romano, et al. (2011). "TDP-43 regulates Drosophila neuromuscular junctions growth by modulating Futsch/MAP1B levels and synaptic microtubules organization." PLoS One **6**(3): e17808.
- Goldlust, M. B. and L. C. Rich (1981). "Chronic immune synovitis in rabbits. II. Modulation by anti-inflammatory and anti-rheumatic agents." Agents Actions **11**(6-7): 729-735.
- Goldstein, L. E., A. M. Fisher, et al. (2012). "Chronic traumatic encephalopathy in blast-exposed military veterans and a blast neurotrauma mouse model." Sci Transl Med **4**(134): 134ra160.
- Gopez, J. J., H. Yue, et al. (2005). "Cyclooxygenase-2-specific inhibitor improves functional outcomes, provides neuroprotection, and reduces inflammation in a rat model of traumatic brain injury." Neurosurgery **56**(3): 590-604.
- Gorina, R., M. Font-Nieves, et al. (2011). "Astrocyte TLR4 activation induces a proinflammatory environment through the interplay between MyD88-dependent NFkappaB signaling, MAPK, and Jak1/Stat1 pathways." Glia **59**(2): 242-255.
- Greenberg, S. G., P. Davies, et al. (1992). "Hydrofluoric acid-treated tau PHF proteins display the same biochemical properties as normal tau." J Biol Chem **267**(1): 564-569.
- Grice, S. C., E. T. Chappell, et al. (1987). "Ibuprofen improves cerebral blood flow after global cerebral ischemia in dogs." Stroke **18**(4): 787-791.
- Gronwall, D. and P. Wrightson (1975). "Cumulative effect of concussion." Lancet **2**(7943): 995-997.
- Guskiewicz, K. M., S. W. Marshall, et al. (2007). "Recurrent concussion and risk of depression in retired professional football players." Med Sci Sports Exerc **39**(6): 903-909.
- Guskiewicz, K. M., N. L. Weaver, et al. (2000). "Epidemiology of concussion in collegiate and high school football players." Am J Sports Med **28**(5): 643-650.
- Hakan, T., H. Z. Toklu, et al. (2010). "Effect of COX-2 inhibitor meloxicam against traumatic brain injury-induced biochemical, histopathological changes and blood-brain barrier permeability." Neurol Res **32**(6): 629-635.
- Hall, E. D., T. R. Gibson, et al. (2005). "Lack of a gender difference in post-traumatic neurodegeneration in the mouse controlled cortical impact injury model." J Neurotrauma **22**(6): 669-679.

- Hanisch, U. K. and H. Kettenmann (2007). "Microglia: active sensor and versatile effector cells in the normal and pathologic brain." Nat Neurosci **10**(11): 1387-1394.
- Hanlon, R. E., J. A. Demery, et al. (1999). "Effects of acute injury characteristics on neuropsychological status and vocational outcome following mild traumatic brain injury." Brain Inj **13**(11): 873-887.
- Hardman, R., D. J. Evans, et al. (1997). "Evidence for recovery of spatial learning following entorhinal cortex lesions in mice." Brain Res **758**(1-2): 187-200.
- Harmon, K. G., J. A. Drezner, et al. (2013). "American Medical Society for Sports Medicine position statement: concussion in sport." Br J Sports Med **47**(1): 15-26.
- Harrison, J. L., R. K. Rowe, et al. (2014). "Acute over-the-counter pharmacological intervention does not adversely affect behavioral outcome following diffuse traumatic brain injury in the mouse." Exp Brain Res **232**(9): 2709-2719.
- He, Z. and A. Bateman (1999). "Progranulin gene expression regulates epithelial cell growth and promotes tumor growth in vivo." Cancer Res **59**(13): 3222-3229.
- He, Z. and A. Bateman (2003). "Progranulin (granulin-epithelin precursor, PC-cell-derived growth factor, acrogranin) mediates tissue repair and tumorigenesis." J Mol Med (Berl) **81**(10): 600-612.
- He, Z., A. Ismail, et al. (2002). "Progranulin (PC-cell-derived growth factor/acrogranin) regulates invasion and cell survival." Cancer Res **62**(19): 5590-5596.
- Hebert, L. E., J. Weuve, et al. (2013). "Alzheimer disease in the United States (2010-2050) estimated using the 2010 census." Neurology **80**(19): 1778-1783.
- Hellewell, S. C., E. B. Yan, et al. (2010). "Post-traumatic hypoxia exacerbates brain tissue damage: analysis of axonal injury and glial responses." J Neurotrauma **27**(11): 1997-2010.
- Heneka, M. T., M. Sastre, et al. (2005). "Acute treatment with the PPARgamma agonist pioglitazone and ibuprofen reduces glial inflammation and Abeta1-42 levels in APPV717I transgenic mice." Brain **128**(Pt 6): 1442-1453.
- Herrmann, J. E., T. Imura, et al. (2008). "STAT3 is a critical regulator of astrogliosis and scar formation after spinal cord injury." J Neurosci **28**(28): 7231-7243.
- Hickey, R. W., P. D. Adelson, et al. (2007). "Cyclooxygenase-2 activity following traumatic brain injury in the developing rat." Pediatr Res **62**(3): 271-276.
- Holmin, S. and T. Mathiesen (1999). "Long-term intracerebral inflammatory response after experimental focal brain injury in rat." Neuroreport **10**(9): 1889-1891.
- Holsinger, T., D. C. Steffens, et al. (2002). "Head injury in early adulthood and the lifetime risk of depression." Arch Gen Psychiatry **59**(1): 17-22.
- Horner, M. D., P. L. Ferguson, et al. (2005). "Patterns of alcohol use 1 year after traumatic brain injury: a population-based, epidemiological study." J Int Neuropsychol Soc **11**(3): 322-330.
- Hrabal, R., Z. Chen, et al. (1996). "The hairpin stack fold, a novel protein architecture for a new family of protein growth factors." Nat Struct Biol **3**(9): 747-752.
- Hu, X., P. Li, et al. (2012). "Microglia/macrophage polarization dynamics reveal novel mechanism of injury expansion after focal cerebral ischemia." Stroke **43**(11): 3063-3070.

- Huh, J. W., A. G. Widing, et al. (2007). "Basic science; repetitive mild non-contusive brain trauma in immature rats exacerbates traumatic axonal injury and axonal calpain activation: a preliminary report." *J Neurotrauma* **24**(1): 15-27.
- Huh, J. W., A. G. Widing, et al. (2008). "Midline brain injury in the immature rat induces sustained cognitive deficits, bihemispheric axonal injury and neurodegeneration." *Exp Neurol* **213**(1): 84-92.
- Huynh, T., D. G. Jacobs, et al. (2006). "Utility of neurosurgical consultation for mild traumatic brain injury." *Am Surg* **72**(12): 1162-1165; discussion 1166-1167.
- Ichas, F. and J. P. Mazat (1998). "From calcium signaling to cell death: two conformations for the mitochondrial permeability transition pore. Switching from low- to high-conductance state." *Biochim Biophys Acta* **1366**(1-2): 33-50.
- Imai, Y., I. Iбата, et al. (1996). "A novel gene *iba1* in the major histocompatibility complex class III region encoding an EF hand protein expressed in a monocytic lineage." *Biochem Biophys Res Commun* **224**(3): 855-862.
- Irwin, D., C. F. Lippa, et al. (2009). "Progranulin (PGRN) expression in ALS: an immunohistochemical study." *J Neurol Sci* **276**(1-2): 9-13.
- Jacobus, W. E., R. Tiozzo, et al. (1975). "Aspects of energy-linked calcium accumulation by rat heart mitochondria." *J Biol Chem* **250**(19): 7863-7870.
- Jantzen, P. T., K. E. Connor, et al. (2002). "Microglial activation and beta -amyloid deposit reduction caused by a nitric oxide-releasing nonsteroidal anti-inflammatory drug in amyloid precursor protein plus presenilin-1 transgenic mice." *J Neurosci* **22**(6): 2246-2254.
- Jennett, B., G. Teasdale, et al. (1976). "Predicting outcome in individual patients after severe head injury." *Lancet* **1**(7968): 1031-1034.
- Jin, X., J. Liu, et al. (2012). "Spatiotemporal evolution of blood brain barrier damage and tissue infarction within the first 3h after ischemia onset." *Neurobiol Dis* **48**(3): 309-316.
- Kalkonde, Y. V., A. Jawaid, et al. (2012). "Medical and environmental risk factors associated with frontotemporal dementia: a case-control study in a veteran population." *Alzheimers Dement* **8**(3): 204-210.
- Kane, M. J., M. Angoa-Perez, et al. (2012). "A mouse model of human repetitive mild traumatic brain injury." *J Neurosci Methods* **203**(1): 41-49.
- Kao, A. W., R. J. Eisenhut, et al. (2011). "A neurodegenerative disease mutation that accelerates the clearance of apoptotic cells." *Proc Natl Acad Sci U S A* **108**(11): 4441-4446.
- Karve, I. P., J. M. Taylor, et al. (2016). "The contribution of astrocytes and microglia to traumatic brain injury." *Br J Pharmacol* **173**(4): 692-702.
- Kaufmann, W. E., K. I. Andreasson, et al. (1997). "Cyclooxygenases and the central nervous system." *Prostaglandins* **54**(3): 601-624.
- Kawamata, T., H. Akiyama, et al. (1992). "Immunologic reactions in amyotrophic lateral sclerosis brain and spinal cord tissue." *Am J Pathol* **140**(3): 691-707.
- Kayasuga, Y., S. Chiba, et al. (2007). "Alteration of behavioural phenotype in mice by targeted disruption of the progranulin gene." *Behav Brain Res* **185**(2): 110-118.
- Khuman, J., W. P. Meehan, 3rd, et al. (2011). "Tumor necrosis factor alpha and Fas receptor contribute to cognitive deficits independent of cell death after concussive traumatic brain injury in mice." *J Cereb Blood Flow Metab* **31**(2): 778-789.

- Kiernan, P. T., P. H. Montenegro, et al. (2015). "Chronic traumatic encephalopathy: a neurodegenerative consequence of repetitive traumatic brain injury." Semin Neurol **35**(1): 20-28.
- Kojo, H., M. Fukagawa, et al. (2003). "Evaluation of human peroxisome proliferator-activated receptor (PPAR) subtype selectivity of a variety of anti-inflammatory drugs based on a novel assay for PPAR delta(beta)." J Pharmacol Sci **93**(3): 347-355.
- Kraft, A. W., X. Hu, et al. (2013). "Attenuating astrocyte activation accelerates plaque pathogenesis in APP/PS1 mice." FASEB J **27**(1): 187-198.
- Kraus, J. F. and P. Nourjah (1988). "The epidemiology of mild, uncomplicated brain injury." J Trauma **28**(12): 1637-1643.
- Krishnamurthy, K. and D. T. Laskowitz (2016). Cellular and Molecular Mechanisms of Secondary Neuronal Injury following Traumatic Brain Injury. Translational Research in Traumatic Brain Injury. D. Laskowitz and G. Grant. Boca Raton (FL).
- Kubo, K., K. Nishikawa, et al. (2009). "Altered responses to propofol, but not ketamine, in mice deficient in the 65-kilodalton isoform of glutamate decarboxylase." J Pharmacol Exp Ther **329**(2): 592-599.
- Kuhn, J. E., C. N. Steimle, et al. (1986). "Ibuprofen improves survival and neurologic outcome after resuscitation from cardiac arrest." Resuscitation **14**(4): 199-212.
- Kumar, A. and D. J. Loane (2012). "Neuroinflammation after traumatic brain injury: opportunities for therapeutic intervention." Brain Behav Immun **26**(8): 1191-1201.
- Kunz, T., N. Marklund, et al. (2006). "Effects of the selective cyclooxygenase-2 inhibitor rofecoxib on cell death following traumatic brain injury in the rat." Restor Neurol Neurosci **24**(1): 55-63.
- Kupina, N. C., M. R. Detloff, et al. (2003). "Cytoskeletal protein degradation and neurodegeneration evolves differently in males and females following experimental head injury." Exp Neurol **180**(1): 55-73.
- Kurca, E., S. Sivak, et al. (2006). "Impaired cognitive functions in mild traumatic brain injury patients with normal and pathologic magnetic resonance imaging." Neuroradiology **48**(9): 661-669.
- Landauer, M. R. and R. L. Balster (1982). "A new test for social investigation in mice: effects of d-amphetamine." Psychopharmacology (Berl) **78**(4): 322-325.
- Langlois, J. A., W. Rutland-Brown, et al. (2006). "The epidemiology and impact of traumatic brain injury: a brief overview." J Head Trauma Rehabil **21**(5): 375-378.
- Laurer, H. L., F. M. Bareyre, et al. (2001). "Mild head injury increasing the brain's vulnerability to a second concussive impact." J Neurosurg **95**(5): 859-870.
- Lehmann, J. M., J. M. Lenhard, et al. (1997). "Peroxisome proliferator-activated receptors alpha and gamma are activated by indomethacin and other non-steroidal anti-inflammatory drugs." J Biol Chem **272**(6): 3406-3410.
- Leung, L. Y., P. J. VandeVord, et al. (2008). "Blast related neurotrauma: a review of cellular injury." Mol Cell Biomech **5**(3): 155-168.
- Leverenz, J. B., C. E. Yu, et al. (2007). "A novel progranulin mutation associated with variable clinical presentation and tau, TDP43 and alpha-synuclein pathology." Brain **130**(Pt 5): 1360-1374.

- Lighthall, J. W. (1988). "Controlled cortical impact: a new experimental brain injury model." *J Neurotrauma* **5**(1): 1-15.
- Lim, G. P., F. Yang, et al. (2000). "Ibuprofen suppresses plaque pathology and inflammation in a mouse model for Alzheimer's disease." *J Neurosci* **20**(15): 5709-5714.
- Liu, C. J. and X. Bosch (2012). "Progranulin: a growth factor, a novel TNFR ligand and a drug target." *Pharmacol Ther* **133**(1): 124-132.
- Liu, J., M. C. Liu, et al. (2008). "Calpain in the CNS: from synaptic function to neurotoxicity." *Sci Signal* **1**(14): re1.
- Lobsiger, C. S., S. Boillee, et al. (2007). "Toxicity from different SOD1 mutants dysregulates the complement system and the neuronal regenerative response in ALS motor neurons." *Proc Natl Acad Sci U S A* **104**(18): 7319-7326.
- Longhi, L., K. E. Saatman, et al. (2005). "Temporal window of vulnerability to repetitive experimental concussive brain injury." *Neurosurgery* **56**(2): 364-374; discussion 364-374.
- Lu, R. and G. Serrero (2001). "Mediation of estrogen mitogenic effect in human breast cancer MCF-7 cells by PC-cell-derived growth factor (PCDGF/granulin precursor)." *Proc Natl Acad Sci U S A* **98**(1): 142-147.
- Lucin, K. M. and T. Wyss-Coray (2009). "Immune activation in brain aging and neurodegeneration: too much or too little?" *Neuron* **64**(1): 110-122.
- Luo, J., A. Nguyen, et al. (2014). "Long-term cognitive impairments and pathological alterations in a mouse model of repetitive mild traumatic brain injury." *Front Neurol* **5**: 12.
- Macauley, S. L., M. Pekny, et al. (2011). "The role of attenuated astrocyte activation in infantile neuronal ceroid lipofuscinosis." *J Neurosci* **31**(43): 15575-15585.
- Madathil, S. K., S. W. Carlson, et al. (2013). "Astrocyte-Specific Overexpression of Insulin-Like Growth Factor-1 Protects Hippocampal Neurons and Reduces Behavioral Deficits following Traumatic Brain Injury in Mice." *PLoS One* **8**(6): e67204.
- Makdissi, M., D. Darby, et al. (2010). "Natural history of concussion in sport: markers of severity and implications for management." *Am J Sports Med* **38**(3): 464-471.
- Malaspina, A., N. Kaushik, et al. (2001). "Differential expression of 14 genes in amyotrophic lateral sclerosis spinal cord detected using gridded cDNA arrays." *J Neurochem* **77**(1): 132-145.
- Mannix, R., W. P. Meehan, et al. (2013). "Clinical correlates in an experimental model of repetitive mild brain injury." *Ann Neurol* **74**(1): 65-75.
- Mantovani, A., M. Locati, et al. (2004). "Extracellular and intracellular decoys in the tuning of inflammatory cytokines and Toll-like receptors: the new entry TIR8/SIGIRR." *J Leukoc Biol* **75**(5): 738-742.
- Marar, M., N. M. McIlvain, et al. (2012). "Epidemiology of concussions among United States high school athletes in 20 sports." *Am J Sports Med* **40**(4): 747-755.
- Marmarou, A., M. A. Foda, et al. (1994). "A new model of diffuse brain injury in rats. Part I: Pathophysiology and biomechanics." *J Neurosurg* **80**(2): 291-300.
- Martens, L. H., J. Zhang, et al. (2012). "Progranulin deficiency promotes neuroinflammation and neuron loss following toxin-induced injury." *J Clin Invest* **122**(11): 3955-3959.

- Martland, H. S. (1928). "Punch drunk." Journal of the American Medical Association **91**: 1103-1107.
- McAllister, T. W., M. B. Sparling, et al. (2001). "Differential working memory load effects after mild traumatic brain injury." Neuroimage **14**(5): 1004-1012.
- McCrea, M., W. B. Barr, et al. (2005). "Standard regression-based methods for measuring recovery after sport-related concussion." J Int Neuropsychol Soc **11**(1): 58-69.
- McCrea, M., T. Hammeke, et al. (2004). "Unreported concussion in high school football players: implications for prevention." Clin J Sport Med **14**(1): 13-17.
- McCrory, P., K. Johnston, et al. (2005). "Summary and agreement statement of the 2nd International Conference on Concussion in Sport, Prague 2004." Br J Sports Med **39**(4): 196-204.
- McCrory, P., M. Makdissi, et al. (2005). "Value of neuropsychological testing after head injuries in football." Br J Sports Med **39** **Suppl 1**: i58-63.
- McCrory, P., W. H. Meeuwisse, et al. (2013). "Consensus statement on concussion in sport: the 4th International Conference on Concussion in Sport held in Zurich, November 2012." Br J Sports Med **47**(5): 250-258.
- McCrory, P. R. and S. F. Berkovic (1998). "Second impact syndrome." Neurology **50**(3): 677-683.
- McGeer, P. L. and E. G. McGeer (1998). "Glial cell reactions in neurodegenerative diseases: pathophysiology and therapeutic interventions." Alzheimer Dis Assoc Disord **12** **Suppl 2**: S1-6.
- McGeer, P. L. and E. G. McGeer (1998). "Mechanisms of cell death in Alzheimer disease--immunopathology." J Neural Transm Suppl **54**: 159-166.
- McIntosh, T. K., L. Noble, et al. (1987). "Traumatic brain injury in the rat: characterization of a midline fluid-percussion model." Cent Nerv Syst Trauma **4**(2): 119-134.
- McKee, A. C., R. C. Cantu, et al. (2009). "Chronic traumatic encephalopathy in athletes: progressive tauopathy after repetitive head injury." J Neuropathol Exp Neurol **68**(7): 709-735.
- McKee, A. C., D. H. Daneshvar, et al. (2014). "The neuropathology of sport." Acta Neuropathol **127**(1): 29-51.
- McKee, A. C., B. E. Gavett, et al. (2010). "TDP-43 proteinopathy and motor neuron disease in chronic traumatic encephalopathy." J Neuropathol Exp Neurol **69**(9): 918-929.
- McKee, A. C. and M. E. Robinson (2014). "Military-related traumatic brain injury and neurodegeneration." Alzheimers Dement **10**(3 **Suppl**): S242-253.
- McKee, A. C., T. D. Stein, et al. (2015). "The neuropathology of chronic traumatic encephalopathy." Brain Pathol **25**(3): 350-364.
- McMahon, P., A. Hricik, et al. (2014). "Symptomatology and functional outcome in mild traumatic brain injury: results from the prospective TRACK-TBI study." J Neurotrauma **31**(1): 26-33.
- McNett, M., S. Amato, et al. (2014). "The FOUR score and GCS as predictors of outcome after traumatic brain injury." Neurocrit Care **21**(1): 52-57.

- Meehan, W. P., 3rd, P. d'Hemecourt, et al. (2010). "High school concussions in the 2008-2009 academic year: mechanism, symptoms, and management." Am J Sports Med **38**(12): 2405-2409.
- Meehan, W. P., 3rd, J. Zhang, et al. (2012). "Increasing recovery time between injuries improves cognitive outcome after repetitive mild concussive brain injuries in mice." Neurosurgery **71**(4): 885-891.
- Menon, D. K., K. Schwab, et al. (2010). "Position statement: definition of traumatic brain injury." Arch Phys Med Rehabil **91**(11): 1637-1640.
- Mercado, P. A., Y. M. Ayala, et al. (2005). "Depletion of TDP 43 overrides the need for exonic and intronic splicing enhancers in the human apoA-II gene." Nucleic Acids Res **33**(18): 6000-6010.
- Moisse, K., K. Volkening, et al. (2009). "Divergent patterns of cytosolic TDP-43 and neuronal progranulin expression following axotomy: implications for TDP-43 in the physiological response to neuronal injury." Brain Res **1249**: 202-211.
- Moncada, S. and J. R. Vane (1979). "Arachidonic acid metabolites and the interactions between platelets and blood-vessel walls." N Engl J Med **300**(20): 1142-1147.
- Montenigro, P. H., C. M. Baugh, et al. (2014). "Clinical subtypes of chronic traumatic encephalopathy: literature review and proposed research diagnostic criteria for traumatic encephalopathy syndrome." Alzheimers Res Ther **6**(5): 68.
- Morris, J. C. (1994). "Differential diagnosis of Alzheimer's disease." Clin Geriatr Med **10**(2): 257-276.
- Mouzon, B., H. Chaytow, et al. (2012). "Repetitive mild traumatic brain injury in a mouse model produces learning and memory deficits accompanied by histological changes." J Neurotrauma **29**(18): 2761-2773.
- Mouzon, B. C., C. Bachmeier, et al. (2014). "Chronic neuropathological and neurobehavioral changes in a repetitive mild traumatic brain injury model." Ann Neurol **75**(2): 241-254.
- Murray, C. and A. Lopez (1996). "Global Health Statistics." Global Burden of Disease and Injury Series II.
- Mychasiuk, R., H. Hehar, et al. (2016). "The direction of the acceleration and rotational forces associated with mild traumatic brain injury in rodents effect behavioural and molecular outcomes." J Neurosci Methods **257**: 168-178.
- Mychasiuk, R., H. Hehar, et al. (2015). "A mild traumatic brain injury (mTBI) induces secondary attention-deficit hyperactivity disorder-like symptomology in young rats." Behav Brain Res **286**: 285-292.
- Neumann, M., D. M. Sampathu, et al. (2006). "Ubiquitinated TDP-43 in frontotemporal lobar degeneration and amyotrophic lateral sclerosis." Science **314**(5796): 130-133.
- Ng, S. Y., B. D. Semple, et al. (2012). "Attenuation of microglial activation with minocycline is not associated with changes in neurogenesis after focal traumatic brain injury in adult mice." J Neurotrauma **29**(7): 1410-1425.
- Nichols, J. N., A. S. Deshane, et al. (2016). "Greater neurobehavioral deficits occur in adult mice after repeated, as compared to single, mild traumatic brain injury (mTBI)." Behav Brain Res **298**(Pt B): 111-124.
- Nonaka, M., X. H. Chen, et al. (1999). "Prolonged activation of NF-kappaB following traumatic brain injury in rats." J Neurotrauma **16**(11): 1023-1034.

- Ogawa, O., H. Umegaki, et al. (2000). "Inhibition of inducible nitric oxide synthase gene expression by indomethacin or ibuprofen in beta-amyloid protein-stimulated J774 cells." Eur J Pharmacol **408**(2): 137-141.
- Ojo, J. O., B. Mouzon, et al. (2013). "Repetitive mild traumatic brain injury augments tau pathology and glial activation in aged hTau mice." J Neuropathol Exp Neurol **72**(2): 137-151.
- Ojo, J. O., B. C. Mouzon, et al. (2016). "Repetitive head trauma, chronic traumatic encephalopathy and tau: Challenges in translating from mice to men." Exp Neurol **275 Pt 3**: 389-404.
- Okada, S., M. Nakamura, et al. (2006). "Conditional ablation of Stat3 or Socs3 discloses a dual role for reactive astrocytes after spinal cord injury." Nat Med **12**(7): 829-834.
- Omalu, B. I., S. T. DeKosky, et al. (2006). "Chronic traumatic encephalopathy in a national football league player: part II." Neurosurgery **59**(5): 1086-1092; discussion 1092-1083.
- Omalu, B. I., S. T. DeKosky, et al. (2005). "Chronic traumatic encephalopathy in a National Football League player." Neurosurgery **57**(1): 128-134; discussion 128-134.
- Palmer, A. M., D. W. Marion, et al. (1994). "Increased transmitter amino acid concentration in human ventricular CSF after brain trauma." Neuroreport **6**(1): 153-156.
- Papadopoulos, V. and L. Lecanu (2009). "Translocator protein (18 kDa) TSPO: an emerging therapeutic target in neurotrauma." Exp Neurol **219**(1): 53-57.
- Park, B., L. Buti, et al. (2011). "Granulin is a soluble cofactor for toll-like receptor 9 signaling." Immunity **34**(4): 505-513.
- Parnell, P. G., J. Wunderlich, et al. (1992). "Transforming growth factor e: amino acid analysis and partial amino acid sequence." Growth Factors **7**(1): 65-72.
- Patel, P. M., J. C. Drummond, et al. (1993). "Effect of ibuprofen on regional eicosanoid production and neuronal injury after forebrain ischemia in rats." Brain Res **614**(1-2): 315-324.
- Pekny, M., C. Eliasson, et al. (1999). "The impact of genetic removal of GFAP and/or vimentin on glutamine levels and transport of glucose and ascorbate in astrocytes." Neurochem Res **24**(11): 1357-1362.
- Pereson, S., H. Wils, et al. (2009). "Progranulin expression correlates with dense-core amyloid plaque burden in Alzheimer disease mouse models." J Pathol **219**(2): 173-181.
- Petkau, T. L., S. J. Neal, et al. (2012). "Synaptic dysfunction in progranulin-deficient mice." Neurobiol Dis **45**(2): 711-722.
- Petraglia, A. L., B. A. Plog, et al. (2014). "The spectrum of neurobehavioral sequelae after repetitive mild traumatic brain injury: a novel mouse model of chronic traumatic encephalopathy." J Neurotrauma **31**(13): 1211-1224.
- Pettus, E. H., C. W. Christman, et al. (1994). "Traumatically induced altered membrane permeability: its relationship to traumatically induced reactive axonal change." J Neurotrauma **11**(5): 507-522.

- Piccin, D. and C. M. Morshead (2011). "Wnt signaling regulates symmetry of division of neural stem cells in the adult brain and in response to injury." Stem Cells **29**(3): 528-538.
- Plassman, B. L., R. J. Havlik, et al. (2000). "Documented head injury in early adulthood and risk of Alzheimer's disease and other dementias." Neurology **55**(8): 1158-1166.
- Plowman, G. D., J. M. Green, et al. (1992). "The epithelin precursor encodes two proteins with opposing activities on epithelial cell growth." J Biol Chem **267**(18): 13073-13078.
- Povlishock, J. T. and C. W. Christman (1995). "The pathobiology of traumatically induced axonal injury in animals and humans: a review of current thoughts." J Neurotrauma **12**(4): 555-564.
- Povlishock, J. T. and D. I. Katz (2005). "Update of neuropathology and neurological recovery after traumatic brain injury." J Head Trauma Rehabil **20**(1): 76-94.
- Price, L., C. Wilson, et al. (2016). Blood-Brain Barrier Pathophysiology following Traumatic Brain Injury. Translational Research in Traumatic Brain Injury. D. Laskowitz and G. Grant. Boca Raton (FL).
- Prins, M. L., D. Alexander, et al. (2013). "Repeated mild traumatic brain injury: mechanisms of cerebral vulnerability." J Neurotrauma **30**(1): 30-38.
- Prins, M. L., A. Hales, et al. (2010). "Repeat traumatic brain injury in the juvenile rat is associated with increased axonal injury and cognitive impairments." Dev Neurosci **32**(5-6): 510-518.
- Raghupathi, R. and J. W. Huh (2007). "Diffuse brain injury in the immature rat: evidence for an age-at-injury effect on cognitive function and histopathologic damage." J Neurotrauma **24**(10): 1596-1608.
- Ramlackhansingh, A. F., D. J. Brooks, et al. (2011). "Inflammation after trauma: microglial activation and traumatic brain injury." Ann Neurol **70**(3): 374-383.
- Ramprasad, M. P., V. Terpstra, et al. (1996). "Cell surface expression of mouse macrophage mannose receptor and human CD68 and their role as macrophage receptors for oxidized low density lipoprotein." Proc Natl Acad Sci U S A **93**(25): 14833-14838.
- Ransohoff, R. M. and A. E. Cardona (2010). "The myeloid cells of the central nervous system parenchyma." Nature **468**(7321): 253-262.
- Rao, V. L., M. K. Baskaya, et al. (1998). "Traumatic brain injury down-regulates glial glutamate transporter (GLT-1 and GLAST) proteins in rat brain." J Neurochem **70**(5): 2020-2027.
- Redell, J. B., A. N. Moore, et al. (2013). "Analysis of functional pathways altered after mild traumatic brain injury." J Neurotrauma **30**(9): 752-764.
- Reiner, A., S. A. Heldt, et al. (2015). "Motor, visual and emotional deficits in mice after closed-head mild traumatic brain injury are alleviated by the novel CB2 inverse agonist SMM-189." Int J Mol Sci **16**(1): 758-787.
- Reines, S. A., G. A. Block, et al. (2004). "Rofecoxib: no effect on Alzheimer's disease in a 1-year, randomized, blinded, controlled study." Neurology **62**(1): 66-71.
- Richardson, R. L., E. M. Kim, et al. (2005). "Chronic intracerebroventricular infusion of lipopolysaccharide: effects of ibuprofen treatment and behavioural and histopathological correlates." Behav Pharmacol **16**(7): 531-541.

- Riggs, J. E. (1993). "Antecedent trauma and amyotrophic lateral sclerosis in young adult men." Mil Med **158**(1): 55-57.
- Rimel, R. W., B. Giordani, et al. (1981). "Disability caused by minor head injury." Neurosurgery **9**(3): 221-228.
- Risau, W. and H. Wolburg (1990). "Development of the blood-brain barrier." Trends Neurosci **13**(5): 174-178.
- Roberts, G. W., S. M. Gentleman, et al. (1991). "beta A4 amyloid protein deposition in brain after head trauma." Lancet **338**(8780): 1422-1423.
- Roberts, G. W., S. M. Gentleman, et al. (1994). "Beta amyloid protein deposition in the brain after severe head injury: implications for the pathogenesis of Alzheimer's disease." J Neurol Neurosurg Psychiatry **57**(4): 419-425.
- Roberts, G. W., H. L. Whitwell, et al. (1990). "Dementia in a punch-drunk wife." Lancet **335**(8694): 918-919.
- Romer, D. (1980). "Pharmacological evaluation of mild analgesics." Br J Clin Pharmacol **10 Suppl 2**: 247S-251S.
- Rowe, R. K., J. L. Harrison, et al. (2014). "Recovery of neurological function despite immediate sleep disruption following diffuse brain injury in the mouse: clinical relevance to medically untreated concussion." Sleep **37**(4): 743-752.
- Ryan, C. L., D. C. Baranowski, et al. (2009). "Progranulin is expressed within motor neurons and promotes neuronal cell survival." BMC Neurosci **10**: 130.
- Saatman, K. E., B. Abai, et al. (2003). "Traumatic axonal injury results in biphasic calpain activation and retrograde transport impairment in mice." J Cereb Blood Flow Metab **23**(1): 34-42.
- Saatman, K. E., K. J. Feeko, et al. (2006). "Differential behavioral and histopathological responses to graded cortical impact injury in mice." J Neurotrauma **23**(8): 1241-1253.
- Saing, T., M. Dick, et al. (2012). "Frontal cortex neuropathology in dementia pugilistica." J Neurotrauma **29**(6): 1054-1070.
- Sales, K. J. and H. N. Jabbour (2003). "Cyclooxygenase enzymes and prostaglandins in pathology of the endometrium." Reproduction **126**(5): 559-567.
- Scharf, S., A. Mander, et al. (1999). "A double-blind, placebo-controlled trial of diclofenac/misoprostol in Alzheimer's disease." Neurology **53**(1): 197-201.
- Schenk, F. and R. G. Morris (1985). "Dissociation between components of spatial memory in rats after recovery from the effects of retrohippocampal lesions." Exp Brain Res **58**(1): 11-28.
- Schoch, K. M., H. N. Evans, et al. (2012). "Calpastatin overexpression limits calpain-mediated proteolysis and behavioral deficits following traumatic brain injury." Exp Neurol **236**(2): 371-382.
- Schwaninger, M., S. Sallmann, et al. (1999). "Bradykinin induces interleukin-6 expression in astrocytes through activation of nuclear factor-kappaB." J Neurochem **73**(4): 1461-1466.
- Schwarzmaier, S. M., S. W. Kim, et al. (2010). "Temporal profile of thrombogenesis in the cerebral microcirculation after traumatic brain injury in mice." J Neurotrauma **27**(1): 121-130.

- Selwyn, R. G., S. J. Cooney, et al. (2015). "Outcome after Repetitive Mild Traumatic Brain Injury is Temporally Related to Glucose Uptake Profile at Time of Second Injury." J Neurotrauma.
- Semple, B. D., S. Lee, et al. (2015). "Repetitive concussions in adolescent athletes - translating clinical and experimental research into perspectives on rehabilitation strategies." Front Neurol **6**: 69.
- Serbest, G., M. F. Burkhardt, et al. (2007). "Temporal profiles of cytoskeletal protein loss following traumatic axonal injury in mice." Neurochem Res **32**(12): 2006-2014.
- Shang, J. L., Q. Cheng, et al. (2014). "Possible roles of COX-1 in learning and memory impairment induced by traumatic brain injury in mice." Braz J Med Biol Res **0**: 0.
- Shapira, Y., E. Shohami, et al. (1988). "Experimental closed head injury in rats: mechanical, pathophysiologic, and neurologic properties." Crit Care Med **16**(3): 258-265.
- Shitaka, Y., H. T. Tran, et al. (2011). "Repetitive closed-skull traumatic brain injury in mice causes persistent multifocal axonal injury and microglial reactivity." J Neuropathol Exp Neurol **70**(7): 551-567.
- Shultz, S. R., F. Bao, et al. (2012). "Repeated mild lateral fluid percussion brain injury in the rat causes cumulative long-term behavioral impairments, neuroinflammation, and cortical loss in an animal model of repeated concussion." J Neurotrauma **29**(2): 281-294.
- Shultz, S. R., D. F. MacFabe, et al. (2012). "Sub-concussive brain injury in the Long-Evans rat induces acute neuroinflammation in the absence of behavioral impairments." Behav Brain Res **229**(1): 145-152.
- Smith, C., S. M. Gentleman, et al. (2013). "The neuroinflammatory response in humans after traumatic brain injury." Neuropathol Appl Neurobiol **39**(6): 654-666.
- Smith, D. H., M. Nonaka, et al. (2000). "Immediate coma following inertial brain injury dependent on axonal damage in the brainstem." J Neurosurg **93**(2): 315-322.
- Smith, K. R., J. Damiano, et al. (2012). "Strikingly different clinicopathological phenotypes determined by progranulin-mutation dosage." Am J Hum Genet **90**(6): 1102-1107.
- Soares, H. D., R. R. Hicks, et al. (1995). "Inflammatory leukocytic recruitment and diffuse neuronal degeneration are separate pathological processes resulting from traumatic brain injury." J Neurosci **15**(12): 8223-8233.
- Spires, T. L., J. D. Orne, et al. (2006). "Region-specific dissociation of neuronal loss and neurofibrillary pathology in a mouse model of tauopathy." Am J Pathol **168**(5): 1598-1607.
- Springer, J. E., R. R. Rao, et al. (2010). "The functional and neuroprotective actions of Neu2000, a dual-acting pharmacological agent, in the treatment of acute spinal cord injury." J Neurotrauma **27**(1): 139-149.
- Stemper, B. D., A. S. Shah, et al. (2015). "Head rotational acceleration characteristics influence behavioral and diffusion tensor imaging outcomes following concussion." Ann Biomed Eng **43**(5): 1071-1088.
- Stern, R. A., D. H. Daneshvar, et al. (2013). "Clinical presentation of chronic traumatic encephalopathy." Neurology **81**(13): 1122-1129.
- Stewart, W. F., C. Kawas, et al. (1997). "Risk of Alzheimer's disease and duration of NSAID use." Neurology **48**(3): 626-632.

- Stiell, I. G., G. A. Wells, et al. (2001). "The Canadian CT Head Rule for patients with minor head injury." Lancet **357**(9266): 1391-1396.
- Strong, M. J., K. Volkening, et al. (2007). "TDP43 is a human low molecular weight neurofilament (hNFL) mRNA-binding protein." Mol Cell Neurosci **35**(2): 320-327.
- Sullivan, P. G., M. B. Thompson, et al. (1999). "Cyclosporin A attenuates acute mitochondrial dysfunction following traumatic brain injury." Exp Neurol **160**(1): 226-234.
- Suzuki, M., M. Bannai, et al. (2000). "Suppression of copulatory behavior by intracerebroventricular infusion of antisense oligodeoxynucleotide of granulin in neonatal male rats." Physiol Behav **68**(5): 707-713.
- Suzuki, M., S. Yoshida, et al. (1998). "Identification of a sex steroid-inducible gene in the neonatal rat hypothalamus." Neurosci Lett **242**(3): 127-130.
- Syed, A. T., N. A. Lone, et al. (2007). "Clinical management of patients with minor head injuries." Int J Health Sci (Qassim) **1**(1): 131-140.
- Tanaka, Y., T. Matsuwaki, et al. (2013a). "Exacerbated inflammatory responses related to activated microglia after traumatic brain injury in progranulin-deficient mice." Neuroscience **231**: 49-60.
- Tanaka, Y., T. Matsuwaki, et al. (2013b). "Increased lysosomal biogenesis in activated microglia and exacerbated neuronal damage after traumatic brain injury in progranulin-deficient mice." Neuroscience **250**: 8-19.
- Tang, W., Y. Lu, et al. (2011). "The growth factor progranulin binds to TNF receptors and is therapeutic against inflammatory arthritis in mice." Science **332**(6028): 478-484.
- Teasdale, G. and B. Jennett (1974). "Assessment of coma and impaired consciousness. A practical scale." Lancet **2**(7872): 81-84.
- Teasdale, G., R. Knill-Jones, et al. (1978). "Observer variability in assessing impaired consciousness and coma." J Neurol Neurosurg Psychiatry **41**(7): 603-610.
- Tellier, A., L. C. Della Malva, et al. (1999). "Mild head injury: a misnomer." Brain Inj **13**(7): 463-475.
- Thau-Zuchman, O., E. Shohami, et al. (2012). "The anti-inflammatory drug carprofen improves long-term outcome and induces gliogenesis after traumatic brain injury." J Neurotrauma **29**(2): 375-384.
- Thibault, L. E., D. F. Meaney, et al. (1992). "Biomechanical aspects of a fluid percussion model of brain injury." J Neurotrauma **9**(4): 311-322.
- Thurman, D. J., C. M. Branche, et al. (1998). "The epidemiology of sports-related traumatic brain injuries in the United States: recent developments." J Head Trauma Rehabil **13**(2): 1-8.
- Tokuda, T., S. Ikeda, et al. (1991). "Re-examination of ex-boxers' brains using immunohistochemistry with antibodies to amyloid beta-protein and tau protein." Acta Neuropathol **82**(4): 280-285.
- Tolkatchev, D., S. Malik, et al. (2008). "Structure dissection of human progranulin identifies well-folded granulin/epithelin modules with unique functional activities." Protein Sci **17**(4): 711-724.

- Tomei, G., D. Spagnoli, et al. (1990). "Morphology and neurophysiology of focal axonal injury experimentally induced in the guinea pig optic nerve." Acta Neuropathol **80**(5): 506-513.
- Trapp, B. D., P. Hauer, et al. (1988). "Axonal regulation of myelin protein mRNA levels in actively myelinating Schwann cells." J Neurosci **8**(9): 3515-3521.
- Tzekov, R., A. Quezada, et al. (2014). "Repetitive mild traumatic brain injury causes optic nerve and retinal damage in a mouse model." J Neuropathol Exp Neurol **73**(4): 345-361.
- Uryu, K., H. Laurer, et al. (2002). "Repetitive mild brain trauma accelerates A β deposition, lipid peroxidation, and cognitive impairment in a transgenic mouse model of Alzheimer amyloidosis." J Neurosci **22**(2): 446-454.
- Van Damme, P., A. Van Hoecke, et al. (2008). "Progranulin functions as a neurotrophic factor to regulate neurite outgrowth and enhance neuronal survival." J Cell Biol **181**(1): 37-41.
- Varvel, N. H., K. Bhaskar, et al. (2009). "NSAIDs prevent, but do not reverse, neuronal cell cycle reentry in a mouse model of Alzheimer disease." J Clin Invest **119**(12): 3692-3702.
- Veasey, S. C. (2012). "Piecing together phenotypes of brain injury and dysfunction in obstructive sleep apnea." Front Neurol **3**: 139.
- Ventura, R. E., L. J. Balcer, et al. (2014). "The neuro-ophthalmology of head trauma." Lancet Neurol **13**(10): 1006-1016.
- Vercesi, A., B. Reynafarje, et al. (1978). "Stoichiometry of H⁺ ejection and Ca²⁺ uptake coupled to electron transport in rat heart mitochondria." J Biol Chem **253**(18): 6379-6385.
- Villapol, S., K. R. Byrnes, et al. (2014). "Temporal dynamics of cerebral blood flow, cortical damage, apoptosis, astrocyte-vasculature interaction and astrogliosis in the pericontusional region after traumatic brain injury." Front Neurol **5**: 82.
- Viswanathan, S., L. J. Frishman, et al. (1999). "The photopic negative response of the macaque electroretinogram: reduction by experimental glaucoma." Invest Ophthalmol Vis Sci **40**(6): 1124-1136.
- Wang, B. C., H. Liu, et al. (2015). "New discovery rarely runs smooth: an update on progranulin/TNFR interactions." Protein Cell **6**(11): 792-803.
- Wang, G., J. Zhang, et al. (2013). "Microglia/macrophage polarization dynamics in white matter after traumatic brain injury." J Cereb Blood Flow Metab **33**(12): 1864-1874.
- Wang, J., M. A. Fox, et al. (2013). "Diffuse traumatic axonal injury in the optic nerve does not elicit retinal ganglion cell loss." J Neuropathol Exp Neurol **72**(8): 768-781.
- Wang, W. X., B. R. Wilfred, et al. (2010). "miR-107 regulates granulin/progranulin with implications for traumatic brain injury and neurodegenerative disease." Am J Pathol **177**(1): 334-345.
- Weil, Z. M., K. R. Gaier, et al. (2014). "Injury timing alters metabolic, inflammatory and functional outcomes following repeated mild traumatic brain injury." Neurobiol Dis **70**: 108-116.
- Werner, C. and K. Engelhard (2007). "Pathophysiology of traumatic brain injury." Br J Anaesth **99**(1): 4-9.

- Wilkinson, A. E., L. R. Bridges, et al. (1999). "Correlation of survival time with size of axonal swellings in diffuse axonal injury." Acta Neuropathol **98**(2): 197-202.
- Wils, H., G. Kleinberger, et al. (2012). "Cellular ageing, increased mortality and FTLTDP-associated neuropathology in progranulin knockout mice." J Pathol **228**(1): 67-76.
- Xu, L., J. V. Nguyen, et al. (2014). "Repetitive mild traumatic brain injury with impact acceleration in the mouse: Multifocal axonopathy, neuroinflammation, and neurodegeneration in the visual system." Exp Neurol.
- Yan, Q., J. Zhang, et al. (2003). "Anti-inflammatory drug therapy alters beta-amyloid processing and deposition in an animal model of Alzheimer's disease." J Neurosci **23**(20): 7504-7509.
- Yin, F., R. Banerjee, et al. (2010). "Exaggerated inflammation, impaired host defense, and neuropathology in progranulin-deficient mice." J Exp Med **207**(1): 117-128.
- Yin, F., M. Dumont, et al. (2010). "Behavioral deficits and progressive neuropathology in progranulin-deficient mice: a mouse model of frontotemporal dementia." FASEB J **24**(12): 4639-4647.
- Yuh, E. L., P. Mukherjee, et al. (2013). "Magnetic resonance imaging improves 3-month outcome prediction in mild traumatic brain injury." Ann Neurol **73**(2): 224-235.
- Zhang, J., V. Puvanna, et al. (2016). Biomarkers of Traumatic Brain Injury and Their Relationship to Pathology. Translational Research in Traumatic Brain Injury. D. Laskowitz and G. Grant. Boca Raton (FL).
- Zhang, J., Z. Teng, et al. (2015). "Inhibition of monoacylglycerol lipase prevents chronic traumatic encephalopathy-like neuropathology in a mouse model of repetitive mild closed head injury." J Cereb Blood Flow Metab **35**(3): 443-453.
- Zhou, J., G. Gao, et al. (1993). "Purification of an autocrine growth factor homologous with mouse epithelin precursor from a highly tumorigenic cell line." J Biol Chem **268**(15): 10863-10869.
- Zhu, Z., D. Stevenson, et al. (2002). "Expression of IL-10 and TNF-inhibitor genes in lacrimal gland epithelial cells suppresses their ability to activate lymphocytes." Cornea **21**(2): 210-214.
- Ziebell, J. M. and M. C. Morganti-Kossmann (2010). "Involvement of pro- and anti-inflammatory cytokines and chemokines in the pathophysiology of traumatic brain injury." Neurotherapeutics **7**(1): 22-30.
- Zohar, O., V. Rubovitch, et al. (2011). "Behavioral consequences of minimal traumatic brain injury in mice." Acta Neurobiol Exp (Wars) **71**(1): 36-45.

VITA

Amanda N. Bolton Hall

Citizenship: USA

Previous Educational Experience

2006-2010 **Georgetown College: Georgetown, Kentucky**
B.S. in Biology
Minor in Chemistry
3.59/4.0 GPA; Cum Laude

Professional Experience

2011-2016 **Predoctoral Graduate Research Assistant**—Lexington, KY
Ph.D. Mentorship and training under Kathryn E. Saatman, Ph.D.

2014 **Instructor for Anatomy and Physiology course**, Bluegrass Community
and Technical College, Lexington, KY

July 2013 **Instructor for Health Researchers Youth Academy**—Lexington, KY

2009-2010 **Biology Department Tutor**—Georgetown, KY

2008-2009 **Biology Laboratory Assistant**—Georgetown, KY

Selected Awards

2014, 2015 **Winner of the graduate student poster competition at the
Bluegrass Society for Neuroscience Spring Neuroscience Day**

2013 **Finalist in the 31st Annual National Neurotrauma Symposium
student poster competition**

Initiated 2007 **Alpha Lambda Delta, Honor Society**

2007-2008 **Vice-President of Alpha Lambda Delta**

Initiated 2008 **Omicron Delta Kappa, Leadership Society**

2006-2010 **Georgetown College Dean's List (5 semesters)**

2006-2010 **Trustee Scholarship**

Service

March 2015 **Madison Central High School**
2013-2014 **Representative for Physiology Graduate Students**
2013-2014 **Mentorship-Karla Ladino**
 MSTC Student from Dunbar High School
Nov. 2013 **Neuroscience Discovery Night**
2011-2013 **Graduate Student Advisory Committee**
2011-2014 **Committee for Center-wide Initiatives**
Feb. 2012: **ACE Arts and Science Day**
April 2011 **Science Explorers Program**

Professional Membership

2011 to present **Bluegrass Chapter of the Society for Neuroscience**
2013 to present **National Neurotrauma Society**

Manuscripts:

Bolton AN, Saatman KE. (2014). “Regional Neurodegeneration and Gliosis Are Amplified by Mild Traumatic Brain Injury Repeated at 24-Hour Intervals”. *Journal of Neuropathology and Experimental Neurology*. Volume 73, p 933-947

Bolton Hall AN, Joseph B, Brelsfoard JM, Saatman KE. “Repeated Closed Head Injury in Mice Results in Sustained Motor and Memory Deficits and Chronic Cellular Changes.” *In Revision*

Grants:

2014-2016 **NIH F31 NRSA**, “The role of microglia in acute pathology of repeated concussion and CTE development”

2012-2014 **NIH T32 trainee**, “Neurobiology of CNS Injury and Repair” (Drs. Ed Hall and Jim Geddes, co-PI)

Speaking Engagements:

- 2015 **Bolton AN** “Acute and Chronic Effects of Repeated Mild Traumatic Brain Injuries in a Mouse”.
Kentucky Spinal Cord and Head Injury Research Trust Symposium,
Louisville, KY
- 2013 **Bolton AN** “Effects of time interval variation between repeated mild traumatic brain injuries in mice”.
University of Kentucky, Department of Physiology, Lexington, KY

Abstracts and Presentations:

*Denotes presenter

- 2016 **Bolton Hall AN***, Brelsfoard JM, Joseph B, Saatman KE. “Chronic Exacerbation of Microgliosis after Repeated Mild Traumatic Brain Injury in Progranulin Deficient Mice”.
--34th Annual National Neurotrauma Society Symposium,
Lexington, KY
- 2016 Brelsfoard JM*, **Bolton Hall AN**, Joseph B, Saatman KE. “Repeated Mild Closed Head Injury in Mice Results in Motor Deficits for 2 months and Cognitive Impairment for up to 6 months”.
--34th Annual National Neurotrauma Society Symposium,
Lexington, KY
- 2016 Joseph B, **Bolton Hall AN**, Brelsfoard JM, Saatman KE. “Progranulin Deficiency Exacerbates Microgliosis but not Axonal Injury in the Visual Pathway after Mild TBI”
--34th Annual National Neurotrauma Society Symposium,
Lexington, KY
- 2015 **Bolton AN***, Brelsfoard JM, Saatman KE. “Chronic Effects of Repeated Mild Traumatic Brain Injuries in a Mouse”.
Poster Presented at:
--Bluegrass Society for Neuroscience Spring Neuroscience Day,
Lexington, KY
- 2014 Biswas A, Menon N, **Bolton AN**, Saatman KE, Geddes* JW. “Brain Injury Screening by Ocular Analysis (BISON)”. *Journal of Neurotrauma*. v. 31, p A-37; 2014
Presented at:
--32nd Annual National Neurotrauma Society Symposium, San Francisco, CA

- 2014 **Bolton AN***, Saatman KE. “Entorhinal Cortex and Hippocampal Damage are Amplified by Concussions Repeated at 24h Intervals”
 Poster Presentation at:
 --Bluegrass Society for Neuroscience Spring Neuroscience Day, Lexington, KY
 --Kentucky Spinal Cord and Head Injury Research Trust Symposium, Lexington, KY
 --ApoE, ApoE Receptors & Neurodegeneration Symposium, Lexington, KY
- 2013 **Bolton AN***, Tuttle BC, Brelsfoard JP, Saatman KE. “Effects of time interval variation between repeated mild traumatic brain injuries in mice”. *Journal of Neurotrauma*, v. 30, p A-2; 2013
 Finalist for Student Poster competition at:
 --31st Annual National Neurotrauma Society Symposium, Nashville, TN
- 2013 **Bolton AN***, Tuttle BC, Brelsfoard JP, Saatman KE. “Effects of time interval variation between repeated mild traumatic brain injuries in mice”.
 Poster Presentation at:
 --Bluegrass Society for Neuroscience Spring Neuroscience Day, Lexington, KY
 --Kentucky Spinal Cord and Head Injury Research Trust Symposium, Louisville, KY
- 2012 **Bolton AN***, Tuttle BC, Saatman KE. “Development of a Novel Mild Closed Head Injury Model in Mice”.
 Poster Presentation at:
 --Kentucky Spinal Cord and Head Injury Research Trust Symposium, Lexington, KY May
- 2012 **Bolton AN***, Tuttle BC, Saatman KE. “A Mild Closed Head Injury Model in Mice Produces Increased Gliosis with Repeated Injuries”. *Journal of Neurotrauma*, v. 29, p. A-70; 2012
 Poster presentation at:
 --30th Annual National Neurotrauma Society Symposium, 2012, Phoenix, AZ July