



Fall 2009

Transylvania's Skull with a Hole in It

Charles T. Ambrose

University of Kentucky, cambros@uky.edu

Right click to open a feedback form in a new tab to let us know how this document benefits you.

Follow this and additional works at: https://uknowledge.uky.edu/microbio_facpub

 Part of the [History of Science, Technology, and Medicine Commons](#), and the [Medical Humanities Commons](#)

Repository Citation

Ambrose, Charles T., "Transylvania's Skull with a Hole in It" (2009). *Microbiology, Immunology, and Molecular Genetics Faculty Publications*. 47.

https://uknowledge.uky.edu/microbio_facpub/47

This Article is brought to you for free and open access by the Microbiology, Immunology, and Molecular Genetics at UKnowledge. It has been accepted for inclusion in Microbiology, Immunology, and Molecular Genetics Faculty Publications by an authorized administrator of UKnowledge. For more information, please contact UKnowledge@lsv.uky.edu.

Transylvania's Skull with a Hole in It

Notes/Citation Information


Published in *Transylvania Treasures*, v. 2, no. 3, p. 2-3.

© 2009 Transylvania University

The copyright holder has granted the permission for posting the article here.

Transylvania's Skull with a Hole in it

On a table at the far end of Transylvania's Moosnick Medical and Science Museum is a skullcap (the upper dome-like part of the cranium) with a penny-size hole on the right parietal area—four inches or so above where the right ear once had been (see photo below). The hole resulted from an operation called trephination. We know that the skullcap belonged to a person who survived the procedure for some years afterward, because the operation, whether crudely or skillfully performed, initially created a jagged or rough edge to the opening. Now, the opening has a rounded edge, like the lip of a glass beverage bottle—an edge that could form as such only if several years had elapsed after the operation to allow bone remodeling there.



Trephination (or trepanation) may be the earliest successful surgical procedure apart from setting a broken bone, pulling a bad tooth, or lancing a boil or abscess. It dates back to the Neolithic Age in Europe. Indeed, a skull recently discovered in Alsace, France, that belonged to a 50-year-old male who died around 5000 B. C. showed two smooth trephine holes (2.25-3.5 inches in diameter). An Inca trephined skull from Peru shows seven well-healed holes, indicating the skill of the primitive medicine man or shaman, and the luck of the patient. The operation was practiced in Afghanistan, China, Japan, and Africa. But the most examples have been found in South America and Mexico, possibly because the arid climate there preserved skeletal remains. Nineteen trephined skulls have been found in

prehistoric North America: eight in the U.S. (one of Mound builders in Illinois) and 11 in Canada.¹ It's unlikely that the Moosnick Museum's specimen is from a native Indian, because it is not an entire skull, but is a cleanly cut skullcap, such as obtained at an autopsy or dissection.

The hundreds of such trephined skulls in anatomical museums throughout the world raise questions of why and how they were done. In modern times neurosurgeons perform this operation (a type of craniotomy) to relieve pressure on the brain caused by a subdural or epidural hemorrhage, an intracranial tumor, or a fractured skull where the broken bone or fragments press on the brain. Prehistoric and primitive people had no knowledge of the above pathologies but must have been motivated by other reasons to perform such a drastic procedure. One obvious reason may have been a severe, chronic headache, which they would likely have ascribed to evil spirits inside the skull. Accordingly, a small opening in the skull over the

area of the pain might allow escape of the spirit or demon. Other reasons for undertaking trephination may have included epilepsy, intractable vertigo, and insanity, but this presumes that the brain was then recognized as the locus of these problems. Such an association likely came from awareness that a blow on the head sometimes rendered the victim temporarily confused, dizzy, convulsive, or unconscious.² A skull fracture or intracranial hemorrhage could result from an everyday accident as well as a blow by a club or sling-stone during warfare.

Trephination involves first lifting up a skin flap over the relevant area of the skull to expose the fibrous membrane (periosteum) covering the bone. The main operation entails removing a small square or round piece of the skull. To do so, a medicine man or shaman cut several small holes over the chosen area (i.e., three or four in a rectangle or a series in a circle) and then pried up the piece of bone between the holes. This fragment of bone came to be called a *rondelle* (or *roundel*) and was often preserved as a sacred amulet, with several some-

times being strung on a cord for a necklace. The primitive cutting instrument used was likely a pointed broken shell or a piece of obsidian glass. Probably by trial and error it was learned not to cut into or pierce the underlying dura mater, which covers the brain.

Since medieval times surgeons have used a circle-cutting metal bit with a saw-tooth edge (a trephine) to cut into the bone and rim out the edges of the ronnelle. This cutting bit was rotated by hand or attached to a bow drill, a device similar to that used by Boy Scouts to start fires without matches. "Trephine" comes from the French *très fines*, referring to an improved form of the trephine with a center pin to fix it on the bone and steady its rotation. The term "trepanation" is derived from the Greek word *τροπιάνου*, meaning a borer.

Benjamin Dudley, who taught at Transylvania's Medical Department from 1814-50, performed many such operations. His surgical kit, which now resides in the Moosnick Museum, contains two trephines of different diameters. (See page 6.) He published five of his trephination cases in the first issue of the

Transylvania Journal of Medicine, 1828.³ All of these had suffered blows or injuries to the head, with most of them later experiencing convulsions or epilepsy.

In 1826, Transylvania medical student Azra Offutt wrote his Inaugural Thesis mainly on the subject of trephination.

The source of the Moosnick Museum's skullcap is a mystery. The hole in it matches the smaller of Dr. Dudley's two trephines, but post-mortems were relatively uncommon during the period of Dudley's tenure at Transylvania. Corpses for dissection in anatomical

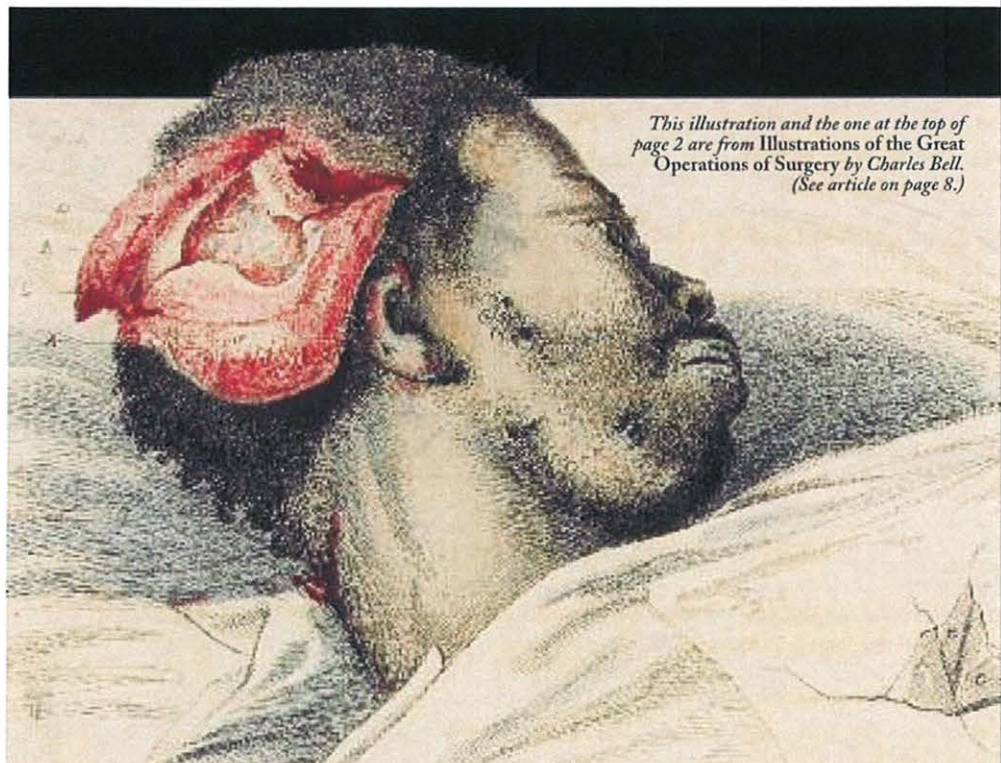classes at Transylvania also were few and hard to come by for medical students like Offutt. In his book, *Transylvania: Tutor to the West*, John D. Wright Jr. wrote that students were obliged "to secure their own 'subjects' by illegal means, or to turn to the commercial 'resurrectionists.'" He quoted a student who recalled disinterring bodies, occasionally being fired upon in graveyards, and once being "hauled up to the court house for trial."⁴ Perhaps this skull was procured one night by Transylvania medical students who purposefully robbed the grave of someone known to have been trephined in the past. Thus the reader is invited to

ponder the provenance of Transylvania's skullcap and the anonymous owner who lived for a time with a hole in his head. **II**



Charles T. Ambrose is a Professor in the Department of Microbiology, Immunology, and Molecular Genetics at the University of Kentucky College of Medicine.

1. J. L. Stone and M. L. Miles, "Skull Trepanation among the Early Indians of Canada and the United States," *Neurosurgery* 1990; 26: 1015-1020.
2. P. Prioraeschi, "Possible Reasons for Neolithic Skull Trephining," *Perspectives in Biology and Medicine* 1991; 34: 296-303.
3. B. W. Dudley, "Observations on Injuries of the Head," *The Transylvania Journal of Medicine and the Associate Sciences* 1828; 1: 11-40.
4. J. D. Wright Jr., *Transylvania: Tutor to the West*, Lexington, Ky.: Transylvania University, 1975, p. 85.



This illustration and the one at the top of page 2 are from Illustrations of the Great Operations of Surgery by Charles Bell. (See article on page 8.)