

University of Groningen

Patient experience in nerve-to-masseter-driven smile reanimation

van Veen, Martinus M.; Dusseldorp, Joseph R.; Quatela, Olivia; Baiungo, Jennifer; Robinson, Mara; Jowett, Nate; Hadlock, Tessa A.

Published in:
Journal of Plastic Reconstructive and Aesthetic Surgery

DOI:
[10.1016/j.bjps.2019.03.037](https://doi.org/10.1016/j.bjps.2019.03.037)

IMPORTANT NOTE: You are advised to consult the publisher's version (publisher's PDF) if you wish to cite from it. Please check the document version below.

Document Version
Publisher's PDF, also known as Version of record

Publication date:
2019

[Link to publication in University of Groningen/UMCG research database](#)

Citation for published version (APA):

van Veen, M. M., Dusseldorp, J. R., Quatela, O., Baiungo, J., Robinson, M., Jowett, N., & Hadlock, T. A. (2019). Patient experience in nerve-to-masseter-driven smile reanimation. *Journal of Plastic Reconstructive and Aesthetic Surgery*, 72(8), 1265-1271. <https://doi.org/10.1016/j.bjps.2019.03.037>

Copyright

Other than for strictly personal use, it is not permitted to download or to forward/distribute the text or part of it without the consent of the author(s) and/or copyright holder(s), unless the work is under an open content license (like Creative Commons).

The publication may also be distributed here under the terms of Article 25fa of the Dutch Copyright Act, indicated by the "Taverne" license. More information can be found on the University of Groningen website: <https://www.rug.nl/library/open-access/self-archiving-pure/taverne-amendment>.

Take-down policy

If you believe that this document breaches copyright please contact us providing details, and we will remove access to the work immediately and investigate your claim.

Downloaded from the University of Groningen/UMCG research database (Pure): <http://www.rug.nl/research/portal>. For technical reasons the number of authors shown on this cover page is limited to 10 maximum.



ELSEVIER



Patient experience in nerve-to-masseter-driven smile reanimation

Martinus M. van Veen^{a,b,*}, Joseph R. Dusseldorp^{a,c},
Olivia Quatela^a, Jennifer Baiungo^a, Mara Robinson^a,
Nate Jowett^a, Tessa A. Hadlock^a

^a Department of Otolaryngology/Head and Neck surgery, Facial Nerve Center, Massachusetts Eye and Ear Infirmary and Harvard Medical School, 243 Charles St., Boston, MA 02114, USA

^b Department of Plastic surgery, University Medical Center Groningen and University of Groningen, P.O. Box 30.001, NL-9700 RB Groningen, the Netherlands

^c Department of Plastic and Reconstructive Surgery, Royal Australasian College of Surgeons and University of Sydney, City Road, Camperdown/Darlington NSW 2006, Australia

Received 10 September 2018; accepted 24 March 2019

KEYWORDS

Facial paralysis;
Facial paresis;
Patient-reported
outcome;
Nerve to masseter

Abstract *Introduction:* The nerve-to-masseter is one of the most frequently used neural sources in smile reanimation surgery. Very little information has been reported on patient experience with regard to reanimated smile usage and sequelae following transfer. The aim of this study was to quantify patient perception of nerve-to-masseter use in smile reanimation surgery.

Methods: An online questionnaire was developed based on the clinical expertise of our team, patient interviews, and existing questionnaires of facial palsy-related quality of life and temporomandibular joint dysfunction. All patients treated with nerve-to-masseter-driven smile reanimation surgery, both nerve transfers and muscle transplantations, between 2007 and 2016 with a valid email address were invited to participate.

Results: Of 171 operated patients, 122 with a valid email address were invited to participate. Seventy-one patients responded (63.4% female, mean age 51.1 years) after a median follow-up of 3.8 years. A voluntary smile while biting down at least “most of the time” was reported by 83.1% of patients; 46.5% reported ability to smile on the affected side without bite. A “normal” or “almost normal” spontaneous smile was reported in 23.9% of patients. A total of 18.3% of patients self-reported masseter muscle atrophy, and 1.4–14.1% reported temporomandibular

* Corresponding author at: Department of Plastic Surgery, University Medical Centre Groningen and University of Groningen, P.O. Box 30.001, NL-9700 RB Groningen, the Netherlands.

E-mail address: m.m.van.veen@umcg.nl (M.M. van Veen).

joint dysfunction. Forty-one patients (57.7%) reported prandial movement of the face at least “most of the time,” with 9 patients (12.7%) considering this bothersome.

Conclusion: Patients report good voluntary smiling ability following nerve-to-masseter-driven smile reanimation surgery, with low rates of sequelae.

© 2019 British Association of Plastic, Reconstructive and Aesthetic Surgeons. Published by Elsevier Ltd. All rights reserved.

Introduction

Ongoing debate exists regarding the optimal neural source to drive smile reanimation in both the early setting (less than 18-24 months),¹ when facial muscles are receptive to reinnervation, and long-standing palsy, when they are not. Recently, the most commonly used neural source to augment facial function has become the nerve-to-masseter (NTM) because of its high axonal density and favorable anatomical location.²⁻⁵ Other neural sources include the ipsilateral facial nerve stump through cable graft, cross-facial nerve graft (CFNG), deep temporal nerve, hypoglossal nerve, and accessory nerve.

In the acute setting, a masseteric-to-facial (V-to-VII) nerve transfer can be performed, whereby a branch of the NTM is transposed to an ideal distal facial nerve branch that supplies the zygomaticus and orbicularis oculi muscles or to the main trunk of the facial nerve to reanimate the smile and enable some voluntary eye closure.⁵⁻⁸ In longstanding facial palsy, free or regional muscle transfers are needed to reanimate a smile. Cross-facial nerve grafting is considered as the more ideal neural source to reinnervate free muscle transfers, as it provides spontaneity.⁹ However, in recent years, the NTM has been shown to provide more reliable voluntary contraction of the transplanted muscle.^{4,10,11}

While successful reanimation of voluntary smiling is highly reliable after this procedure, opinions vary on the ability of the NTM to produce a spontaneous or emotional smile.¹²⁻¹⁸ Relatively few studies have assessed the patient experience of NTM-driven smile reanimation,¹⁹ although there have been many studies that report low morbidity following its use for smile reanimation.^{7,20-22} Recognized limitations of NTM are that it does not provide resting tone to the face, and complete division of the nerve can lead to atrophy of the masseter muscle and a contour irregularity over the mandibular angle.²²⁻²⁴ Prandial activation is inherent to the use of the NTM in smile reanimation, although a recent study found that this was rarely bothersome to patients.¹⁹ Varying physical therapy regimens have been suggested to optimize training the “bite-smile” to achieve a smile that is balanced with the contralateral healthy side. These exercises could lead to temporomandibular joint (TMJ) pain due to overuse.²⁵ The aim of this study was to understand the patients’ perspective of the NTM-driven smile and to investigate the rates of possible accessory complaints.

Methods

Institutional review board approval was obtained before the start of this cross-sectional study. All patients treated with a V-to-VII nerve transfer or gracilis functional free muscle

transfer (FFMT) innervated by the NTM between January 2007 and December 2016 at our center were invited to complete an online questionnaire. Patient charts were reviewed for patient characteristics, and the eFace score for “oral commissure movement with smile.”

Questionnaire development and administration

A questionnaire was developed to assess patient experience following NTM-driven smile reanimation surgery based on the clinical expertise of our surgeons and physical therapists. Relevant items from the “Facial Clinimetric Evaluation (FaCE) scale” (facial palsy-related quality of life) and the “Research Diagnostic Criteria for Temporomandibular Disorders” were included in our survey. During a qualitative stage of survey development, four surgeons, two physical therapists, and five patients were interviewed. This was done to ensure direct input from patients into the content of our study questionnaire. Four domains were identified as being of critical importance: smile and symmetry, eating and social behavior, TMJ complaints, and physical therapy exercises. The questionnaire comprised closed-ended questions in both Likert scale and yes/no formats (Appendix - Full questionnaire). The questionnaire was administered through an online survey platform (REDCap, Vanderbilt University, Nashville, USA) to all patients for whom an email address was valid.

Data analysis

Nominal data were presented as frequencies and percentages. Ordinal data were presented as medians and interquartile ranges. Interval data were presented as means and standard deviations or medians and interquartile ranges, depending on whether or not the data were normally distributed. Testing between groups was performed using chi-squared tests and Mann-Whitney U tests. Correlation coefficients were tested by Spearman correlation. Statistical analysis was performed in SPSS version 25 with an alpha of 0.05.

Results

NTM-driven smile reanimation was performed in 171 patients between January 2007 and December 2016 (104 gracilis FFMT and 67 V-to-VII nerve transfers). A valid email address was known for 122 patients, and two patients declined to participate in the study. A total of 71 (58.2%) patients responded to our invitation to participate.

Table 1 Patient characteristics (n = 71).

Gender (n (%))	
Male	26 (36.6)
Female	45 (63.4)
Side (n (%))	
Left	33 (46.5)
Right	34 (47.9)
Bilateral	4 (5.6)
Etiology (n (%))	
Acoustic neuroma	20 (28.2)
Bell's palsy	9 (12.7)
Benign head and neck tumor	19 (26.8)
Malignant head and neck tumor	8 (11.3)
Otologic surgery	3 (4.2)
Trauma	4 (5.6)
Other	8 (11.3)
Age at the time of study, years (mean (SD))	51.1 (15.6)
Follow-up duration, years (median (IQR))	3.8 (2.2; 5.0)
Type surgery (n (%))	
Gracilis by V	42 (59.2)
V-to-VII nerve transfer	29 (40.8)
Additional static midface procedure (n (%))	29 (40.8)
Type of facial palsy (n (%))	
Flaccid	47 (66.2)
Non-flaccid	24 (33.8)

Abbreviations: IQR: interquartile range, n: number, SD: standard deviation, V: nerve-to-masseter, VII: facial nerve.

Of the 71 respondents, 42 (59.2%) underwent gracilis FFMT (innervated by the NTM alone) and 29 (40.8%) underwent V-to-VII nerve transfer. Mean (SD) age at the time of study was 51.1 (15.6) years. Median (IQR) follow-up was 3.8 (2.2; 5.0) years. Most patients presented with facial palsy because of an acoustic neuroma (28.2%). In addition to smile reanimation surgery, static suspension with fascia lata was performed in 29 (40.8%) patients. Forty-seven patients (66.2%) had flaccid facial palsy, and the remaining patients had nonflaccid facial palsy (n = 24, 33.8%) (Table 1). The patients included in this study did not differ from the rest of the operative cohort in gender (p = 0.749) or age (p = 0.128). The time between operation and study date was shorter for respondents than for nonrespondents (p = 0.011).

A majority of patients (n = 59, 83.1%) described being able to smile while biting down at least “most of the time,” while fewer patients (n = 33, 46.5%) were able to smile without biting down (Figure 1). Seventeen patients (23.9%) reported a “normal” or “almost normal” spontaneous smile (Figure 2). No statistically significant difference in self-reported ability to smile (voluntary with and without biting down, and spontaneous) was found between patients with flaccid and nonflaccid facial palsy (p = 0.902, p = 0.450, and p = 0.233, respectively). Self-reported smiling abilities were not statistically significantly different for patients with a follow-up shorter than 2 years than for patients with a follow-up longer than 2 years for all three smile types (p = 0.692, p = 0.930, and p = 0.668, respectively). A weak and nonsignificant correlation was found

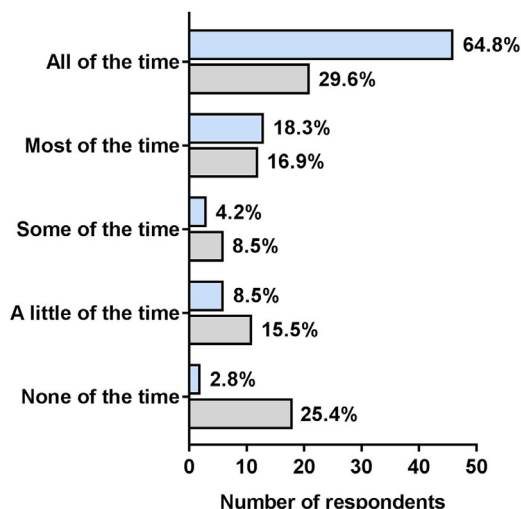


Figure 1 Bar charts of patient self-reported ability to smile voluntarily with biting down (blue) and without biting down (gray) (missing: n = 1 (1.4%) and n = 3 (4.2%), respectively).

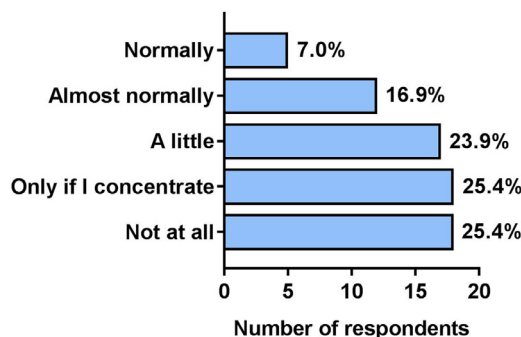


Figure 2 Patient self-reported spontaneity of smile (missing: n = 1 (1.4%).)

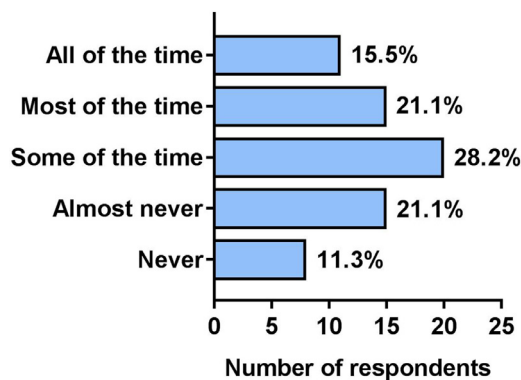


Figure 3 Answers to the question: “How often do you use your bite-smile?” (missing: n = 2 (2.8%).)

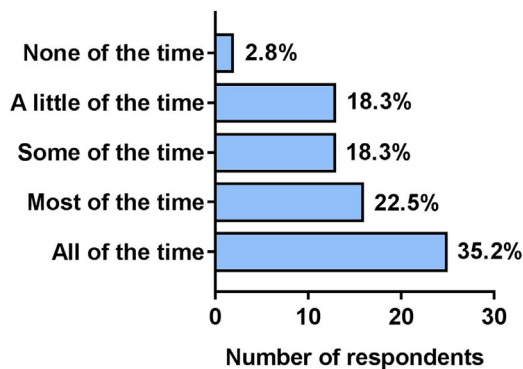
between clinician-observed smiling ability and patient self-reported voluntary smiling ability (Spearman correlation coefficient = 0.175, p = 0.235). Twenty-three patients (32.4%) reported “never” or “almost never” using their bite-driven smile (Figure 3), with 14 patients (19.8%) reporting the need to bite down to smile as being “bothersome” or “very bothersome”. In descending order of frequency, patients

Table 2 Answers to the question “Have you noticed any loss of volume or asymmetry over your jaw on your affected side compared to your healthy side?”

	All patients (n = 71)	Gracilis by V (n = 42)	V-to-VII nerve transfer (n = 29)
Yes (n (% ^a))	13 (18.3)	6 (14.3)	7 (24.1)
No (n (% ^a))	38 (53.5)	25 (59.5)	13 (44.8)
I am not sure (n (% ^a))	18 (25.4)	10 (23.8)	8 (27.6)
Missing (n (% ^a))	2 (2.8)	1 (2.4)	1 (3.4)

^a Percentages are column percentages.

Abbreviations: n: number, V: nerve-to-masseter, VII: facial nerve.

**Figure 4** Answers to the question: “When you eat, does the affected side of your face move?” (missing: n = 2 (2.8%)).

reported using their bite smile for “photos” (n = 34, 47.9%), “meeting new people” (n = 20, 28.2%), “interacting with acquaintances” (n = 16, 22.5%), and “interacting with close family or friends” (n = 14, 19.7%).

Sixty-five patients (91.6%) reported improved symmetry of the face after surgery, and 63 patients (88.8%) reported improved symmetry of their smile. Forty-three patients (60.5%) scored their face as symmetric, and 30 patients (42.3%) scored their smile as symmetric. No significant difference was seen between patients who were and who were not treated with a concurrent static midface suspension procedure (using a Bonferroni corrected p-value for four tests ($p = 0.013$)).

Thirteen patients (18.3%) perceived masseter muscle atrophy or facial contour asymmetry following NTM transfer (Table 2). Although this difference was not statistically significant ($p = 0.429$), a larger proportion of the “V-to-VII nerve transfer” patients reported self-perceived masseter muscle atrophy or asymmetry than the the “gracilis by V” patients (24.1% versus 14.3%, respectively) (Table 2). More than half of respondents perceived cheek movement while eating “all of the time” (n = 25, 35.2%) or “most of the time” (n = 16, 22.5%) (Figure 4), with eight patients (11.3%) reporting movements such as “bothersome”, and one patient (1.4%) reporting “very bothersome.” Patients generally reported few complaints regarding TMJ function (Table 3). Fifteen patients (21.1%) reported preoperative existence of problems with the TMJ or a preoperative diagnosis of TMJ disorder.

Fifty-five of the 71 respondents (77.5%) received targeted facial nerve physical therapy. Thirty-five patients (49.3%) reported adherence to the physical therapy treatment plan. Twenty-seven patients (38.0%) stated that phys-

ical therapy was an important part of their treatment plan, and 36 patients (50.7%) stated that physical therapy helped them to understand how to use their “bite-driven smile”.

A full list of the answers to all questions in the questionnaire is given in the appendix.

Discussion

The NTM is growing in popularity as a first-line neural source to reinnervate smile in facial palsy in our center. The aim of this study was to better understand patients’ perspectives regarding NTM-driven smile reanimation and to quantify potential and reported side effects of its use.

We found that the vast majority of respondents were able to smile voluntarily (83.1%) while biting down. A “normal” or “almost normal” spontaneous smile was self-reported by only 23.9% of patients in our study, which is in line with the 23% of spontaneous smile rates after NTM-driven smile reanimation found by a recent systematic review.⁸ The ability to smile emotionally or spontaneously following NTM-driven smile reanimation has been reported, and several explanations may account for this.⁸ The most commonly attributed rationale is cortical plasticity, whereby new neuronal connections are made in the brain allowing signals from the facial nerve nucleus to cause activation of the motor nucleus of trigeminal nerve.^{16,17} This is believed to occur more frequently in younger patients. Additionally, cortical plasticity is reported to occur more frequently in bilateral facial palsy patients.¹⁶ With only four patients with bilateral palsy in our series, we were not able to test this hypothesis statistically. Other groups describe improvements in spontaneity from intensive neuromuscular retraining.^{18,26} Another more direct explanation is that nearly 40% of normal subjects studied co-contract masseter and zygomaticus major while smiling.¹³ Thus, the presence of spontaneity in some patients may be due to this pre-existing co-contraction of the masseter muscle with smiling, making them ideal candidates for NTM-driven smile reanimation.¹³

While self-reported voluntary smiling ability is generally good following NTM-driven smile reanimation, a relevant proportion of patients (32.4%) report infrequent use of their bite-smile. Simultaneously, patients report less use of the bite smile when interacting with close friends or family than taking photos or meeting new people. This difference may indicate that the bite smile is seen as a good tool for non-verbal communication, which is known to be a critically important for psychosocial functioning after facial palsy.²⁷⁻²⁹

Masseter muscle atrophy was self-reported in 18.3% of all patients, although some patients (25.4%) reported not being

Table 3 Answers to patient self-perceived complaints regarding the TMJ.

	All of the time	Most of the time	Some of the time	Almost never	Never	Missing
Pain/discomfort ^b (n (% ^a))	1 (1.4)	2 (2.8)	16 (22.5)	9 (12.7)	41 (57.7)	2 (2.8)
Clicking/locking ^c (n (% ^a))	1 (1.4)	2 (2.8)	12 (16.9)	16 (22.5)	39 (54.9)	1 (1.4)
Difficulty chewing ^d (n (% ^a))	4 (5.6)	5 (7.0)	15 (21.1)	23 (32.4)	22 (31.0)	2 (2.8)
Difficulty opening ^e (n (% ^a))	10 (14.1)	17 (23.9)	17 (23.9)	7 (9.9)	15 (21.1)	5 (7.0)

^a Percentages are row percentages.

^b Do you experience pain or discomfort around the joint of the jaw in front of the ear?

^c Do you experience clicking or locking of the lower jaw?

^d Do you have difficulty chewing certain foods?

^e Do you have difficulty opening your mouth wide to eat certain foods (e.g., an apple or hamburger)? Abbreviations: n: number, TMJ: temporomandibular joint.

sure whether masseter muscle atrophy was present. The authors of a case series of seven patients treated with V-to-VII nerve transfer report no postoperative problems with chewing and only one case (14.3%) of facial contour asymmetry due to masseter muscle atrophy.²² An important option in preventing masseter muscle atrophy from happening is preserving the anterior branch of the NTM during donor nerve mobilization, which we have started to do more recently as well.

Only 2.8% of respondents reported never having experienced movement of the oral commissure with prandial activity. Postoperative prandial movement of the cheek was reported by 97.2% of all patients, ranging from “a little of the time” to “all of the time.” A small proportion of patients reported this involuntary movement to be “bothersome” (11.3%) or “very bothersome” (1.4%). In a study solely focused on examining involuntary movement during mastication in NTM-driven gracilis FFMT patients, the authors acquired postoperative videos of 16 patients eating and evaluated the pattern of mastication, observer-perceived cheek movement, and social hindrance according to the patient.¹⁹ The authors observed prandial movement in all 16 patients, but only 33% of the patients self-report being aware of prandial movement. Similar to our study, prandial movement was not considered bothersome by the majority of patients.

TMJ complaints are relatively common in the general population, with prevalence rates of 6-12% being reported.³⁰ In our study, “pain or discomfort” and “clicking or locking” of the TMJ were reported by a small proportion of patients. Difficulty chewing and difficulty opening the mouth, in particular, were reported more often (Table 3), but 21.1% of patients also reported a pre-existing diagnosis of TMJ disorders or complaints. Given the high rate of preoperative TMJ complaints, it seems unlikely that NTM-driven smile reanimation techniques cause complaints of the TMJ. This is further supported by a case series of 11 patients after V-to-VII nerve transfer.²⁵ The authors evaluated the rehabilitation of the facial muscles after the procedure with clinical examination of the masseter muscle and TMJ, finding no symptoms or signs of TMJ dysfunction after 18 months. However, this is a clinician report, and symptoms such as patient self-perceived pain of the TMJ were not evaluated.

Physical therapy is known to be of benefit in the rehabilitation of NTM-driven smile reanimation.^{5,25,26} Physical therapy is important in not only helping patients initially using their bite-driven smile but also teaching how to generate

a smile without active bite movement and how to avoid cheek movement when eating. Patients generally share this view, with relatively high proportions of patients stating that physical therapy is important, helped them to understand how to activate their smile, and a good self-reported adherence to the physical therapy treatment plan. It is our opinion that optimal smile reanimation requires a comprehensive team effort including the surgeon and physical therapist.

This study has several limitations. All responses were retrospective and thus subject to recall and responder bias, although a response rate of approximately 60% is sufficient to make some conclusions from the data presented. There were also very few differences found between the responder and nonresponder groups, thereby limiting the degree of responder bias. All rates presented were self-reported by patients through a questionnaire, and the use of closed-ended questions may have limited the answer options for some patients. Although the present study shows that rates of accessory complaints among NTM-driven smile reanimation patients are low, qualitative studies specifically addressing these individual areas could be useful in the future. Additionally, we chose to utilize an online platform for administering this questionnaire, ruling out patients without an email address, which may represent a source of selection bias.

This study was not designed to predict which patients would be more likely to have a successful outcome after smile reanimation driven by the NTM versus other innervation strategies. Other studies such as discrete choice experiments are needed to answer this important question. Similarly, patients who underwent cross-facial nerve grafting or dual-innervated reanimations were not surveyed, and hence, it is not reasonable to make comparisons between techniques using these data. Future studies should attempt to objectively quantify rates of spontaneous smiling after various innervation strategies in addition to including patient-reported data.

Conclusion

Patients report good voluntary smiling ability following NTM-driven smile reanimation surgery, with low rates of sequelae. Patients report generally low rates of spontaneous smiling, and one-third of patients report rarely using their bite-driven smile. The present study supports the acclaimed

low morbidity of NTM-driven smile reanimation surgery. Further prospective studies are required to analyze the effect of dual-innervation strategies and to be able to objectively quantify spontaneous smiling.

Conflict of interest

The authors have no personal or financial relationships to disclose.

Funding

None.

Supplementary materials

Supplementary material associated with this article can be found, in the online version, at doi:[10.1016/j.bjps.2019.03.037](https://doi.org/10.1016/j.bjps.2019.03.037).

References

- Jowett N, Hadlock TA. Free gracilis transfer and static facial suspension for midfacial reanimation in long-standing flaccid facial palsy. *Otolaryngol Clin North Am* 2018;**51**(6):1129-39 doi:[10.1016/j.otol.2018.03.001](https://doi.org/10.1016/j.otol.2018.03.001) [pii].
- Borschel GH, Kawamura DH, Kasukurthi R, Hunter DA, Zuker RM, Woo AS. The motor nerve to the masseter muscle: an anatomic and histomorphometric study to facilitate its use in facial reanimation. *J Plast Reconstr Aesth Surg* 2011;**65**(3):363-6. doi:[10.1016/j.bjps.2011.09.026](https://doi.org/10.1016/j.bjps.2011.09.026).
- Bhama PK, Weinberg JS, Lindsay RW, Hohman MH, Cheney ML, Hadlock TA. Objective outcomes analysis following microvascular gracilis transfer for facial reanimation: a review of 10 years' experience. *JAMA Fac Plast Surg* 2014;**16**(2):85-92. doi:[10.1001/jamafacial.2013.2463](https://doi.org/10.1001/jamafacial.2013.2463).
- Snyder-Warwick AK, Fattah AY, Zive L, Halliday W, Borschel GH, Zuker RM. The degree of facial movement following microvascular muscle transfer in pediatric facial reanimation depends on donor motor nerve axonal density. *Plast Reconstr Surg* 2015;**135**(2):81e [doi]. doi:[10.1097/PRS.0000000000000860](https://doi.org/10.1097/PRS.0000000000000860).
- Garcia R, Hadlock T, Klebuc M, Simpson R, Zenn M, Marcus J. Contemporary solutions for the treatment of facial nerve paralysis. *Plast Reconstr Surg* 2015;**135**(6):1046e. doi:[10.1097/PRS.0000000000001273](https://doi.org/10.1097/PRS.0000000000001273).
- Coombs CJ, Ek EW, Wu T, Cleland H, Leung MK. Masseteric-facial nerve coaptation - an alternative technique for facial nerve reinnervation. *J Plast Reconstr Aesthet Surg* 2009;**62**(12):1580-8 [doi]. doi:[10.1016/j.bjps.2008.05.046](https://doi.org/10.1016/j.bjps.2008.05.046).
- Klebuc MJA. Facial reanimation using the masseter-to-facial nerve transfer. *Plast Reconstr Surg* 2011;**127**(5):1909-15. doi:[10.1097/PRS.0b013e31820e9138](https://doi.org/10.1097/PRS.0b013e31820e9138).
- Murphey AW, Clinkscales WB, Oyer SL. Masseteric nerve transfer for facial nerve paralysis: a systematic review and meta-analysis. *JAMA Fac Plast Surg* 2018. doi:[10.1001/jamafacial.2017.1780](https://doi.org/10.1001/jamafacial.2017.1780).
- O'Brien BM, Franklin JD, Morrison WA. Cross-facial nerve grafts and microvascular free muscle transfer for long established facial palsy. *Br J Plast Surg* 1980;**33**(2):202-15 doi:[10.1054/bjps.1980.330202](https://doi.org/10.1054/bjps.1980.330202) [pii].
- Zuker RM, Goldberg CS, Manktelow RT. Facial animation in children with mobius syndrome after segmental gracilis muscle transplant. *Plast Reconstr Surg* 2000;**106**(1):8 discussion 9.
- Bae YC, Zuker RM, Manktelow RT, Wade S. A comparison of commissure excursion following gracilis muscle transplantation for facial paralysis using a cross-face nerve graft versus the motor nerve to the masseter nerve. *Plast Reconstr Surg* 2006;**117**(7):2407-13 [doi]. doi:[10.1097/01.prs.0000218798.95027.21](https://doi.org/10.1097/01.prs.0000218798.95027.21).
- Buendia J, Loayza FR, Luis EO, Celorrio M, Pastor MA, Hontanilla B. Functional and anatomical basis for brain plasticity in facial palsy rehabilitation using the masseteric nerve. *J Plast Reconstr Aesth Surg* 2015;**69**(3):417-26. doi:[10.1016/j.bjps.2015.10.033](https://doi.org/10.1016/j.bjps.2015.10.033).
- Schaverien M, Moran G, Stewart K, Addison P. Activation of the masseter muscle during normal smile production and the implications for dynamic reanimation surgery for facial paralysis. *J Plast Reconstr Aesthet Surg* 2011;**64**(12):1585-8 [doi]. doi:[10.1016/j.bjps.2011.07.012](https://doi.org/10.1016/j.bjps.2011.07.012).
- Hontanilla B, Cabello A. Spontaneity of smile after facial paralysis rehabilitation when using a non-facial donor nerve. *J Cranio Maxillo Fac Surg* 2016;**44**(9):1305-9. doi:[10.1016/j.jcms.2016.06.031](https://doi.org/10.1016/j.jcms.2016.06.031).
- Hontanilla B, Marre D. Differences between sexes in dissociation and spontaneity of smile in facial paralysis reanimation with the masseteric nerve. *Head Neck* 2014;**36**(8):1176-80. doi:[10.1002/hed.23432](https://doi.org/10.1002/hed.23432).
- Manktelow RT, Tomat LR, Zuker RM, Chang M. Smile reconstruction in adults with free muscle transfer innervated by the masseter motor nerve: effectiveness and cerebral adaptation. *Plast Reconstr Surg* 2006;**118**(4):885-99. doi:[10.1097/01.prs.0000232195.20293.bd](https://doi.org/10.1097/01.prs.0000232195.20293.bd).
- Garmi R, Labbé D, Coskun O, Compère J, Bénateau H. Lengthening temporalis myoplasty and brain plasticity: a functional magnetic resonance imaging study. *Annales de Chirurgie Plastique et Esthétique* 2013;**58**(4):271. <http://www.ncbi.nlm.nih.gov/pubmed/23623628>.
- Labbe D, Huault M. Lengthening temporalis myoplasty and lip reanimation. *Plast Reconstr Surg* 2000;**105**(4):97 discussion 1298.
- Rozen S, Harrison B. Involuntary movement during mastication in patients with long-term facial paralysis reanimated with a partial gracilis free neuromuscular flap innervated by the masseteric nerve. *Plast Reconstr Surg* 2013;**132**(1):116e. doi:[10.1097/PRS.0b013e318290f644](https://doi.org/10.1097/PRS.0b013e318290f644).
- Yoshioka N, Tominaga S. Masseteric nerve transfer for short-term facial paralysis following skull base surgery. *J Plast Reconstr Aesth Surg* 2015;**68**(6):764-70. doi:[10.1016/j.bjps.2015.02.031](https://doi.org/10.1016/j.bjps.2015.02.031).
- Biglioli F, Colombo V, Rabbiosi D, et al. Masseteric-facial nerve neurotomy: results of a case series. *J Neurosurg* 2017;**126**(1):312-18. doi:[10.3171/2015.12.JNS14601](https://doi.org/10.3171/2015.12.JNS14601).
- Biglioli F, Frigerio A, Colombo V, et al. Masseteric-facial nerve anastomosis for early facial reanimation. *J Cranio Maxillo Fac Surg* 2011;**40**(2):149-55. doi:[10.1016/j.jcms.2011.03.005](https://doi.org/10.1016/j.jcms.2011.03.005).
- Chen G, Wang W, Wang W, Ding W, Yang X. Symmetry restoration at rest after masseter-to-facial nerve transfer: is it as efficient as smile reanimation. *Plast Reconstr Surg* 2017;**140**(4):793-801 [doi]. doi:[10.1097/PRS.0000000000003698](https://doi.org/10.1097/PRS.0000000000003698).
- Rozen SM. Discussion: symmetry restoration at rest after masseter-to-facial nerve transfer: is it as efficient as smile reanimation? *Plast Reconstr Surg* 2017;**140**(4):802-4 [doi]. doi:[10.1097/PRS.0000000000003736](https://doi.org/10.1097/PRS.0000000000003736).
- Pavese C, Cecini M, Lozza A, et al. Rehabilitation and functional recovery after masseteric-facial nerve anastomosis. *Eur J Phys Rehabil Med* 2016;**52**(3):379-88 doi:[10.1017/S11267331150026](https://doi.org/10.1017/S11267331150026) [pii].

26. Tzou CH, Chuang DC, Chen HY. Cortical adaptation staging system: a new and simple staging for result evaluation of functioning free-muscle transplantation for facial reanimation. *Ann Plast Surg* 2014;**73**(1):50-3.
27. Coulson SE, O'dwyer NJ, Adams RD, Croxson GR. Expression of emotion and quality of life after facial nerve paralysis. *Otol Neurotol* 2004;**25**(6):1014-19 doi:00129492-200411000-00026 [pii].
28. VanSwearingen JM, Cohn JF, Bajaj-Luthra A. Specific impairment of smiling increases the severity of depressive symptoms in patients with facial neuromuscular disorders. *Aesthetic Plast Surg* 1999;**23**(6):416-23 APS1273 [pii].
29. van Veen MM, Tavares-Brito J, van Veen BM, et al. Association of regional facial dysfunction with facial palsy-related quality of life. *JAMA Fac Plast Surg* 2018. doi:10.1001/jamafacial.2018.0804.
30. Liu F, Steinkeler A. Epidemiology, diagnosis, and treatment of temporomandibular disorders. *Dent Clin North Am* 2013;**57**(3):465-79. doi:10.1016/j.cden.2013.04.006.