

University of Groningen

**Pulmonary vein anatomy addressed by computed tomography and relation to success of second-generation cryoballoon ablation in paroxysmal atrial fibrillation**

Mulder, Bart A; Al-Jazairi, Meelad I H; Arends, Bauke K O; Bax, Niels; Dijkshoorn, Leonard A; Sheikh, Uzaifa; Tan, Eng Shiong; Wiesfeld, Ans C P; Tieleman, Robert G; Vliementhart, Rozemarijn

*Published in:*  
Clinical Cardiology

*DOI:*  
[10.1002/clc.23163](https://doi.org/10.1002/clc.23163)

**IMPORTANT NOTE: You are advised to consult the publisher's version (publisher's PDF) if you wish to cite from it. Please check the document version below.**

*Document Version*  
Publisher's PDF, also known as Version of record

*Publication date:*  
2019

[Link to publication in University of Groningen/UMCG research database](#)

*Citation for published version (APA):*

Mulder, B. A., Al-Jazairi, M. I. H., Arends, B. K. O., Bax, N., Dijkshoorn, L. A., Sheikh, U., ... Blaauw, Y. (2019). Pulmonary vein anatomy addressed by computed tomography and relation to success of second-generation cryoballoon ablation in paroxysmal atrial fibrillation. *Clinical Cardiology*, 42(4), 438-443. <https://doi.org/10.1002/clc.23163>

**Copyright**

Other than for strictly personal use, it is not permitted to download or to forward/distribute the text or part of it without the consent of the author(s) and/or copyright holder(s), unless the work is under an open content license (like Creative Commons).


**Take-down policy**

If you believe that this document breaches copyright please contact us providing details, and we will remove access to the work immediately and investigate your claim.

*Downloaded from the University of Groningen/UMCG research database (Pure): <http://www.rug.nl/research/portal>. For technical reasons the number of authors shown on this cover page is limited to 10 maximum.*

**CLINICAL INVESTIGATIONS**

# Pulmonary vein anatomy addressed by computed tomography and relation to success of second-generation cryoballoon ablation in paroxysmal atrial fibrillation

Bart A. Mulder<sup>1</sup>  | Meelad I. H. Al-Jazairi<sup>1</sup> | Bauke K. O. Arends<sup>1</sup> | Niels Bax<sup>1</sup> | Leonard A. Dijkshoorn<sup>1</sup> | Uzaifa Sheikh<sup>1</sup> | Eng S. Tan<sup>1</sup> | Ans C. P. Wiesfeld<sup>1</sup> | Robert G. Tieleman<sup>1,2</sup> | Rozemarijn Vliegthart<sup>3</sup> | Michiel Rienstra<sup>1</sup> | Isabelle C. van Gelder<sup>1</sup> | Yuri Blaauw<sup>1</sup>

<sup>1</sup>Department of Cardiology, University of Groningen, University Medical Center Groningen, Groningen, The Netherlands

<sup>2</sup>Department of Cardiology, Martini Hospital, Groningen, The Netherlands

<sup>3</sup>Department of Radiology, University of Groningen, University Medical Center Groningen, Groningen, The Netherlands

**Correspondence**

Bart A. Mulder, MD, PhD, Department of Cardiology, Thoraxcenter, University of Groningen, University Medical Center Groningen, P.O. Box 30.001, 9700 RB Groningen, The Netherlands.  
Email: b.a.mulder@umcg.nl

**Background:** Cryoballoon isolation is considered a safe and effective treatment for atrial fibrillation (AF). However, recurrence of AF after first cryoballoon ablation occurs in ~30% of patients. Pre-procedurally identifying patients at risk of AF recurrence could be beneficial.

**Hypothesis:** Our aim was to determine how pulmonary vein (PV) anatomy influences the recurrence of AF using the second-generation cryoballoon in patients with paroxysmal AF.

**Methods:** We included 88 consecutive patients with paroxysmal AF undergoing PVI procedure with a second-generation 28-mm cryoballoon. All patients were evaluated at 3, 6 and 12 months using a 12-lead ECG and 24-hour Holter monitoring. PV anatomy was assessed by creating three-dimensional models using computed tomography (CT) segmentations of the left atrium.

**Results:** Fifty-one patients (61%) had left PVs with a shared carina, 35 patients (42%) had a shared right carina. Nine patients (11%) were classified having a right middle PV. In total 17 (20.2%) of patients had a left common PV. At 12 months, 14 patients (17%) had experienced AF recurrence. Neither PV ovality, variant anatomy, the presence of shared carina nor a common left PV was a predictor for AF recurrence.

**Conclusions:** No specific characteristics of PV dimensions nor morphology were associated with AF recurrence after cryoballoon ablation in patients with paroxysmal AF.

**KEYWORDS**

anatomy, atrial fibrillation, computed tomography, cryoballoon ablation, outcome, pulmonary veins

## 1 | INTRODUCTION

Atrial fibrillation (AF) is the most encountered arrhythmia in clinical practice. In 2010, it was estimated that 33.6 million people suffer from AF worldwide.<sup>1</sup> Recent guidelines state that pulmonary vein isolation (PVI) is considered first choice treatment.<sup>2</sup> PVI using cryoballoon is a common used ablation strategy, however, a significant proportion of patient experience AF recurrences.<sup>3,4</sup>

Ablation outcome may be affected by clinical factors, such as type of AF, left atrial (LA) size, comorbidities or operator experience.<sup>5,6</sup> Besides these clinical characteristics, it has been suggested that PV morphology may also affect outcome. PV anatomy is very heterogeneous and optimal circumferential contact between the cryoballoon and PV/atrial myocardium is important for long-term freedom from AF.<sup>7</sup> Previous studies on the relationship between PV ovality and cryoballoon ablation showed that a larger ovality index of the left

This is an open access article under the terms of the Creative Commons Attribution License, which permits use, distribution and reproduction in any medium, provided the original work is properly cited.

© 2019 The Authors. *Clinical Cardiology* published by Wiley Periodicals, Inc.

inferior pulmonary vein (LIPV) has been found to predict AF recurrence in a group of paroxysmal and persistent AF patients.<sup>8,9</sup> However in previous studies both the first- and second-generation balloon with different balloon sizes (23- and 28-mm) were used<sup>9</sup> and a heterogeneous group of patients (both paroxysmal and/or persistent AF) were included.<sup>8</sup>

The aim of the present study was to assess PV morphology and variants including carina width, shared carina or PV ovality index and whether this is of influence on AF recurrence after PVI with the second generation 28 mm cryoballoon in a homogenous population of patients with paroxysmal AF.

## 2 | METHODS

### 2.1 | Patients

Eighty-eight consecutive patients with drug-refractory paroxysmal AF underwent second-generation cryoballoon ablation between February 2014 and February 2015 in the University Medical Center Groningen. To ensure a homogenous group of patients, we included only patients with paroxysmal AF who underwent second-generation cryoballoon ablation therapy in this study. Of these patients, 84 had computed tomography (CT) scans prior to the ablation procedure that could be analyzed for PV dimensions and morphology and were included in this analysis. All data were retrospectively collected from the patients' medical files. All patients consented to the ablation procedure, all data is anonymously gathered retrospectively and no additional studies were performed, therefore, no ethical approval was obtained.

### 2.2 | CT image acquisition and analysis

Cardiac CT scanning was performed with a first generation dual-source CT system (SOMATOM Definition, Siemens Healthcare, Forchheim, Germany). Scan acquisitions were made with the patient at inspiratory breath hold. A topogram was made to determine the scan range, from a couple of centimeters above the carina to just below the heart, to include all PVs entering the left atrium. CT scan protocols details include: prospective ECG triggering, sequential mode with collimation  $2 \times 64 \times 0.6$  mm using a flying z-spot, tube voltage 100, 120, or 140 kV (depending on patient size), gantry rotation time 330 ms, reference tube current 220/200/196 mAs/rotation, respectively, electrocardiography (ECG)-gated tube current modulation. The contrast agent injected was iomeprol 350 or 400 mg/100 mL (Iomeron 350 or 400, Bracco Imaging S.p.A., Milan, Italy). The contrast bolus depended on patient size and length of the scan, and was followed by a saline flush. Contrast-enhanced cardiac CT scanning was performed at 70% of the cardiac cycle. Computed tomography angiography (CTA) data were reconstructed with as 1.2 mm consecutive slices in the axial plane, using a smooth kernel (B30f). The cardiac radiologist performed reporting in clinical setting, and reported on the lung vein anatomy, left atrium and thrombus in left atrial appendage on the cardiac CT, as well as side findings. For further analysis, CT scans were uploaded to Syngo X Workplace VB21C (Siemens AG, Wittelsbacherplatz, Munich, Germany) and segmented to obtain the LA. Subsequently, the scans

were transferred to CartoMerge (Biosense Webster, Diamond Bar, California) for segmentation and analysis in the three-dimensional field. The vein ostia were identified as the visual anatomical entry point of the PVs in the atrial wall, which was the point with the highest inflection.<sup>10</sup> Ostium of all PVs was identified and thereafter assessment of carina width, vein diameter, and morphology. The patient population was divided into two groups and analyzed by four independent researchers, two for each group. Thus, each CT was analyzed twice by two independent researchers who were blinded to the outcome of the clinical procedure. The order of CT scans was shuffled, to account for a learning curve. The average of these measurements was calculated and used in the analysis. In case of disagreement about morphology, the case was discussed among the researchers until a consensus was reached.

The carina was defined as the segment connecting ipsilateral adjacent PVs and was measured using the shortest possible line through two points at the highest inflection of this portion (carina width). A shared carina was defined as a carina width of  $<5$  mm. The ostium was assessed using multiplanar reformatting, measuring the largest (Dmax), and smallest (Dmin) diameter of each PV entering the LA. The ovality index was then calculated using the formula  $D_{max}/D_{min}$ . Veins were classified as round (ovality index  $<1.2$ ), oval (1.2-1.4) or flat ( $>1.4$ ).<sup>11,12</sup> Left common pulmonary vein (PV) was defined as the presence of bifurcated PVs entering the left atrial contour together and a distance between the virtual border of the left atrium and the bifurcation of both PVs  $\geq 5$  mm.<sup>13</sup>

### 2.3 | Cryoballoon ablation procedure

The ablation procedure was performed under conscious sedation. LA access was achieved with a single transseptal puncture. The target ACT level was  $>300$ . The second-generation 28-mm cryoballoon (Artic Front Advance, Cryocath) was used for ablation. At least two cryothermal applications (lasting 240 seconds) were delivered to isolate each vein. During cryothermal ablation of the right PVs, diaphragmatic stimulation, using a quadripolar catheter placed in the superior caval vein, was performed to avoid phrenic nerve injury. Electrical isolation of the PVs was evaluated using the circular Achieve mapping catheter (entrance block). In case of presence of remaining PV potentials pacing within the PVs was performed with 10 mA to check for exit block.

### 2.4 | Post-ablation management and follow-up

Three outpatient clinic visits were scheduled to follow the patients at 3, 6, and 12 months after the cryoballoon procedure, each preceded by a 12-lead ECG and 24-hour Holter monitoring. During these visits, medical history was obtained and physical examination was performed. Patients presenting with AF symptoms were given an event recorder to document possible recurrences. In addition, information about AF, atrial flutter, or atrial tachycardia recurrence documented by the general practitioner, during emergency room visits or during hospital admissions was also collected. Antiarrhythmic medication was continued during the first 3 months after the procedure, and then discontinued in patients without symptoms of AF.

## 2.5 | Covariate definitions

Time since first AF diagnosis was defined as the time from first documented AF episode till ablation date. Coronary artery disease was defined as history of myocardial infarction, percutaneous coronary intervention, or coronary artery bypass grafting. Hypertension was defined as systolic blood pressure >140 mm Hg and diastolic blood pressure >90 mm Hg or by use of antihypertensive medication. Body mass index (BMI) was calculated as the ratio of weight (in kilograms) to height (in meters) squared (kg/m<sup>2</sup>). Diabetes was defined as a fasting plasma glucose  $\geq$ 7.0 mmol/L, a non-fasting plasma glucose  $\geq$ 11.1 mmol/L, or use of anti-diabetic drugs. AF was considered paroxysmal if all past AF episodes ended within a week of onset (self-terminating or by cardioversion). CHA<sub>2</sub>DS<sub>2</sub>-VASc was defined according to the European Society of Cardiology guidelines.

## 2.6 | Endpoints

The primary endpoint was the first recurrence of AF, atrial flutter, or atrial tachycardia documented by ECG, Holter monitoring (episode lasting for more than 30 seconds) or by an event recorder, or repeat ablation during a follow-up of 12 months, excluding recurrences occurring in the first 90 days (blanking period).

## 2.7 | Statistical analysis

Normally distributed continuous variables were given as mean  $\pm$  SD, skewed data as median with interquartile range and categorical data as numbers with percentages. Normal distribution of data was checked using Shapiro-Wilk W test for normal data. The  $\chi^2$  was used to compare nominal variables. Intraclass coefficient (ICC) estimates between raters were calculated based on a mean-rating ( $k = 2$ ), consistency agreement, two-way mixed effects model. The first occurrence of the primary outcome was assessed by Kaplan-Meier curves. Univariate screening using Cox regression analysis was done to identify predictors of AF recurrence. A univariate  $P < 0.2$  was required for entrance in a multivariate model. All tests of significance were two-sided, with  $P$ -values of  $<0.05$  assumed to indicate significance. Data were analyzed with Stata version 13.0 (StataCorp, College Station, Texas).

## 3 | RESULTS

### 3.1 | Patient population

In total, 84 patients with paroxysmal AF were included for the present analysis. In our study population, 49 patients (58%) were male and median age at inclusion was  $59 \pm 10$  years. AF duration was 2.9 (1.2-6.6) years. A total of 47 patients (56%) had hypertension, 11 (13%) had diabetes mellitus, and 10 (12%) had coronary artery disease. Table 1 shows detailed patient characteristics. Total procedure time of the cryoballoon ablation was  $118.9 \pm 37.3$  minutes. The total number of cryo applications was  $9.6 \pm 2.7$ . Electrical isolation of the PVs was achieved in 90.5% of patients. In total, 6 complications occurred (data not shown): 2 (2.4%) phrenic nerve palsy (at discharge),

**TABLE 1** Baseline characteristics

	Overall (n = 84)	No recurrence (n = 70)	Recurrence (n = 14)	P-value
Age, mean $\pm$ SD	59 $\pm$ 10	58 $\pm$ 10	61 $\pm$ 9	0.32
Male sex, no. (%)	49 (58%)	41 (59%)	8 (57%)	0.92
Body mass index, mean $\pm$ SD	28 $\pm$ 5	28 $\pm$ 5	29 $\pm$ 6	0.65
Years of AF history, median	2.9 (1.2-6.6)	2.8 (1.2-6.9)	3.2 (0.8-5.0)	0.70
Hypertension, no. (%)	47 (56%)	41 (59%)	6 (43%)	0.28
Diabetes mellitus, no. (%)	11 (13%)	8 (11%)	3 (21%)	0.31
Coronary artery disease, no. (%)	10 (12%)	10 (14%)	0 (0%)	0.13
CHA <sub>2</sub> DS <sub>2</sub> VASc score 0 or 1, no. (%)	40 (47%)	34 (48%)	6 (43%)	0.55
Use of any anticoagulant drug, no. (%)	52 (62%)	43 (61%)	9 (64%)	0.84
Use of any antiarrhythmic drugs, no. (%)	54 (64%)	46 (66%)	8 (57%)	0.54
Use of flecainide or propafenone, no. (%)	29 (35%)	22 (31%)	7 (50%)	0.18
Use of sotalol >160 mg/day, no. (%)	20 (24%)	19 (27%)	1 (7%)	0.11
Use of amiodarone, no. (%)	5 (6%)	5 (7%)	0 (0%)	0.30
Left ventricular ejection fraction, mean $\pm$ SD	57 $\pm$ 2	57 $\pm$ 2	56 $\pm$ 3	0.10
Left atrial volume, mean $\pm$ SD	31 $\pm$ 7	31 $\pm$ 8	29 $\pm$ 7	0.29

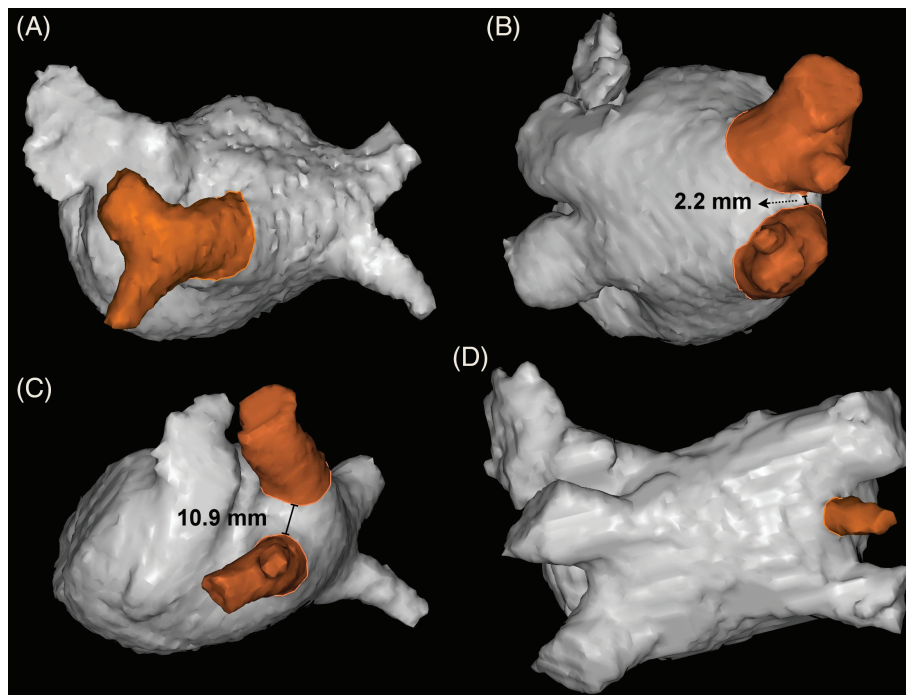
2 (2.4%) femoral pseudoaneurysm, 1 (1.2%) arterio-venous fistula, and 1.2% dissection of iliac vein.

### 3.2 | PV diameters

Measures of interobserver reproducibility revealed that all ICC estimates were significant (data not shown), except for three variables. In these instances, not enough ( $n = 3$ ) measurements were made to produce reproducible results. Figure 1 shows examples of PV anatomy. In total, 17 (20.2%) of patients had a left common PV (Figure 1A). Fifty-one patients (61%) had a shared carina left, 35 patients (42%) had a shared carina right (Figure 1B). Nine patients (11%) were classified having a right middle PV (RMPV) (Figure 1D). Table 2 displays all mean PV measurements including calculated ovality. Maximal diameters of LSPV, LIPV, RSPV, and RIPV were respectively 19.5 (17.1-20.8), 17.4 (16.0-18.9), 20.5 (18.3-23.5), and 18.0 (15.8-20.6) mm.

### 3.3 | AF recurrence

At 12 months, 14 patients (17%) had experienced AF recurrence. When compared to patients without recurrence, there was no observed difference in ovality index in patients with AF recurrence



**FIGURE 1** Examples of pulmonary vein anatomy. A, Left common pulmonary vein, B, shared carina, C, non shared carina, and D, right middle pulmonary vein

**TABLE 2** Pulmonary vein diameters

	No recurrence (n = 70)	Recurrence (n = 14)	P-value
Left sided PV			
LSPV max outer diameter, median (IQR)	20.8 (18.3-22.5)	20.8 (18.5-23.0)	0.83
LIPV max outer diameter, median (IQR)	18.5 (17.1-20.0)	17.5 (16.7-19.0)	0.19
Right sided PV			
RSPV max outer diameter, median (IQR)	23.4 (20.5-25.9)	22.4 (20.5-26.1)	0.74
RIPV max outer diameter, median (IQR)	20.2 (17.3-22.2)	19.1 (18.6-21.0)	0.49

Abbreviations: IQR, interquartile range; LIPV, left inferior pulmonary vein; LSPV, left superior pulmonary vein; PV, pulmonary vein; RIPV, right inferior pulmonary vein; RSPV, right superior pulmonary vein.

(Table 3). Also, no significant interaction between a shared carina left or right, or left common PV and AF recurrence at 12 months (Table 2) was observed. No significant difference in AF recurrence was observed between presence and absence of RMPV (17% vs 11%, respectively,  $P = 0.64$ ).

### 3.4 | Cox proportional hazard analysis

Univariate Cox regression (data not shown) showed that BMI (HR = 0.91, 95% confidence interval [CI] = 0.79-1.05), usage of sotalol >160 mg/day (HR = 0.24, 95% CI = 0.03-1.80), LVEF (HR = 0.86, 95% CI = 0.70-1.05) and LAVI (HR = 0.94, 95% CI = 0.86-1.01) were considered for entrance in our multivariable model. After multivariate analysis none were significant. Table 4 shows the Cox regression for the vein diameters, ovality index, shared carina, or morphological

characteristics of which none were considered a significant predictor of AF recurrence.

## 4 | DISCUSSION

In the present study, we explored whether specific characteristics of PV dimension or anatomy could predict outcome of cryoballoon ablation in patients with paroxysmal AF. Neither PV ovality, the presence of anatomical variants (right middle PVs, common ostia), shared carina nor carina width influenced AF recurrence rate at 12 months.

As PVI outcome is difficult to predict because of many confounding factors, we limited our analysis to a homogenous patient population and reproducible ablation procedure, that is, paroxysmal AF patients treated with a 28-mm second-generation cryoballoon. Other studies evaluating the predictive value of PV dimensions and morphology on ablation outcome used both the first- and second-generation balloons, different sizes balloon (23- and 28-mm) and a heterogeneous group of patients (both paroxysmal and/or persistent AF). In concordance with previous studies, we found that 11% of patients had a right middle PV.<sup>8,14</sup> There was no association between the presence of a right middle PV and AF recurrence. This has also been reported in a comparable study (The Sustained Treatment of Paroxysmal Atrial Fibrillation (STOP AF) trial.<sup>15</sup> In this trial, early or late recurrence was not associated with non-standard anatomy following cryoballoon PVI.<sup>15</sup> Another theory is that early branching of the RLPV predicts AF recurrence.<sup>16</sup> Several other studies have assessed PV morphology and success of cryoballoon ablation.<sup>9,11,13</sup> Principle findings were that left-side PV ovality is more often observed than right-sided ovality and that left-sided ovality is associated with more difficult isolation of the vein and more AF recurrence. We observed no

**TABLE 3** Ovality index

		No recurrence (n = 70)	Recurrence (n = 14)	P-value
LSPV ovality	Round	13 (19%)	2 (14%)	0.85
	Oval	22 (32%)	4 (29%)	
	Flat	34 (49%)	8 (57%)	
LIPV ovality	Round	13 (19%)	3 (21%)	0.39
	Oval	22 (32%)	2 (14%)	
	Flat	33 (49%)	9 (64%)	
RSPV ovality	Round	29 (42%)	6 (43%)	0.23
	Oval	22 (32%)	7 (50%)	
	Flat	18 (26%)	1 (7%)	
RIPV ovality	Round	42 (62%)	13 (93%)	0.076
	Oval	21 (31%)	1 (7%)	
	Flat	5 (7%)	0 (0%)	

Abbreviations: LIPV, left inferior pulmonary vein; LSPV, left superior pulmonary vein; RIPV, right inferior pulmonary vein; RSPV, right superior pulmonary vein;

difference for any PV diameter or ovality index. The difference between our study and previous studies was a more heterogeneous patient population including persistent and paroxysmal AF patients or usage of a first-generation cryoballoon. The presently used second-generation balloon has double the amount of cooling ports and the balloon has a more evenly spread cooling zone. We hypothesized that ablation with the first-generation cryoballoon in oval-shaped PVs not all the tissue is affected by the cryoapplication. This potentially may lead to higher recurrence rates. The more powerful second-generation cryoballoon used in this study could explain why PV ovality does not influence cryoballoon ablation success rate anymore. This was also demonstrated in a recent study in patients with

**TABLE 4** Cox regression analysis of pulmonary vein anatomy

	Hazard ratio	95% CI	P-value
Shared carina left	0.88	0.30-2.53	0.810
Shared carina right	0.55	0.17-1.77	0.318
LSPV outer ovality			
Round	1	1	—
Oval	1.84	0.37-9.10	0.457
Flat	1.16	0.23-5.74	0.856
LIPV outer ovality			
Round	1	1	—
Oval	0.69	0.12-4.12	0.682
Flat	1.25	0.27-5.79	0.774
RSPV outer ovality			
Round	1	1	—
Oval	0.93	0.32-2.69	0.89
Flat	—	—	—
RIPV outer ovality			
Round	1	1	—
Oval	—	—	—
Flat	—	—	—

Abbreviations: CI, confidence interval; LIPV, left inferior pulmonary vein; LSPV, left superior pulmonary vein; RIPV = right inferior pulmonary vein; RSPV, right superior pulmonary vein.

a left common PV.<sup>17</sup> In the present study, using a second-generation cryoballoon, these patients had (compared with a control population) similar high acute success rates and comparable durable results.<sup>17</sup>

AF triggers often originate from the right and left PV carina.<sup>18</sup> Through histological and electrophysiological studies, the importance of the carina in PVI was demonstrated.<sup>19-21</sup> Crossing myocardial strands and bridges at the interpulmonary isthmus may be the anatomical substrate for electrical connection between superior and inferior PVs.<sup>20</sup> However, no studies investigated the role of the carina width for predicting cryoballoon ablation success. Cryoapplications at ipsilateral PVs result in multiple (at least 4 if 2 application are given per vein) applications at the carina. In patients with small width carina there is overlap of the cryoapplications. This may have impact on durability of cryolesions and also on recurrence rate. We, however, found no difference in carina width in patients with or without AF recurrence.

#### 4.1 | Limitations

Our study is limited by the limitations inherent to the retrospective study design. Recurrences of AF were monitored by standard outpatient clinic ECG and Holter monitoring, asymptomatic episodes of AF will therefore been missed. Also, all PV diameters have been measured using a manual caliper function. A (semi-)automated caliper function would produce more reliable and consistent results. The most reliable results would have been produced through an algorithm that calculates the exact location where the balloon touches the ostium, based on the pre-procedural CT. Furthermore, we did not account for PVs with early branching.

## 5 | CONCLUSION

No specific characteristics of PV dimensions or morphology were associated with AF recurrence after cryoballoon PVI in patients with paroxysmal AF. Further research on individual parameters associated with the success or failure of PVI is essential.

#### CONFLICTS OF INTEREST

The authors declare no potential conflict of interests.

#### ORCID

Bart A. Mulder  <https://orcid.org/0000-0002-4411-3918>

#### REFERENCES

- Chugh SS, Havmoeller R, Narayanan K, et al. Worldwide epidemiology of atrial fibrillation: a Global Burden of Disease 2010 Study. *Circulation*. 2014;129:837-847.
- Kirchhof P, Benussi S, Kotecha D, et al. Authors/Task Force Members, Document Reviewers: 2016 ESC Guidelines for the management of atrial fibrillation developed in collaboration with EACTS: The Task Force for the management of atrial fibrillation of the European Society of Cardiology (ESC) Developed with the special contribution of the European Heart Rhythm Association (EHRA) of the ESC Endorsed by the European Stroke Organisation (ESO). *Eur Heart J*. 2016;37(38):2893-2962.

3. Kuck KH, Brugada J, Furnkranz A, et al. Cryoballoon or Radiofrequency Ablation for Paroxysmal Atrial Fibrillation. *N Engl J Med*. 2016;374:2235-2245.
4. Packer DL, Kowal RC, Wheelan KR, et al. Cryoballoon ablation of pulmonary veins for paroxysmal atrial fibrillation first results of the North American Arctic Front (STOP AF) pivotal trial. *J Am Coll Cardiol*. 2013;61:1713-1723.
5. Balk EM, Garlitski AC, Alsheikh-Ali AA, Terasawa T, Chung M, Ip S. Predictors of atrial fibrillation recurrence after radiofrequency catheter ablation: a systematic review. *J Cardiovasc Electrophysiol*. 2010;21:1208-1216.
6. Khoueiry Z, Albenque JP, Providencia R, et al. Outcomes after cryoablation vs. radiofrequency in patients with paroxysmal atrial fibrillation: impact of pulmonary veins anatomy. *Europace*. 2016;18:1343-1351.
7. Chun KR, Schmidt B, Metzner A, et al. The 'single big cryoballoon' technique for acute pulmonary vein isolation in patients with paroxysmal atrial fibrillation: a prospective observational single centre study. *Eur Heart J*. 2009;30:699-709.
8. Guler E, Guler GB, Demir GG, et al. Effect of Pulmonary Vein Anatomy and Pulmonary Vein Diameters on Outcome of Cryoballoon Catheter Ablation for Atrial Fibrillation. *Pacing Clin Electrophysiol*. 2015;38:989-996.
9. Schmidt M, Dorwarth U, Straube F, et al. Cryoballoon in AF ablation: impact of PV ovality on AF recurrence. *Int J Cardiol*. 2013;167:114-120.
10. Kato R, Lickfett L, Meininger G, et al. Pulmonary vein anatomy in patients undergoing catheter ablation of atrial fibrillation: lessons learned by use of magnetic resonance imaging. *Circulation*. 2003;107:2004-2010.
11. Ang R, Hunter RJ, Baker V, et al. Pulmonary vein measurements on pre-procedural CT/MR imaging can predict difficult pulmonary vein isolation and phrenic nerve injury during cryoballoon ablation for paroxysmal atrial fibrillation. *Int J Cardiol*. 2015;195:253-258.
12. Schmidt B, Ernst S, Ouyang F, et al. External and endoluminal analysis of left atrial anatomy and the pulmonary veins in three-dimensional reconstructions of magnetic resonance angiography: the full insight from inside. *J Cardiovasc Electrophysiol*. 2006;17:957-964.
13. Sorgente A, Chierchia GB, de Asmundis C, et al. Pulmonary vein ostium shape and orientation as possible predictors of occlusion in patients with drug-refractory paroxysmal atrial fibrillation undergoing cryoballoon ablation. *Europace*. 2011;13:205-212.
14. Kaseno K, Tada H, Koyama K, et al. Prevalence and characterization of pulmonary vein variants in patients with atrial fibrillation determined using 3-dimensional computed tomography. *Am J Cardiol*. 2008;101:1638-1642.
15. Andrade JG, Khairy P, Macle L, et al. Incidence and significance of early recurrences of atrial fibrillation after cryoballoon ablation: insights from the multicenter Sustained Treatment of Paroxysmal Atrial Fibrillation (STOP AF) Trial. *Circ Arrhythm Electrophysiol*. 2014;7:69-75.
16. Knecht S, Kuhne M, Altmann D, et al. Anatomical predictors for acute and mid-term success of cryoballoon ablation of atrial fibrillation using the 28 mm balloon. *J Cardiovasc Electrophysiol*. 2013;24:132-138.
17. Heeger CH, Tscholl V, Wissner E, et al. Acute efficacy, safety, and long-term clinical outcomes using the second-generation cryoballoon for pulmonary vein isolation in patients with a left common pulmonary vein: A multicenter study. *Heart Rhythm*. 2017;14:1111-1118.
18. Valles E, Fan R, Roux JF, et al. Localization of atrial fibrillation triggers in patients undergoing pulmonary vein isolation importance of the carina region. *J Am Coll Cardiol*. 2008;52:1413-1420.
19. Udyavar AR, Chang SL, Tai CT, et al. The important role of pulmonary vein carina ablation as an adjunct to circumferential pulmonary vein isolation. *J Cardiovasc Electrophysiol*. 2008;19:593-598.
20. Cabrera JA, Ho SY, Climent V, Fuertes B, Murillo M, Sanchez-Quintana D. Morphological evidence of muscular connections between contiguous pulmonary venous orifices: relevance of the interpulmonary isthmus for catheter ablation in atrial fibrillation. *Heart Rhythm*. 2009;6:1192-1198.
21. Lin YJ, Tsao HM, Chang SL, et al. The distance between the vein and lesions predicts the requirement of carina ablation in circumferential pulmonary vein isolation. *Europace*. 2011;13:376-382.

**How to cite this article:** Mulder BA, Al-Jazairi MIH, Arends BKO, et al. Pulmonary vein anatomy addressed by computed tomography and relation to success of second-generation cryoballoon ablation in paroxysmal atrial fibrillation. *Clin Cardiol*. 2019;1-6. <https://doi.org/10.1002/clc.23163>