



University of Groningen

The necessity of 4D-motion monitoring for thoracic tumors treated with pencil beam scanning proton therapy

den Otter, Lydia; Anakotta, R.M.; Dieters, Margiet; Muijs, Christina T; Both, Stefan; Langendijk, J.A.; Knopf, Antje

IMPORTANT NOTE: You are advised to consult the publisher's version (publisher's PDF) if you wish to cite from it. Please check the document version below.

Document Version

Publisher's PDF, also known as Version of record

Publication date:

2018

[Link to publication in University of Groningen/UMCG research database](#)

Citation for published version (APA):

den Otter, L., Anakotta, R. M., Dieters, M., Muijs, C. T., Both, S., Langendijk, J. A., & Knopf, A. (2018). The necessity of 4D-motion monitoring for thoracic tumors treated with pencil beam scanning proton therapy: a comprehensive 4D-imaging study. Poster session presented at 57th Particle Therapy Co-Operative Group (PTCOG) meeting, Cincinnati, United States.

Copyright

Other than for strictly personal use, it is not permitted to download or to forward/distribute the text or part of it without the consent of the author(s) and/or copyright holder(s), unless the work is under an open content license (like Creative Commons).

Take-down policy

If you believe that this document breaches copyright please contact us providing details, and we will remove access to the work immediately and investigate your claim.

Downloaded from the University of Groningen/UMCG research database (Pure): <http://www.rug.nl/research/portal>. For technical reasons the number of authors shown on this cover page is limited to 10 maximum.

The necessity of 4D-motion monitoring for thoracic tumors treated with pencil beam scanning proton therapy: a comprehensive 4D-imaging study



L.A. den Otter*, R.M. Anakotta*, M. Dieters*, C.T. Muijs*, N.M. Sijtsema*, S. Both*, J.A. Langendijk*, A.C. Knopf*

*University of Groningen, University Medical Center Groningen, Radiation Oncology, Groningen, The Netherlands

INTRODUCTION

For pencil beam scanning intensity modulated proton therapy (PBS-IMPT) moving targets remain challenging. The time structure of PBS-IMPT makes the treatment of moving tumours challenging due to the interplay effect. Even when using motion mitigation strategies, one needs to be aware of motion variations. Therefore, we investigated weekly and daily inter-fraction motion variations to define the most optimal motion monitoring protocol for PBS-IMPT treatments of non-small-cell lung cancer (NSCLC) patients.

PURPOSE

To define the most optimal motion monitoring protocol for PBS-IMPT treatments of (N)SCLC cancer patients by investigating weekly and daily motion variations.

MATERIALS & METHODS

For 20 (N)SCLC patients (12 male, 8 female, age: 47-89, stage II-IV) 4DCT imaging was performed during pre-treatment simulation (week 0). In addition, weekly 4DCT imaging was performed during the treatment course of five weeks (week 1-5). This is to monitor anatomical changes and differences in motion. Gross tumor volumes (GTVs) were delineated on the maximum inspiration and expiration 4DCT phases. For each weekly delineated GTV, the centroid was calculated and centroid 3D-vector translations were evaluated accordingly.

For one patient, daily 3D-vector centroid 4DCBCT motion was evaluated additionally. This was also done by delineating the GTV on the maximum inspiration and expiration 4DCBCT phases, calculating the centroid positions and evaluating the centroid 3D-vector translations.

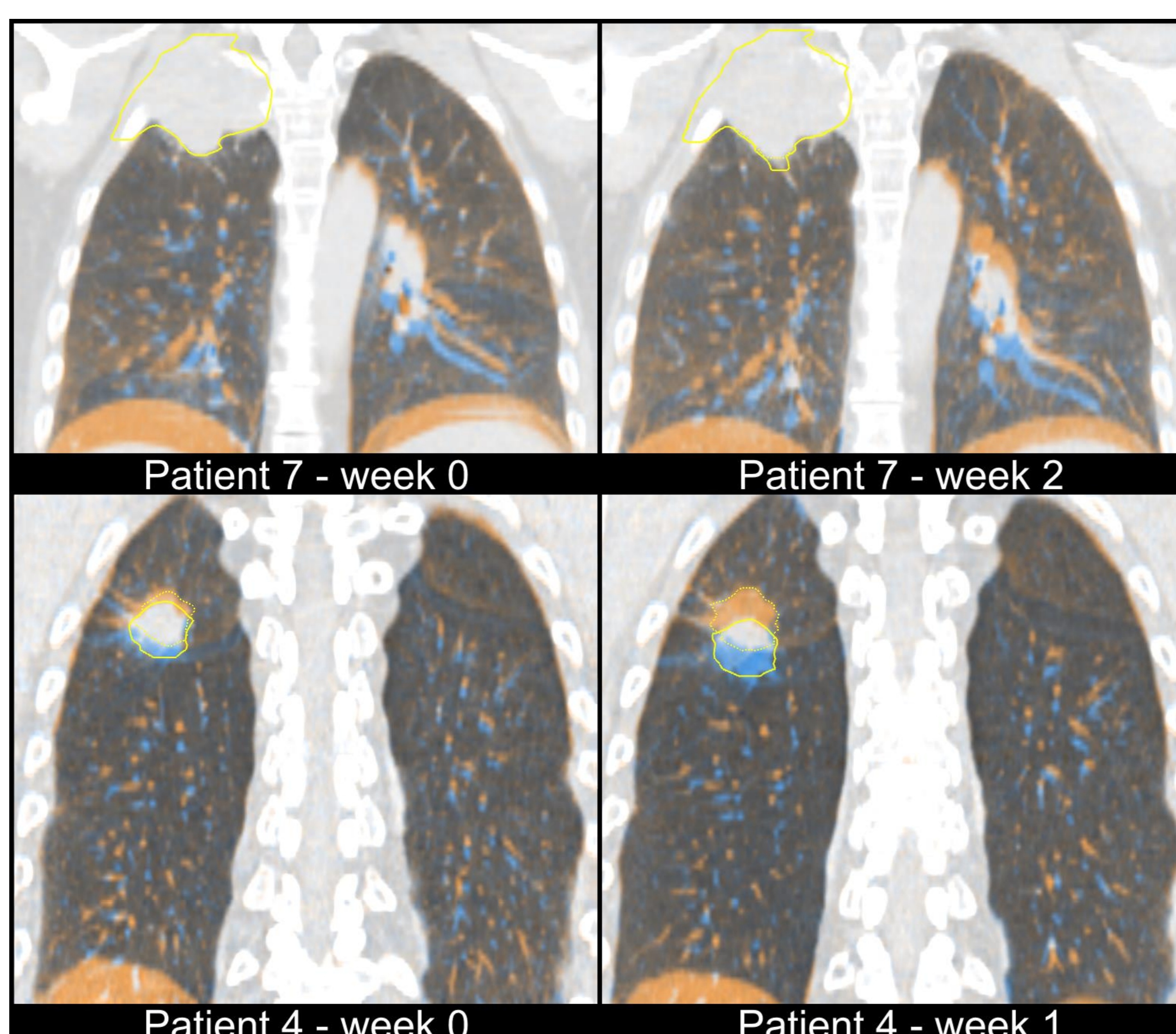


Figure 2: Coronal fusion views of patient's GTVs at maximum inspiration and expiration phases. One patient showed little tumor motion variation and the second patient showed larger motion variation.

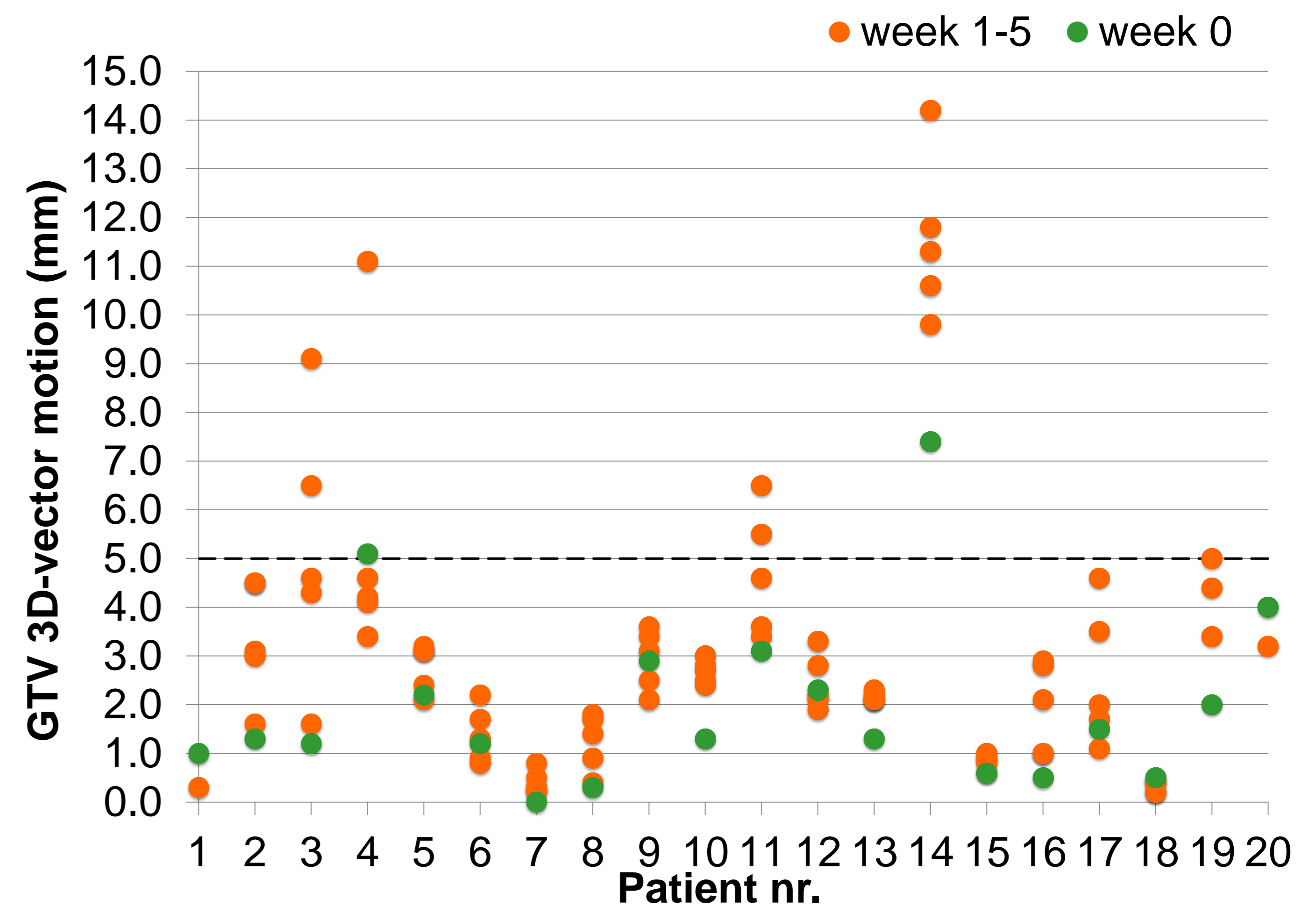


Figure 1: GTV-motion variations for 20 (N)SCLC patients extracted from weekly 4DCTs.

RESULTS

Figure 1 shows the 3D-vector motion amplitudes for the twenty patients. A median initial tumor motion was observed of 1.3 mm (range: 0.0 – 7.4 mm). Four patients showed a motion amplitude beyond 5 mm during the course of treatment. 7 out of 20 patients showed motion variation of more than 3 mm compared to the motion measured in week 0. Figure 2 visualizes two coronal fusion views of patients with smaller and larger motion variation. The median initial GTV volume was 28.7 cm³ (range 1.0 – 430.0 cm³). During treatment GTV volumes of 16 out of 19 patients shrunk with a median decrease of 39% (range: 10.8%- 63.7%), and a median absolute volume change of 8.3 cm³ (range: 0.5-105.9 cm³).

Figure 3 shows that motion amplitudes extracted from weekly 4DCTs were not predictive for motion amplitudes extracted from daily 4DCBCTs for patients number 14. This patient showed larger motion amplitudes with a maximum weekly variation of 6.8 mm. Motion amplitudes measured by 4DCBCTs showed a daily variation up to 11.2 mm.

We are currently extending the presented data for a weekly motion analysis in 40, and a daily motion analysis in 10 lung patient cases.

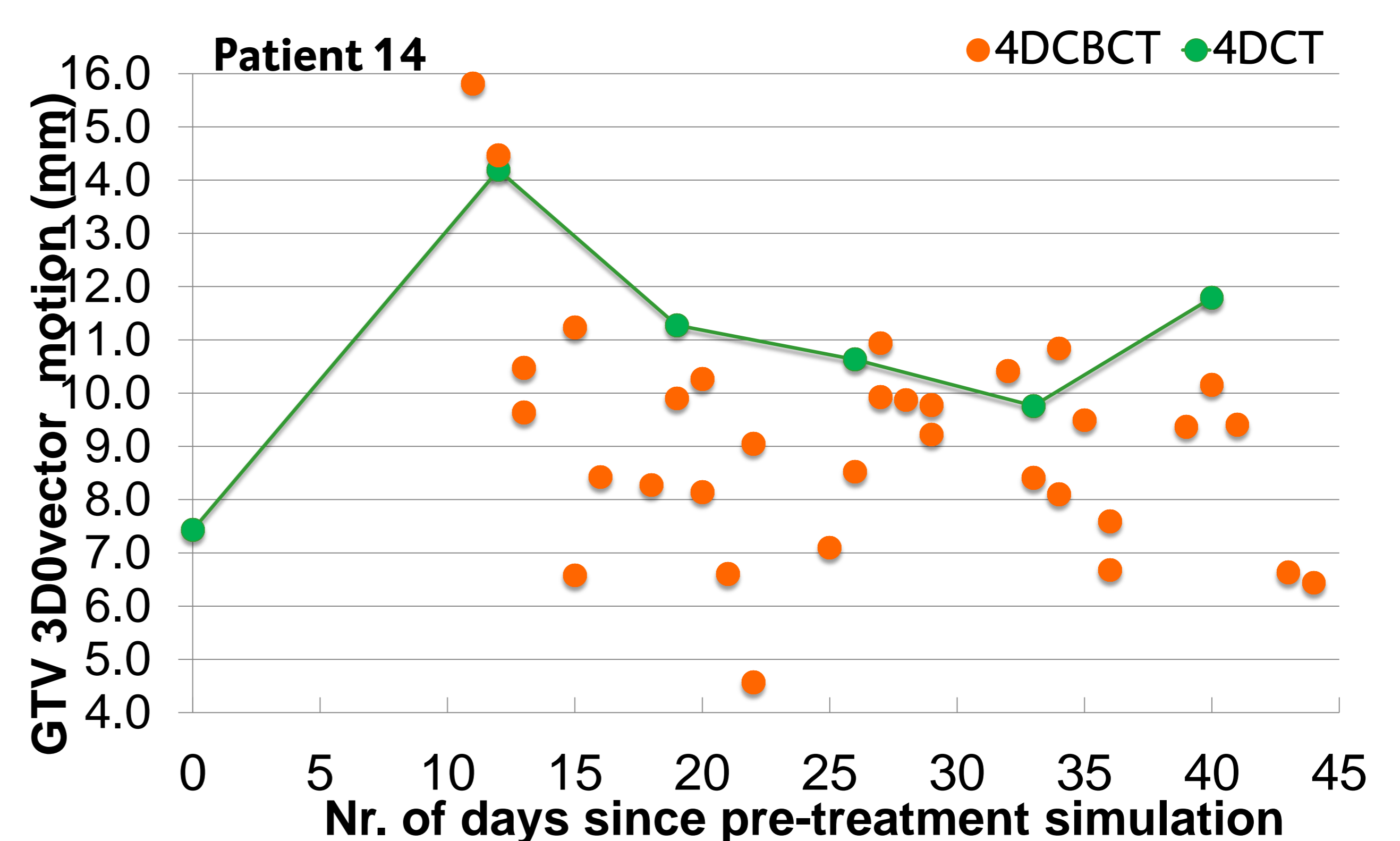


Figure 3: GTV-motion variations for patient 14 extracted from weekly 4DCTs and daily 4DCBCTs.

CONCLUSION

For a considerable part of the patients, the motion measured in week 0 based on weekly repeat 4DCT imaging was not predictive for motion in the following weeks. Daily motion measured by 4DCBCT imaging for one patient suggests that weekly measured 4DCT motion is not predictive for the daily motion in between the weekly 4DCTs. This indicates that breathing motion differs from day to day and daily 4D-imaging is therefore needed to assure safe PBS-PT treatments for lung cancer patients.