



University of Groningen

Primary Sjögren's Syndrome

Delli, Konstantina

IMPORTANT NOTE: You are advised to consult the publisher's version (publisher's PDF) if you wish to cite from it. Please check the document version below.

Document Version

Publisher's PDF, also known as Version of record

Publication date:

2017

[Link to publication in University of Groningen/UMCG research database](#)

Citation for published version (APA):

Delli, K. (2017). Primary Sjögren's Syndrome: towards a new era in diagnosis, treatment and e-patient education. [Groningen]: University of Groningen.

Copyright

Other than for strictly personal use, it is not permitted to download or to forward/distribute the text or part of it without the consent of the author(s) and/or copyright holder(s), unless the work is under an open content license (like Creative Commons).

Take-down policy

If you believe that this document breaches copyright please contact us providing details, and we will remove access to the work immediately and investigate your claim.

Downloaded from the University of Groningen/UMCG research database (Pure): <http://www.rug.nl/research/portal>. For technical reasons the number of authors shown on this cover page is limited to 10 maximum.

Chapter 3F

Salivary gland biopsy for Sjögren's syndrome

Konstantina Delli¹, Arjan Vissink¹, Frederik KL Spijkervet¹

Department of Oral and Maxillofacial Surgery
University of Groningen, University Medical Center Groningen,
Groningen, the Netherlands

Edited version of: Oral Maxillofac Surg Clin North Am.
2014;26:23-33.

Key Points

- Lymphocytic sialadenitis in labial salivary glands is a widely accepted criterion for histological confirmation of Sjögren's syndrome (SS).
- Sensitivity and specificity of parotid and labial biopsies for diagnosing SS are comparable.
- Parotid gland incision biopsy can overcome most of the disadvantages of labial gland excision biopsy.
- In contrast to labial salivary glands, lymphoepithelial lesions and early stage lymphomas can be often observed in parotid gland tissue of SS patients.
- Parotid tissue can be harvested easily, repeated biopsies from the same parotid gland are possible, and histopathological results can be compared with other diagnostic results derived from the same gland.
- Parotid biopsies, in contrast to labial salivary gland biopsies, allow the clinician to prospectively monitor disease progression and to assess effects of intervention treatment at a glandular level.

Introduction

Salivary gland biopsy is a technique broadly applied for the diagnosis of Sjögren's syndrome (SS), lymphoma accompanying SS, sarcoidosis, amyloidosis and other connective tissue disorders. SS has characteristic microscopic findings, involving lymphocytic infiltration surrounding the excretory ducts in combination with destruction of acinar tissue (Figure 1). In affected parotid glands, epimyoeplithelial islands in a background of lymphoid stroma can be additionally seen and lymphoepithelial lesions (LELs) are a common phenomenon (Figure 2).

Biopsy of the labial salivary glands is considered as one of the four objective European- American Consensus Group classification criteria (AECG) and one of the three objective American College of Rheumatology (ACR) classification criteria for SS (Table 1). While the parotid biopsy has been shown as an alternative for labial salivary gland biopsy when applying AECG classification criteria, it has still to be validated in regard to the ACR classification criteria [1].

This chapter will focus on the main techniques used for taking labial and parotid salivary gland biopsies in the diagnostic work-up of SS with respect to their advantages, their post-operative complications, and their usefulness for diagnostic procedures, monitoring disease progression and treatment evaluation.

Figure 1: Lymphocytic infiltration (*) surrounding excretory ducts and destruction of acini.

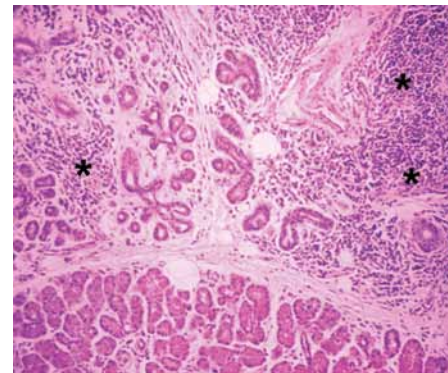


Figure 2: Lymphoepithelial lesions (*) form as the result of atrophy of the columnar ductal epithelium and proliferation of basal epithelial cells, associated with intraepithelial infiltration.

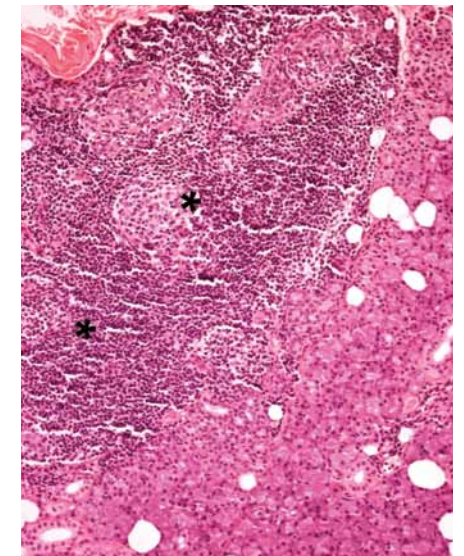


Table 1: Histological criteria for diagnosing SS on salivary gland biopsies [1,18,19].

Type of biopsy	Positivity
Labial gland	if minor salivary glands (obtained through normal appearing mucosa) demonstrate focal lymphocytic sialadenitis, evaluated by an expert histopathologist, with a focus score ≥ 1 , defined as a number of lymphocytic foci (which are adjacent to normal appearing mucous acini and contain more than 50 lymphocytes) per 4 mm ² of glandular tissue
Parotid gland	if one of the two following criteria is fulfilled: <ol style="list-style-type: none"> a focus score of ≥ 1, defined as the number of lymphocytic foci (which are adjacent to normal-appearing acini and contain >50 lymphocytes) per 4 mm² of glandular parotid tissue (including fat tissue), irrespective of the presence of benign LELs small lymphocytic infiltrates, not fulfilling the criterion of a focus score of ≥ 1, in combination with the presence of benign LELs

Labial salivary gland biopsy

Minor salivary glands are widely distributed in the labial, buccal and palatal mucosa of the oral cavity [2]. Since pathognomonic changes are seen in minor salivary glands, the minor salivary gland biopsy is largely used for assisting the diagnosis of SS. Labial salivary glands in particular are easily accessible, lie above the muscle layer and are separated from the oral mucous membrane by a thin layer of fibrous connective tissue. Although the chance of excessive bleeding is minimal, since the arterial supply to the lip lies deep [3], there is a risk of sensible nerve injury, as the branches of the mental nerve in the lower lip are closely associated to the minor salivary glands (Figure 3) [4].

Labial salivary gland biopsies in the diagnosis of SS was introduced by Chisholm and Mason in 1968 and involved oral preparation of the patient with local anesthetic infiltration followed by excising an ellipse of oral mucous membrane down to the muscle layer [5]. The wound was closed with 4-0 gauge silk sutures, which were removed after 4-5 days. Ideally 6 to 8 minor glands must be harvested and sent for histopathologic examination.

Several clinicians have revised this technique (Table 2). Greenspan and colleagues described a 1.5-2 cm linear incision of mucosa, parallel to the vermilion border and lateral to the midline [6]. Marx et al. modified Greenspan's technique with a mucosal excision of 3x0.75 cm [7]. Delgado and Moscuada preferred a longitudinal incision of 1 cm in the labial mucosa in front of the mandibular cuspids [8]. Guevara-Gutierrez and coworkers proposed the punch biopsy technique, performed with a 4 mm punch just penetrating the epithelium of the lower lip [9]. Mahlsted et al. recommended a 1-1.5 cm wedge-shaped excision of mucosa between the midline and commissure [10]. Gorson and Ropper reported a 1 cm vertical incision

just behind the wet line through the mucosa and submucosa [11]. An oblique incision, starting 1.5 cm from the midline and proceeding latero-inferiorly, avoiding the glandular free zone in the center of the lower lip was advocated by Berquin and colleagues [12]. Caporali et al. reported a small incision of 2-3 mm on the inner surface of the lower lip [13]. In view of the lack of sufficient evidence to support the superiority of one technique over the others, especially in respect to short and long term morbidity, the shape and the size of the incision can be considered a matter of preference. Incision shape has included elliptical, horizontal, vertical and wedge shapes, and incision length has varied from a few mm to 2 cm. The authors of the present article, based on their clinical experience, suggest a horizontal incision of approximately 2 cm in agreement with the technique proposed by Greenspan and colleagues [6], where the surgeon uses loupe operation glasses (magnification x2.5) to precisely excise the salivary glands without disturbing the direct underlying sensible nerves (Figure 4).

The first grading system for salivary gland biopsies was employed by Chisholm and Mason in an attempt to standardize the examined area and record the degree of histopathological change [5]. At present, according to the revised AECG classification criteria and the ACR classification criteria for SS, a labial salivary gland biopsy is considered positive if minor salivary glands (obtained through normal appearing mucosa) demonstrate focal lymphocytic sialadenitis, evaluated by an expert histopathologist, with a focus score ≥ 1 , defined as a number of lymphocytic foci, containing more than 50 lymphocytes per 4 mm² of glandular tissue (Table 1).

Complications

The most commonly reported complications of labial gland biopsy are [1,6-8,10,12-17]:

1. Localized sensory alteration, which is frequently described with the terms anesthesia, reduced or partial loss of sensation, transitory numbness and hypoesthesia. The condition may last for a few months or can be even permanent;
2. External haematoma;
3. Local swelling;
4. Formation of granulomas;
5. Internal scarring and cheloid formation;
6. Failing sutures;
7. Local pain.

Suitability for diagnostic and treatment evaluation purposes

A widely accepted criterion for histological confirmation of SS is focal lymphocytic sialadenitis in labial salivary glands [18,19]. Labial biopsies are mainly well suited for the diagnostic work-up, but not for treatment and disease activity evaluation [20],

Figure 3: The branch of the mental nerve (*) that supplies the mucous membrane of the lower lip divides usually into two sub-branches: a horizontal and a vertical, which has an ascending course toward the vermillion border and is in close relation to the labial salivary glands (**).

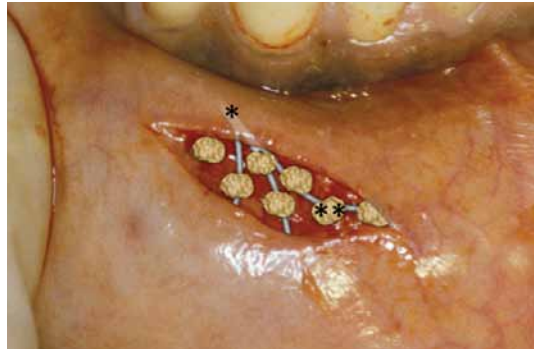
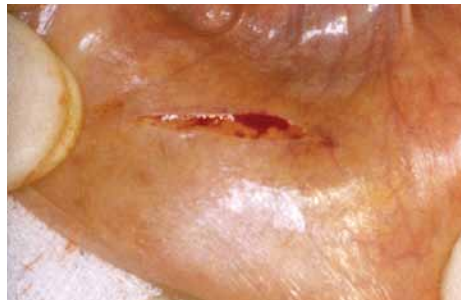
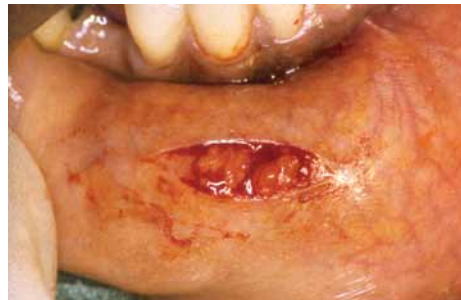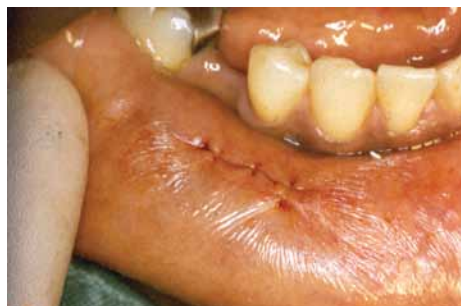Figure 4: Harvesting labial salivary glands.



A. Horizontal incision of approximately 1.5 cm.



B. Harvest of 6-8 minor salivary glands.



C. Closure of the wound with 5-0 Vicryl rapide® (resorbable) inverted buried notch sutures.

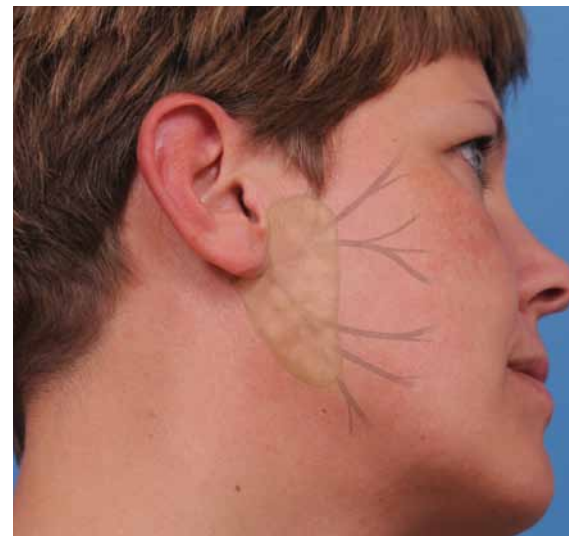although very rare, B-cell MALT lymphomas can be found in labial biopsies of SS patients [21,22].

Parotid gland biopsy

The parotid gland is the largest salivary gland and is positioned on the lateral aspect of the face overlying the posterior surface of the mandible and antero-inferiorly to the auricle [23]. Traditionally, the gland is divided into a superficial and deep lobe based on the course of the facial nerve as it passes through. When the facial nerve enters the parotid gland, it forms a characteristic branching pattern that resembles a goose foot and is known as 'the pes anserinus', giving two main divisions of the facial nerve (Figure 5). Surgically, the facial nerve can be located in approximately 2-4 mm deep to the inferior end of the tympanomastoid suture line and 1 cm deep and slightly antero-inferior to the tragal pointer.

The technique of the parotid gland biopsy was initially described by Kraaijenhagen [24]: the area is anesthetized with local infiltration anesthesia after the standard preparation. With a No 15 blade, a small 1-2 cm incision is made just below the earlobe near the posterior angle of the mandible. The skin is incised and the pa-

Figure 5: The facial nerve enters the parotid gland forming a characteristic branching pattern that resembles a goose foot and is known as the pes anserinus, giving two main divisions of the facial nerve. The parotid gland is divided into a superficial and deep lobe based on the course of the facial nerve as it passes through. In the area of the incisional biopsy of the parotid gland, the distance between the gland surface and the facial nerve is approximately 1.5 cm.



rotid capsule is exposed by blunt dissection. The capsule of the gland is carefully opened and a small amount of superficial parotid tissue is removed. The procedure is completed with a 2 to 3-layered closure. The capsule must be cautiously closed to avoid future leakage or development of sialoceles (Figure 6).

The technique was slightly modified by the present authors with an incision below and slightly behind the earlobe (Figure 7). The capsule of the parotid gland and subcutaneous tissue is closed with 4-0 Vicryl® sutures, whereas the skin is closed with 5-0 Ethilon® sutures. In this way, aesthetic results are excellent and future scar is invisible to the eye from anterior/lateral point of view.

Pijpe and coworkers established a new set of validated histopathological criteria for diagnosing SS according to the AECG classification criteria based on biopsy of the parotid gland (Table 1) [1]. A parotid biopsy was considered positive if one of the two following criteria was fulfilled:

- i. a focus score of ≥ 1 , defined as the number of lymphocytic foci (which are adjacent to normal-appearing acini and contain >50 lymphocytes) per 4 mm^2 of glandular parotid tissue (including fat tissue), irrespective of the presence of benign LELs.
- ii. small lymphocytic infiltrates, not fulfilling the criterion of a focus score of ≥ 1 , in combination with the presence of benign LELs.

Complications

Despite the potential risk of facial nerve damage, the development of sialoceles and salivary fistulae, temporary change in sensation in the skin area of the incision is the only well documented complication described to date [1,7].

Suitability for diagnostic and treatment evaluation purposes

Parotid biopsies allow the clinician to monitor disease progression and to assess the effect of an intervention treatment in SS. This is feasible due to the fact that parotid tissue can be harvested easily, repeated biopsies from the same parotid gland are possible, and the histopathological results can be compared with other diagnostic results derived from the same gland (e.g. secretory function, sialographic appearance, and ultrasound) [25]. Additionally, by performing parotid biopsies as a routine diagnostic procedure for SS, LELs and lymphomas located in the parotid gland can be identified [7,26].

Sublingual salivary gland biopsy

The sublingual salivary gland is the smallest of the major salivary glands. It lies in the floor of the mouth on both sides of the tongue and is covered only by oral mu-

cosa. There are a few reports about taking a biopsy of the sublingual salivary gland for the diagnosis of SS [12,27,28]. The technique is performed with an 1 cm linear mucosal incision in the floor of the mouth, 1 cm anterolaterally from Wharton's duct to 1 cm antero-posteriorly [12,28,28].

Complications

The post-operative complications of sublingual salivary gland biopsy are [12,27]:

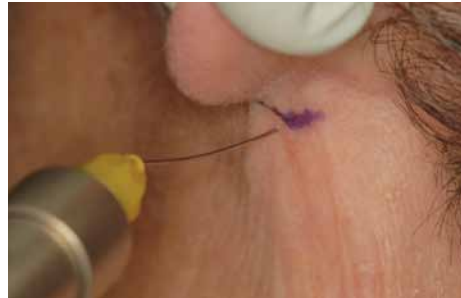
1. Ligaturing Wharton's duct, resulting from the placement of sutures;
2. Bleeding;
3. Swelling in the floor of the mouth.

Comparison of techniques (Table 2)

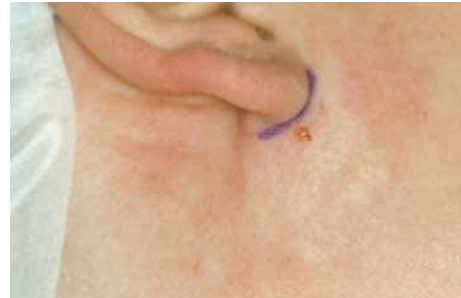Although focal lymphocytic sialadenitis in the labial salivary gland is a widely accepted criterion for histological confirmation of SS, biopsies of the labial salivary glands may have several disadvantages. The sensitivity and specificity of labial salivary gland biopsies vary in the literature. Data from different studies are often difficult to compare because different sets of criteria for diagnosing SS have been used and the outcome of the labial biopsy is a strong determinant for the final diagnosis. In a normal population, the labial biopsy resulted in 6–9% false-positive diagnoses, and 18–40% of the patients with a clinical diagnosis of SS have a negative labial biopsy, resulting in a sensitivity of 60–82% and a specificity of 91–94% (Table 3) [14,29–33]. According to the ACR classification criteria, the labial biopsy has a sensitivity of 89.8 (95% CI: 87.2–92.0), but a lower specificity of 74.3 (95% CI: 71.0–77.5) [19]. Moreover, it may be difficult to harvest a sufficient number of labial salivary glands in atrophic submucosa of patients with longstanding SS [30]. In addition, permanent sensory loss of the mucosa of the lower lip, occurring in 1–10% of the patients, is a known complication of a labial biopsy [7,14,15]. Pijpe and coworkers report sensory loss in 6% of patients after labial biopsy, while no permanent sensory loss was observed after parotid biopsy [1].

Incisional biopsy of the parotid gland can overcome most of the disadvantages of the labial biopsy. When evaluating the parotid and the labial biopsy, sensitivity and specificity are comparable (Table 3), estimated in 78% and 86% respectively [1]. Parotid gland tissue can be harvested easily, repeated biopsies from the same parotid gland are possible (an important asset in studies assessing the efficacy of a treatment in SS patients or monitoring disease progression), and the histopathological results can be compared with other diagnostic results derived from the same gland (secretory function, sialographic appearance, ultrasound). In contrast to labial salivary glands, LELs are often observed in parotid gland tissue of SS patients. These LELs, a characteristic histological feature of the major salivary glands

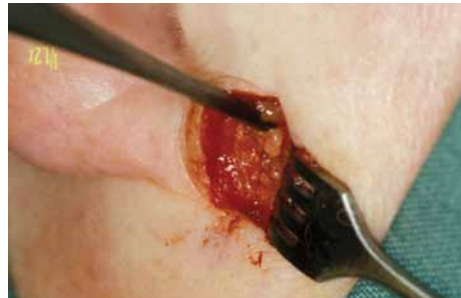
Figure 6: Incisional biopsy of the parotid gland.



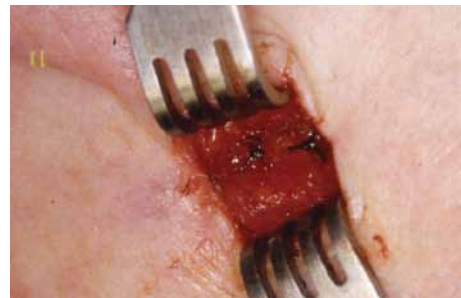A. The area is anesthetized with local infiltration anesthesia.



B. With a No 15 blade a small 1-2 cm incision is made just below and behind the earlobe near the posterior angle of the mandible.



C. The skin is incised and the parotid capsule is exposed by blunt dissection. The capsule of the gland is carefully opened and a small amount of superficial parotid tissue is removed.

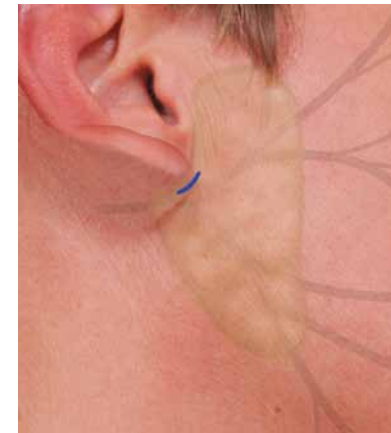


D. The procedure is completed with a 2 to 3-layered closure with 4-0 gauge absorbable sutures (polyglycolic acid), while the skin layer is closed with 5-0 nylon sutures.

in SS [33], develop as a result of hyperplasia of ductal basal cells within a lymphocytic infiltrate. In addition, well-formed lymphoid follicles or germinal centers, often adjacent to ductal epithelium, can be found in the major salivary glands [34]. Since both LELs and reactive lymphoid follicles are also indicative of malignant lymphoma, benign LELs must be discriminated from (pre)malignant lesions, using strict criteria [35,36].

Four to seven per cent of patients with SS develop malignant B cell lymphoma [37, 38], 48%–75% of which are of the MALT-type. These B cell lymphomas are most frequently located in the parotid gland [39,40,41]. Assessment of SS patients who may have developed a MALT lymphoma is not always easy, but an incisional biopsy of the parotid gland can safely be performed under local anesthesia [4] and can help towards this diagnosis. Pollard and coworkers have established an algorithm

Figure 7: The technique of the biopsy of the parotid gland was slightly modified by the present authors with an incision below and slightly behind the earlobe.



for the management of MALT-type lymphoma of parotid gland and associated SS (MALT-SS), showing the importance of a parotid gland biopsy for controlling the disease [26].

Additionally, in pediatric patients with clinical suspicion of SS and a negative minor salivary gland biopsy result, a parotid gland biopsy could be safe and effective in order to establish histopathologic evidence for the diagnosis of SS [43].

Finally, it is noteworthy that the pain following labial and parotid biopsies is comparable in severity and disappears within 1 month [1].

Notwithstanding these aforementioned advantages, biopsies of the parotid gland have not become commonplace because of the concern for damage to the facial nerve, development of sialoceles and salivary fistulae (Table 2). In addition, parotid gland biopsies are not part of the established criteria for diagnosing SS and demand higher surgical expertise. They are validated for the AECG classification criteria, but not yet for the ACR classification criteria.

Comparison of sublingual gland biopsy to labial gland biopsy has shown that the sensitivity of sublingual gland biopsy is better than the one of the labial gland biopsy, while the specificity of the latter is better than that of the former (Table 3) [27]. As far as the post-operative complications are concerned, researchers claim that sublingual gland biopsy is a relatively safe procedure (Table 2). Owing the fact that placing a suture might increase the risk of ligaturing Wharton's duct and lead to swelling of the floor of the mouth, no suture [28] or careful placement of one to two sutures could be an alternative [29]. A damage to the mental nerve is obviously not feasible, because of the operation site, while a damage to the lingual nerve related to this biopsy technique has never been reported in the literature. Advanced risk

Table 2: Comparison of techniques [5-13,24,27,28,42].

	Technique	Advantages	Complications
Labial gland			
Chisholm and Mason, 1968	Ellipse of oral mucous membrane down to the muscle layer. Harvest of 6-8 glands. Wound closure with 4-0 gauge silk sutures, which must be removed after four-five days.	1. Widely distributed glands 2. Easily accessible glands 3. Minimal chance of bleeding	1. Temporary or permanent alteration in sensation in the area of the incision 2. External haematoma 3. Local swelling 4. Granulomas formation 5. Internal scarring and cheloid formation 6. Suture failing 7. Local pain
Greenspan et al., 1975	1.5-2 cm linear incision of mucosa, parallel to the vermillion border and lateral to the midline		
Marx et al., 1988	Mucosal incision of 3x0.75 cm		
Delgado and Moscuada, 1989	Longitudinal incision of 1 cm in the labial mucosa in front of the mandibular cuspids		
Guevara-Gutierrez et al., 2001	Punch biopsy		
Mahlisted et al., 2002	1-1.5 cm wedge-shaped incision between the midline and commissure		
Gorson and Ropper, 2003	1 cm vertical incision just behind the wet line through the mucosa and submucosa		
Berquin et al., 2006	Oblique incision, starting 1.5 cm from the midline and proceeding latero-inferiorly, avoiding the glandular free zone in the center of the lower lip		
Caporali et al., 2008	Small incision of 2-3 mm on the inner surface of the lower lip		
Parotid gland			
Kraaijenhagen 1975	1-2 cm incision just below and behind the earlobe near the posterior angle of the mandible.	1. Presence of LELs	1. Temporary alteration in sensation in the area of the incision
Marx et al., 1988	The skin is incised and the parotid capsule is exposed by blunt dissection. The capsule of the gland is opened and adequate amount of superficial parotid tissue is removed. The procedure is completed with a 2 to 3-layered closure	2. Identification of MALT 3. Possibility of repeated biopsy from the same gland 4. Comparison with other diagnostic results derived from the same gland (e.g. secretory function, sialographic appearance)	2. Facial nerve damage 3. Sialoceles 4. Salivary fistulae 5. Risk of harvesting only fat tissue 6. Demanding surgical expertise
Mc Guirt et al., 2002			
Baurmash et al., 2005			
Pijpe et al., 2007			
Sublingual salivary gland			
Pennec et al., 1990	Incision between the first premolar and the lateral cutting tooth	Collection of sufficient amount of tissue	1. Uncomfortable scars 2. Bleeding 3. Swelling in the floor of the mouth 4. Risk of ligaturing Wharton's duct 5. Not established histopathologic criteria
Adam et al., 1992	Mucosal incision 1 cm anterolaterally from the Whartonian duct to 1 cm anteroposteriorly.		
Berquin et al., 2006	Blunt dissection and harvest of 0.5 ml of gland. The wound edges are joined with 1-2 resorbable stiches		

Table 3: Sensitivity and specificity of biopsy techniques [1,27].

Technique	Sensitivity	Specificity
Labial gland biopsy	60-82%	91-94%
Parotid gland biopsy	78%	86%
Sublingual gland biopsy	66%	52%

of bleeding is encountered in cases a more posterior incision is made, which, however, resolves spontaneously [12]. To date, specialized histopathological criteria have not been established for the diagnosis of SS after a sublingual gland biopsy and researchers merely employed the criteria for labial gland biopsies [12,27,29].

Conclusion

Early diagnosis and treatment are of high importance for preventing the complications associated with SS. Unfortunately, so far there is not a single test capable of confirming the diagnosis of SS. A positive salivary gland biopsy provides strong evidence, which in correlation with additional diagnostic tests can establish the classification of SS. Parotid gland biopsy is a relatively simple technique, has the potential to overcome most of the disadvantages of the labial biopsy and can additionally aid in monitoring disease progression and the effect of an intervention treatment in SS.

References

- Pijpe J, Kalk WW, van der Wal JE et al. Parotid gland biopsy compared with labial biopsy in the diagnosis of patients with primary Sjögren's syndrome. *Rheumatology* 2007;46:335-41.
- Geerling G, Raus P. Minor salivary gland transplantation. *Dev Ophthalmol* 2008;41:243-54.
- Meskin LH, Bernard B, Warwick WJ. Biopsy of the labial mucous salivary glands in cystic fibrosis. *JAMA* 1964;188:82-3.
- Alsaad K, Lee TC, McCartan B. An anatomical study of the cutaneous branches of the mental nerve. *Int J Oral Maxillofac Surg* 2003;32:325-33.
- Chisholm DM, Mason DK. Labial salivary gland biopsy in Sjögren's disease. *J Clin Pathol* 1968;21:656-60.
- Greenspan JS, Daniels TE, Talal N, et al. The histopathology of Sjögren's syndrome in labial salivary gland biopsies. *Oral Surg Oral Med Oral Pathol* 1974;37:217-29.
- Marx RE, Hartman KS, Rethman KV. A prospective study comparing incisional labial to incisional parotid biopsies in the detection and confirmation of sarcoidosis, Sjögren's disease, sialosis and lymphoma. *J Rheumatol* 1988;15:621-9.
- Delgado WA, Mosqueda A. A highly sensitive method for diagnosis of secondary amyloidosis by labial salivary gland biopsy. *J Oral Pathol Med* 1989 May;18:310-4.
- Guevara-Gutierrez E, Tlacuilo-Parra A, Minjares-Padilla LM. Minor salivary gland punch biopsy for evaluation of Sjögren's syndrome. *J Clin Rheumatol* 2001;7:401-2.
- Mahlsted K, Ussmüller J, Donath K. Value of minor salivary gland biopsy in diagnosing Sjögren's syndrome. *J Otolaryngol* 2002;31:299-303.
- Gorson KC, Ropper AH. Positive salivary gland biopsy, Sjögren syndrome, and neuropathy: clinical implications. *Muscle Nerve* 2003;28:553-60.
- Berquin K, Mahy P, Weyand B, et al. Accessory or sublingual salivary gland biopsy to assess systemic disease: a comparative retrospective study. *Eur Arch Otorhinolaryngol* 2006;263:233-36.
- Caporali R, Bonacci E, Epis O, et al. Comment on: parotid gland biopsy compared with labial biopsy in the diagnosis of patients with primary Sjögren's syndrome [author reply]. *Rheumatology* 2007;46:1625.
- Daniels TE. Labial salivary gland biopsy in Sjögren's syndrome. Assessment as a diagnostic criterion in 362 suspected cases. *Arthritis Rheum* 1984;27:147-56.
- Richards A, Mutlu S, Scully C, et al. Complications associated with labial salivary gland biopsy in the investigation of connective tissue disorders. *Ann Rheum Dis* 1992;51:996-97.
- Friedman H, Kilmar V, Galletta VP, et al. Lip biopsy in connective tissue diseases. A review and study of seventy cases. *Oral Surg Oral Med Oral Pathol* 1979;47:256-62.
- Teppo H, Revonta M. A follow-up study of minimally invasive lip biopsy in the diagnosis of Sjögren's syndrome. *Clin Rheumatol* 2007;26:1099-103.
- Vitali C, Bombardieri S, Jonsson R, et al. Classification criteria for Sjögren's syndrome: a revised version of the European criteria proposed by the American-European Consensus Group. *Ann Rheum Dis* 2002;61:554-8.
- Shiboski SC, Shiboski CH, Criswell L, et al.; Sjögren's International Collaborative Clinical Alliance (SICCA) Research Groups. American College of Rheumatology classification criteria for Sjögren's syndrome: a data-driven, expert consensus approach in the Sjögren's International Collaborative Clinical Alliance cohort. *Arthritis Care Res (Hoboken)*. 2012;64:475-87.

20. Vissink A, Bootsma H, Kroese FG, Kallenberg CG. How to assess treatment efficacy in Sjögren's syndrome? *Curr Opin Rheumatol* 2012;24:281-9.
21. Van Mello NM, Pillemer SR, Tak PP, et al. B cell MALT lymphoma diagnosed by labial minor salivary gland biopsy in patients screened for Sjögren's syndrome. *Ann Rheum Dis* 2005;64:471-473.
22. Theander E, Vasaitis L, Baecklund E, et al. Lymphoid organisation in labial salivary gland biopsies is a possible predictor for the development of malignant lymphoma in primary Sjögren's syndrome. *Ann Rheum Dis* 2011;70:1363-1368.
23. Witt RL. Salivary gland anatomy. In: *Salivary gland diseases. Surgical and medical management*. New York: Thieme Medical Publishers; 2005. p 1-7.
24. Kraaijenhagen HA. Letter: Technique for parotid biopsy. *J Oral Surg* 1975;33:328.
25. Pijpe J, Meijer JM, Bootsma H, et al. Clinical and histologic evidence of salivary gland restoration supports the efficacy of rituximab treatment in Sjögren's syndrome. *Arthritis Rheum* 2009;60:3251-56.
26. Pollard RP, Pijpe J, Bootsma H, et al. Treatment of mucosa-associated lymphoid tissue lymphoma in Sjögren's syndrome: a retrospective clinical study. *J Rheumatol* 2011;38:2198-208.
27. Pennec YL, Leroy JP, Jouquan J, et al. Comparison of labial and sublingual salivary gland biopsies in the diagnosis of Sjögren's syndrome. *Ann Rheum Dis* 1990;49:37-9.
28. Adam P, Haroun A, Billet J, et al. Biopsy of the salivary glands. The importance and technique of biopsy of the sublingual gland on its antero-lateral side. *Rev Stomatol Chir Maxillofac* 1992;93:337-40.
29. Lindahl G, Hedfors E. Focal lymphocytic infiltrates of salivary glands are not confined to Sjögren's syndrome. *Scand J Rheumatol Suppl* 1986;61:52-5.
30. Vitali C, Tavoni A, Simi U et al. Parotid sialography and minor salivary gland biopsy in the diagnosis of Sjögren's syndrome. A comparative study of 84 patients. *J Rheumatol* 1988;15:262-67.
31. De Wilde PC, Kater L, Baak JP, et al. A new and highly sensitive immunohistologic diagnostic criterion for Sjögren's syndrome. *Arthritis Rheum* 1989;32:1214-20.
32. Vitali C, Moutsopoulos HM, Bombardieri S. The European Community Study Group on diagnostic criteria for Sjögren's syndrome. Sensitivity and specificity of tests for ocular and oral involvement in Sjögren's syndrome. *Ann Rheum Dis* 1994;53:637-47.
33. Ihrler S, Zietz C, Sendelhofert A, et al. Lymphoepithelial duct lesions in Sjögren-type sialadenitis. *Virchows Arch* 1999;434:315-23.
34. Jordan RC, Speight PM. Lymphoma in Sjögren's syndrome. From histopathology to molecular pathology. *Oral Surg Oral Med Oral Pathol Oral Radiol Endod* 1996;81:308-20.
35. Quintana PG, Kapadia SB, Bahler DW, et al. Salivary gland lymphoid infiltrates associated with lymphoepithelial lesions: a clinicopathologic, immunophenotypic, and genotypic study. *Hum Pathol* 1997;28:850-61.
36. De Vita S, De Marchi G, Sacco S, et al. Preliminary classification of nonmalignant B cell proliferation in Sjögren's syndrome: perspectives on pathobiology and treatment based on an integrated clinico-pathologic and molecular study approach. *Blood Cells Mol Dis* 2001;27:757-66.
37. Sutcliffe N, Inanc M, Speight P, et al. Predictors of lymphoma development in primary Sjögren's syndrome. *Semin Arthritis Rheum* 1998;28:80-7.
38. Theander E, Henriksson G, Ljungberg O, et al. Lymphoma and other malignancies in primary Sjögren's syndrome: a cohort study on cancer incidence and lymphoma predictors. *Ann Rheum Dis* 2006;65:796-803.
39. Kassin SS, Thomas TL, Moutsopoulos HM, et al. Increased risk of lymphoma in sicca syndrome. *Ann Intern Med* 1978;89:888-92.
40. Tzioufas AG, Boumba DS, Skopouli FN, et al. Mixed monoclonal cryoglobulinemia and monoclonal rheumatoid factor cross-reactive idiotypes as predictive factors for the development of lymphoma in primary Sjögren's syndrome. *Arthritis Rheum* 1996;39:767-72.
41. Voulgarelis M, Dafni UG, Isenberg DA, et al. Malignant lymphoma in primary Sjögren's syndrome: a multicenter, retrospective, clinical study by the European Concerted Action on Sjögren's syndrome. *Arthritis Rheum* 1999;42:1765-72.
42. McGuirt WF Jr, Whang C, Moreland W. The role of parotid biopsy in the diagnosis of pediatric Sjögren syndrome. *Arch Otolaryngol Head Neck Surg* 2002;128:1279-81.
43. Radfar L, Kleiner DE, Fox PC, et al. Prevalence and clinical significance of lymphocytic foci in minor salivary glands of healthy volunteers. *Arthritis Rheum* 2002;47:520-4.

Chapter 4

Treatment

