

University of Groningen

## Development of poly(trimethylene carbonate) based implant devices and their application in oral and maxillofacial surgery

Leeuwen, Anne Cornelis van

**IMPORTANT NOTE: You are advised to consult the publisher's version (publisher's PDF) if you wish to cite from it. Please check the document version below.**

*Document Version*

Publisher's PDF, also known as Version of record

*Publication date:*

2012

[Link to publication in University of Groningen/UMCG research database](#)

*Citation for published version (APA):*

Leeuwen, A. C. V. (2012). Development of poly(trimethylene carbonate) based implant devices and their application in oral and maxillofacial surgery. Groningen: s.n.

### **Copyright**

Other than for strictly personal use, it is not permitted to download or to forward/distribute the text or part of it without the consent of the author(s) and/or copyright holder(s), unless the work is under an open content license (like Creative Commons).

### **Take-down policy**

If you believe that this document breaches copyright please contact us providing details, and we will remove access to the work immediately and investigate your claim.

*Downloaded from the University of Groningen/UMCG research database (Pure): <http://www.rug.nl/research/portal>. For technical reasons the number of authors shown on this cover page is limited to 10 maximum.*

# Development of Poly(trimethylene carbonate) based Implant Devices and their Application in Oral and Maxillofacial Surgery

soluble solutions

Anne C. van Leeuwen



© A.C. van Leeuwen, 2012

All rights reserved.

No part of this publication may be reported or transmitted, in any form or by any means, without permission of the author.

Design by: [www.fototh.nl](http://www.fototh.nl) and [www.sgaar.nl](http://www.sgaar.nl)

Printed by: Drukkerij van der Eems, Heerenveen

ISBN: 978-90-367-5664-8

RIJKSUNIVERSITEIT GRONINGEN

Development of Poly(trimethylene carbonate) based  
Implant Devices and their Application in Oral and  
Maxillofacial Surgery

soluble solutions

**Proefschrift**

ter verkrijging van het doctoraat in de  
Medische Wetenschappen  
aan de Rijksuniversiteit Groningen  
op gezag van de  
Rector Magnificus, dr. E. Sterken,  
in het openbaar te verdedigen op  
woensdag 17 oktober 2012  
om 16.15 uur

door

Anne Cornelis van Leeuwen  
geboren op 13 december 1977  
te Leeuwarden

Promotores: Prof. dr. R.R.M. Bos  
Prof. dr. D.W. Grijpma

Copromotor: Dr. T.G. van Kooten

Beoordelingscommissie: Prof. dr. J.A. Loontjes  
Prof. dr. J.P.R. van Merkesteyn  
Prof. dr. M.P. Mourits

Paranimfen:

Michiel Doff

Wieger van Leeuwen

# Contents


<b>Chapter 1</b>	9
Introduction and aims of the thesis	
<b>Chapter 2</b>	21
Guided bone regeneration in rat mandibular defects using resorbable poly(trimethylene carbonate) barrier membranes	
AC van Leeuwen, JJR Huddleston Slater, PFM Gielkens, JR de Jong, DW Grijpma, RRM Bos Published in: Acta Biomater. 2012 Apr;8(4):422-9.	
<b>Chapter 3</b>	39
In vivo behaviour of a biodegradable poly(trimethylene carbonate) barrier membrane: a histological study in rats	
AC van Leeuwen, TG van Kooten, DW Grijpma, RRM Bos Published in: J Mater Sci Mater Med. 2012 Aug;23(8):1951-9.	
<b>Chapter 4</b>	55
Reconstruction of orbital wall defects: recommendations based on a mathematical model	
AC van Leeuwen, SH Ong, A Vissink, DW Grijpma, RRM Bos Published in: Exp Eye Res. 2012 Apr;97(1):10-8.	
<b>Chapter 5</b>	75
Composite materials based on poly(trimethylene carbonate) and $\beta$ -tricalcium phosphate for orbital floor reconstruction	
AC van Leeuwen, RRM Bos, DW Grijpma Published in: J Biomed Mater Res B Appl Biomater. 2012 Aug;100(6):1610-20.	
<b>Chapter 6</b>	93
Poly(trimethylene carbonate) and biphasic calcium phosphate composites for orbital floor reconstruction: a feasibility study in sheep	
AC van Leeuwen, H Yuan, C Passanisi, WJ van der Meer, JD de Bruijn, TG van Kooten, DW Grijpma, RRM Bos Submitted	

<b>Chapter 7</b>	119
Summary and general discussion	
<b>Chapter 8</b>	129
Dutch summary	
<b>Chapter 9</b>	135
Frisian summary/Gearfetting	
<b>Dankwoord</b>	141





# Introduction and aims of the thesis



*"A biomaterial is a (nonviable) material used in a (medical) device, intended to interact with biological systems." (Williams, 1987)*



## HISTORY IN A NUTSHELL

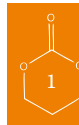
Incorporation of non-biological materials into the human body is known since ancient history <sup>1</sup>. In 1996 a skeleton was found at the banks of the Columbia River near Kennewick (Washington, USA). The remains were studied by archeologist James Chatter. Radiocarbon-dating dated the “Kennewick Man” back to approximately 9000 BC. Meticulous observations showed that bone had partially grown around a 79 mm stone projectile lodged in the Ilium, part of the pelvic bone. Further analysis revealed that the projectile was made from a siliceous gray stone that was found to have igneous origins. The projectile was leaf-shaped, long, broad and had serrated edges, all fitting the definition of the point of a spear. Apparently, the wound had healed with the spear point in place and probably this foreign body had not significantly impeded the man’s activity.

Although the spear point bears little resemblance to modern day biomaterials, this ancient example does illustrate the body’s capacity to tolerate foreign materials, and somehow could be considered one of the first incorporated implants. A few millennia later, materials, unlike the spear point, were devised as implants for intentional use. At the end of the twentieth century during archeological excavations in France, archeologists stumbled upon a Gallo-Roman skeleton dated 200 AD that had an iron dental implant which was described as “properly integrated into the bone” by Cruzeby et al. <sup>2</sup>. This iron dental implant is typical for the new era in which humans had started to search for implants that could be used to replace missing body parts. The following centuries (even until today) humans kept developing and applying biomaterials to replace lost body parts.

In the past, the developed and applied implants mainly consisted of metals and their derivative alloys, however, natural materials like ivory were also used <sup>3</sup>. It was not until the twentieth century, that polymers made their entry in the medical field for use as biomaterial in reconstructive surgery. After World War II, developments expanded enormously. Polymeric materials developed for war activities were discovered by medical specialists, mainly surgeons, who now started to use the “off the shelf” materials for medical purposes. Around the 1950s papers emerged regarding the use of a variety of polymeric plastics. Well-known examples are polyethylene, polytetrafluoroethylene and silicone rubber, polymers which are still in use as biomaterials today.

In the following decade, the increasing use of biomaterials led to a number of pioneering discoveries, including the ‘understanding of healing’, the discovery of the ‘foreign body reaction’ and the realization that biomaterials could assist in the regeneration of lost tissues <sup>1</sup>.

In the early 1960s and 1970s the focus shifted from non-degradable polymers towards biodegradable polymeric materials. Whereas the non-biodegradable polymers were still part of the search for implants that could be used to replace missing body parts, biodegradable polymeric materials seemed attractive alternatives for use as temporary replacements during the regeneration of lost tissues. For this new approach biodegradable materials/polymers, were designed with properties to degrade after they have performed their function. This degradation is a distinct advantage over the non-degradable biomaterials, in that the need for removal when the ‘job’ is done is absent. A striking example of this in the medical field is the entry of biodegradable suture materials based on lactic acid <sup>4</sup>. Furthermore, (another) disadvantage of the non-degradable



biomaterials is the increased risk of infection, which can lead to the necessity of early removal<sup>5,6</sup>.

Lactic acid based polymers were among the first and most extensively investigated and tested biodegradable biomaterials. Degradation of these polymers largely occurs by hydrolysis in a process called bulk degradation<sup>7</sup>. A disadvantage of the lactic acid based polymers is that, although the short term biocompatibility is very acceptable, the long term complications can have detrimental effects on the surrounding host tissues. These complications emerge during the degradation of the polymer in the human body. Chronic foreign body reactions due to crystalline remnants and acidic degradation environments have been a major concern. Illustrative examples are the treatment of patients with fractures of the zygomatic and ankle bone with high molecular weight poly(L-lactic) acid (PLLA) bone plates and screws<sup>8-11</sup>. Some time after implantation these patients returned with a swelling at the site of implantation. Microscopic evaluation showed remnants of degraded PLLA material surrounded by a dense fibrous capsule and signs of chronic inflammatory foreign body reactions. Performed X-rays even showed osteolytic changes of the bone. These side-effects make lactic- and glycolic acid based polymers not the most suited for use in the regeneration of tissues like bone, that dissolve in acidic environments. In order to use biodegradable polymers for use in bone tissue regeneration purposes, it is of great importance that the degradation products itself do not have a negative effect on bone and regenerated bone tissue. In this regard, polymers that degrade without the formation of these detrimental degradation products might be well suited for application. Nowadays, several biodegradable polymeric materials are available for use in bone and tissue engineering applications, however, one in particular seems very interesting and has been gaining more attention during the last decades: poly(trimethylene carbonate).

### POLY(TRIMETHYLENE CARBONATE)

Poly(trimethylene carbonate) (PTMC) is prepared by ring opening polymerization of trimethylene carbonate (TMC) (Fig 1). The resulting polymer is an amorphous polymer with a low glass transition temperature ( $T_g$ , approx -17 °C). Due to its low  $T_g$  and due to its amorphous nature, PTMC is a very flexible polymer with rubberlike properties. By gamma irradiation under vacuum, form-stable elastomeric networks can be formed<sup>12</sup>. *In vitro* and *in vivo* research have shown that this polymer is both biocompatible and degradable. PTMC degrades by surface erosion without the formation of acidic degradation products<sup>13</sup>.

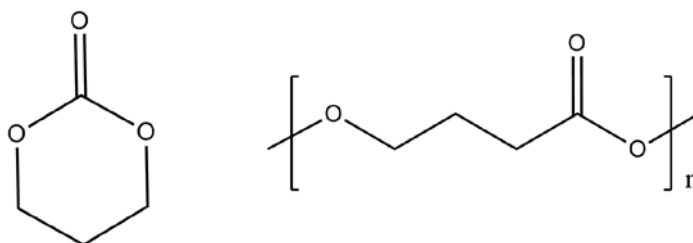
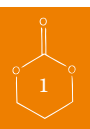


Figure 1: Trimethylene carbonate monomer (TMC) and -polymer (PTMC)



One of the first reports on poly(trimethylene carbonate) (PTMC) dates back to 1930<sup>14</sup>. In 1985 Davis and Geck reported on a suture material (Maxon<sup>®</sup>) based on glycolic acid and TMC<sup>15</sup>. The TMC co-polymer was introduced for flexibility purposes as well as for its favourable degradation profile. Since then, TMC has been more routinely applied in medical devices, most of the times as softening unit or to tune degradation behaviour of medical devices<sup>1, 16, 17</sup>. In the early 2000s PTMC gained new interest as a scaffolding material for tissue engineering applications.

The last decade many reports about the suitability as a biomaterial for biomedical applications have been published<sup>16, 18-24</sup>. The majority of these reports deal with the development of trimethylene carbonate-based materials for use in biomedical applications, especially as scaffold material for use in tissue engineering. We are aiming at the development of resorbable sheets based on PTMC for use in guided bone regeneration techniques to restore (lost) bone tissue. In particular, we aim at the development of (1) resorbable barrier membranes for use in guided bone regeneration procedures prior to implant dentistry and (2) the development of resorbable osteoinductive composite sheets for guided bone regeneration in orbital floor fractures.

#### **SOME IMPORTANT CONCEPTS IN BONE FORMATION AND REGENERATION: OSTEOGENESIS, OSTEOCONDUCTION AND OSTEOINDUCTION**

The terms osteogenesis, osteoconduction and osteoinduction are frequently used in literature concerning bone formation. Unfortunately, the fact that these terms are frequently used does not mean that they are used correctly. A clear understanding of what is meant by these terms is therefore of great importance.

There are two forms of bone formation: endochondral and intramembranous ossification<sup>25</sup>. In endochondral ossification a cartilage model serves as the precursor of the bone (*e.g.* bone formation of extremities in the human body). In intramembranous ossification, bone is formed by a much simpler method, without the intervention of a cartilage precursor stage. The flat bones of the skull, face and mandible for instance, develop by intramembranous ossification. In intramembranous ossification, bone is formed by differentiation of mesenchymal cells into osteoblasts. The differentiated osteoblasts secrete the collagen and proteoglycans of the bone matrix, which is called osteoid. With time this matrix becomes calcified. In this way, layer after layer is formed. This process is called appositional growth. The whole process of the formation of bone by osteoblasts is called *osteogenesis*.

When osteogenesis is influenced by external factors, like biomaterials, *osteoconduction* and *osteoinduction* become involved. Osteoconduction means that the formation of bone (bone growth) is conducted over a surface. This surface can be endogenous, but also exogenous. Implanted biomaterials are examples of exogenous surfaces. The growth of bone over the surface always originates from already existing bone (differentiated osteoblasts), and thus can be considered appositional growth.

Osteoinduction means that primitive, undifferentiated and pluripotent cells are stimulated to develop into the bone forming cell lineage. This means that the characteristics of the (implanted) materials induce mesenchymal cells to become osteoblasts and to form bone. Osteoinduction can

occur in an orthotopic ('bony') as well as in an ectopic (generally intramuscular) location, whereas osteoconduction usually only happens in close contact with existing bone at an orthotopic location.

### GUIDED BONE REGENERATION: APPLICATION OF PTMC AS A BARRIER MEMBRANE

Guided bone regeneration (GBR) can be defined as the use of a barrier membrane to provide available space for new bone formation in a bony defect. This treatment modality was developed in the 1950s and 1960s. Nowadays GBR has proven to be a predictable procedure for alveolar ridge augmentation prior to implant surgery<sup>26, 27</sup>. In guided bone regeneration, the barrier membrane prevents in-growth of fibroblasts and provides a space for osteogenesis within the underlying blood clot<sup>28</sup> (Fig. 2). This blood clot is necessary for new bone formation<sup>29</sup>.

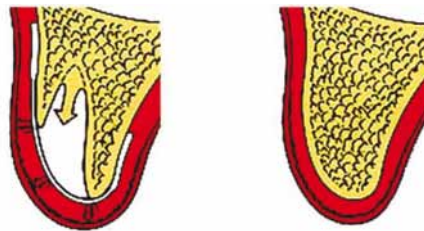


Figure 2: concept of guided bone regeneration with the use of a barrier membrane

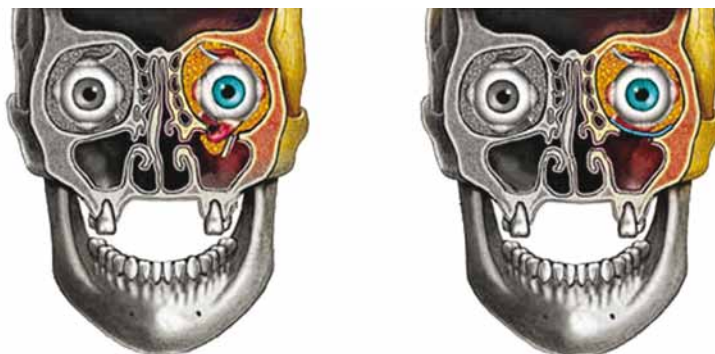Nowadays, two sorts of barrier membranes are available: non-resorbable and resorbable membranes. Although as a rule the used non-resorbable membranes have better space-maintaining properties than the resorbable membranes, main disadvantages are the need for their removal in a second operation and the increased risk of infection, which can lead to the necessity of early removal with loss of underlying bone<sup>5, 6</sup>. The majority of clinically used resorbable membranes are based on collagen. As the collagen is animal derived, these membranes carry the risk of disease transmission from animal to human<sup>30-32</sup>. Another group of available resorbable barrier membranes are synthetic membranes based on lactide and glycolide polymers. However, as previously stated, these polymers might not be the most suitable membrane materials for applications in GBR, since they produce acidic degradation products which can have a detrimental effect on bone and bone formation.

The ideal membrane should be clinically manageable and occlusive, and possess space-maintaining properties. Furthermore, it should be prepared from a synthetic biocompatible material, which resorbs in a favourable manner<sup>33</sup>. In this respect PTMC seems to be a promising material. The synthetic biocompatible PTMC can be compression moulded into thin membranes, which are easy to handle, flexible but still have sufficient rigidity and most importantly resorb in *the* favourable manner (*i.e.* without degradation products that negatively affect the (regenerated) bone). In concept the PTMC polymer seems an ideal material.

## TREATMENT OF ORBITAL FLOOR FRACTURES: COMPOSITES BASED ON PTMC FOR ORBITAL FLOOR RECONSTRUCTION

Fractures of the orbital floor, alone or in conjunction with other facial skeletal damage, are commonly encountered fractures. Orbital floor fractures were first described by MacKenzie in 1844 in Paris<sup>34</sup>. Orbital (floor) fractures can vary in size from a small isolated crack to large multiple wall defects. Most often the part medial to the infraorbital groove and canal and medio caudal from the orbital roof is affected, due to the limited thickness of the bone in this area<sup>35</sup>.

As a result of an orbital floor fracture the volume of the orbit can increase by sagging of the orbital content into the maxillary sinus. Well known consequences of this condition are diplopia, eye movement impairment, hypoglobus and enophthalmos. A most important asset in the treatment is the anatomical reconstruction of the orbital wall thereby restoring the pre-existent volume. To achieve an anatomical reconstruction a wide variety of materials has been used. Autologous bone is often used, but stable synthetic materials like titanium, polytetrafluoroethylene (PTFE), polyethylene (PE) and silicone rubbers (Silastic, Perthese) have been employed in the surgical treatment of orbital floor fractures<sup>36</sup>. Just as in other areas of the medical field there is also interest in the use of degradable and resorbable implant materials for orbital floor reconstruction. Lactide and glycolide based reconstruction materials are among the most often applied resorbable polymeric materials for orbital floor reconstruction. Although they have shown to be quite successful in the treatment of orbital floor fractures in the short-term, a concern are the long-term results. The main short-term goal of surgical reconstruction of orbital floor fractures with resorbable materials is to obtain a stiff scar, composed of a connective tissue capsule, to prevent the orbital content from sagging into the maxillary sinus during degradation and even resorption of the implant<sup>37</sup>. However, limited stiff scar formation and the absence of regeneration of the bone of the orbital floor can result in late complications with enophthalmos. The non-resorbable materials function by means of the continuous presence of their mechanical properties, since the non-resorbable materials do not degrade.



*Figure 3:* Example of orbital floor fracture in left orbit. Note the increase in volume of the affected orbit. Sagging of periorbital fat into the maxillary sinus and entrapment of ocular muscle is eminent. The image in the right shows the situation after surgical reconstruction. An implant is placed to cover the defect and to prevent the orbital content from sagging into the maxillary sinus.



Ideally, bone should be regenerated during healing of the fractured orbital floor. However, with the currently used materials, this is only the case when autologous bone is used. For resorbable synthetic materials to regenerate bone osteoconductive properties are required, and when applied in critical size defects even osteoinductive properties are desired. Besides these bone regenerating potential, these resorbable synthetic materials ought to possess sufficient mechanical properties for a sufficient amount of time. In this respect, composite systems comprising a (resorbable) polymer matrix and bioactive ceramic filler may be of interest. Regarding ceramic fillers, calcium phosphates are of special interest. Calcium phosphates occur naturally in the human body. Calcium phosphates have been used as a bone filler and bone substitute material, and previous studies have shown their osteoconductive and osteoinductive potential<sup>38-41</sup>.

The major problem of calcium phosphate ceramics as an implant material is that their use is limited by their inability to be shaped and contoured, due to their brittleness. In orbital floor reconstruction the “covering” and “bridging” of orbital floor defects with sintered structures, usually blocks, of calcium phosphate is not possible without doing great concessions to the desired contour, with dire consequences. Here a shapeable composite based on a flexible PTMC matrix could provide a soluble solution.

#### AIMS OF THIS THESIS

The aim of the present investigation was to develop resorbable medical devices based on PTMC for application in oral and maxillofacial surgery. In particular we were interested in applications of PTMC based devices for use in guided bone regeneration techniques.

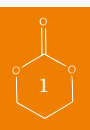
This thesis is divided into two parts. In part I, besides a general introduction (**Chapter 1**), the development and application of PTMC membrane sheets as barrier membranes in guided bone regeneration are described in **Chapter 2 and 3**. Research questions were whether PTMC would have an osteopromotive effect and if the degradation products of the PTMC would have a negative effect on bone formation as well as the quality of the formed bone? And furthermore, could PTMC, being flexible by nature, have sufficient rigidity to provide a space for bone formation?

To establish the suitability of PTMC as a barrier membrane in GBR, membrane sheets composed of high-molecular weight PTMC were developed (**Chapter 2**). These newly developed membrane sheets were evaluated *in vivo* with regard to their effect on new bone regeneration in a study in rats (**Chapter 2**). In **Chapter 3** the *in vivo* behaviour with respect to degradation and reaction of and towards surrounding tissues was evaluated.

Part II focuses on the development and application of osteoinductive composite materials based on PTMC for use in orbital floor reconstruction to guide bony regeneration of the orbital floor.

In **Chapter 4** a mathematical model is proposed, which could assist in assessing the suitability of reconstruction materials in the surgical treatment of orbital floor fractures. **Chapter 5** describes the development and mechanical characterization of composites based on PTMC and calcium phosphates. In **Chapter 6** eventually, the suitability of the developed composites (**Chapter 5**) as reconstruction materials for use in the surgical treatment of orbital floor fractures is *in vivo* evaluated in a study in sheep. Research questions here were: are newly developed resorbable



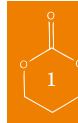

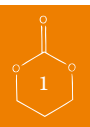
PTMC and calcium phosphates composites rigid enough for initial and short-term reconstruction of the orbital floor? And does their use lead to proper regeneration of the bony orbital floor in the long-term?

In **Chapter 7**, finally, the findings of this thesis are summarized and discussed. A patent application based on the work described in part II of this thesis has been filed.

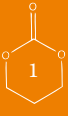## REFERENCES

1. Ratner, B.D., Hoffman, A.S., Schoen, F.J., Lemons, J.E.: Biomaterials science: an introduction to materials in medicine. , 2004
2. Crubezy E, Murail P, Girard L, Bernadou JP: False teeth of the Roman world. *Nature* 391:29, 1998
3. Narayan RJ: The next generation of biomaterial development PREFACE. *Philosophical Transactions of the Royal Society A-Mathematical Physical and Engineering Sciences* 368:1831, 2010
4. Cutright DE, Beasley JD, Perez B: Histologic Comparison of Poly(lactic and Polyglycolic Acid Sutures. *Oral Surgery Oral Medicine Oral Pathology Oral Radiology and Endodontics* 32:165, 1971
5. Machtei EE: The effect of membrane exposure on the outcome of regenerative procedures in humans: A meta-analysis. *J Periodontol* 72:512, 2001
6. Wang HL, Carroll WJ: Guided bone regeneration using bone grafts and collagen membranes. *Quintessence Int* 32:504, 2001
7. Carlotta D: A literature review of poly(lactic acid). *Journal of Polymers and the Environment* 9:63, 2001
8. Bergsma JE, Debruijn WC, Rozema FR, Bos RRM, Boering G: Late Degradation Tissue-Response to Poly(l-Lactide) Bone Plates and Screws. *Biomaterials* 16:25, 1995
9. Bostman O, Partio E, Hirvensalo E, Rokkanen P: Foreign-Body Reactions to Polyglycolide Screws - Observations in 24/216 Malleolar Fracture Cases. *Acta Orthop Scand* 63:173, 1992
10. Bostman OM: Osteolytic Changes Accompanying Degradation of Absorbable Fracture Fixation Implants. *Journal of Bone and Joint Surgery-British Volume* 73:679, 1991
11. Bostman OM: Intense Granulomatous Inflammatory Lesions Associated with Absorbable Internal-Fixation Devices made of Polyglycolide in Ankle Fractures. *Clin Orthop* :193, 1992
12. Pego AP, Grijpma DW, Feijen J: Enhanced mechanical properties of 1,3-trimethylene carbonate polymers and networks. *Polymer* 44:6495, 2003
13. Pego AP, Van Luyn MJA, Brouwer LA, van Wachem PB, Poot AA, Grijpma DW, Feijen J: In vivo behavior of poly(1,3-trimethylene carbonate) and copolymers of 1,3-trimethylene carbonate with D,L-lactide or epsilon-caprolactone: Degradation and tissue response. *Journal of Biomedical Materials Research Part a* 67A:1044, 2003
14. Carothers WH, Van Natta FJ: Studies on polymerization and ring formation. III. Glycol esters of carbonic acid. 52:314-326, 1930
15. Benicewicz BC, Hopper PK: Polymers for Absorbable Surgical Sutures .2. *J Bioact Compatible Polym* 6:64, 1991
16. Pego AP, Vleggeert-Lankamp CLAM, Deenen M, Lakke EAJF, Grijpma DW, Poot AA, Marani E, Feijen J: Adhesion and growth of human schwann cells on trimethylene carbonate (co)polymers. *Journal of Biomedical Materials Research Part a* 67A:876, 2003
17. Amecke B, Bendix D, Entenmann G: Synthetic resorbable polymers based on glycolide, lactides, and similar monomers. :982, 1995
18. Pego AP, Poot AA, Grijpma DW, Feijen J: Copolymers of trimethylene carbonate and epsilon-caprolactone for porous nerve guides: Synthesis and properties. *Journal of Biomaterials Science-Polymer Edition* 12:35, 2001
19. Pego AP, Siebum B, Van Luyn MJA, Van Seijen XJGY, Poot AA, Grijpma DW, Feijen J: Preparation of degradable porous structures based on 1,3-trimethylene carbonate and D,L-lactide (co)polymers for heart tissue engineering. *Tissue Eng* 9:981, 2003 8A:139, 2006
20. Fabre T, Schappacher M, Bareille R, Dupuy B, Soum A, Bertrand-Barat J, Baquey C: Study of a (trimethylenecarbonate-co-epsilon-caprolactone) polymer - Part 2: in vitro cytocompatibility analysis and in vivo ED1 cell response of a new nerve guide. *Biomaterials* 22:2951, 2001
21. Timbart L, Tse MY, Pang SC, Babasola O, Amsden BC: Low Viscosity Poly(trimethylene carbonate) for Localized Drug Delivery: Rheological Properties and in vivo Degradation. *Macromolecular Bioscience* 9:786, 2009
22. Zhang Y, Zhuo RX: Synthesis and drug release behavior of poly (trimethylene carbonate)-poly (ethylene glycol)-poly (trimethylene carbonate) nanoparticles. *Biomaterials* 26:2089, 2005
23. Bat E, Harmsen MC, Plantinga JA, van Luyn MJA, Jan Feijen, Grijpma DW: Flexible scaffolds based on poly(trimethylene carbonate) networks for cardiac tissue engineering. *J Controlled Release* 148:E74, 2010






24. Bat E, Kothman BHM, Higuera GA, van Blitterswijk CA, Feijen J, Grijpma DW: Ultraviolet light crosslinking of poly(trimethylene carbonate) for elastomeric tissue engineering scaffolds. *Biomaterials* 31:8696, 2010
25. Ross MH, Romrell LJ, Kaye GI: *Histology: a text and atlas.*, 1995
26. Hammerle CHF, Jung RE: Bone augmentation by means of barrier membranes. *Periodontol* 2000 33:36, 2003
27. Hallman M, Sennerby L, Lundgren S: A clinical and histologic evaluation of implant integration in the posterior maxilla after sinus floor augmentation with autogenous bone, bovine hydroxyapatite, or a 20 : 80 mixture. *Int J Oral Maxillofac Implants* 17:635, 2002
28. Hollinger JO, Buck DC, Bruder SP: *Biology of bone healing: its impact on clinical therapy.* :17, 1999
29. Murray G, Holden R, Roschlau W: Experimental and Clinical Study of New Growth of Bone in a Cavity. *Am J Surg* 93:385, 1957
30. von Arx T, Cochran DL, Schenk RK, Buser D: Evaluation of a prototype trilayer membrane (PTLM) for lateral ridge augmentation: an experimental study in the canine mandible. *Int J Oral Maxillofac Surg* 31:190, 2002
31. Pauli G: Tissue safety in view of CJD and variant CJD. *Cell Tissue Banking* 6:191, 2005
32. Fishman JA: Infection in xenotransplantation. *J Card Surg* 16:363, 2001
33. Gielkens PFM, Schortinghuis J, de Jong JR, Raghoobar GM, Stegenga B, Bos RRM: Vivosorb (R), Bio-Gide (R), and Gore-Tex (R) as barrier membranes in rat mandibular defects: an evaluation by microradiography and micro-CT. *Clin Oral Implants Res* 19:516, 2008
34. Ng P, Chu C, Young N, Soo M: Imaging of orbital floor fractures. *Australas Radiol* 40:264, 1996
35. Metzger MC, Schoen R, Tetzlaff R, Weyer N, Rafii A, Gellrich N-, Schmelzeisen R: Topographical CT-data analysis of the human orbital floor. *Int J Oral Maxillofac Surg* 36:45, 2007
36. Potter JK, Ellis E: Biomaterials for reconstruction of the internal orbit. *Journal of Oral and Maxillofacial Surgery* 62:1280, 2004
37. Enislidis G: Treatment of orbital fractures: The case for treatment with resorbable materials. *Journal of Oral and Maxillofacial Surgery* 62:869, 2004
38. Fellah BH, Gauthier O, Weiss P, Chappard D, Layrolle P: Osteogenicity of biphasic calcium phosphate ceramics and bone autograft in a goat model. *Biomaterials* 29:1177, 2008
39. Habibovic P, Yuan HP, Van den Doel M, Sees TM, Van Blitterswijk CA, De Groot K: Relevance of osteoinductive biomaterials in critical-sized orthotopic defect. *Journal of Orthopaedic Research* 24:867, 2006
40. Yuan HP, Yang ZJ, de Bruijn JD, de Groot K, Zhang XD: Material-dependent bone induction by calcium phosphate ceramics: a 2.5-year study in dog. *Biomaterials* 22:2617, 2001
41. Yuan H, van Blitterswijk CA, de Groot K, de Bruijn JD: A comparison of bone formation in biphasic calcium phosphate (BCP) and hydroxyapatite (HA) implanted in muscle and bone of dogs at different time periods. *Journal of Biomedical Materials Research Part A* 78A:139, 2006





# Guided bone regeneration in rat mandibular defects using resorbable poly(trimethylene carbonate) barrier membranes



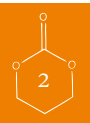
AC van Leeuwen  
JJR Huddleston Slater  
PFM Gielkens  
JR de Jong  
DW Grijpma  
RRM Bos

*Published in: Acta Biomater. 2012 Apr;8(4):422-9*

## ABSTRACT

The present study evaluates a new synthetic degradable barrier membrane based on poly(trimethylene carbonate) (PTMC) for use in guided bone regeneration. A collagen membrane and an expanded polytetrafluoroethylene (e-PTFE) membrane served as reference materials. In 192 male Sprague-Dawley rats, a standardised 5.0 mm circular defect was created in the left mandibular angle. New bone formation was demonstrated by post-mortem micro-radiography, micro-CT imaging and histological analysis. Four groups (control, PTMC, collagen, e-PTFE) were evaluated at 3 time intervals (2, 4 and 12 weeks). In the membrane groups the defects were covered; in the control group the defects were left uncovered. Data were analysed using a multiple regression model.

In contrast to uncovered mandibular defects, substantial bone healing was observed in defects covered with a barrier membrane. In the latter case, the formation of bone was progressive over 12 weeks. No statistically significant differences between the amount of new bone formed under the PTMC membranes and the amount of bone formed under the collagen and e-PTFE membranes were observed. Therefore, it can be concluded that PTMC membranes are well suited for use in guided bone regeneration (GBR).



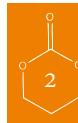## INTRODUCTION

Guided bone regeneration (GBR) has proven to be a predictable procedure for alveolar ridge augmentation prior to implant dentistry<sup>1,2</sup>. In guided bone regeneration, a barrier membrane prevents in-growth of fibroblasts and provides a space for osteogenesis within the underlying blood clot<sup>3</sup>. This blood clot is necessary for new bone formation<sup>4</sup>. The membrane also excludes inhibiting factors and preserves growth factors<sup>5</sup>.

This barrier effect can be achieved with various biocompatible materials. Currently, two sorts of barrier membranes are available: non-resorbable and resorbable membranes. Although the non-resorbable membranes have better space-maintaining properties than the resorbable membranes, a main disadvantage is the need for their removal in a second operation. Another disadvantage is the increased risk of infection, which can lead to the necessity of early removal<sup>6,7</sup>. The majority of clinically used resorbable membranes are based on collagen. As the collagen is animal derived, these membranes carry the risk of disease transmission from animal to human<sup>8-10</sup>. Another group of available resorbable barrier membranes are synthetic membranes based on lactide and glycolide polymers. However, due to an extensive foreign body reaction, adverse effects like postoperative swelling have been reported for these materials<sup>11-18</sup>. Furthermore, as it is known that these materials can produce significant amounts of acidic compounds during degradation in the body, and since bone dissolves in acidic environments, it can be expected that these polymers will not be the most suitable membrane materials in guided bone regeneration<sup>12,17,19,20</sup>. The ideal membrane should be clinically manageable and occlusive, and possess space-maintaining properties. Furthermore, it should be prepared from a synthetic biocompatible material, which resorbs in a favourable manner<sup>21</sup>.

We have developed a novel, synthetic resorbable membrane based on poly(trimethylene carbonate) (PTMC). Poly(trimethylene carbonate) is an amorphous polymer with a glass transition temperature of approximately -17 °C and a relatively low elastic modulus of 5 to 7 MPa at room temperature. The flexible polymer can be crosslinked into a creep-resistant and form-stable network by gamma-irradiation<sup>22</sup>. Most importantly, PTMC is a biocompatible polymer that degrades enzymatically *in vivo* without the formation of acidic degradation products<sup>23,24</sup> by a surface erosion process. The trimethylene carbonate monomer and polymer are well-known in the medical field, and have been used in surgical sutures and tissue engineering scaffolds<sup>25,26</sup>.

We hypothesized that a PTMC membrane can be space-maintaining, and at the same time be flexible enough to adapt to the contour of cortical bone. The objective of this study was to evaluate the suitability of PTMC barrier membranes in the regeneration of bone in critical size rat mandibular defects, and to compare their performance with collagen and expanded polytetrafluoroethylene (e-PTFE) membranes.





## MATERIALS AND METHODS

### *Materials*

Polymerization grade 1,3-trimethylene carbonate (TMC) was obtained from Boehringer Ingelheim, Germany. Stannous octoate ( $\text{SnOct}_2$  from Sigma, USA) was used as received.

The used solvents were of technical grade and were purchased from Biosolve, the Netherlands.

### *Preparation of PTMC barrier membranes*

Poly(trimethylene carbonate) (PTMC) was prepared by ring opening polymerization of trimethylene carbonate at 130 °C for a period of 3 days. Stannous octoate,  $\text{Sn}(\text{Oct})_2$ , was used as a catalyst at a concentration of  $2 \times 10^{-4}$  mol per mol of monomer. Analysis of the synthesized polymer by proton nuclear magnetic resonance ( $^1\text{H-NMR}$ ) (300MHz, Varian Innova, USA), differential scanning calorimetry (DSC) (Perkin Elmer Pyris 1), gel permeation chromatography (GPC) (GPC, Viscotek, USA) using chloroform as solvent and narrow polystyrene standards for calibration was done according to previously described procedures<sup>22</sup>. The GPC measurements showed that high molecular weight polymer with  $M_w=443000$  and  $M_n=332000$  g/mol had been synthesized, while NMR indicated that the monomer conversion was higher than 98 %. The glass transition temperature of the amorphous polymer was approximately -17 °C, as thermal analysis indicated.

The PTMC polymer was purified by dissolution in chloroform at a concentration of 5g per 100 ml, followed by precipitation into a five-fold excess of ethanol 100%. The PTMC was collected and dried under vacuum at room temperature until constant weight was reached.

After drying, the PTMC precipitate was compression moulded using 0.3 mm thick stainless steel moulds. Disks with a diameter of 8 mm were prepared at 140 °C and a pressure of 3 MPa (31 kg/cm<sup>2</sup>) using a Carver model 3851-0 laboratory press (Carver Inc., USA). Compression moulding under these conditions does not lead to significant polymer degradation<sup>22</sup>.

The disk-shaped PTMC membrane sheets were then vacuum-sealed in laminated polyethylene bags and exposed to 25 kGy gamma irradiation from a  $^{60}\text{Co}$  source (Isotron BV, The Netherlands for sterilization and simultaneous crosslinking of the polymer.

### *Animals and surgical procedures*

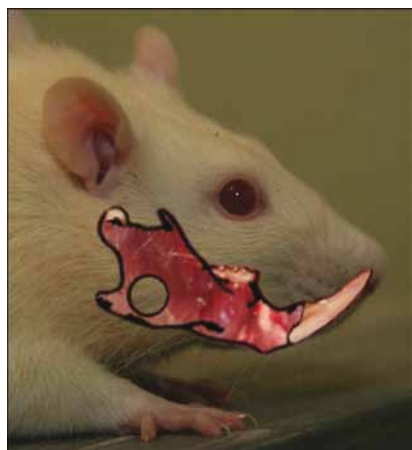The animal model we employed to assess new bone formation in rat mandibular defects covered with barrier membranes was the same as previously described in our group<sup>21,27</sup>.

A sample size calculation was done to estimate the minimum number of animals required for statistical testing of a given difference between groups with statistical significance. Using the outcomes of a previously performed study in our group<sup>21</sup>, the difference in new bone formation between a membrane-treated group and a non-treated control group that is to be tested was 20%  $\pm$  18% (average  $\pm$  SD)<sup>27,28</sup>. This yielded a sample size of 12 animals. When animals for histological analysis are included, 16 animals per evaluation time period are then required.

Animal care and surgical procedures were conducted in accordance with international standards on animal welfare and complied with guidelines of the Animal Research Committee of the University Medical Center Groningen. One hundred and ninety-two male Sprague-Dawley rats, varying

in age between 12-16 weeks and in weight between 325-400 gram were included in the study. The rats were randomly divided into four experimental groups: 3 groups in which membranes were used to cover the created bone defects, and 1 control group in which the defect was left uncovered. Different membranes were used: a PTMC membrane which was prepared as described above, a porous collagen membrane (prepared from porcine type 1 and 3 collagen with a thickness of 0.3-0.4 mm, Geistlich Bio-Gide, Geistlich, Switzerland), and an expanded polytetrafluoroethylene membrane (Gore-Tex, e-PTFE with a thickness of 0.15 mm from W.L. Gore & Associates, USA).

Under nitrous-oxygen-isoflurane inhalation anaesthesia a 5.0 mm circular defect was drilled in the mandibular angle with a trephine in a standardized surgical procedure (Fig. 1).



*Fig. 1:* In the mandibular angle a 5.0 mm diameter defect was drilled with a trephine. The defect was left uncovered in the control group and covered in the membrane treated groups. [Image taken from ref. 21, used with permission]

In the membrane-treated groups, the defect was covered with a barrier membrane on the buccal and lingual side. According to instructions of the manufacturer, the e-PTFE membranes were sutured, while the collagen membranes were not fixed. The PTMC membranes were also not sutured to the underlying bone. The wound was then closed in layers using 4-0 resorbable sutures (Vicryl Rapid 4-0, Ethicon, USA). A single dose of Temgesic (0.05 mg/kg) was administered perioperative to relieve postoperative pain. The rats were given standard laboratory food.

At 2, 4 and 12 weeks a number of rats from each experimental group was anaesthetized by nitrous-oxygen-isoflurane inhalation and sacrificed by intracardial injection of pentobarbital. The mandibles were then explanted and fixated in 4% phosphate-buffered formaline solution.

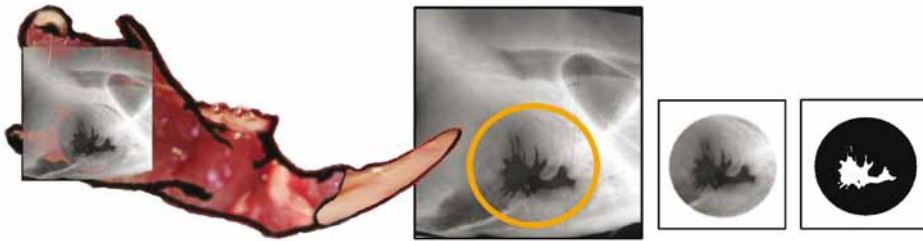### *Histology*

Samples for histological analysis were decalcified and dehydrated in a graded series of increasing ethanol concentrations. The specimens were embedded in glycidyl methacrylate resin (GMA).

Histological sections with a thickness of 2  $\mu$ m were cut from the tissue blocks with a microtome. The sections were cut perpendicularly to the defects. From each sample two sections were stained with Toluidin Blue and with Toluidin Blue/Basic Fuchsin as counterstain. The sections were evaluated by light microscopy using a Leica DMR (Germany) microscope.

### *Micro-radiography and micro-computed tomography*

The explanted mandibles were embedded in methyl methacrylate (MMA) resin. An X-ray source (Philips PW 1730, The Netherlands) was used to obtain microradiographs of the specimens on 35 mm film (Fuji B/W, POS/71337). The mandibular buccal plane was parallel to the film to ensure that a non-distorted image of the defect was obtained. The microradiographs of the mandibular defects were digitized using a stereo microscope (Wild/Leitz M7 S, Switzerland, magnification x10) equipped with a CCD camera (CFW 1312M, Scion Corporation, USA). The digitized images were stored as 1360 x 1024 pixel canvases with a resolution of 256 grey values. Micro-computed tomography (micro-CT) images were obtained using a Siemens MicroCAT II pre-clinical cone-beam CT scanner (Germany). The CCD sensor measured 7 x 5 cm. In order to prevent truncation artefacts, the specimens were arranged in a 3-dimensional (3D) array that did not exceed field-of-view dimensions. From the data, 3D images with an isotropic voxel size of 48 x 48 x 48  $\mu\text{m}$  were reconstructed.



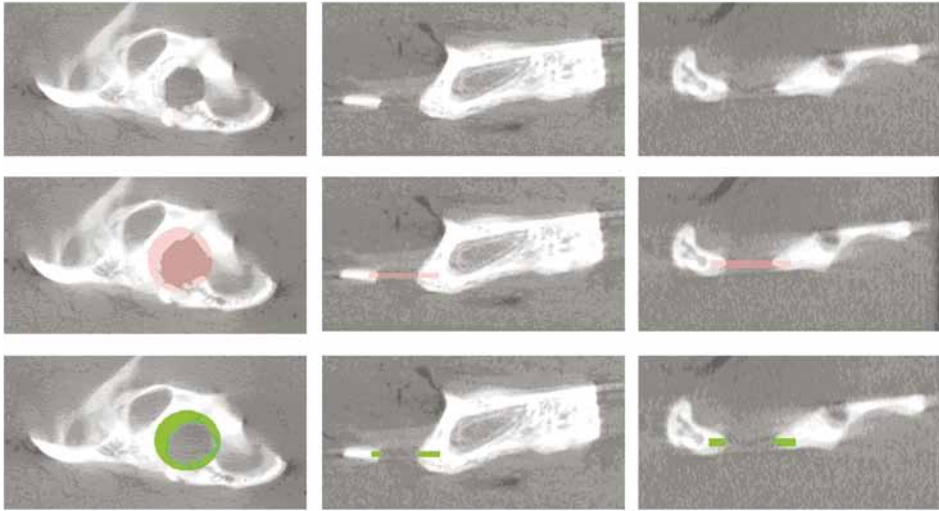
*Fig. 2:* For micro-radiographic evaluation of the defects a 5.0 mm diameter circle was selected corresponding to the original defect. Based on the difference in grey values, the threshold of bone/no-bone boundary was determined for the selected area and applied. The remaining defect area was computed automatically and expressed as a percentage of the original defect size. [Image taken from ref. 21, used with permission]

### *Qualitative and quantitative assessment of new bone formation*

In the stained histological sections, new formed bone could be identified by light microscopy. The new bone that formed in the defect could be distinguished by its morphological characteristics.

In the digitized micro-radiographs, the amount of new bone formed in the defect can be determined using image analysis software (Scion, Scion Corporation, USA). Based on the difference in grey value between void space and bone, a bone/no-bone threshold was determined in each individual digitized microradiograph. This threshold was then applied to the original circular defect to assess the amount of new bone formed. The amount of new bone formed can be expressed as a percentage of the area of the original defect (Fig. 2). The micro-CT data sets were evaluated with more advanced image analysis software (Inveon Research Workplace, Siemens, Germany). The original circular defect was located, and a three dimensional region of interest (ROI) measuring 5.0 mm in diameter and 0.3 mm in height was defined and placed over the original defect. (Note that the minimal thickness of the mandibula at the site of the defect as measured by micro-CT was 0.3 mm).

A bone/no-bone threshold value in CT Hounsfield units (HU) was determined. Based on this threshold, a distinction between bone and no-bone volume elements can be made. As the volume of the ROI corresponds to the volume of the original defect, the amount of bone present within the ROI is the amount of new formed bone. For each specimen, new bone formation was expressed as a percentage of defect closure in the 5.0 mm diameter defect (Fig. 3).



*Fig. 3:* Micro-computed tomographic images of a mandibular angle defect illustrating the manner in which the bone formation inside the defects is quantified. Sagittal, coronal and transversal views are shown, respectively. First the defect was located. Then a 3D region of interest (ROI) corresponding to the size of the original defect was defined and situated at the site of the defect. A bone/no-bone threshold was introduced. New bone formation was expressed as a percentage of defect closure in the 5.0 mm defect area.

## RESULTS

### *Implant retrieval*

Of the one hundred and ninety-two rats that underwent surgery, three rats died during the procedure. All other animals showed uneventful healing. No significant reductions in body weight and no postoperative infections were observed. After termination of the animals and processing of the tissues for evaluation, one sample was lost.

From each experimental subgroup, new bone formation was qualitatively assessed by histological evaluation of the explanted mandibles of 4 animals at the different time points. At the different time points, bone formation in the bone defects of the other animals was quantitatively evaluated by micro-CT and by micro-radiographic analysis.

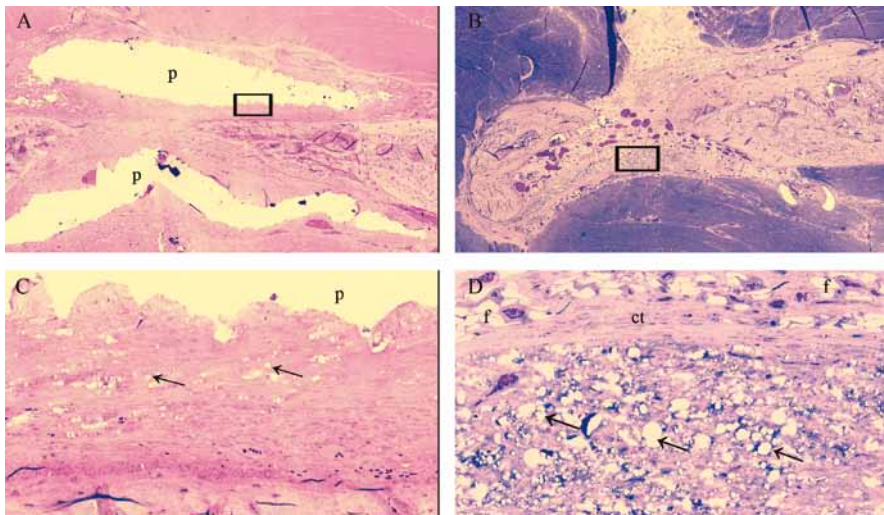
### *Qualitative histological evaluation*

Microscopic examination showed new bone formation originating from the bony borders of the defects towards the center. In the control defects that were not covered with a membrane limited

bone formation was observed. In the membrane treated defects, considerable amounts of bone were formed. These amounts seemed to increase in time, and bone completely bridged the defects after 12 weeks. No adverse tissue reactions were observed.

While during the evaluation period the e-PTFE membranes remained unchanged, with some ingrowth of tissue, the collagen and PTMC membranes showed clear signs of resorption. The collagen barrier membranes were similar to collagen connective tissue, although it could be differentiated from host collagen connective tissue after 4 weeks.

At 12 weeks the collagen membrane could not be identified anymore; besides extensive signs of degradation of the membrane, differentiation between any remaining membrane material and host collagen was virtually impossible. Degradation and resorption of the PTMC membranes had also taken place upon implantation, as the PTMC membranes appeared thinner after 2 and 4 weeks. The PTMC membrane showed extensive signs of degradation after 4 and 12 weeks. After 12 weeks of implantation, only small amounts of remnants of the PTMC membranes could be identified (Fig. 4).



*Fig. 4:* Light micrographs (2x-20x) of rat mandibular defects covered with a PTMC membrane after 4 weeks (4A and C) and 12 weeks (4B and D) of implantation. The PTMC membranes are clearly visible after 4 weeks, whereas after 12 weeks only remnants of the PTMC could be distinguished. Toluidin blue with basic fuchsin as counterstain was used for the staining of the histological sections. (p) polymer, (ct) connective tissue, (f) fat cell, arrows indicate phagocytosed intracellular polymer (PTMC) fragments. Figure 4C and 4D are magnifications (20x) of the marked regions from respectively fig. 4A and B, which are 2x magnifications.

#### *Quantitative evaluation of bone regeneration*

Bone regenerated in all animals (Fig. 5), with mean percentages of 85%, 79%, 89% and 41% for respectively collagen, PTMC, e-PTFE and the control group as measured by micro-radiography (MR) after 12 weeks.

The mean percentages as evaluated by micro-CT after 12 weeks were 74%, 71%, 83% and 33% for respectively collagen, PTMC, e-PTFE and the control group. Figure 6 (see page 32) presents the percentages of new bone formation in the defects evaluated by MR and micro-CT after 2, 4 and 12 weeks. It is shown in the figure that after 12 weeks the membrane treated groups had formed significantly higher values of bone compared to the control group. Moreover, between the membrane treated groups there were no significant differences in bone formation after 12 weeks.

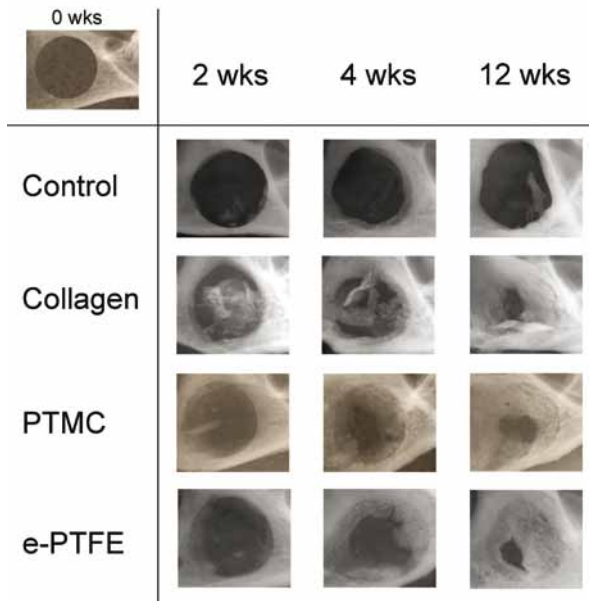


Fig. 5: Microradiographical X-ray images of the control and membrane treated groups after 2, 4 and 12 weeks. T=0 is depicted in the left upper corner of the image table. Where the membrane treated groups showed almost complete closure of the defects after 12 weeks, the control defect did not close after 12 weeks.

### Statistical analysis

A mathematical model was created to analyse the bone formation over time for the control and the three membrane materials. The technique used for the analysis was a multiple linear regression technique, in which the dependent variable was the amount of newly formed bone. The independent variables were the material groups (*i.e.*, control, PTMC, collagen and e-PTFE) and time (*i.e.*, 2, 4, and 12 weeks). In a second model, which is an extension of the first model, the interaction between the materials and time was also calculated to test whether the effect of the membrane materials on bone formation was different for the different timepoints.

The first model can be written as  $Y = \beta_1 * \text{material} + \beta_2 * \text{time}$  and the second model can be written as  $Y = \beta_1 * \text{material} + \beta_2 * \text{time} + \beta_3 * \text{time} * \text{material}$ . No constants were added to the models because the amount of newly formed bone was zero at T=0. The calculated coefficients  $\beta_1 + \beta_2 + \beta_3$  are given in Table 1 and 2. Hence, the statistical analysis involves testing whether the coefficients are equal to zero. In other words: to test the  $H_0$  hypothesis:  $\beta_1 = 0, \beta_2 = 0, \beta_3 = 0$ .

**Table 1: Linear regression model of defect closure as measured by micro-radiography. Model 1 is a regression model without the correction for interaction effects, model 2 with correction for interaction effects.**

Model 1	Coefficients	95%-CI <sup>a</sup>	P-value
Control ( $\beta_1$ )	2.9	2.2 – 3.6	<0.001
PTMC <sup>b</sup> ( $\beta_2$ )	20.6	11.1 - 30.1	<0.001
Collagen ( $\beta_2$ )	35.2	26.9 - 43.4	<0.001
e-PTFE <sup>c</sup> ( $\beta_2$ )	29.0	20.2 - 37.8	<0.001
Model 2			
Control ( $\beta_1$ )	0.5	-0.9 – 1.9	0.446
PTMC ( $\beta_2$ )	-4.2	-20.0 – 11.8	0.606
Collagen ( $\beta_2$ )	21.1	7.0 – 35.3	0.004
e-PTFE ( $\beta_2$ )	6.9	-7.9 – 21.7	0.359
Interaction time*PTMC ( $\beta_3$ )	3.9	1.8 - 6.0	0.021
Interaction time*collagen ( $\beta_3$ )	2.1	0.3 - 4.0	<0.001
Interaction time*e-PTFE ( $\beta_3$ )	3.5	1.5 - 5.4	<0.001

<sup>a</sup>CI = confidence interval

<sup>b</sup>PTMC = poly(trimethylene carbonate)

<sup>c</sup>e-PTFE = expanded polytetrafluoroethylene

The analysis of the micro-radiography data showed that there were no significant differences in bone formation between the 3 different membrane-treated groups. When the interaction term time was taken into account (see model 2), the differences between the membrane-treated groups were still not significant, although it showed that the effect on bone formation for the materials differed at the different time points. Similar results were found using the data obtained by micro-CT. Again no significant differences were found between the different membrane-treated groups, although the extent of bone formation differed at the different time points.

The regression analyses of the mean percentages of bone formation determined using MR and micro-CT are summarized in Tables 1 and 2, respectively. These results are graphically displayed for the different membrane materials and the control group in Figure 7 (see page 33). Although it should be noted that the displayed lines/functions are an approximation of the reality, since the percentage of bone formation has not been assessed between the time intervals (2, 4 and 12 weeks).

**Table 2: Linear regression model of defect closure as measured by micro-computed tomography. Model 1 is a regression model without the correction for interaction effects, model 2 with correction for interaction effects.**

Model 1	Coefficients	95%-CI <sup>a</sup>	P-value
Control ( $\beta_1$ )	3.3	2.6 - 4.0	<0.001
PTMC <sup>b</sup> ( $\beta_2$ )	14.2	4.9 - 23.5	0.003
Collagen ( $\beta_2$ )	20.3	11.5 - 29.1	<0.001
e-PTFE <sup>c</sup> ( $\beta_2$ )	19.5	10.0 - 29.0	<0.001
Model 2			
Control ( $\beta_1$ )	-0.6	-2.0 - 0.8	0.406
PTMC ( $\beta_2$ )	-16.5	-31.1 - -1.9	0.027
Collagen ( $\beta_2$ )	-7.9	-21.9 - 6.1	0.269
e-PTFE ( $\beta_2$ )	-16.0	-30.8 - -1.1	0.036
Interaction time*PTMC ( $\beta_3$ )	4.8	2.9 - 6.7	<0.001
Interaction time*collagen ( $\beta_3$ )	4.3	2.6 - 6.1	<0.001
Interaction time*e-PTFE ( $\beta_3$ )	5.6	3.6 - 7.6	<0.001

<sup>a</sup>CI = confidence interval

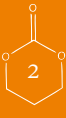<sup>b</sup>PTMC = poly(trimethylene carbonate)

<sup>c</sup>e-PTFE = expanded polytetrafluoroethylene

## DISCUSSION

The present study demonstrated that the new PTMC membrane can be used successfully as a biodegradable barrier membrane for GBR in critical-size defects of the mandible in rats. Similar amounts of bone formed in defects treated with the PTMC membrane compared to defects covered with the collagen or e-PTFE membrane. Overall, far more bone was formed in rats treated with a barrier membrane compared to rats treated with no membrane. It has been shown that soft tissue ingrowth into bony defects leads to significantly less bone formation compared to membrane treated groups in the long term<sup>29-32</sup>. Our results are consistent with the results from previous studies.

In recent animal studies several barrier membranes have been investigated with variable results. Polyglactin 910 membranes collapsed and degraded early leading to incomplete bone regeneration<sup>31</sup>. A synthetic barrier membrane composed of poly(DL-lactide- $\epsilon$ -caprolactone) showed less bone formation in rat mandibular defects compared to collagen and e-PTFE membranes<sup>16</sup>. More promising results were found with a polylactide membrane<sup>33</sup>. However, an adequate control group was not included in the latter study, thus making a relevant comparison difficult. More





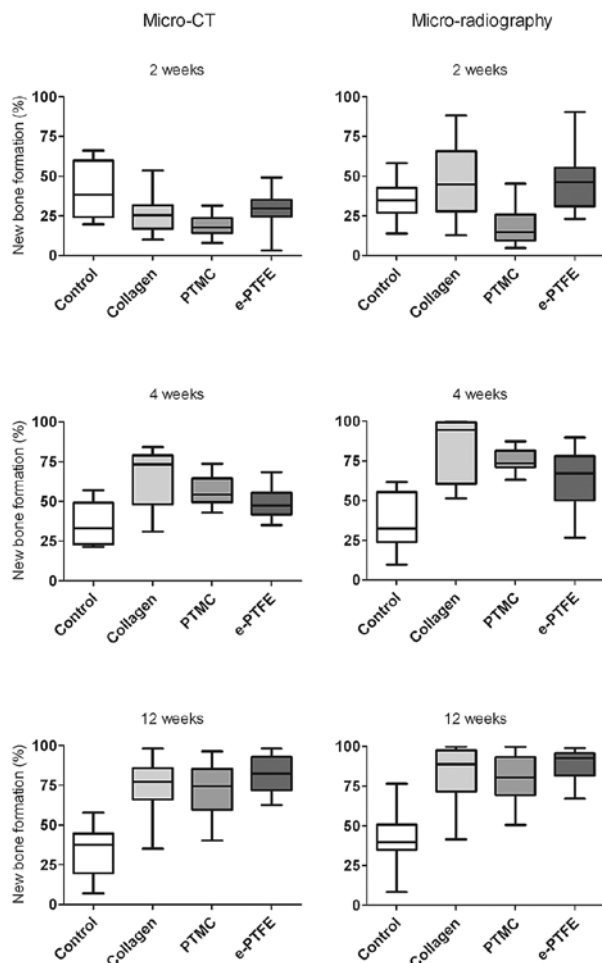


Fig. 6: Percentage of newly formed bone within the former defects as measured by micro- radiography and micro-computed tomography (box plot with whiskers). The left column shows the results measured by micro-computed tomography, the right column the results by micro-radiography.

recently synthetic hydrogels have been evaluated as barrier membranes<sup>34</sup> over cranial defects in rabbits. Although the results were promising the lack of space maintaining properties made it necessary to use (synthetic) bone graft materials to prevent the *in situ* formed membranes from collapsing into the defect, thus making it less suitable to bridge defects.

For this study it was chosen to measure new bone formation in the defects by MR and micro-CT only and not to perform histomorphometric analysis on the samples although the latter is considered the 'gold standard'. Recently, Gielkens<sup>35</sup> showed in a comparative study that micro-CT combined with MR can be used for quantitative measurements of bone formation to obtain valid results. Although MR tends to overestimate the amount of bone formation<sup>21</sup> compared to micro-CT the results in this study were not (statistically) significantly different.

MR and micro-CT showed progressive bone formation from 2 to 12 weeks for the membrane treated groups. Although both MR and micro-CT showed less new bone formation after 2 weeks

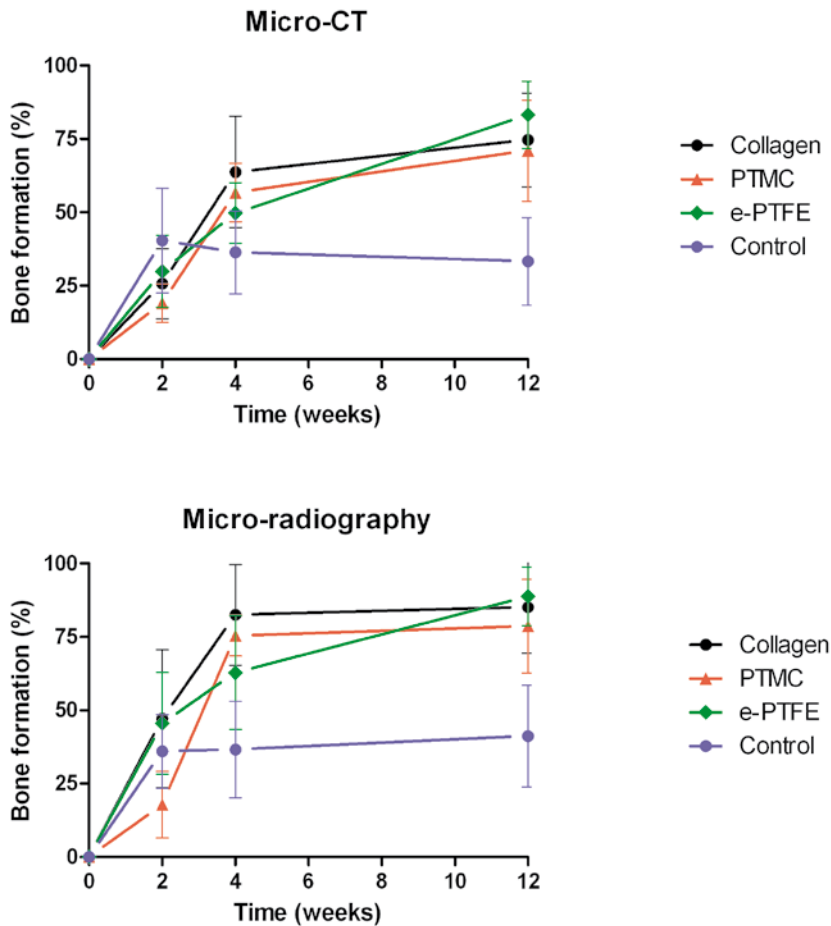
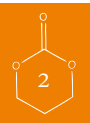


Fig. 7: The regression analyses of the mean percentages in micro-CT and micro radiography are graphically displayed for 'model 2' (i.e. with the correction for interaction of time, see text) is displayed. Mean $\pm$ SD are presented. It should be noted that the displayed lines/functions are an approximation of the reality, since the percentage of bone formation has not been assessed between the time intervals (2, 4 and 12 weeks).

for the PTMC treated group, this was neither statistically nor clinically relevant. After 4 and 12 weeks results for bone formation were similar compared to collagen and e-PTFE.

In a model without correction for the interaction effect, the regression analyses showed that all membranes allow more bone to be formed than the control. In the collagen group more bone was formed than in the PTMC and e-PTFE groups. However, when the regression coefficients for the different membranes are considered with correction for the interaction effect of 'time' (e.g. model 2) it shows that for the collagen treated group relatively little bone formation in time was observed compared to the other membrane treated groups (Table 1 model 2). This apparent contradiction could be explained by the fact that collagen already showed a large amount of new bone at 2 weeks. The increase of new bone per unit of time thereafter is less compared with the other membranes,



although the amount of bone at each occasion is larger. It should be realized that the regression analysis is used to evaluate whether the effect of the materials on bone formation is different for the various time points, by using a so called interaction term. In our study the regression analysis shows approximately the pattern of bone formation underneath the different membranes taking the interaction term into account.

After 2 weeks more bone formation was observed in the control group evaluated by micro-CT, though this difference is neither statistically nor clinically relevant. Surprisingly micro-CT showed, although statistically not significant, a slight decrease in mean percentage of bone formation for the control group over time. It is not inconceivable that masticatory forces of the muscles overlying the defect play a role in the new bone formation, especially in the control group where the forces act directly onto the newly formed bone. Thus newly formed bone could have been resorbed over time due to masticatory forces of the musculature protruding into the defect.

Qualitative histologic observations revealed that degradation of the PTMC membrane had occurred upon implantation and the PTMC membrane appeared thinner after 2 and 4 weeks. After 12 weeks only remnants of the PTMC membrane were detected. Overall, no adverse tissue reactions were found. These findings are in accordance with the findings of previous studies<sup>23,24</sup>.

The PTMC barrier membrane designed is well suitable for GBR in and over bone defects because of superior space maintaining properties compared to collagen membranes. Although during the first surgical procedures it became clear that the PTMC membrane adhered less to the underlying bone as compared with collagen, it was nevertheless decided not to fix the newly designed membrane with sutures or pins. If a new synthetic resorbable barrier membrane would only show satisfactory outcomes with fixation, then this would be a major disadvantage for clinical practice and such a membrane would not be capable of competing with the already available degradable collagen membranes.

Also it became clear during the implantation procedure that the PTMC membranes handling and space maintaining properties were superior to those of the collagen and e-PTFE membrane. Where the collagen membrane tended to collapse into the defect, the PTMC membrane was easily placed over the defect edges to ensure inhibition of soft-tissue in-growth and in contrast to the e-PTFE membranes, the PTMC membranes did not have to be fixed by sutures or pins. Other advantages over the collagen and e-PTFE membrane are respectively the synthetic origin of the PTMC membrane and the lack for the need of removal in a second operation.

Finally, the general opinion in medicine is that (resorbable) animal derived materials should be replaced by similar performing (resorbable) synthetic materials when available, in order to avoid the associated risks of possible disease transmission<sup>8-10</sup>. In this respect the application of PTMC as a barrier membrane over bone defects could be a step forward as an alternative for the animal derived collagen membranes.

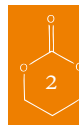
All the advantages considered the PTMC membrane seems highly applicable for use in GBR. Therefore the next step will be to study the PTMC membrane as a barrier membrane for guided bone regeneration in dental implant surgery in a preclinical animal study in dogs, as the human situation regarding dental implant surgery is well simulated in these animals.

## CONCLUSIONS

In this study the performance of new poly(trimethylene carbonate) (PTMC) barrier membranes in guided bone regeneration (GBR) in rat mandibular defects was evaluated and compared to currently available collagen and e-PTFE membranes. A non-treated control group was included in the study as well. After 2, 4 and 12 weeks the extent of bone formation was assessed by MR and micro-CT. All membrane treated groups showed progressive bone formation compared to the control group. Statistical analysis showed no significant differences in bone formation between the membrane-treated groups. It can be concluded that the PTMC membrane seems suitable for use in GBR. In addition, the degradable synthetic origin and the lack for the need of removal in a second operation can be considered advantageous features when compared to collagen and e-PTFE barrier membranes.

## ACKNOWLEDGEMENTS

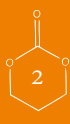We would like to thank Mr. J.L. Ruben for his assistance and advice during the micro-radiographic procedures. Ms. Y. Heddema and Ms. N. Broersma are acknowledged for their assistance in the surgical procedures, Ms. M.B.M. van Leeuwen is acknowledged for her help in the histological evaluations. Furthermore, we would like to thank Geistlich Biomaterials and W.L. Gore & Associates for provision of respectively Geistlich Bio-Gide and Gore-Tex Regenerative membranes.



## REFERENCES


1. Hammerle CHF, Jung RE: Bone augmentation by means of barrier membranes. *Periodontol* 2000 33:36, 2003
2. Hallman M, Sennerby L, Lundgren S: A clinical and histologic evaluation of implant integration in the posterior maxilla after sinus floor augmentation with autogenous bone, bovine hydroxyapatite, or a 20 : 80 mixture. *Int J Oral Maxillofac Implants* 17:635, 2002
3. Hollinger JO, Buck DC, Bruder SP: Biology of bone healing: Its impact on clinical therapy. In: Lynch SE, Genco RJ, Marx RE, editors. *Tissue engineering. Applications in maxillofacial surgery and periodontics*. Chicago: Quintessence; 1999. p 17-53.
4. Murray G, Holden R, Roschlaw W: Experimental and Clinical Study of New Growth of Bone in a Cavity. *Am J Surg* 93:385, 1957
5. Zellin G, Linde A: Importance of delivery systems for growth-stimulatory factors in combination with osteopromotive membranes. An experimental study using rhBMP-2 in rat mandibular defects. *J Biomed Mater Res* 35:181, 1997
6. Machtei EE: The effect of membrane exposure on the outcome of regenerative procedures in humans: A meta-analysis. *J Periodontol* 72:512, 2001
7. Wang HL, Carroll WJ: Guided bone regeneration using bone grafts and collagen membranes. *Quintessence Int* 32:504, 2001
8. von Arx T, Cochran DL, Schenk RK, Buser D: Evaluation of a prototype trilayer membrane (PTLM) for lateral ridge augmentation: an experimental study in the canine mandible. *Int J Oral Maxillofac Surg* 31:190, 2002
9. Pauli G: Tissue safety in view of CJD and variant CJD. *Cell Tissue Banking* 6:191, 2005
10. Fishman JA: Infection in xenotransplantation. *J Card Surg* 16:363, 2001
11. Bergsma JE, Debruijn WC, Rozema FR, Bos RRM, Boering G: Late Degradation Tissue-Response to Poly(L-Lactide) Bone Plates and Screws. *Biomaterials* 16:25, 1995
12. Bostman OM: Osteolytic Changes Accompanying Degradation of Absorbable Fracture Fixation Implants. *Journal of Bone and Joint Surgery-British Volume* 73:679, 1991
13. Bostman OM: Absorbable Implants for the Fixation of Fractures. *Journal of Bone and Joint Surgery-American Volume* 73A:148, 1991
14. Bostman O, Partio E, Hirvensalo E, Rokkanen P: Foreign-Body Reactions to Polyglycolide Screws - Observations in 24/216 Malleolar Fracture Cases. *Acta Orthop Scand* 63:173, 1992
15. Bostman OM, Pihlajamaki HK, Partio EK, Rokkanen PU: Clinical Biocompatibility and Degradation of Polylevolactide Screws in the Ankle. *Clin Orthop* :101, 1995
16. Hurzeler MB, Quinones CR, Hutmacher D, Schupbach P: Guided bone regeneration around dental implants in the atrophic alveolar ridge using a bioresorbable barrier - An experimental study in the monkey. *Clin Oral Implants Res* 8:323, 1997
17. Tams J, Rozema FR, Bos RRM, Roodenburg JLN, Nikkels PGJ, Vermey A: Poly(L-lactide) bone plates and screws for internal fixation of mandibular swing osteotomies. *Int J Oral Maxillofac Surg* 25:20, 1996
18. von Arx T, Kurt B, Hardt N: Treatment of severe peri-implant bone loss using autogenous bone and a resorbable membrane - Case report and literature review. *Clin Oral Implants Res* 8:517, 1997
19. Wu LB, Ding JD: In vitro degradation of three-dimensional porous poly(D,L-lactide-co-glycolide) scaffolds for tissue engineering. *Biomaterials* 25:5821, 2004
20. Taylor MS, Daniels AU, Andriano KP, Heller J: 6 Bioabsorbable Polymers - In-Vitro Acute Toxicity of Accumulated Degradation Products. *Journal of Applied Biomaterials* 5:151, 1994
21. Gielkens PFM, Schortinghuis J, de Jong JR, Raghoobar GM, Stegenga B, Bos RRM: Vivosorb (R), Bio-Gide (R), and Gore-Tex (R) as barrier membranes in rat mandibular defects: an evaluation by microradiography and micro-CT. *Clin Oral Implants Res* 19:516, 2008
22. Pego AP, Grijpma DW, Feijen J: Enhanced mechanical properties of 1,3-trimethylene carbonate polymers and networks. *Polymer* 44:6495, 2003
23. Pego AP, Van Luyn MJA, Brouwer LA, van Wachem PB, Poot AA, Grijpma DW, Feijen J: In vivo behavior of poly(1,3-trimethylene carbonate) and copolymers of 1,3-trimethylene carbonate with D,L-lactide or epsilon-caprolactone: Degradation and tissue response. *Journal of Biomedical Materials Research Part A* 67A:1044, 2003

24. Zhang Z, Kuijer R, Bulstra SK, Grijpma DW, Feijen J: The in vivo and in vitro degradation behavior of poly(trimethylene carbonate). *Biomaterials* 27:1741, 2006
25. Pego AP, Vleggeert-Lankamp CLAM, Deenen M, Lakke EAJF, Grijpma DW, Poot AA, Marani E, Feijen J: Adhesion and growth of human schwann cells on trimethylene carbonate (co)polymers. *Journal of Biomedical Materials Research Part A* 67A:876, 2003
26. Amecke B, Bendix D, Entenmann G. Synthetic resorbable polymers based on glycolide, lactides, and similar monomers. In: Wise DL, editor. *Encyclopedic Handbook of Biomaterials and Bioengineering*. New York: Marcel Dekker Inc.; 1995. p 982-3.
27. Schortinghuis J, Ruben JL, Raghoobar GM, Stegenga B: Therapeutic ultrasound to stimulate osteoconduction - A placebo controlled single blind study using e-PTFE membranes in rats. *Arch Oral Biol* 49:413, 2004
28. Schortinghuis J, Ruben JL, Raghoobar GM, Stegenga B, de Bont LGM: Does ultrasound stimulate osteoconduction? A placebo-controlled single-blind study using collagen membranes in the rat mandible. *Int J Oral Maxillofac Implants* 20:181, 2005
29. Bornstein MM, Heynen G, Bosshardt DD, Buser D: Effect of Two Bioabsorbable Barrier Membranes on Bone Regeneration of Standardized Defects in Calvarial Bone: A Comparative Histomorphometric Study in Pigs. *J Periodontol* 80:1289, 2009
30. McAllister BS, Haghighat K: Bone augmentation techniques. *J Periodontol* 78:377, 2007
31. Aaboe M, Pinholt EM, Schou S, Hjorting-Hansen E: Incomplete bone regeneration of rabbit calvarial defects using different membranes. *Clin Oral Implants Res* 9:313, 1998
32. Aslan M, Simsek G, Dayi E: Guided bone regeneration (GBR) on healing bone defects: a histological study in rabbits. *The journal of contemporary dental practice* 5:114, 2004
33. Mueller AA, Rahn BA, Gogolewski S, Leiggener CS: Early dural reaction to polylactide in cranial defects in rabbits. *Pediatr Neurosurg* 41:285, 2005
34. Jung RE, Zwahlen R, Weber FE, Molenberg A, van Lenthe GH, Hammerle CHF: Evaluation of an in situ formed synthetic hydrogel as a biodegradable membrane for guided bone regeneration. *Clin Oral Implants Res* 17:426, 2006
35. Gielkens PFM, Schortinghuis J, de Jong JR, Huysmans MCDNJM, van Leeuwen MBM, Raghoobar GM, Bos RRM, Stegenga B: A comparison of micro-CT, microradiography and histomorphometry in bone research. *Arch Oral Biol* 53:558, 2008





In vivo behaviour of a biodegradable  
poly(trimethylene carbonate) barrier membrane:  
a histological study in rats



AC van Leeuwen  
TG van Kooten  
DW Grijpma  
RRM Bos

*Published in: J Mater Sci Mater Med. 2012 Aug;23(8):1951-9*

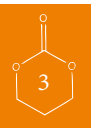

## ABSTRACT

The aim of the present study was to evaluate the response of surrounding tissues to newly developed poly(trimethylene carbonate) (PTMC) membranes. Furthermore, the tissue formation beneath and the space maintaining properties of the PTMC membrane were evaluated. Results were compared with a collagen membrane (Geistlich BioGide), which served as control.

Single-sided standardized 5.0 mm circular bicortical defects were created in the mandibular angle of rats. Defects were covered with either the PTMC membrane or a collagen membrane. After 2, 4 and 12 weeks rats were sacrificed and histology was performed. The PTMC membranes induced a mild tissue reaction corresponding to a normal foreign body reaction. The PTMC membranes showed minimal cellular capsule formation and showed signs of a surface erosion process. Bone tissue formed beneath the PTMC membranes comparable to that beneath the collagen membranes. The space maintaining properties of the PTMC membranes were superior to those of the collagen membrane.

Newly developed PTMC membranes can be used with success as barrier membranes in critical size rat mandibular defects.



## INTRODUCTION

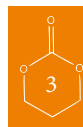Guided bone regeneration (GBR) is a widely used modality for restoring bone deficiencies. In GBR the use of barrier membranes leads to predictable bone formation, by preventing in-growth of fibroblasts and provision of space for osteogenesis within a blood clot formed in the defect<sup>1</sup>. A variety of biocompatible membranes have been used to achieve this desired barrier effect. The optimal barrier membrane should exert biocompatible, synthetic, degradable and space maintaining properties<sup>2,3</sup>. Currently, non-resorbable membranes have better space maintaining properties compared to resorbable membranes. However, a major disadvantage of non-resorbable membranes is the need for their removal in a second operation.

The majority of clinically used resorbable membranes are based on collagen. As collagen is an animal derived product, these membranes carry the risk of disease transmission from animal to human<sup>3-5</sup>. Other available resorbable barrier membranes are synthetic polymeric membranes based on lactide and glycolide. However, due to an extensive foreign body reaction, adverse effects like postoperative swelling have been reported when using these materials<sup>6-13</sup>. It is known that these materials can produce significant amounts of acidic compounds during degradation in the body, and since bone dissolves in acidic environments, it can be expected that these polymers will not be the most suited materials for use in guided bone regeneration<sup>7,12,14,15</sup>.

Recently, we have developed a flexible synthetic biodegradable barrier membrane prepared from poly(trimethylene carbonate) (PTMC) for GBR<sup>16</sup>. PTMC is a flexible, rubber-like, amorphous and biodegradable polymer. The monomer from which it is prepared, trimethylene carbonate (TMC), has been used to prepare copolymers for use in barrier membranes in the medical field before<sup>17-20</sup>. By gamma irradiation under vacuum, form-stable elastomeric networks can be formed<sup>21</sup>. *In vitro* and *in vivo* research has shown that this polymer is both biocompatible and can be degraded by surface erosion without the formation of acidic degradation products<sup>22,23</sup>.

In the aforementioned study<sup>16</sup> the PTMC membrane, prepared from TMC only, was evaluated and compared with a collagen (Geistlich BioGide) and an expanded-polytetrafluoroethylene (e-PTFE, GoreTex) membrane and a non-treated control site for its suitability as a barrier membrane for use in guided bone regeneration over bony defects in rats. Both quantitative micro-radiographical and quantitative micro-computed tomographical analysis showed excellent amounts of bone formed underneath the PTMC membrane<sup>16</sup>. Evaluation after 12 weeks showed that comparable amounts of bone had formed underneath the PTMC and reference membranes. The mean percentages of regenerated bone were 74%, 71%, 83% and 33%, for respectively the collagen, PTMC e-PTFE and the non-treated control group<sup>16</sup>.

The purpose of this current study was to evaluate histologically the response of the surrounding tissue to the PTMC membrane, the tissue formation beneath the PTMC membrane, and the space maintaining properties of the PTMC membrane. Furthermore, the degradation of the membrane was assessed. The collagen membrane served as a reference.



## MATERIALS AND METHODS

### *Membrane synthesis*

Polymerization grade 1,3-trimethylene carbonate (TMC) was obtained from Boehringer Ingelheim, Germany. Stannous octoate ( $\text{SnOct}_2$  from Sigma, USA) was used as received. The used solvents were of analytical grade and purchased from Biosolve, the Netherlands.

Poly(trimethylene carbonate) (PTMC) was synthesized by ring opening polymerization of trimethylene carbonate monomer under vacuum at 130 °C for a period of three days using stannous octoate as a catalyst. The polymer was purified by dissolution in chloroform and precipitation into a five-fold excess of ethanol 100%. The precipitated PTMC was dried under vacuum at room temperature. Analysis of the synthesized polymer by proton nuclear magnetic resonance ( $^1\text{H-NMR}$ ), gel permeation chromatography (GPC) and differential scanning calorimetry (DSC) according to standardized procedures <sup>21</sup> indicated that high molecular weight polymer had been synthesized. GPC measurements showed that  $M_w=443000$  and  $M_n=332000$  g/mol, while NMR indicated that the monomer conversion was more than 98 %. The glass transition temperature of this amorphous polymer was approximately -17 °C, as thermal analysis showed.

The purified polymer was then compression moulded at 140 °C and a pressure of 3.0 MPa (31 kg/cm<sup>2</sup>) using a Carver model 3851-0 laboratory press (Carver Inc, USA) into films with a thickness of 0.3 mm and a diameter of 8 mm using stainless steel moulds. The PTMC membranes were then sealed under vacuum and exposed to 25 kGy gamma irradiation from a  $^{60}\text{Co}$  source (Isotron BV, The Netherlands). This sterilization method leads to simultaneous crosslinking of the polymer <sup>21</sup>.

### *Study design*

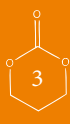The gamma irradiated PTMC membranes were evaluated by a subperiosteal implantation in rats. All procedures performed on the animals were done according to international standards on animal welfare and complied with the Animal Research Committee of the University Medical Centre Groningen.

Twenty-four Sprague-Dawley rats from an earlier study <sup>16</sup> were included in here. The surgical procedure consisted of drilling one bicortical critical size (5.0 mm diameter) mandibular defect in the left mandibular angle with a trephine. The created defects were covered with a barrier membrane on the buccal and lingual side using either the PTMC membrane, or a collagen (Geistlich BioGide, Geistlich, Switzerland) membrane which served as reference. (The procedures are described in the section *Implantation procedure*.) At three different time periods (2 wk, 4 wk and 12 weeks) the rats were sacrificed. Per time period 8 rats were evaluated; 4 rats treated with the collagen membrane and 4 rats treated with the PTMC membrane. The rats were histologically evaluated for the response of the surrounding tissue to the membranes, and the tissue proliferation at the defect site, covered by the membranes. Furthermore, space maintaining properties and degradation of the PTMC membranes were assessed (Table 1).

(In a separate study, of which the results will be reported in another communication, the bone sample that was obtained with the trephine was transplanted to the contralateral mandibular angle

**Table 1: Semiquantitative histological grading scale**

Soft tissue response to membrane	
Fibrous, mature, not dense, resembling connective or fat tissue in the noninjured regions	4
Shows blood vessels and young fibroblasts, few macrophages and giant cells are present	3
Shows macrophages and other inflammatory cells in abundance, but connective tissue components between	2
Dense and exclusively of inflammatory type	1
Cannot be evaluated because of infection or other factors not necessarily related to the material	0
Tissue proliferation in defect	
Mature bone and differentiation of bone marrow	4
Bone or osteoid formation	3
Fibrous connective tissue: collagen fibers at defect site	2
Fibrous connective tissue: cellular and vascular components	1
Cannot be evaluated because of infection or other factors not necessarily related to the material	0
Space maintaining properties of membrane	
No contact between membranes at defect site, bone formation in between	4
No contact between membranes at defect site, connective tissue in between	3
Contact between membranes at defect site, bone formation present	2
Contact between membranes at defect site, connective tissue in between	1
Cannot be evaluated because of degradation or absence of the material	0



to evaluate the suitability of the membranes on modelling and incorporation of autologous bone grafts.)

### *Implantation procedure*

The animals were anaesthetized with nitrous–oxygen–isoflurane. After the mandibular area was shaved and disinfected, a peri angular incision was made and a standardised circular 5.0 mm critical size bicortical defect was drilled with a trephine in the left mandibular angle<sup>24,25</sup>. In one group the PTMC membrane was used to cover the defects. In the other group the defects were covered with a collagen membrane (Geistlich BioGide, Geistlich, Switzerland).

The wound was closed in layers using resorbable sutures (Vicryl Rapide 4-0, Ethicon, USA).

A single dose of Temgesic (0.05 mg/kg) was administered perioperative for postoperative pain relief, and the diet was composed of standard laboratory food.

At three different time intervals (2 wk, 4 wk and 12 wk), the rats were anaesthetised by nitrous-oxygen-isoflurane inhalation and sacrificed by an intracardially injected overdose of pentobarbital. The mandibles were explanted and fixed in 4% phosphate buffered formaline solution.

#### *Light microscopy: histological scoring analysis*

After explantation, the specimens were decalcified and dehydrated in a series of ethanol. The specimens were embedded in glycidyl methacrylate (GMA). The tissue blocks were cut perpendicularly to the defects with a microtome. The resulting histological sections were 2  $\mu\text{m}$  thick. From all samples two sections were stained, one series with toluidin blue and one with toluidin blue/basic fuchsin. The histological sections were digitalized with a ScanScope GL (Aperio Technology Inc., Vista, CA). Digital images were then stored for further analysis. Histological sections were qualitatively and semiquantitatively analyzed using a modified histological scoring analysis (Table 1). Two histological sections were evaluated for each animal. The investigators were blinded for time interval and type of material used during evaluation of the explanted samples. During analysis each section was evaluated with respect to the foreign body response (soft tissue response to PTMC membrane), (the kind of) tissue proliferation at the defect site and finally for the space maintaining properties of the membrane. Each section received a single score. The scores for each time interval were then averaged; mean and standard deviation were reported.

#### *Statistical analysis*

The data sets were statistically evaluated with a Fisher's Exact Test using SPSS 17 (Statistical Package for the Social Sciences, SPSS Inc., USA). The null hypothesis (the means of each set are equal) was evaluated with 95% confidence level ( $\alpha = 0.05$ ).

## **RESULTS**

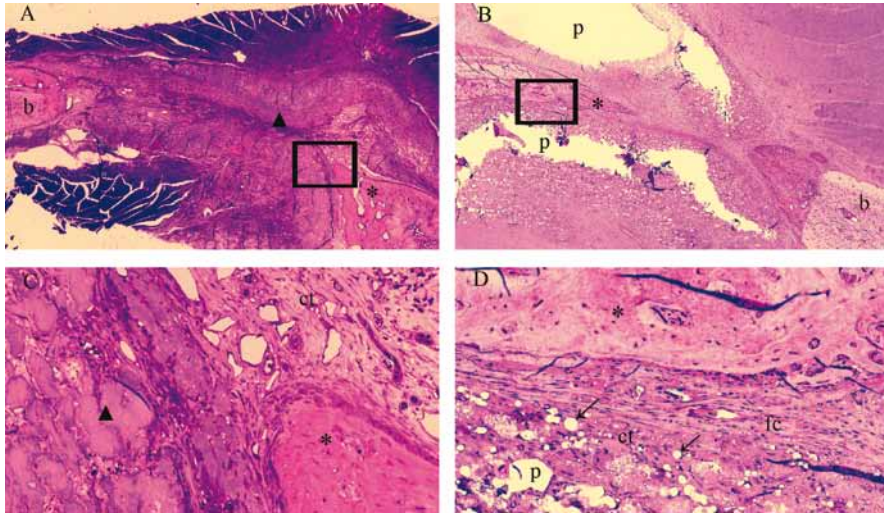
### *Clinical Observations*

None of the rats died or suffered from postoperative complications. The animals started eating immediately after the surgical procedure and did not lose weight.

### *Descriptive microscopic observations*

A gross light microscopical inspection of all histological sections was performed. Defects and the PTMC and collagen barrier membranes could easily be identified after 2 and 4 weeks ((Fig 1 and 2, see page 45/46)). The PTMC membrane appeared white in the sections, the collagen barrier membrane appeared similar to (collagen) connective tissue, although it could be differentiated from host (collagen) connective tissue.

At 12 weeks it was more difficult to identify the defects, whereas in some animals the defect had closed. The collagen membrane could not be identified anymore at 12 weeks because, besides extensive signs of degradation of the membrane, the differentiation between membrane and host col-



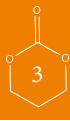*Figure 1:* Light micrographs of rat mandibular defects covered with either a collagen (1A and C) or a PTMC (1B and D) membrane after 2 weeks of implantation. The collagen and PTMC membrane can be readily distinguished. Degradation of the PTMC membrane can be observed. Toluidin blue with basic fuchsin as counterstain was used for the staining of the histological sections. (p) polymer, (ct) connective tissue, (b) bone, (fc), fibrous capsule, (\*) osteoid, (▲) collagen membrane, arrows indicate phagocytosed intracellular fragments. Figure 1C and 1D are magnifications (20x) of the marked regions from respectively fig. 1A and B, which are 2x magnifications.

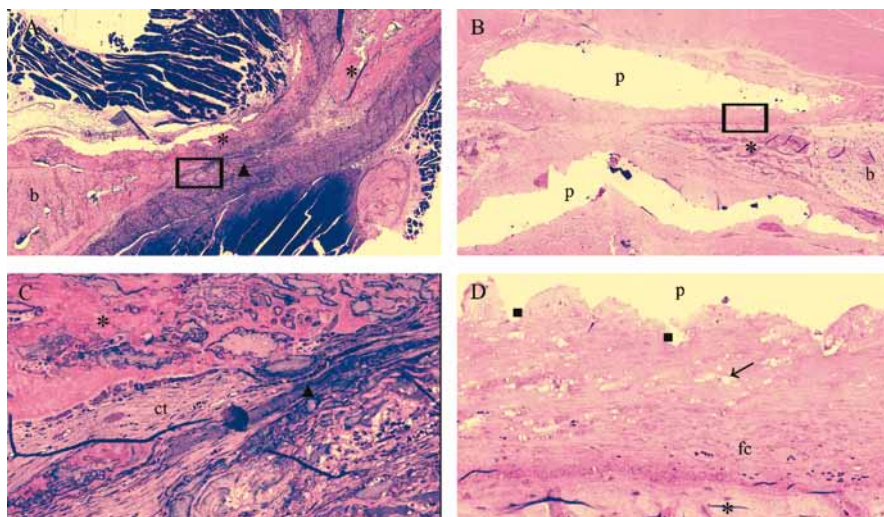
lagen was virtually impossible. The PTMC membrane showed extensive signs of degradation. Only some remnants of the PTMC membrane could still be identified after 12 weeks (Fig 3, see page 47).

After 2 weeks both the collagen membrane and the PTMC membrane was surrounded by a thin fibrous capsule. The thin fibrous capsule around the collagen membranes was composed of loose connective tissue fibers with the presence of very few macrophages, giant cells and other inflammatory cells. The fibrous capsule around the PTMC membrane was also composed of loose connective tissue fibers though appeared thicker and showed more invasion of macrophages and also giant cells compared to the collagen treated animals. The macrophages and giant cells appeared to erode the surface of the PTMC membrane by phagocytosis (Fig 2B and D)(see page 46).

At 2 weeks high numbers of blood vessels were present at the tissues surrounding the PTMC membranes and especially located in the tissues filling the defects covered with the PTMC membranes. By contrast the animals treated with the collagen membranes showed blood vessel formation mainly localized *in and throughout* the membranes, as well as in the surrounding tissues.

Osteoid (bone) formation was already observed after 2 weeks in both the collagen and PTMC membrane treated groups. Interestingly at 2 and 4 weeks, two different patterns of bone formation were identified. The animals treated with the collagen membrane tended to form osteoid and new bone throughout the defect by forming bony islets (Fig 2 and 3). By contrast the PTMC membrane treated animals showed osteoid and new bone formation originating from the defect borders. The pattern of new bone formation was found similar for both groups after 12 weeks, since the majority of the sections by then showed complete bridging of the defect with newly formed mature bone.





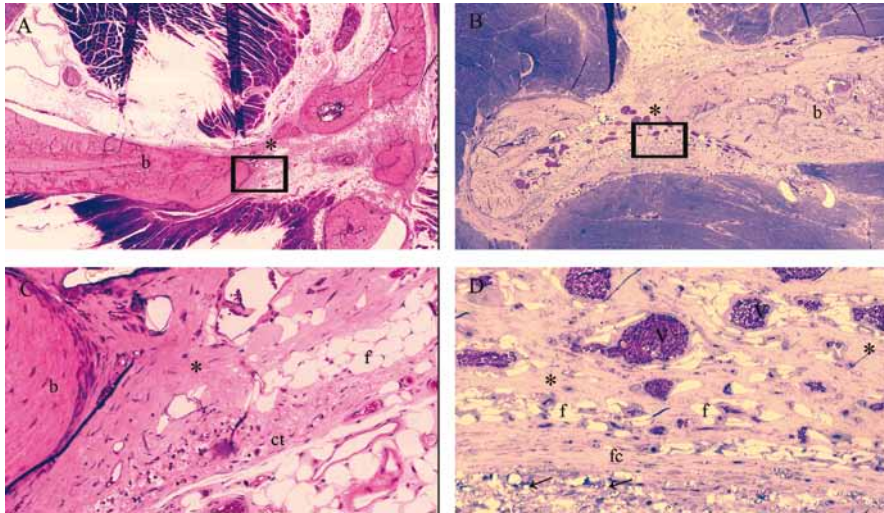
**Figure 2:** Light micrographs of rat mandibular defects covered with either a collagen (2A and C) or a PTMC (2B and D) membrane after 4 weeks of implantation. The collagen membrane can be distinguished from the rats connective tissue. Bone forms in and around the collagen membrane, by contrast bone formation underneath the PTMC membrane originates from the defect borders. Toluidin blue with basic fuchsin as counterstain was used for the staining of the histological sections. (p) polymer, (ct) connective tissue, (b) bone, (fc), fibrous capsule, (\*) osteoid, (▲) collagen membrane, arrows indicate phagocytosed intracellular fragments. (■) Indicates surface erosion degradation by macrophage and giant cell activity. Figure 2C and 2D are magnifications (20x) of the marked regions from respectively fig. 2A and B, which are 2x magnifications.

### *Histological analysis*

Figure 4A (see page 48). shows the data of the histological rating of the soft tissue response to the collagen and PTMC membrane, respectively. Statistical analysis of these data revealed that after 2, 4 and 12 weeks significant differences existed between the tissue response towards the used membranes ( $p < 0.001$ ,  $p < 0.001$  and  $p = 0.006$ , resp.). The tissue reaction to the PTMC membrane shows a higher density of inflammatory cells after 2, 4 and 12 weeks compared to the collagen membrane. For both membranes the score increased at 12 weeks, which means that there was a reduction in inflammatory cell density, and the number of giant cells, and an increase in vascularization of the surrounding tissue.

The data on tissue formation at the defect site, shown in figure 4B, was similar for both membranes. After 2 and 4 weeks the majority of the sections showed amounts of osteoid and bone formation in the defects for both membrane treated groups. Between 4 and 12 weeks the newly formed bone had matured and after 12 weeks extensive amounts of mature bone were found for both membrane groups. There were no statistical differences in the tissue proliferation at the defect sites between the collagen and PTMC treated animals ( $p = 0.467$ ). Moreover, after 12 weeks mature bone with bone marrow had formed at the defect sites, whereas after 4 weeks bone could be assessed as immature.

Figure 4C presents the data on the space maintaining properties of the two membranes. The



*Figure 3:* Light micrographs of rat mandibular defects covered with either a collagen (3A and C) or a PTMC (3B and D) membrane after 12 weeks of implantation. Bone bridges the mandibular defects in both membrane groups. The collagen membrane is not present anymore and has resorbed. The PTMC membrane eroded completely, only a few phagocytosed polymer particles are in situ. Toluidin blue with basic fuchsin as counterstain was used for the staining of the histological sections. (p) polymer, (ct) connective tissue, (b) bone, (fc), fibrous capsule, (\*) osteoid, (v) marks blood vessel, (f) fat cell, arrows indicate phagocytosed intracellular fragments.

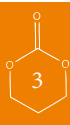Figure 3C and 3D are magnifications (20x) of the marked regions from respectively fig. 3A and B, which are 2x magnifications.

PTMC membrane showed a distinctively maintained space at the level of the mandibular defects, between the buccal and lingual placed membranes after 2 and 4 weeks (Fig 1 and 2). This space was filled with either connective tissue, osteoid or newly formed bone depending on the time of evaluation, respectively 2, 4 or 12 weeks. The collagen membranes by contrast showed no space maintaining at all after 2 and 4 weeks. After 12 weeks the space maintaining properties of both membranes could not be assessed for two reasons: firstly, because bone had bridged the majority of the defects, and as a result there was no ‘space’ left to be assessed, and secondly because of the extensive degradation of both membranes. The collagen membranes could not be discerned anymore due to degradation and similarity to the host connective tissue and for the PTMC membranes only some phagocytosed particles were observed. As a consequence the space maintaining properties could not be assessed, and score ‘0’ was assigned to all specimens of the 12 weeks group.

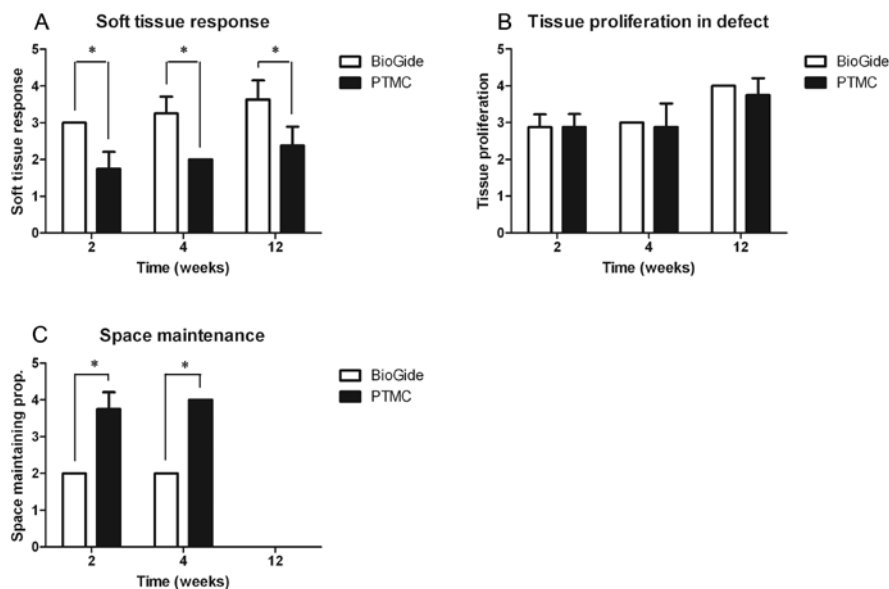
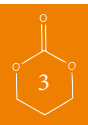
## DISCUSSION

In the present study a rat model was used to investigate the soft and hard tissue response to a barrier membrane composed of solid PTMC. Furthermore the space maintaining properties were assessed, as space maintaining is an important factor in guided bone regeneration.

While copolymers prepared from lactide, glycolide and TMC have been intensively investigated







*Figure 4:* A) Histological scoring results for the soft tissue response to the collagen and PTMC membrane after 2, 4 and 12 weeks. Error bars represent means $\pm$ standard deviation for n=4. \* = p < 0.05. B) Scoring results for the proliferated tissue at the mandibular defect site. Error bars represent means $\pm$ standard deviation for n=4. \* = p < 0.05. C) Scoring results for the space-maintaining properties for both membranes. At time = 12 weeks the space-maintaining properties could not be assessed because of closure of the mandibular defects and degradation of both the membranes. Error bars represent means $\pm$ standard deviation for n=4. \* = p < 0.05.

and are now in clinical use<sup>17-19</sup>, this is the first time barrier membranes prepared from TMC only have been applied in guided bone regeneration.

Critical size rat mandibular defects were selected as the orthotopic model to evaluate the PTMC membranes. Previously performed studies have shown that 5.0 mm circular rat mandibular defects are of critical size and therefore will not heal spontaneously during the lifetime of the animal<sup>25,26</sup>.

The benign soft tissue response to PTMC membranes indicated that PTMC membranes are promising materials for use in guided bone regeneration techniques. The thin cellular capsule around the PTMC membranes implies that the host has initiated the foreign body reaction that is observed with many implant materials, and at the same time still is involved in a response at the interface with the implanted material. The results after 2, 4, and 12 weeks show that the soft tissue response to the PTMC membrane is accompanied by a larger influx of macrophages, giant cells and other inflammatory cells concentrated at the tissue-implant interface when compared to the collagen membrane. However, this reaction can be regarded as a normal tissue response to the PTMC, as the degradation is characterized by a surface erosion process<sup>22,27</sup>. The surface erosion process attracted cells involved in the foreign body reaction and degradation to the tissue-implant interface. This is in accordance with the results of previous studies, where also an influx of macrophages and formation of foreign body giant cells was observed at the tissue-implant interface<sup>22,27</sup>. The foreign

body giant cells were only transiently present and disappeared with increasing implantation time. Therefore, it can be concluded that the tissue reaction (*i.e.* foreign-body reaction) induced by the PTMC membrane was mild and transient.

The tissue response to the collagen membrane was characterized by an even milder reaction, possibly due to its resemblance to native collagen. The degradation profile is characterized by a macrophage and polymorphonuclear leukocyte associated degradation as well as an enzymatic degradation profile<sup>28, 29</sup>.

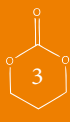The histological evaluation of the proliferated tissue at the defect site showed for both membranes that increasing amounts of bone had formed with time, witnessing the defect closure with increasing implantation time. Recent quantitative analysis of the amount of bone formed in rat mandibular defects covered using PTMC and collagen (and e-PTFE) membranes had shown that significant amounts of bone were formed, without statistically significant differences between the membranes<sup>16</sup>. This implies that use of the PTMC membrane facilitates in bone regeneration in critical size defects in rats. These results suggest that the PTMC membrane is biocompatible with bone and assists in promoting bone regeneration in critical size defects.

As mentioned before, two different patterns of bone formation were observed. The bone formed beneath the PTMC membranes tended to grow from the defect borders towards the centre of the defect. This way of defect closure has been described often in literature and seems to be the most common in the formation of new bone when non-osteoinductive biomaterials are applied<sup>30-32</sup>. The collagen membrane showed bone formation within the membrane and throughout the defect originating from bony islets and the defect border. This has been previously described by Hoogeveen *et al.* in a comparative study between three different barrier membranes used in guided bone regeneration<sup>33</sup>. A possible explanation for the formation of these bony islets could be that the animal derived natural collagen has osteoinductive properties. Nonetheless, the different bone formation patterns did not show statistical differences regarding the tissue proliferation at the defect site between the two membranes for the different time periods. After just 2 weeks osteoid formation was present for both membranes, again indicating that the PTMC is a bone biocompatible material that allows for bone formation in the space in between the membranes.

Space maintaining properties of the barrier membrane are important in GBR to lead to predictable bone formation, by providing space for the blood clot and new bone formation in the defect. During the implantation procedure it became clear that the handling and space maintaining properties of 0.3 mm thick PTMC membranes were superior to the collagen membrane. This was confirmed by the results of the histological evaluation after 2 and 4 weeks. Compared to the collagen membrane the PTMC membrane exerted better space maintaining properties.

The space maintaining properties of the membranes after 12 weeks could not be assessed for two reasons. Firstly, since both the PTMC and collagen membrane had almost completely resorbed, and therefore had lost their mechanical strength resulting in a complete loss of space maintaining properties. A second reason is that new bone had bridged the majority of the defects and space maintaining properties cannot be assessed without a distinct defect in the rat mandible.

An important problem with collagen membranes is that almost immediately upon implantation

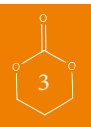

they lose their mechanical strength and, therefore, their space maintaining properties. The collagen membrane is therefore best used in combination with (autologous) grafting materials to achieve comparable results to non-resorbable e-PTFE barrier membranes<sup>20, 34-36</sup>. The better mechanical properties of the resorbable PTMC membrane should enable comparable results to those of non-resorbable e-PTFE membrane without the use of grafting materials. Before conducting clinical trials in humans, this should preferably be evaluated in a next study where deeper defects with larger volumes are created. This will emphasize the importance of the space maintaining properties of the membranes. A model such as the one described by Oh *et al.* would be useful<sup>32</sup> as they created buccal dehiscence defects in the jaw bone around dental implants measuring 4 mm in height from the crestal bone, 3 mm in depth from the surface and 3 mm in width in dogs. In this model the membranes space maintaining properties can be better assessed as larger volumes of deficient bone are involved, also its biological behaviour around dental implants and more importantly its behaviour towards exposure to the oral environment can be assessed. Nevertheless, the present study demonstrated histologically that the PTMC membrane allows bone growth and therefore makes it suitable for use in guided bone regeneration techniques.

Finally, the general opinion in medicine is that (resorbable) animal derived materials should be replaced by similarly performing (resorbable) synthetic materials when available, in order to avoid possible transmission of disease<sup>3-5</sup>. In this respect, the application of PTMC as a barrier membrane in guided bone regeneration techniques could be a step forward as an alternative for the animal derived collagen membranes.

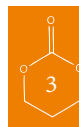
#### ACKNOWLEDGEMENTS

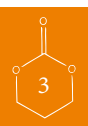
Gratitude is expressed to Ms. M.B.M. van Leeuwen for her assistance and advice during the histological procedures. Ms. Y. Heddema and Ms. N. Broersma are acknowledged for their assistance during the surgical procedures. Furthermore we would like to thank Geistlich Biomaterials for provision of the Geistlich BioGide regenerative membranes.



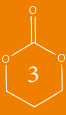
## REFERENCES

1. Hollinger JO, Buck DC, Bruder SP: Biology of bone healing: its impact on clinical therapy. :17, 1999
2. Kay SA, Wisner-Lynch L, Marxer M, Lynch SE: Guided bone regeneration: integration of a resorbable membrane and a bone graft material. *Practical periodontics and aesthetic dentistry* : PPAD 9:185, 1997
3. von Arx T, Cochran DL, Schenk RK, Buser D: Evaluation of a prototype trilayer membrane (PTLM) for lateral ridge augmentation: an experimental study in the canine mandible. *Int J Oral Maxillofac Surg* 31:190, 2002
4. Pauli G: Tissue safety in view of CJD and variant CJD. *Cell Tissue Banking* 6:191, 2005
5. Fishman JA: Infection in xenotransplantation. *J Card Surg* 16:363, 2001
6. Bergsma JE, Debruijn WC, Rozema FR, Bos RRM, Boering G: Late Degradation Tissue-Response to Poly(L-Lactide) Bone Plates and Screws. *Biomaterials* 16:25, 1995
7. Bostman OM: Osteolytic Changes Accompanying Degradation of Absorbable Fracture Fixation Implants. *Journal of Bone and Joint Surgery-British Volume* 73:679, 1991
8. Bostman OM: Absorbable Implants for the Fixation of Fractures. *Journal of Bone and Joint Surgery-American Volume* 73A:148, 1991
9. Bostman O, Partio E, Hirvensalo E, Rokkanen P: Foreign-Body Reactions to Polyglycolide Screws - Observations in 24/216 Malleolar Fracture Cases. *Acta Orthop Scand* 63:173, 1992
10. Bostman OM, Pihlajamaki HK, Partio EK, Rokkanen PU: Clinical Biocompatibility and Degradation of Polylevulactide Screws in the Ankle. *Clin Orthop* :101, 1995
11. Hurzeler MB, Quinones CR, Huttmacher D, Schupbach P: Guided bone regeneration around dental implants in the atrophic alveolar ridge using a bioresorbable barrier - An experimental study in the monkey. *Clin Oral Implants Res* 8:323, 1997
12. Tams J, Rozema FR, Bos RRM, Roodenburg JLN, Nikkels PCJ, Vermey A: Poly(L-lactide) bone plates and screws for internal fixation of mandibular swing osteotomies. *Int J Oral Maxillofac Surg* 25:20, 1996
13. von Arx T, Kurt B, Hardt N: Treatment of severe peri-implant bone loss using autogenous bone and a resorbable membrane - Case report and literature review. *Clin Oral Implants Res* 8:517, 1997
14. Wu LB, Ding JD: In vitro degradation of three-dimensional porous poly(D,L-lactide-co-glycolide) scaffolds for tissue engineering. *Biomaterials* 25:5821, 2004
15. Taylor MS, Daniels AU, Andriano KP, Heller J: 6 Bioabsorbable Polymers - In-Vitro Acute Toxicity of Accumulated Degradation Products. *Journal of Applied Biomaterials* 5:151, 1994
16. Van Leeuwen AC, Huddleston Slater JJR, Gielkens PFM, De Jong JR, Grijpma DW, Bos RRM: Guided bone regeneration in rat mandibular defects using resorbable poly(trimethylene carbonate) barrier membranes. *Acta Biomaterialia* 8:1422, 2012
17. Stavropoulos F, Dahlin C, Ruskin J, Johansson C: A comparative study of barrier membranes as graft protectors in the treatment of localized bone defects - An experimental study in a canine model. *Clin Oral Implants Res* 15:435, 2004
18. Amecke B, Bendix D, Entenmann G: Synthetic resorbable polymers based on glycolide, lactides, and similar monomers. :982, 1995
19. Zwahlen RA, Cheung LK, Zheng L, Chow RLK, Li T, Schuknecht B, Graetz KW, Weber FE: Comparison of two resorbable membrane systems in bone regeneration after removal of wisdom teeth: a randomized-controlled clinical pilot study. *Clin Oral Implants Res* 20:1084, 2009
20. Donos N, Kostopoulos L, Karring T: Alveolar ridge augmentation using a resorbable copolymer membrane and autogenous bone grafts - An experimental study in the rat. *Clin Oral Implants Res* 13:203, 2002
21. Pego AP, Grijpma DW, Feijen J: Enhanced mechanical properties of 1,3-trimethylene carbonate polymers and networks. *Polymer* 44:6495, 2003
22. Pego AP, Van Luyn MJA, Brouwer LA, van Wachem PB, Poot AA, Grijpma DW, Feijen J: In vivo behavior of poly(1,3-trimethylene carbonate) and copolymers of 1,3-trimethylene carbonate with D,L-lactide or epsilon-caprolactone: Degradation and tissue response. *Journal of Biomedical Materials Research Part A* 67A:1044, 2003
23. Zhang Z, Kuijter R, Bulstra SK, Grijpma DW, Feijen J: The in vivo and in vitro degradation behavior of



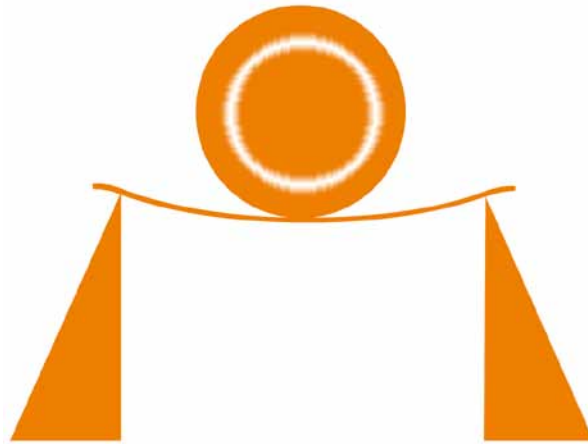


- poly(trimethylene carbonate). *Biomaterials* 27:1741, 2006
24. Gielkens PFM, Schortinghuis J, de Jong JR, Raghoebar GM, Stegenga B, Bos RRM: Vivosorb (R), Bio-Gide (R), and Gore-Tex (R) as barrier membranes in rat mandibular defects: an evaluation by microradiography and micro-CT. *Clin Oral Implants Res* 19:516, 2008
25. Schortinghuis J, Ruben JL, Meijer HJA, Bronckers ALJJ, Raghoebar GM, Stegenga B: Microradiography to evaluate bone growth into a rat mandibular defect. *Arch Oral Biol* 48:155, 2003
26. Kaban LB, Glowacki J, Murray JE: Repair of Experimental Mandibular Bony Defects in Rats. *Surg Forum* 30:519, 1979
27. Bat E, Plantinga JA, Harmsen MC, van Luyn MJA, Feijen J, Grijpma DW: In vivo behavior of trimethylene carbonate and epsilon-caprolactone-based (co)polymer networks: Degradation and tissue response. *Journal of Biomedical Materials Research Part a* 95A:940, 2010
28. von Arx T, Broggini N, Jensen SS, Bornstein MM, Schenk RK, Buser D: Membrane durability and tissue response of different bioresorbable barrier membranes: A histologic study in the rabbit calvarium. *Int J Oral Maxillofac Implants* 20:843, 2005
29. Kozlovsky A, Aboodi G, Moses O, Tal H, Artzi Z, Weinreb M, Nemcovsky CE: Bio-degradation of a resorbable collagen membrane (Bio-Gide((R))) applied in a double-layer technique in rats. *Clin Oral Implants Res* 20:1116, 2009
30. Mueller AA, Rahn BA, Gogolewski S, Leiggenger CS: Early dural reaction to polylactide in cranial defects in rabbits. *Pediatr Neurosurg* 41:285, 2005
31. Mokbel N, Bou Serhal C, Matni G, Naaman N: Healing patterns of critical size bony defects in rat following bone graft. *Oral and maxillofacial surgery* 12:73, 2008
32. Oh TJ, Meraw SJ, William EJ, Giannobile WV, Wang HL: Comparative analysis of collagen membranes for the treatment of implant dehiscence defects. *Clin Oral Implants Res* 14:80, 2003
33. Hoogveen EJ, Gielkens PFM, Schortinghuis J, Ruben JL, Huysmans M-DNJM, Stegenga B: Vivosorb (R) as a barrier membrane in rat mandibular defects. An evaluation with transversal microradiography. *Int J Oral Maxillofac Surg* 38:870, 2009
34. Lundgren AK, Lundgren D, Sennerby L, Taylor A, Gottlow J, Nyman S: Augmentation of skull bone using a bioresorbable barrier supported by autologous bone grafts - An intra-individual study in the rabbit. *Clin Oral Implants Res* 8:90, 1997
35. Lundgren AK, Sennerby L, Lundgren D, Taylor A, Gottlow J, Nyman S: Bone augmentation at titanium implants using autologous bone grafts and a bioresorbable barrier - An experimental study in the rabbit tibia. *Clin Oral Implants Res* 8:82, 1997
36. Simion M, Misitano U, Gionso L, Salvato A: Treatment of dehiscences and fenestrations around dental implants using resorbable and nonresorbable membranes associated with bone autografts: A comparative clinical study. *Int J Oral Maxillofac Implants* 12:159, 1997





# Reconstruction of orbital wall defects: recommendations based on a mathematical model



AC van Leeuwen  
SH Ong  
A Vissink  
DW Grijpma  
RRM Bos

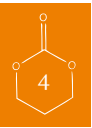*Published in: Exp Eye Res. 2012 Apr;97(1):10-8*



## ABSTRACT

This experimental study was performed to develop an engineering model of the orbital floor in which materials for orbital floor reconstruction can be evaluated in order to formulate recommendations for the choice of implant material in orbital floor reconstruction in relation to defect size. Data from the literature on the orbital floor, intraorbital pressure and traumatic changes in orbital volume causing enophthalmos were incorporated in a mathematical orbital floor engineering model. Using the engineering model, the behaviour of different reconstruction materials over a series of theoretical orbital floor defects was evaluated.

A close relation between the mechanical properties of reconstruction materials and defect size of orbital floor fractures with respect to changes in orbital volume and enophthalmos was observed when applying the engineering model. The developed orbital floor engineering model was shown to be helpful in the pre-operative evaluation of reconstruction materials for orbital floor fractures providing information on what reconstruction material can be considered appropriate for a particular orbital floor defect. Applying such a material in reconstruction of the defect is thought to prevent early onset enophthalmos.



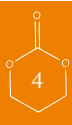## INTRODUCTION

Fractures of the orbital floor are a common result of orbital injury. These fractures can vary in size from a small crack to large defects. Fractures of the orbital floor mainly occur medial to the infraorbital groove and canal and medio caudal from the orbital roof, due to the limited thickness of the bone in this area <sup>1</sup>.

As a result of an orbital floor fracture, the volume of the orbit can increase with hypoglobus, enophthalmos and diplopia as well known consequences. Hence a most important asset in the treatment is the anatomical reconstruction of the orbital wall thereby restoring the pre-existent volume. To achieve an anatomical reconstruction a wide variety of materials has been used, ranging from autologous bone grafts to non-resorbable and resorbable alloplastic implants like e.g. titanium, polyethylene, silicone, and polylactic and -glycolic acid <sup>2</sup>. These materials differ with respect to their mechanical properties and therefore in their behaviour under pressure load. When deformation (sagging) of materials and subsequent increase of orbital volume occurs complications, like enophthalmos, may arise. There are 4 important variables that influence the deformation of a reconstruction material: (1) the size of the orbital floor defect, (2) the mechanical properties of the used reconstruction material, (3) the thickness of the reconstruction material and (4) the pressure load of the orbital content on the reconstruction material. Thus to decide (preoperative) which reconstruction material could be (most) suitable for reconstruction of an orbital floor defect, all 4 mentioned variables should be taken into account.

Previously, efforts have been made to relate the choice of reconstruction material to size and extent of orbital floor defects. Furthermore, the relation between increase of the orbital cavity volume following an orbital floor fracture and enophthalmos has been subject of investigation <sup>3-7</sup>. Al-Sukhun *et al.* even developed a three dimensional finite-element model of the human orbit, to predict orbital deformation following blunt trauma <sup>8</sup>.

However, to our knowledge none of the publications on this topic considered the relation between defect size, mechanical properties and thickness of reconstruction materials on one hand and deformation of the reconstruction material leading to enophthalmos on the other. Therefore, we developed a mathematical engineering model of the orbital floor in which materials for orbital floor reconstruction can be evaluated in order to formulate recommendations for the choice of the most suitable implant material in orbital floor reconstruction in relation to defect size. When applying this model, a surgeon is able to decide on which material(s) are suitable for reconstruction of the defect in the orbital floor taking the relation between material properties and defect size into account.



## MATERIALS AND METHODS

### *Mathematical engineering model*

Based on the models and equations of the ‘classical plate equation’ described by Roarks *et al.*, the deformation or sagging of reconstruction materials can be calculated using a simplified model (see Figure A in appendix). By assuming the implant materials and the orbital floor defects to be circular and assuming that the circular reconstruction material is freely supported along its periphery (*i.e.* not fixed to the edges of the fractured orbital floor) and that the load is homogeneously distributed, the deformation can be calculated according to <sup>9</sup>:

$$\frac{pr^4}{Et^4} = \frac{1.016}{1-\nu} * \frac{h}{t} + 0.376 \left( \frac{h}{t} \right)^3 \quad \text{Equation 1}$$

In this equation

$h$  = deformation of the disk-shaped implant at its center ( $m$ )

$p$  = applied load ( $Pa$ )

$r$  = radius of the defect of the orbital floor ( $m$ )

$\nu$  = Poisson’s ratio of the material from which the implant is prepared (assumed to be 0.3).

$t$  = thickness of the implant ( $m$ )



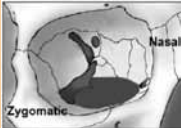

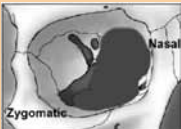
$E$  = flexural modulus of the material from which the implant is prepared ( $Pa$ )

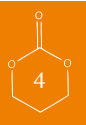(Note that the modulus determined in bending experiments is the flexural modulus, while when determined in tensile tests it is referred to as the Young’s modulus or tensile modulus. At small deformations, however, these values are quite similar.)

This equation accounts for the 4 important variables mentioned in the introduction which influence the deformation of reconstruction materials, *i.e.* size of orbital floor defect, pressure load on the implant material, mechanical properties and thickness of implant materials. The assigned values for these variables are below elucidated. To characterize the size of the orbital floor defects we used the classification of Jaquiéry *et al.* <sup>3</sup>. This classification groups the orbital floor fractures and -defects according to their size and the involvement of certain anatomical landmarks. An overview is presented in Table 1. In this scheme, the defect size of the orbital floor increases in categories 1 through 4. Category 5 defects are relatively large defects that also involve the orbital roof. In our study categories 1-4 corresponded to 1, 2.5, 4, 5.5 cm<sup>2</sup>, respectively, based on the evaluations of the orbital floor by Ploder *et al.* <sup>4</sup>. The radius ( $r$ ) of the defect was adjusted accordingly, although it should be noted that by changing the radius of the defect in the equation a virtually infinite number of defect sizes can be evaluated.

Based on the research by Cordewener *et al.* it was assumed that the pressure load ( $p$ ) on the orbital floor implant due to the load of the orbital content after trauma was about 13 mmHg (1.73 kPa) <sup>10</sup>. This assumption is based on the fact that the normal retrobulbar pressure (RBP) in humans

**Table 1. Classification of orbital floor defects according to Jaquiéry et al. Schematic frontal views of the right orbit illustrate the defect categories (Jaquiéry et al., 2007).**

Defect category	Schematic frontal view of the orbital floor	Description
Category 1		Isolated defect of the orbital floor, 1-2 cm <sup>2</sup> in size
Category 2		Defect of the orbital floor, larger than 2 cm <sup>2</sup>
Category 3		Defect of the orbital floor, larger than 2 cm <sup>2</sup> with lateral extension into the infraorbital fissure
Category 4		Defect of the entire orbital floor extending into medial wall, >4 cm <sup>2</sup> in size
Category 5		Defect of the entire orbital floor, >4 cm <sup>2</sup> in size extending into the orbital roof



ranges from 3-4.5 mmHg. This pressure can increase by approximately 2 mmHg due to functional eye movements<sup>11-13</sup>. Analogous to Cordewener *et al* we decided that a pressure load corresponding to twice the RBP taking normal eye function into account, thus 13 mmHg, could be a reasonable representation of the pressure load subjected to implant materials after trauma.

The thickness and mechanical properties of the reconstruction materials, including calvarian bone, had to be evaluated (for details see next sections), since to our knowledge there are no such data available in the literature.

When the deformation of a reconstruction material has been assessed by completing equation 1, the subsequent change in volume of the orbital cavity can be evaluated as follows: the sequence of events when an orbital floor fracture is reconstructed and deformation of the reconstruction material occurs is illustrated by Figure 1 (see page 60). Figure 1C and 1D. depict the spatial relation between the deformation of a reconstruction material and the following change in volume of the orbital cavity. The increase in volume of the orbital cavity is equal to the part of the orbital

content/eye that sinks through the orbital floor. This part can be considered to be the cap of a sphere with radius ‘R’, of which the volume can be calculated using:

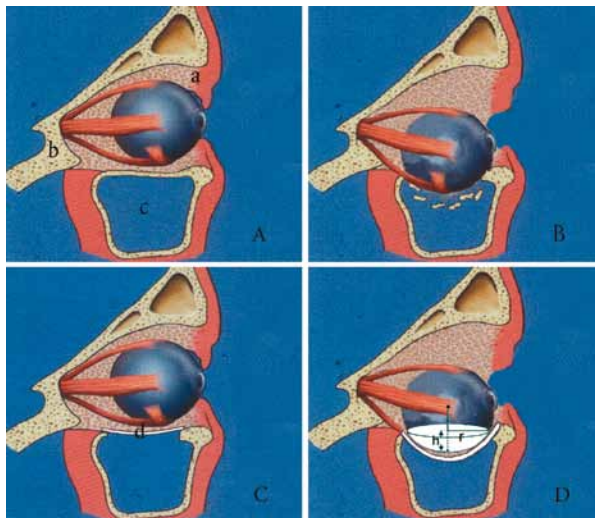
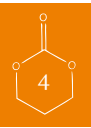$$V = \frac{1}{6} \pi h (3r^2 + h^2) \quad \text{Equation 2}$$

where,

$V$  = volume increase of the orbital cavity due to deformation of the reconstruction material ( $m^3$ )

$h$  = deformation of the disk-shaped implant ( $m$ )

$r$  = radius of the circular orbital floor defect ( $m$ )



*Figure 1:* Reconstruction of orbital floor fractures.

A) Lateral view of the normal human orbit, the orbital contents rest on the orbital floor. In the figure soft tissue (a), bone tissue (b) and the maxillary sinus (c) can be discerned.

B) As a result of trauma, the orbital floor has fractured and the contents of the orbital cavity sag into the maxillary sinus. This leads to an increase of the orbital volume and enophthalmos.

C) Restoration of the anatomy of the orbital cavity by reconstruction of the orbital floor with an implant (d).

D) Inadequate anatomical reconstruction of the orbital floor or deformation of the implant and sagging of the orbital content into the maxillary sinus can lead to an increase of the orbital volume and enophthalmos. The increase in volume of the orbital cavity, which is shown as part of a sphere, can be calculated according to equation 2.

Using equation 1 and 2, the increase in volume of the orbital cavity when deformation of the reconstruction material occurs can be calculated.

Now that we can quantify the deformation of the reconstruction material and subsequent volume increase of the orbit, it is the question to what extent volume increase may occur, before enophthalmos emerges. Evaluations in patients with blowout fractures of the orbital floor by Ploder *et al.* revealed that an increase of orbital volume of as little as  $0.7 \text{ cm}^3$  can be associated with enophthalmos<sup>4</sup>. This means that deformation of reconstruction materials leading to an increase of the orbital volume  $\geq 0.7 \text{ cm}^3$  should be avoided at all costs. Since the best possible reconstruction of the orbital floor is qualified as the pre-existent anatomical situation of the orbital floor, another question arises, namely: how to quantify this anatomical situation for use as a reference.

The most ideal situation would be that there is no deformation at all of reconstruction materials.

However, a certain degree of deformation will always occur. It is known that the orbital floor too can deform when subjected to a (sudden) increase in pressure load. Hence not every trauma leads to a fracture. Whether it bends or breaks depends on the magnitude of the increase and anatomical differences amongst humans. We used the ability of the human orbital floor to bend under a pressure load to quantify the anatomical situation by determining the mechanical properties of the human orbital floor and assessing the behaviour of the (intact) orbital floor subjected to the aforementioned pressure load of 13 mmHg. It was chosen to use the assumed traumatic pressure (13 mmHg) instead of the physiologic pressure (6.5 mmHg), because as not every trauma to the orbit and orbital floor leads to an orbital floor fracture, it still can give rise to a temporary increase in pressure due to intra orbital hematoma and swelling.

The evaluation of the thickness and mechanical properties of the human orbital floor is described in the section ‘mechanical properties’ and ‘structural analysis of orbital floor bone’.

To evaluate the orbital floor correctly, a different mathematical model needs to be used (see Figure B in appendix). As the orbital floor is part of the skeleton, the orbital floor is considered to be fixed to a support structure. The appropriate equation is <sup>9</sup>:

$$h = \frac{pr^4}{64D} \quad \text{Equation 3}$$

Where,

$h$  = deformation of the human orbital floor

$p$  = applied load

$r$  = radius of the orbital floor:  $r = 0.0132 \text{ m}$ , based on the evaluations that the entire orbital floor is  $5.5 \text{ cm}^2$ .

$\nu$  = Poisson’s ratio of the material from which the implant is prepared (assumed to be 0.3).

$D$  = flexural rigidity of the human orbital floor defined as:

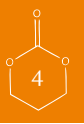$$D = \frac{Et^3}{12(1-\nu^2)} \quad \text{Equation 4}$$

In this equation

$E$  = flexural modulus of the human orbital floor

$t$  = determined thickness of the human orbital floor

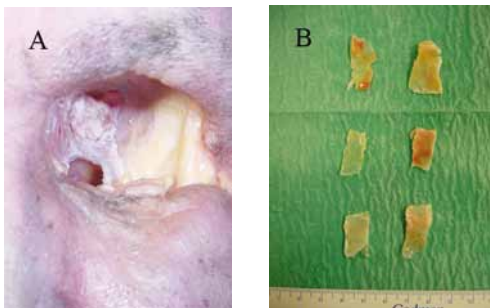
After the deformation of the orbital floor has been calculated the increase in volume of the orbital cavity is given according to equation 2 as mentioned before. The thus obtained value will serve as reference for anatomical reconstruction.



### *Orbital floor and calvarian bone harvest*

Fifteen fresh-frozen cadaveric heads (12 male and 3 female, aged  $70 \pm 8.3$  years (mean  $\pm$  SD)) were obtained from the Department of Anatomy, University of Groningen, yielding 30 orbital floors. The orbital walls of each of these 15 specimens were exposed through a transcutaneous periorbital incision and subsequent removal of the orbital content. Using a water-cooled bur (model Aesculap Elan-E) samples for mechanical testing were taken from the medial part of the orbital floor, medial of the infraorbital nerve and lateral of the medial wall, as shown in Fig. 2.

Because calvarian bone was selected as reconstruction material for evaluation, samples of the outer table of the calvarian parietal bone were taken from 5 cadavers ( $n=5$  was considered adequate sample size for measuring). The calvarian bone was exposed through a transcutaneous incision. Four 10 mm cranial bur holes were drilled with a water-cooled craniotome (model Aesculap Elan-E) and connected by a fraise. The full thickness calvarian plate was then removed and samples of the outer table were taken by splitting off the outer table from the inner table with a chisel. Both orbital floor and calvarian bone samples for mechanical testing were preserved in a solution of 0.9 wt % NaCl solution.

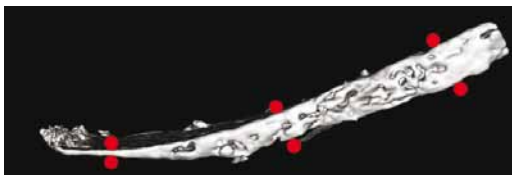


*Figure 2: A) Photograph of the harvest site of the medial part of the orbital floor in human cadavers.*

*Figure 2: B) Photograph of harvested samples of the human orbital floor. Note the thinness of the samples.*

### *Structural analysis of orbital floor bone*


Structural analysis of the collected samples of orbital floor bone was performed using micro-computed tomography (micro-CT) scanning on a GE eXplore Locus SP scanner at 8 micrometer resolution. The scan was carried out at 80 kV voltage, 80 mA current and 3000 ms exposure time, without filter. Scans were stored and thickness of samples was determined using GE MicroView Analysis Software (*freeware*). Thickness was measured at three points per sample (Fig 3).



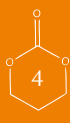*Figure 3: Lateral view of a micro-CT image of a human orbital floor sample. The red dots represent measure points for the thickness evaluation as evaluated with GE MicroView Analysis Software. The mean thickness was used for evaluation in three-point bending test.*

### *Selected reconstruction materials used for evaluation*

Besides calvarian bone, four commonly used reconstruction materials were selected (Figure 4). Both non-resorbable and resorbable alloplastic implants were selected for evaluation: Micro Orbital Titanium Mesh (KLS-Martin, Germany), ResorbX (50/50 poly-D,L-lactide) (KLS-Martin, Germany), Medpor (polyethylene) (Porex Surgical, USA), Perthese (reinforced silicone sheet) (Perouse Plastic, France). The materials were evaluated for their deformation over a series of theoretical orbital floor defects in a mathematical engineering model.



*Figure 4:* Selected commercially available implants for surgical reconstruction of the orbital floor. A) Micro Orbital Mesh, B) Resorb X, C) Medpor, D) (fibre reinforced) Perthese.



### *Mechanical properties*

The mechanical properties of the reconstruction materials including calvarian bone and the orbital floor samples were evaluated in a three-point bending test. Three-point free supported bending tests were performed on a DMA Perkin Elmer universal tensile test machine operated at a crosshead speed of 0.5 mm/min, according to ISO 178-1975 (E). Samples from orbital floors and calvarian outer table were tested to determine their flexural modulus (E-modulus). Samples from the alloplastic materials, used for orbital floor reconstruction, were tested in three-fold. The length and width of the test samples were 25 mm and 10 mm, respectively. The thickness of the test samples varied from 0.3 mm to 1.0 mm, depending on the type of reconstruction material (see Table 2). Samples from the orbital floor and calvarian bone were 15 mm and 5 mm in length and width, respectively. The thickness of the orbital floor samples was determined by micro-CT. The thickness of the calvarian bone samples was measured using a digital calliper, and ranged from 1.5-3.0 mm. The samples of the orbital floor bone were mounted in the test set-up with the side facing the maxillary sinus downwards and the orbital side facing upwards. Both the samples from the alloplastic implants as well as samples from the outer table of calvarian bone were mounted in the test set-up according to the position as used for reconstruction.




## RESULTS

### *Mechanical properties of reconstruction materials and human orbital floor*

The results for the bending test of the calvarian bone and alloplastic materials currently used for reconstruction as well as their characteristics are presented in Table 2. The values for the flexural modulus of the calvarian bone samples were parametrical distributed with mean  $2790 \pm 1338$  MPa. Regarding the flexural modulus of the alloplastic materials values ranged from  $3.93 \pm 0.01$  MPa for Perthese to  $6533 \pm 453$  MPa for Micro Orbital Titanium Mesh.

**Table 2. Mechanical properties of commercially available implants used in the surgical reconstruction of orbital floor fractures and the materials from which they are prepared. Also the mechanical properties of calvarian bone are presented.**



	Flexural modulus (MPa)	Characteristics
Micro Orbital Mesh	$6533 \pm 453$	62% porous permanent titanium mesh, thickness 0.3 mm.
Resorb X	$1283 \pm 140$	15% porous perforated resorbable PDLLA mesh, thickness 0.6 mm.
MedPore	$119 \pm 6$	50% porous permanent polyethylene sheet, thickness 0.85 mm.
Perthese	$3.9 \pm 0.1$	Non-porous, permanent polyester fiber reinforced silicone rubber sheet, thickness 1.0 mm
Calvarian bone	$2790 \pm 1338$	Cortical bone, thickness 1.5-3.0 mm

The harvest procedure resulted in 30 orbital floors of which 28 were included (samples of 1 female cadaver had to be excluded because of irregularity of the sample dimensions). The results for the bending tests and thickness evaluation by micro-CT are presented in Table 3. The determined values of the flexural modulus of the orbital floor exhibited a non-parametric distribution with median 2555 MPa and Inter Quartile Range (IQR) 1260-4550 MPa. In some instances major differences were found in mechanical properties between the right and left orbital floor in the same cadaver. Micro-CT analysis showed a parametrical distribution for the thickness of the orbital floor samples with mean thickness  $0.26 \pm 0.1$  mm.

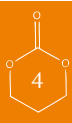### *Calculating volume increase*

Using the equations as described, a Microsoft Excel spreadsheet was constructed to facilitate the calculations for the different materials (the Microsoft Excel spreadsheet is freely available at: [www.omf-research.com](http://www.omf-research.com)). Using this spreadsheet, the deformation and the corresponding increase in volume of the orbita were calculated for the orbital floor and different reconstruction materials including calvarian bone. As stated, the evaluated defect categories 1, 2, 3 and 4 (as

**Table 3: Data on thickness, as measured by micro-CT, and flexural modulus of right and left orbital floor samples. The excluded samples are not shown.**

Specimen	Sex	Age (yr)	Orbital Floor	Thickness* (mm)	Flexural modulus (MPa)
1	M	55	Right	0.19	4600
			Left	0.14	4600
2	M	70	Right	0.22	3690
			Left	0.41	790
3	M	73	Right	0.2	2010
			Left	0.13	670
4	M	70	Right	0.27	2680
			Left	0.2	2180
5	M	72	Right	0.16	5530
			Left	0.25	2900
6	M	66	Right	0.19	4840
			Left	0.16	9170
7	M	86	Right	0.27	6870
			Left	0.32	810
8	F	69	Right	0.26	1890
			Left	0.36	730
9	M	79	Right	0.42	2270
			Left	0.31	720
10	M	64	Right	0.2	4400
			Left	0.15	5100
11	M	60	Right	0.28	2540
			Left	0.22	2340
12	M	78	Right	0.21	3850
			Left	0.39	1910
13	F	64	Right	0.47	790
			Left	0.46	3600
14	M	79	Right	0.36	1050
			Left	0.33	2570
		70±8.3		0.26±0.1	Median 2555 with IQR 1260-4550

\* Mean thickness after evaluation by micro-CT



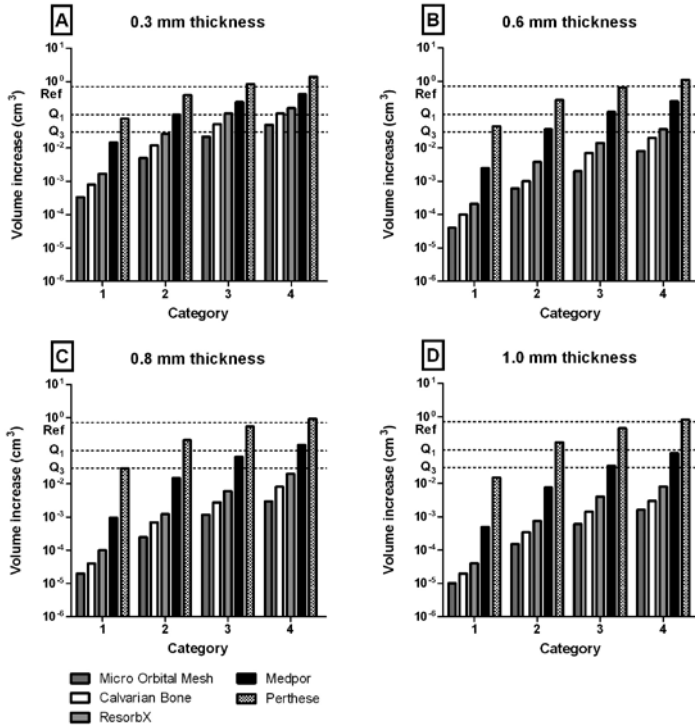


Figure 5: Relation between reconstruction material, defect size and volume increase. The dotted line 'Ref' represents the reference line corresponding to a volume increase of 0.7 cm<sup>3</sup>. Line Q1 and Q3 are the borders of the IQR. The IQR provides 'a physiological band width' which represents the volume increase of the orbital volume due to deformation of the orbital floor under pressure. Note that a volume increase below the level of the IQR is even better. Thickness of the reconstruction materials is varied from 0.3 mm to 1.0 mm, panels A-D, respectively.

described by Jaquiéry *et al*) were considered to correspond to a defect size of 1, 2.5, 4 and 5.5 cm<sup>2</sup>, respectively.

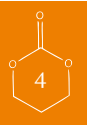The volume increase of the orbital cavity regarding the use of the different reconstruction materials over the series of (theoretically) defined (orbital floor) defect sizes is graphically presented in Figure 5. Analogous to the variation in the defect size of the theoretical orbital floor defects (Cat. 1-4) also the evaluated thickness for the different materials was varied (Fig 5, panels A-D).

Note that the model in the evaluation of the human orbital floor in all cases used the mean measured thickness of the orbital floor (0.26 mm) and the evaluated 'defect size' was always category 4 corresponding to 5.5 cm<sup>2</sup>. The volume increase was calculated for the median modulus (2550 MPa) as well as for the IQR (Q<sub>1</sub> 1260 MPa, Q<sub>3</sub> 4550 MPa). This led to a constant volume increase of the orbital volume (0.03 cm<sup>3</sup>, Q<sub>1</sub> 0.1 cm<sup>3</sup>, Q<sub>3</sub> 0.02 cm<sup>3</sup>) for the data on the human orbital floor, with the IQR creating some sort of 'physiologic band width' for an 'ideal' reconstruction. As stated, no volume increase is regarded the most ideal reconstruction.

It can be seen that the orbital floor, considered in the *fixed* situation, showed some increase in orbital volume under the applied pressure load. Regarding the reconstruction materials the Titanium Micro Orbital Mesh led to the least increase in orbital volume, closely followed by calvarian bone and ResorbX. The more flexible materials Medpor and Perthese showed bigger increases in orbital volume compared to the aforementioned materials. Depending on the evaluated thickness their performance improved. Overall, the volume of the orbital cavity increased, as expected, when the reconstruction materials were thinner. Also an enlarged defect size led to an increase in orbital cavity volume.

Table 4 shows the implementation of the data for the different implant materials regarding the reconstruction of orbital floor defects.

**Table 4: Recommendations for the choice of type and thickness of implant materials in the reconstruction of orbital floor defects. A reconstruction material with a minimal thickness of 0.3 mm is considered suitable (S) for reconstruction, when it performs within the ‘physiologic band width’ or better. When performing ‘above’ the physiologic band width or even above the maximum (0.7 cm<sup>3</sup>; the reference line) the material is considered not suitable (NS). If necessary the minimal required thickness for a reconstruction within the physiologic band width is provided. Based on figure 5 specimens with a thickness no thinner than 0.3 mm were evaluated.**



Defect category	Cat. 1	Cat. 2	Cat. 3	Cat. 4
Material				
Micro orbital titanium mesh	S	S	S	S
Calvarian bone	S	S	S	S
ResorbX	S*	S*	S*	S*
Medpor	S	S $\geq$ 0.6 mm	S $\geq$ 0.8 mm	S $\geq$ 1.0 mm
Perthese	S $\geq$ 0.3 mm	NS	NS	NS

S $\geq$ 0.3 mm: material is suitable provided that the thickness is at least 0.3 mm, etc.

S\*: only initial strength is considered, late complications can occur due to degradation of the reconstruction material

## DISCUSSION

Incorrect reconstruction of orbital wall defects can lead to volume increase of the orbital cavity with complications like enophthalmos, hypoglobus and diplopia. Hence most important is an anatomical reconstruction that ensures pre-existent orbital cavity volume. Therefore, sagging of implants must be avoided. The lack of clear guidelines for orbital floor reconstruction regarding the relation between the different implant materials and defect size can lead to peri- and postoperative

sagging of implant material. A preoperative evaluation of the behaviour of the different implant materials over the orbital floor defect could avoid (late) complications. Therefore, we developed a mathematical engineering model of the orbital floor in which all types of implant material, while taking their thickness into account, can be evaluated over a multitude of orbital floor defects. When applying this model it could be shown that most of the materials tested, with the exception of Perthese, are suitable for reconstruction of a fracture of the orbital floor (Table 4).

Although previous literature has recognized the relation between degree of enophthalmos, defect size and orbital cavity volume, this relation has, to our knowledge, not been linked in a mathematical way to the reconstruction materials used in orbital wall surgery<sup>4-6, 8</sup>. Literature mainly focused on the treatment of orbital floor fractures, on the timing of surgical intervention and whether surgical intervention is necessary<sup>14-16</sup>. Although efforts have been made to formulate recommendations concerning the choice of implant material(s) with regard to defect size, it often remained limited to statements like ‘small to medium sized defects can be reconstructed with more flexible materials (silicone, polydioxanone), while large defects are best reconstructed with rigid materials like titanium or a combination of materials’, thus leaving the surgeon (again) without an advice that takes thickness and implant material in relation to defect size into account<sup>3</sup>.

The novelty of our model is that it can assess the (minimal) thickness needed for the implant materials to limit the volume increase of the orbital cavity to the physiologic band width or below when the defect size is known. However, our model might not precisely quantify the orbital volume increase. Firstly, the orbital floor is not flat. In fact, the anatomy of the orbital floor is very complicated as the shape of the orbital floor ranges from sinusoidal to more or less flat configurations, and differs within and between individuals<sup>1, 17</sup>. However, as shown by Nagasao *et al.*, the orbital floor in children and the young and middle aged is rather flat in an anterior-posterior direction, while in the elderly there is more of a curvature<sup>17</sup>. Moreover, the paper by Nagasao *et al.* showed that the majority of orbital floor fractures occurred in young and middle age patients<sup>17</sup>. This supports our choice for using an easy to apply flat model. Secondly, the assumed pressure load on the orbital floor is based on the retrobulbar pressure which in normal conditions ranges from 3 to 4.5 mm Hg. Based on the assumptions by Cordewener *et al.* the pressure load on the orbital floor was set at 13 mm Hg. We believe that this value approaches the physiologic pressure load (due to hematoma and edema of structures of the orbital content) after a trauma. Nevertheless, the lack of more accurate data concerning the intraorbital pressure(s) and force(s) necessitated us to build the model around this estimated pressure load. Next to a physiologic pressure load, there also might be incidentally high pressure loads like, e.g., high blood pressure due to postoperative pain and Valsalva maneuvers be involved. Regarding high blood pressure, incidental increases in blood pressure are corrected for by the elasticity of the blood vessels and autoregulation system of the human body itself. Regarding the rise in pressure caused by the Valsalva maneuver, not only the pressure in the orbit is increased, but also in the tissues surrounding the orbit. These pressures act as counter-act pressures. Hence, it can be concluded that the pressure gradient over the orbital floor/walls is negligible unless the orifice of the maxillary sinus is blocked. A third deficit of the model is that the *in vivo* behaviour of the different materials cannot be predicted, again the

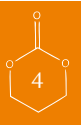


lack of accurate data on this topic is to blame. It is, however, not inconceivable that precisely the more plastic and bioactive materials act differently in the *in vivo* situation. Resorbable implants, like ResorbX e.g., lose their mechanical properties, thus strength and rigidity, during degradation. For polylactic acid derived implants reductions up to 60% of the initial values after 12 weeks of implantation are known<sup>18</sup>. This could lead to sagging and subsequent (late) enophthalmos, especially when large (cat 3-4) defects are involved. In the case of resorbable polymers it is important that the tissue formed at the site of the defect should be strong enough to withstand the pressure load of the orbital content. The model does not consider or correct for this behaviour of biodegradable implant materials, including (autologous) bone, it only evaluates materials in their initial state. This has to be recognized when reconstructions with these materials are carried out, because there is a risk for sagging once the biodegradable material has lost its mechanical properties. Nevertheless, we have the opinion that the deficits of the model theoretically not seriously affect the measured outcomes for the different materials.

Another model described in literature to test the strength of reconstructive materials for reconstruction of orbital floor defects is the model by Hwang *et al.*<sup>7</sup>. In that model of the orbital floor pre-bent reconstruction materials were evaluated for their supporting strength. With their model, the authors could show that certain materials are indeed suitable to prevent development of enophthalmos. The reconstruction materials to be tested were fixed to the anterior part of the orbit or orbital rim. However, in contrast to our model, in the model of Hwang *et al.* the reconstruction materials were not supported along the lateral, medial and posterior borders. This is a limitation of that model<sup>7</sup>. By contrast, our model presumes that the reconstruction materials are supported along their complete periphery by remaining stable parts of the damaged orbital floor. Although there are great dissimilarities between both models, both studies showed that an increase in orbital volume indeed results in enophthalmos and that the suitability of a material to restore a defect can indeed be tested a priori. However, while in our model the increase in volume of the orbit and the effect of a specific material to reduce enophthalmos can be calculated at chair side, for the model developed by Hwang *et al.* the efficacy of every material that is considered to restore the defect has to be separately examined in a laboratory setting.

From the results for the different reconstruction materials assessed by the model it can be concluded that not all materials are suitable when varying defect sizes are considered (Table 4). Surgeons should be aware of the fact that localization of the defect also plays a role in the development of enophthalmos. Defects of the posterior part of the medial orbital wall, for example, can lead to severe enophthalmos as the posterior part of the orbital wall together with the lateral orbital wall are the main support for a correct anterior projection of the globe<sup>19</sup>. By contrast, defects anterior to the equator of the globe do not influence the position of the globe and thus are not associated with development of enophthalmos.

It seems safe to treat category 1-4 fractures with titanium, bone, poly(D,L-lactide) and polyethylene, but the configuration of the fracture and the demands for the configuration of the implant material in order to achieve an anatomical reconstruction could have an effect on implant choice. Unlike titanium meshes for example that can be bent in stable configurations, this is not the case



for polyethylene. Furthermore, care should be taken when (thin) flexible materials are applied as is illustrated when silicone is used for reconstruction of category 3-4 defects. The volume increase measured due to deformation of the orbital floor samples could be considered as an ideal situation, although it should be mentioned that all materials, especially when coming in minimal thickness, will show a certain degree of volume increase due to sagging. This cannot be avoided but should be kept to a minimum.

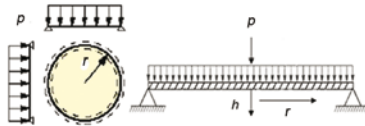
It is not the intention of the model to predict or recommend whether to treat or not to treat orbital floor fractures, nor to recommend degradable over non-degradable materials or *vice versa*. Moreover, the model can give an overview of the suitability of implant materials in relation to defect size and help to choose the appropriate (minimal) thickness of reconstruction materials in a way to minimize orbital volume increase. Therefore the proposed model could be useful in the preoperative management of orbital floor fractures by helping the surgeon to choose a suitable reconstruction material with the correct thickness. The model is, however, less suitable for secondary reconstructions. Since atrophy of the very complex musculoseptal apparatus and orbital adipose tissue are unpredictable, a correction for the relative increase in volume of the orbit is impossible. Only, in case the extent of volume decrease of the orbital content is known, it is theoretically possible to incorporate such data in our model. In addition, shaping of the reconstruction material to correct the position of the globe is “surgeon-work” and the outcomes are dependent on the skills of the surgeon.

Although the medial wall is often involved in orbital floor fractures we were not able to implement the medial wall in our model. Unlike the orbital floor, being a simple osseous layer that separates the orbit from the maxillary sinus, the medial wall is determined by different irregular honeycomb-like cells of the ethmoidal complex. Consequently, pressure loads applied to the medial wall are not uniformly distributed and therefore make it much more difficult to implement in our model. However, strengthened by the idea that if implant materials perform sufficiently in (isolated) orbital floor fractures, they will also in combined orbital floor and medial wall fractures, with respect to their mechanical properties. This makes the model theoretically suitable for the evaluation of orbital floor fractures combined with fractures of the medial wall.

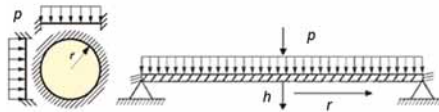
#### ACKNOWLEDGEMENTS

Gratitude is expressed to KLS-Martin, Porex Surgical and Perouse Plastic for providing us with the reconstruction materials. Dr F.A. Holtkamp is acknowledged for his assistance in preparing the figures.

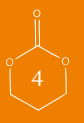## APPENDIX



*Figure A:* Technical illustration of a model in which the deformation of the reconstruction materials can be evaluated (top view and lateral view). Note that here the reconstruction material is freely supported (this is indicated by the dotted line shown in the axial view of the model). 'p'= applied pressure/pressure load; 'h'=deformation of reconstruction material; 'r'=radius of orbital floor defect radius.



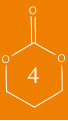*Figure B:* Technical illustration of the model in which the deformation of the orbital floor is evaluated. Note that here the orbital floor sample is not freely-supported, but fixed at the edges (this is indicated by the shaded areas in the axial and lateral views of the model)





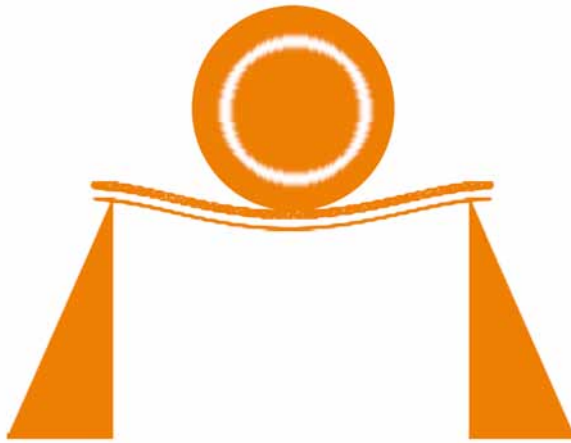
## REFERENCES

1. Metzger MC, Schoen R, Tetzlaff R, Weyer N, Rafii A, Gellrich N-, Schmelzeisen R: Topographical CT-data analysis of the human orbital floor. *Int J Oral Maxillofac Surg* 36:45, 2007
2. Potter JK, Ellis E: Biomaterials for reconstruction of the internal orbit. *Journal of Oral and Maxillofacial Surgery* 62:1280, 2004
3. Jaquiere C, Aeppli C, Cornelius P, Palmowsky A, Kunz C, Hammer B: Reconstruction of orbital wall defects: critical review of 72 patients. *Int J Oral Maxillofac Surg* 36:193, 2007
4. Ploder O, Klug C, Voracek M, Burggasser G, Czerny C: Evaluation of computer-based area and volume measurement from coronal computed tomography scans in isolated blowout fractures of the orbital floor. *Journal of Oral and Maxillofacial Surgery* 60:1267, 2002
5. Ahn HB, Ryu WY, Yoo KW, Park WC, Rho SH, Lee JH, Choi SS: Prediction of enophthalmos by computer-based volume measurement of orbital fractures in a Korean population. *Ophthal Plast Reconstr Surg* 24:36, 2008
6. Cunningham LL, Peterson GP, Haug RH: The relationship between enophthalmos, linear displacement, and volume change in experimentally recreated orbital fractures. *Journal of Oral and Maxillofacial Surgery* 63:1169, 2005
7. Hwang K, Kim DH: Comparison of the Supporting Strength of a Poly-L-Lactic Acid Sheet and Porous Polyethylene (Medpor) for the Reconstruction of Orbital Floor Fractures. *J Craniofac Surg* 21:847, 2010
8. Al-Sukhun J, Lindqvist C, Kontio R: Modelling of orbital deformation using finite-element analysis. *Journal of the Royal Society Interface* 3:255, 2006
9. Young WC: Roark's formulas for stress and strain . New York, McGraw-Hill Book Co, 1989
10. Cordewener FW, Rozema FR, Joziase CAP, Bos RRM, Boering G, Pennings AJ: Poly(96l/4d-Lactide) Implants for Repair of Orbital Floor Defects - an In-Vitro Study of the Material Properties in a Simulation of the Human Orbit. *Journal of Materials Science-Materials in Medicine* 6:561, 1995
11. Simonsz HJ, Harting F, Dewaal BJ, Verbeeten BWJM: Sideways Displacement and Curved Path of Recti Eye-Muscles. *Arch Ophthalmol* 103:124, 1985
12. Moses RA, Lurie P, Wette R: Horizontal Gaze Position Effect on Intraocular-Pressure. *Invest Ophthalmol Vis Sci* 22:551, 1982
13. Moses RA, Carniglia PE, Grodzki WJ, Moses J: Proptosis and Increase of Intraocular-Pressure in Voluntary Lid Fissure Widening. *Invest Ophthalmol Vis Sci* 25:989, 1984
14. Bowers JF: The Management of Blow-Out Fracture of the Orbital Floor. *Surv Ophthalmol* 40:237, 1964
15. Burnstine MA: Clinical recommendations for repair of isolated orbital floor fractures - An evidence-based analysis. *Ophthalmology* 109:1207, 2002
16. Kontio R, Lindqvist C: Management of orbital fractures. *Oral Maxillofac Surg Clin North Am* 21:209, 2009
17. Nagasao T, Hikosaka M, Morotomi T, Nagasao M, Ogawa K, Nakajima T: Analysis of the orbital floor morphology. *Journal of Cranio-Maxillofacial Surgery* 35:112, 2007
18. Heidemann W, Jeschkeit S, Ruffieux K, Fischer JH, Wagner M, Kruger G, Wintermantel E, Gerlach KL: Degradation of poly(D,L)lactide implants of calciumphosphates with or without addition in vivo. *Biomaterials* 22:2371, 2001
19. Hammer B., 2002. Orbital Reconstruction, in: Greenberg, A.M., Prein, J. (Eds.), *Cranio-maxillofacial Reconstructive and Corrective Bone Surgery Principles of Internal Fixation Using the AO/ASIF Technique*. Springer-Verlag, New York, pp. 478-482.





Composite materials based on poly(trimethylene carbonate) and  $\beta$ -tricalcium phosphate for orbital floor and wall reconstruction



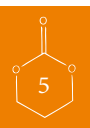AC van Leeuwen  
RRM Bos  
DW Grijpma

*Published in: J Biomed Mater Res B Appl Biomater. 2012 Aug;100(6):1610-20*

## ABSTRACT

Poly(trimethylene carbonate) and  $\beta$ -tricalcium phosphate (PTMC/ $\beta$ -TCP) composite materials were prepared by coprecipitation and compression moulding. The effect of different amounts of the ceramic component (15 and 30 vol%) on the properties was investigated. The effect of lamination with minimal amounts of poly(D,L-lactide) (PDLLA) was assessed as well. It was hypothesized that these composites would be suitable for orbital floor reconstruction, as the polymer component resorbs enzymatically without the formation of acidic compounds, while the ceramic component could induce bone formation.

To assess their suitability as load bearing devices, the flexural properties of the prepared (laminated) composites were determined in three point bending experiments and compared with those of currently used reconstruction devices. The flexural modulus of PTMC composites increased from 6 MPa to 17 MPa when introducing 30 vol%  $\beta$ -TCP. A laminate of this composite with PDLLA (with respective layer thicknesses of 0.8 and 0.2 mm) had a flexural modulus of 64 MPa. When evaluated in a mathematical engineering model of the orbital floor the (laminated) composites materials showed similar behaviour compared to the currently used materials. The results suggest that from a mechanical point of view these (laminated) composite sheets should be well suited for use in orbital floor reconstruction.



## INTRODUCTION

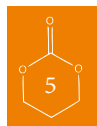Fractures of the internal orbit are common facial injuries. They can range in size from small cracks in the orbital floor to extensive multiple-wall defects. Over the years, many different materials have been used to reconstruct the orbit. Autologous bone is often used, but stable synthetic materials like titanium, polytetrafluoroethylene (PTFE), polyethylene (PE) and silicone rubbers (Silastic, Perthes) have been employed to manufacture orbital floor implants<sup>1-4</sup>. There is also much interest in the use of degradable and resorbable implant materials such as poly(lactide)s and poly(glycolide)s<sup>5,6</sup>, since they possess a distinct advantage over the life-long risk of complications characteristic for non-resorbable materials.

Ideally, bone is regenerated during healing of the fractured orbit. However, with the currently used materials, this is only the case when autologous bone is used. To develop a synthetic material that will lead to regeneration of bone in bony defects, osteoinductive or osteoconductive properties are required. Composite systems comprising a biodegradable polymer matrix and a bioactive ceramic filler may be interesting substitutes for autologous bone, and find application in reconstruction of the orbital floor. In this regard,  $\beta$ -tricalcium phosphate ( $\text{Ca}_3(\text{PO}_4)_2$ ) ( $\beta$ -TCP) is especially interesting. It is a biocompatible calcium phosphate which occurs naturally in the human body and has a chemical composition that corresponds to the inorganic phase of bone (which constitutes 60-70% of human bone)<sup>7,8</sup>. It has been used as a bone filler and bone substitute material, and previous studies have shown its osteoconductive and osteoinductive potential<sup>9,10</sup>.

A number of calcium phosphate composites, mainly based on poly(lactide)s or copolymers of lactide and glycolide, have been developed for other applications<sup>11,12</sup>. As it is known that lactide and glycolide (co)polymers can produce significant amounts of acidic compounds during degradation in the body, and that calcium phosphate ceramics and more importantly bone dissolve in acidic environments, it can be expected that these polymers will not be the most suitable matrix materials<sup>13,14</sup>.

We are aiming at developing a resorbable composite material for orbital floor reconstruction that does take full advantage of the bone forming potential of the ceramic component. Composite materials based on poly(trimethylene carbonate) (PTMC) and  $\beta$ -tricalcium phosphate are being evaluated. Poly(trimethylene carbonate) is an amorphous polymer with a glass transition temperature of approximately  $-17^\circ\text{C}$  and a relatively low elastic modulus of 5 to 7 MPa at room temperature. The polymer can be crosslinked into a creep-resistant and form-stable network by gamma-irradiation<sup>15</sup>. Most importantly, PTMC is a biocompatible resorbable polymer that degrades enzymatically *in vivo* without the formation of acidic degradation products by a surface erosion process<sup>16,17</sup>. The trimethylene carbonate monomer and polymer are well-known in the medical field, and have been used in surgical sutures and tissue engineering scaffolds<sup>18,19</sup>.

In this paper the preparation and characterization of composite materials based on PTMC and  $\beta$ -TCP is described, and comparisons are made with currently used orbital floor reconstruction devices. Although implant materials with low elasticity modulus values (such as silicone rubber which has an elasticity modulus similar to that of PTMC) have been quite effective in reconstructing (small) orbital floor defects<sup>2,3</sup>, the reconstruction of large defects might necessitate the use



of more rigid materials. For this we also developed laminated structures of PTMC and  $\beta$ -TCP composites with poly(D,L-lactide) (the E-modulus of PDLA is much higher and approximately 2700 MPa). In preparing these structures, however, we ensured that the PDLA component was in minimal contact with the calcium phosphate particles, and that only small amounts of PDLA are used.

## MATERIALS AND METHODS

### *Materials*

Polymerization grade 1,3-trimethylene carbonate (TMC) was obtained from Boehringer Ingelheim, Germany. Stannous octoate ( $\text{SnOct}_2$  from Sigma, USA) was used as received. High molecular weight poly(D,L-lactide) (PDLA, with a 50/50 molar ratio of L- to D-lactide) was obtained from Purac Biochem, the Netherlands. Calcium phosphate ceramic powder ( $\beta$ -TCP) sintered at 1300 °C and sieved to particle sizes smaller than 50  $\mu\text{m}$  was obtained from Cam Bioceramics, the Netherlands. The used solvents were of technical grade and were purchased from Biosolve, the Netherlands.

### *Preparation of composites and laminates*

Poly(trimethylene carbonate) (PTMC) was prepared by ring opening polymerization of trimethylene carbonate at 130 °C for a period of 3 days. Stannous octoate was used as a catalyst at a concentration of  $2 \times 10^{-4}$  mol per mol of monomer. Analysis of the synthesized polymer by proton nuclear magnetic resonance ( $^1\text{H-NMR}$ ) (300MHz, Varian Innova, USA), gel permeation chromatography (GPC, Viscotek, USA) and differential scanning calorimetry (DSC) (Perkin Elmer Pyris 1) according to standardized procedures indicated that high molecular weight polymer had been synthesized<sup>15</sup>. GPC measurements showed that  $M_w=279000$  and  $M_n=232000$  g/mol, while NMR indicated that the monomer conversion was more than 98 %. The glass transition temperature of this amorphous polymer was approximately -17 °C, as thermal analysis showed.

Composites of PTMC with  $\beta$ -TCP particles were prepared by dissolving the PTMC in chloroform at a concentration of 5 g/100 ml, after which the  $\beta$ -TCP was added and uniformly dispersed in the solution. The dispersion was then precipitated into a five-fold excess of ethanol 100%. The composite was collected and dried under vacuum at room temperature until constant weight was reached. PTMC composites containing up to 30 vol% (corresponding to 50 wt%) of  $\beta$ -TCP were prepared.

After drying, the composite precipitate was compression moulded into sheets and test specimens at 140 °C and a pressure of 3.0 MPa (31 kg/cm<sup>2</sup>) using a Carver model 3851-0 laboratory press (Carver, USA). Stainless steel moulds measuring 0.8 and 1 mm in thickness were used.

The poly(D,L-lactide) was also of high molecular weight, with  $M_w=234000$  g/mol and  $M_n=178000$  g/mol. NMR indicated that the residual monomer content was less than 1 %. The glassy polymer was also amorphous, and had a glass transition temperature of approximately 52 °C. This polymer was also compression moulded into 0.2 and 1 mm thick specimens at 140 °C.

Laminates of the PTMC/ $\beta$ -TCP composites and PDLA were prepared by compression moulding PDLA sheets onto sheets of the composite material at 140 °C. The composite layer

was 0.8 mm thick, while the PDLA was 0.2 mm thick. After compression moulding, the laminated sheets were 1 mm thick.

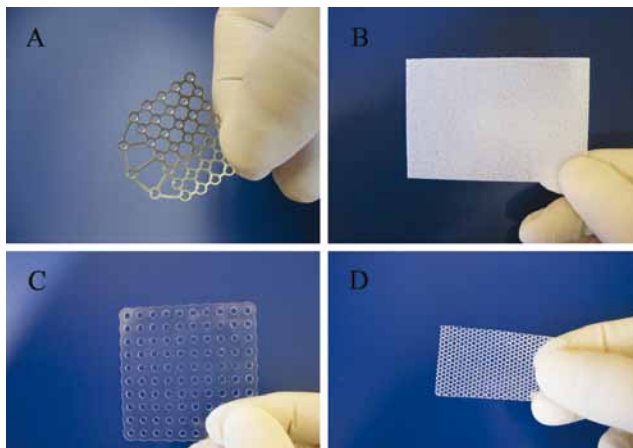
### *Mechanical properties of composites and laminates*

Three-point bending tests were performed on rectangular-shaped specimens measuring 1x25x40 mm using a Zwick Z020 universal testing machine (Ulm, Germany) according to ISO178-1975(E). The distance between the supports was 16 mm, and the testing machine was operated at a crosshead speed of 0.5 mm/min. The flexural modulus of compression moulded PTMC and PDLA polymers, composites and laminated sheets, and of high density polyethylene (Sigma-Aldrich, The Netherlands) and silicone rubber elastomer (Sylgard 184, Dow Corning, USA) were determined in triplicate at room temperature. In a number of cases the flexural strength and the elongation at the maximum strength were also determined.

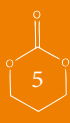Flexural analysis was also performed using a dynamic mechanical analysis instrument (DMA, Perkin Elmer 7e, The Netherlands). With this instrument it is possible to determine the flexural properties of materials using much smaller specimens. In this way also the flexural properties of devices for orbital floor reconstruction and human orbital floor bone were evaluated.

### *Devices for orbital floor reconstruction*

For comparison with our composites and laminates, four commercially available devices used in orbital floor reconstruction were selected: Micro Orbital Mesh (0.3 mm thick titanium) and ResorbX (perforated PDLA, 0.6 mm thick) both from KLS-Martin, Germany. Medpor (0.8 mm thick porous polyethylene from Porex Surgical Inc, USA) and Perthese (1.0 mm thick reinforced silicone rubber sheet from Perouse Plastic, France). The mechanical properties of these medical devices and the materials they are prepared from were also determined as described above, and compared to those of the prepared PTMC composites and laminate. The appearance of these implants is presented in Figure 1.



*Figure 1.* Commercially available implants used in surgical reconstruction of the orbital floor. A) Micro Orbital Mesh, B) Medpor, C) Resorb X, D) (fibre reinforced) Perthese.





### Scanning electron microscopy

The calcium phosphate filler particles and the particle distribution in the compression moulded composite sheets were analyzed by scanning electron microscopy (SEM, LEO 1550 Gemini field emission SEM, Germany). To be able to analyse cross-sections of the composites, the specimens were snap-frozen in liquid nitrogen. Samples were sputter-coated with gold.

## RESULTS AND DISCUSSION

In comparison to the volume of the orbit, the orbital floor is relatively thin and therefore quite prone to fracture in case of trauma. In first studies we evaluated the characteristics of orbital floor samples taken from fresh frozen human cadavers<sup>30</sup>. We found that the thickness of the bone varied between 0.14 and 0.42 mm, the mean thickness was 0.26 mm. In three-point bending experiments conducted on small orbital floor samples we determined an average flexural modulus of 2.7 GPa, with values ranging between 800 MPa and 5.0 GPa. The average flexural strength was 49 MPa, with values ranging between 15 and 131 MPa.

In many cases surgery is required to prevent enophthalmos followed by gaze restriction, and a variety of alloplastic implants has been used to repair orbital floor and wall fractures. The implants

**Table 1. Properties of commercially available implants used in the surgical reconstruction of orbital floor fractures and the materials from which they are prepared. Implants are often available in different thicknesses, surgeons choose thicker implants for larger defects.**

	Flexural modulus (MPa)	Characteristics
ResorbX	1283 ±140	15 % porous perforated resorbable PDLA mesh, available in thicknesses of 0.30-1.00 mm. The determined flexural modulus and -strength of PDLA are 2781±90 MPa and 77.9 ± 9.3 MPa, respectively.
Micro Orbital Mesh	6533±453	62% porous permanent titanium mesh, available in a thickness of 0.30 mm only. The flexural modulus of titanium is 110 ± 1.4 GPa, its flexural strength is 1477 ± 94 MPa. <sup>31</sup>
Perthese	3.93±0.01	Non-porous, permanent polyester fiber reinforced silicone rubber sheet, available in thicknesses of 0.175-1.00 mm The tensile modulus and -strength of silicone rubber are 2.6±0.2 MPa and 8.7±0.2MPa, respectively. <sup>32</sup>
MedPore	119±6	50% porous permanent polyethylene sheet, available in thicknesses of 0.25 to 3.00 mm. The determined flexural modulus and -strength of polyethylene are 861±66 MPa and 27.2 ± 1.99 MPa, respectively.

and devices used do not only differ in the material they are manufactured from, they can also have quite distinct structural features such as different thicknesses, porosities and rigidities. Table 1 gives an overview of selected commercially available orbital floor reconstruction implants, and their characteristic properties. Measurement of the flexural properties in three-point bending tests showed that the most rigid implants are those that are prepared from the stiffest materials. The table also shows the significant effect of porosity in reducing the stiffness of the device. It is clear that to be able to span a larger defect, a less stiff implant will need to be thicker than a more rigid one. Furthermore, implants are often available in different thicknesses, and surgeons in general choose thicker implants for the reconstruction of larger defects.

In repairing the fractured orbital floor, correct anatomical reconstruction without an increase in volume of the orbital cavity is of great importance. This is schematically shown in Figures 2A, B and C. An increase in volume of the orbital cavity, either immediately during surgery or at longer times, could lead to enophthalmus. Enophthalmus is defined as the (relative) difference in the position of the globes along an anteroposterior axis. At the same time, a downwards movement (hypophthalmus) can also occur. Enophthalmus  $\geq 2\text{mm}$  is generally accepted as critical and requires reconstruction of the orbital floor. In their evaluations, Ploder *et al.*<sup>21</sup> observed that increases in volume of the orbital cavity varying from as little as 0.7 to 3.0 cm<sup>3</sup> have lead to critical enophthalmus and vision impairment, and aesthetic dilemmas. (Note that on average the volume of the orbital cavity is 27 ml, ranging from 23 to 31 ml.<sup>22</sup>) Figure 2D illustrates the inadequate repair of a (large) orbital floor defect with a badly chosen implant.

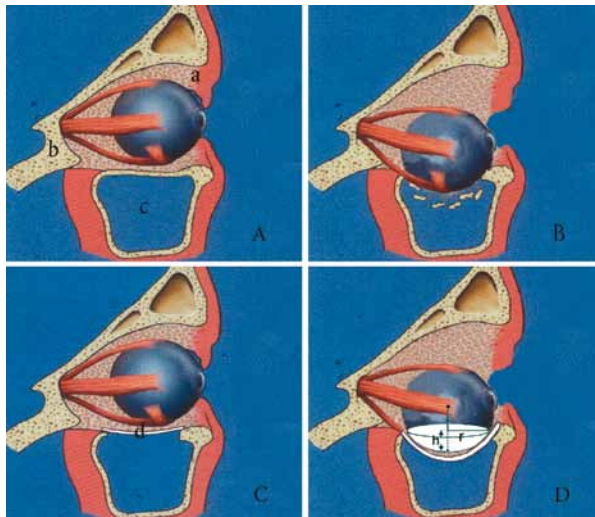


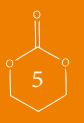
Figure 2. Reconstruction of orbital floor fractures.

A) Lateral view of the normal human orbit, the orbital contents rest on the orbital floor. In the figure soft tissue (a), bone tissue (b) and the maxillary sinus (c) can be discerned.

B) As a result of trauma, the orbital floor has fractured and the contents of the orbital cavity sag into the maxillary sinus. This leads to an increase of the orbital volume and enophthalmus.

C) Restoration of the anatomy of the orbital cavity by reconstruction of the orbital floor with an implant (d).


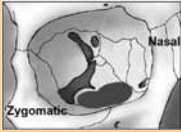
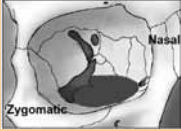


D) Inadequate anatomical reconstruction of the orbital floor or deformation of the implant and sagging of the orbital content into the maxillary sinus can lead to an increase of the orbital volume and enophthalmus. The increase in volume of the orbital cavity, which is shown as part of a sphere, can be calculated according to equation 2.



To rationally select a suitable implant for the repair of an orbital floor fracture, it is necessary to be able to estimate the deformation of the orbital floor implant and the accompanying change in the orbital volume. At present there are no clinical guidelines regarding characteristics of the implant materials and devices that should be used for orbital floor fracture repair, especially in relation to the size of the defect. The available literature mainly concerns the timing of surgical intervention, rather than emphasizing the importance of the defect size<sup>1,23,24</sup>.

Orbital floor defects of different sizes can be categorized according to the classification of Jaquiéry *et al.*<sup>25</sup>. This classification groups the orbital floor fractures and -defects according to their size and the involvement of certain anatomical orbital structures. An overview is presented in Table 2. In this scheme, the defect size of the orbital floor increases in categories 1 through 4. Category 5 defects are relatively large defects that also involve the orbital roof.

**Table 2. Classification of orbital floor defects according to Jaquiéry et al.<sup>25</sup> Schematic frontal views of the right orbit illustrate the defect categories.**

Defect category	Schematic frontal view of the orbital floor	Description
Category 1		Isolated defect of the orbital floor, 1-2 cm <sup>2</sup> in size
Category 2		Defect of the orbital floor, larger than 2 cm <sup>2</sup>
Category 3		Defect of the orbital floor, larger than 2 cm <sup>2</sup> with lateral extension into the infraorbital fissure
Category 4		Defect of the entire orbital floor extending into medial wall, >4 cm <sup>2</sup> in size
Category 5		Defect of the entire orbital floor, >4 cm <sup>2</sup> in size extending into the orbital roof

The change in volume of the orbital cavity due to deformation or sagging of the implant can be estimated by assuming the implant and the orbital floor defect to be circular. It should be realized, however, that traumatically induced orbital floor and wall defects in general have irregularly shaped borders due to the energy of the trauma. In a first approximation, we have assumed the defects to be circular. If the disk-shaped implant is freely supported along its periphery and the load is homogeneously distributed, then the deformation can be calculated according to <sup>26</sup>:

$$\frac{pr^4}{Et^4} = \frac{1.016}{1-\nu} * \frac{h}{t} + 0.376 \left( \frac{h}{t} \right)^3 \quad \text{Equation 1}$$

In this equation

$h$  = deformation of the disk-shaped implant at its center ( $m$ )

$p$  = applied load ( $Pa$ )

$r$  = radius of the defect of the orbital floor ( $m$ )

$\nu$  = Poisson's ratio of the material from which the implant is prepared (assumed to be 0.3).

$t$  = thickness of the implant ( $m$ )

$E$  = flexural modulus of the material from which the implant is prepared ( $Pa$ )

(Note that the modulus determined in bending experiments is the flexural modulus, while when determined in tensile tests it is referred to as the Young's modulus or tensile modulus. At small deformations, however, these values are quite similar.)

The increase in volume of the orbital cavity is equal to the part of the eye that sinks through the orbital floor. This can be considered to be the cap of a sphere with radius  $R$ , of which the volume can be calculated using:

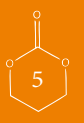
$$V = \frac{1}{6} \pi h (3r^2 + h^2) \quad \text{Equation 2}$$

where,

$V$  = volume increase of the orbital cavity due to deformation of the reconstruction material ( $m^3$ )

$h$  = deformation of the disk-shaped implant ( $m$ )

$r$  = radius of the circular orbital floor defect ( $m$ )



Using these expressions, the increase in volume of the orbital cavity pictured in Figure 2D can be calculated.

For our purposes, it was assumed that the stress on the orbital floor implant due to the load of the orbital content upon trauma was 13 mmHg (1.73 kPa)<sup>27</sup>. Furthermore, this stress was considered to be constant and uniformly distributed. To compare the behaviour of different implants, the deformation of a disk-shaped implant and the corresponding increase in volume of the orbital cavity were calculated for circular orbital floor defects of different sizes. In our calculations the different defect categories 1, 2, 3 and 4 according to Jaquiéry were considered to correspond to a defect size of 1, 2.5, 4 and 5.5 cm<sup>2</sup>, respectively. These defect sizes are based on measurements of the surface area of the orbital floor<sup>28</sup>.

The estimated changes in orbital volume after restoration of orbital floor defects of different sizes with currently available orbital floor repair implants are presented in Figure 3. It is clear from the figure that the increase in volume of the orbital cavity will significantly depend on the category and size of the orbital floor fracture, the implant material and the thickness of the implant. As mentioned before, the increase in volume of the orbital cavity should be less than 0.7 cm<sup>3</sup>.

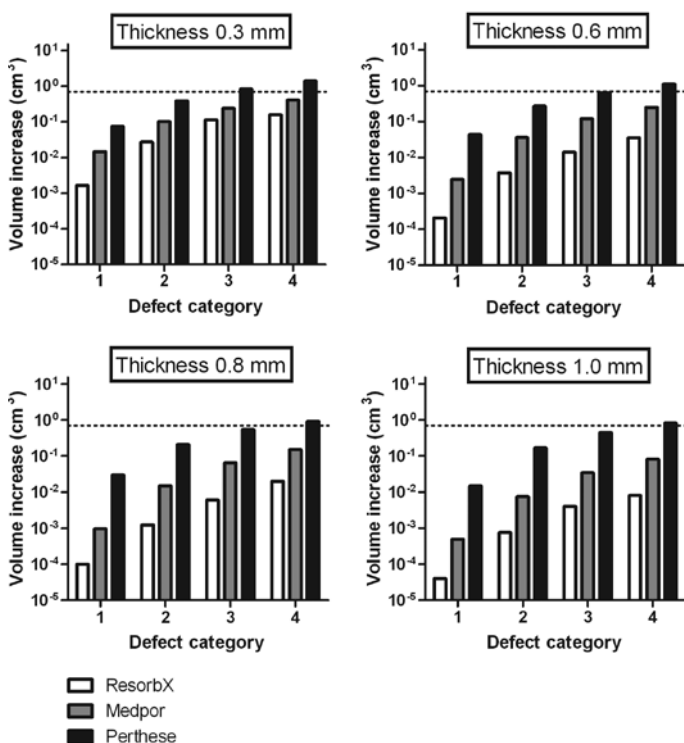


Figure 3: Estimated changes in volume of the orbital cavity after reconstruction of orbital floor defects of different sizes with several currently used implants. The defects are classified according to Jaquiéry et al. The dotted line corresponds to a volume increase of the orbital cavity of 0.7 cm<sup>3</sup>.

(It was assumed in the calculations that the implants were freely-supported and disk-shaped, the defects were circular and the stress on the implant due to the contents of the orbit was 1.73 kPa, see text.)

A titanium Micro Orbital Mesh implant, has more than adequate rigidity to be able to reconstruct defects of all categories. After (autologous) bone, titanium meshes are the preferred synthetic materials used. With use of ResorbX or Medpor implants with a thickness of 0.3 to 1.0 mm thick, it should be possible to reconstruct orbital floor defects of categories 1 through 4 successfully. When using Perthese implants with a thickness of 0.3 mm thickness, it should be possible to reconstruct defects of category 1 and 2. But when reconstructing category 4 orbital floor defects, Perthese implants thicker than 1.0 mm are to be recommended. These differences in applicability are due to the large differences in elastic modulus of the different implant materials as shown in Table 1. Given these considerations, it is surprising that manufacturers of implants recommend their materials as being suitable for orbital floor reconstruction without specifying the thickness of the implant in relation to the size of the defect. Especially in the case of a flexible material like Perthese. (See the instructions for use of Perthese, Resorb X and Medpor.) From a clinical point of view, it should be noted that (relatively thick implants prepared from) reinforced silicone materials like Perthese are unlikely to be used when large (*e.g.* Cat. 4-5) defects are concerned. These defects are anatomically complex and therefore technically difficult to reconstruct. In such cases, thinner implants prepared from more rigid materials are generally applied. Our model leads to recommendations on the appropriate (minimal) thicknesses of a reconstruction material to be used, and could prove useful in the preoperative management of orbital floor and wall fractures as it can aid the surgeon in guiding his choice of a specific implant device.

In manners similar to flexible silicone rubber implants, implant devices prepared from PTMC can also be expected to be suitable for orbital floor defect repair. The elasticity modulus of PTMC is of the same order of magnitude as that of silicone rubber, but a composite material with a bioactive ceramic  $\beta$ -TCP phase that enhances bone formation will have significantly higher modulus values.

We prepared PTMC/ $\beta$ -TCP composites by dispersing  $\beta$ -TCP in a PTMC solution, followed by precipitation in a non-solvent, drying and compression moulding. The sizes of the  $\beta$ -TCP particles ranged from 10 to 50 $\mu$ m, their size distribution was normal with a an average size of 29.6 $\mu$ m and a standard deviation of 7.2 $\mu$ m. Figure 4A shows an SEM image of the used particles. Note the porosity of the particles, which is the result of the sintering process used during their manufacturing.

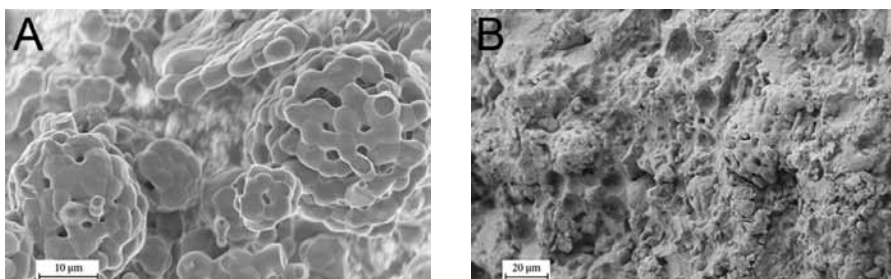
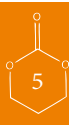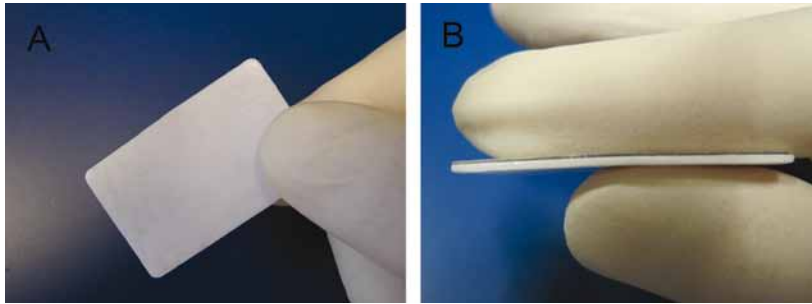


Figure 4: High resolution SEM images of the  $\beta$ -TCP particles used in preparing the PTMC/ $\beta$ -TCP composites (A) and their distribution in the polymer matrix (B). Note the porosity of the particles which is the result of the sintering process. The image of the cross-section of the PTMC/ $\beta$ -TCP composite contains 30 vol% of homogeneously distributed particles.



In Figure 4B, an image is shown of the cross-section of a PTMC composite containing 30 vol%  $\beta$ -TCP. The method used to prepare the composite led to a homogeneous distribution of the particles in the polymer matrix without the formation of agglomerates. Figure 5 shows photographs of the prepared PTMC/ $\beta$ -TCP composite as well as the laminated PTMC/ $\beta$ -TCP composite.



*Figure 5:* Images of the prepared PTMC/ $\beta$ -TCP composite (A) and the laminated PTMC/ $\beta$ -TCP composite sheets (B). As a result of the presence of  $\beta$ -TCP particles, the sheets appear white. Figure B shows the thin layer of PDLLA in the laminated PTMC/ $\beta$ -TCP composite sheet. To prepare the laminate, a sheet of PDLLA (0.2 mm) was compression moulded onto a PTMC/ $\beta$ -TCP composite sheet (0.8 mm).

The mechanical properties of PTMC and  $\beta$ -TCP composites containing 0 vol%, 15 vol% and 30 vol%  $\beta$ -TCP were determined in three-point bending experiments, the data is presented in Table 3. It can be seen that with increasing fraction of  $\beta$ -TCP the flexural modulus and the flexural strength of the PTMC materials increased. The flexural strengths increased from 0.4 MPa for PTMC to 1.1 MPa for the composite containing 30 vol%  $\beta$ -TCP, the corresponding elastic modulus values of the composite increased from 5.5 MPa to 17 MPa.

Although the elastic modulus of the PTMC composites were lower than those of Micro Orbital Mesh, ResorbX and Medpor implants, their rigidity was up to four times higher than that of fibre reinforced Perthes.

**Table 3.** The effect of the  $\beta$ -TCP content on the flexural properties of composites of PTMC and  $\beta$ -TCP microparticles. The mechanical properties of 1 mm thick compression moulded specimens were determined in triplicate, values are presented as averages  $\pm$  standard deviations.

	$\beta$ -TCP (vol%)	Flexural modulus (MPa)	Maximal flexural strength (MPa)
PTMC	0	5.5 $\pm$ 0.4	0.38 $\pm$ 0.03
PTMC and $\beta$ -TCP composite	15	8.2 $\pm$ 0.8	0.55 $\pm$ 0.08
PTMC and $\beta$ -TCP composite	30	17.0 $\pm$ 0.4	1.13 $\pm$ 0.07

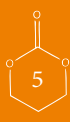The suitability of implants prepared from PTMC and PTMC/ $\beta$ -TCP composites for orbital floor reconstruction was also assessed by calculating the changes in the volume of the orbital cavity for the different defect categories and implant thicknesses, as previously described for the commercial devices. Figure 6 (see page 88) shows that the thinnest (0.3 mm thick) PTMC materials should perform satisfactorily in repairing orbital floor defects of categories 1 to 3. This is not the case for Perthese implants. For the larger category 4 orbital defects, the PTMC composite materials that contain 15 or 30 vol%  $\beta$ -TCP can be expected to perform very well as here too the change in the volume of the orbital cavity remains well below 0.7 cm<sup>3</sup>. The calculated change in volume significantly decreases with increasing amounts of  $\beta$ -TCP in the composites.

**Table 4.** The effect of lamination with PDLLA on the flexural properties of PTMC and composite sheets of PTMC and  $\beta$ -TCP (15 and 30 % vol). Bonded laminates comprising a 0.8 mm thick PTMC or PTMC/ $\beta$ -TCP layer and a 0.2 mm thick PDLLA layer were prepared by compression moulding at 140 °C. Measurements were conducted in triplicate, values are presented as averages  $\pm$  standard deviations.

	$\beta$ -TCP (vol%)	Flexural modulus (MPa)	Maximal flexural strength (MPa)
PTMC and PDLLA laminate	0	43.8 $\pm$ 0.6	2.7 $\pm$ 0.4
PTMC/ $\beta$ -TCP composite and PDLLA laminate	15	54.3 $\pm$ 0.8	3.3 $\pm$ 0.5
PTMC/ $\beta$ -TCP composite and PDLLA laminate	30	64.5 $\pm$ 0.7	3.8 $\pm$ 0.4

Even smaller volume changes in the orbital cavity can be realized when the composite materials from which the implants are to be prepared are laminated with PDLLA. As the elasticity modulus of PDLLA is very much higher than that of PTMC and the PTMC composite, even a relatively thin layer will significantly influence the mechanical properties of the laminate. This can be of great importance when the largest defects, such as orbital floor defects of category 4 and 5, are to be bridged by the implant. Furthermore, it should be realized that these materials are degradable and will resorb in time. Therefore, also changes in mechanical properties and load bearing capacities of the devices in time should be accounted for. Additionally, it is desirable to implant the smallest amounts of material possible.

In Table 4 the effect of a 0.2 mm thick PDLLA layer laminated onto 0.8 mm thick sheets of PTMC and PTMC/ $\beta$ -TCP composites is illustrated. It can be seen that the flexural strengths as well as the flexural modulus values of the reconstruction materials are considerably increased.





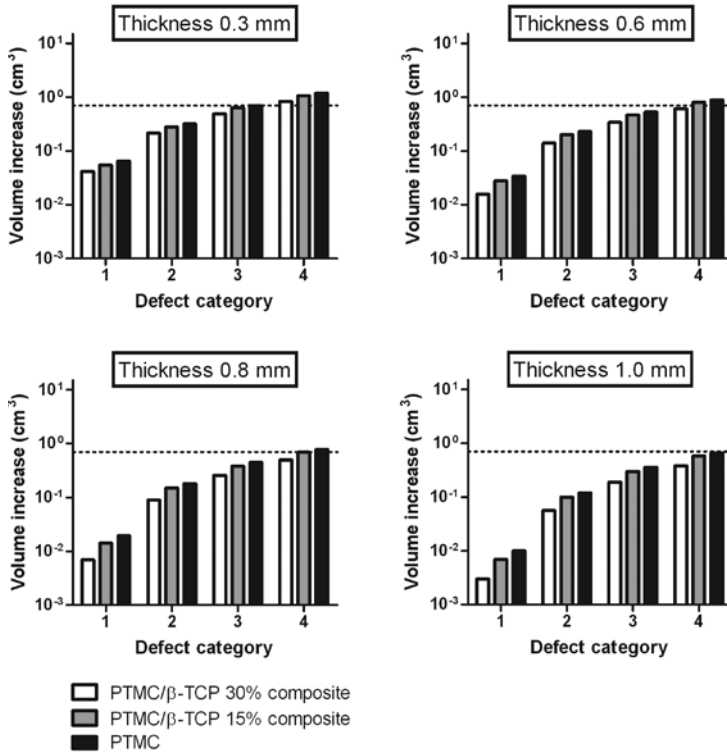
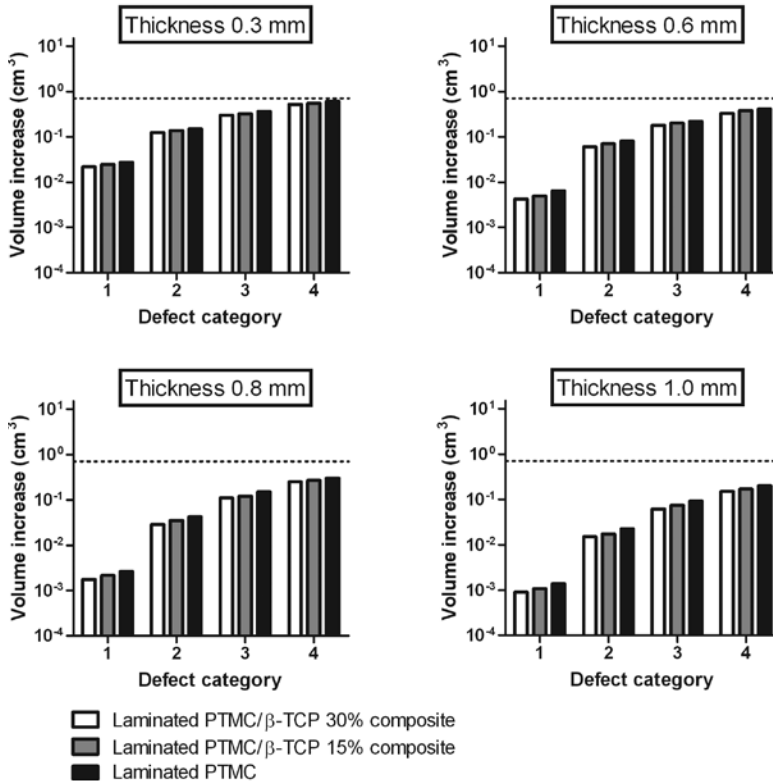


Figure 6. Estimated changes in volume of the orbital cavity after reconstruction of orbital floor defects of different sizes with implants prepared from PTMC and PTMC/ $\beta$ -TCP composites containing 15 and 30 vol% of the ceramic microparticles. The defects are classified according to Jaquiéry et al. The dotted line corresponds to a volume increase of the orbital cavity of 0.7 cm<sup>3</sup>.

(It was assumed in the calculations that the implants were freely-supported and disk-shaped, the defects were circular and the stress on the implant due to the contents of the orbit was 1.73 kPa, see text.)

Figure 7 shows that now in all cases, also for the thinnest specimens and the largest defects, the calculated changes in volume of the orbital cavity are very much smaller than 0.7 cm<sup>3</sup>.

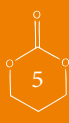When using degradable implants, the formed fibrous capsule that remains after the degradation process might by itself not be sufficiently rigid to prevent late enophthalmos. This is especially relevant when reconstructing large orbital floor defects<sup>21, 29, 30</sup>. Therefore, new bone formation during healing of the fractured orbit is highly desired. In future research we will evaluate (laminated) calcium phosphate composites with PTMC *in vivo*, and assess their orbital floor repair and their bone-forming capacity. For this a large animal model, in which the anatomy of the bony maxillofacial region resembles that of the human, will be used.



*Figure 7.* Estimated changes in volume of the orbital cavity after reconstruction of orbital floor defects of different sizes with laminates prepared from PTMC or PTMC/ $\beta$ -TCP (15 and 30 vol%  $\beta$ -TCP microparticles) composite and PDLA. The thicknesses of the layers of the laminate were respectively 0.8 mm for PTMC or PTMC/ $\beta$ -TCP composite layer and 0.2 mm for the PDLA layer. The defects are classified according to Jacquierey et al. (It was assumed in the calculations that the implants were freely-supported and disk-shaped, the defects were circular and the stress on the implant due to the contents of the orbit was 1.73 kPa, see text.)

## CONCLUSIONS

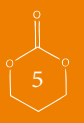
Homogenous composite materials based on PTMC and  $\beta$ -TCP microparticles can readily be prepared by coprecipitation methods and compression moulding. Using relevant anatomical and clinical data, as well as engineering models describing the deformation of disk-shaped materials, we were able to assess the performance of these novel materials and compare them with currently available reconstruction materials. Our evaluations show that for fractures of the orbital floor, the largest defects should ideally be reconstructed using implants with a relatively high rigidity. This can be achieved by using materials with a high modulus of elasticity or by using relatively thick specimens. Implants 0.8 to 1 mm thick prepared from PTMC/ $\beta$ -TCP composites and laminates of these composites with PDLA can be expected to perform well in orbital floor reconstruction, as they perform better or equal to currently used implant materials like silicone, PTFE and titanium. This is also the case for large class 3 and 4 defects.



## REFERENCES

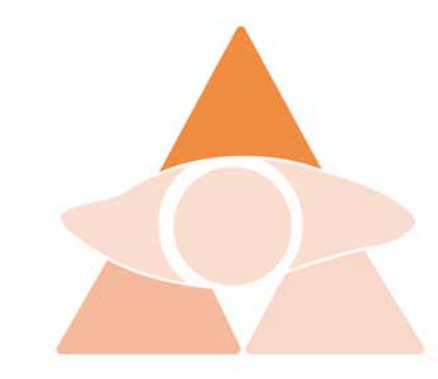
1. Ellis E, Messo E: Use of nonresorbable alloplastic implants for internal orbital reconstruction. *Journal of Oral and Maxillofacial Surgery* 62:873, 2004
2. Bowers JF: The Management of Blow-Out Fracture of the Orbital Floor. *Surv Ophthalmol* 40:237, 1964
3. Lerman S, Cramer LM: Blowout Fractures of Orbit. *Am J Ophthalmol* 57:264, 1964
4. Lange WA: Fractures of the Orbit; the Anatomy, Diagnosis and Treatment. *Plast Reconstr Surg* 35:26, 1965
5. Heidemann W, Gerlach KL: Anwendung eines resorbierbaren Osteosynthesesystems aus Poly(D,L)Laktid in der Mund- Kiefer- und Gesichtschirurgie. 57:50-53, 2002
6. Eppley BL, Prevel CD: Nonmetallic fixation in traumatic midfacial fractures. *J Craniofac Surg* 8:103, 1997
7. Gaasbeek RDA, Toonen HG, van Heerwaarden RJ, Buma P: Mechanism of bone incorporation of beta-TCP bone substitute in open wedge tibial osteotomy in patients. *Biomaterials* 26:6713, 2005
8. Hench LL, Best S. Ceramics, glasses and glass-ceramics. In: Ratner BD, editor. *Biomaterials Science: An Introduction to Materials in Medicine*. London: Elsevier; 2004. pp 153–166.
9. Zerbo IR, Bronckers ALJJ, de Lange GL, van Beek GJ, Burger EH: Histology of human alveolar bone regeneration with a porous tricalcium phosphate - A report of two cases. *Clin Oral Implants Res* 12:379, 2001
10. Yuan HP, De Bruijn JD, Li YB, Feng JQ, Yang ZJ, De Groot K, Zhang XD: Bone formation induced by calcium phosphate ceramics in soft tissue of dogs: a comparative study between porous alpha-TCP and beta-TCP. *Journal of Materials Science-Materials in Medicine* 12:7, 2001
11. Haaparanta A, Haimi S, Ella V, Hopper N, Miettinen S, Suuronen R, Kellomaki M: Porous polylactide/beta-tricalcium phosphate composite scaffolds for tissue engineering applications. *Journal of Tissue Engineering and Regenerative Medicine* 4:366, 2010
12. Kim SS, Park MS, Jeon O, Choi CY, Kim BS: Poly(lactide-co-glycolide)/hydroxyapatite composite scaffolds for bone tissue engineering. *Biomaterials* 27:1399, 2006
13. Wu LB, Ding JD: In vitro degradation of three-dimensional porous poly(D,L-lactide-co-glycolide) scaffolds for tissue engineering. *Biomaterials* 25:5821, 2004
14. Taylor MS, Daniels AU, Andriano KP, Heller J: 6 Bioabsorbable Polymers - In-Vitro Acute Toxicity of Accumulated Degradation Products. *Journal of Applied Biomaterials* 5:151, 1994
15. Pego AP, Grijpma DW, Feijen J: Enhanced mechanical properties of 1,3-trimethylene carbonate polymers and networks. *Polymer* 44:6495, 2003
16. Pego AP, Van Luyn MJA, Brouwer LA, van Wachem PB, Poot AA, Grijpma DW, Feijen J: In vivo behavior of poly(1,3-trimethylene carbonate) and copolymers of 1,3-trimethylene carbonate with D,L-lactide or epsilon-caprolactone: Degradation and tissue response. *Journal of Biomedical Materials Research Part a* 67A:1044, 2003
17. Zhang Z, Kuijter R, Bulstra SK, Grijpma DW, Feijen J: The in vivo and in vitro degradation behavior of poly(trimethylene carbonate). *Biomaterials* 27:1741, 2006
18. Pego AP, Vleggeert-Lankamp CLAM, Deenen M, Lakke EAJF, Grijpma DW, Poot AA, Marani E, Feijen J: Adhesion and growth of human schwann cells on trimethylene carbonate (co)polymers. *Journal of Biomedical Materials Research Part a* 67A:876, 2003
19. Amecke B, Bendix D, Entenmann G. Synthetic resorbable polymers based on glycolide, lactides, and similar monomers. In: Wise DL, editor. *Encyclopedic Handbook of Biomaterials and Bioengineering*. New York: Marcel Dekker; 1995. pp 982–983.
20. Van Leeuwen AC, Ong SH, Vissink A, Grijpma DW, Bos RRM: Reconstruction of orbital floor fractures: recommendations based on a mathematical model. *Exp Eye Res.* 97:10, 2012
21. Ploder O, Klug C, Voracek M, Burggasser G, Czerny C: Evaluation of computer-based area and volume measurement from coronal computed tomography scans in isolated blowout fractures of the orbital floor. *Journal of Oral and Maxillofacial Surgery* 60:1267, 2002
22. Lang J, Wachsmuth W. Kopf: Gehirn- und Augenschädel. In: Metz J, editor. *Praktische Anatomie: ein Lehr- und Hilfsbuch der anatomischen Grundlagen ärztlichen Handelns. Erster Band Teil Ib*. New York: Springer-Verlag; 1979. pp 432–435.
23. Burnstine MA: Clinical recommendations for repair of isolated orbital floor fractures - An evidence-based analysis. *Ophthalmology* 109:1207, 2002

24. Potter JK, Ellis E: Biomaterials for reconstruction of the internal orbit. *Journal of Oral and Maxillofacial Surgery* 62:1280, 2004
25. Jaquier C, Aeppli C, Cornelius P, Palmowsky A, Kunz C, Hammer B: Reconstruction of orbital wall defects: critical review of 72 patients. *Int J Oral Maxillofac Surg* 36:193, 2007
26. Young WC: Roark's formulas for stress and strain . New York, McGraw-Hill Book Co, 1989
27. Cordewener FW, Rozema FR, Joziase CAP, Bos RRM, Boering G, Pennings AJ: Poly(96l/4d-Lactide) Implants for Repair of Orbital Floor Defects - an In-Vitro Study of the Material Properties in a Simulation of the Human Orbit. *Journal of Materials Science-Materials in Medicine* 6:561, 1995
28. Ploder O, Klug C, Voracek M, Backfrieder W, Tschabitscher M, Czerny C, Baumann A: A computer-based method for calculation of orbital floor fractures from coronal computed tomography scans. *Journal of Oral and Maxillofacial Surgery* 59:1437, 2001
29. Ahn HB, Ryu WY, Yoo KW, Park WC, Rho SH, Lee JH, Choi SS: Prediction of enophthalmos by computer-based volume measurement of orbital fractures in a Korean population. *Ophthal Plast Reconstr Surg* 24:36, 2008
30. Cunningham LL, Peterson GP, Haug RH: The relationship between enophthalmos, linear displacement, and volume change in experimentally recreated orbital fractures. *Journal of Oral and Maxillofacial Surgery* 63:1169, 2005
31. Stewardson DA, Shortall AC, Marquis PM, Lumley PJ: The flexural properties of endodontic post materials. *Dental Materials* 26:730, 2010
32. Schüller-Ravoo S. Advanced microstructures based on poly(trimethylenecarbonate): Microfabrication and stereolithography. 2011 University of Twente, Enschede, PhD Thesis.





Poly(trimethylene carbonate) and biphasic calcium phosphate composites for orbital floor reconstruction:  
a feasibility study in sheep



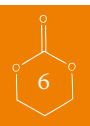AC van Leeuwen  
H Yuan  
G Passanisi  
WJ van der Meer  
JD de Bruijn  
TG van Kooten  
DW Grijpma  
RRM Bos

*Submitted*

## ABSTRACT

In the treatment of orbital floor fractures, bone is ideally regenerated. The materials currently used for orbital floor reconstruction do not lead to the regeneration of bone. Our objective was to render polymeric materials based on poly(trimethylene carbonate) (PTMC) osteoinductive, and to evaluate their suitability for use in orbital floor reconstruction. For this purpose, osteoinductive biphasic calcium phosphate (BCP) particles were introduced into a polymeric PTMC matrix. Composite sheets containing 50 wt% BCP particles were prepared. Also laminates with poly(D,L-lactide) (PDLLA) were prepared by compression moulding PDLLA films onto the composite sheets. After sterilization by gamma irradiation, the sheets were used to reconstruct surgically-created orbital floor defects in sheep. The bone inducing potential of the different implants was assessed upon intramuscular implantation.

The performance of the implants in orbital floor reconstruction was assessed by cone beam computed tomography (CBCT). Histological evaluation revealed that in the orbital and intramuscular implantations of BCP containing specimens, bone formation could be seen after 3 and 9 months. Analysis of the CBCT scans showed that the composite PTMC sheets and the laminated composite sheets performed well in orbital floor reconstruction. It is concluded that PTMC/BCP composites and PTMC/BCP composites laminated with PDLLA have osteoinductive properties and seem suitable for use in orbital floor reconstruction.



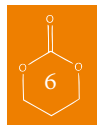## INTRODUCTION

Orbital floor fractures are a common result of injury to the orbit. Herniation of orbital fat and/or entrapment of ocular muscle can be avoided by reconstructing the bony orbital floor. The use of autologous bone grafts is considered to be the 'gold standard' for repair and reconstruction of bony defects in orbital floor fractures. However, the method has several disadvantages, among which are: the extra operation time, the accompanying donor-site morbidity and the poor predictability of the resorption rate of autologous bone<sup>1</sup>. To avoid these drawbacks, implants prepared from (non-resorbable) materials like titanium, polytetrafluoroethylene, polyethylene and silicone rubbers have been applied in the treatment of orbital floor fractures<sup>2,3</sup>. Being able to use biodegradable and resorbable implant materials would be of great interest, as the use of permanent implants is associated with the life-long risk of infections. However, after degradation of biodegradable materials, the formed fibrous capsule that remains might not be sufficiently rigid to prevent late enopthalmos. This is especially relevant when reconstructing large orbital floor defects<sup>4-6</sup>. New bone formation during healing of the fractured orbit would therefore be highly desired. Poly(lactide)s and poly(glycolide)s are biodegradable polymers that have most often been investigated<sup>7,8</sup>. Upon degradation of these polymers, however, acidic compounds are formed. These compounds can have a detrimental effect on surrounding (bone) tissues, and hinder the formation of new bone<sup>9,10</sup>.

As a result of its osteogenic and osteoinductive properties, bone formation in orbital floor reconstruction currently only occurs when autologous bone is used. To obtain a synthetic implant material that leads to formation of bone in bony defects, osteoinductive or osteoconductive properties are required. It has been shown in several animal studies, that calcium phosphate ceramics with specific surface microstructures have osteoinductive properties<sup>11-17</sup>. Unfortunately, these (sintered) ceramic materials are brittle and difficult to obtain in a specific shape. To overcome these drawbacks, composite materials have been prepared by introducing the calcium phosphates into polymeric matrices<sup>18</sup>. This was shown to improve both mechanical- and handling properties. Hence, composite materials based on bone-inducing microstructured biphasic calcium phosphate (BCP) and a polymeric matrix of poly(trimethylene carbonate) (PTMC) seem interesting.

Poly(trimethylene carbonate) (PTMC) is an amorphous polymer that degrades enzymatically *in vivo* by a surface erosion process without the formation of acidic degradation products<sup>19,20</sup>. The polymer has not been shown to calcify or lead to the formation of new bone upon implantation. It is hypothesized that the composite materials will have osteoinductive properties as the BCP will become exposed during degradation of the PTMC matrix.

This paper describes the preparation and *in vivo* evaluation of composite materials based on microstructured BCP and PTMC. Although implant materials with (relative) low elasticity modulus values such as silicone have been quite effective in reconstructing (small) orbital floor defects<sup>3</sup>, the reconstruction of large defects might necessitate the use of more rigid materials. To allow the reconstruction of large orbital floor defects, we also prepared laminates of the composite materials with a single thin layer of poly(D,L-lactide) (PDLA). This has been described in more detail in previous work<sup>21</sup>.





## MATERIALS AND METHODS

### *Materials*

Polymerization grade 1,3-trimethylene carbonate (TMC) was obtained from Boehringer Ingelheim, Germany. Stannous octoate ( $\text{SnOct}_2$  from Sigma, USA) was used as received. High molecular weight poly(D,L-lactide) (PDLLA, with a 50/50 molar ratio of L- to D-lactide) was obtained from Purac Biochem, the Netherlands, and used as received.

Biphasic calcium phosphate ceramic, ( $20 \pm 3\%$  tricalcium phosphate (TCP) and  $80 \pm 3\%$  hydroxyl apatite (HA)), which was sintered at  $1150^\circ\text{C}$  for 8 hours and sieved to particle sizes 45-150  $\mu\text{m}$  according to Habibovic et al.<sup>14</sup>, was obtained from Xpand Biotechnology, the Netherlands.

The microstructure of the surface of the BCP particles results from the microporosity and the small grain size<sup>22</sup>. The particles had a microporosity of 17% and a specific surface of  $1.0 \text{ m}^2/\text{g}$ . The used solvents were of technical grade and purchased from Biosolve, the Netherlands.

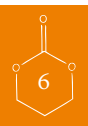### *Preparation of composites and laminates*

Poly(trimethylene carbonate) (PTMC) was prepared by ring opening polymerization of trimethylene carbonate at  $130^\circ\text{C}$  for a period of 3 days. Stannous octoate was used as a catalyst at a concentration of  $2 \times 10^{-4}$  mol per mol of monomer. Analysis of the synthesized polymer by proton nuclear magnetic resonance ( $^1\text{H-NMR}$ ), gel permeation chromatography (GPC) and differential scanning calorimetry (DSC) according to procedures described earlier<sup>23</sup> indicated that high molecular weight polymer had been synthesized. GPC measurements showed that  $M_w = 414000 \text{ g/mol}$  and  $M_n = 316000 \text{ g/mol}$ , while NMR indicated that monomer conversion was more than 98%. The glass transition temperature of this amorphous polymer was approximately  $-17^\circ\text{C}$ , as thermal analysis showed.

The PTMC polymer was purified by dissolving in chloroform and precipitation into an excess of ethanol. Similarly, composites of PTMC with BCP particles were prepared by dissolving PTMC in chloroform at a concentration of 5 g/100 ml, after which the BCP was added and dispersed in the solution by magnetic stirring. The uniform dispersion was then precipitated into a five-fold excess of ethanol 100%. The composite precipitate was collected and dried under vacuum at room temperature until constant weight was reached. PTMC/BCP composites containing 50 wt% (corresponding to 30 vol%) of BCP were prepared.

After drying, the purified PTMC and the composite precipitate were compression moulded into 1.5 mm thick sheets at  $140^\circ\text{C}$  and a pressure of 3.0 MPa using a Carver model 3851-0 laboratory press (Carver, USA). The poly(D,L-lactide) was also of high molecular weight, and had an  $M_w = 234000 \text{ g/mol}$  and an  $M_n = 178000 \text{ g/mol}$ . NMR indicated that the residual monomer content was less than 1%. The glassy polymer was also amorphous, and had a glass transition temperature of approximately  $52^\circ\text{C}$ . This polymer was compression moulded into 0.3 mm thick sheets at  $140^\circ\text{C}$ .

Laminates of the PTMC/BCP composites and PDLLA were prepared by compression moulding PDLLA sheets onto sheets of the composite material at  $140^\circ\text{C}$ . The PTMC/BCP composite layer was 1.2 mm thick, while the PDLLA layer was 0.3 mm thick.



The prepared sheets were then sealed under vacuum and exposed to 25 kGy gamma irradiation from a <sup>60</sup>Co source (Isotron BV, Ede, The Netherlands) for sterilization.

### *Experimental design of the animal study*

All procedures performed on the animals were done according to international standards on animal welfare as well as being compliant with the Animal Research Committee of the University Medical Center Groningen.

Ten full-grown female Dutch Texel sheep were operated on and (evenly) divided into two groups. The first group had a follow-up of 3 months, the second a follow-up of 9 months. Critical size defects measuring 2.5-3.0 cm<sup>2</sup><sup>6</sup>, were created in both orbital floors and reconstructed with: 1) a PTMC sheet, 2) a composite (PTMC/BCP) sheet or 3) a laminated composite (PTMC/BCP-PDLLA) sheet. Regarding the laminated composite, the PDLLA layer faced the maxillary sinus.

To be able to distinguish between osteoinductivity and osteoconductivity, bone formation is generally evaluated in a non-bony environment<sup>14, 24-26</sup>. To assess osteoinductive properties of our materials, samples (1.5 mm x 10 mm Ø) of the prepared sheets, as well as 1 ml of the used BCP particles, were implanted intramuscularly in the back of the sheep. An overview of the performed implantations is provided in Table 1.

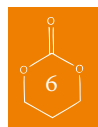**Table 1: Overview of implantations and implantation sites for the experimental 3 and 9 month implantation groups.**

Implantation material	3 months	9 months
BCP particles	IM: n=5	IM: n=5
PTMC	OF: n=3 IM: n=3	OF: n=3 IM: n=3
PTMC/BCP composite	OF: n=4 IM: n=4	OF: n=4 IM: n=4
PTMC/BCP-PDLLA laminated composite	OF: n=3 IM: n=3	OF: n=3 IM: n=3

**OF: orbital floor**

**IM: intramuscular**

To determine the position of the reconstructed orbital floor, all sheep were evaluated by cone-beam computed tomography (CBCT) 1 week before and 1 week after surgery, and at the time of termination. To monitor bone formation over time, fluorochrome markers were administered at 3, 6 and 9 weeks after surgery and at 30, 33 and 36 weeks for respectively the 3- and the 9 month group. Bone formation was evaluated by histology and histomorphometry of non-decalcified sections using epifluorescent confocal and conventional light microscopy.



### *Surgical procedure and fluorochrome labelling*

Ten adult full-grown female Dutch Texel sheep, aged 24–36 months, were acquired and allowed to acclimatize for two weeks. The surgical procedures were performed under general anaesthesia. After the subciliar area was shaved and disinfected, both orbital floors were exposed using an infraorbital approach. The periosteum was elevated and the floor was fractured using a burr and/or a chisel. Bone fragments were removed from the defect site. The bony defects created were approximately circular and measured 2.5–3.0 cm<sup>2</sup> in size. Then the orbital floor was reconstructed using one of the implant materials (PTMC, PTMC/BCP composite or laminated PTMC/BCP-PDLLA composite sheet). The size of the implant was cut with a scissor to fit the orbit, while care was taken to ensure that the defect was completely covered. In this first study, implants were fixed with one titanium screw (1.5 x 3.5 mm, KLS-Martin, Germany) to prevent dislocation. After reconstruction, the orbital periosteum was incised to mimic a traumatic situation (the incision allowed the orbital fat and musculature to prolapse into the orbit). The wound was closed in layers with resorbable sutures (Polyglactin 910, Ethicon, USA). At the same time, samples were implanted intramuscularly in the paraspinal muscles. The muscle fascia was closed with non-resorbable sutures to mark the different implantation sites in the back (Polypropylene, Ethicon, USA). The other layers were closed with resorbable sutures. Prior to surgery amoxicillin (15 mg/kg) was administered and continued for 6 days postoperative. Buprenorphin was administered for peri- and postoperative pain relief.

Fluorochrome markers were administered at the previously mentioned time points prior to termination. Calcein Green (10 mg/kg intravenously, Sigma, The Netherlands) was administered at 3 weeks and at 30 weeks, Xylenol Orange (100 mg/kg intravenously, Sigma, The Netherlands) at 6 weeks and at 33 weeks and Oxytetracyclin (Engemycine 32 mg/kg intramuscularly, Mycofarm, The Netherlands) at 9 weeks and at 36 weeks after surgery. NaHCO<sub>3</sub> and saline solutions were used as solvents. After 3 and 9 months follow-up, the animals were sacrificed by injecting an overdose of pentobarbital (Organon, The Netherlands), and the implantation areas were retrieved and fixed in a 4% phosphate-buffered formaline solution.

### *Histological preparation*

The fixed samples were rinsed with phosphate buffered solution (PBS), dehydrated in a series of ethanol solutions (70%, 80%, 90%, 96%, 100% x2) and embedded in methyl methacrylate (LTI, The Netherlands). Using a modified diamond saw<sup>27</sup> (Leica SP1600, Leica Microsystems, Germany), histological sections (10–20 µm thick) were made along the plane perpendicular to the orbital floor. The tissue samples of the intramuscularly implanted materials were sawed parallel to the long axis of the implants. Sections for light microscopy (Nikon Eclipse E200, Japan) observation were stained with 1% methylene blue (Sigma-Aldrich, The Netherlands) and 0.3% basic fuchsin (Sigma-Aldrich) solutions. Sections for epifluorescent confocal laser microscopy (Leica TCS SP2, Leica, Germany) observation were not stained. Epifluorescent data was collected with 20x oil immersion objective, including transmitted light detection. The peak absorption (abs.) and emission (em.) wavelengths where: 351/364 nm abs. and 560 nm em., 543 nm abs. and 580



nm em., 488 nm abs. and 517 nm em., for respectively Tetracycline, Xylenol Orange and Calcein. These are the optimal settings. This means that, contrary to conventional fluorescent microscopy, the fluorescence of Oxytetracycline, Xylenol Orange and Calcein is respectively blue, red and green coloured. (Note that these settings also allow to distinguish between the fluorescence of Tetracycline in blue and the co-localization of Xylenol Orange and Calcein in yellow).

### *Histomorphometry and statistics*

Images of the stained sections for histomorphometric analysis were made using a slide scanner (Dimage Scan Elite 5400 II, Konica Minolta Photo Imaging Inc, Japan). Histomorphometry was performed using Adobe Photoshop Elements 4.0 software. Briefly, the implant area was selected as the region of interest (ROI) and the corresponding number of pixels registered. Then both BCP particles and mineralized bone were pseudo-colored and the resulting numbers of pixels used to calculate the percentage of bone formation in the available space (available space is defined as the space between the BCP particles assuming the polymer has resorbed) as:

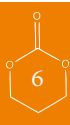$$\text{Bone formation \%} = \frac{\text{Bonepixels}}{\text{ROI} - \text{BCPpixels}} \times 100\%$$

Averages and standard deviations were calculated for the percentage of bone formed in the available area.

### *Radiological examination*

Cone-beam computed tomography (CBCT) scanning was performed preoperatively to assess the position of the orbital floor. The position of the reconstructed orbital floor was assessed postoperatively and at the time of termination. Scanning was carried out under general anaesthesia with propofol (1.5 mg/kg). The CBCT images were acquired with an i-CAT Scanner (i-CAT, Imaging Sciences International, USA) with a 0.3 mm voxel size and a 170 mm field of view. Each scan was performed with the head of the animal in the same, reproducible position using the laser guide of the scanner as a reference.

Using Mimics Software (Materialise Dental, Belgium), 3-dimensional (3D) reconstructions of all individual scans were made. In each dataset, a threshold was applied to depict the bone. The preoperative (intact) orbital floors, and the postoperative reconstructed orbital floors (*i.e.* the orbital floor implants) and the reconstructed orbital floors at the time of termination, were then selected as region of interest (ROI). Using Geomagic Studio Software (Geomagic GmbH, Germany), the 3D reconstructed scans were aligned and registered with the preoperative 3D reconstructed scans using an iterative closest-point registration algorithm. The deviations between the datasets are presented using a sliding colour scale to visualize the differences between the surface of the orbital floors at the different time points (see for example Figure 7). For each implant, the mean negative deformation at the location of the defect was calculated.



The negative deformation of the different implants at the different time points was used to calculate the increase of the orbital volume using <sup>28</sup>:

$$V_{increase} = \frac{1}{6} \pi h (3r^2 + h^2) \quad (2)$$

where,

$V_{increase}$  = volume increase of the orbital cavity due to deformation of the reconstruction material ( $m^3$ )

$h$  = deformation of the disk-shaped implant ( $m$ )

$r = 0.0098$  (m); this is the radius of a circular orbital floor defect measuring  $3.0 \text{ cm}^2$

The changes in orbital volume give an indication of the suitability of the different implants for reconstruction of orbital floor defects in sheep. An increase in orbital volume of more than  $0.7 \text{ cm}^3$  is considered the maximum allowable volume increase, as a larger increase in volume can lead to enophthalmos <sup>28,29</sup>

## RESULTS

During the *in vivo* experiment, none of the sheep showed signs of infection or adverse tissue reactions. One (otherwise healthy) animal died unexpectedly 6 months postoperatively. A performed autopsy did not reveal an obvious cause of death. No animals were excluded from this study, and the prematurely deceased animal was evaluated as a separate 6 month time point group.

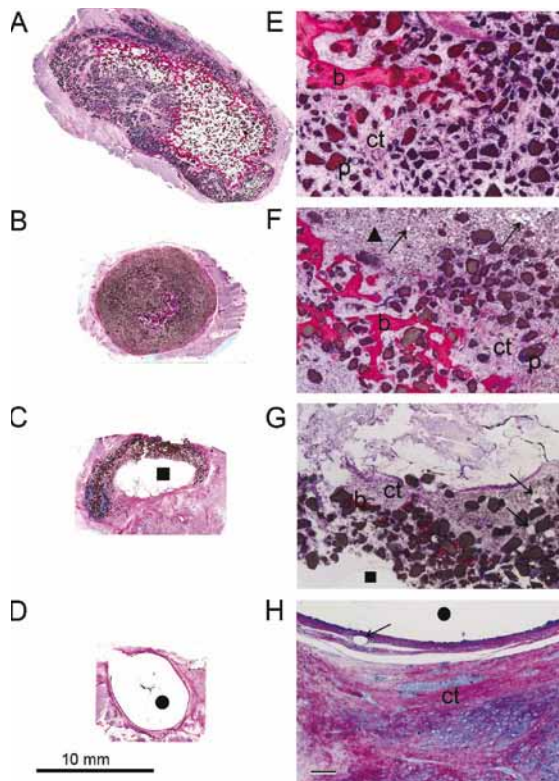
### *Descriptive microscopical observations of intramuscular implantations*

After 3 and 9 months all intramuscularly implanted specimens were harvested. Table 2 (see page 102) gives an overview of the bone incidence observed. Light microscopical evaluation of the stained sections showed that bone formation had occurred when BCP particles or BCP-containing materials were implanted. Implantations of PTMC sheets that did not contain BCP particles did not lead to formation of bone in any of the sheep.

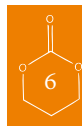
Figure 1 (see page 101) gives an overview of the intramuscularly implanted materials after 3 months. Light microscopical observations showed that, when present, bone had formed around the BCP particles. The BCP particles were in close contact with the newly formed bone. Ingrowth of connective tissue was also observed. It was shown that for the implanted PTMC/BCP composites the PTMC polymer matrix had resorbed profoundly and only small amounts of the polymer could be identified. Of the laminated PTMC/BCP-PDLLA composite, the PDLLA component could still be seen at this time point. In the implantations of the PTMC sheets (not containing BCP) no bone was formed. The remaining PTMC was surrounded by a fibrous capsule of dense connective tissue. Besides signs of polymer degradation, also disintegration of the BCP particles was observed. In Figure 2 (see page 103) the degradation of the polymeric PTMC matrix and the disintegration of the BCP particles is shown at higher magnifications.



Histological images of the intramuscularly implanted materials at 9 months are available as supplementary information (see appendix). After 9 months, the implantation of the BCP particles had led to progressive bone formation. By contrast, ectopically formed bone upon implantation of the PTMC/BCP composites and the PTMC/BCP-PDLLA laminated composite could not be discerned at this time point. The polymeric components of the composites had resorbed almost completely. Only few phagocytosed PTMC particles could be observed. Signs of disintegration of the BCP particles were seen. The intramuscularly implanted PTMC sheets were still identifiable, although degradation had progressed. The remaining material was surrounded by a fibrous capsule consisting of dense connective tissue.



*Figure 1:* Light micrographs of intramuscular implantation sites after 3 months. Figures 1A-D represent overviews of intramuscular implantations of respectively BCP, PTMC/BCP composite, PTMC/BCP-PDLLA laminated composite and PTMC. Figures 1E-F represent magnifications (4x) of the overviews: image E is a magnification of A, image F of B, etc.. Bone (b) is clearly visible and surrounds the BCP particles (p) in Figures 1A-C and their corresponding magnifications. The PTMC (●) matrix has resorbed extensively, phagocytosed polymeric material (arrows) can be observed. (▲) designates an area where remnants of disintegrated BCP particles are present. (■) PDLLA polymer. (Scale bar represents 100µ) Note that the polymer is transparent in the microscopical sections, and thus shows white in the images.



### *Descriptive microscopy of the orbital implantations*

The results of the evaluations of the orbital implantations are shown in Table 2 and Figure 3 (see page 104). After 3 months, the composite implants and the laminated composites clearly showed the formation of bone. Most of the polymeric PTMC matrix had resorbed at this time, and only small remnants of the polymer could be observed. The newly formed bone was in close contact to the BCP particles that have now become available. Following the implantation of the composite implants, the newly formed bone showed osseous integration with the host bone at places where

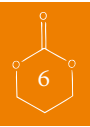

Table 2: Bone incidence upon implantations after 3, 6 and 9 months and concomitant percentages of the amount of new bone formed in the available area as determined by histomorphometry. Mean±standard deviation is presented.

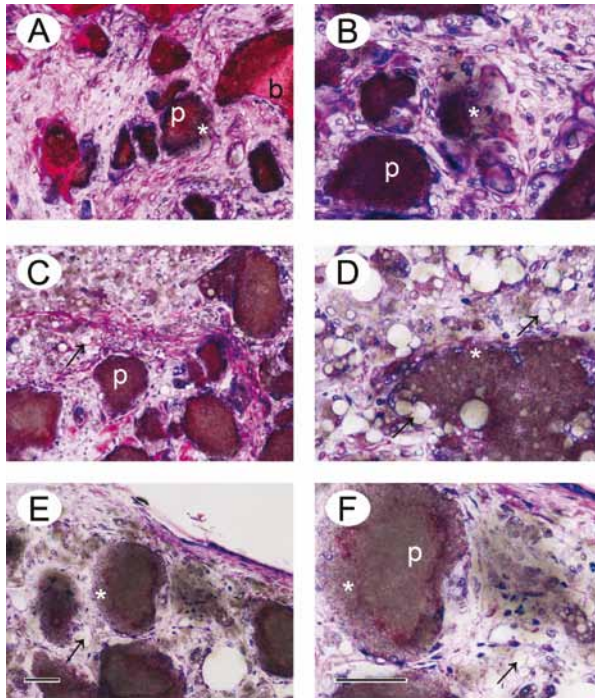
Implanted material	Bone incidence 3 months		% new bone 6 months		Bone incidence 9 months		% new bone	
	IM: 2/5	OF: 0/3	IM: 1/1	NI	IM: 2/4	OF: 0/3	IM: 2/4	OF: 0/3
BCP particles	IM: 2/5	OF: 0/3	IM: 1/1	NI	IM: 2/4	OF: 0/3	IM: 2/4	OF: 0/3
PTMC	IM: 0/3	OF: 0/3	NI	NI	IM: 0/3	OF: 0/3	IM: 0/3	OF: 0/3
PTMC/BCP composite	OF: 3/4	OF: 7.7±8.1	OF: 1/1	OF: 1/1	OF: 3/3	OF: 3/3	OF: 3/3	OF: 3/3
	IM: 2/4	IM: 0.3±0.6	IM: 0/1	IM: 0/1	IM: 0/3	IM: 0/3	IM: 0/3	IM: 0/3
PTMC/BCP-PDLLA laminated composite	OF: 3/3	OF: 5.3±4.0	OF: 1/1	OF: 1/1	OF: 1/2	OF: 1/2	OF: 1/2	OF: 1/2
	IM: 2/3	IM: 2.0±1.9	IM: 0/1	IM: 0/1	IM: 0/2	IM: 0/2	IM: 0/2	IM: 0/2

OF: orbital floor

IM: intramuscular

NI: not implanted

the implants were in contact with the host bone (*i.e.* at the orbital floor defect borders), see Figure 4 (see page 105). At the site of the defect, where the composite implants were not in contact with host bone, several layers of dense connective tissue covered the degrading implants. However, bone had also formed in regions where the implant covered the defect, this is shown in Figure 3B and 3H.



*Figure 2:* Light micrographs of intramuscular implantations after 3 months of respectively pure BCP particles (A, B), PTMC/BCP composite (C, D) and PTMC/BCP-PDLLA laminated composite (E, F). Note that the depicted images are magnifications of corresponding areas shown in Figure 1A, B and C. The dust-like aspect (\*) at the surface of the particles (p) suggests their disintegration. Remaining PTMC material (indicated by the arrows) can clearly be identified. (b) bone. (Figures 2A, C and E are 20x magnifications, Figures 2B, D and F 40x). (Scale bars represent 50µ)

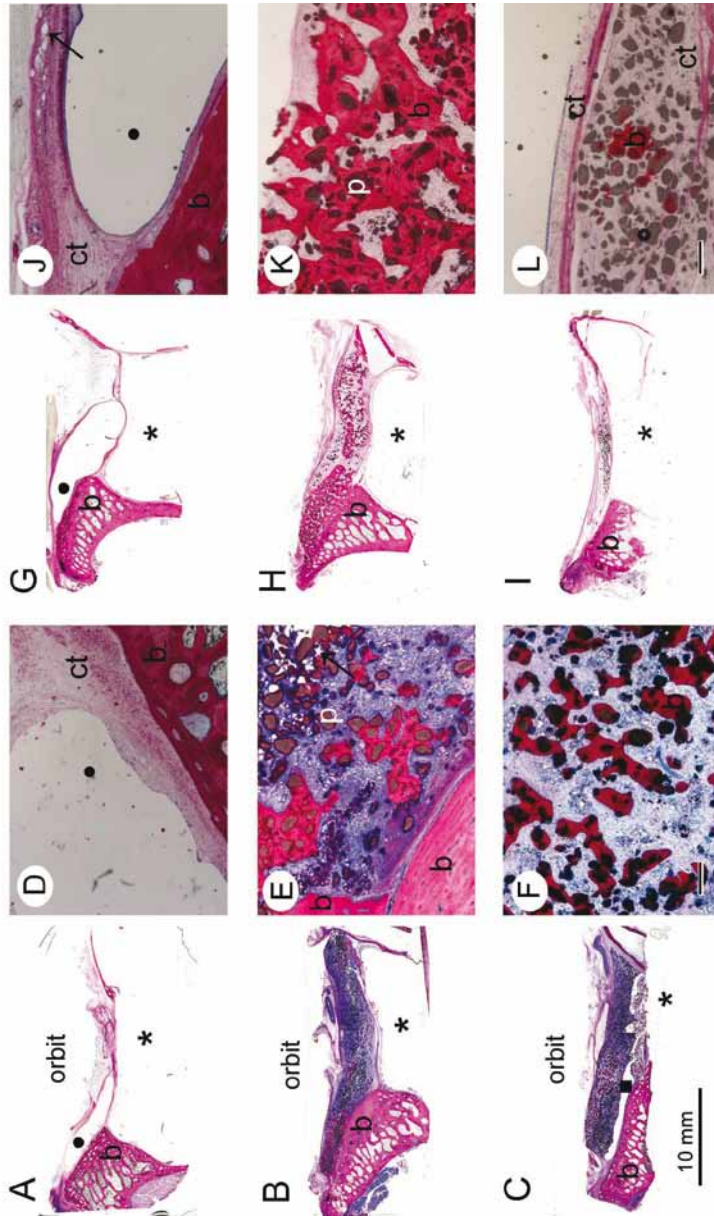
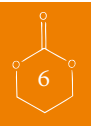The PTMC/BCP-PDLLA laminated composites, by contrast, did not show this osseous integration of newly formed bone with host bone. These were completely surrounded by a fibrous capsule composed of dense connective tissue (Figure 4).

After 9 months the bone formation appeared to be progressive for the PTMC/BCP composite implants. In some animals bone almost bridged the defect (Figure 3H). Both the PTMC/BCP composite implants and the PTMC/BCP-PDLLA laminated composite implants showed almost complete resorption of the polymeric PTMC matrix. Only some remaining phagocytized PTMC polymer material could be discerned. The PDLLA layer seemed to have been resorbed completely at 9 months. Whereas the newly formed bone in the composite implants still showed integration with the host bone at this time point, the PTMC/BCP-PDLLA laminated composites remained surrounded by a fibrous capsule and subsequently did not show osseous integration.

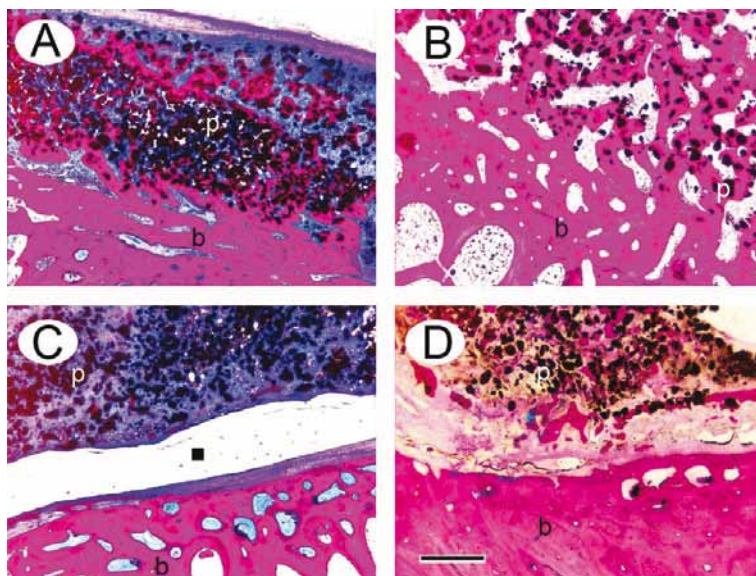
Signs of disintegration of the BCP particles were also seen after the 9 month implantation period. Figure 5 (see page 106) shows a PTMC/BCP composite implant and a PTMC/BCP-PDLLA laminated composite implant after 3 and 9 months at higher magnifications.







**Figure 3:** Light micrographs of orbital implantations after 3 (3A-F) and 9 (3G-L) months. Figure A, D, G and J show reconstruction with the PTMC sheet. Capsule formation is visible (see ct area in images D and J), there is no sign of bone formation. New bone formation is clearly visible and in close contact with the BCP particles after 3 months in the PTMC/BCP composite sheet (3B, E) and is progressive after 9 months (3H, K). Note that in Figure 3H bone is growing in/over the original defect area. The PTMC/BCP-PDLLA laminated composite sheet also showed bone formation around BCP particles after 3 months (see 3C, F), however to a lesser extent than when compared to the composite sheet as shown in image 3B, E, H, and K. After 9 months limited bone formation was found as shown in image I and L. Images D-F and J-L are 4x magnifications of respectively images A-C and G-I; (●) PTMC, (\*) maxillary sinus, (b) bone, (p) BCP particle, (■) PDLLA polymer, (arrow) residual polymeric PTMC material, (ct) connective tissue. (Scale bar represents 100 $\mu$ .)

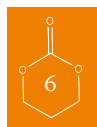


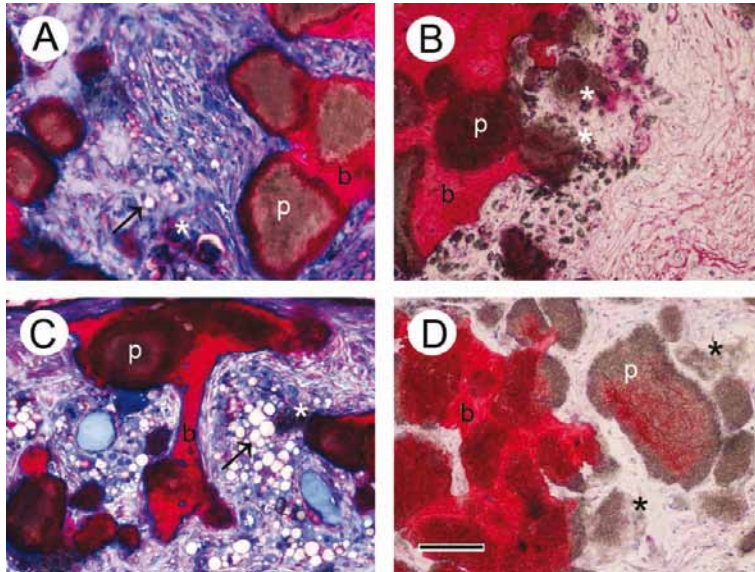
*Figure 4:* Light micrographs (2.5x) representing the transition area of the PTMC/BCP composite (4A, B) and the PTMC/BCP-PDLLA laminated composite (4C, D) implant, to host (and newly formed) bone in the orbit of the sheep. Figures 4A and B are respectively magnifications of the areas shown in Figure 3B and 3H where the composite implants are in close contact with the host bone and show excellent osseous integration of newly formed bone with the host bone after respectively 3 and 9 months. Figure 4C and D are respectively magnifications of the areas shown in Figure 3C and 3I where the laminated composite implants are in close contact with the host bone. Figure 4C clearly illustrates the PDLLA layer of the laminated composite impeding osseous integration after 3 months. Figure 4D shows that after 9 months, although the PDLLA layer has degraded, osseous integration of newly formed bone with the host bone still has not occurred. This could be due to the fibrous capsule which is present between the newly formed bone and the host bone. (b) bone, (p) BCP particle, (■) PDLLA polymer. (Scale bar represents 400 $\mu$ )

The histological findings for the animal that died after 6 months were comparable to the observations found for the other animals after 9 months. In this animal the orbital PTMC/BCP composite implant showed new bone formation that had integrated with the host bone. Although the PTMC/BCP-PDLLA laminated composite implant placed in the other orbit did show bone formation, the newly formed bone (again) had not integrated with the host bone. A fibrous capsule surrounded the laminated composite implant. Besides the intramuscularly implanted BCP particles, none of the intramuscular composite material implantations lead to ectopic bone formation (see Table 2). At 6 months the degradation and resorption of the PTMC polymer matrix and the PDLLA layer was shown to be progressive when compared to 3 month implants. However, the degradation was not as advanced as in the 9 month groups. Remnants of the PDLLA layer could still be identified. Disintegration of the BCP particles was observed when BCP or (laminated) BCP composites were implanted.

#### *Fluorescence microscopy*

Epifluorescent confocal microscopy of the sequential fluorochrome labels revealed that 3 weeks after implantation the formation of bone had started in the intramuscular implantations of the BCP



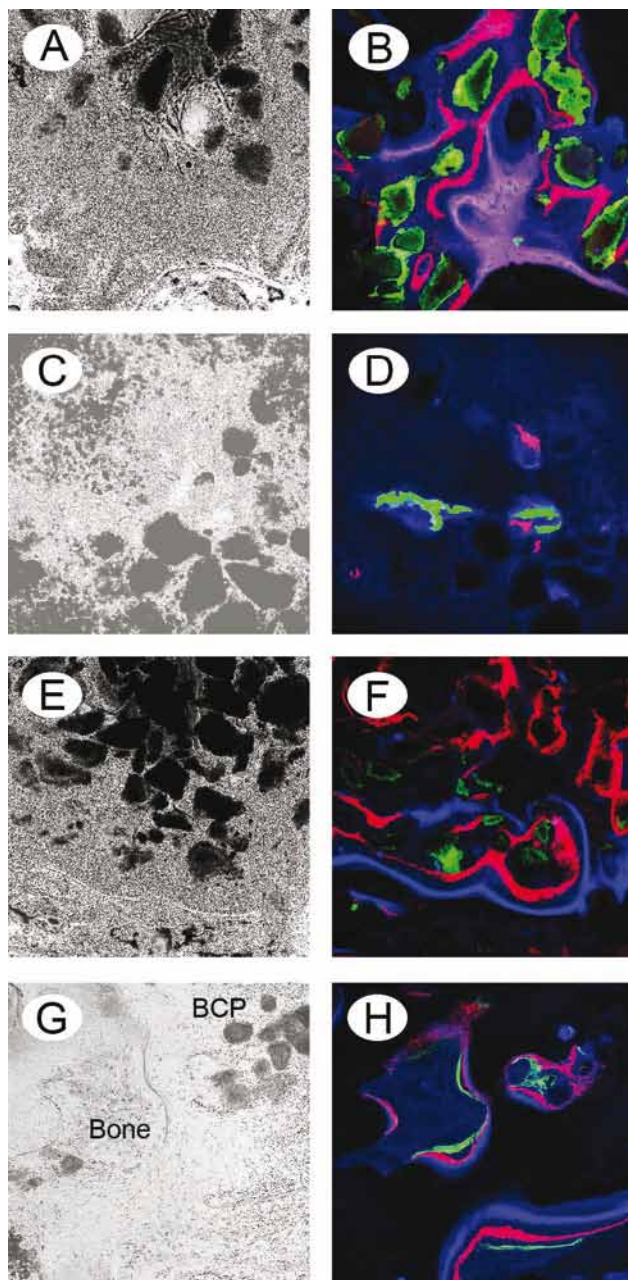


*Figure 5:* Light micrographs (20x) showing the disintegration of BCP particles following orbital implantations after 3 and 9 months. Figure 5A and B are sections of orbital PTMC/BCP composite implantations as shown in Figure 3B and 3H. Figures 5C and D are sections of orbital PTMC/BCP-PDLLA laminated composite implants as shown in Figure 3C and 3I. The dust-like aspect (\*) at the surface of the BCP particles (p) suggests they are disintegrating. Remaining PTMC material (arrows) is easily identified. The disintegration of the BCP particles in the composite and in the laminated composite tended to be more extensive when compared to the disintegration in the intramuscular implantations of BCP particles only. (\*) shows an area containing disintegrating BCP, (arrow) phagocytosed PTMC material, (b) bone. (Scale bar represents 50 $\mu$ .)

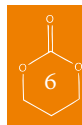
particles and the (laminated) composites. Similar observations were found for the PTMC/BCP composite and the laminated PTMC/BCP-PDLLA composite implants in the orbital implantation experiments (Figure 6, see page 107). Colours for the labels were set as follows: calcein is green; xylenol orange is red; oxytetracycline is blue. Analysis of the fluorochrome labels indicated that the formation of bone had started at the surface of the BCP particles and progressed outwards. After 9 months the fluorochrome labelling showed that the process of bone formation and remodelling was still active in the orbital floor implantations. None of the intramuscularly implanted (laminated) composites showed fluorescence after 9 months. The prematurely deceased animal had died before the fluorochromes were administered and did therefore not show fluorochrome fluorescence.

### *Histomorphometry*

The results of the histomorphometrical analysis of the intramuscular and orbital implantation sites are shown in Table 2 (see page 102). The mean percentages and standard deviations are presented for the amount of bone formed in the available area. (The available area is defined as the space between the BCP particles where the polymer has resorbed). Not all animals showed bone formation following the implantations. Furthermore, when bone was present, large variations in



*Figure 6:* Epifluorescent confocal micrographs of intramuscularly implanted BCP (6A-B) and PTMC/BCP composite (6C-D). Figures 6E-F and 6G-H are images of orbital implantations of the PTMC/BCP composite after, respectively 3 and 9 months. 6A, C, E, and G are bright field images, 6B, D, F, and H are corresponding epifluorescent images. By comparing micrographs of the same region of an unstained section under epifluorescent (6B, D, F and H) and transmitted light (6A, C, E and G), correlations between the composite and bone formation are possible. Calcein = green, Xylenol Orange = red and Oxytetracycline = blue. It can be seen that bone formation had started after 3 weeks (green coloured zones) around the intramuscularly implanted BCP and PTMC/BCP composite. The orbital implantations showed similar results. Bone formation had started after 3 weeks (green coloured zones in 6F) in the 3 month group. The blue coloured zones in 6H show the process of bone formation still being active at 9 months.



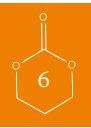the amounts of formed bone were observed in and between individual animals.

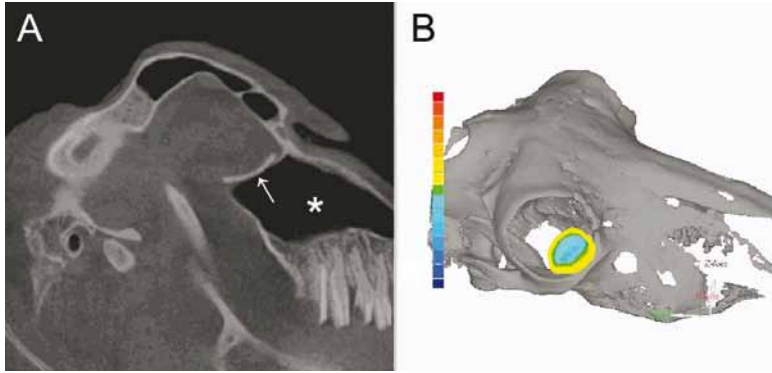
After 3 months measurements showed  $7.7 \pm 8.1$  % (mean  $\pm$  SD) of bone had formed following the PTMC/BCP composite orbital floor implantations. After 9 months the percentage of bone had increased to  $15.7 \pm 14.6$  %. The PTMC/BCP-PDLLA laminated composite orbital floor implants showed  $5.3 \pm 4.0$  % and  $1.7 \pm 2.4$  % of bone formation, respectively after 3 and 9 months. The intramuscular implantations only showed limited bone formation. The intramuscularly placed PTMC/BCP composite samples showed  $0.3 \pm 0.6$  % and the PTMC/BCP-PDLLA laminated composite  $2.0 \pm 1.9$  % of bone formation after 3 months. The intramuscularly placed amounts of BCP particles showed  $2.9 \pm 5.9$  % bone formation, which progressed to  $6.4 \pm 6.9$  % of bone after 9 months.

The prematurely deceased animal showed respectively 13.9 % and 14.9% of bone formation for the PTMC/BCP-PDLLA laminated composite and PTMC/BCP composite implantations in the orbits. The intramuscularly implanted BCP particles resulted in 12.8 % bone formation.

#### *Evaluation of the reconstructed orbital floor by cone beam CT (CBCT)*

Figure 7 graphically presents the evaluation process of the reconstruction of the orbital floors, and illustrates the performance of the different implants. It can be seen that the radio-opaque PTMC/BCP composite and PTMC/BCP-PDLLA laminated composite sheets were easily identified. As described in the experimental part, the colour mapping shows the deviation of the reconstructed orbital floor compared to the preoperative intact orbital floor. The results for the deformation of the implants and the calculated changes in the concomitant orbital volumes are summarized in Table 3 (see page 110). It can be seen that the increase in the orbital volume of animals treated with the PTMC implants (implants not containing BCP) ranged from  $+0.16$  to  $+0.23$  cm<sup>3</sup>, after 3 and 9 months respectively. The animals treated with the PTMC/BCP composite implants showed an orbital volume increase that ranged from  $+0.14$  to  $+0.19$  cm<sup>3</sup>, while the animals treated with the PTMC/BCP-PDLLA laminated composite implants showed volume increases ranging from  $+0.11$  to  $+0.15$  cm<sup>3</sup>.





*Figure 7:* Assessment of orbital floor position. Figure A shows a lateral view of a postoperative CBCT scan of a sheep. The PTMC/BCP composite implant (arrow) is radio-opaque and can be clearly identified at the top of the maxillary sinus (\*). Figure B shows the superposition of the postoperative scan over the preoperative scan. The region of interest is highlighted. The colour mapping is shown. There is a slight 'negative' deformation at the center of the implant when compared to the preoperative situation. Where the implant overlies the defect borders (i.e. is resting on the intact orbital floor borders), the deformation is slightly 'positive' when compared to the preoperative situation of the intact orbital floor.

## DISCUSSION

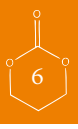The present study describes the evaluation of the osteoinductive properties of composite materials prepared from PTMC and microstructured BCP. The composite materials were evaluated both in an orthotopic (orbit), as well as in an ectopic (intramuscular) site in sheep. With the evaluation of the osteoinductive properties of the composite materials, the suitability of the composite materials to serve as a load-bearing material for orbital floor reconstruction was assessed. From the results of this first study, it seems that PTMC/BCP composite materials and PDLLA-laminated PTMC/BCP composite materials have osteoinductive properties and can therefore be suited for use in the reconstruction of critical size orbital floor defects in sheep. Moreover, fluorochrome labelling indicated that the osteoinductive potential of the composites remained active at 9 months.

To our knowledge this is not only the first report on the *in vivo* evaluation of osteoinductive solid composites composed of a continuous PTMC phase and a dispersed (biphase) calcium phosphate particle phase, but it is also the first report on *synthetic* resorbable osteoinductive composites for use in orbital floor reconstruction.

The first clinical use of resorbable polymeric implants in the management of orbital floor fractures was reported in 1972 by Cutright and Hunsuck<sup>30</sup>, who used poly(lactic acid) implants to reconstruct orbital floor fractures. Since then, several studies evaluating poly(lactic acid) as a reconstruction material in orbital floor fractures have been conducted<sup>6,31-33</sup>.

In the early 1970s, calcium phosphates were also used to repair bone defects in craniomaxillofacial surgery<sup>34,35</sup>. Although their use led to bony regeneration of the fractured orbital floor<sup>36,37</sup>, problems regarding the shaping of the brittle calcium phosphate implants were encountered. This led to postoperative enophthalmos in a significant number of patients<sup>38</sup>.

Downes and Tanner<sup>39</sup> reported on an osteoconductive composite for the treatment of orbital



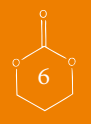

Table 3: Mean negative deformations of the reconstructed orbital floors and after 3 and 9 months using different implant materials. The animal that died after 6 months is considered individually. The preoperative scan served as reference. Mean negative deformations  $\pm$ SD are given in mm.

The calculated maximum increase in volume after 3 and 9 months for the different reconstruction materials is also provided. For this the most negative deformation of each reconstruction material was used. The (maximum) increase in volume occurred due to deformation of the reconstruction materials. The defect size was considered to be 3 cm<sup>2</sup>.

	PTMC 3 months	9 months	PTMC/BCP* 3 months	6 months	9 months	PTMC/BCP- PDLA** 3 months	6 months	9 months
Deformation (mm)	-0.77 $\pm$ 0.25	-1.20 $\pm$ 0.36	-0.48 $\pm$ 0.79	-1.1	-0.67 $\pm$ 0.25	-0.80 $\pm$ 0.26	-0.7	-0.70 $\pm$ 0.42
Max. vol. increase orbit (cm <sup>3</sup> )	0.16	0.23	0.19	0.16	0.14	0.15	0.11	0.15

\* PTMC/BCP: composite

\*\* PTMC/BCP-PDLA: laminated composite

floor fractures which was based on hydroxyl apatite and polyethylene (HAPEX). This composite did neither demonstrate osteoinductive properties nor signs of degradation. Also the limitations of ceramic materials regarding shape-ability were recognized, in particular in the reconstruction of orbital floor fractures.

During the surgical procedures in our study, it became clear that the shape-ability of the PTMC implants was excellent. Also the PTMC composite- and laminated composite implants could be easily cut into a desired shape. Furthermore, our results showed that both the composite and the laminated composite implants exerted osteoinductive properties. The composite implants showed excellent osseous integration of the newly formed bone with the host bone. At the defect site, where the composite implants were not in contact with host bone, even new bone formation that almost bridged the defect was demonstrated. Although such findings have been reported previously<sup>6,33</sup> this is nevertheless of great importance for the long-term results as the composite implants are resorbable and bony regeneration of the orbital floor at the defect site is the main target.

The histological observations of the degradation of the polymeric PTMC matrix with simultaneous formation of bone supported our hypothesis that a resorbable polymeric matrix could enhance the mechanical properties of calcium phosphate ceramics, without negatively affecting the osteoinductive properties of the calcium phosphate particles. For the laminated composites, however, the PDLA layer might have exerted a negative effect on bone formation and osseous integration of newly formed bone with host bone in two ways: firstly, by creating a physico-mechanical barrier between the composite and host bone and secondly, by inducing an acidic environment during degradation which can have detrimental effects on host bone and bone formation<sup>9,10</sup>.

Osseous integration might also have been impeded by the fibrous capsule which surrounded the degrading laminated composites. Formation of a fibrous capsule around (resorbable) biomaterials occurs when the surface-to-volume ratio of the implanted biomaterial is unfavourably low, or when the implanted biomaterial impedes or hinders the regeneration of normal tissues<sup>40,41</sup>. This could explain the fact that while remnants of the orbitally implanted PTMC/BCP composite implants were not completely surrounded by a fibrous capsule, remnants of the (orbitally implanted) PTMC/BCP-PDLA laminated composite implants and the PTMC implants were completely encapsulated. Both the PTMC and the PDLA layer might have hindered the regeneration of normal tissue. The PTMC/BCP composites did not hinder the regeneration of normal/local tissue as their use led to excellent osseous integration. Since the degradation process can progress along the surface of exposed BCP particles, the surface-to-volume ratio can be expected to increase favourably.

The histological observation of the disintegration of BCP particles (also in composites) has been reported previously<sup>17,42-45</sup>. Dupraz *et al.* developed a composite of BCP and a degradable cellulosic ether<sup>43</sup>. The result from their *in vivo* study in rabbits revealed that phagocytosis upon implantation of the composites and of the BCP particles themselves was mediated by macrophages and giant multinucleated cells. Since these cells play a major role in the degradation process of PTMC<sup>20,46</sup> it is most likely that macrophages and giant multinucleated cells also are involved in the BCP disintegration process observed in our experiments.





The large variations in the amounts of induced bone that we observed in and between the individual animals are not uncommon in research on osteoinductive materials. It is known that besides animal-specific factors, implantation site-specific factors can also have an effect on the amount of induced bone<sup>14, 47, 48</sup>. Implantations in orthotopic locations tend to result in larger amounts of induced bone than implantations in ectopic locations<sup>14</sup>. Also, it is suggested that the intrinsic ability of individual animals to form new bone in osteopromotive environments could vary as a result of genetic factors which in the process of osteoinduction can lead to different responses<sup>49-51</sup>. As we used non-inbred Texel sheep, genetic variation can be expected to be present.

The evaluation by CBCT showed that all the reconstructed orbital floors were adequately positioned as when compared with the preoperative anatomical situation. None of the maximum calculated increases in volume of the orbits that result from deformation of the implants were larger than the aforementioned critical value of 0.7 cm<sup>3</sup> (see Table 3). In the treatment of orbital floor fractures with resorbable materials, the main short-term goal is to obtain a stiff scar composed of a dense connective tissue capsule. This scar prevents the orbital content from sagging into the maxillary sinus during degradation or resorption of the implant<sup>52</sup>. It should be noted however, that complications at the long-term (such as late enophthalmos) are not always prevented by the formation of such fibrous capsule, and ideally bone is regenerated at the level of the orbital floor defect. In this respect, the PTMC/BCP composite and PTMC/BCP-PDLLA laminated composite showed promising results. Nonetheless, future research on the outcomes at the long-term will need to be conducted. The question whether the regenerated bone will become a regenerated bony orbital floor that is in contact with the host bone and capable of keeping the orbital content in position and prevent late on-set enophthalmos will be addressed.

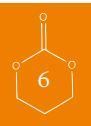## CONCLUSIONS

The present study describes the preparation and *in vivo* evaluation of osteoinductive (PDLLA-laminated) composites composed of PTMC and microstructured BCP particles for use in orbital floor reconstruction. Composites were also laminated with PDLLA. From the obtained data it can be concluded that the composite materials are shapeable, seem to exert osteoinductive properties and are likely very well suited for use in the bone-regenerating reconstruction of orbital floor fractures in sheep. Furthermore, excellent osseous integration of the newly formed bone with the host bone was observed, after 9 months bone almost bridged the defects reconstructed with the PTMC/BCP composite materials.

Future research focussing on the long term performance of these promising composite materials will be performed, and definitive conclusions regarding their bone regenerating capacity and suitability as reconstruction material in the treatment of orbital floor fractures will be drawn.

## ACKNOWLEDGEMENTS

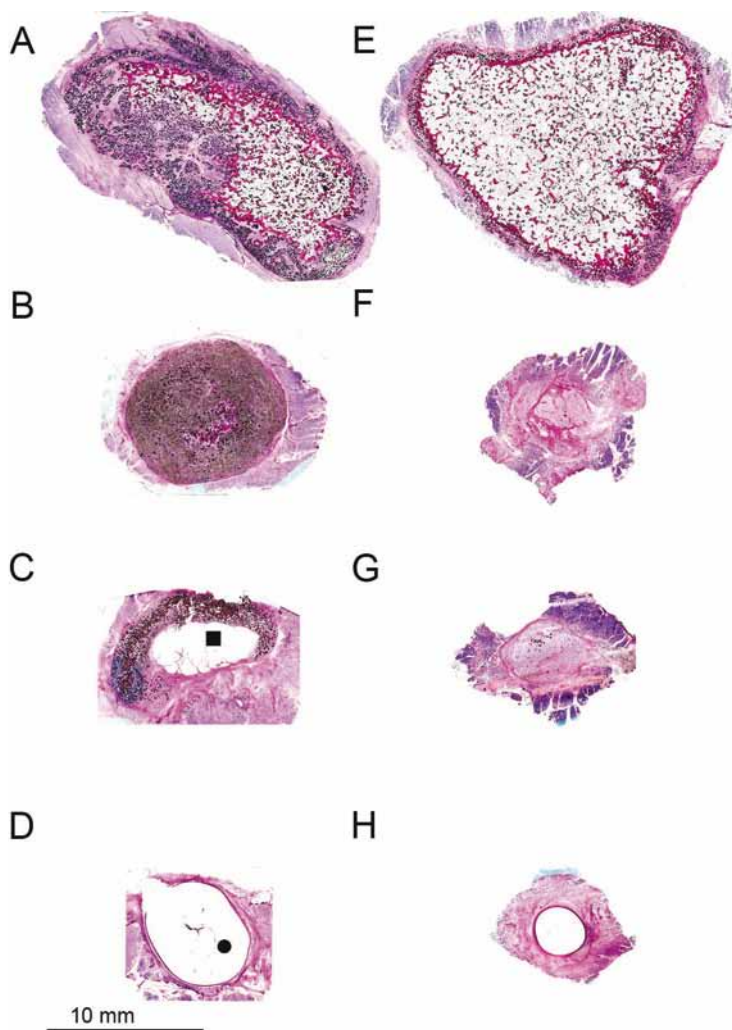
Gratitude is expressed to Ms. L. van Leeuwen, Mr. D. Barbieri and Mr. X Luo for their assistance in the animal experiments and histological processing of the explanted samples. Ms. M.B.M. van Leeuwen and Mr. K. van den Broek are acknowledged for their assistance in the fluorochrome



labeling process. Furthermore, we thank the department of Oral and Maxillofacial Surgery, Radboud University Medical Center Nijmegen, The Netherlands, for their assistance during the post-mortem CBCT scans.



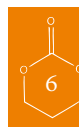APPENDIX



*Supplemental Figure:* Light micrographs of intramuscular implantation sites after 3 and 9 months. Images A-D represent overviews of intramuscular implantations of respectively BCP, PTMC/BCP composite, PTMC/BCP-PDLLA laminated composite and PTMC after 3 months. Images E-F represent overviews of respectively BCP, PTMC/BCP composite, PTMC/BCP-PDLLA laminated composite and PTMC after 9 months. It can be observed that when compared to the 3 months evaluation time point, the implantation of BCP particles (alone) also led to bone formation after 9 months. Bone formation upon implantation of the PTMC/BCP composites and the PTMC/BCP-PDLLA laminated composite could not be discerned at 9 months. Images F and G show that the polymeric components of the composites as well as the ceramic component had resorbed almost completely. The intramuscularly implanted PTMC sheets were still identifiable, although degradation had much progressed. The remaining material was surrounded by a fibrous capsule consisting of dense connective tissue. In accordance with Figure 1, the black dots represent the BCP particles, also PDLLA polymer (■) and PTMC polymer (●) can be discerned.

## REFERENCES

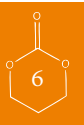
1. Giannoudis PV, Dinopoulos H, Tsiridis E: Bone substitutes: an update. *Injury* 36 Suppl 3:S20, 2005
2. Ellis E, Messo E: Use of nonresorbable alloplastic implants for internal orbital reconstruction. *Journal of Oral and Maxillofacial Surgery* 62:873, 2004
3. Prowse SJB, Hold PM, Gilmour RF, Pratap U, Mah E, Kimble FW: Orbital floor reconstruction: A case for silicone. A 12 year experience. *Journal of Plastic Reconstructive and Aesthetic Surgery* 63:1105, 2010
4. Jaquiere C, Aeppli C, Cornelius P, Palmowsky A, Kunz C, Hammer B: Reconstruction of orbital wall defects: critical review of 72 patients. *Int J Oral Maxillofac Surg* 36:193, 2007
5. Kontio R, Lindqvist C: Management of orbital fractures. *Oral and maxillofacial surgery clinics of North America* 21:209, 2009
6. Kontio R, Suuronen R, Kontinen YT, Hallikainen D, Lindqvist C, Kommonen B, Kellomaki M, Kylma T, Virtanen I, Laine P: Orbital floor reconstruction with poly-L/D-lactide implants: clinical, radiological and immunohistochemical study in sheep. *Int J Oral Maxillofac Surg* 33:361, 2004
7. Potter JK, Ellis E: Biomaterials for reconstruction of the internal orbit. *Journal of Oral and Maxillofacial Surgery* 62:1280, 2004
8. Eppley BL, Prevel CD: Nonmetallic fixation in traumatic midfacial fractures. *J Craniofac Surg* 8:103, 1997
9. Wu LB, Ding JD: In vitro degradation of three-dimensional porous poly(D,L-lactide-co-glycolide) scaffolds for tissue engineering. *Biomaterials* 25:5821, 2004
10. Taylor MS, Daniels AU, Andriano KP, Heller J: 6 Bioabsorbable Polymers - In-Vitro Acute Toxicity of Accumulated Degradation Products. *Journal of Applied Biomaterials* 5:151, 1994
11. Le Nihouannen D, Daculsi G, Saffarzadeh A, Gauthier O, Delplace S, Pilet P, Layrolle P: Ectopic bone formation by microporous calcium phosphate ceramic particles in sheep muscles. *Bone* 36:1086, 2005
12. Malard O, Boulter JM, Guicheux J, Heymann D, Pilet P, Coquard C, Daculsi G: Influence of biphasic calcium phosphate granulometry on bone ingrowth, ceramic resorption, and inflammatory reactions: Preliminary in vitro and in vivo study. *J Biomed Mater Res* 46:103, 1999
13. Ripamonti U: Osteoinduction in porous hydroxyapatite implanted in heterotopic sites of different animal models. *Biomaterials* 17:31, 1996
14. Habibovic P, Yuan HP, Van den Doel M, Sees TM, Van Blitterswijk CA, De Groot K: Relevance of osteoinductive biomaterials in critical-sized orthotopic defect. *Journal of Orthopaedic Research* 24:867, 2006
15. Yuan HP, Fernandes H, Habibovic P, de Boer J, Barradas AMC, de Ruiter A, Walsh WR, van Blitterswijk CA, de Bruijn JD: Osteoinductive ceramics as a synthetic alternative to autologous bone grafting. *Proc Natl Acad Sci U S A* 107:13614, 2010
16. Fellah BH, Gauthier O, Weiss P, Chappard D, Layrolle P: Osteogenicity of biphasic calcium phosphate ceramics and bone autograft in a goat model. *Biomaterials* 29:1177, 2008
17. Fellah BH, Delorme B, Sohier J, Magne D, Hardouin P, Layrolle P: Macrophage and osteoblast responses to biphasic calcium phosphate microparticles. *Journal of Biomedical Materials Research Part a* 93A:1588, 2010
18. Guan LM, Davies JE: Preparation and characterization of a highly macroporous biodegradable composite tissue engineering scaffold. *Journal of Biomedical Materials Research Part a* 71A:480, 2004
19. Zhang Z, Kuijter R, Bulstra SK, Grijpma DW, Feijen J: The in vivo and in vitro degradation behavior of poly(trimethylene carbonate). *Biomaterials* 27:1741, 2006
20. Pego AP, Van Luyn MJA, Brouwer LA, van Wachem PB, Poot AA, Grijpma DW, Feijen J: In vivo behavior of poly(1,3-trimethylene carbonate) and copolymers of 1,3-trimethylene carbonate with D,L-lactide or epsilon-caprolactone: Degradation and tissue response. *Journal of Biomedical Materials Research Part a* 67A:1044, 2003
21. van Leeuwen AC, Bos RRM, Grijpma DW: Composite materials based on poly(trimethylene carbonate) and beta-tricalcium phosphate for orbital floor and wall reconstruction. *Journal of biomedical materials research. Part B, Applied biomaterials* 100:1610, 2012
22. Yuan HP, Kurashina K, de Bruijn JD, Li YB, de Groot K, Zhang XD: A preliminary study on osteoinduction of two kinds of calcium phosphate ceramics. *Biomaterials* 20:1799, 1999
23. Pego AP, Grijpma DW, Feijen J: Enhanced mechanical properties of 1,3-trimethylene carbonate polymers and networks. *Polymer* 44:6495, 2003



24. Urist MR: Bone - Formation by Autoinduction. *Science* 150:893, 1965
25. Urist MR, Silverman BF, Buring K, Dubuc FL, Rosenberg JM: The bone induction principle. *Clin Orthop* 53:243, 1967
26. Barradas AMC, Yuan H, van Blitterswijk CA, Habibovic P: Osteoinductive biomaterials: current knowledge of properties, experimental models and biological mechanisms. *European cells & materials* 21:407, 2011
27. Klein CPAT, Sauren YMHF, Modderman WE, Vanderwaerden JPCM: A New Saw Technique Improves Preparation of Bone Sections for Light and Electron-Microscopy. *Journal of Applied Biomaterials* 5:369, 1994
28. van Leeuwen AC, Ong SH, Vissink A, Grijpma DW, Bos RRM: Reconstruction of orbital wall defects: Recommendations based on a mathematical model. *Exp Eye Res* 97:10, 2012
29. Ploder O, Klug C, Voracek M, Burggasser G, Czerny C: Evaluation of computer-based area and volume measurement from coronal computed tomography scans in isolated blowout fractures of the orbital floor. *Journal of Oral and Maxillofacial Surgery* 60:1267, 2002
30. Cutright DE, Hunsuck EE: Repair of Fractures of Orbital Floor using Biodegradable Polylactic Acid. *Oral Surgery Oral Medicine Oral Pathology Oral Radiology and Endodontics* 33:28, 1972
31. Bairo F: Biomaterials and implants for orbital floor repair. *Acta biomaterialia* 7:3248, 2011
32. Bergsma JE, Rozema FR, Bos RRM, Debruijn WC, Boering G: Poly(L-Lactic)acid Implants in Repair of Defects of the Orbital Floor - a 5-Year Animal Study. *Cells and Materials* 4:31, 1994
33. Rozema FR, Bos RRM, Pennings AJ, Jansen HWB: Poly(L-Lactide) Implants in Repair of Defects of the Orbital Floor - an Animal Study. *Journal of Oral and Maxillofacial Surgery* 48:1305, 1990
34. Levitt SR, Crayton PH, Monroe EA, Condrate RA: Forming method for apatite prostheses. *J Biomed Mater Res* 3:683, 1969
35. Monroe EA, Votava W, Bass DB, McMullen J: New Calcium Phosphate Ceramic Material for Bone and Tooth Implants. *J Dent Res* 50:860, 1971
36. Mathur KK, Tatum SA, Kellman RM: Carbonated apatite and hydroxyapatite in craniofacial reconstruction. *Archives of facial plastic surgery : official publication for the American Academy of Facial Plastic and Reconstructive Surgery, Inc. and the International Federation of Facial Plastic Surgery Societies* 5:379, 2003
37. Sinikovic B, Kramer FJ, Swennen G, T Luebbers H, Dempf R: Reconstruction of orbital wall defects with calcium phosphate cement: clinical and histological findings in a sheep model. *Int J Oral Maxillofac Surg* 36:54, 2007
38. Nam SB, Bae YC, Moon JS, Kang YS: Analysis of the postoperative outcome in 405 cases of orbital fracture using 2 synthetic orbital implants. *Ann Plast Surg* 56:263, 2006
39. Tanner KE, Downes RN, Bonfield W: Clinical-Applications of Hydroxyapatite Reinforced Materials. *British Ceramic Transactions* 93:104, 1994
40. Anderson JM, Shive MS: Biodegradation and biocompatibility of PLA and PLGA microspheres. *Adv Drug Deliv Rev* 28:5, 1997
41. Ratner, B.D., Hoffman, A.S., Schoen, F.J., Lemons, J.E.: *Biomaterials science: an introduction to materials in medicine.* , 2004
42. Dupraz A, Nguyen TP, Richard M, Daculsi G, Passuti N: Influence of a cellulosic ether carrier on the structure of biphasic calcium phosphate ceramic particles in an injectable composite material. *Biomaterials* 20:663, 1999
43. Dupraz A, Delecricin J, Moreau A, Pilet P, Passuti N: Long-term bone response to particulate injectable ceramic. *J Biomed Mater Res* 42:368, 1998
44. Benahmed M, Bouler JM, Heymann D, Gan O, Daculsi G: Biodegradation of synthetic biphasic calcium phosphate by human monocytes in vitro: A morphological study. *Biomaterials* 17:2173, 1996
45. Gauthier O, Bouler JM, Weiss P, Bosco J, Aguado E, Daculsi G: Short-term effects of mineral particle sizes on cellular degradation activity after implantation of injectable calcium phosphate biomaterials and the consequences for bone substitution. *Bone* 25:71S, 1999
46. Bat E, Plantinga JA, Harmsen MC, van Luyn MJA, Feijen J, Grijpma DW: In vivo behavior of trimethylene carbonate and epsilon-caprolactone-based (co)polymer networks: Degradation and tissue response. *Journal of Biomedical Materials Research Part a* 95A:940, 2010

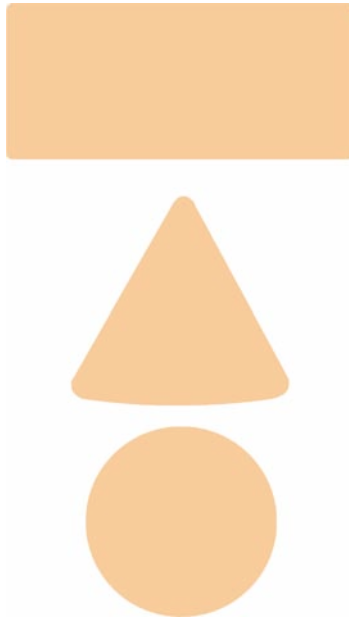


47. Yuan H, van Blitterswijk CA, de Groot K, de Bruijn JD: A comparison of bone formation in biphasic calcium phosphate (BCP) and hydroxyapatite (HA) implanted in muscle and bone of dogs at different time periods. *Journal of Biomedical Materials Research Part a* 78A:139, 2006
48. Yuan H, Van Blitterswijk CA, De Groot K, De Bruijn JD: Cross-species comparison of ectopic bone formation in biphasic calcium phosphate (BCP) and hydroxyapatite (HA) scaffolds. *Tissue Eng* 12:1607, 2006
49. Habibovic P, Yuan HP, van der Valk CM, Meijer G, van Blitterswijk CA, de Groot K: 3D microenvironment as essential element for osteoinduction by biomaterials. *Biomaterials* 26:3565, 2005
50. Geesink RGT, Hoefnagels NHM, Bulstra SK: Osteogenic activity of OP-1 bone morphogenetic protein (BMP-7) in a human fibular defect. *Journal of Bone and Joint Surgery-British Volume* 81B:710, 1999
51. Marusic A, Katavic V, Greevic D, Lukic IK: Genetic variability of new bone induction in mice. *Bone* 25:25, 1999
52. Enislidis G: Treatment of orbital fractures: The case for treatment with resorbable materials. *Journal of Oral and Maxillofacial Surgery* 62:869, 2004





## Summary and general discussion





In the introduction to the thesis (**Chapter 1**) the evolution of biomaterials over the centuries until today is described. The materials of choice have evolved from metals and natural materials to polymeric plastics and resorbable polymers. All with one goal: to restore the function of missing body parts.

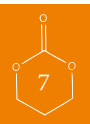Nowadays, the interest has shifted towards the use of bioactive biomaterials that are able to regenerate the missing tissues. Preferably these materials resorb during and after they have completed their function. A problem with resorbable materials can be, however, that their degradation products itself can harm the surrounding tissues. This is undesired and has to be prevented. Furthermore, the application dictates the needed properties of a biomaterial as well as that the properties of a biomaterial determine its possible application(s). In order to use biodegradable polymers for bone tissue regeneration purposes, it is of great importance that the degradation products itself do not have a negative effect on bone and regenerated bone tissue. In this regard, polymers that degrade without the formation of detrimental degradation products will be most suited for application.

Several biodegradable polymeric materials are currently available for use in bone and tissue engineering applications, however, one material in particular seems very interesting and has gained more attention during the last decades: poly(trimethylene carbonate) (PTMC). Amongst others, PTMC seems a promising material for use in guided bone regeneration techniques as applied in oral and maxillofacial surgery. Therefore, the general aim of this PhD research was to develop and test medical devices based on PTMC for use in oral and maxillofacial surgery. The focus of the research was on the development of (1) resorbable barrier membranes for use in guided bone regeneration procedures prior to implant dentistry and (2) the development of resorbable osteoinductive composite sheets for guided bone regeneration in orbital floor fractures.

Hence, this thesis is divided into two parts. As mentioned, the focus of the first part of this thesis was to establish the suitability of PTMC as a barrier membrane in guided bone regeneration. Newly developed membrane sheets were *in vivo* evaluated for their effect on new bone regeneration in a study in rats (**Chapter 2**). In **Chapter 3** the *in vivo* behaviour with respect to degradation and reaction of and towards surrounding tissues, *i.e.* reaction of surrounding host tissues to membrane and its degradation products, was evaluated. The second part of this thesis focused on the development and application of osteoinductive composite materials based on PTMC for use in orbital floor reconstruction to guide bony regeneration of the orbital floor.

## GUIDED BONE REGENERATION

Guided bone regeneration (GBR) in implant dentistry can be defined as the use of a barrier membrane to provide available space for new bone formation in a bony defect. Generally, the use of barrier membranes leads to predictable bone formation in GBR, by preventing in-growth of fibroblasts and provision of space for osteogenesis within a blood clot formed in the defect. This barrier effect can be achieved with various biocompatible materials. Nowadays, two types of barrier membranes are available: non-resorbable and resorbable membranes. Non-resorbable membranes find a main disadvantage in the need for their removal in a second operation. The majority



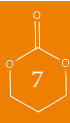of the currently available resorbable membranes are either animal derived or based on lactide and glycolide polymers. The former carry the risk of disease transmission to humans and the latter are known for their adverse tissue reactions, *e.g.* postoperative swelling and acidic degradation products. The ideal membrane properties are: clinically manageable and occlusive, space maintaining and resorbable in a favourable manner. It was hypothesized that a membrane made from poly(trimethylene carbonate) (PTMC) could feature these properties.

In **Chapter 2** a study is described in which a PTMC membrane was applied for GBR. The objective of this study was to assess the suitability of PTMC barrier membranes in GBR of critical size rat mandibular defects, and to compare their performance with collagen and expanded polytetrafluoroethylene (e-PTFE) membranes. For this, PTMC membranes with a thickness of 0.3 mm were prepared by compression moulding. Critical size rat mandibular defects were created and covered with either PTMC membranes, collagen or e-PTFE membranes. Non-treated defects served as control. After 2, 4 and 12 weeks implantation time the animals were sacrificed and bone regeneration in the defects was analysed by micro-radiography and micro-computed tomography. In contrast to the uncovered mandibular defects (controls), substantial bone healing was observed in defects covered with either barrier membrane. In the latter case, the formation of bone was progressive over 12 weeks. The amount of new bone formed underneath the PTMC membranes was not statistically significant different compared to the amount of bone formed under the collagen and e-PTFE membranes. Therefore, it can be concluded that, when compared to the already clinically applied collagen and e-PTFE membranes, barrier membranes based on PTMC are equally well suited for use in guided bone regeneration in critical size rat mandibular defects.

The *in vivo* behaviour of the PTMC barrier membranes and the reaction of the surrounding tissues to the degrading membranes were assessed in the study described in **Chapter 3**. The aim of that study was to evaluate histologically the response of the surrounding tissues to the newly developed PTMC barrier membranes. Besides this, the bone formation beneath and the space maintaining properties of the PTMC membranes were evaluated. A standard resorbable collagen membrane served as control.

In 24 male Sprague-Dawley rats a single-sided standardized 5.0 mm circular bicortical critical size defect was created in the mandibular angle. The defects were covered with either the PTMC membrane or the collagen membrane. After 2, 4 and 12 weeks the rats were sacrificed and a histological analysis was performed. Both a qualitative and semiquantitative scoring analysis was carried out. The PTMC membranes induced a mild tissue reaction. No adverse tissue reactions, other than the normal foreign body reactions were observed. The amount of bone formation beneath the PTMC membrane was not significantly different from the collagen membrane. The handling and space maintaining properties of the PTMC membranes were superior to the collagen membrane.

From this study it was concluded that the newly developed PTMC membranes can be used successfully as barrier membranes in critical size rat mandibular defects. There were no adverse tissue reactions observed. Moreover, compared to collagen membranes PTMC membranes exert superior handling and space maintaining properties.



## ORBITAL FLOOR DEFECTS

Orbital floor fractures are a common result of orbital injury. As a result of an orbital floor fracture the volume of the orbit can increase with diplopia, hypoglobus and enophthalmos as well known consequences. Surgical reconstruction of the bony orbital floor can obviate the aforementioned complications. A most important asset in the treatment is the anatomical reconstruction of the orbital floor and thereby restoring the pre-existent volume. To achieve this a wide variety of materials has been used, ranging from autologous bone grafts to non-resorbable and resorbable alloplastic implants like *e.g.* titanium, polyethylene, silicone, and polylactic and -glycolic acid.

After surgical reconstruction deformation (sagging) of the reconstruction materials can occur. There are 4 important variables that influence the deformation of a reconstruction material: (1) the size of the orbital floor defect, (2) the mechanical properties of the used reconstruction material, (3) the thickness of the reconstruction material and (4) the pressure load of the orbital content on the reconstruction material.

In **Chapter 4**, a study is described in which an engineering model of the orbital floor was developed by which materials for orbital floor reconstruction can be evaluated. The 4 above mentioned variables were incorporated in the mathematical engineering model. With this model, recommendations regarding the choice of implant material in orbital floor reconstruction can be worked out taking the defect size into consideration. The proposed engineering model is presumed to be helpful in the preoperative evaluation of reconstruction materials taking the relation between material properties and defect size into account. In this way it is helpful to surgeons in the decision process on which material(s) could be suitable for reconstruction of a defect in the orbital floor.

Ideally, bone is regenerated in the treatment of orbital floor fractures. The synthetic materials currently used for orbital floor reconstruction do not lead to regeneration of bone, due to the absence of osteoinductive properties. The development, preparation and (mechanical) evaluation of composite and laminated composite materials composed of PTMC and a bioactive calcium phosphate, intended for use in orbital floor reconstruction, is described in **Chapter 5**. The effect of different amounts of the ceramic (*i.e.* calcium phosphate) component (15 and 30 vol%) on the mechanical properties was investigated and the effect of lamination with minimal amounts of poly(D,L-lactide) (PDLLA) was assessed. Scanning electron microscopy (SEM) of the developed composite materials showed that homogenous composite materials based on PTMC and  $\beta$ -tricalcium phosphate microparticles ( $\beta$ -TCP) with a particle size  $<50\ \mu\text{m}$  had been prepared by coprecipitation methods and compression moulding. To assess the suitability as load bearing devices, the flexural properties of the prepared (laminated) composites were determined in three-point bending experiments and compared with those of currently used reconstruction devices. Using relevant anatomical and clinical data, as well as the mathematical engineering model (see **Chapter 4**) describing the deformation of reconstruction materials over orbital floor defects, we were able to assess the suitability of the prepared materials for orbital floor reconstruction. The flexural modulus of PTMC composites increased from 6 MPa to 17 MPa when introducing 30 vol%  $\beta$ -TCP. Composites laminated with minimal amounts of PDLLA had a flexural modulus of 64 MPa. When evaluated with the mathematical engineering model of the

orbital floor the (laminated) composite materials showed similar behaviour compared to currently used materials. Therefore it was concluded that from a mechanical point of view the (laminated) composite sheets are well suited for use in orbital floor reconstruction as they perform better or equal to currently used implant materials like silicone rubber, PTFE and titanium.

The synthetic materials currently used for orbital floor reconstruction do not lead to regeneration of bone, due to the absence of osteoinductive properties. Our objective was to render polymeric materials based on poly(trimethylene carbonate) (PTMC) osteoinductive, and to evaluate their suitability for use in orbital floor reconstruction in a pilot study. As stated earlier, ideally bone is regenerated in the treatment of orbital floor fractures. For this osteoinductive biphasic calcium phosphate (BCP) particles were introduced into a polymeric matrix of PTMC.

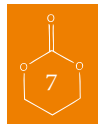In **Chapter 6**, the *in vivo* evaluation of these (laminated) composites composed of PTMC and biphasic calcium phosphate (BCP) for use in the reconstruction of orbital floor fractures is described. Homogenous composite sheets of PTMC were prepared containing 50 wt% (corresponding to 30 vol%) of BCP particles. Also laminates with poly(D,L-lactide) (PDLLA) were prepared by compression moulding a thin layer of PDLLA onto the composite sheets. After sterilization by gamma irradiation the sheets were used to reconstruct surgically created orbital floor defects in sheep. Samples of the orbital implants were implanted intramuscularly to serve as controls. Ten full-grown female Dutch Texel sheep were operated on and (evenly) divided into two groups. The first group had a follow-up of three months, the second a follow-up of nine months. To assess the position of the reconstructed orbital floor, all sheep were evaluated by cone-beam computer tomography (CBCT) one week before and one week after surgery and at time of termination. To monitor the bone formation over time, fluorochrome markers were administered. Bone formation was evaluated by histology and histomorphometry of non-decalcified sections using epifluorescent and conventional light microscopy.

Histological evaluation revealed that bone formation was present in orbital and intramuscular implantations containing BCP after three and nine months. Analysis of the CBCT scans showed that the composite and laminated sheets performed well after three and nine months. Only minimal deformation had occurred.

From this study it was concluded that composites and PDLLA laminated composites based on PTMC and BCP exert osteoinductive properties and are promising materials for orbital floor reconstruction. Furthermore, it was concluded that the resorbable polymeric matrix consisting of PTMC did not hinder the osteoinductive properties of the incorporated BCP particles.

## GENERAL DISCUSSION

As can be read in the summary, this thesis focused on the application of PTMC and composites based on PTMC and BCP in oral and maxillofacial surgery. The results of the various animal studies have shown that the developed materials seem promising for use in their intended applications, respectively as barrier membranes in GBR techniques and in the surgical treatment of orbital floor fractures.



## GUIDED BONE REGENERATION

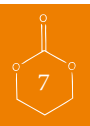The presented studies in **Chapters 2** and **3** have demonstrated that the new PTMC membrane can be used successfully as a biodegradable barrier membrane for GBR in critical-size defects of the mandible in rats. In defects treated with the PTMC membrane an amount of bone was formed comparable to defects covered with the collagen or e-PTFE membrane. Furthermore, the studies indicated a benign soft tissue response to the PTMC membranes and good space maintaining properties. Therefore it could be concluded that PTMC membranes are promising materials for use in guided bone regeneration techniques. To introduce the membranes in the treatment modality in humans, next a feasibility study in humans seems justified with respect to the results shown by the animal studies.

For GBR procedures it is known that in order to gain predictable bone formation in bony defects the barrier effect of membranes should be guaranteed for a time sufficient to allow the bony defect to be filled with bone<sup>1-3</sup>. Generally, larger defects need more time to heal. This implies that the barrier function of membranes applied for larger defects should be prolonged too. In this respect, tuning of the degradation rate and overall degradation time can be further optimized as the PTMC membranes we have developed were almost completely resorbed after 12 weeks of implantation in rats. To prolong the degradation rate and time several modifications to the polymer and the membrane are possible: by simply thickening of the membrane a prolonged degradation time is provided, although this implies using more material. The polymer properties can be adjusted by lowering the molecular weight, irradiating at higher doses of gamma radiation and copolymerization with other monomers<sup>4-6</sup>. These adjustments will also lead to a prolonged degradation time.

However, other adjustments to enhance the material properties are also of interest. Rendering osteoinductive properties to the PTMC membranes as was done for the orbital floor reconstruction materials described in this thesis, seems a logical next step in the process of pursuing the conditions for the ideal barrier membrane. Although, it should be realized that the addition of a ceramic component to the membranes not only could have an effect on bone formation, but also on degradation rate and time. To what extent this will influence the membranes behaviour and degradation profile is currently under investigation.

## ORBITAL FLOOR RECONSTRUCTION

Besides an anatomical reconstruction of the orbital floor bone at the fracture site, ideally bone is regenerated in the treatment of orbital floor fractures<sup>7,8</sup>. The materials currently used for orbital floor reconstruction, except for autologous bone, do not regenerate bone, due to the absence of osteoinductive properties<sup>7,8</sup>. Our objective was to add osteoinductive properties to polymeric materials based on poly(trimethylene carbonate) (PTMC) for use in orbital floor reconstruction techniques. For this purpose, calcium phosphate particles were introduced into a polymeric matrix of PTMC. These calcium phosphate particles have osteoinductive properties. In the study in **Chapter 6** the developed composite sheets were used to reconstruct surgically created orbital floor defects in sheep. The results regarding bone formation as well as stable orbital floor reconstruction, as shown by the CBCT, seem very promising.

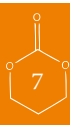

During the surgical procedures in our study it became clear that regarding the shape-ability the composite and the laminated composite, as well as the PTMC implants could be cut easily into the desired shape. Most importantly, however, our results showed that the composite as well as the laminated composite implants exerted osteoinductive properties. Contrary to the laminated composites, the composite implants showed excellent osseous integration of the newly formed bone with the host bone. This could prove to be vital in the long-term regarding bony regeneration of the orbital floor, to prevent migration and sagging of the reconstructed orbital floor as well as regenerated bony orbital floor.

Although the thin PDLA layer seems to hinder the osseous integration of the laminated composite sheets, at least up to nine months as shown by our study, we did not encounter migration of the implants. Knowing that the composite sheet performed similarly in orbital reconstruction compared to the laminated composite might have given the impression that the PDLA is redundant and could be omitted when orbital floor defects with sizes up to 3.0 cm<sup>2</sup> are considered. In fact this is true. However, when more demanding stable configurations are required, for example when orbital wall reconstructions are performed of the 'key area' <sup>9</sup> or when multiple wall defects are considered, the addition of the PDLA layer might prove to be advantageous too, as it is known that PDLA can be bent, when heated, into different configurations and more important can retain these configurations after cooling. This is not the case when the developed composite sheets are considered. Although they can be cut easily, the surgeon cannot form the implant to his specific needs in all cases.

A limitation of this study is the relatively small number of animals used for the different materials and the relatively short maximum follow-up of nine months. Nevertheless, conclusions regarding the osteoinductivity of the composite materials and the formation of bone can still be drawn. The results of the performed study in **Chapter 6** clearly show the formation of bone around calcium phosphate particles in the degrading (laminated) composite implants implanted in the orbit and musculature of sheep. Similarly, the reconstruction of orbital floor defects in sheep seems stable up till at least nine months. Whether these conclusions (with)stand long(er)-term results remains an untold story yet.

The next step will therefore be conducting a similar study with a larger sample size, to draw final conclusions on the bone forming ability, long term resorption and suitability of these devices for orbital floor reconstruction. In this study also the so-called key area and multiple wall defects will have to be considered in order to evaluate form-stability of (modified) composite reconstruction materials in more sophisticated configurations.



## CONCLUDING REMARKS

The performed studies in this thesis have shown that the developed medical devices, barrier membranes and the composite materials, seem promising devices for use in guided bone regeneration techniques, with regard to bone formation. Furthermore, the findings of the performed studies offer new perspectives for future research. After all, now that it is established that the resorbable polymeric PTMC matrix neither hinders bone formation nor hinders the osteoinductive properties of the osteoinductive calcium phosphate particles, research could focus on further improvement of these materials. And so, future research will focus on the introduction of these resorbable devices into the treatment modalities in humans.



## REFERENCES

1. Murray G, Holden R, Roschlaw W: Experimental and Clinical Study of New Growth of Bone in a Cavity. *Am J Surg* 93:385, 1957
2. von Arx T, Broggini N, Jensen SS, Bornstein MM, Schenk RK, Buser D: Membrane durability and tissue response of different bioresorbable barrier membranes: A histologic study in the rabbit calvarium. *Int J Oral Maxillofac Implants* 20:843, 2005
3. von Arx T, Cochran DL, Schenk RK, Buser D: Evaluation of a prototype trilayer membrane (PTLM) for lateral ridge augmentation: an experimental study in the canine mandible. *Int J Oral Maxillofac Surg* 31:190, 2002
4. Bat E, Plantinga JA, Harmsen MC, van Luyn MJA, Feijen J, Grijpma DW: In vivo behavior of trimethylene carbonate and epsilon-caprolactone-based (co)polymer networks: Degradation and tissue response. *Journal of Biomedical Materials Research Part a* 95A:940, 2010
5. Pego AP, Van Luyn MJA, Brouwer LA, van Wachem PB, Poot AA, Grijpma DW, Feijen J: In vivo behavior of poly(1,3-trimethylene carbonate) and copolymers of 1,3-trimethylene carbonate with D,L-lactide or epsilon-caprolactone: Degradation and tissue response. *Journal of Biomedical Materials Research Part a* 67A:1044, 2003
6. Zhang Z, Kuijjer R, Bulstra SK, Grijpma DW, Feijen J: The in vivo and in vitro degradation behavior of poly(trimethylene carbonate). *Biomaterials* 27:1741, 2006
7. Potter JK, Ellis E: Biomaterials for reconstruction of the internal orbit. *Journal of Oral and Maxillofacial Surgery* 62:1280, 2004
8. Bairo F: Biomaterials and implants for orbital floor repair. *Acta biomaterialia* 7:3248, 2011
9. Hammer B. Orbital Reconstruction. In: *Craniofacial Reconstructive and Corrective Bone Surgery: Principles of Internal Fixation Using the AO/ASIF Technique*. Alex M. Greenberg and Joachim Prein, editors. New York: Springer-Verlag; 2002. p 478-482





# Samenvatting

In dit proefschrift wordt de ontwikkeling en toepassing van membranen en composiet implantaten op basis van het polymeer poly(trimethyleen carbonaat) (PTMC) voor gebruik in de Mond-, Kaak- en Aangezichtschirurgie beschreven.

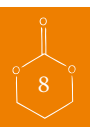
In de inleiding van het proefschrift (hoofdstuk 1) wordt kort de evolutie van biomaterialen door de eeuwen heen tot vandaag de dag beschreven. De keuze van materialen is geëvolueerd van metalen en natuurlijke materialen naar polymere kunststoffen en resorbeerbare polymeren (kunststoffen). Allemaal met één doel: de functie van en verloren gegane delen van het lichaam te herstellen. Tegenwoordig is de belangstelling verschoven naar het gebruik van bioactieve (bio)materialen welke in staat zijn om de ontbrekende weefsels te regenereren. Bij voorkeur zijn deze materialen resorbeerbaar tijdens en na afronding van hun functie. Een probleem met resorbeerbare materialen kan echter zijn, dat hun afbraakproducten zelf de omliggende weefsels beschadigen. Dit is ongewenst en moet worden vermeden. Zo is bij het gebruik van biologisch afbreekbare polymeren voor (bot)weefselregeneratie doeleinden het van groot belang dat de afbraakproducten zelf geen negatief effect op het bot en geregeneerd botweefsel hebben. Daarom lijken polymeren die afbreken zonder de vorming van schadelijke afbraakproducten het meest geschikt. Momenteel zijn verschillende biologisch afbreekbaar polymere materialen beschikbaar voor gebruik in bot-en weefselregeneratie toepassingen, echter één materiaal in het bijzonder lijkt erg interessant en heeft meer aandacht gekregen de laatste decennia: poly (trimethyleencarbonaat) (PTMC).

Het doel van dit promotieonderzoek is om implantaten op basis van PTMC te ontwikkelen en te testen voor gebruik in de Mond-, Kaak- en Aangezichtschirurgie. Dit proefschrift bestaat uit 2 delen. Het eerste deel beschrijft de ontwikkeling van resorbeerbare barrière membranen voor gebruik in guided bone regeneration (GBR) (geleide bot regeneratie) procedures voorafgaande aan het plaatsen van tandheelkundige implantaten. Het tweede deel beschrijft de ontwikkeling van resorbeerbare osteoinductieve (botinducerende) composiet implantaten voor gebruik in de reconstructie van orbitabodem fracturen.

In het eerste deel van dit proefschrift, te weten hoofdstuk 2 en 3 wordt de geschiktheid van PTMC membranen in de functie van barrière membraan in GBR geëvalueerd. Hoofdstuk 2 beschrijft het effect van de nieuw ontwikkelde membranen op de botregeneratie in een studie bij ratten. In hoofdstuk 3 wordt het gedrag van het omliggende weefsel op de afbraak- en reactieproducten van de membranen geëvalueerd. Het tweede deel van dit proefschrift beschrijft de ontwikkeling en toepassing van osteoinductieve composiet materialen op basis van PTMC voor gebruik in de reconstructie van orbitabodemfracturen.

## GUIDED BONE REGENERATION

Guided bone regeneration ofwel geleide bot regeneratie (GBR) kan als volgt worden gedefinieerd: het creëren van beschikbare ruimte voor botvorming/ingroei in een benig defect met behulp van een barrière membraan. Het gebruik van barrière membranen leidt over het algemeen tot voorspelbare hoeveelheden nieuw gevormd bot door het voorkomen van ingroei van fibroblasten en het voorzien in ruimte voor botingroei. Dit barrière effect kan worden bereikt met verschillende biocompatibele materialen. Vandaag de dag zijn twee soorten barrière membranen beschikbaar: niet-resorbeerbare

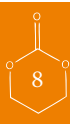

en resorbeerbare membranen. Niet-resorbeerbare membranen hebben als nadeel dat ze in een tweede operatie verwijderd moeten worden, in tegenstelling tot de oplosbare membranen welke oplossen en daarom niet verwijderd hoeven te worden. De meeste van de beschikbare resorbeerbare membranen zijn of van dierlijke oorsprong of gebaseerd op lactide en glycolide polymeren. Eerstgenoemde dragen het risico van de overdracht van ziekten van dier naar mens, laatstgenoemde zijn berucht om hun zure afbraakproducten en nadelige weefselreacties zoals bijvoorbeeld postoperatieve zwelling.

De ideale eigenschappen voor een barrière membraan zijn: synthetisch materiaal, klinisch goede hanteerbaarheid, goede oclusieve eigenschappen met space maintaining eigenschappen en bovenal resorbeerbaar zonder schadelijke afbraakproducten. De hypothese is dat een membraan gemaakt van poly (trimethyleencarbonaat) (PTMC) al deze eigenschappen zou kunnen bezitten.

In hoofdstuk 2 wordt een studie beschreven waarin het PTMC membraan wordt toegepast in een GBR procedure. Het doel van deze studie is om PTMC membranen te evalueren als barrière membraan in een GBR procedure in onderkaakdefecten bij de rat en daarbij de prestaties te vergelijken met een collageen en een expanded polytetrafluorethyleen (e-PTFE) membraan. Ten behoeve van deze studie werden PTMC membranen met een dikte van 0,3 mm vervaardigd middels een compression moulding techniek. Onderkaakdefecten met een kritieke omvang werden aangebracht in ratten en bedekt met PTMC membranen, collageen of e-PTFE membranen. Niet-behandelde defecten dienden als controle. Vervolgens werden 2, 4 en 12 weken na implantatie dieren opgeofferd en werd de hoeveelheid nieuw gevormd bot in de defecten geanalyseerd met micro-radiografie en micro-CT. In tegenstelling tot in de onbedekte defecten (controles) werden aanzienlijke hoeveelheden nieuw gevormd bot waargenomen in de defecten bedekt met een barrière membraan. De hoeveelheid nieuw gevormd bot onder de PTMC membranen was niet verschillend van de hoeveelheden bot gevormd onder de collageen en e-PTFE membranen. Derhalve kan geconcludeerd worden dat, in vergelijking met de reeds klinisch toegepaste collageen en e-PTFE membranen barrière membranen, de PTMC membranen evenzo goed geschikt zijn voor geleide bot regeneratie in onderkaakdefecten van de rat.

In hoofdstuk 3 wordt het gedrag van de PTMC barrière membranen en de reactie van het omliggende weefsel op de degraderende PTMC membranen beoordeeld in een studie in ratten. In deze studie werd histologisch gekeken naar de reactie van de omliggende weefsels op de nieuw ontwikkelde PTMC barrière membranen. Daarnaast werden de botvorming onder en de space maintaining eigenschappen van de PTMC membranen geëvalueerd. Een resorbeerbaar collageen membraan (BioGide Geistlich) diende als controle. In 24 ratten werden evenals in de studie beschreven in hoofdstuk 2 enkelzijdige gestandaardiseerde bicorticale defecten gemaakt in de onderkaak met een diameter van 5.0 mm. De defecten werden (dubbelzijdig) bedekt met ofwel het PTMC membraan of het collageen membraan. Na 2, 4 en 12 weken werden de ratten geofferd en histologisch geëvalueerd. Zowel een kwalitatieve als semi-kwantitatieve evaluatie werd uitgevoerd. De PTMC membranen veroorzaakten een lichte weefselreactie. Geen nadelige weefselreacties, anders dan de normale vreemd lichaam reacties werden waargenomen. De hoeveelheid botvorming tussen de PTMC membranen was niet significant verschillend van die tussen de collageen membranen. De klinische hanteerbaarheid en de space maintaining eigenschappen van de PTMC membranen bleken superieur

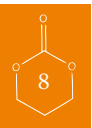

aan die van het collageen membraan. Naar aanleiding van de uitkomsten van deze studie kon worden geconcludeerd dat de nieuw ontwikkelde PTMC membranen met succes kunnen worden gebruikt als barrière membranen bij de geleide bot regeneratie in onderkaakdefecten van kritische omvang in ratten. Er werden geen nadelige weefselreacties waargenomen. Bovendien, bleek dat in vergelijking met de collageen membranen, de PTMC membranen superieure handling en space maintaining eigenschappen bezitten.

## FRACTUREN VAN DE ORBITABODEM

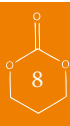Fracturen van de orbitabodem (oogkasbodem) komen vaak voor in samenhang met letsels van de orbita (oogkas). Als gevolg van een orbitabodemfractuur kan het volume van de orbita toenemen met diplopie (dubbelzien), hypoglobus en enophthalmos (laagstand en terugliggen van oog) als vervellende gevolgen. Chirurgische reconstructie van de benige orbitabodem kan de bovengenoemde complicaties verhelfen en voorkomen. Een zeer belangrijk punt bij de behandeling is de anatomische reconstructie van de orbitabodem en daarmee het pre-existente volume. Voor de reconstructie van orbitabodemfracturen is een veelheid aan materialen gebruikt, variërend van autoloog bot tot niet-resorbeerbare en resorbeerbare alloplastische implantaten. Bekende voorbeelden hiervan zijn titanium, polyethyleen, siliconen en polylactide en -glycolzuur. Na chirurgische reconstructie kan vervorming (uitzakken) van de reconstructiematerialen optreden. Er zijn vier belangrijke variabelen die de vervorming van een reconstructie materiaal beïnvloeden: (1) de grootte van het defect in de orbitabodem, (2) de mechanische eigenschappen van het gebruikte reconstructiemateriaal (3) de dikte van het reconstructiemateriaal en (4) de druk-belasting van de orbitainhoud op het reconstructiemateriaal. In hoofdstuk 4 wordt de ontwikkeling van een wiskundig model van de orbitabodem beschreven. In dit model kunnen reconstructiematerialen die gebruikt worden voor reconstructie van defecten van de orbitabodem worden geëvalueerd. De 4 bovengenoemde variabelen werden opgenomen in het model. Het voorgestelde model kan behulpzaam zijn bij de preoperatieve evaluatie van reconstructiematerialen waarbij de relatie tussen materiaaleigenschappen en defectgrootte in acht wordt genomen. Op deze manier is het model nuttig voor chirurgen in de besluitvorming aangaande welk(e) materiaal(en) geschikt zouden kunnen zijn voor de reconstructie van de orbitabodem.

Idealiter wordt nieuw bot geregenereerd tijdens en na de behandeling van fracturen van de orbitabodem. Echter de huidige kunststof materialen die voor reconstructie van orbitabodemdefecten worden gebruikt doen dit niet vanwege de afwezigheid van osteoinductieve (botinducerende) eigenschappen. In hoofdstuk 5 wordt de ontwikkeling en mechanische evaluatie van composiet materialen gebaseerd op PTMC en een bioactief calciumfosfaat beschreven. De composieten werden ontwikkeld met het doel om als reconstructie materiaal te dienen bij de reconstructie van orbitabodemdefecten. Naast de ontwikkeling werd het effect van verschillende hoeveelheden van het calciumfosfaat (15 en 30 vol%) op de mechanische eigenschappen onderzocht evenals de werking van lamineren met minimale hoeveelheden poly(D, L-lactide) (PDLA). Door middel van een co-precipitatie en compression moulding proces werden composieten vervaardigd bestaande uit een PTMC matrix met daarin  $\beta$ -tricalciumfosfaat microdeeltjes ( $\beta$ -TCP). Om de geschiktheid van de composieten voor orbitabodemreconstructies te evalueren, werd de buigsterkte van de composieten bepaald in een



buigtest. Vervolgens werden de materialen met behulp van relevante anatomische en klinische gegevens in het (beschreven) wiskundige model (zie hoofdstuk 4) geëvalueerd. De buigmodulus van de PTMC composieten werd verhoogd van 6 MPa naar 17 MPa bij het incorporeren van 30 vol%  $\beta$ -TCP. Composieten gelamineerd met minimale hoeveelheden PDLA hadden een buigmodulus van 64 MPa. Evaluatie in het wiskundige model liet zien dat de (gelamineerde) composieten in vergelijking met enkele reeds klinisch in gebruik zijnde reconstructie materialen vergelijkbaar gedrag vertoonden. Daarom werd geconcludeerd dat vanuit mechanisch oogpunt de (gelamineerd) composiet implantaten geschikt zijn voor gebruik in de reconstructie van orbitabodemfracturen.

Zoals reeds gesteld wordt idealiter nieuw bot geregenereerd tijdens en na de behandeling van orbitabodemfracturen. De synthetische materialen die momenteel voor orbitabodemreconstructie worden gebruikt leiden niet tot de regeneratie van bot, vanwege de afwezigheid van botinducerende eigenschappen. Daarom was het doel van een deel van de in het proefschrift beschreven studies om polymere materialen op basis van poly(trimethyleencarbonaat) (PTMC) osteoinductief te maken. Dit botinducerend karakter werd gerealiseerd door het toevoegen van bioactief calciumfosfaat. In hoofdstuk 6 wordt de *in vivo* evaluatie van de bovengenoemde (gelamineerde) composieten bestaande uit een polymere matrix van PTMC en bifasische calciumfosfaat deeltjes (BCP) voor gebruik in de reconstructie van orbitabodemdefecten beschreven. Composieten bestaande uit een polymere PTMC matrix en 30 vol% van BCP deeltjes werden vervaardigd middels de in hoofdstuk 5 reeds beschreven techniek. Wederom werden ook gelamineerde composieten met poly(D, L-lactide) (PDLA) vervaardigd. Na sterilisatie met gammastraling werden de (gelamineerde) composieten gebruikt om bewust chirurgisch gecreëerde orbitabodemdefecten bij schapen te reconstrueren. Tevens werden monsters van de in de oogkas gebruikte reconstructiematerialen intramusculair geïmplantéerd om te dienen als controle. In deze studie werden 10 volwassen Texelse oaien geopereerd en (gelijmatig) verdeeld in twee groepen. De eerste groep had een follow-up van drie maanden, de tweede een follow-up van negen maanden. Om postoperatief en aan het eind van de follow-up de positie van de gereconstrueerde orbitabodem te beoordelen, m.a.w. de (eventuele) vervorming van de gereconstrueerde orbitabodem, werden alle schapen geëvalueerd door middel van cone-beam computer tomografie (CBCT) een week voor en een week na de operatie en op het moment van terminatie. Om de (nieuw) botvorming in de tijd te volgen, werden fluorochrome markers toegevend. De vorming van bot werd geëvalueerd door histologische en histomorphometrische analyse van niet-ontkalkte explantaten met behulp van epifluorescerende en conventionele lichtmicroscopie. Uit de histologische evaluatie bleek dat botvorming aanwezig was zowel in de implantaties in de orbita (orbitabodem) als in de intramusculaire implantaties in de (gelamineerde) composieten na drie en negen maanden. Na analyse van de CBCT scans bleek dat voor zowel de composieten als gelamineerde composieten na drie en negen maanden een minimale, doch niet kritieke, vervorming had plaatsgevonden. Uit de resultaten van deze studie kan worden geconcludeerd dat de resorbereerbare polymere matrix van PTMC niet de osteoinductieve eigenschappen van de ingebouwde BCP deeltjes belemmert en dat composieten en PDLA gelamineerde composieten op basis van PTMC en BCP osteoinductieve eigenschappen uitoefenen en veelbelovend zijn als reconstructiemateriaal in de behandeling van orbitabodemfracturen.





# Gearfetting



Yn dit proefskrift wurdt de ûntwikkeling en tapassing fan membranen en komposit ymplantaten op basis fan it polymeer poly(trimethyleen carbonaat) (PTMC) foar gebrûk yn de Mûle-, Kaak- en Oangesichtssjirurgy beskreaun.

Yn de ynliding fan it proefskrift (haadstik 1) wurdt koart de ûntwikkeling fan biomaterialen troch de ieuwen hinne oan hjoed de dei beskreaun. De kar fan materialen is evoluearre fan metalen en natuerlike materialen nei polymere keunststoffen en ôfbrekberere polymeren (keunststoffen). Allegearre mei ien doel: de funksje fan en ferlerne gonge dielen fan it lichem better te meitsjen. Tsjinwurdich is de belangstelling ferskoud nei it gebrûk fan bioaktive biomaterialen hokker ynsteat binne om de ûntbrekkende weefsels te regenerearjen. By foarkar binne dizze materialen ôfbrekber ûnder en nei ôfrûning fan harren funksje. In swierrichheid mei ôfbrekberere materialen kin lykwols wêze dat harren ôfbrekprodukten sels de omlizzende weefsels skeine. Dit is net winslik en moat foarkommen wurde. Sa is by it gebrûk fan biologysk ôfbrekberere polymeren foar (bonke) weefselregeneraasje doelen it fan grut belang dat de ôfbrekprodukten sels gjin negatyf effekt ha op de bonke en it regenerereard bonkeweefsel. Dêrom lykje polymeren dy ôfbrekke sûnder de foarming fan skalike ôfbrekprodukten it meast geskikt. Hjoed de dei binne ferskillende biologyske ôfbrekberere polymere materialen beskikber foar gebrûk yn de bonke- en weefselregeneraasje tapassingen, lykwols ien materiaal yn it bysûnder liket tige nijsgjirrich en hat mear omtinken krigen de lêste desennia: poly(trimethyleen carbonaat) (PTMC).

It doel fan dit promoasjeûndersyk is om ymplantaten op grûn fan PTMC te ûntwikkeljen en te testen foar gebrûk yn de Mûle-, Kaak- en Oangesichtssjirurgy. Dit proefskrift bestiet út 2 dielen. It 1<sup>ste</sup> diel beskriuwt de ûntwikkeling fan ôfbrekberere barriêre membranen foar gebrûk yn guided bone regeneration (GBR) (stjûrde bonke bymeitsjen) prosedures foarôfgeand oan it pleatsen fan toskehiekkundige ymplantaten. It 2<sup>de</sup> diel beskriuwt de ûntwikkeling fan ôfbrekberere bonkefoarming befoarderjend komposit ymplantaten foar gebrûk yn de rekonstruksje fan eachatboaiem breuken.

Yn it 1<sup>ste</sup> diel fan dit proefskrift te witten haadstik 2 en 3 wurdt de gaadlikens fan PTMC membranen yn de funksje fan barriêre membranen yn GBR evaluearre. Haadstik 2 beskriuwt it effekt fan de nij ûntwikkelde membranen op de bonkeregeneraasje yn in stúdzje by rotten. Yn haadstik 3 wurdt it gedrach fan it omlizzende weefsel op de ôfbrek-en reaksjeprodukten fan de membranen evaluearre. It 2<sup>de</sup> diel fan dit proefskrift beskriuwt de ûntwikkeling en tapassing fan bonkefoarming befoarderjende komposit materialen op basis fan PTMC foar gebrûk yn de rekonstruksje fan eachatboaiem breuken.

## GUIDED BONE REGENERATION

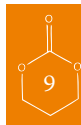
Guided bone regeneration oftewol stjûrde bonke bymeitsjen (GBR) kin as folgt definiearre wurde: it kreëarjen fan beskikbere rûmte foar bonkefoarming/yngroei yn in bonkich defekt mei help fan in barriêre membraan. It gebrûk fan barriêremembranen liedt oer it generaal ta foarsisbere protten nij foarme bonke troch it foarkommen fan yngroei fan fibroblasten en it foarsjen yn rûmte foar bonkeyngroei. Dit barriêre effekt kin berikt wurde mei ferskillende biocompatibele materialen. Hjoed de dei binne 2 soarten barriêre membranen beskikber: net-

ôfbrekbere en ôfbrekbere membranen. Net-ôfbrekbere membranen ha as neidiel dat se yn in 2<sup>de</sup> operaasje ferwiderd wurde moatte, yn tsjinstelling oant de ôfbrekbere membranen dy oplosse en dêrom net ferwiderd hoege te wurden. De measte fan de beskikbere ôfbrekbere membranen binne as fan dierlike oarsprong as basearre op lactide en glycolide polymeren. Earstneamde drage it risiko fan de oerdracht fan sykten fan bist nei minske, lêstneamde binne berucht om harren soere ôfbrekprodukten en neidielige weefselreaksjes sa as bygelyks tining (zwellling) nei de operaasje.

De ideale eigenskippen foar in barriêre membraan binne: keunst materiaal, klinysk goede handichheid, goede tichtmeitsjende eigenskippen mei rûmte hânholdende eigenskippen en boppeal ôfbrekber sûnder skalike ôfbrekprodukten. De ûnderstelling is dat in membraan makke fan poly(trimethyleen carbonaat) (PTMC) oan al dizze eigenskippen kin foldwaan.

Yn haadstik 2 wurdt in stúdzje beskreaun wêryn it PTMC membraan wurdt tapast yn in GBR proseduere. It doel fan dizze stúdzje wie om PTMC membranen te evaluarjen as barriêremembraan yn in GBR proseduere yn ûnderkaakdefekten by de rôten en dêrby de prestaasjes te ferlikenje mei collageen en in expanded polytetrafluorethyleen (e-PTFE) membraan. Foar dizze stúdzje waarden PTMC membranen mei in dikte fan 0.3 mm makke troch in compression moulding technyk. ûnderkaakdefekten mei in kritike omfang waarden oanbrocht yn rotten en bedekt mei PTMC membranen, collageen as e-PTFE membranen. Net-behandelde defekten tsjinden as kontrôle. Ferfolgens waarden 2 en 4 en 12 wiken nei ymplantaasje bisten offere en waard in protte nij foarme bonke yn de defekten ûndersocht mei micro-radiografie en micro-CT. Yn tsjinstelling oant yn de ûnbedekte defekten (kontrôles) waarden oansjenlike protten nij foarme bonke waarnommen yn de defekten bedekt mei in barriêre membraan. De protte nij foarme bonke ûnder de PTMC membranen wie net ferskillend fan de protte bonke foarme ûnder de collageen en e-PTFE membranen. Dêrom kin klonkludearre wurde dat, yn ferliking mei de al klinyske tapast collageen en e-PTFE membranen barriêre membranen, de PTMC membranen krekt sa goed geskikt binne foar stjûrde bonke regeneraasje yn ûnderkaakdefekten fan de rôten.

Yn haadstik 3 wurdt it gedrach fan de PTMC barriêre membranen en de reaksje fan it omlizzende weefsel op de degradearjende PTMC membranen skôgjend (beoardieljend) yn in stúdzje yn rotten. Yn dizze stúdzje waard histologysk sjoen nei de reaksje fan de omlizzende weefsels op de nij ûntwikkelde PTMC barriêre membranen. Dêrneist waarden de bonkefoarming ûnder rûmte behâldende eigenskippen fan de PTMC membranen evaluarre. In ôfbrekber collageen membraan (BioGide Geistlich) tsjinne as kontrôle. Yn 24 rotten waarden lykas yn de stúdzje beskreaun yn haadstik 2 oan ien kant folgens in mjitstêf biocorticale defekten makke yn de ûnderkaak mei in diameter fan 5 mm. De defekten waarden oan beide kanten bedekt mei oftewol it PTMC membraan as it collageen membraan. Nei 2 en 4 en 12 wike waarden de rotten offere en hystologysk evaluarre. Sawol in kwalitative as semy-kwantitative evaluaasje waard útfierd. De PTMC membranen feroarsaakten in bytsje weefselreaksje. Gjin neidielige weefselreaksjes, oars dan de normale frijend lichem reaksjes waarden waarnommen. De protte bonkefoarming tusken de PTMC membranen wie net echt ferskillend fan die tusken de collageen membranen. De klinyske hânsumheid en de rûmte hânholdende eigenskippen fan de PTMC membranen bliken better te wêzen dan die fan it collageen membraan. Nei oanlieding fan de útkomsten fan dizze



stúdzje koe wurde konkludearre dat de nij ûntwikkele PTMC membranen mei sukses kinne wurde brûkt as barriêre membranen by de stjûrde bonke regeneraasje yn ûnderkaakdefekten fan krityske omfang yn rotten. Der waarden gjin neidielige weefselreaksjes waarnommen. Boppedat, blick dat yn ferliking mei de collageen membranen, de PTMC membranen bettere hânsomheid en rûmte hânhâldende eigenskippen besitte.

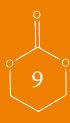## BREUKEN FAN DE EACHGATBOAIEM

Breuken fan de eachgatboaiem komme faak foar yn gearhing mei letsels as gefolch fan it eachgat. As gefolch fan in eachgatboaiem breuk kin it folume fan it eachgat tanimme mei ferfelende gefolgen as dûbel bylden, wei sakjend each en in djipper lizzend each. Sjirurgyske rekonstruksje fan de bonkige eachgatboaiem kin de boppeneamde komplikaasjes ferhelpe en foarkomme. In hiel wichtich punt by de behandeling is de anatomyske rekonstruksje fan de eachgatboaiem en dêrmei it oarspronklike folume. Foar de rekonstruksje fan eachgatboaiem breuken is in protte oan materialen brûkt, fariearjend fan eigen bonke oant net-ôfbrekberere en ôfbrekberere alloplastische ymplantaten. Bekende foarbylden hjirfan binne titanium, polyethyleen, siliconen en polylactide en -glycolzuur. Nei sjirurgyske rekonstruksje kin ferfoarming (útsakjen) fan de rekonstruksjematerialen him foardwaan. Der binne 4 wichtige fariabelen dy de ferfoarming fan in rekonstruksje materiaal beynfloedzje: (1) de grutte fan it defekt yn de eachgatboaiem, (2) de meganyske eigenskippen fan it brûkte rekonstruksjemateriaal, (3) de dikte fan it rekonstruksjemateriaal en (4) de krêft belêsting fan de eachgatynhâld op it rekonstruksjemateriaal. Yn haadstik 4 wurdt de ûntwikkeling fan in wiskundich model fan de eachgatboaiem beskreaun. Yn dit model kinne rekonstruksje materialen dy brûkt wurde foar rekonstruksje fan defekten fan de eachgatboaiem evaluearre wurde. De 4 boppeneamde fariabelen waarden opnommen yn it model. It foarstelde model kin behelpsum wêze by de preoperative evaluaasje fan de rekonstruksje materialen wêrby de relaasje tusken materiaaleigenskippen en defektgrutte yn acht nommen wurdt. Op dizze wize is it model nuttich foar sjirurgen yn de beslútfoarming oangeande hokfoar materiaal geskikt wêze soe foar de rekonstruksje fan de eachgatboaiem.

It leafst wurdt nij bonke regenerarre ûnder en nei de behandeling fan eachgatboaiem breuken. Lykwols, de hjoeddeiske keunststof materialen dy foar rekonstruksje fan eachgatboaiem defekten brûkt wurde dogge dit net fanwege de ôfwêzichheid fan bonkefoarming befoarderjende eigenskippen. Yn haadstik 5 wurdt de ûntwikkeling en meganyske evaluaasje fan komposit materialen basierjend op PTMC en in bioaktyfcalciumfosfaat beskreaun. De kompositen waarden ûntwikkele mei as doel om as rekonstruksje materiaal te tsjinjen by de rekonstruksje fan eachgatboaiem defekten. Neist de ûntwikkeling waard it effekt fan ferskillende protten fan it calciumfosfaat (15 en 30 fol%) op de meganyske eigenskippen ûndersocht lyk as de wurking fan laminearjen mei minimale protten poly(D, L-lactide) (PDLLA). Troch in co-precipitatie en compression moulding proses waarden kompositen makke besteande út in PTMC matrix mei dêryn  $\beta$ -tricalciumfosfaat microdieltsjes ( $\beta$ -TCP). Om de gaadlikens fan de kompositen foar eachgatboaiem rekonstruksjes te evaluearjen waard de bûgsterkte fan de kompositen fêststeld yn in bûgtest. Dernei waarden de materialen mei help fan relevante anatomyske en klinyske feiten yn

it (beskreaune) wiskundige model (sjoch haadstik 4) evaluearre. De bûgmodules fan de PTMC kompositen waard ferhege fan 6 MPa nei 17 MPa by it ferwurkjen fan 30 fol %  $\beta$ -TCP. Kompositen laminearde mei minimale protten PDLLA hiene in bûgmodulus fan 64 MPa. Evaluaasje yn it wiskundige model liet sjen dat de (laminearde) kompositen in ferliking mei in pear al klinysk yn gebrûk wêzende rekonstruksje materialen it selde gedrach sjen lieten. Dêrom waard konkludearre dat fanút meganysk eachpunt de (laminearde) komposit ymplantaten geskikt binne foar gebrûk yn de rekonstruksje fan eachgatboaiem breuken.

Sa-asalsteld, wurdt it leafstnijje bonke regenearre ûnderen nei de behanneling fan eachgatboaiem breuken. De syntetyske materialen dy op dit stuit foar eachgatboaiem rekonstruksje brûkt wurde liede net tot de regeneraasje fan de bonke, fanwege de ôfwêzichheid fan bonkegroei befoarderjende eigenskippen. Dêrom wie it doel fan in diel fan de yn it proefskrift beskreaune stúdzjes om polymere materialen op basis fan poly(trimethyleen carbonaat) (PTMC) bonkefoarming befoarderjend te meitsjen. Dit bonkegroei karakter waard realisearre troch it tafogjen fan bioaktyf calciumfosfaat. Yn haadstik 6 wurdt de yn libbene wêzens evaluaasje fan de boppeneamde (laminearde) kompositen besteande út in polymere matrix fan PTMC en bifasische calciumfosfaat dieltsjes foar gebrûk yn de rekonstruksje fan eachgatboaiem defekten beskreaun. Kompositen besteande út in polymere PTMC matrix en 30 fol% fan BCP dieltsjes waarden makke troch de yn haadstik 5 al beskreaune technyk. Alwer waarden ek laminearde kompositen mei poly(D, L-lactide) (PDLLA) makke. Nei sterilisaasje mei gammastraling waarden de (laminearde) kompositen brûkt om bewust sjirurgysk kreëarde eachgatboaiem defekten by skiep te rekonstruearjen. Tagelyk waarden meunsters fan de yn it eachgat brûkte rekonstruksjematerialen yn de spier ymplantearre om te tsjinjen as kontrôle. Yn dizze stúdzje waarden 10 folwoeksen Texelse skiep operearre en (lykmittich) ferdield yn 2 groepen. De 1<sup>ste</sup> groep hat in kontrôle fan 3 moanne, de 2<sup>de</sup> groep in kontrôle fan 9 moanne. Om nei de operaasje en oan it ein fan de kontrôle de posysje fan de rekonstruearde eachgatboaiem te beoardieljen, mei oare wurden de (mooglike) ferfoarming fan de rekonstruearde eachgatboaiem, waarden alle skiep evaluearre troch middel fan cone-beam computer tomografie (CBCT) in wike foar en in wike nei de operaasje en op it stuit fan beëindigjen. Om de (nije) bonkefoarming yn de tiid te ferfolgjen, waarden fluorochrome markers tatsjinne. De foarming fan bonke waard evaluearre troch histologyske en histomorphometriske analyse fan net-ûntkalkte explantaten mei help fan epifluoresearjende en konvinsjonele ljochtmicroscopie. Út de histologyske evaluaasje blik dat bonkefoarming oanwêzig wie sawol yn de ymplantaasjes yn it eachgat (eachgatboaiem) as yn de spier ymplantaasjes yn de (laminearde) kompositen nei 3 en 9 moanne. Nei analyse fan de CBCT scans blik dat sawol by de kompositen as laminearde kompositen nei 3 en 9 moanne in minimale, dochs net kritike, ferfoarming hie plakfûn. Út de resultaten fan dizze stúdzje kin konkludearre wurde dat de ôfbrekberere polymere matrix fan PTMC net de bonkefoarming befoarderjende eigenskippen fan de ynboude BCP dieltsjes behindert en dat kompositen en PDLLA laminearde kompositen besteande út in PTMC matrix en BCP bonkefoarming befoarderjende eigenskippen útoefenje en folbeloftes binne as rekonstruksjemateriaal yn de behanneling fan de eachgatboaiem breuken.





Dankwoord

Dat het onderzoek nu is waar het is en dat het proefschrift nu voor u ligt zou niet gelukt zijn zonder de hulp van een groot aantal mensen. Graag wil ik een aantal mensen hier persoonlijk voor bedanken.

Allereerst dank ik Prof.dr. LGM de Bont voor de mogelijkheid die mij geboden is om zowel de opleiding tot Kaakchirurg in te gaan en naast het Tandheelkundige gedeelte van deze opleiding het promotieonderzoek te kunnen uitvoeren. Dankzij uw inspanningen in het verleden heerst er een geschikt klimaat voor deze combinatie op de afdeling. Ik wens Dr. FKL Spijkervet veel succes bij het ‘vervullen’ van de leegte die Prof.dr. LGM de Bont achterlaat bij zijn vertrek.

Prof.dr. RRM Bos, hooggeleerde eerste promotor, beste Ruud. Welbeschouwd is het aan jou te danken dat ik hier nu zit. Had jij het niet aangedurfd om met een ‘Groningse’ Fries het onderzoeksbootje in te stappen, dan was er voor mij geen onderzoek en geen opleiding tot Kaakchirurg geweest. Ik dank je voor je begeleiding en inventieve ideeën tijdens onze verschillende onderzoeksbijeenkomsten. Hoewel de biomaterialen die jij voor staat oplossen, verdwijnt je enthousiasme nimmer. We hebben veel met dieren gedaan en mooie resultaten behaalt tijdens het onderzoek, maar ook daarbuiten, getuige een aantal mooie tableaux tijdens gezamenlijke jacht en beheer acties. Gelet op de zéér grote aantallen overwinterende en overzomerende ganzen tegenwoordig zullen we nog vaak samen ‘het veld’ in moeten.

Prof.dr. DW Grijpma, hooggeleerde tweede promotor, beste Dirk. Wanneer jij net zo vluchtig zou zijn als het materiaal waar je mee aankwam dan waren we hier nu niet geweest. Jij hebt me veel geleerd, zowel op het theoretische als praktische vlak van onderzoek doen. Ik kan me herinneren dat ik, als clinicus, en jij, als polymeer chemicus/materiaalkundige, niet altijd op de dezelfde golflengte zaten in het begin. Gelukkig berustte dit niet op onwil, maar kwam dit door de manier van het benaderen van problemen: klinisch vs materiaalkundig. Men zou het kunnen vergelijken met de afzonderlijke materialen van ons composiet: het ‘ruwe’ calcium fosfaat aan de ene en het ‘subtiele’ polymeer aan de andere kant, toch is er letterlijk en figuurlijk een mooi composiet ontstaan getuige de ‘geboorte’ van dit proefschrift. Ik dank je voor je begeleiding en hulp waar nodig gedurende het onderzoek. Het proefschrift is af, maar wij zijn nog niet klaar.....

Prof.dr. A Vissink, beste Arjan. Aangezien jij sneller praat dan de meesten van ons *kunnen denken*, kunnen wij alleen maar gissen naar de snelheid van jouw gedachten. Ik heb je leren kennen als een bevlogen onderzoeksbegeleider en stafflid Kaakchirurgie. Net zoals de snelheid van je gedachten is de manier waarop je artikelen van ons onderzoekers beoordeelt en corrigeert fenomenaal. Ik dank je voor je bijdrage aan dit proefschrift.

Prof.dr. GM Raghoobar, beste Gerry. Bedankt voor het meedenken ten aanzien van de membranenstudies. Jouw kennis en kunde hebben ons enorm geholpen *en* kunnen ons nog van pas komen bij het introduceren van het ontwikkelde barrièremembraan in de kliniek. Ik hoop dat je hieraan wilt meewerken.

Dr. TG van Kooten, weledelzeergeleerde copromotor, beste Theo. Ik heb me altijd zeer welkom gevoeld op het lab bij jullie op de afdeling. Bedankt voor het delen van je wetenschappelijke kennis en kunde en uiteraard je niet onverdienstelijke bijdrage aan dit proefschrift. Verder delen we nog een gemeenschappelijke hobby: beiden mogen we graag ‘in het veld’ zijn en vogels bestuderen, alleen jij haalt bepaalde vogelsoorten figuurlijk dichterbij, ik letterlijk.

Dr. PFM Gielkens, beste Pepijn. “Jouw proefschrift was mijn Wikipedia”, klinkt bekend denk ik, maar ik kan het zelf niet beter zeggen. Bedankt voor je hulp en input, met als kroon een mooie publicatie.

Dr. JJR Huddleston Slater, beste James. Bedankt voor je significante statistische ondersteuning. Het is in het verleden al eens opgemerkt dat je een aanwinst bent voor de afdeling en ik kan dat alleen maar beamen. Jouw inspanningen hebben er mede toe geleid dat hoofdstuk 2 in een topblad is weggezet.

Mw Ing. MBM van Leeuwen, beste Babs. Onze achternamen doen vermoeden dat wij elkaar al sinds jaar en dag kennen, echter dit berust op louter toeval. Je hebt me enorm geholpen door het vele werk wat je hebt verzet voor de verschillende dierstudies. Mede door jouw precieze werken is het een overzichtelijk geheel geworden. Echter zoals in het dierenrijk geldt: twee dominante Leeuwen kun je niet te lang bij elkaar in één kooi stoppen. Bedankt voor je hulp en inzet.

Beste CDL-medewerkers, en in het bijzonder Yvonne, Natascha, Annemiek, Arie, Michel, Ar. Bedankt voor jullie hulp en inzet bij de verschillende dierstudies. Onvergetelijk zijn de momenten waarop we met de schapen door catacomben van het ziekenhuis naar de poli gingen om daar vervolgens de dieren te scannen. Het liep allemaal zo soepel, dat ik er geen Champions League duel voor heb hoeven missen. Volgens mij was het voor jullie net zo leuk als voor mij.

Beste Konrad en overige CDL-medewerkers Nijmegen. Bedankt voor jullie hulp en goede zorgen bij de schaapstudie.

Dr. PJ Gerrits, K van Linschoten, J Dokter, P Veldman, beste Peter, Klaas, Jan en Peter. Bedankt voor de ‘levendige’ momenten binnen het ‘dooie’ onderzoeksgeburen.

Beste heren van de instrumentenwerkplaats, in het bijzonder Jakob, dank voor de attributen (pomp en boor) voor de verschillende dierstudies. Het wordt weer tijd voor taart denk ik.

Beste heren van de instrumentmakerij, in het bijzonder Jan, Wolter, Jeroen en Hans. Bedankt voor het vervaardigen van de verschillende mallen, ‘boren’ en ‘supporters’. Jullie waren altijd bereid om mee te denken, bedankt daarvoor. Hans bedankt voor het maken van een steuntje voor de navigatieapparatuur op de motor.



Dr. R Kuijer en heren JL Ruben en J de Vries, beste Roel, Jan en Joop. Bedankt voor jullie input en goede ideeën. Eeuwig zonde Jan dat je nu in Nijmegen zit (behalve voor Nijmegen).

De leden van de beoordelingscommissie: Geachte Prof.dr. JA Loontjes, Prof.dr. JPR van Merkesteyn en Prof.dr. MP Mourits. Ik wil u allen bedanken voor de tijd die u heeft willen steken in het beoordelen van mijn manuscript.

Dr. JR de Jong en Ing. JWA Sybesma, beste Johan en Jurjen. Bedankt voor jullie hulp bij het maken en interpreteren van de micro-CT scans. Hierdoor heeft het onderzoek van hoofdstuk 2 een extra dimensie gekregen.

Drs. SH Ong, beste Henry. In het begin van de studie Tandheelkunde werden jij en ik aan elkaar gekoppeld: de 'jongste' aan de 'oudste'. Ik heb in de loop der jaren van dichtbij mogen meemaken hoe jij alles met ogenschijnlijk speels gemak doet. Mede door jouw wiskundige hulp is hoofdstuk 3 van dit proefschrift uitgegroeid tot een waardig artikel. Veel succes met je vervolgopleiding(en).

Prof.dr. JD de Bruijn, Dr. H Yuan, dear Joost en Yuan. I owe you and Guilia and Xaoman many thanks. Together with you we have reached some interesting results. I wish you the very best with your (future) products and hope that your company and our department can guide each other in the regeneration of bone.

Dr. FA Holtkamp, beste Frank. Ik dank je voor je grafische input bij dit proefschrift.

Drs WJ van der Meer, beste Joerd. Bedankt voor het meedenken en je monnikenwerk met betrekking tot de analyses van de CBCT-scans van de schaapstudie. Veel succes met het afronden van jouw proefschrift. Leuk dat jij ook graag 'in 't wit loopt'.

Beste Nienke, Lisa, Karin en Harrie en (ex)collega-onderzoekers. Ik wil jullie bedanken voor jullie 'lach', hulp en ondersteuning 'boven'.

Beste stafleden, medewerkers en (ex)-collega's van 'beneden'. Bedankt voor alle goede en gezellige momenten, dat er nog vele mogen volgen. Ik heb veel van jullie mogen leren en leer nog steeds. Met het moment dat jullie dit lezen is er trouwens een einde gekomen aan de 'tussenwachten' die ik overigens met plezier heb vervuld.

Beste röntgendames, Anne, Tiny, Emmy, Liliane, Yvonne en Anja. Zonder jullie was het scannen van de schapen nooit gelukt. Bedankt voor jullie hulp.

Beste familie Wolthuis. Zonder jullie landbouwplastic was het waarschijnlijk een vieze boel geworden tijdens het scannen van de schapen. De schoonmakers zijn jullie eeuwig dankbaar.

Derk Jan Hofstee, beste Deejee. Bedankt voor je digitale input.

Taeke Horneman, beste Taeke. Gezien het feit dat jij altijd alles tot in detail moet uitzoeken, denk ik dat er aan jou een goede wetenschappelijk onderzoeker verloren is gegaan. Bedankt dat je samen met mij dit proefschrift vorm hebt willen geven.

Beste Susan en Sebastiaan. Vijf jaar geleden begonnen we samen aan de opleiding met daarnaast onze promotieonderzoeken. Helaas Sebastiaan liep je vanaf het begin een beetje uit de pas door verplichtingen met betrekking tot je promotieonderzoek, toch heb je een keurige inhaalslag Tandheelkunde gemaakt. Tja Susan, helaas loop jij nu behoorlijk uit de pas. Ik vind het heel jammer dat je de opleiding gestaakt hebt, maar je weet dat ik er begrip voor heb. Ik wens jullie beide veel succes met het afronden van jullie proefschriften.

Beste Michiel, ‘pabbe’. Wij kennen elkaar vanaf het moment dat ik op de afdeling kwam. Onze ontmoeting kon in de Bijbel beschreven zijn: ‘Anne zag Michiel en God zag dat het goed was.’ Ik denk dat humor wel een 4<sup>e</sup> dimensie heeft gekregen, al is dit niet *euclidisch* aan te tonen. Ik vind het mooi dat jij vandaag mijn paranimf wilt zijn.

Dr. Nesse, beste Willem. Alweer vijf jaar geleden kwam ik bij jou en Madelon op de kamer: ik had het niet beter kunnen treffen. We begonnen als collega’s maar gaandeweg is dit uitgegroeid tot een mooie vriendschap. In ‘e War groet Minne Hûn.

Beste Madelon en Rachel. Bedankt voor de rust waarin ik heb kunnen werken op *onze* kamer. Het synchroon lopen van jullie roosters was ideaal. Wanneer jullie dit lezen is het moment aangebroken dat jullie ook wat meer rust van mijn kant kunnen verwachten op *jullie* kamer.

Beste Anne Wietsma. Bedankt voor je hulp tijdens de studie Tandheelkunde en je hulp bij het onderzoek. Je bent een ‘levende gereedschapskist’ voor de afdeling.

Beste familie, vrienden en kennissen. Dat ik er de laatste jaren wel eens niet bij was heeft te maken met de opleiding en dit boekje. Dit zou nu wel eens kunnen gaan veranderen.

Beste Wieger, lieve broer. Wij zijn *jouw* hele leven al vrienden en ik hoop dat wij dit ook blijven *ons* hele leven. Ik kan wel zeggen dat we eigenlijk alleen maar mooie dingen hebben meegemaakt. Wij hebben letterlijk aan een half woord genoeg. Jammer van ‘*Hielke*’. Bedankt dat jij vandaag mijn paranimf wilt zijn.

Leave heit en mem. Tige tank foar de kânsen dy’t jim Wieger en mij joun hawwe. Tank foar jimme ûndersteuning sûnder bitingsten by al myn keuzes. Ik hoopje dat mei it ôfmeitsjen fan dit wurkje der wer wat mear tiid frijkomt foar oare saaken en dat wy mekoar dêrtroch ek wer wat faeker sjen sille.

Bij deze wil ik iedereen die zich gepasseerd voelt persoonlijk bedanken: bedankt!



Publication of this thesis was generously supported by:

Dent-Med Materials (Geistlich Bio-Oss and Bio-Gide): [www.dent-medmaterials.nl/](http://www.dent-medmaterials.nl/)

Xpand Biotechnology: [www.xpand-biotech.com](http://www.xpand-biotech.com)

Nobel Biocare: [www.nobelbiocare.com/nl/home](http://www.nobelbiocare.com/nl/home)

Straumann: [www.straumann.nl/](http://www.straumann.nl/)

Tandartspraktijk Boetje: [www.tandartspraktijkboetje.nl](http://www.tandartspraktijkboetje.nl)

NVMKA: [www.nvmka.nl](http://www.nvmka.nl)

Martin Nederland (Marned BV): [www.klsmartin.com](http://www.klsmartin.com)

Rijksuniversiteit Groningen: [www.rug.nl](http://www.rug.nl)

W.J. Kolff Institute: [www.rug.nl/umcg/onderzoek/interfacultaireinstituten/bmsa/index](http://www.rug.nl/umcg/onderzoek/interfacultaireinstituten/bmsa/index)

BioComp Dental bv: [www.biocomp.eu](http://www.biocomp.eu)

Tandtechnisch Laboratorium Gerrit van Dijk

Nederlandse Vereniging voor Gnathologie en Prothetische

Tandheelkunde (NVGPT): [www.nvgpt.nl](http://www.nvgpt.nl)

ExamVision: [www.examvision.nl](http://www.examvision.nl)

Merck Sharp & Dohme Corp. (MSD): [www.msd.nl](http://www.msd.nl)

PURAC Biochem bv: [www.purac.com](http://www.purac.com)

Raadsheeren bv: [www.raadsheeren.nl](http://www.raadsheeren.nl)

CamBioceramics: [www.cambioceramics.com/nl/3203-Home.html](http://www.cambioceramics.com/nl/3203-Home.html)

Orthocom bv: [info@orthocom.nl](mailto:info@orthocom.nl)

University Medical Center Groningen: [www.umcg.nl](http://www.umcg.nl)

Dam Medical: [www.dammedical.nl](http://www.dammedical.nl)

Maatschap Mondziekten, Kaak- en Aangezichtschirurgie (Dr. W.W.I. Kalk & Dr. A.

Hoekema), Tjongerschans Ziekenhuis Heerenveen: [www.cbi-heerenveen.nl](http://www.cbi-heerenveen.nl)

Dentaid Benelux bv: [www.dentaid.nl](http://www.dentaid.nl)

Anker Verzekeringen bv: [www.ankerdirect.nl](http://www.ankerdirect.nl)

Maatschap Heelkunde Zuid-Friesland: [www.maatschapchirurgiezuidfriesland.nl](http://www.maatschapchirurgiezuidfriesland.nl)

Carl Zeiss: [www.zeiss.nl](http://www.zeiss.nl)

Dentsply Lomberg: [www.lomberg.nl](http://www.lomberg.nl)

Biomet: [www.biomet.nl](http://www.biomet.nl) advert

PLI Rademaker Apotheekhoudend Huisarts: [www.huisartsrademaker.nl](http://www.huisartsrademaker.nl)

Maatschap Mond-, Kaak- en Aangezichtschirurgie Catharina Ziekenhuis

Eindhoven/St. Jans Gasthuis Weert: [www.catharinaziekenhuis.nl](http://www.catharinaziekenhuis.nl)

Raadgevers Kuijkhoven: [www.raadgevers.nl](http://www.raadgevers.nl)

## SonicWeld Rx<sup>®</sup>

*A Revolution in  
Cranio-Maxillofacial  
Osteosynthesis*



*Experience all benefits*

of a unique and revolutionary  
osteosynthesis technique:

- 100% amorphous and biodegradable thanks to pure PDLLA
- Highest stability thanks to cortical as well as cancellous anchorage and immediate locking between PDLLA pin and plate
- Simple to use and easy handling thanks to ultrasonic driven introduction of the resorbable materials



**W** The KLS Martin SonicWeld Rx<sup>®</sup> system is based on the BoneWelding<sup>®</sup> technology (1) protected by the industrial property rights of Neuchâtelix AG, Switzerland, and has been licensed to this company.  
(1) BoneWelding<sup>®</sup> is a registered trade mark.

Martin Nederland/Marmed BV  
Een onderdeel van de KLS Martin Group  
Visserstraat 9a - 1271 VE Huiszen  
Tel. 035-52 34 538 - Fax 035-52 35 348  
info@martin nederland.nl - www.klsmartin.com



**BIOMET®**

**One Surgeon. One Patient.**