

Journal of Mind and Medical Sciences

Volume 6 | Issue 2

Article 25

2019

Chronic vulvar Paget's disease: a therapeutic challenge with a review of the literature

Bouhani Malek

Zemni Ines

Fertani Yasmine

Bouzaiene Hatem

Rahal Khaled

Follow this and additional works at: <https://scholar.valpo.edu/jmms>

 Part of the [Obstetrics and Gynecology Commons](#), [Oncology Commons](#), [Plastic Surgery Commons](#), and the [Surgery Commons](#)

Recommended Citation

Malek, Bouhani; Ines, Zemni; Yasmine, Fertani; Hatem, Bouzaiene; and Khaled, Rahal (2019) "Chronic vulvar Paget's disease: a therapeutic challenge with a review of the literature," *Journal of Mind and Medical Sciences*: Vol. 6 : Iss. 2 , Article 25.

DOI: 10.22543/7674.62.P356360

Available at: <https://scholar.valpo.edu/jmms/vol6/iss2/25>

This Case Presentation is brought to you for free and open access by ValpoScholar. It has been accepted for inclusion in Journal of Mind and Medical Sciences by an authorized administrator of ValpoScholar. For more information, please contact a ValpoScholar staff member at scholar@valpo.edu.



Received for publication: August 12, 2018
Accepted: September 16, 2019

Case report

Chronic vulvar Paget's disease: a therapeutic challenge with a review of the literature

Bouhani Malek¹, Zemni Ines¹, Fertani Yasmine¹, Bouzaiene Hatem¹, Rahal Khaled¹

¹Department of oncologic surgery, Salah Azaiz Institute, Tunis Tunisia

Abstract

Vulvar Paget's disease is an uncommon adenocarcinoma of the female genital tract, occurring more often in postmenopausal Caucasian women and accounting for 1-2% of all vulvar malignancies. A 39-year-old female patient was examined for the erythematous and pruritic vulvar lesion, with biopsy and histological examination revealing vulvar Paget's disease. We did not diagnose any associated neoplasm. The patient underwent four surgical resections for relapsed disease, varying from local excision to extended excision, including radical vulvectomy, with esthetic coverage. The margins were involved. Due to the extended target volumes, radiotherapy was rejected and the patient underwent a local topical therapy with Imiquimod 5%. The patient was free of disease, with three years of regular follow-ups. This case was challenging due to the long recurrence of the disease for approximately 26 years and due to the therapeutics issues that occurred.

Keywords

: vulvar neoplasm, reconstructive surgical procedures, extramammary Paget's disease, Imiquimod

Highlights

- ✓ Vulvar Paget's disease is a therapeutic challenge for physicians due to its chronicity and its high rate of recurrence. The management of local recurrence is associated with mutilating surgery.
- ✓ Currently, new conservative approaches such as local cream use, laser therapy, and many other treatments are being adopted. Imiquimod 5% cream is an alternative for consideration in the case of invaded margins.

To cite this article: Bouhani Malek, Zemni Ines, Fertani Yasmine, Bouzaiene Hatem, Rahal Khaled. Chronic vulvar Paget's disease: a therapeutic challenge with a review of the literature. *J Mind Med Sci.* 2019; 6(2): 356-360. DOI: 10.22543/7674.62.P356360

Introduction

In 1876, Sir James Paget observed chronic eczematous disease on the skin of the nipple and areola that was associated with a breast intraductal carcinoma (1). This entity was defined as mammary Paget's disease. Later, in 1901, William Dubreuilh described vulvar Paget's disease (VPD) (2). VPD is an uncommon adenocarcinoma of the female genital tract (3). It occurs more often in postmenopausal Caucasian women (3) and accounts for 1-2% of all vulvar malignancies (3, 4).

Given its chronicity, the disease is under-diagnosed, thus leading to a real therapeutic challenge for physicians. Surgery remains the treatment of choice; however, many new therapeutic approaches also seem appealing. We cite radiotherapy, topical therapy, laser therapy, photodynamic therapy, and radiotherapy as possibilities (5-10). Despite these varied therapies, VPD still has high relapse rates, ranging from 15 to 72% (5, 7, 8, 11).

Case report

In 1990, a 39-year-old Caucasian woman presented with an erythematous lesion on the left hemi vulva at another medical facility. She underwent local excision of the lesion and the histological report revealed VPD, but the limits and the invasion were not determined. She did not undergo adjuvant therapy, and her case was subsequently lost over time. Twenty-two years later (in 2012), she presented with a new though similar lesion in the same localization. The patient underwent mammography, coloscopy, gastric endoscopy, and cystoscopy, and all results were negative. She then underwent left hemivulvectomy. The final histological examination concluded VPD again, and the limits were free with a 2-mm clearance.

Three years later (in 2015), after the first relapse, she presented with an erythematous lesion on the right hemivulva and the perianal region. The inguinal areas were free of lymph nodes. The punch biopsy with histological examination confirmed the recurrence of VPD. She had a totalization of the vulvectomy with excision of the perianal lesion and an advanced flap of the inner thigh. We performed a left iliac colostomy to improve the peri-anal scarring. The limits were not free, but the patient was lost again. One year later (in 2016), she was referred to our institute for an evolutive disease. The physical examination revealed multiple erythematous lesions located in mons veneris, in the flap and in the perianal region (Figures 1 and 2).

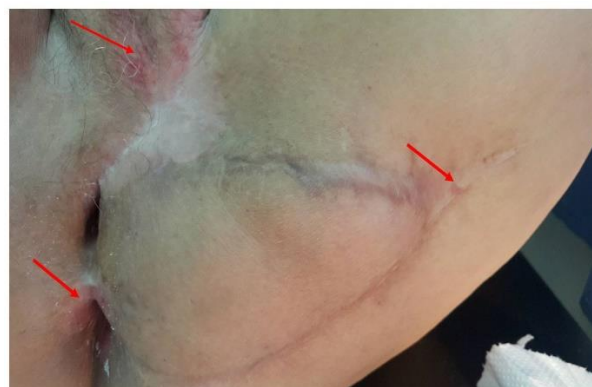


Figure 1. General overview showing multiple erythematous lesions located in mons veneris, in the flap and in the peri-anal region (red circles).

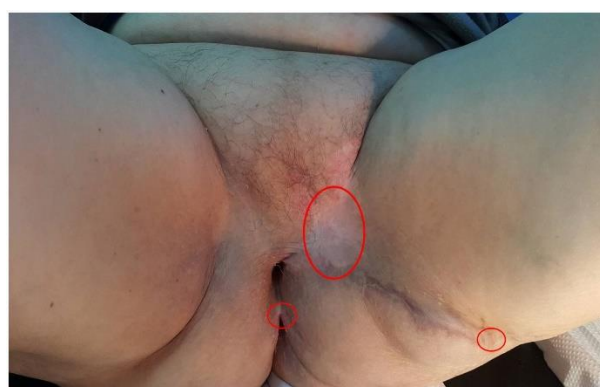

Figure 2. Closeup overview of multiple erythematous lesions located in mons veneris, in the flap and in the peri-anal region (red arrows).

We performed punch biopsies for each suspicious lesion, and the histological examination confirmed the VPD recurrence. She underwent a large excision and coverage by a V-Y flap of the inner thigh (Figures 3 and 4).

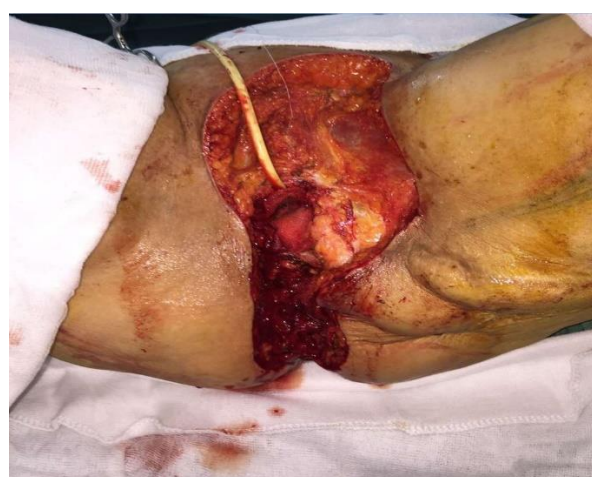

Figure 3. Large excision of the perineal areas, mons veneris and the flap.

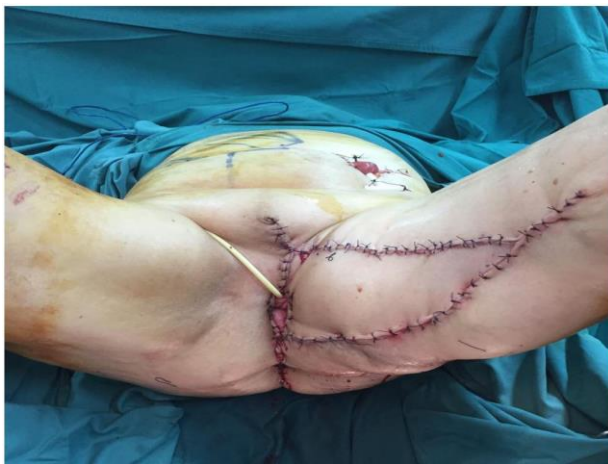

Figure 4. Coverage by a V-Y flap of the inner thigh

Frozen section examination pointed to free limits, but final histology exams showed involved margins. Due to the multiple recurrences of the disease and the involved margins, the patient was proposed for external beam therapy. But radiotherapy was rejected due to the extent of the target volumes. The multidisciplinary committee indicated a topical therapy with Imiquimod 5%. The patient underwent local therapy with imiquimod 5% twice a week for 6 months. At the time of this publication, the patient is 68 years old and she had no recurrence in the first 36 months after treatment.

Discussions

Vulvar Paget's disease remains underdiagnosed due to its rarity and its clinical presentation which mimics a benign lesion. Wilkinson and Brown proposed a classification that divided it into two entities: primary and secondary disease (12). Primary Paget's disease is an intraepithelial adenocarcinoma that occurs in the appendages of the epidermis or the underlying skin. Secondary Paget's disease is associated with underlying noncutaneous adenocarcinoma, most frequently anorectal adenocarcinoma, and urothelial carcinoma of the bladder or urethra, carcinoma of the cervix, ovaries, or endometrium (13). For this reason in our case, we did a full workup so as to avoid underdiagnosing an underlying adenocarcinoma.

The VPD mechanism of spreading is still under debate. Mehta et al. supposed that a Pagetoid tumor spreads throughout the basal layers and the alteration of the tumor microenvironment is responsible for the progression of the disease (14).

Throughout time, surgery has been the main treatment of VPD, but VPD extends beyond the clinical limits of the lesion. In fact, the spread of Paget's cells may be difficult

to recognize in a frozen section examination. This makes margin control hard to achieve. The preferred surgical method uses Mohs micrographic surgery to avoid false-negative free margins in the results of the frozen section, as in our case (15). Surgery varies from local excision to radical vulvectomy, with a high risk of recurrence regardless of the margin status which then leads to increasingly mutilating surgery, and thus plastic reconstructive surgery is often needed to cover the tissue loss, as in our case.

Because of the mutilating surgery, a variety of other therapeutic means have been attempted (8-10). Radiotherapy alone or associated with chemotherapy remains a treatment option for the relapsing disease (16, 17). But the high morbidity of those treatments has stimulated the search for less invasive treatment options such as chemotherapy with intralesional interferon alfa-2b, bleomycin, laser ablation, photodynamic therapy, topical fluorouracil (5-Fu), and imiquimod 5% cream.

The conservative treatment approach is promising because it conserves the vulvar anatomy and the sexual functions. Laser therapy was successfully used, but the major disadvantages are the high rate of recurrence and the significant pain level (18, 19).

Imiquimod 5%—an immune response modifier—is a known treatment for vulvar condyloma, actinic keratosis, or even basal cell carcinoma. The treatment also has a direct antitumor activity, being first described as a local treatment for VPD in 2003 by Wang et al. (20). A systematic review conducted by Dogan showed the efficacy of imiquimod as an alternative for VPD, with a complete remission rate of 71% (21). However, treatment protocols for imiquimod are not well codified. Applications are generally about 3 per week, although with widely variable durations. In our case, radiotherapy could not be performed due to the extent of the target volumes. Imiquimod 5% was applied twice a week for 28 weeks, with excellent results, confirming both the efficacy and safety of Imiquimod 5% cream in the treatment of VPD.

Another promising treatment option of VPD is topical photodynamic therapy (PDT), with good outcomes reported by Rioli (22), although other reports have shown a high rate of recurrence (23). Target therapy still needs to be approved in the treatment of VPD when HER-2/neu is overexpressed.

Conclusions

The most challenging feature in the management of VPD is its recurrence because the patient has undergone increasingly mutilating surgery that leads, in some cases,

to an impossible challenge for the surgeon. Imiquimod 5% cream appears to be a viable alternative in such situations.

Conflict of interest disclosure

There are no known conflicts of interest in the publication of this article. The manuscript was read and approved by all authors.

Compliance with ethical standards

Any aspect of the work covered in this manuscript has been conducted according to the ethical norms. Our institution does not require ethical approval for reporting individual cases or case series. Verbal informed consent was obtained from the patient(s) for their anonymized information to be published in this article.

References

1. Paget J. On disease of mammary areola preceding cancer of mammary gland. *CA: A Cancer Journal for Clinicians*. 1971; 21(5): 303–304. DOI: 10.3322/canjclin.21.5.303
2. Dubreuilh W. Paget's disease of the Vulva. *Br J Dermatol*. 1901; 13(11): 407–413. DOI: 10.1111/j.1365-2133.1901.tb16346.x
3. St. Claire K, Hoover A, Ashack K, Khachemoune A. Extramammary Paget disease. *Dermatol Online J*. 2019; 25(4): pii: 13030/qt7qg8g292
4. Borghi C, Bogani G, Ditto A, Martinelli F, Signorelli M, Chiappa V. et al. Invasive Paget Disease of the Vulva. *Int J Gynecol Cancer*. 2018; 28(1): 176-182. DOI: 10.1097/IGC.0000000000001131
5. Tolia M, Tsoukalas N, Sofoudis C, Giaginis C, Spyropoulou D, Kardamakis D, et al. Primary extramammary invasive Paget's vulvar disease: what is the standard, what are the challenges and what is the future for radiotherapy? *BMC Cancer*. 2016; 16: 563. DOI: 10.1186/s12885-016-2622-5
6. Matthews N, Wong V, Brooks J, Kroumpouzou G. Genital diseases in the mature woman. *Clin Dermatol*. 2018; 36(2): 208-221. DOI: 10.1016/j.clindermatol.2017.10.012
7. Nitecki R, Davis M, Watkins JC, Wu YE, Vitonis AF, Muto MG, et al. Extramammary Paget disease of the vulva: A Case Series Examining Treatment, Recurrence, and Malignant Transformation. *Int J Gynecol Cancer*. 2018; 28(3): 632-638. DOI: 10.1097/IGC.0000000000001189
8. Chokoeva AA, Tchernev G, Castelli E, Orlando E, Verma SB, Grebe M, et al. Vulvar cancer: a review for dermatologists. *Wien Med Wochenschr*. 2015; 165(7-8): 164-177. DOI: 10.1007/s10354-015-0354-9
9. Lloyd J, Flanagan AM. Mammary and extramammary Paget's disease. *J Clin Pathol*. 2000; 53(10): 742-749. DOI: 10.1136/jcp.53.10.742
10. Edey KA, Allan E, Murdoch JB, Cooper S, Bryant A. Interventions for the treatment of Paget's disease of the vulva. *Cochrane Database Syst Rev*. 2013; (10): CD009245. DOI: 10.1002/14651858.CD009245.pub2
11. van der Linden M, Meeuwis KAP, Bulten J, Bosse T, van Poelgeest MIE, de Hullu JA. Paget disease of the vulva. *Crit Rev Oncol Hematol*. 2016; 101: 60-74. DOI: 10.1016/j.critrevonc.2016.03.008
12. Wilkinson EJ, Brown HM. Vulvar Paget disease of urothelial origin: a report of three cases and a proposed classification of vulvar Paget disease. *Hum Pathol*. 2002; 33(5): 549-554. DOI: 10.1053/hupa.2002.124788
13. Isrow D, Oregel KZ, Cortes J, Gomez H, Milikowski C, Feun L, et al. Advanced extramammary paget's disease of the groin, penis, and scrotum. *Clin Med Insights Oncol*. 2014; 8: 87–90. DOI: 10.4137/CMO.S13107
14. Mehta A, Agarwal P. Bladder Carcinoma Presenting as Paget's Disease of Vulva: An Uncommon Entity. *Indian J Dermatol*. 2018; 63(6): 518–520. DOI: 10.4103/ijd.IJD_126_18
15. Bouceiro-Mendes R, Mendonça-Sanches M, Soares-de-Almeida L, Correia-Fonseca I. A Case of Chronic and Relapsing Paget Disease of the Vulva. *Rev Bras Ginecol Obstet*. 2019; 41(6): 412-416. DOI: 10.1055/s-0039-1687861
16. Tagliaferri L, Casà C, Macchia G, Pesce A, Garganese G, Gui B, et al. The Role of Radiotherapy in Extramammary Paget Disease: A Systematic Review. *Int J Gynecol Cancer*. 2018; 28(4): 829-39. DOI: 10.1097/IGC.0000000000001237
17. Inayama Y, Abiko K, Miyamoto T, Horie A, Yamaguchi K, Baba T, et al. Invasive Paget's disease of the vulva treated with a combination of surgery and concurrent chemoradiotherapy: A case report. *Mol Clin Oncol*. 2018; 9(5): 489. DOI:10.3892/mco.2018.1719
18. Shaco-Levy R, Bean SM, Vollmer RT, Papalas JA, Bentley RC, Selim MA, et al. Paget disease of the vulva: a histologic study of 56 cases correlating pathologic features and disease course. *Int J Gynecol Pathol*. 2010; 29(1): 69-78. DOI: 10.1097/PGP.0b013e3181b1cc5e
19. Ewing TL. Paget's disease of the vulva treated by combined surgery and laser. *Gynecol Oncol*. 1991; 43(2): 137-140. DOI: 10.1016/0090-8258(91)90059-e

20. Wang LC, Blanchard A, Judge DE, Lorincz AA, Medenica MM, Busbey S. Successful treatment of recurrent extramammary Paget's disease of the vulva with topical imiquimod 5% cream. *J Am Acad Dermatol.* 2003; 49(4): 769–772. DOI: 10.1067/s0190-9622(03)02107-8
21. Dogan A, Hilal Z, Krentel H, Cetin C, Hefler LA, Grimm C, et al. Paget's Disease of the Vulva Treated with Imiquimod: Case Report and Systematic Review of the Literature. *Gynecol Obstet Invest.* 2017; 82(1): 1-7. DOI: 10.1159/000449158
22. Rioli DI, Samimi M, Beneton N, Hainaut E, Martin L, Misery L, et al. Efficacy and tolerance of photodynamic therapy for vulvar Paget's disease: a multicentric retrospective study. *Eur J Dermatol.* 2018; 28(3): 351-355. DOI: 10.1684/ejd.2018.3289
23. Clément E, Sparsa A, Doffoel-Hantz V, Durox H, Prey S, Bonnetblanc JM, et al. Photodynamic therapy for the treatment of extramammary Paget's disease. *Ann Dermatol Venereol.* 2012; 139(2): 103-108. DOI: 10.1016/j.annder.2011.10.414