



## University of Groningen

### Rationale and design of the AdRem study

Stolk, Ronald P.; Vingerling, Johannes R.; Cruickshank, J. Kennedy; Hughes, Alun D.; Stanton, Alice; Lu Juming, [No Value]; Patel, Anushka; Thom, Simon A. McG.; Grobbee, Diederick E.; null, null

*Published in:*  
Contemporary Clinical Trials

*DOI:*  
[10.1016/j.cct.2006.08.011](https://doi.org/10.1016/j.cct.2006.08.011)

**IMPORTANT NOTE:** You are advised to consult the publisher's version (publisher's PDF) if you wish to cite from it. Please check the document version below.

*Document Version*  
Publisher's PDF, also known as Version of record

*Publication date:*  
2007

[Link to publication in University of Groningen/UMCG research database](#)

*Citation for published version (APA):*

Stolk, R. P., Vingerling, J. R., Cruickshank, J. K., Hughes, A. D., Stanton, A., Lu Juming, N. V., ... Lu, J. M. (2007). Rationale and design of the AdRem study: Evaluating the effects of blood pressure lowering and intensive glucose control on vascular retinal disorders in patients with type 2 diabetes mellitus. *Contemporary Clinical Trials*, 28(1), 6-17. <https://doi.org/10.1016/j.cct.2006.08.011>

#### Copyright

Other than for strictly personal use, it is not permitted to download or to forward/distribute the text or part of it without the consent of the author(s) and/or copyright holder(s), unless the work is under an open content license (like Creative Commons).

#### Take-down policy

If you believe that this document breaches copyright please contact us providing details, and we will remove access to the work immediately and investigate your claim.

*Downloaded from the University of Groningen/UMCG research database (Pure): <http://www.rug.nl/research/portal>. For technical reasons the number of authors shown on this cover page is limited to 10 maximum.*

# Rationale and design of the AdRem study: Evaluating the effects of blood pressure lowering and intensive glucose control on vascular retinal disorders in patients with type 2 diabetes mellitus

Ronald P. Stolk<sup>a,b,\*</sup>, Johannes R. Vingerling<sup>c,d</sup>, J. Kennedy Cruickshank<sup>e</sup>,  
Alun D. Hughes<sup>f</sup>, Alice Stanton<sup>g</sup>, Lu Juming<sup>h</sup>, Anushka Patel<sup>i</sup>,  
Simon A. McG. Thom<sup>f</sup>, Diederick E. Grobbee<sup>a</sup>  
on behalf of the AdRem project team and ADVANCE management committee<sup>1</sup>

<sup>a</sup> *Julius Center for Health Sciences and Primary Care, University Medical Center Utrecht, Utrecht, The Netherlands*

<sup>b</sup> *Department of Epidemiology, University Medical Center Groningen, The Netherlands*

<sup>c</sup> *Department of Ophthalmology, Erasmus Medical Center, Rotterdam, The Netherlands*

<sup>d</sup> *Department of Epidemiology and Biostatistics, Erasmus Medical Center, Rotterdam, The Netherlands*

<sup>e</sup> *Clinical Epidemiology, University of Manchester Medical School, Manchester, United Kingdom*

<sup>f</sup> *International Centre for Circulatory Health, National Heart and Lung Institute, Imperial College London, United Kingdom*

<sup>g</sup> *Beaumont Hospital, Dublin, Ireland*

<sup>h</sup> *Chinese PLA General Hospital, Beijing, China*

<sup>i</sup> *The George Institute for International Health, University of Sydney, Sydney, Australia*

Received 14 January 2005; accepted 30 August 2006

## Abstract

The ADVANCE Retinal Measurements (AdRem) Study is a large intervention study evaluating the effects of target driven intensive glucose control and placebo controlled blood pressure lowering on retinal vascular changes. AdRem is a sub-study of the ADVANCE Study (Action in Diabetes and Vascular disease), a 2 × 2 factorial randomized controlled trial with an ACE inhibitor–diuretic combination (perindopril–indapamide) and a gliclazide MR-based regimen in patients with type 2 diabetes mellitus.

The AdRem study is based on seven-field stereoscopic retinal photographs of both eyes. These are taken within 3 months after randomization in ADVANCE (baseline), at the biennial and at the final visit. The primary outcome is progression of two or more steps in ETDRS classification. Secondary outcomes include progression of retinal vascular lesions and distortion of retinal vascular geometry. Retinal photographs are made on film and digitized at a central laboratory. The AdRem study uses fully digitized quality control and grading.

Between August 2002 and January 2004 1978 patients were included in the AdRem study, from 39 centers in 14 countries. Approximately 85% comply with the strict AdRem quality requirements. Publication of the results is expected in early 2008.

*Abbreviations:* ACE, angiotensin-converting-enzyme; ADVANCE, Action in Diabetes and Vascular Disease: Preterax and Diamicon MR Controlled Evaluation; ARIC, Atherosclerosis Risk in Communities; ETDRS, Early Treatment Diabetic Retinopathy Study; UKPDS, United Kingdom Prospective Diabetes Study.

\* Corresponding author. Department of Epidemiology, University Medical Center Groningen, PO Box 30.001, 9700 RB Groningen, The Netherlands. Tel.: +31 50 361 1879.

E-mail address: [R.P.Stolk@epi.umcg.nl](mailto:R.P.Stolk@epi.umcg.nl) (R.P. Stolk).

<sup>1</sup> Members are listed in Appendix A.

The AdRem study is designed to provide reliable evidence on the effects of intensive glucose control and blood pressure lowering on both diabetic retinopathy and abnormalities of retinal vasculature in patients with type 2 diabetes mellitus.

© 2006 Elsevier Inc. All rights reserved.

*Keywords:* Diabetes; Retinopathy; Hypertension; Retinal photography; Retinal vascular geometry

---

## 1. Background and aims

Diabetic retinopathy is a progressive disorder classified according to the presence of various clinical abnormalities. It is the commonest cause of blindness in people aged 30–69 years. When not discovered before vision loss occurs, the disease usually progresses severely, and at that point, laser treatment is rarely effective in restoring vision [1]. Damage to the retina arises from a combination of microvascular leakage and occlusion. Subtle changes of background retinopathy (e.g. small blot hemorrhages and microaneurysms) are easily overlooked by direct fundoscopy and routine ophthalmological examination [2–5].

From observational studies and clinical practice it is known that both increased blood glucose or HbA1c levels and increased blood pressure are associated with an increased incidence and progression of retinopathy [6,7]. In addition to the association between blood pressure and microaneurysms (background retinopathy), increased blood pressure has a direct effect on the retinal arteries, [8] but the more marked changes of the Keith–Wagener–Barker classification [9] are now uncommon since the widespread use of blood pressure lowering treatment. However quantitative assessment of arteriolar and venular changes from retinal photographs can be made, and these have been shown to be associated with hypertension and atherosclerosis in population-based studies [10–12]. Recent data from analyses of retinal vascular geometry also indicate that abnormalities of retinal vessel branching patterns are associated with cardiovascular risk factors such as hypertension, ageing, low birth weight, diabetes and peripheral vascular disease [13,14].

The risk of retinopathy steadily increases with increasing levels of plasma glucose (or HbA1c) and duration of diabetes. Up to 21% of patients with type 2 diabetes have some degree of retinopathy when diabetes is diagnosed, and most develop retinopathy over time [15]. The UKPDS has clearly shown that glucose lowering results in reduced incidence and progression of retinopathy [16]. The number of new retinopathy cases among the UKPDS participants, as well as the number of prevented cases of retinopathy was more than all other endpoints combined [17]. However, in the intervention group of the UKPDS the mean HbA1c after 8 years increased to 8%, which is now considered inadequate glycemic control. Current diabetes treatment guidelines include target values for HbA1c as low as 6.5% in Europe and 7.0% in the United States [18,19]. However, these targets are not based on direct evidence but on extrapolation of results from observational and intervention studies. It is not known whether a larger reduction of retinopathy than obtained in the UKPDS can be achieved by stricter glycemic control without adverse hypoglycemic side effects.

The potential beneficial effects of blood pressure lowering on retinopathy have been demonstrated in the blood pressure lowering part of UKPDS, and control of blood pressure levels is now well established as an important means of preventing retinopathy in patients with diabetes [20]. The impact of blood pressure reduction is probably greater than that of glucose control, but it is not known if blood pressure lowering has beneficial effects on the incidence and progression of retinal vascular lesions in subjects with type 2 diabetes mellitus without hypertension.

The ADVANCE Study (Action in Diabetes and Vascular Disease) is a major ongoing randomised trial of blood pressure lowering with a fixed low-dose perindopril-indapamide combination and intensive glucose control with a modified-release gliclazide-based regimen among high risk individuals with type 2 diabetes [21]. The main objectives of the AdRem (ADVANCE Retinal Measurements) Study, described in this report, are to determine the effects of blood pressure lowering and intensive glucose lowering on retinal vascular disorders as assessed by retinal photography in participants of ADVANCE. The AdRem Study will provide solid evidence on the balance of risks (notably hypoglycemia) and benefits (reduction of retinal lesions) with blood pressure lowering irrespective of baseline blood pressure and more intensive glucose control than in previous randomised trials.

## 2. Specific objectives

The primary objectives of the AdRem study are twofold. Firstly, to investigate if blood pressure lowering by an ACE inhibitor/diuretic combination decreases the incidence and progression of diabetic retinal lesions compared to placebo.

Secondly, to investigate if intensive glucose control decreases the incidence and progression of diabetic retinal lesions compared to standard guidelines-based glucose control. The endpoint for both objectives is progression of two or more steps on the modified ETDRS classification [16].

In addition to the primary objectives, three secondary objectives have been defined. These are, first, to quantify the degree of misclassification of background and proliferative retinopathy and macular oedema diagnosed by funduscopy, as used in the main ADVANCE study; second, to investigate if blood pressure lowering with an ACE inhibitor/diuretic combination prevents the incidence and progression of retinal vascular lesions and distortion of retinal vascular geometry compared to placebo; and third, to investigate if intensive glucose control prevents the incidence and progression of retinal vascular lesions and distortion of retinal vascular geometry compared to standard glucose control.

### 3. Methods

#### 3.1. Intervention

ADVANCE is a  $2 \times 2$  factorial, randomised controlled trial in 11140 patients with type 2 diabetes mellitus receiving standard care. The protocol has been published previously [21]. In short, inclusion is not based on glycemic control or blood pressure, but on an elevated risk of vascular disease. This is defined by at least one of a number of risk factors, including longstanding diabetes ( $\geq 10$  years), older age ( $\geq 65$  years), history of cardiovascular disease or diabetes complications, and elevated levels of cardiovascular risk factors. The two primary endpoints are composite measures of macro- and microvascular disorders, respectively [21,22]. Among all ADVANCE participants, retinopathy is routinely assessed by direct funduscopy and clinical data, such as laser coagulation treatment, are recorded.

Following a 6-week run-in phase on active blood pressure lowering treatment and usual glucose lowering treatment, eligible participants were randomly assigned in a  $2 \times 2$  factorial design to one of four treatment combinations. The two randomized comparisons are a double-blind comparison of blood pressure lowering versus placebo and an open comparison of intensive glucose lowering therapy targeting an HbA1c of 6.5% or less versus standard guidelines-based glucose lowering. The blood pressure treatment is a fixed low-dose combination of perindopril (2–4 mg) and indapamide (0.625–1.25 mg). For patients in whom an ACE-inhibitor is indicated, background perindopril (open label, 2 or 4 mg) is provided. There is no restriction in prescribing other blood pressure lowering medication if deemed necessary by the treating physician. Intensive glucose control starts with a long-acting sulphonylurea (gliclazide MR 30–120 mg), to which other oral glucose lowering agents and insulin may be added to reach the HbA1c of 6.5% or less, at the discretion of the treating physician. It is important to realize that ADVANCE is a pragmatic study that recognizes variations in standard care.

Randomization is stratified by study center, history of macro- or microvascular disease and background use of perindopril at baseline. The scheduled average follow-up is 5.5 years and final results of the main ADVANCE study are anticipated to be available in 2007 [21,22].

#### 3.2. Participants

AdRem is conducted in patients that have been randomized in the ADVANCE trial in a selected number of study centers with access to retinal cameras. In addition to the inclusion and exclusion criteria of ADVANCE, patients who had a previous ophthalmologic intervention procedure in one or both eyes that might interfere with retinal circulation (such as laser coagulation treatment and vitrectomy) were excluded from AdRem. Patients were also excluded if it was unlikely that good quality stereo photographs could be taken, for example due to the presence of severe cataract or pupils that did not dilate at least 4 mm. At each AdRem study center all ADVANCE patients were eligible for the AdRem sub-study.

#### 3.3. Photography

Photographs are taken with 35 mm high quality color films (Kodak EPR64 135–36). These are provided by the AdRem Substudy Coordination Center, where a large quantity of a single batch is stored at  $-20$  °C until required. Retinal cameras with an angle between  $30^\circ$  and  $35^\circ$  and  $2.5\times$  magnification, without special stereo equipment, are used.

Stereoscopic photographs are made of both left and right eyes, according to the seven-standard fields ETDRS protocol [23]. The seven fields include one centered on the optic disc, one centered on the macula, one temporal to the macula, two superior and two inferior fields (Fig. 1).

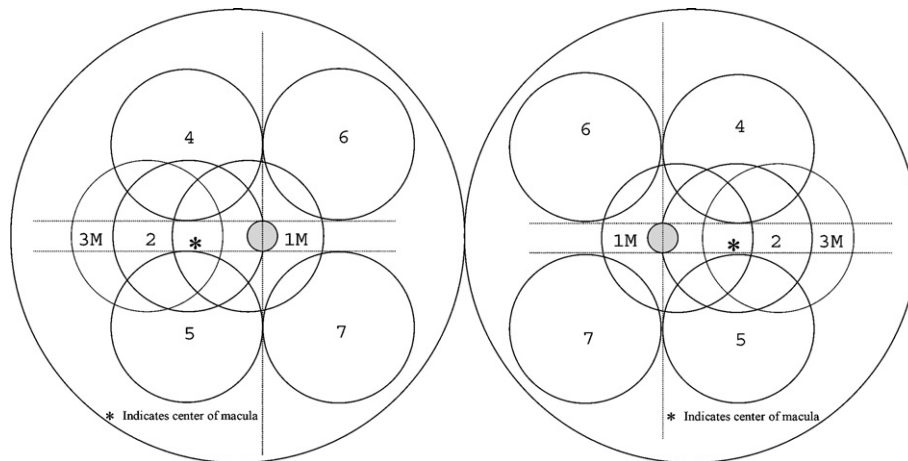


Fig. 1. ETDRS 7-field stereoscopic photography.

The first (baseline) retinal photographs were preferably made within 3 months following the ADVANCE randomization visit. For these patients follow-up photographs are to be made at the ADVANCE two-year (biennial) visit. In patients who had their first photographs taken more than 3 months following the ADVANCE randomization visit no biennial photographs are made during follow-up, but follow-up photographs will be made at the final ADVANCE visit in all those with initial photographs.

If a patient has to undergo an ophthalmologic intervention procedure (e.g. laser coagulation), where possible follow-up photography is performed prior to this intervention. Follow-up photography of the opposite eye is performed if a patient has had an intervention procedure in one eye only.

#### 3.4. Film processing and digitizing

All films are processed at an approved central laboratory, using Fuji process E-6 chemicals. Immediately after processing the films are digitized on a Fuji scanner SP 2000 (Japan) with a resolution of  $20.3 \times 27.3$  cm 300 dpi ( $3259 \times 2432$  pixels). No colour or size adjustments are made during the scanning process. Films are stored after digitizing. All procedures of the AdRem study (notably quality control and grading) are performed on digitised images.

### 4. Study organization

The AdRem study is being performed in 39 ADVANCE centers. Retinal photographs are made in 30 centers, 9 refer their patients to another ADVANCE study center in the same city. These centers are located in 14 countries: Australia, Canada, China, Estonia, France, Germany, India, Ireland, Malaysia, Netherlands, Philippines, Poland, Slovakia, and United Kingdom. The AdRem Coordinating center, located in the Netherlands, provides the films to the LCC, and takes care of central film processing, digitizing, and grading of the images.

Each participating center stores the exposed film in a refrigerator without processing before sending it in batches of 10 films to the AdRem Coordination Center. After arrival of the films, they are processed and digitized, and within 3 weeks the quality of the images is assessed. This allows the centers to retake the photographs in those patients who initially had inadequate images. The procedure is summarized in Fig. 2.

#### 4.1. Feedback to clinical centers

Apart from the quality aspects, the images are evaluated for lesions that may require immediate intervention within 3 weeks after arrival at the AdRem Coordination Center. If present, such lesions are reported to the center by the AdRem ophthalmologist.

Participating centers receive digital copies of the photographs of their patients for clinical use. These include the (non-stereoscopic) fields 1 and 2 from both the right and left eye.

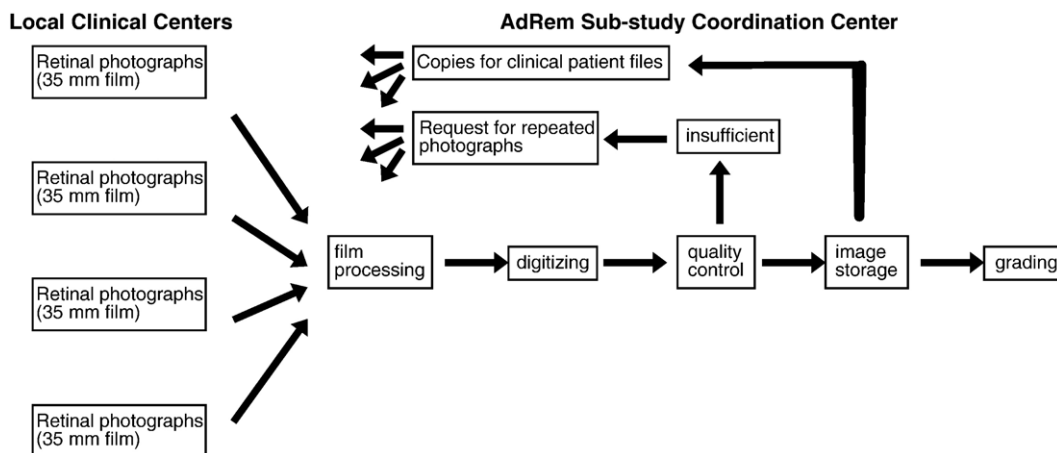


Fig. 2. AdRem flowchart.

#### 4.2. Time schedule

Baseline photographs were taken between August 2002 and January 2004. The biennial follow-up photographs will be obtained in 2004 and 2005. Final photographs are currently scheduled for 2007; publication of the results is expected in early 2008.

### 5. Grading of the photographs

Three different protocols are used to grade the photographs in the AdRem study: diabetic lesions (ETDRS protocol), [16] vascular lesions (ARIC protocol), [10] and vascular geometry (Imperial College London protocol) [14].

#### 5.1. Diabetic lesions

The classification system for diabetic retinal lesions currently used in most clinical trials is that derived from the Early Treatment of Diabetic Retinopathy Study (ETDRS) [23]. The ETDRS classification was slightly modified in the UKPDS study, and this modified classification is used in the AdRem study (Table 1) [16]. Each field is graded separately, with a few additional items graded in the central fields only. Detected lesions are graded in comparison with the ETDRS final scale standard photographs. The worst eye (having the highest score on the ETDRS scale) is used in the analyses. Follow-up photographs are graded independent of the previous photographs taken of the same participant. The primary endpoint for diabetic lesions is a two-step progression on this modified ETDRS scale.

#### 5.2. Vascular lesions

The third examination of the Atherosclerosis Risk in Communities Study (ARIC) included a retinal photograph of one eye to assess vascular lesions. At the University of Wisconsin–Madison Fundus Photograph Reading Center a protocol was developed to quantitatively assess retinal arterial and venous characteristics [10]. This grading system is based on the central retinal fields only. It includes the semi-quantitatively assessment of a number of vascular changes (Table 2) and a standardized measurement of arterial and venous diameters at a distance of two disc diameters from the optic disc [10].

In AdRem the vascular diameters are measured according to the ARIC protocol using the Vascul-O-Matic 3.1 Vessel Measurement Software (University of Wisconsin, Madison, WI). Average retinal and venular diameters (central retinal arteriolar and venular equivalent, CRAE and CRVE respectively) are calculated using the improved Parr–Hubbard formula [24,25]. The arteriovenous ratio (AVR) will be calculated as the ratio of CRAE over CRVE. Because it has been shown that these measurements in both eyes are highly correlated, they are performed in the left eye only [26]. Vessel width is measured across a total of five parallel cross-sections, two either side of that selected by the user, with

Table 1  
Modified ETDRS classification [16]

Severity	Definition
Diabetic retinopathy absent	All diabetic retinopathy features absent
Microaneurysms only	Microaneurysm(s) only, other lesions absent
Mild non-proliferative diabetic retinopathy	Microaneurysm(s) plus retinal hemorrhage(s) and/or hard exudates and/or cotton wool spots
Moderate non-proliferative diabetic retinopathy	Lesions as above + either extensive or severe HMA or IRMA present
Moderate severe non-proliferative diabetic retinopathy	Lesions as above + either extensive or severe HMA with IRMA, or venous beading
Severe non-proliferative diabetic retinopathy	Extensive and severe HMA, IRMA, and/or venous beading
Proliferative diabetic retinopathy	NVD and/or NVE without or with complications

HMA = hemorrhages and microaneurysms, IRMA = intraretinal microvascular abnormalities, NVD = new vessels on the disc, NVE = new vessels elsewhere.

each cross-section being two pixels away from its neighbour. The median of the five measured diameters is taken as the diameter for that vessel. Moreover, vascular characteristics (Table 2) are assessed in all seven fields. The primary endpoint for vascular lesions is the incidence of one or more vascular changes.

### 5.3. Vascular geometry

The retinal vascular geometry measurements are made by operator-directed image analysis using custom-written software [27]. The parameters of interest are measured on arterioles and venules and relate to the branching pattern of the vascular tree.

These include:

- branching angles defined as the internal angle between the daughter vessels arising from a parent stem
- junction exponent ( $x$ ) defined by the relationship  $d_0^x = d_1^x + d_2^x$ , where  $d_0$  and  $d_1, d_2$  are the diameters of the parent and daughter vessels respectively
- length–diameter ratio defined as the inter-branch vessel length divided by the respective diameter
- tortuosity index defined as the inter-branch path length divided by the straight-line distance between the respective branch points.

These are dimensionless parameters which are largely unaffected by variation in refractive properties of the eye. Vessel lengths are measured using a segmentation tracking algorithm [28]. The most complex aspect of measurement involves a ‘sliding linear regression filter’ used to determine vessel edges from the image intensity profile. The process is reproducible and it is robust against noise, the presence of a central light reflex and wide variation in image quality [27].

## 6. Quality control

The AdRem study is conducted in a large number of study centers located in 14 countries in all continents. Moreover, because the photographs are made on film, the result becomes apparent only after processing. These two issues require a strict quality control procedure that covers both the taking of the photographs and the grading of the images.

Table 2  
Vascular changes included in the ARIC protocol [10]

Focal narrowing
Arteriovenous crossing changes (nicking)
Arteriolar sheathing
Microaneurysms
Retinal hemorrhages
Cotton–wool spots (soft exudates)
Hard exudates

### 6.1. Quality assurance of photographs

All photographers participating in AdRem have to be certified for taking seven-field stereoscopic retinal photographs. Certification in another study using stereoscopic retinal photographs within the last 5 years is accepted. Photographers who have not been certified must provide retinal photographs according to the AdRem procedures from two patients. If the quality of all four eyes on the certification films is sufficient to allow grading (Table 3), the photographer is certified.

Within 3 weeks after arrival of the films at the AdRem Substudy Coordination Center the quality of the photographs is assessed. The minimal criteria are based on those characteristics that are important for the grading of diabetic retinal lesions (Table 3). If the quality of both eyes is insufficient, the study center is asked to take the photographs again. If a certified photographer consistently fails to meet the minimal quality criteria or consistently provides borderline quality photographs, certification is suspended.

### 6.2. Quality control of grading procedure

The grading procedure (both diabetic retinal lesions and vascular geometry) includes an assessment by two independent readers, who are blind to the intervention. If the score of a participant differs between readers, the images are discussed at a consensus meeting with both readers and an experienced ophthalmologist. In addition, in a random sample of 10% of the patients the retinal photographs will also be graded at the UKPDS Retinopathy Grading Center, London [16].

## 7. Statistical analyses

### 7.1. Sample size

The UKPDS is the only intervention study of sufficient size to estimate the effects of glucose and blood pressure lowering on retinopathy in mainly European patients. During the first 6 years of UKPDS, 23.0% of those in the intensive glucose control group suffered progression of retinopathy, compared to 27.8% in the conventional treatment arm [17].

Because UKPDS was limited to newly diagnosed patients, and because the difference in HbA1c after 5 years was only 0.8%, we expect a greater reduction of retinopathy in the ADVANCE trial. We assume that the event rate in the conventional treatment group will be the same as in the conventional treatment group of the UKPDS (27.8% after 6 years). Because participants in ADVANCE have a longer duration of diabetes, this is likely to be an underestimation. With two groups of 900 patients and 85% power, it should be possible to find a difference of 6.2% in the event rate between the two groups ( $\alpha=0.05$ ). So, we expect that less than 21.6% of the participants in the intensive glucose control group will develop retinopathy, which is about 5% lower compared with the 23.0% reported in the intensive arm of UKPDS [17]. To account for the shorter follow-up compared to UKPDS, drop-out, and loss to follow up during the intervention period the aim was to include 2000 patients in AdRem.

It should be noted that the blood pressure intervention part of UKPDS resulted in a larger difference in retinopathy progression compared to the glucose intervention. After 4.5 years of intervention, in those patients allocated to tight

Table 3  
Minimum quality requirements for retinal photographs in the AdRem study

---

#### Quality requirements

1. Focus and exposure are sufficient when microaneurysms are potentially detectable.
2. Gradable photographs are defined as at least gradable for large retina details (e.g. main vessels).
3. Stereoscopic effect is sufficient when retinal vessels appear above the retinal pigment epithelium.

#### Quality criteria

- Requirement 1 has to be achieved in fields 1, 2 and 3 for both images of each stereo-pair.
- Requirement 1 has to be achieved in at least 2 of the fields 4, 5, 6 and 7 for at least one image of each stereo-pair.
- Requirement 2 has not to be achieved in both fields of the following pairs: fields 4 and 5 or fields 4 and 7 or fields 5 and 6.
- Requirement 3 has to be achieved in at least field 1 and 2.

All four criteria have to be fulfilled before an eye can be graded.

---



blood pressure control 27.5% showed progression, compared to 36.7% in those with less tight control [20]. However, these were hypertensive patients, and the reduction in blood pressure in the ADVANCE study is expected to be smaller.

### 7.2. Data analysis

The primary endpoints of the AdRem study are progression of diabetic retinopathy (two steps on the modified ETDRS scale) and changes in retinal vascular pattern between baseline, 2 and 4.5 years of intervention. Tests will be performed separately for the effects of blood pressure lowering and glucose control. The primary tests will be for the main effect of one intervention (blood pressure lowering or glucose control), adjusted for the other intervention (glucose control or blood pressure lowering). Differences in follow-up time are handled by using survival analysis adjustments.

Exploratory analyses will be performed to investigate the combined effects of blood pressure lowering and glucose control, but the sample size of AdRem is probably too small to draw definite conclusions.

Analyses will be based on intention-to-treat, which will include all randomized subjects, except those who have taken no trial medication at all. Interim analyses are not planned. All analyses will be done with a two-sided level of significance of 0.05.

### 7.3. Sensitivity analyses

Not all patients included at baseline will have a follow-up photograph at the end of the study. In secondary analyses missing results will be estimated from baseline results and available follow-up data, notably obtained during the clinical visits of the main ADVANCE study. Using the estimated follow-up results in those patients with missing data, the statistical analyses will be repeated to evaluate the potentially improved statistical significance.

## 8. Results

In total 1978 patients have been included in AdRem. The initial aim was to include all eligible patients within 3 months of randomization, but because AdRem only started when about half the participants had already been randomized in the main ADVANCE study, this was achieved in approximately 75% of the AdRem patients.

The strict requirements for quality control (Table 3) were met in approximately 80% of the participants. Due to logistic problems at the participating centers, it was not possible to repeat the photography in all patients with insufficient images. In the final set of 1978 patients, the quality of 83.9% of the photographs was acceptable according to the predefined quality requirements. This percentage differed between the five ADVANCE regions: Australasia 64.5%, Canada 97.1%, China 78.6%, Europe Continental 88.3%, Europe Northern 91.1%. Follow-up photography will be performed in all 1978 included patients.

## 9. Discussion

### 9.1. Other intervention studies

The UKPDS was restricted to newly diagnosed patients. Therefore, diabetes in patients participating in the AdRem Study will be of longer standing and consequently associated with more severe retinal disease. Moreover, glycemic control in the intensive glucose group of the ADVANCE study is intended to be stricter than achieved in UKPDS. This allows us to investigate whether the incidence of retinopathy has a linear relationship with glycemic control up to current treatment recommendations (HbA1c <6.5%). Blood pressure lowering is studied over a wide range of blood pressure levels, whereas in the UKPDS only selected patients with hypertension were randomized into normal and strict blood pressure control. Therefore the AdRem Study will provide evidence on the balance of risks and benefits of more intensive blood pressure and glucose lowering compared to previously available data.

To our knowledge, only two other large-scale retinal photography intervention studies are currently underway in patients with diabetes type 2. The first is DIRECT (DIabetic REtinopathy Candesartan Trial), which will include 1600 such patients. However, this study is limited to the effects of blood pressure reduction only [29,30]. The recently started ACCORD trial (Action to Control Cardiovascular Risk in Diabetes) in the United States is quite similar to ADVANCE: a factorial design with strict glucose lowering and blood pressure reduction in relatively unselected patients with type 2

diabetes mellitus. ACCORD also includes a lipid lowering comparison [31]. The ACCORD-Eye substudy is very similar to the AdRem Study with an intended sample size of 4065. The main differences are lack of intermediate follow-up photographs and a stricter primary endpoint (3 steps on the ETDRS classification).

Compared to UKPDS the AdRem study has a shorter follow-up period, which is compensated by a more detailed photography protocol that allows identification of retinal lesions at an earlier stage. In spite of the strict quality control procedures, inclusion of centres in many different countries will probably result in somewhat reduced data quality compared to UKPDS and ACCORD. AdRem, DIRECT and ACCORD use the same photography technique and the same classification for grading of the images. This will enable pooling of the data to investigate associations in subgroups.

Only a few studies have been published on the effects of gliclazide and perindopril on the incidence and progression of retinopathy. In the previous decade gliclazide was compared to other sulfonylureas in a number of small clinical studies. The results were not conclusive, but indicated that gliclazide, while achieving the same glucose control, may have superior effects in the prevention or retardation of diabetic retinopathy [32,33]. ACE inhibition has been shown to be beneficial in diabetic retinopathy, probably because of a distinct renin-angiotensin system in the eye [34,35].

## 9.2. Retinal photography

The AdRem study is based on stereoscopic seven-field photography of both eyes. This procedure is considered the reference standard for diagnosing diabetic retinopathy in randomized clinical trials [36]. The UKPDS was limited to three photographic fields. It is evident that retinal photography is superior to fundoscopy for detection of small retinal lesions and observation of changes over time.[4] Stereoscopic images are required to accurately diagnose macular edema, which is limited by all techniques using non-stereo retinal imaging [37].

Several studies have evaluated alternative photographic strategies to seven-field photographs for evaluating diabetic retinopathy, including retinal imaging through a non-dilated pupil, or using either one to three photographs taken at 30°, 45°, or 60°. The results of these studies confirm that the procedure with seven field photographs is superior [38].

Until now vascular measurements have been limited to 45° photographs centered on the macula [10]. By this approach peripheral lesions cannot be detected, whereas early lesions probably often occur first at the outer regions.

For screening purposes simpler methods than seven-field photography are regarded sufficient to identify patients with vision-threatening lesions that require intervention [38]. As a result, screening for retinal lesions currently occurs more often with simpler techniques, including the use of low-resolution digital cameras, using one field only and without pupil dilation. Therefore, routinely acquired clinical photographs are usually unsuitable to investigate subtle changes over time.

In conclusion, the AdRem Study should provide clear answers to current questions on the prevention of microvascular diabetes complications in patients with diabetes mellitus type 2, notably the balance of risks and benefits of more intensive blood pressure and glucose lowering. The large number of patients, the extensive photography protocol and the central digital image processing will make the study a valuable resource to investigate other questions related to retinal lesions in patients with diabetes.

## Acknowledgments

ADVANCE is an investigator-designed and-conducted study, funded by grants from the Institut de Recherches Internationales Servier, and the National HealthMedical Research Council of Australia.

## Appendix A. AdRem staff

### *AdRem Investigators (project team)*

Dr. Ronald P. Stolk, Groningen/Utrecht, The Netherlands (principal investigator)

Dr. J. Kennedy Cruickshank, Manchester, United Kingdom (co-principal investigator)

Mr. Stephen J. Aldington, London, United Kingdom

Prof. Diederick E. Grobbee, Utrecht, The Netherlands (chair project team)

Prof. Alun D. Hughes, London, United Kingdom

Prof. Lu Juming, Beijing, China

Dr. Alice A. Stanton, Dublin, Ireland  
 Dr. Simon A.McG. Thom, London, United Kingdom  
 Dr. Johannes R. Vingerling, Rotterdam, The Netherlands

*Advisors:*

Prof. Paulus T.V.M. de Jong, Amsterdam, The Netherlands  
 Prof. Eva M. Kohner, London, United Kingdom

*AdRem Coordination Center*

Dr. Ronald P. Stolk (director AdRem Coordination Center)  
 Mrs. Truus Meijers (coordinator)  
 Mr. Frank R. Leus (data manager)  
 Mr. Peter Huisinga (data manager)  
 Dr. Mary J. van Schooneveld (advisor photo grading)  
 The AdRem Substudy Coordination Center is part of the Vascular Imaging Center of the Julius Center, University Medical Center Utrecht, the Netherlands.  
 Mrs. Karin M. Nijssen (head Vascular Imaging Center)

*ADVANCE Management Committee*

John Chalmers (Chairman) (Australia), Stephen MacMahon (Vice-Chairman) (Australia), Mark Cooper (Australia), Eleuterio Ferrannini (Italy), Paul Glasziou (Australia), Diederick Grobbee (Netherlands), Pavel Hamet (Canada), Stephen Harrap (Australia), Simon Heller (United Kingdom), Liu Lisheng (China), Giuseppe Mancina (Italy), Michel Marre (France), Carl Mogensen (Denmark), Bruce Neal (Australia), Chang Yu Pan (China), Anushka Patel (Australia), Neil Poulter (United Kingdom), Anthony Rodgers (New Zealand), and Mark Woodward (Australia).

**Appendix B. Participating AdRem centers with ADVANCE principal investigator and photographer between parentheses**

*Europe — Northern*

Tallinn, Estonia (Dr. U. Kaasik); Dublin, Ireland (Dr. A. Stanton, Dr. C. Thompson); Aberdeen, United Kingdom (Dr. M.J. MacLeod, A. Farrow, S. McKay); Birmingham, United Kingdom (Prof. G. Lip, I. Lightfoot); Liverpool, United Kingdom (Dr. J. Vora, S. Pearse, J. Sharp); London, United Kingdom (Dr. S. Thom, Dr. N. Witt); London, United Kingdom (Dr. D. Hopkins); Manchester, United Kingdom (Dr. J.K. Cruickshank, J. Gray); Sheffield, United Kingdom (Dr. S. Heller; Dr. C. Brand, C. Mody);

*Europe— Continental*

Paris, France (Prof. M. Marre, Dr. Z. Gureny-Victor); Poitiers, France (Dr. R. Marechaud, Dr. M. Boissonnot, Dr. H. Manic); Dresden, Germany (Prof. M. Hanefeld, Dr. U. Stier); Munich, Germany (Prof. C. von Schacky, Dr. Ulbig); Groningen, The Netherlands (Dr. W.M.T. Janssen, Dr. A.C. Houtman); Rotterdam, The Netherlands (Dr. J.J.C. Jonker, C. van Nieuwkerk); Katowice, Poland (Dr. M. Steuer); Nitra, Slovakia (Dr. M. Porubská, Dr Murgasova);

*China*

Center Hospital of Aviation of China (Wang Chengzhi, Wu Chunrong); 305 Hospital of Chinese P.L.A, Beijing (Yang Husheng, Han Suyi); Center of Endocrinology, Chinese PLA General Hospital (Tian Hui, Han Suyi); Shanghai Hypertension Institute (Wang Xianyan, Zhu Caihong); Aff. 2nd Hospital of Dalian Medical University (Liu Yuhui, Shi Tianwei); No. 1 Municipal Hospital Chengdu (Zhang Tingjie, Meng Dan); Dept. of Cardiology, Beijing 306 Hospital (Ge Hong, Wu Chunrong); Affi. Beijing Tongren Hospital (Yuan Shenyuan, Yan Wei); Beijing Hypertension League Institute (Wang Shuyu, Han Suyi); Jiuxianqiao Hospital, Beijing (Lu Hai, Wu Chunrong); Dept. of Endocrinology, Beijing 306 Hospital (Xu Zhangrong, Wu Chunrong); Aff. Ruijin Hospital of Shanghai, 2nd Med. Univ (Ning Guang, Zhu Caihong); Chang Zheng Hospital of Shanghai (Liu Zhimin, Zhu Caihong); 5th Internal Medicine of Chinese Air Force General Hospital (Shi Jinsheng, Han Suyi); First Hospital, West China University of Medical Sciences (Li Xiujun, Meng Dan);

### Australasia

Adelaide, Australia (Dr. A. Hoh, Dr J. Muecke); Chennai, India (Dr. V. Mohan, Dr. P. Kumar); New Delhi, India (Dr. N. Tandon, Dr P. Venkatesh); Kota Bharu Kelantan, Malaysia (Dr. A. Ismail, Prof W. Mohamad, Dr Wan Hazabah Hitam); Kuala Lumpur, Malaysia (Prof. K. Yusoff, Dr Zuraiha Mohd); Manila, Philippines (Dr. A. Litonjua, Dr. J. Aragon);

### Canada

Calgary, Canada (Dr. S.A. Ross, J. Baker)

## References

- [1] Early Photocoagulation for Diabetic-Retinopathy-Etdrs Report Number-9. *Ophthalmology* 1991;98:766–85.
- [2] Schachat AP, Hyman L, Leske MC, et al. Comparison of diabetic retinopathy detection by clinical examinations and photograph gradings Barbados (West Indies) Eye Study Group. *Arch Ophthalmol* 1993;111:1064–70.
- [3] Moss SE, Klein R, Kessler SD, Richie KA. Comparison between ophthalmoscopy and fundus photography in determining severity of diabetic retinopathy. *Ophthalmology* 1985;92:62–7.
- [4] Lee VS, Kingsley RM, Lee ET, et al. The diagnosis of diabetic-retinopathy — ophthalmoscopy versus fundus photography. *Ophthalmology* 1993;100:1504–12.
- [5] Kinyoun JL, Martin DC, Fujimoto WY, Leonetti DL. Ophthalmoscopy versus fundus photographs for detecting and grading diabetic-retinopathy. *Investig Ophthalmol Vis Sci* 1992;33:1888–93.
- [6] Stolk RP, Vingerling JR, de Jong PT, et al. Retinopathy, glucose, and insulin in an elderly population The Rotterdam Study. *Diabetes* 1995;44:11–5.
- [7] Klein R. Hyperglycemia and microvascular and macrovascular disease in diabetes. *Diabetes Care* 1995;18:258–68.
- [8] Sharrett AR, Hubbard LD, Cooper LS, et al. Retinal arteriolar diameters and elevated blood pressure: the Atherosclerosis Risk in Communities Study. *Am J Epidemiol* 1999;150:263–70.
- [9] Keith NM, Wagener HP, Barker MW. Some different types of essential hypertension: their course and prognosis. *Am J Med Sci* 1939;197:332–43.
- [10] Hubbard LD, Brothers RJ, King WN, et al. Methods for evaluation of retinal microvascular abnormalities associated with hypertension/sclerosis in the Atherosclerosis Risk in Communities Study. *Ophthalmology* 1999;106:2269–80.
- [11] Leung H, Wang JJ, Rochtchina E, Wong TY, Klein R, Mitchell P. Impact of current and past blood pressure on retinal arteriolar diameter in an older population. *J Hypertens* 2004;22:1543–9.
- [12] Ikram MK, de Voogd S, Wolfs RC, et al. Retinal vessel diameters and incident open-angle glaucoma and optic disc changes: the Rotterdam study. *Invest Ophthalmol Vis Sci* 2005;46:1182–7.
- [13] Stanton AV, Wasan B, Cerutti A, et al. Vascular network changes in the retina with age and hypertension. *J Hypertens* 1995;13:1724–8.
- [14] Chapman N, Dell'omo G, Sartini MS, et al. Peripheral vascular disease is associated with abnormal arteriolar diameter relationships at bifurcations in the human retina. *Clin Sci (Lond)* 2002;103:111–6.
- [15] Fong DS, Aiello L, Gardner TW, et al. Diabetic retinopathy. *Diabetes Care* 2003;26:226–9.
- [16] Stratton IM, Kohner EM, Aldington SJ, et al. UKPDS 50: risk factors for incidence and progression of retinopathy in Type II diabetes over 6 years from diagnosis. *Diabetologia* 2001;44:156–63.
- [17] UK Prospective Diabetes Study Group Intensive blood-glucose control with sulphonylureas or insulin compared with conventional treatment and risk of complications in patients with type 2 diabetes (UKPDS 33). *Lancet* 1998;352:837–53.
- [18] Standards of medical care in diabetes. *Diabetes Care* 2005;28(Suppl 1):S4–S36.
- [19] Clemens A, Siegel E, Gallwitz B. Global risk management in type 2 diabetes: blood glucose, blood pressure, and lipids-update on the background of the current guidelines. *Exp Clin Endocrinol Diabetes* 2004;112:493–503.
- [20] UK Prospective Diabetes Study Group Tight blood pressure control and risk of macrovascular and microvascular complications in type 2 diabetes: UKPDS 38. *BMJ* 1998;317:703–13.
- [21] Study rationale and design of ADVANCE: action in diabetes and vascular disease-preterax and diamicon MR controlled evaluation. *Diabetologia* 2001;44:1118–20.
- [22] ADVANCE—Action in Diabetes and Vascular Disease: patient recruitment and characteristics of the study population at baseline. *Diabet Med* 2005;22:882–8.
- [23] Grading diabetic retinopathy from stereoscopic color fundus photographs — an extension of the modified Airlie House classification ETDRS report number 10 Early Treatment Diabetic Retinopathy Study Research Group. *Ophthalmology* 1991;98:786–806.
- [24] Parr JC, Spears GF. General caliber of the retinal arteries expressed as the equivalent width of the central retinal artery. *Am J Ophthalmol* 1974;77:472–7.
- [25] Knudtson MD, Lee KE, Hubbard LD, Wong TY, Klein R, Klein BE. Revised formulas for summarizing retinal vessel diameters. *Curr Eye Res* 2003;27:143–9.
- [26] Leung H, Wang JJ, Rochtchina E, et al. Computer-assisted retinal vessel measurement in an older population: correlation between right and left eyes. *Clin Experiment Ophthalmol* 2003;31:326–30.
- [27] Chapman N, Witt N, Gao X, et al. Computer algorithms for the automated measurement of retinal arteriolar diameters. *Br J Ophthalmol* 2001;85:74–9.
- [28] Gao XW, Bharath A, Stanton A, Hughes A, Chapman N, Thom S. Quantification and characterisation of arteries in retinal images. *Comput Methods Programs Biomed* 2000;63:133–46.

- [29] Chaturvedi N, Sjoelie AK, Svensson A. The Diabetic Retinopathy Candesartan Trials (DIRECT) Programme, rationale and study design. *J Renin Angiotensin Aldosterone Syst* 2002;3:255–61.
- [30] Sjoelie AK, Porta M, Parving HH, Bilous R, Klein R. The Diabetic REtinopathy Candesartan Trials (DIRECT) Programme: baseline characteristics. *J Renin Angiotensin Aldosterone Syst* 2005;6:25–32.
- [31] Action to Control Cardiovascular Risk in Diabetes (ACCORD). [www.accordtrial.org](http://www.accordtrial.org).
- [32] Akanuma Y, Kosaka K, Kanazawa Y, Kasuga M, Fukuda M, Aoki S. Diabetic retinopathy in non-insulin-dependent diabetes mellitus patients: the role of gliclazide. *Am J Med* 1991;90:74S–6S.
- [33] Palmer KJ, Brogden RN. Gliclazide An update of its pharmacological properties and therapeutic efficacy in non-insulin-dependent diabetes mellitus. *Drugs* 1993;46:92–125.
- [34] Chaturvedi N, Sjoelie AK, Stephenson JM, et al. Effect of lisinopril on progression of retinopathy in normotensive people with type 1 diabetes The EUCLID Study Group EURODIAB Controlled Trial of Lisinopril in Insulin-Dependent Diabetes Mellitus. *Lancet* 1998;351:28–31.
- [35] Funatsu H, Yamashita H. Pathogenesis of diabetic retinopathy and the renin–angiotensin system. *Ophthalmic Physiol Opt* 2003;23:495–501.
- [36] Lin DY, Blumenkranz MS, Brothers RJ, Grosvenor DM. The sensitivity and specificity of single-field nonmydriatic monochromatic digital fundus photography with remote image interpretation for diabetic retinopathy screening: a comparison with ophthalmoscopy and standardized mydriatic color photography. *Am J Ophthalmol* 2002;134:204–13.
- [37] Stellingwerf C, Hardus PL, Hooymans JM. Two-field photography can identify patients with vision-threatening diabetic retinopathy: a screening approach in the primary care setting. *Diabetes Care* 2001;24:2086–90.
- [38] Moller F, Hansen M, Sjoelie AK. Is one 60 degrees fundus photograph sufficient for screening of proliferative diabetic retinopathy? *Diabetes Care* 2001;24:2083–5.